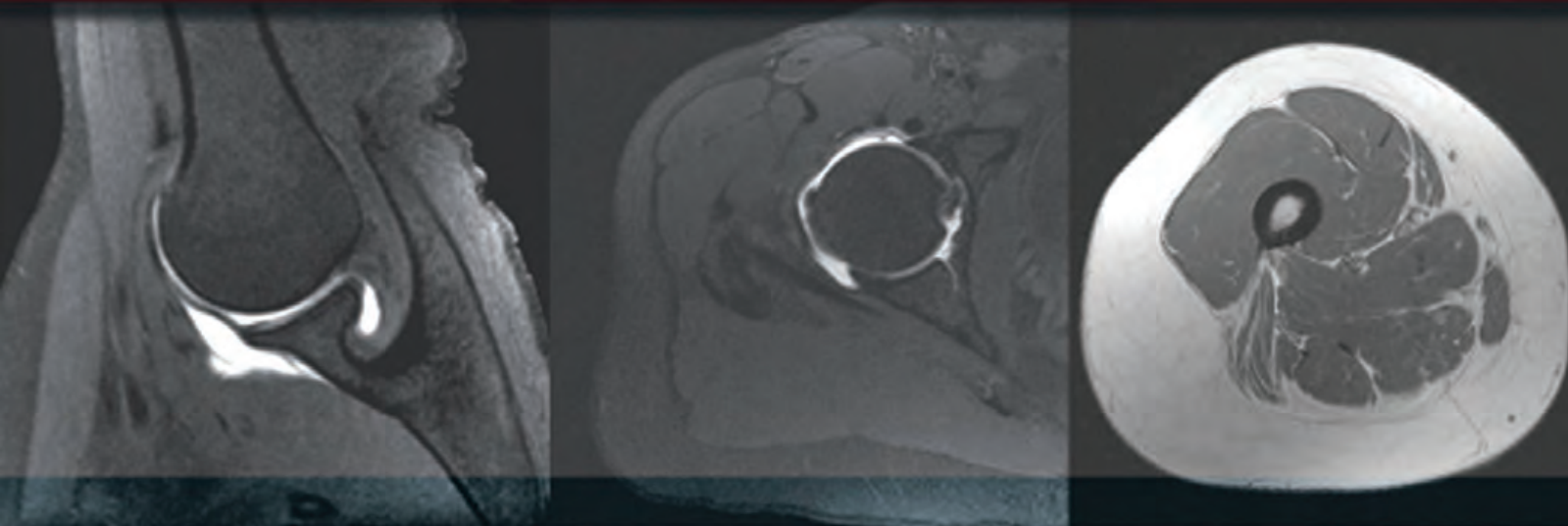


FOURTH EDITION

SECTIONAL ANATOMY

by MRI and CT



MARK W. ANDERSON • MICHAEL G. FOX

ELSEVIER

CLINICAL **KEY**[™]

Smarter search. Faster answers.



Smarter, Faster Search for Better Patient Care

**Unlike a conventional search engine, ClinicalKey
is specifically designed to serve doctors by providing
three core components:**

**1 Comprehensive
Content**

The most current, evidence-based answers available for every medical and surgical specialty.

**2 Trusted
Answers**

Content supplied by Elsevier, the world's leading provider of health and science information.

**3 Unrivaled Speed
to Answer**

Faster, more relevant clinical answers, so you can spend less time searching and more time caring for patients.

Start searching with ClinicalKey today!

Visit ClinicalKey.com for more information and subscription options.

ELSEVIER

The background of the slide is a green geometric pattern consisting of overlapping triangles and hexagons, creating a textured, crystalline effect. The colors range from a light, pale green to a darker, forest green.

Sectional Anatomy by MRI and CT

This page intentionally left blank

Sectional Anatomy by MRI and CT

Fourth Edition

Mark W. Anderson, MD

Harrison Distinguished Teaching Professor of Radiology
Chief, Musculoskeletal Imaging
Professor of Orthopaedic Surgery
University of Virginia
Charlottesville, Virginia

Michael G. Fox, MD

Associate Professor of Radiology and Medical Imaging
Associate Professor of Orthopaedic Surgery
University of Virginia
Charlottesville, Virginia

ELSEVIER

ELSEVIER

1600 John F. Kennedy Blvd.
Ste 1800
Philadelphia, PA 19103-2899

SECTIONAL ANATOMY BY MRI AND CT, FOURTH EDITION

ISBN: 978-0-323-39419-2

Copyright © 2017 by Elsevier, Inc. All rights reserved.

No part of this publication may be reproduced or transmitted in any form or by any means, electronic or mechanical, including photocopying, recording, or any information storage and retrieval system, without permission in writing from the publisher. Details on how to seek permission, further information about the Publisher's permissions policies and our arrangements with organizations such as the Copyright Clearance Center and the Copyright Licensing Agency, can be found at our website: www.elsevier.com/permissions.

This book and the individual contributions contained in it are protected under copyright by the Publisher (other than as may be noted herein).

Notices

Knowledge and best practice in this field are constantly changing. As new research and experience broaden our understanding, changes in research methods, professional practices, or medical treatment may become necessary.

Practitioners and researchers must always rely on their own experience and knowledge in evaluating and using any information, methods, compounds, or experiments described herein. In using such information or methods they should be mindful of their own safety and the safety of others, including parties for whom they have a professional responsibility.

With respect to any drug or pharmaceutical products identified, readers are advised to check the most current information provided (i) on procedures featured or (ii) by the manufacturer of each product to be administered, to verify the recommended dose or formula, the method and duration of administration, and contraindications. It is the responsibility of practitioners, relying on their own experience and knowledge of their patients, to make diagnoses, to determine dosages and the best treatment for each individual patient, and to take all appropriate safety precautions.

To the fullest extent of the law, neither the Publisher nor the authors, contributors, or editors, assume any liability for any injury and/or damage to persons or property as a matter of products liability, negligence or otherwise, or from any use or operation of any methods, products, instructions, or ideas contained in the material herein.

Previous editions copyrighted 2007, 1995, and 1990.

Library of Congress Cataloging-in-Publication Data

Names: Anderson, Mark W., 1957- , author. | Fox, Michael G., author. | El-Khoury, Georges Y. Sectional anatomy by MRI and CT. Preceded by (work):
Title: Sectional anatomy by MRI and CT / Mark W. Anderson, Michael G. Fox.
Description: Fourth edition. | Philadelphia, PA : Elsevier, [2017] | Includes index. | Preceded by Sectional anatomy by MRI and CT / Georges Y. El-Khoury, William J. Montgomery, Ronald A. Bergman. 3rd ed. 2007.
Identifiers: LCCN 2015049199 | ISBN 9780323394192 (hardcover : alk. paper)
Subjects: | MESH: Anatomy, Regional | Magnetic Resonance Imaging | Tomography, X-Ray Computed | Atlases
Classification: LCC QM25 | NLM QS 17 | DDC 611/.90222--dc23
LC record available at <http://lcn.loc.gov/2015049199>

Content Strategist: Robin Carter
Content Development Specialist: Kathryn DeFrancesco
Publishing Services Manager: Catherine Jackson
Senior Project Manager: Daniel Fitzgerald
Designer: Paula Catalano

Printed in China

Last digit is the print number: 9 8 7 6 5 4 3 2 1



Working together
to grow libraries in
developing countries

www.elsevier.com • www.bookaid.org

Preface

With the explosion of cross-sectional imaging, the accessibility of a high quality anatomic atlas has become essential and it is with great pleasure that we introduce the fourth edition of this classic atlas.

Since it was first published in 1990, it has become a standard anatomic reference source. The first three editions were masterfully edited by Drs. Georges El-Khoury, Ronald Bergman, and William Montgomery, and we are honored to be able to continue the tradition of excellence that they established.

New features in this fourth edition include color-coded labeling and a corresponding online version that allows for easy access anytime/anywhere and provides features such as scroll, zoom, and search functions that should further enhance the user's experience.

We hope that you will find this new edition to be an integral and valuable addition to your practice.

Mark W. Anderson, MD
Michael G. Fox, MD

Acknowledgments

We are indebted to Drs. El-Khoury and Bergman for their prior efforts in producing and improving this text and for allowing us to continue along the path of excellence they established. We also thank Robin Carter, Katie DeFrancesco, and Dan Fitzgerald

from Elsevier for helping to bring this project to fruition. Without their invaluable assistance, it wouldn't have happened!

Mark W. Anderson, MD
Michael G. Fox, MD

Contents

SECTION I UPPER EXTREMITY

Chapter 1 MRI of the Pectoral Girdle and Chest Wall, 3

Axial, 4
Sagittal, 14
Coronal, 24

Chapter 2 MRI of the Shoulder, 34

Axial, 36
Oblique Sagittal, 46
Oblique Coronal, 56

Chapter 3 MR Arthrography of the Shoulder, 66

Axial, 67
Oblique Sagittal, 72
Oblique Coronal, 78
ABER (Abduction and External Rotation), 84

Chapter 4 MRI of the Arm, 90

Axial, 92
Sagittal, 98
Coronal, 105

Chapter 5 MRI of the Elbow, 114

Axial, 115
Oblique Sagittal, 125
Oblique Coronal, 134

Chapter 6 MRI of the Forearm, 143

Axial, 146
Sagittal, 156
Coronal, 162

Chapter 7 MRI of the Wrist, 170

Axial, 171
Sagittal, 180
Coronal, 189

Chapter 8 MRI of the Hand, 196

Axial, 198
Sagittal, 205
Coronal, 214

SECTION II LOWER EXTREMITY

Chapter 9 MRI of the Hip, 221

Axial, 224
Sagittal, 233
Coronal, 243

Chapter 10 MR Arthrography of the Hip, 250

Axial, 251
Sagittal, 257
Coronal, 262

Chapter 11 MRI of the Thigh, 267

Axial, 269
Sagittal, 277
Coronal, 286

Chapter 12 MRI of the Knee, 294

Axial, 295
Sagittal, 302
Coronal, 311

Chapter 13 MRI of the Leg, 321

Axial, 324
Sagittal, 334
Coronal, 342

Chapter 14 MRI of the Ankle, 348

Axial, 349
Oblique Axial, 359
Sagittal, 365
Coronal, 372

Chapter 15 MRI of the Foot, 381

Axial, 385
Sagittal, 391
Coronal, 399

SECTION III SPINE AND BACK

Chapter 16 MRI of the Thoracic Spine, 411

Axial, 415
Sagittal, 417
Coronal, 420

Chapter 17 MRI of the Lumbar Spine, 424

Axial, 425
Sagittal, 429
Coronal, 432

SECTION IV THORAX

Chapter 18 CT of the Thorax, 441

Axial, 442
Sagittal, 449
Coronal, 453

Chapter 19 MRI of the Heart, 459

Axial, 460
Sagittal, 464
Coronal, 467

SECTION V ABDOMEN

Chapter 20 CT of the Abdomen, 473

Axial, 475
Sagittal, 481
Coronal, 487

Chapter 21 MRI of the Abdomen, 493

Axial, 494
Sagittal, 502
Coronal, 510

SECTION VI PELVIS

Chapter 22 CT of the Male Pelvis, 521

Axial, 522
Sagittal, 528
Coronal, 531

Chapter 23 CT of the Female Pelvis, 537

Axial, 538
Sagittal, 543
Coronal, 546

Chapter 24 MRI of the Male Pelvis, 552

Axial, 553
Sagittal, 559
Coronal, 565

Chapter 25 MRI of the Female Pelvis, 571

Axial, 572
Sagittal, 576
Coronal, 580

Index, 585

Section
I

Upper Extremity

This page intentionally left blank

Chapter
1

**MRI of the Pectoral Girdle
and Chest Wall**

AXIAL

Figure 1.1.1

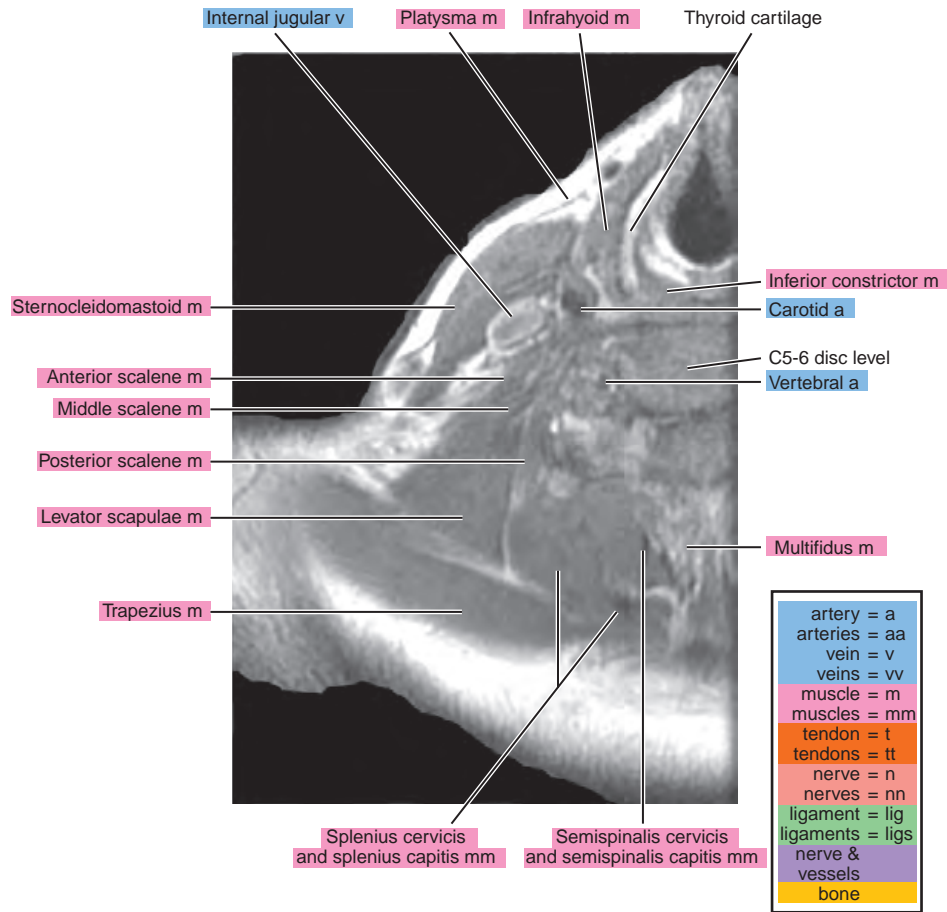
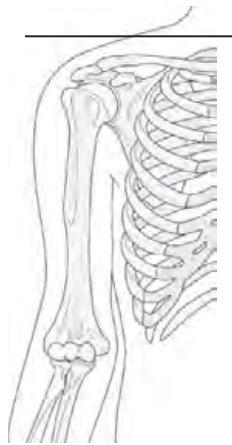

Figure 1.1.2

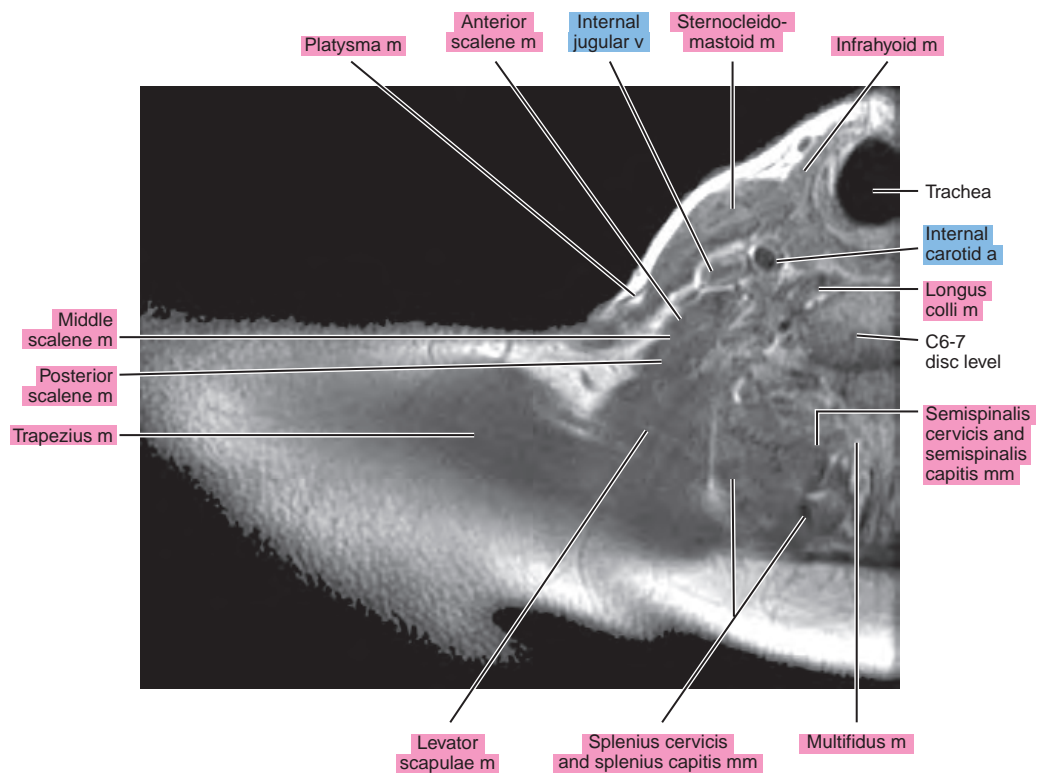
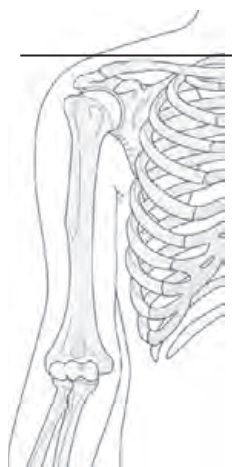


Figure 1.1.3

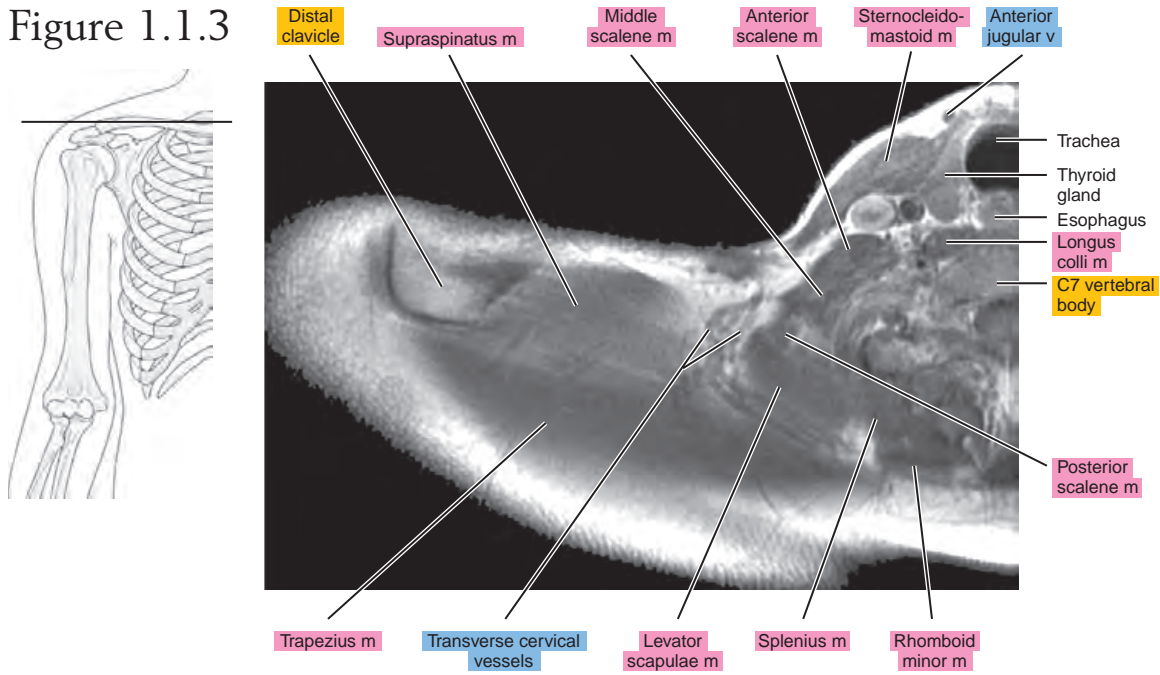


Figure 1.1.4

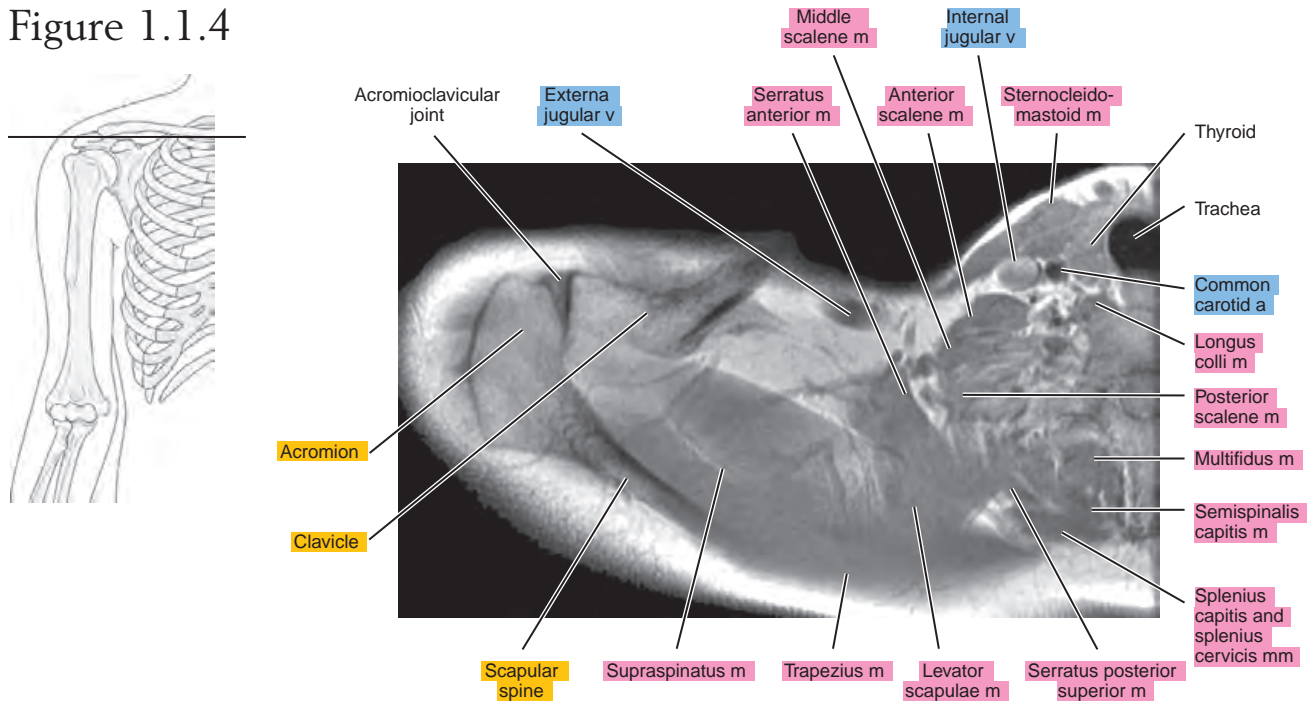


Figure 1.1.5

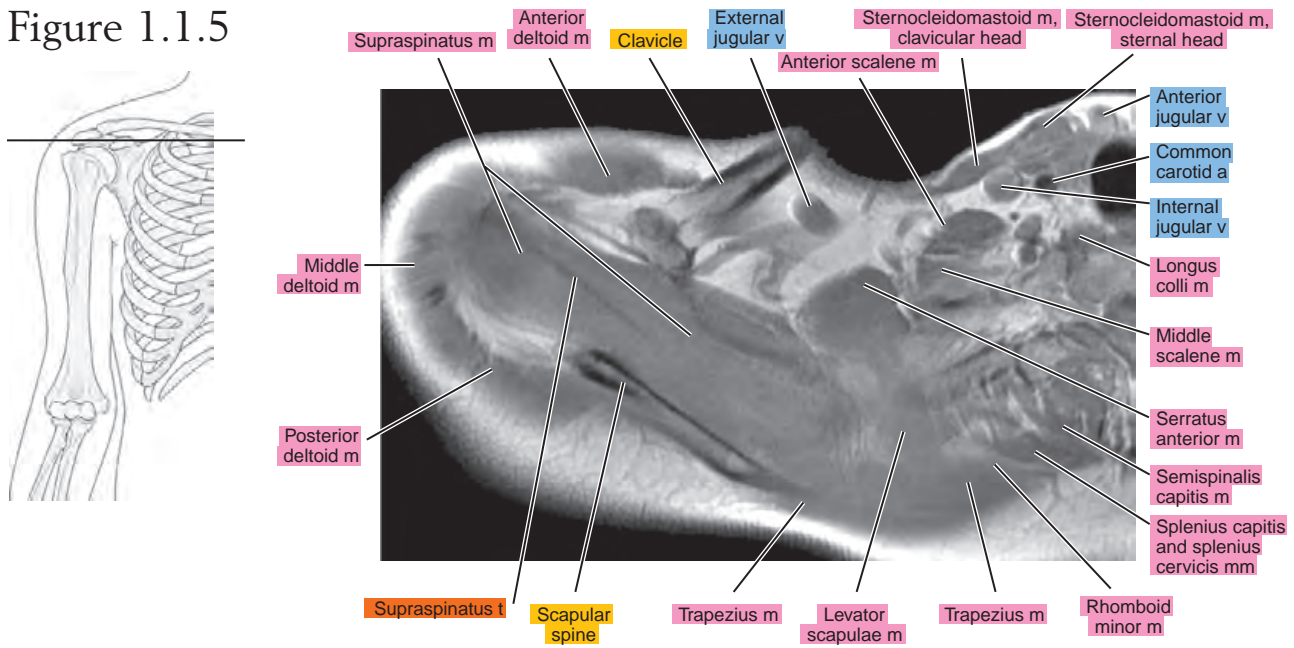


Figure 1.1.6

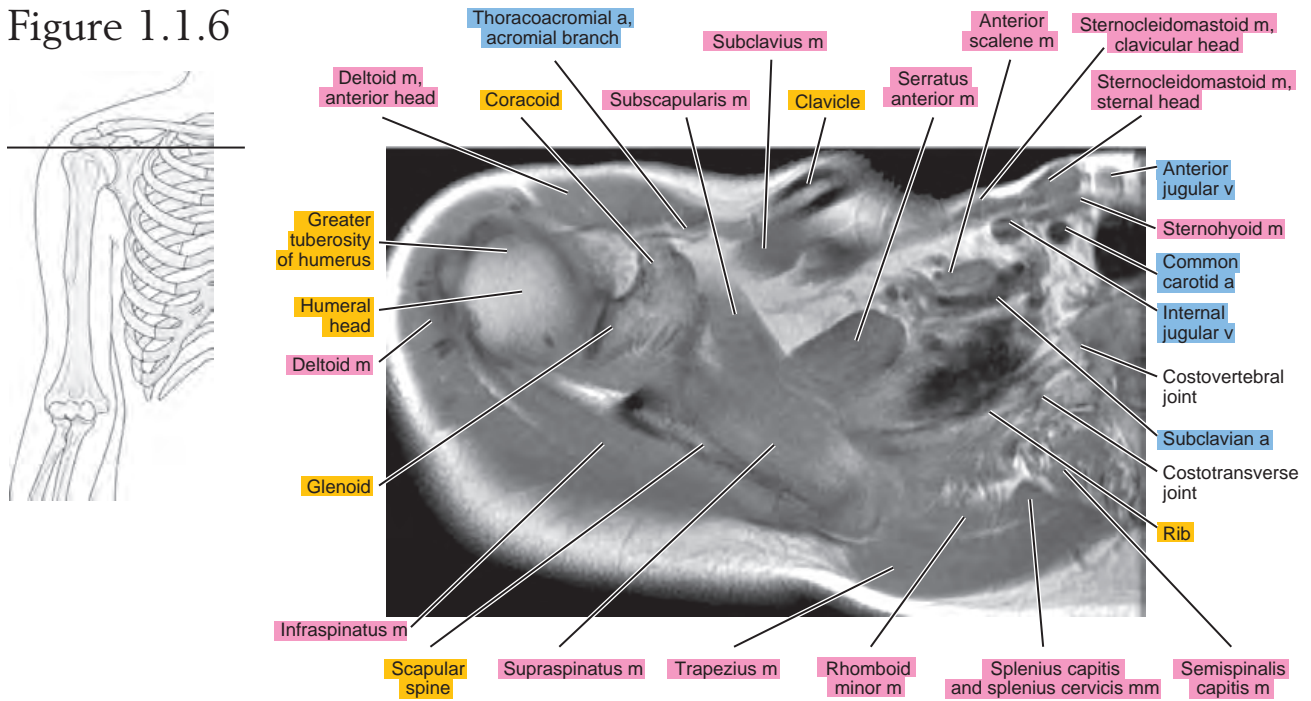


Figure 1.1.7

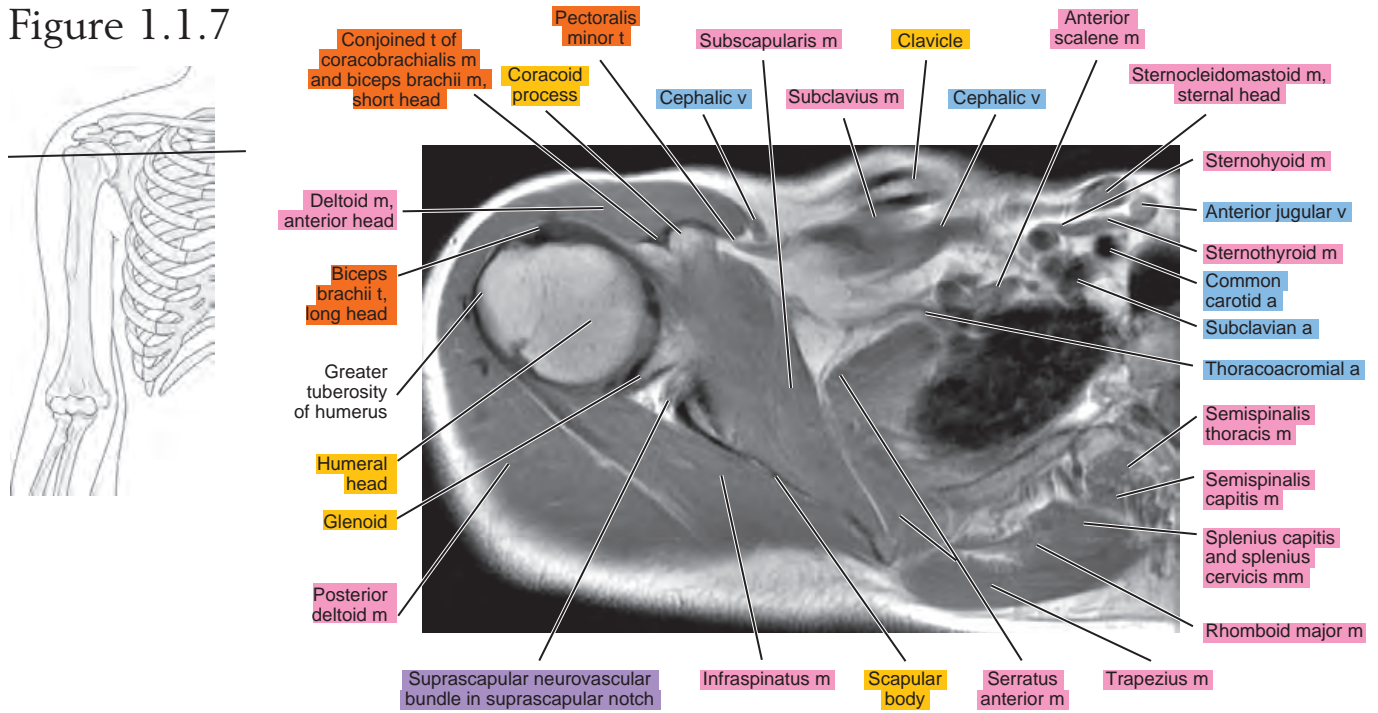


Figure 1.1.8

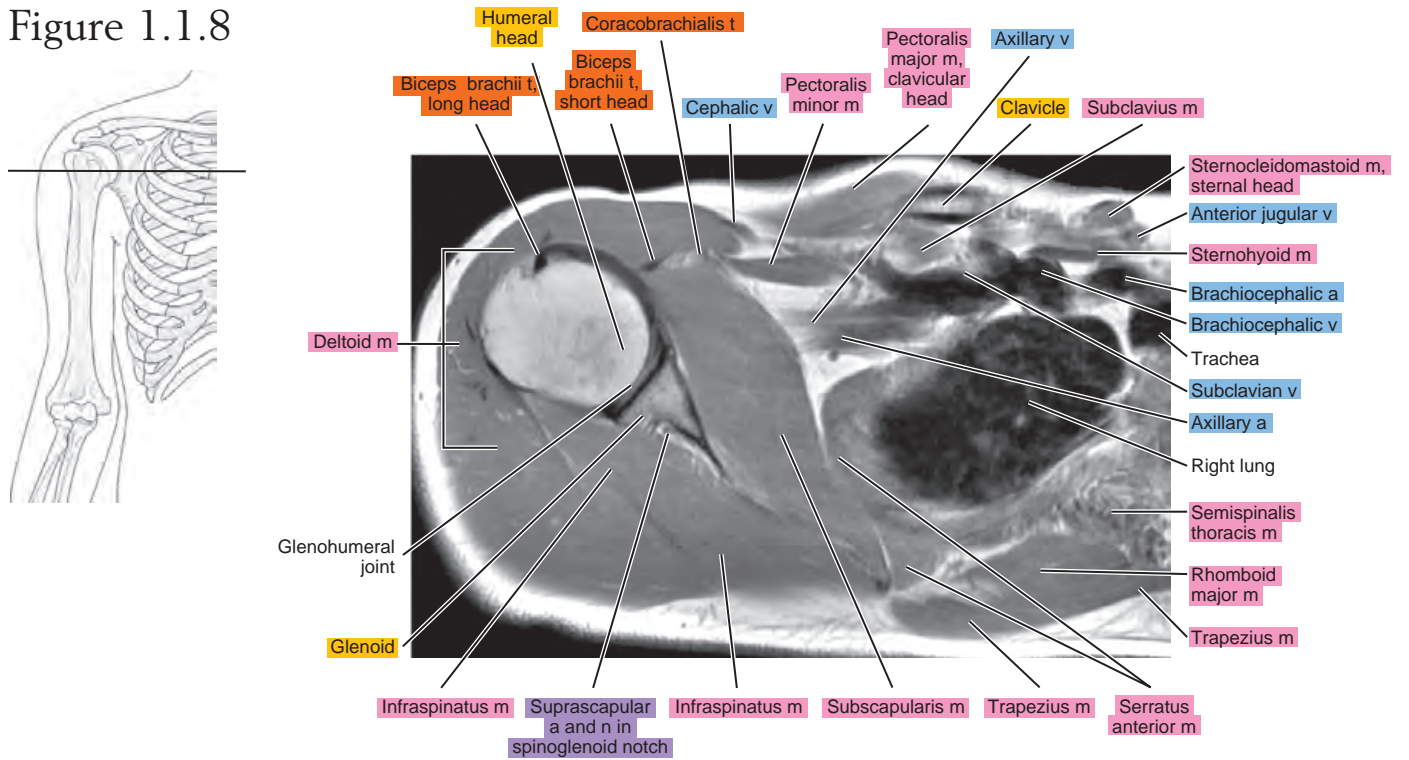


Figure 1.1.9

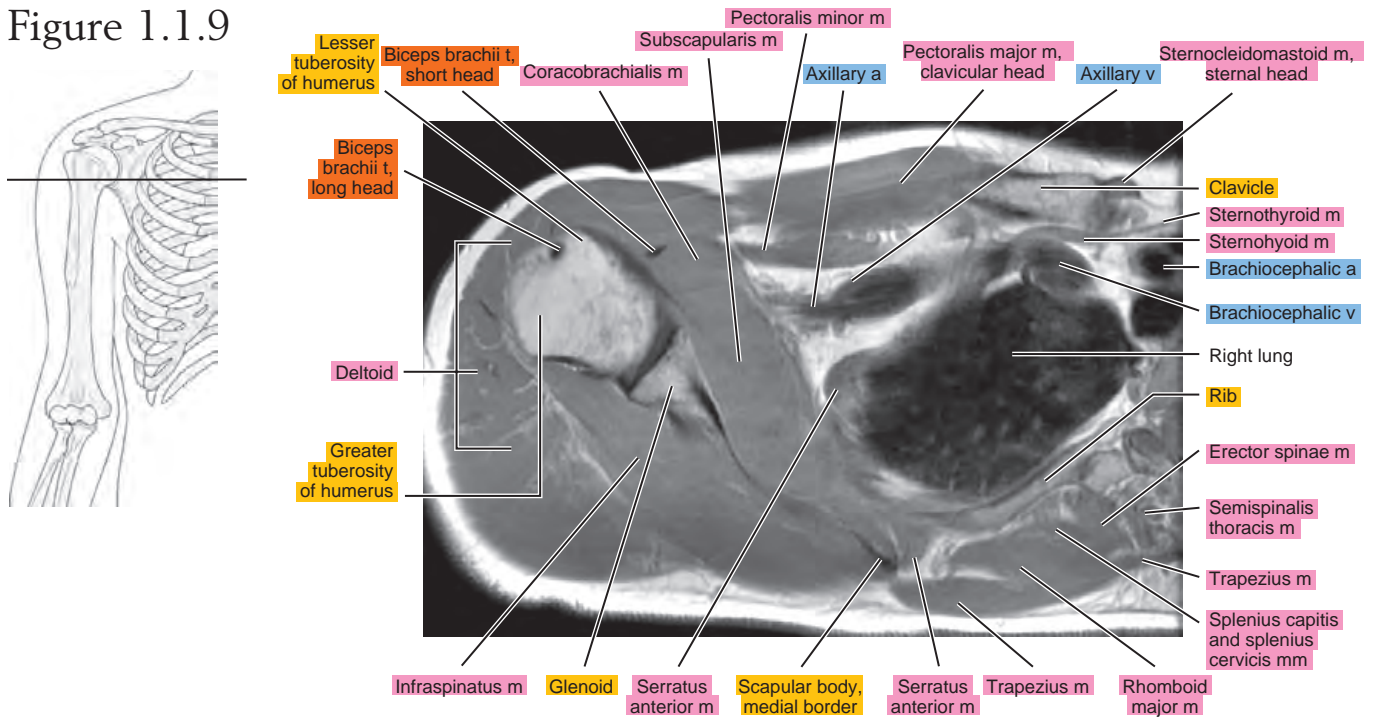


Figure 1.1.10

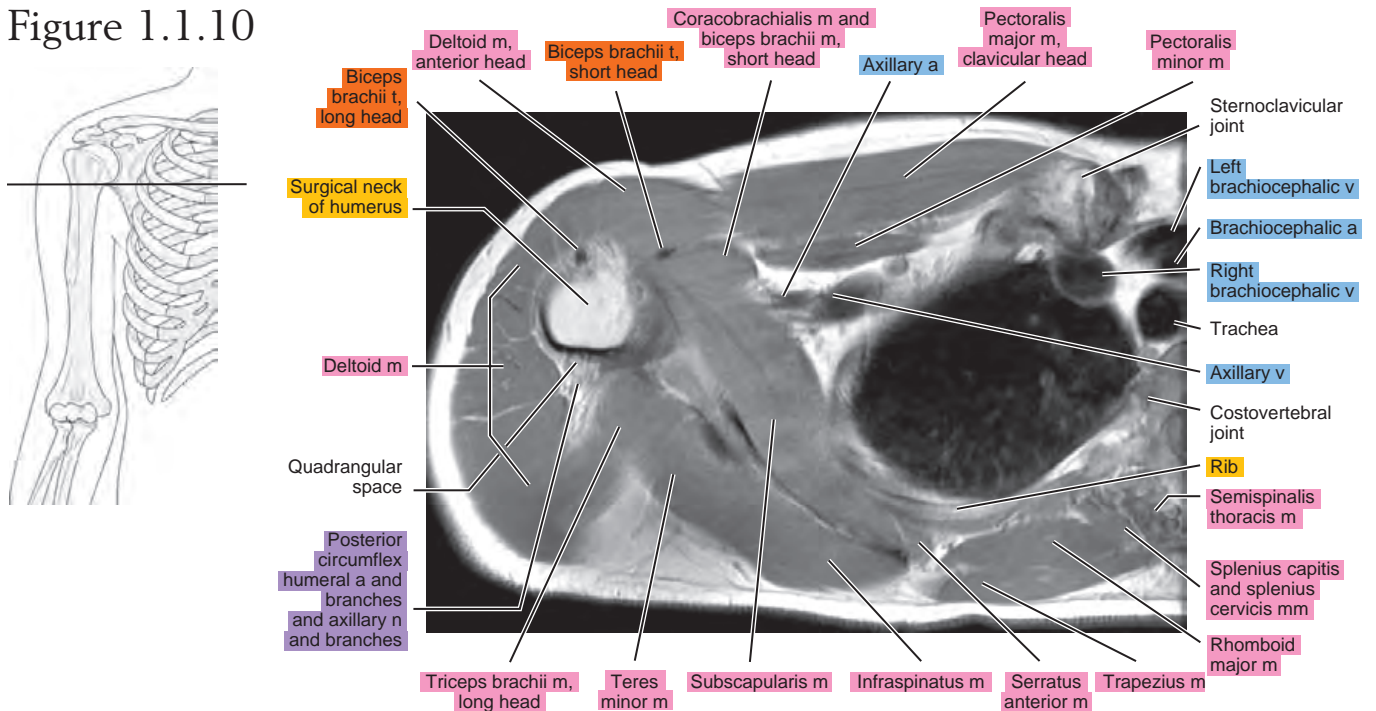


Figure 1.1.11

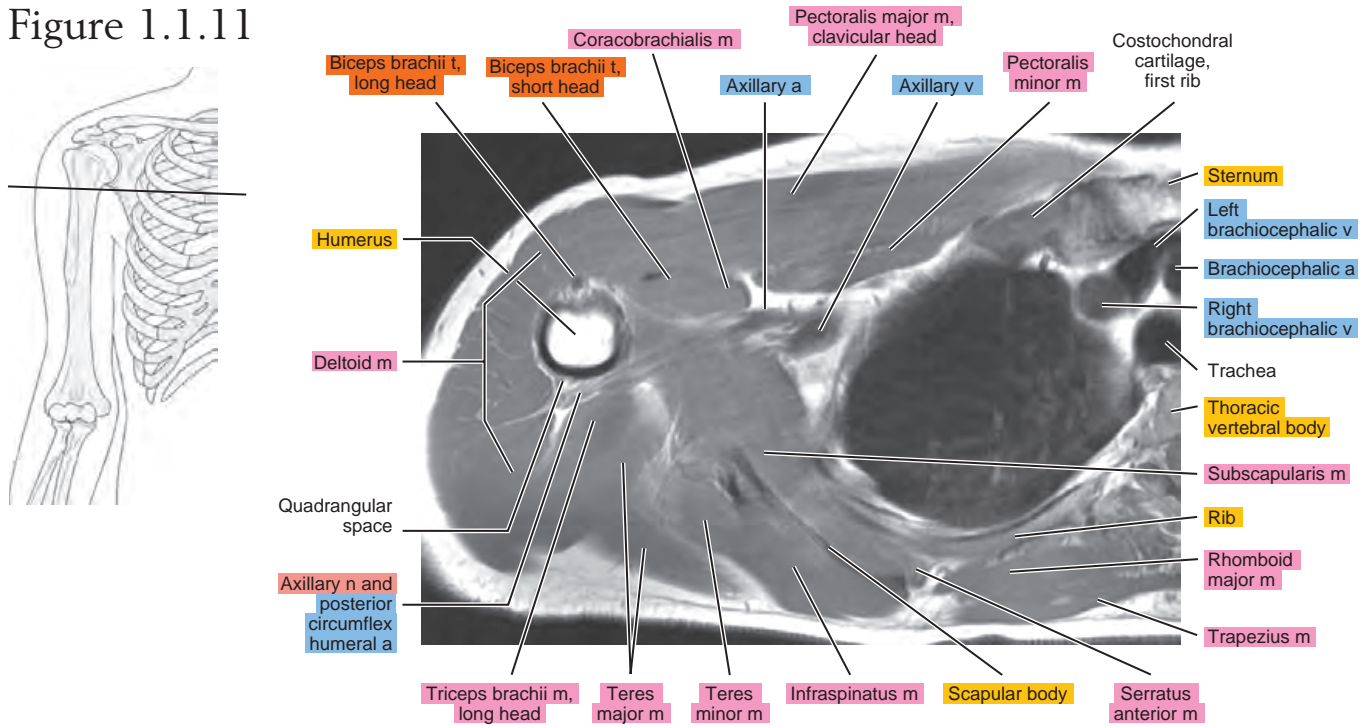


Figure 1.1.12

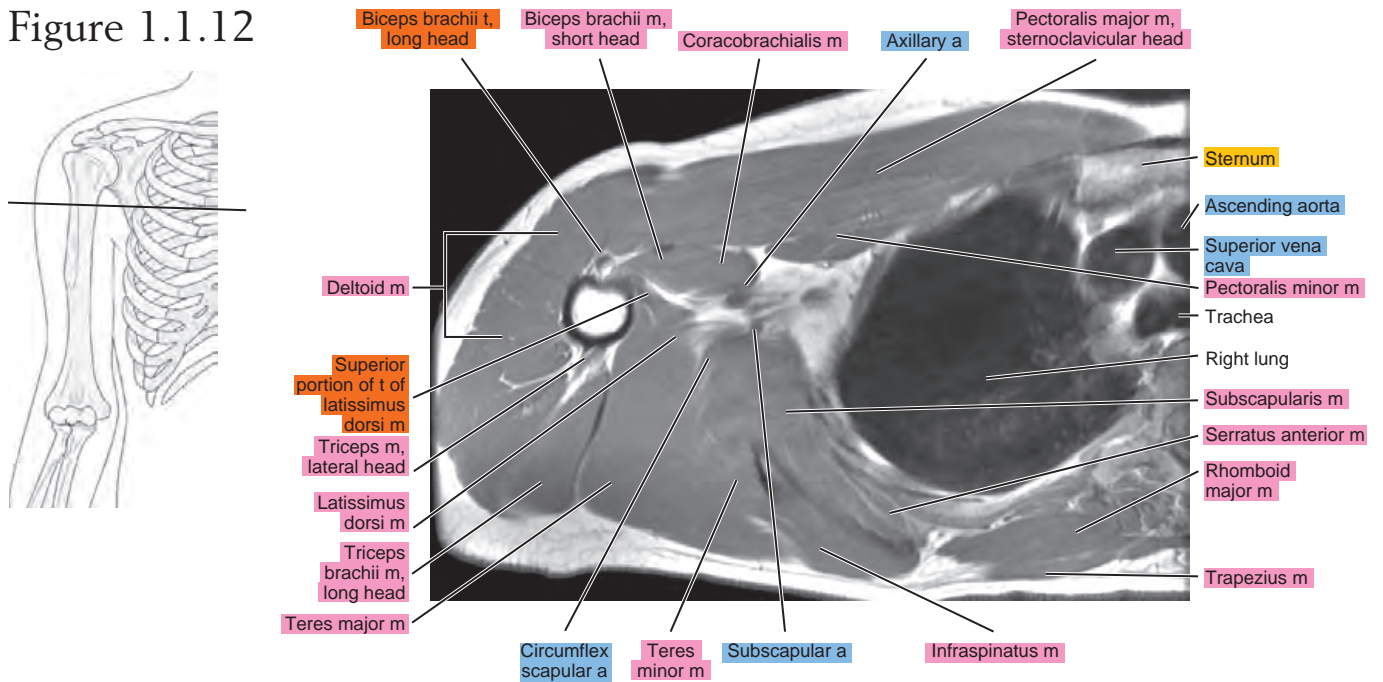


Figure 1.1.13

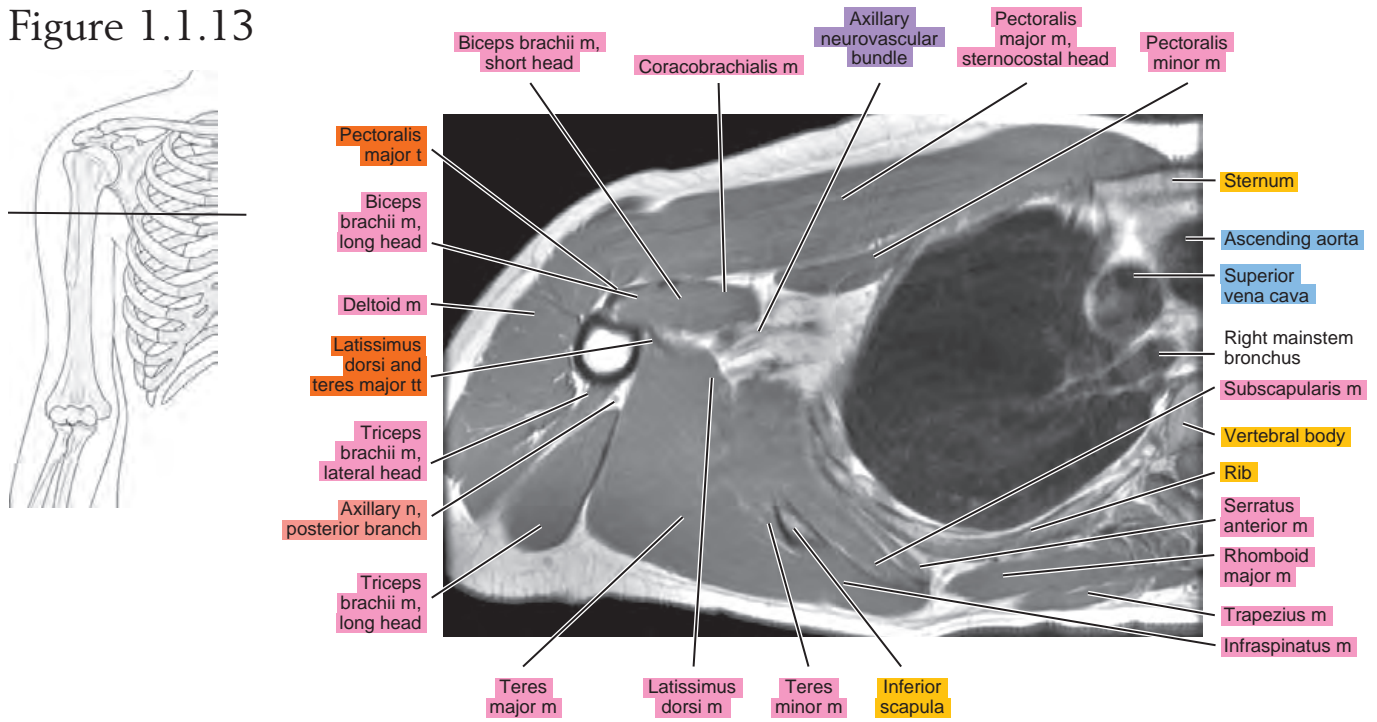


Figure 1.1.14

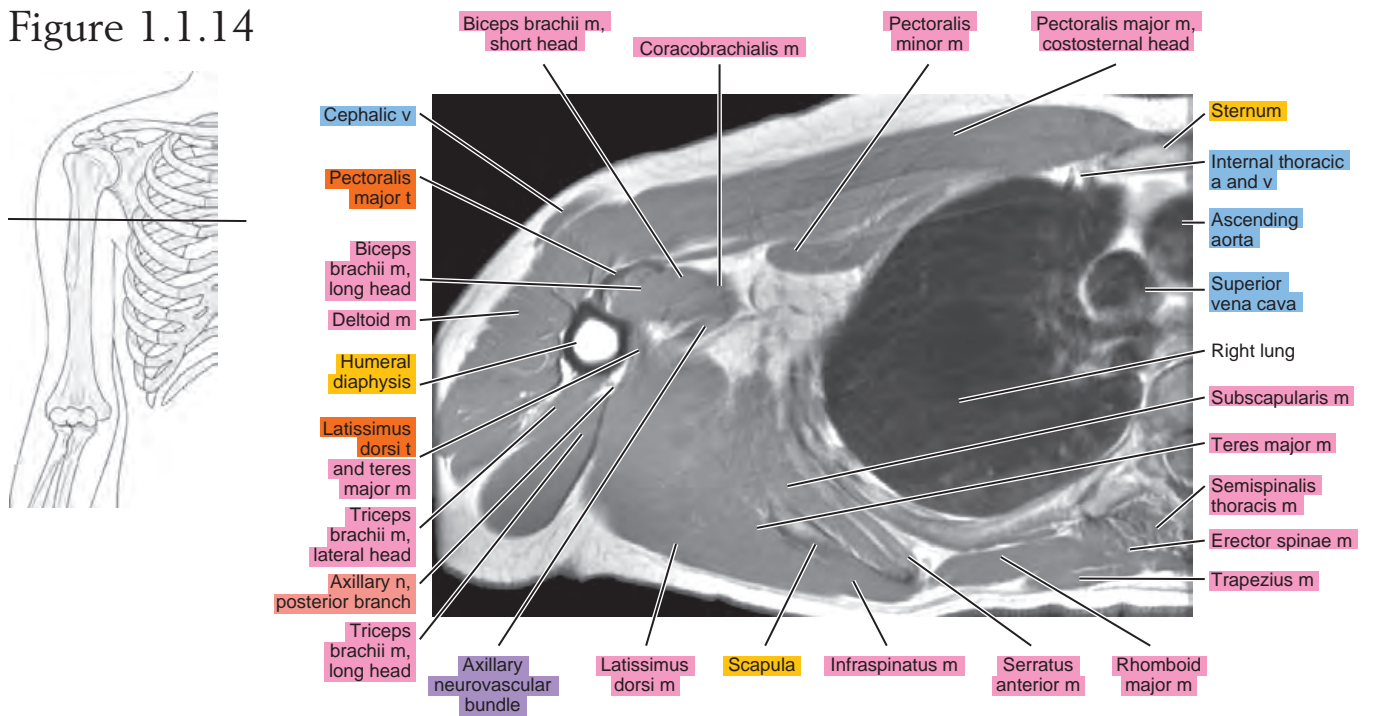


Figure 1.1.15

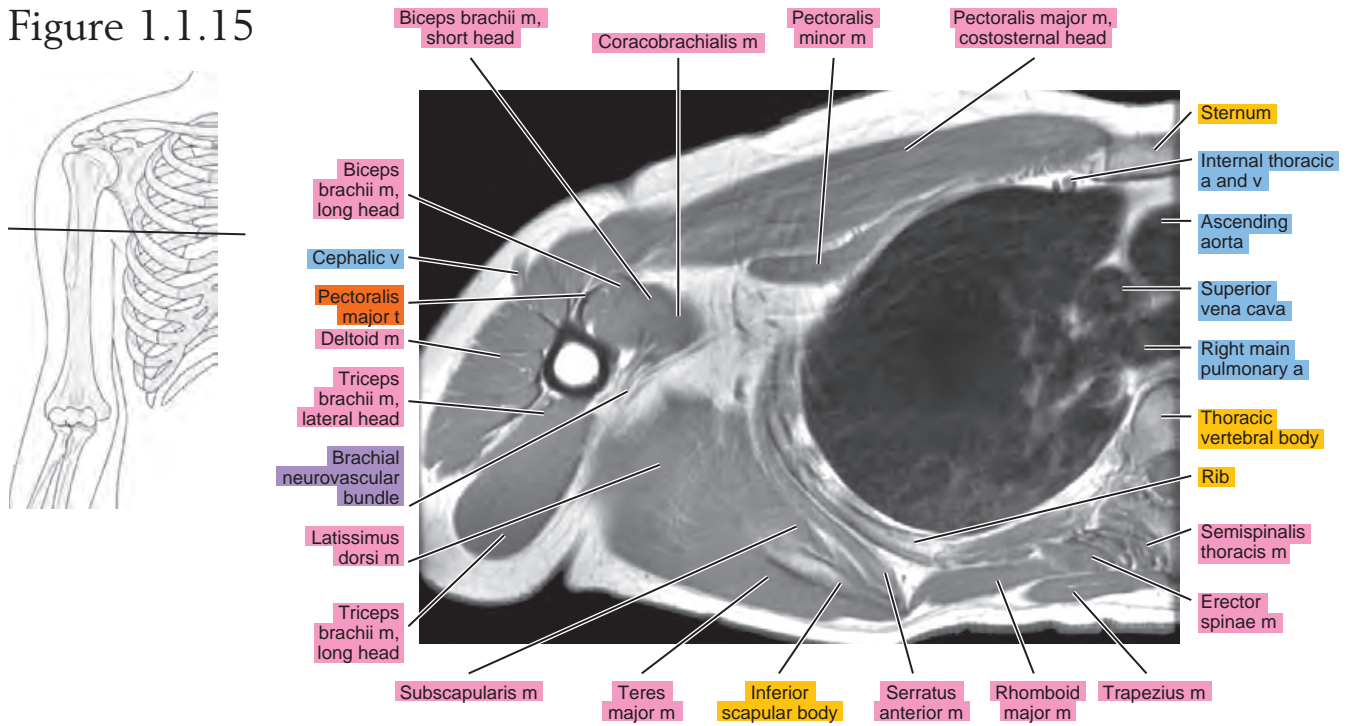


Figure 1.1.16

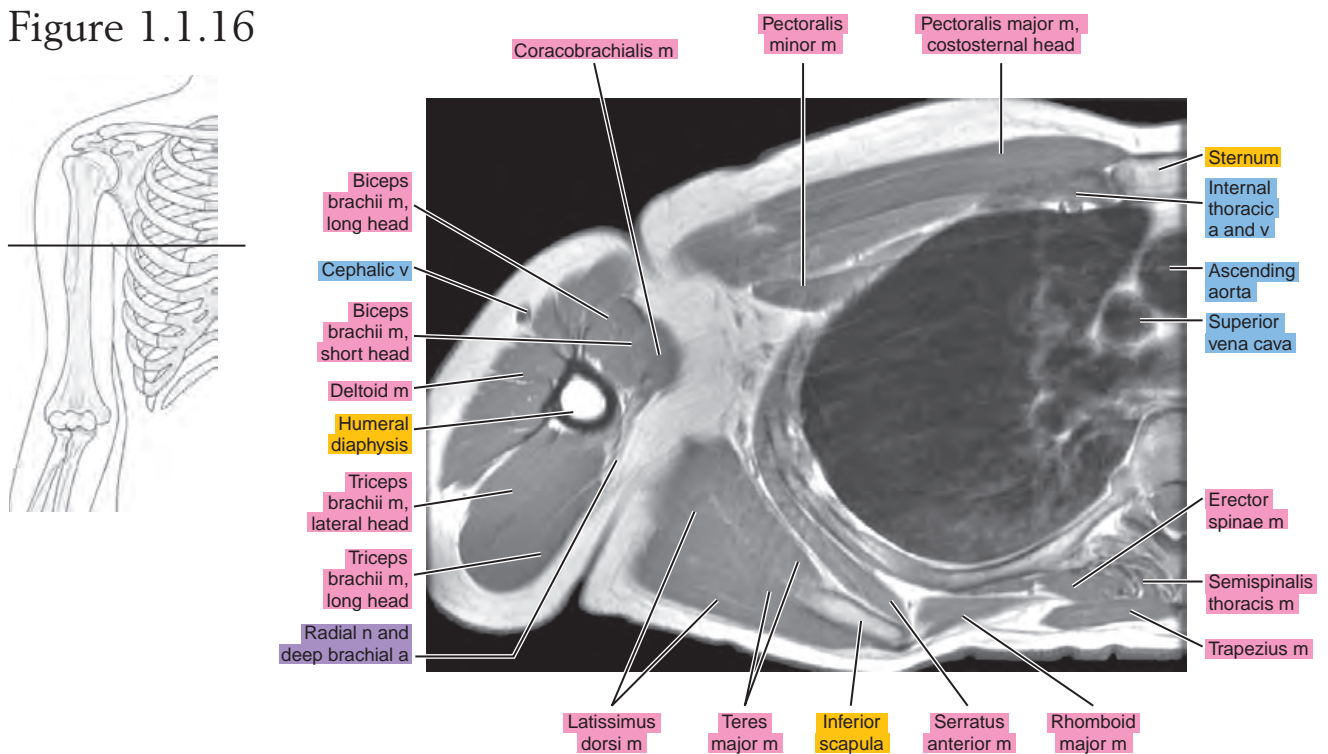


Figure 1.1.17

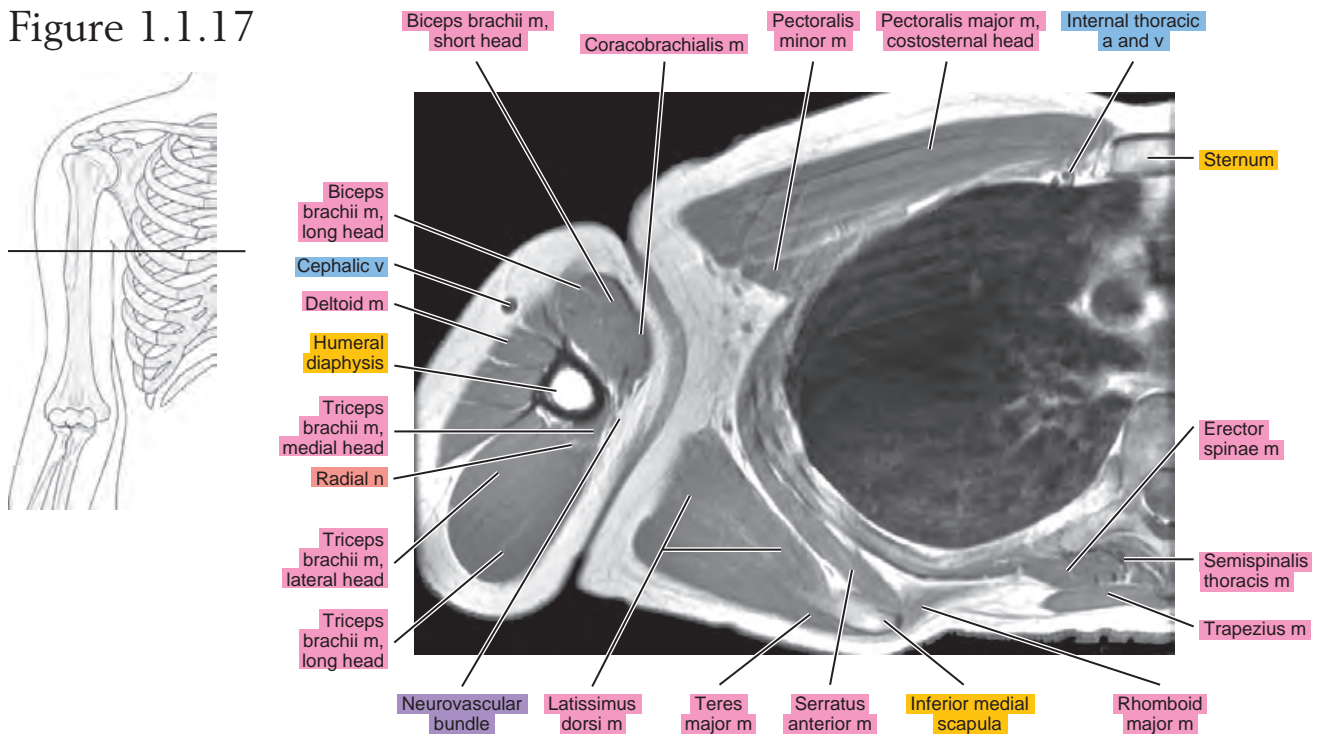


Figure 1.1.18

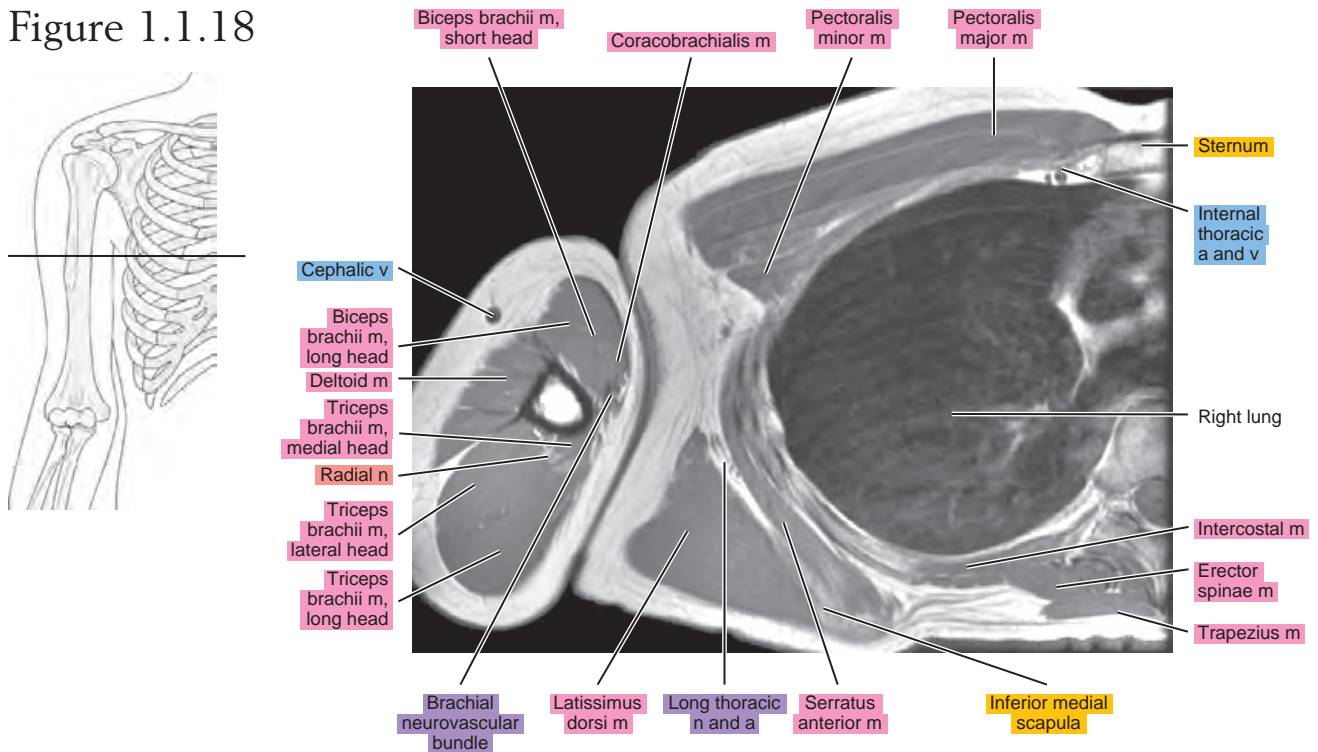
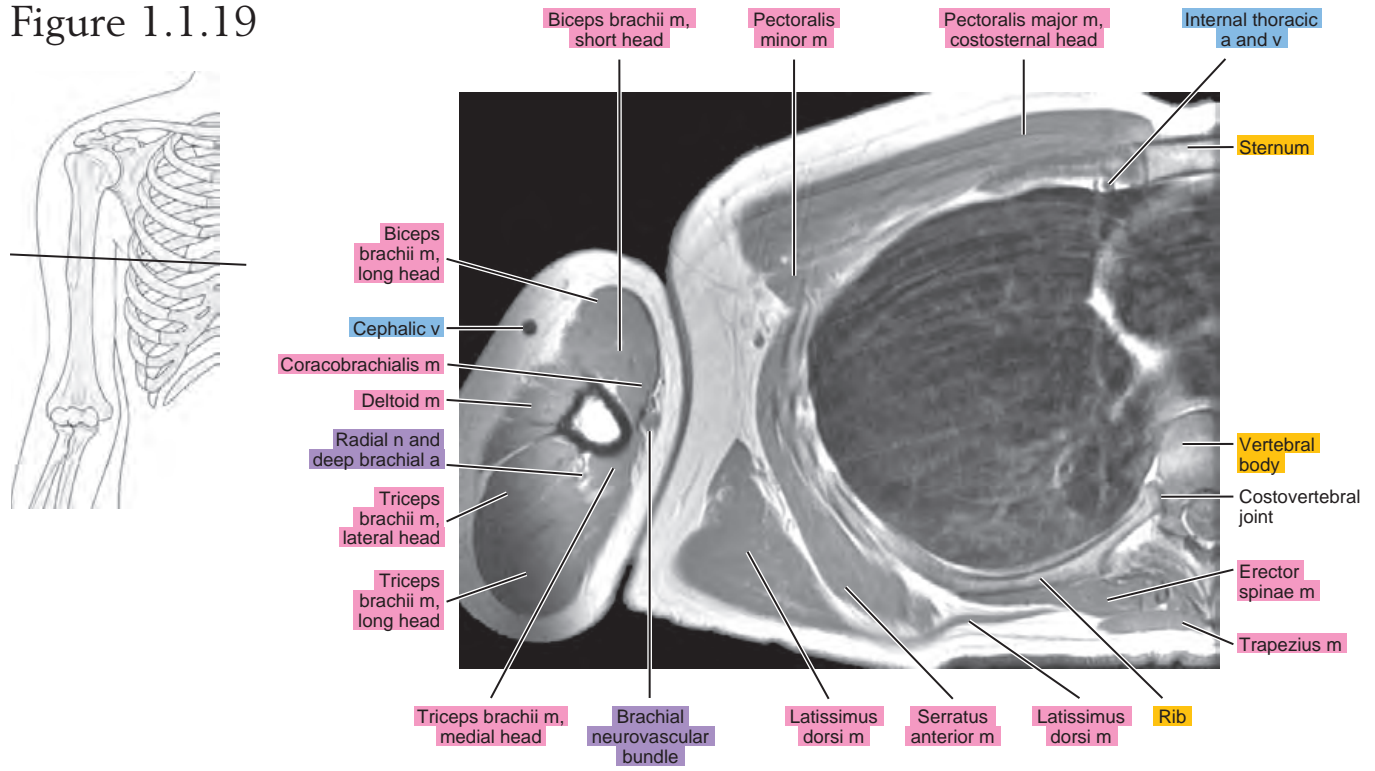


Figure 1.1.19



SAGITTAL

Figure 1.2.1

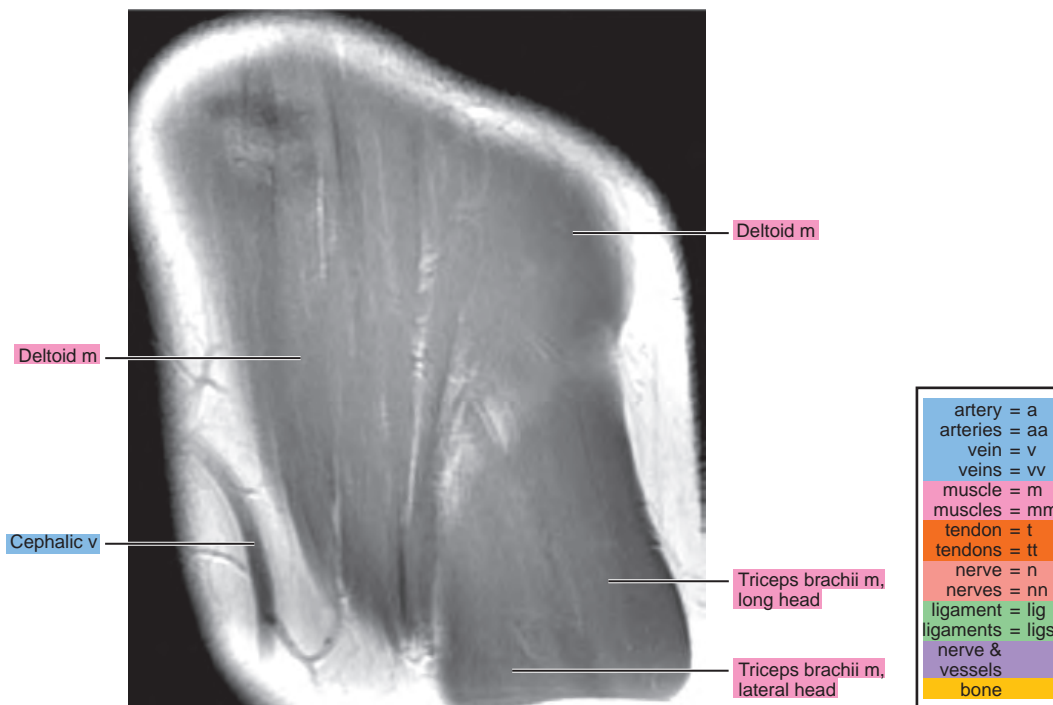
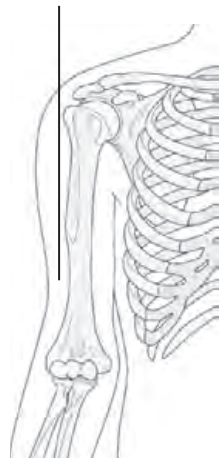

Figure 1.2.2

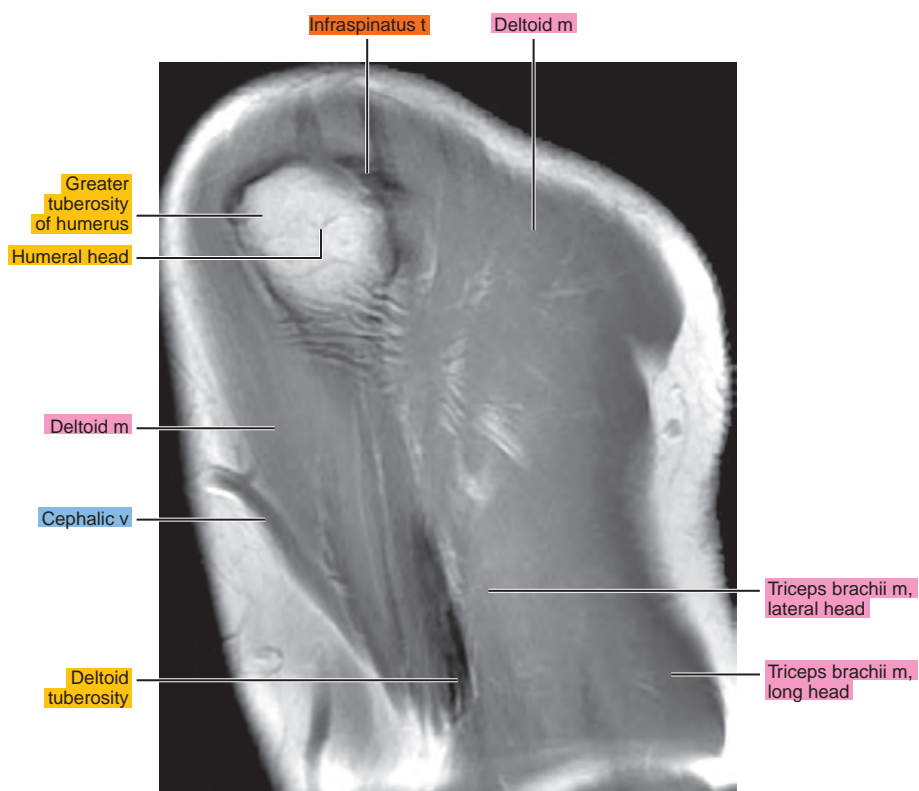
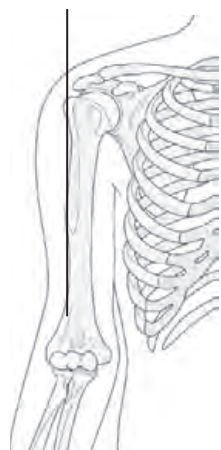


Figure 1.2.3

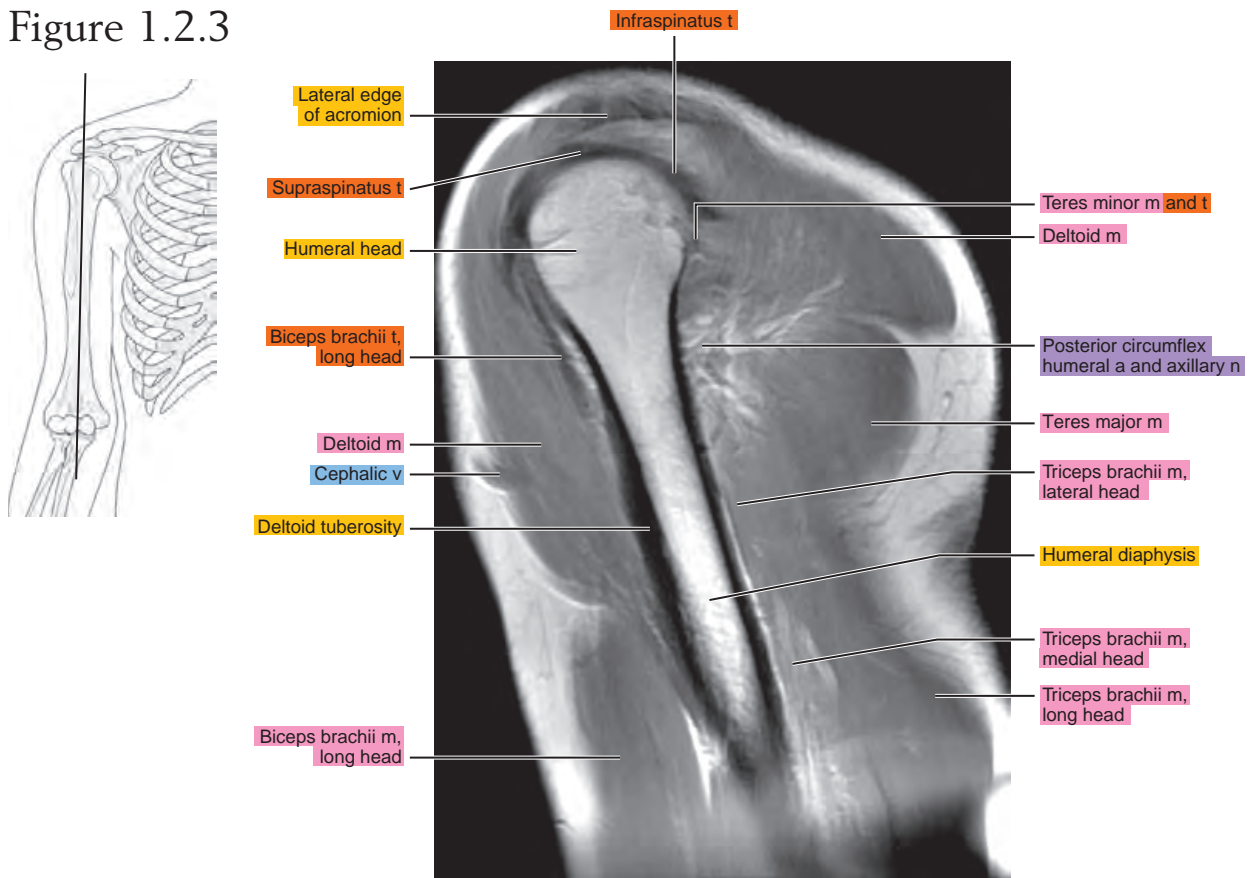


Figure 1.2.4

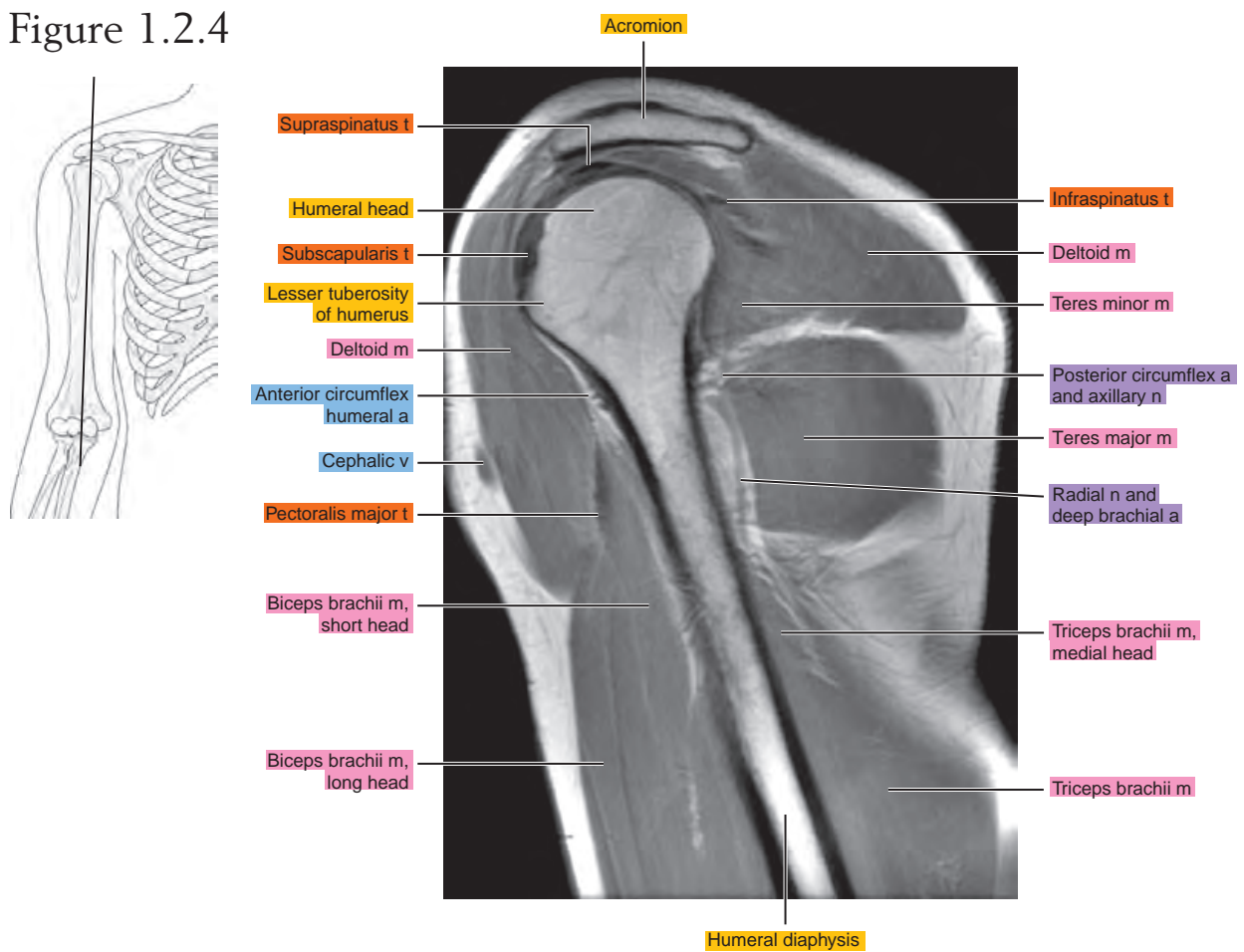


Figure 1.2.5

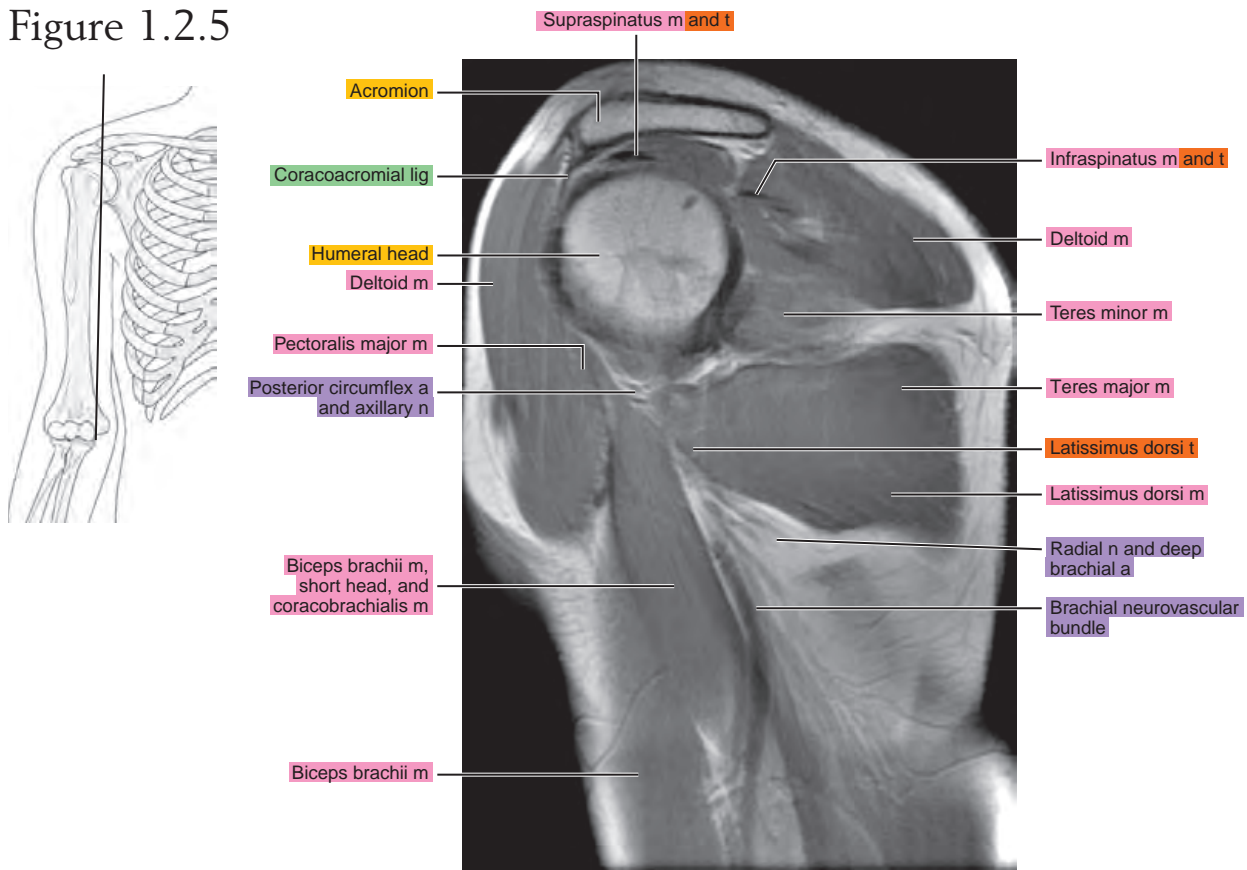


Figure 1.2.6

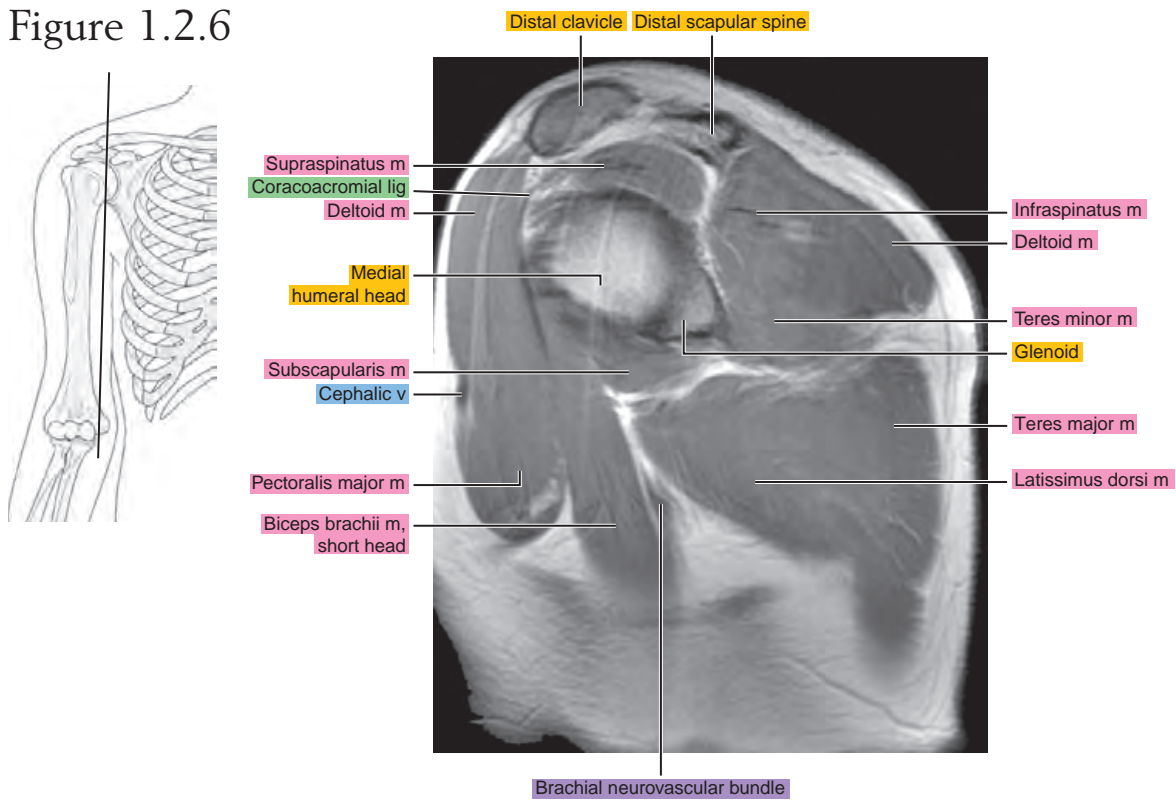


Figure 1.2.7

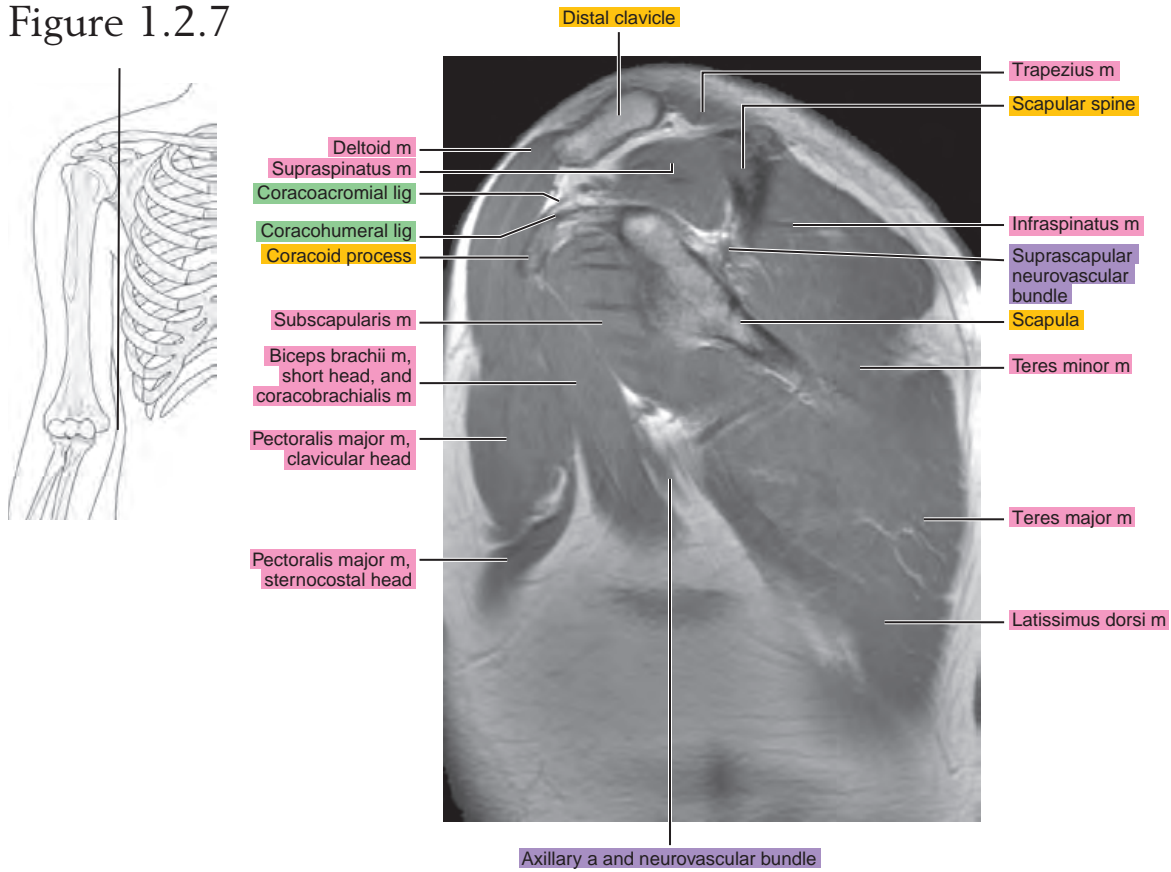


Figure 1.2.8

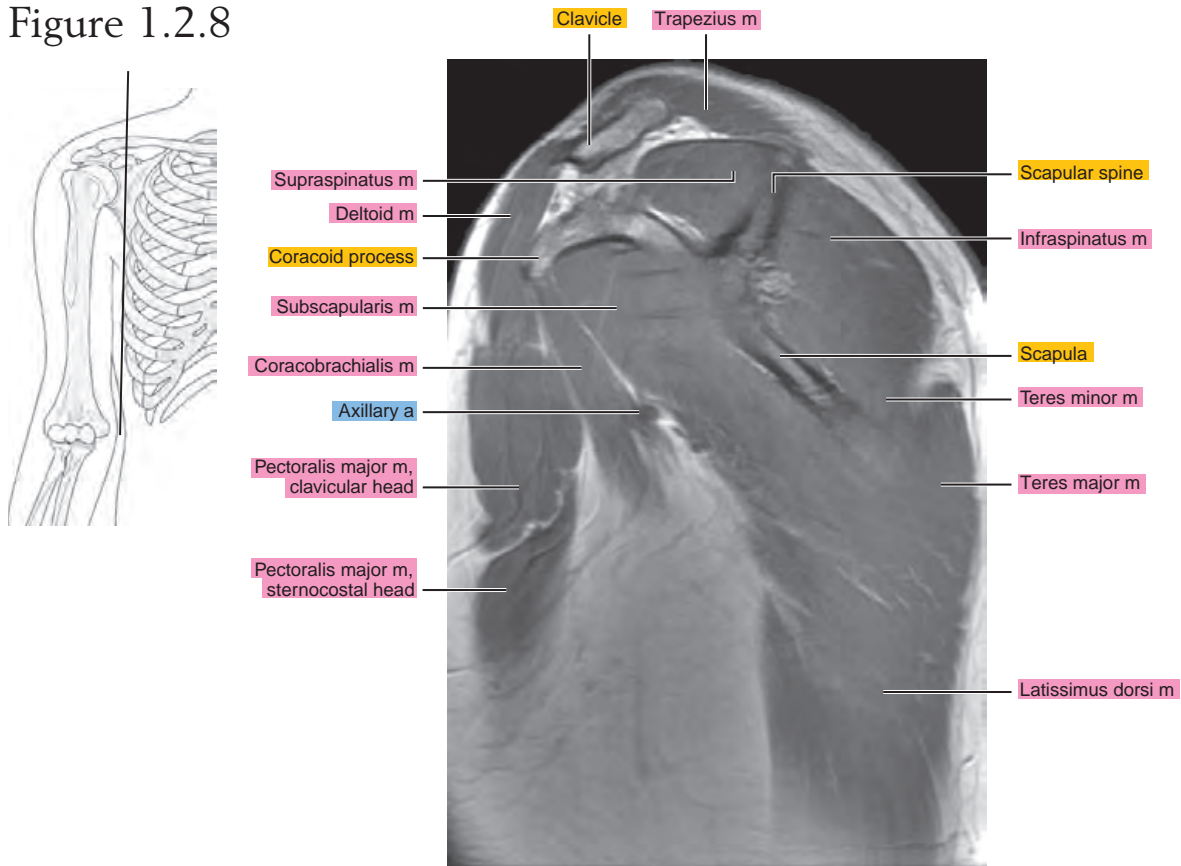


Figure 1.2.9

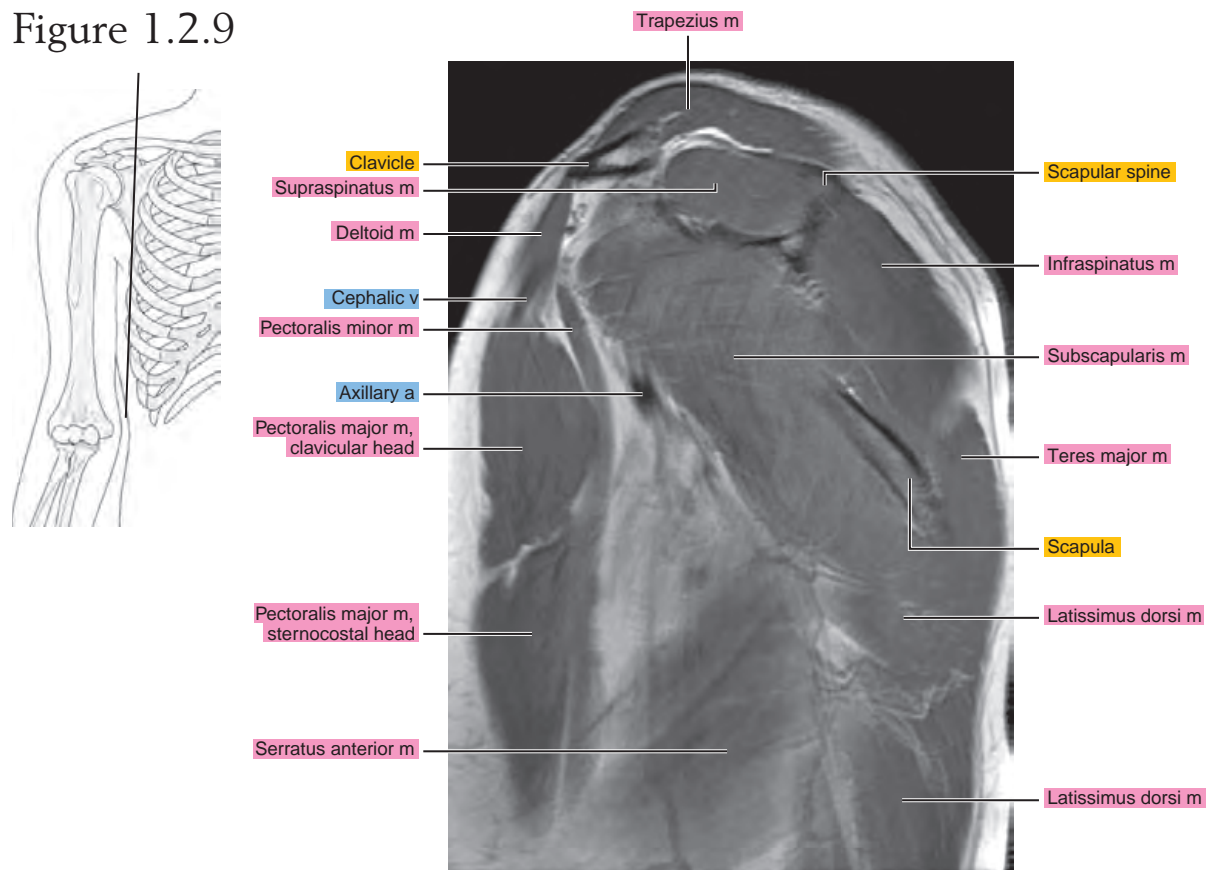


Figure 1.2.10

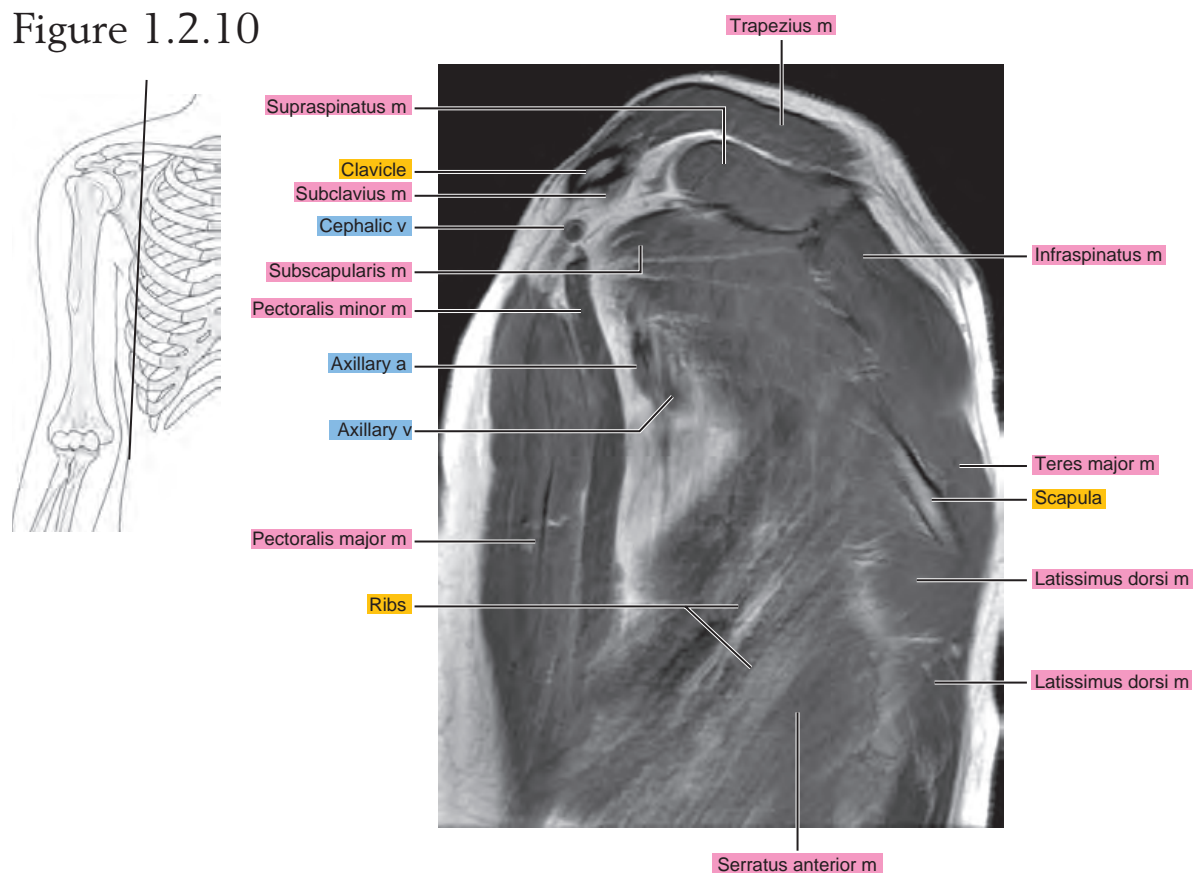


Figure 1.2.11

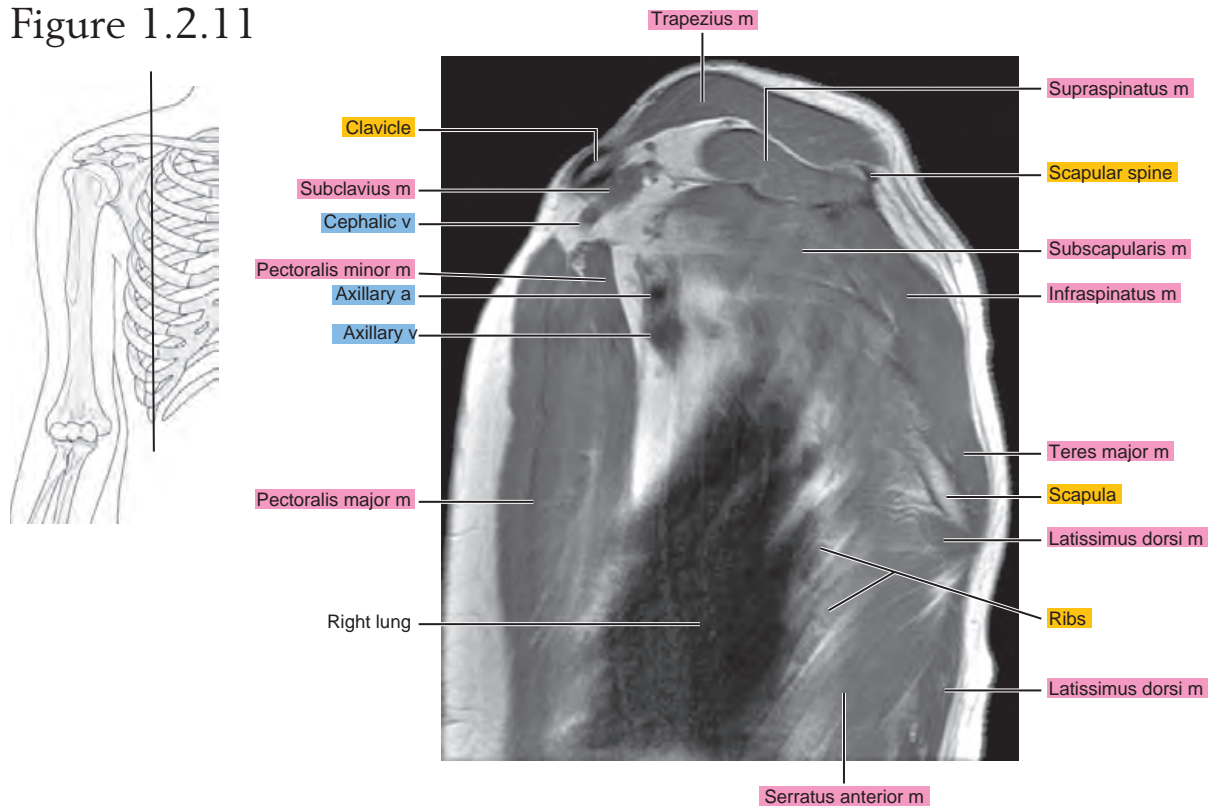


Figure 1.2.12

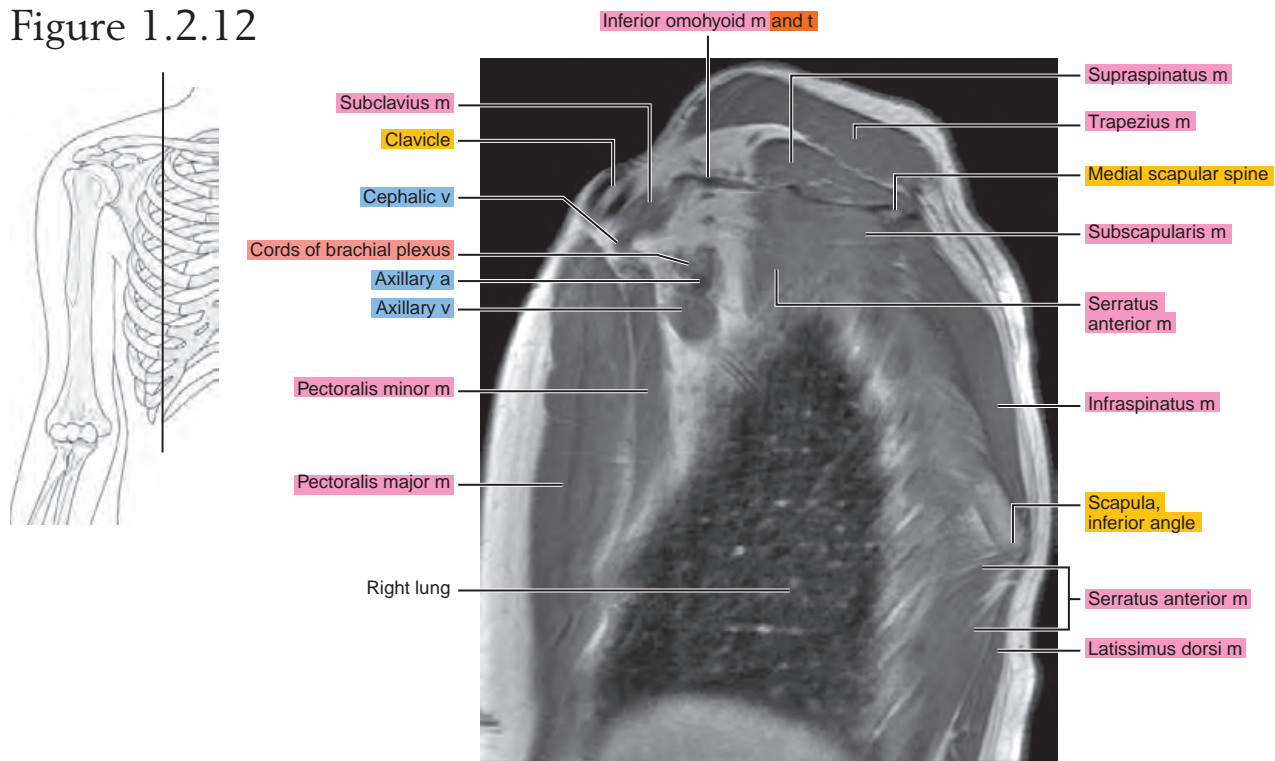


Figure 1.2.13

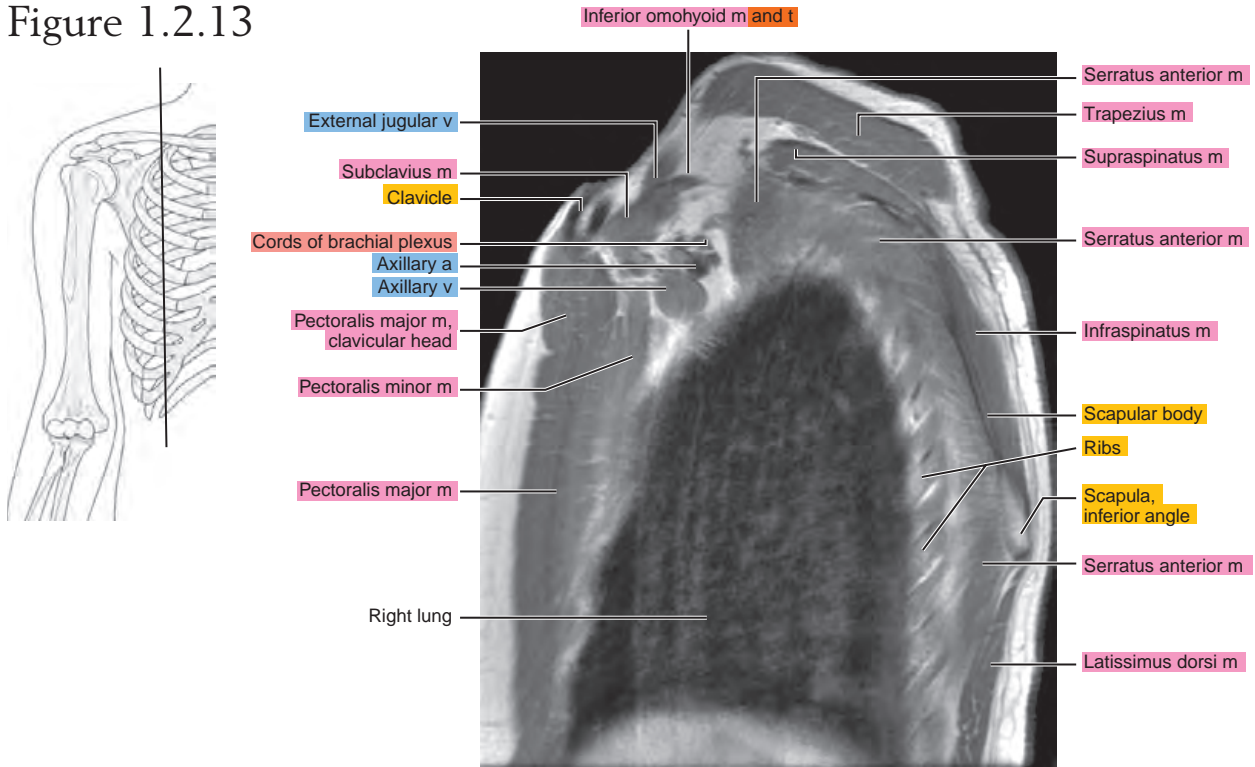


Figure 1.2.14

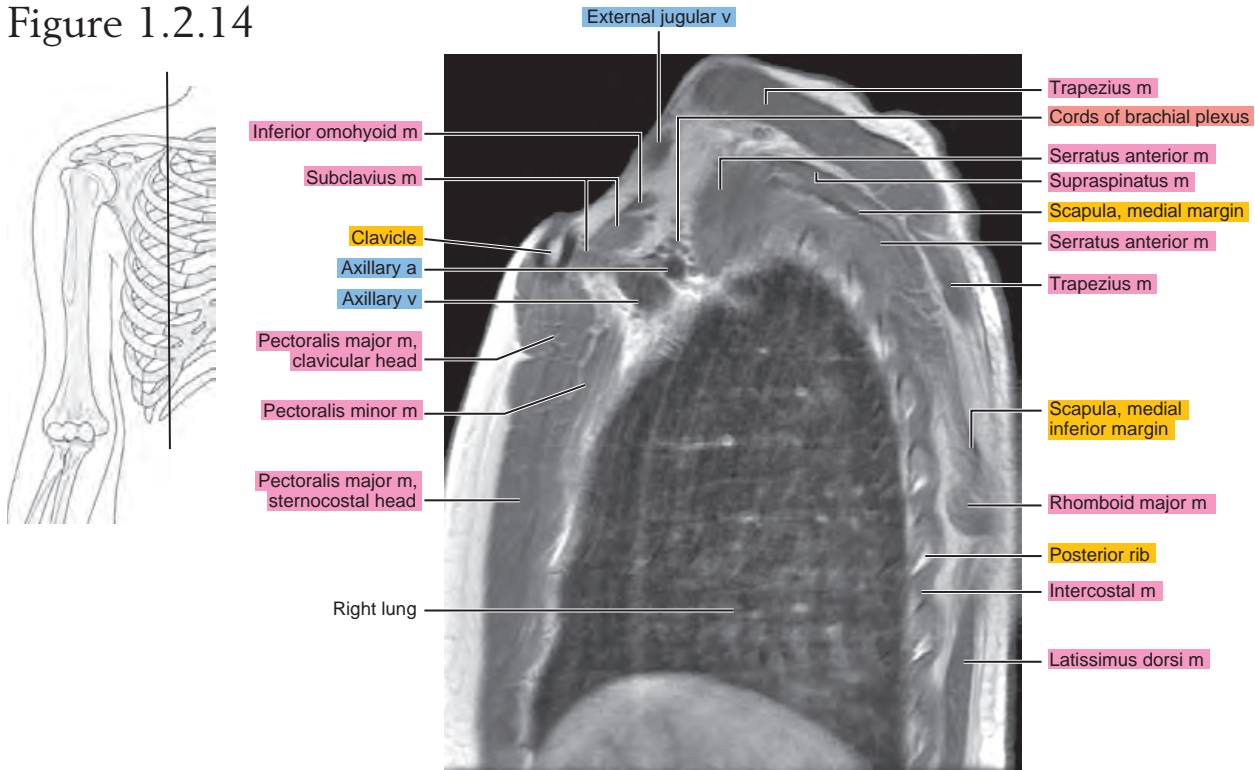


Figure 1.2.15

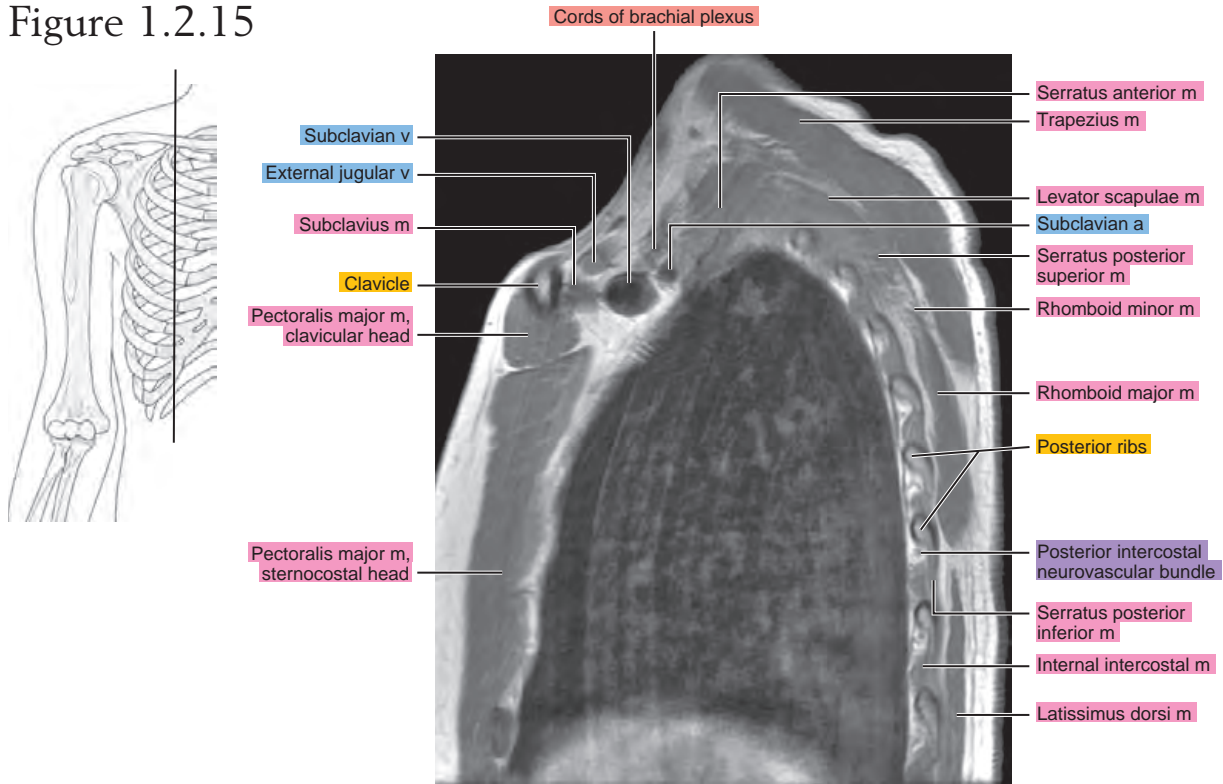


Figure 1.2.16

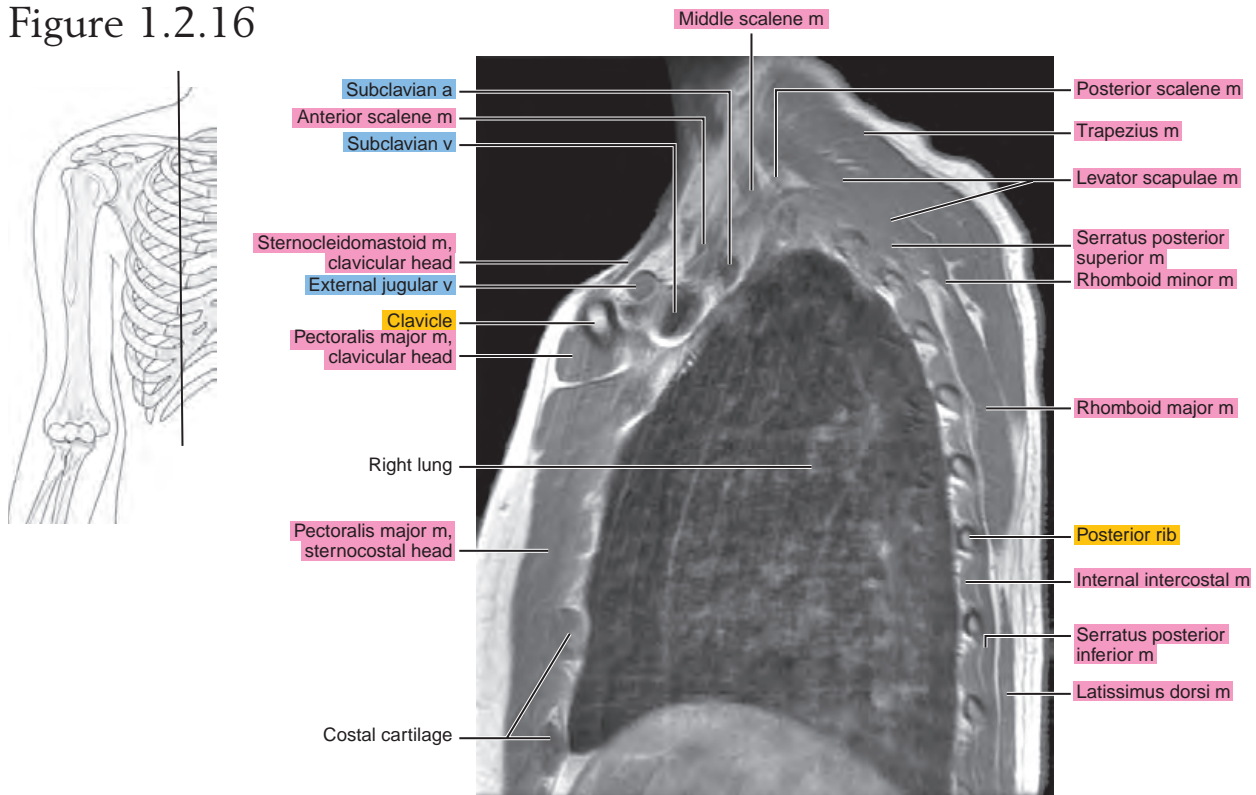


Figure 1.2.17

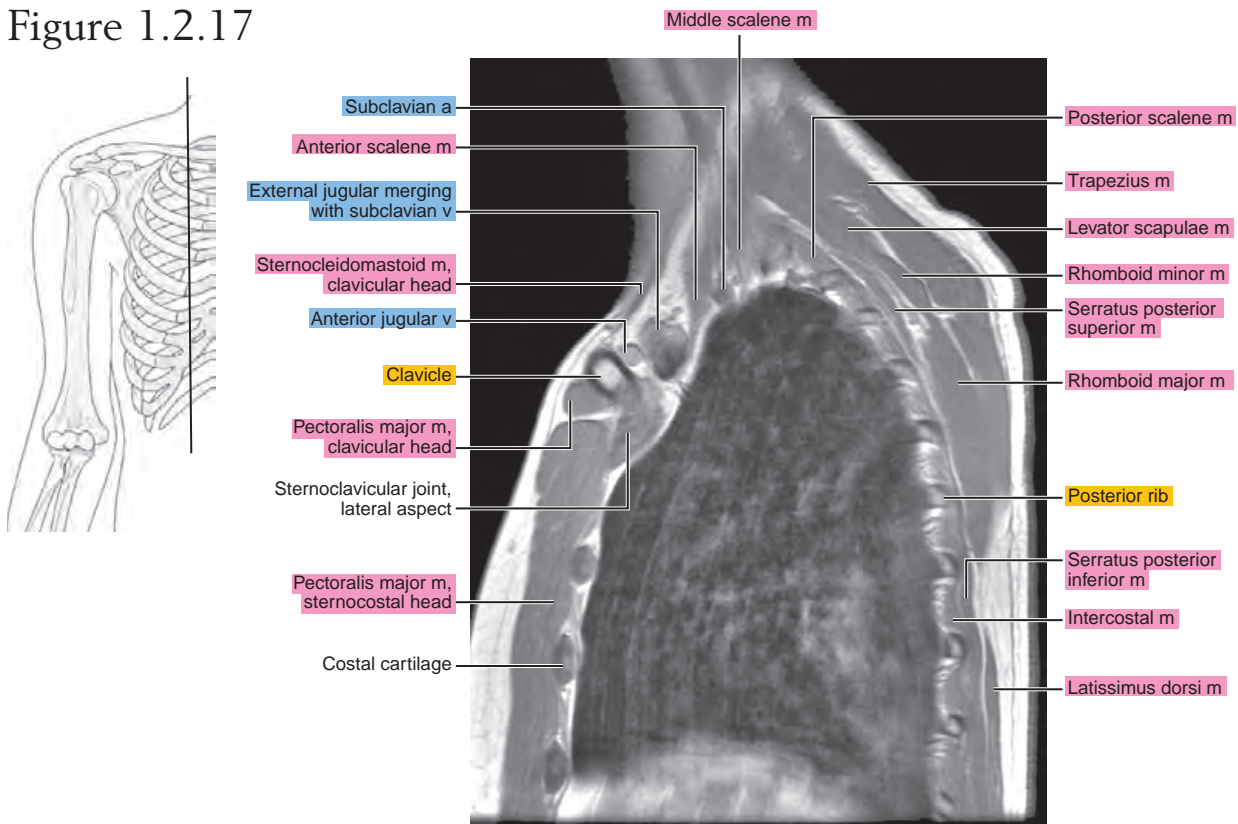


Figure 1.2.18

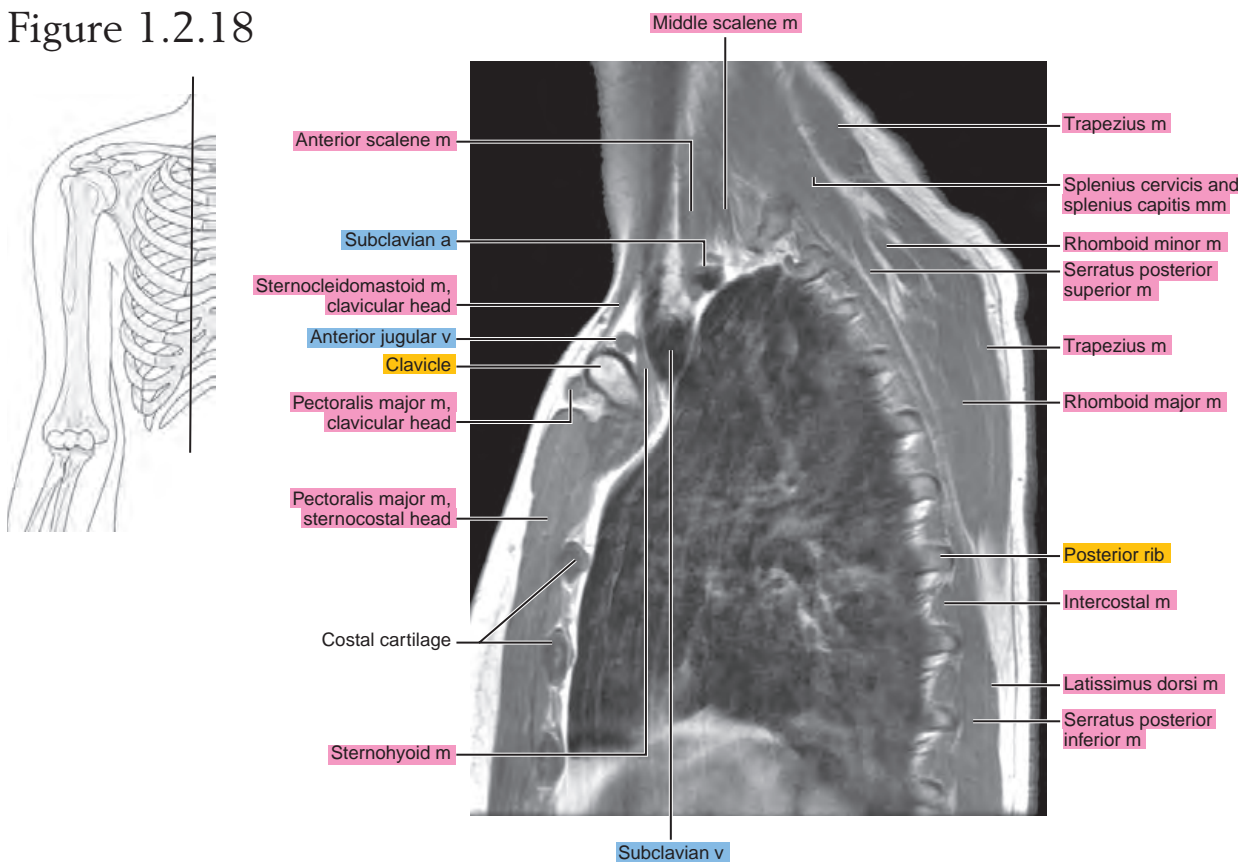
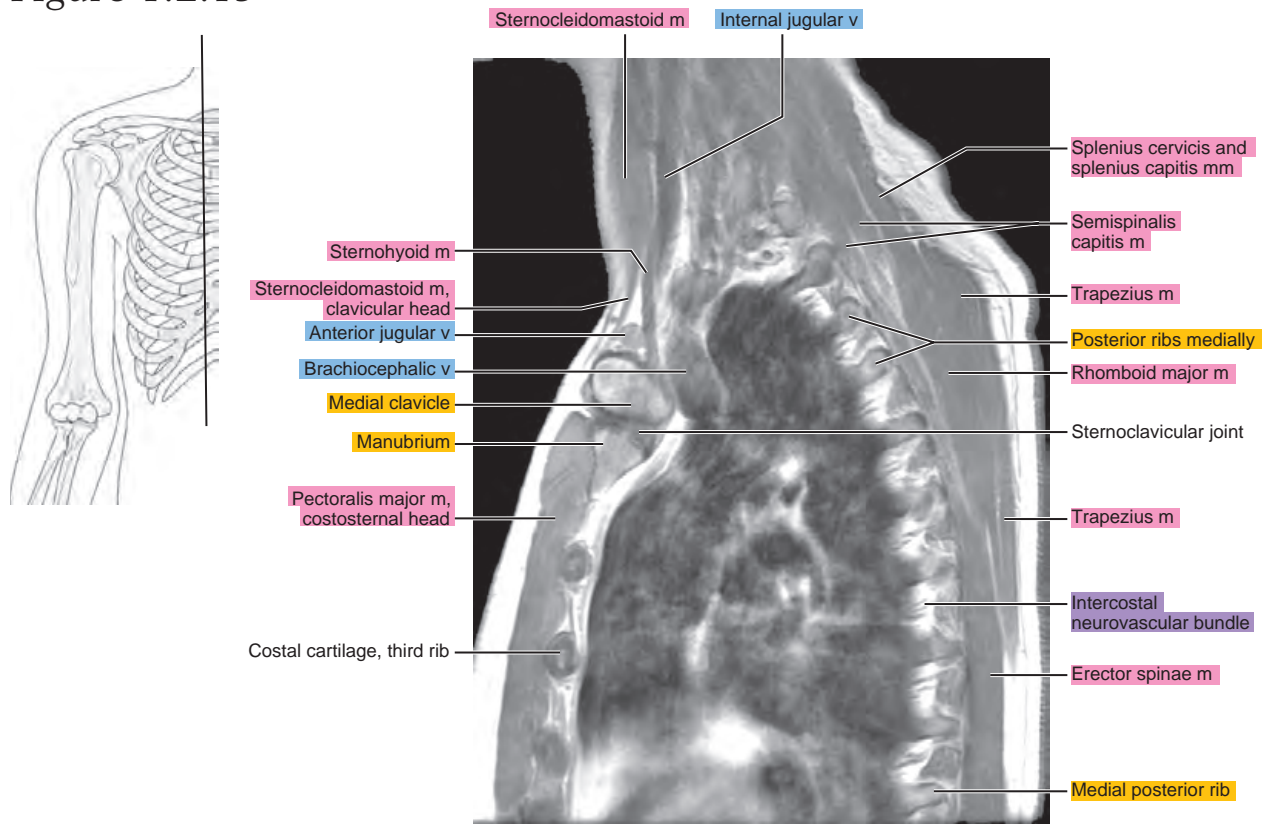


Figure 1.2.19



CORONAL

Figure 1.3.1

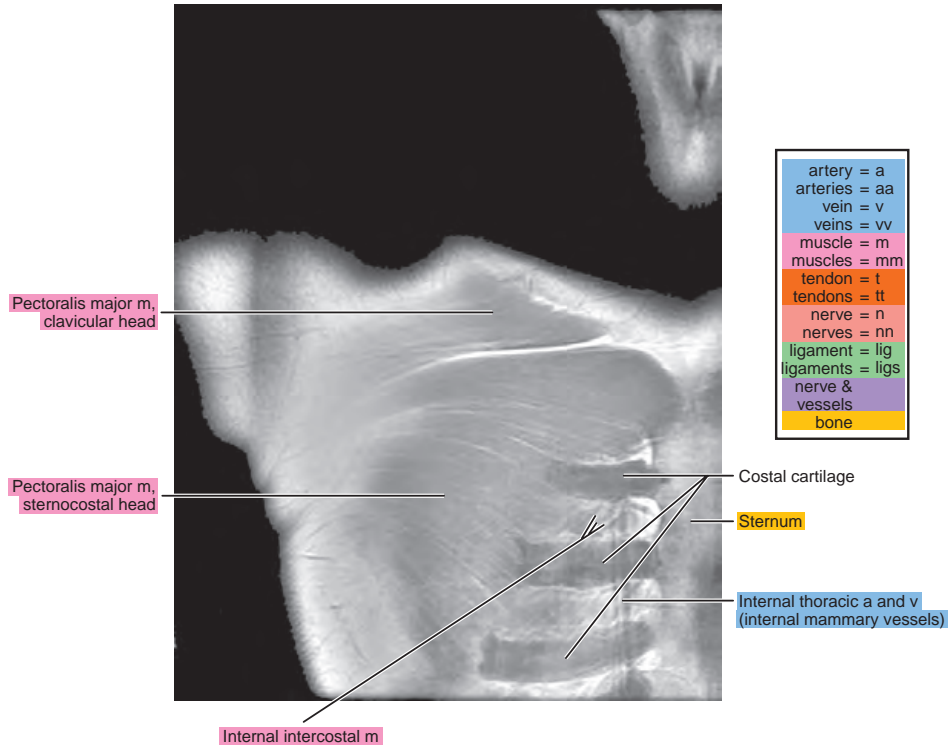
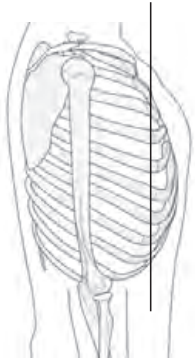


Figure 1.3.2

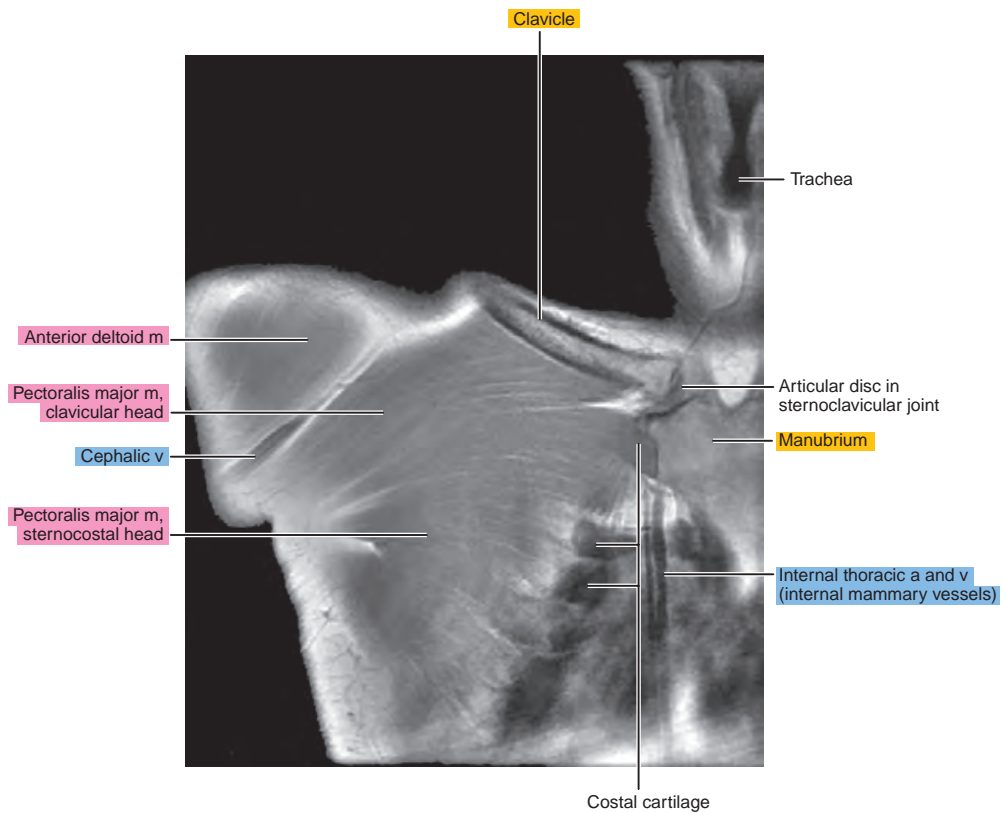
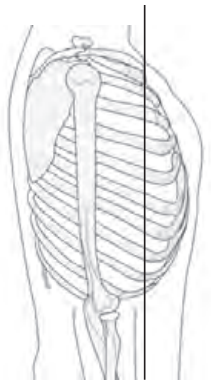


Figure 1.3.3

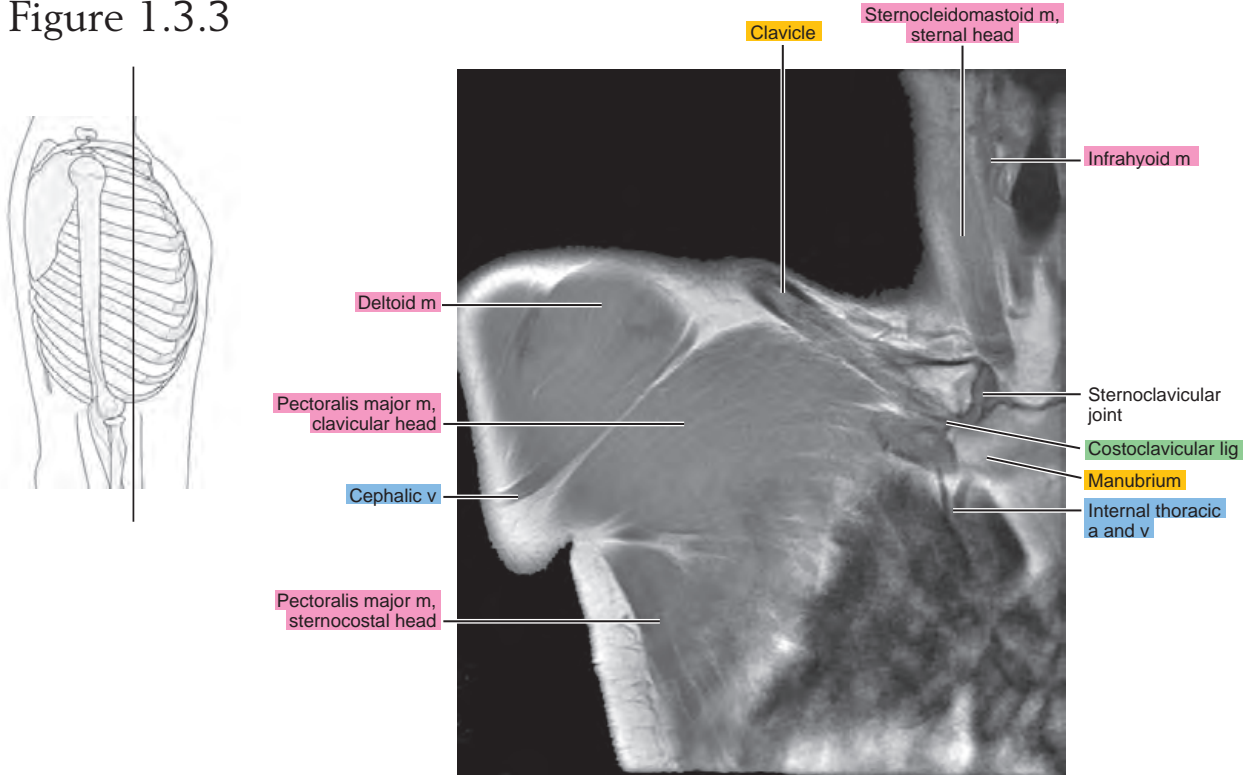


Figure 1.3.4

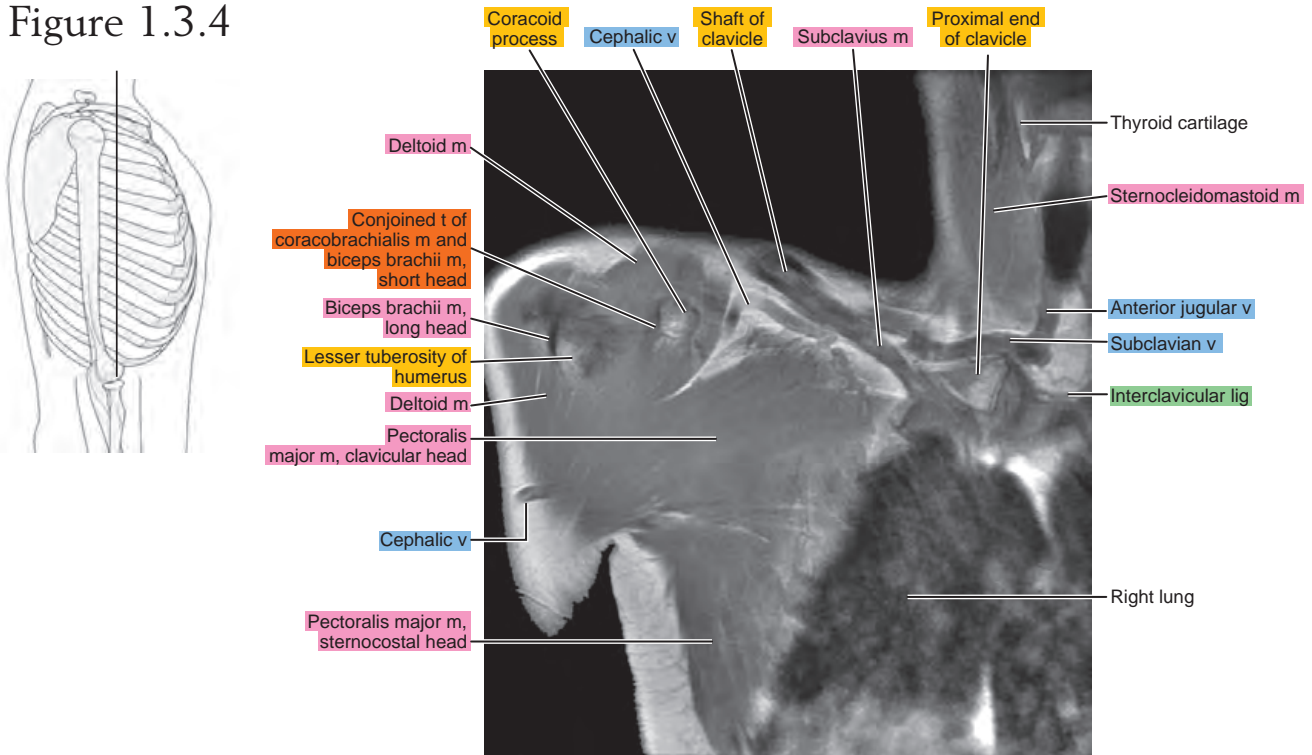


Figure 1.3.5

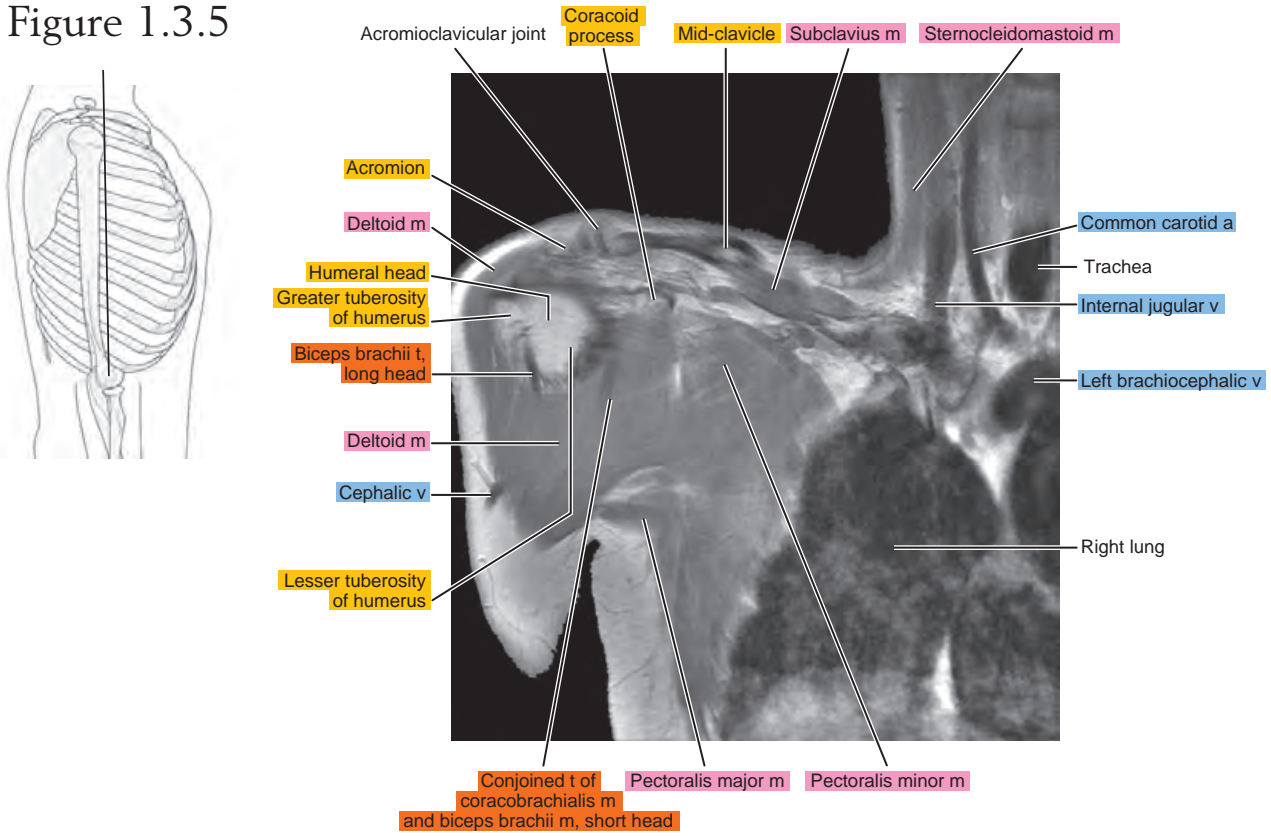


Figure 1.3.6

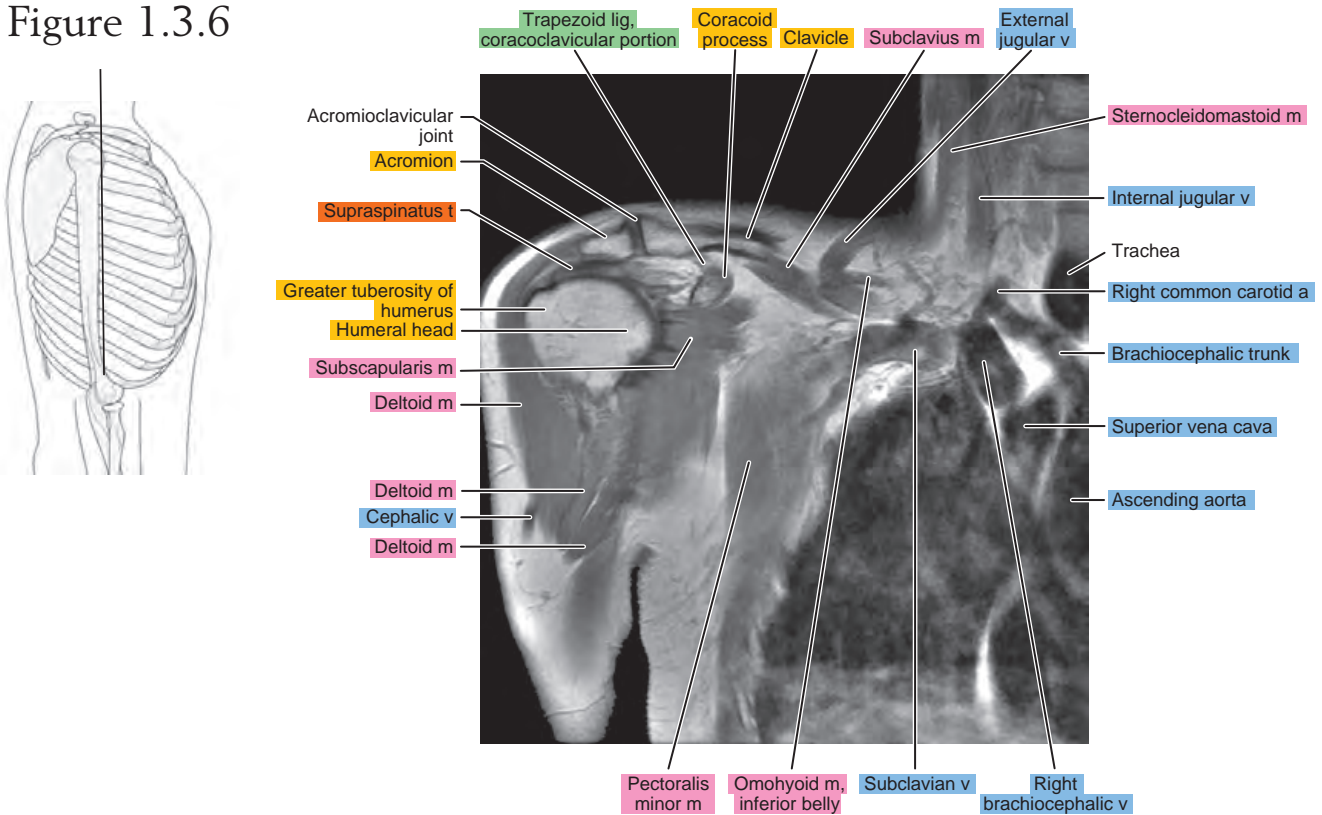


Figure 1.3.7

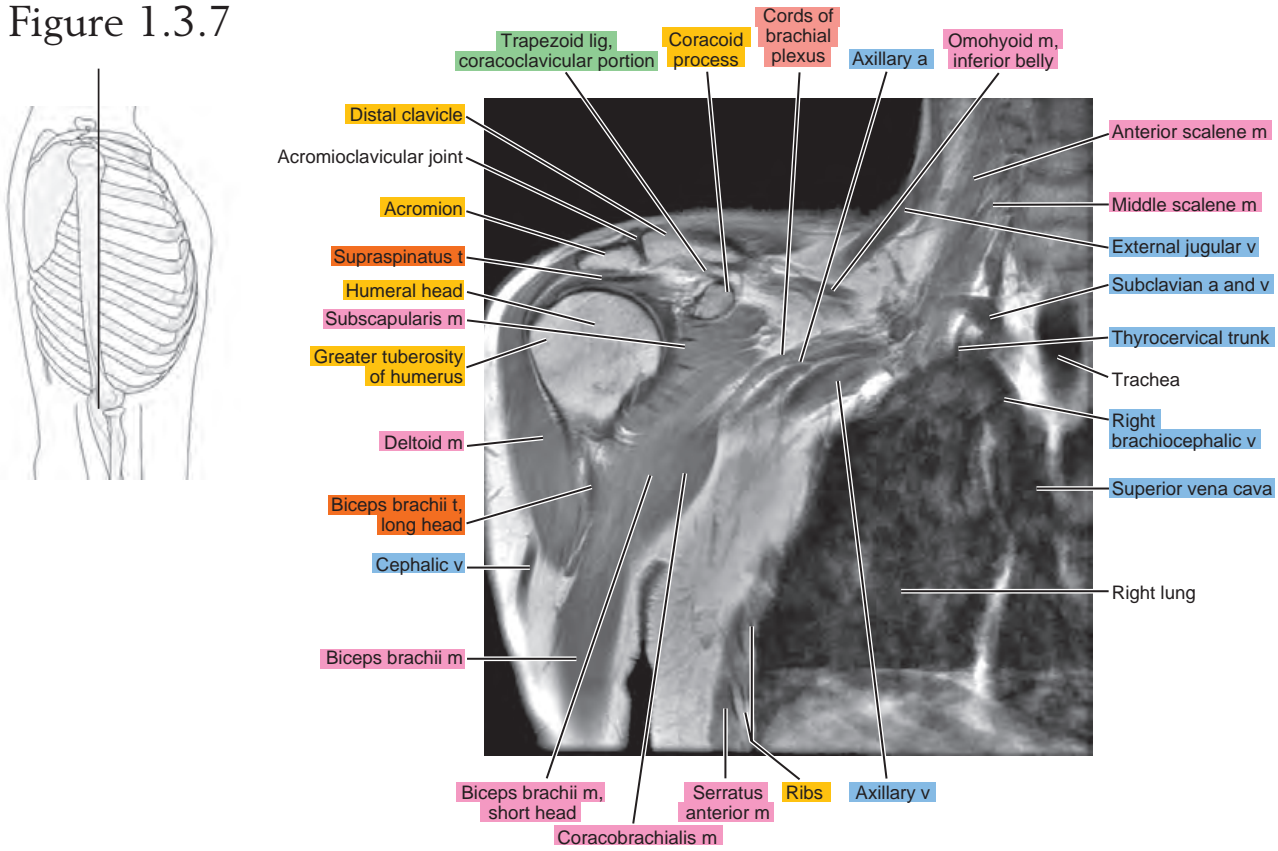


Figure 1.3.8

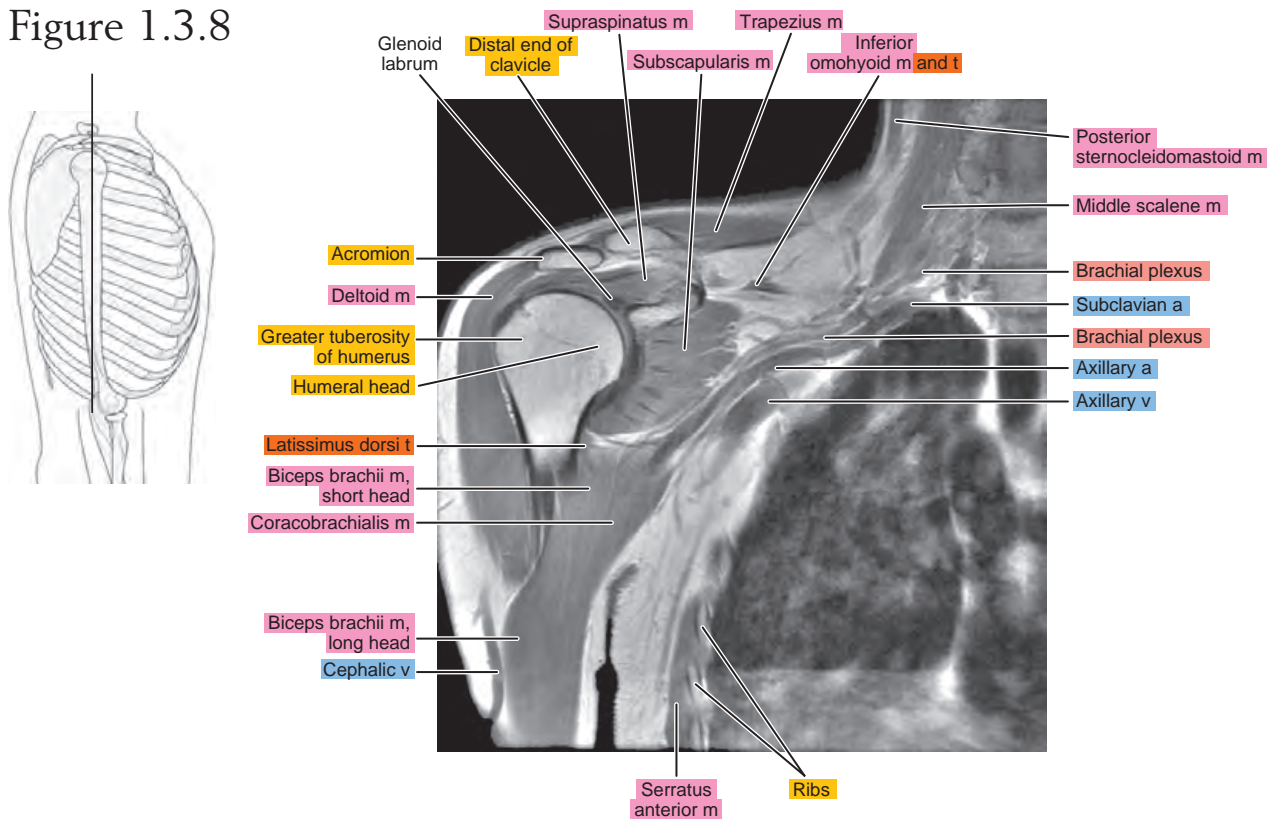


Figure 1.3.9

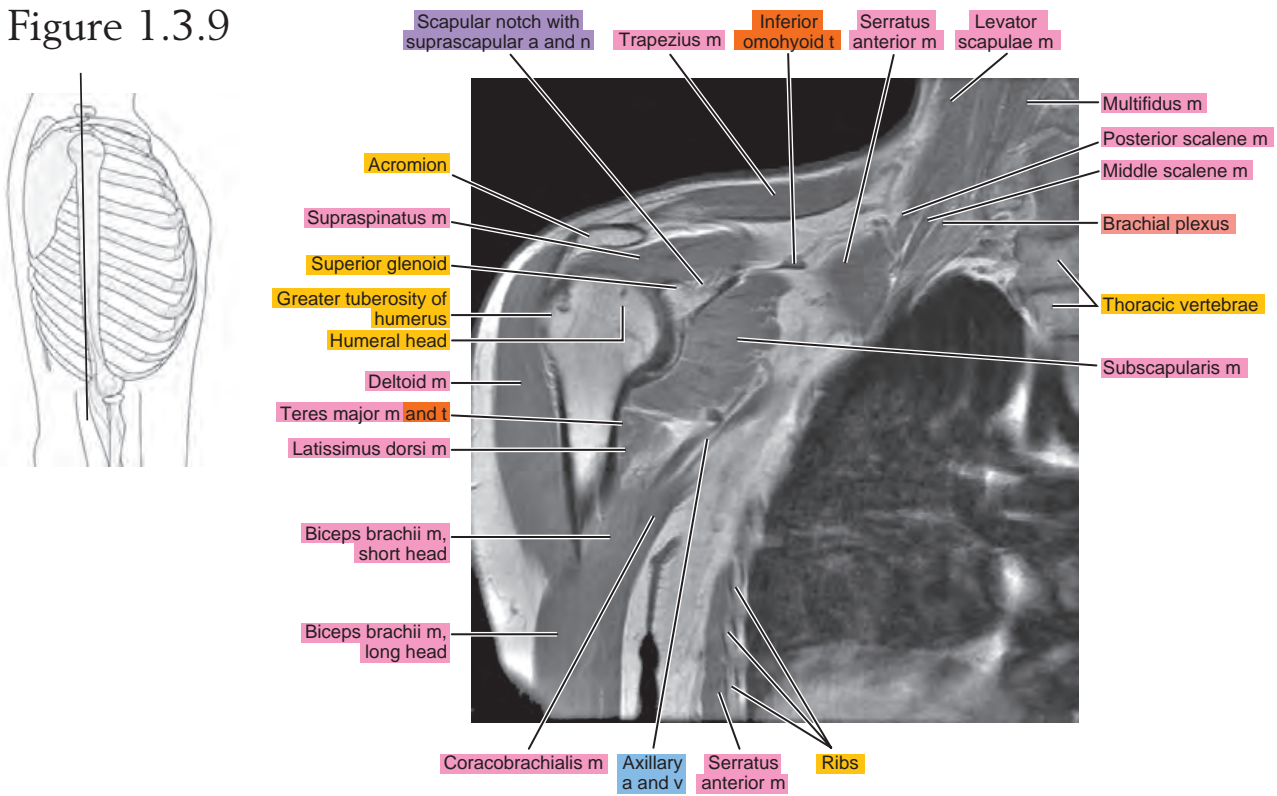


Figure 1.3.10

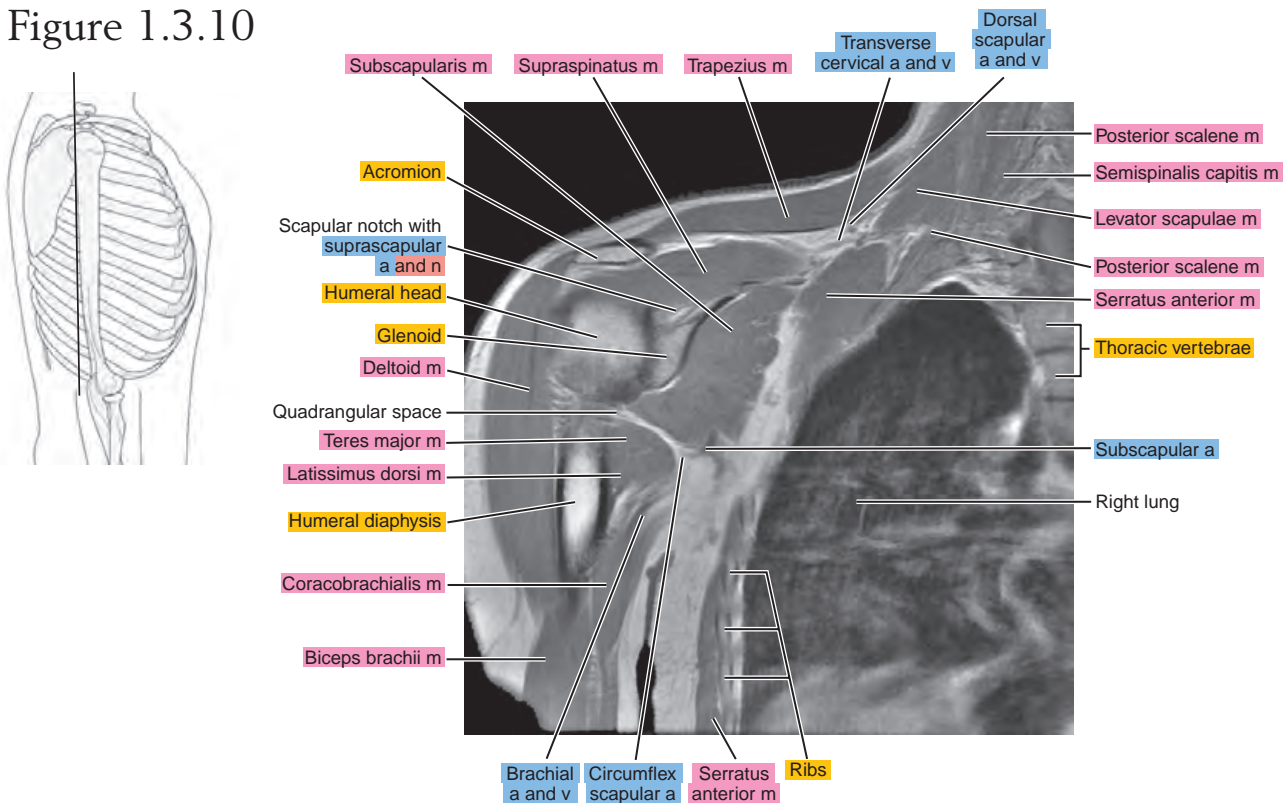


Figure 1.3.11

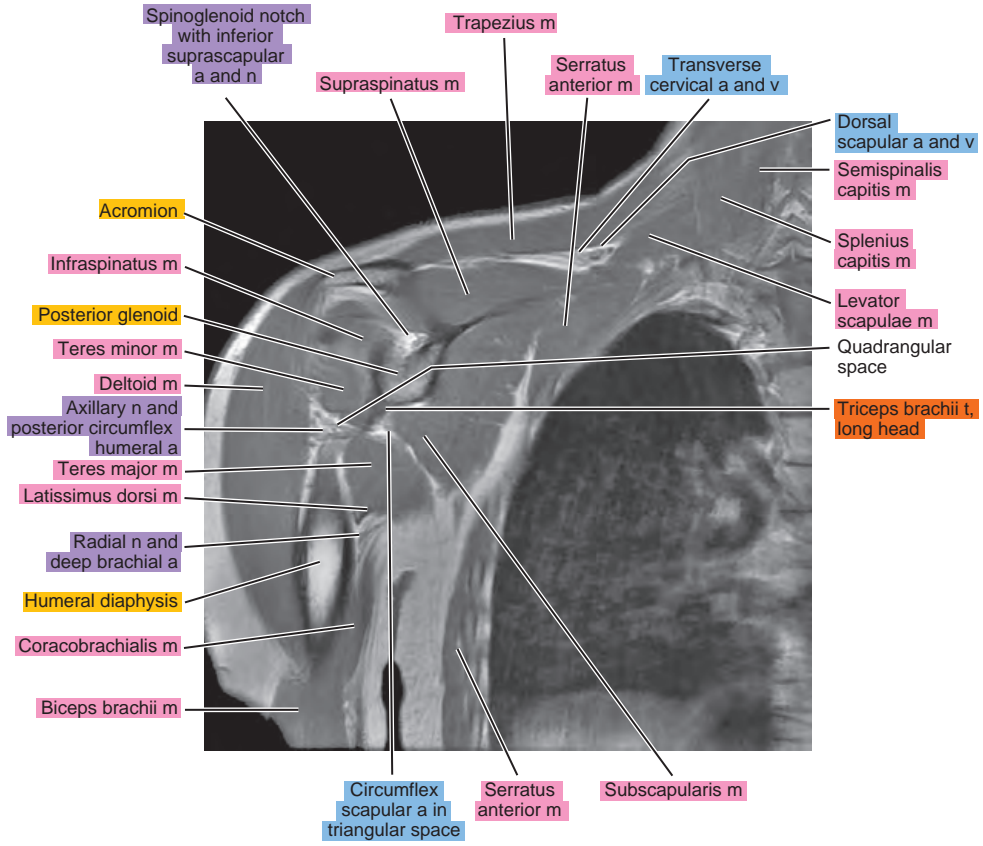
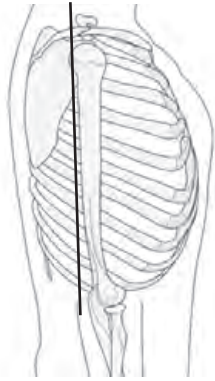


Figure 1.3.12

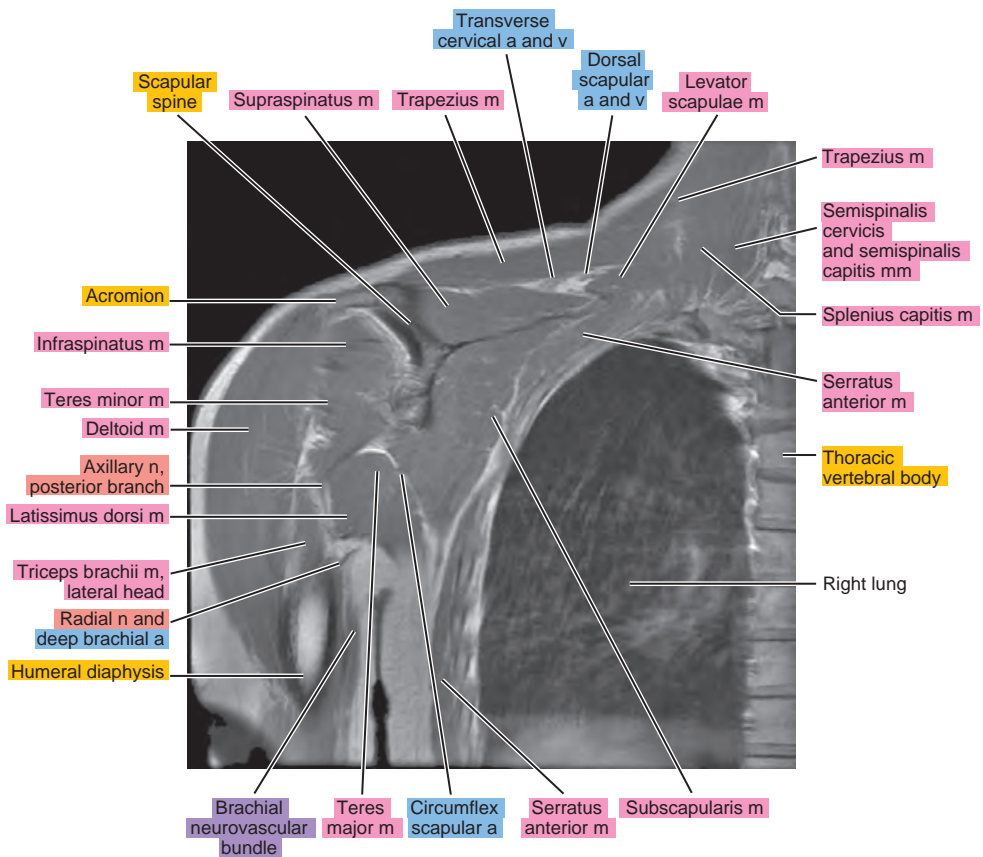
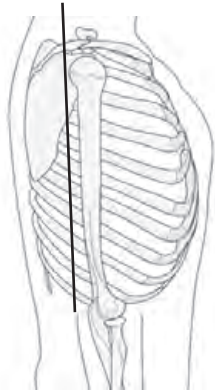


Figure 1.3.13

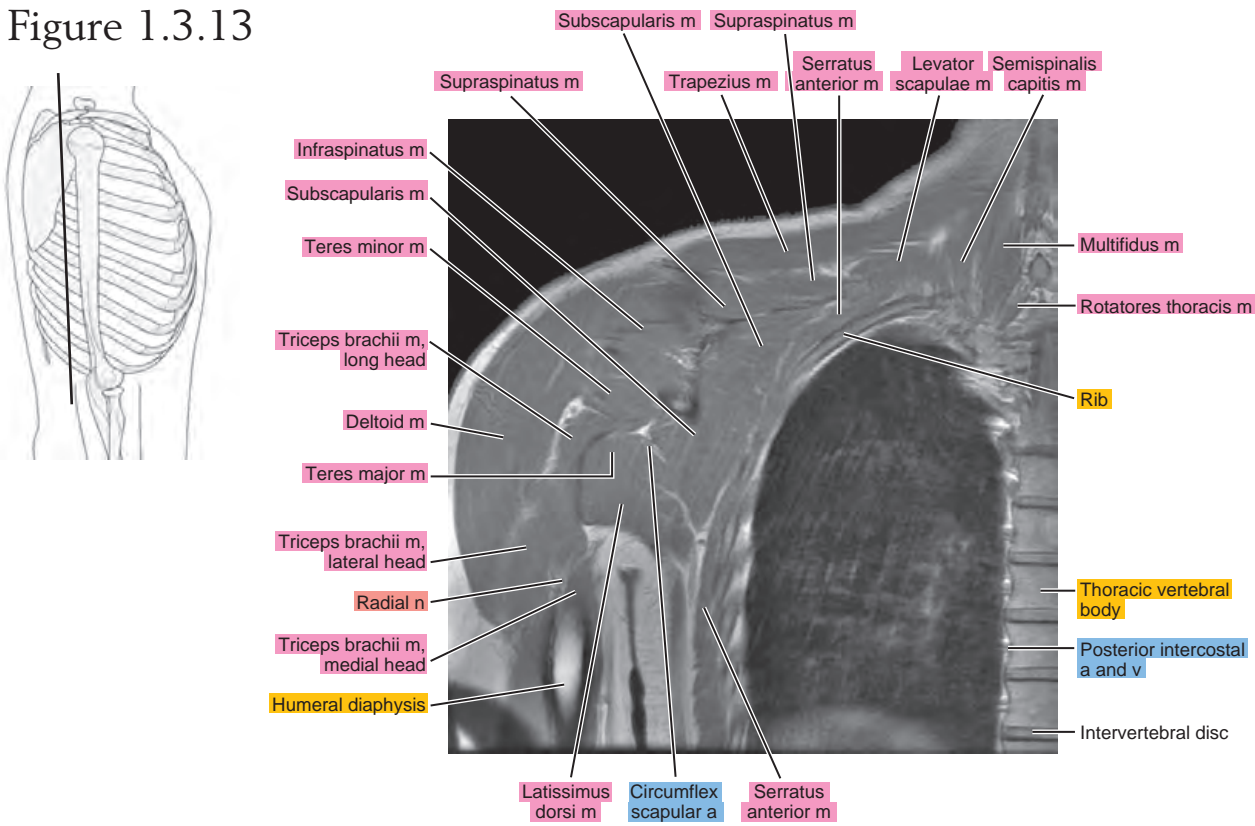


Figure 1.3.14

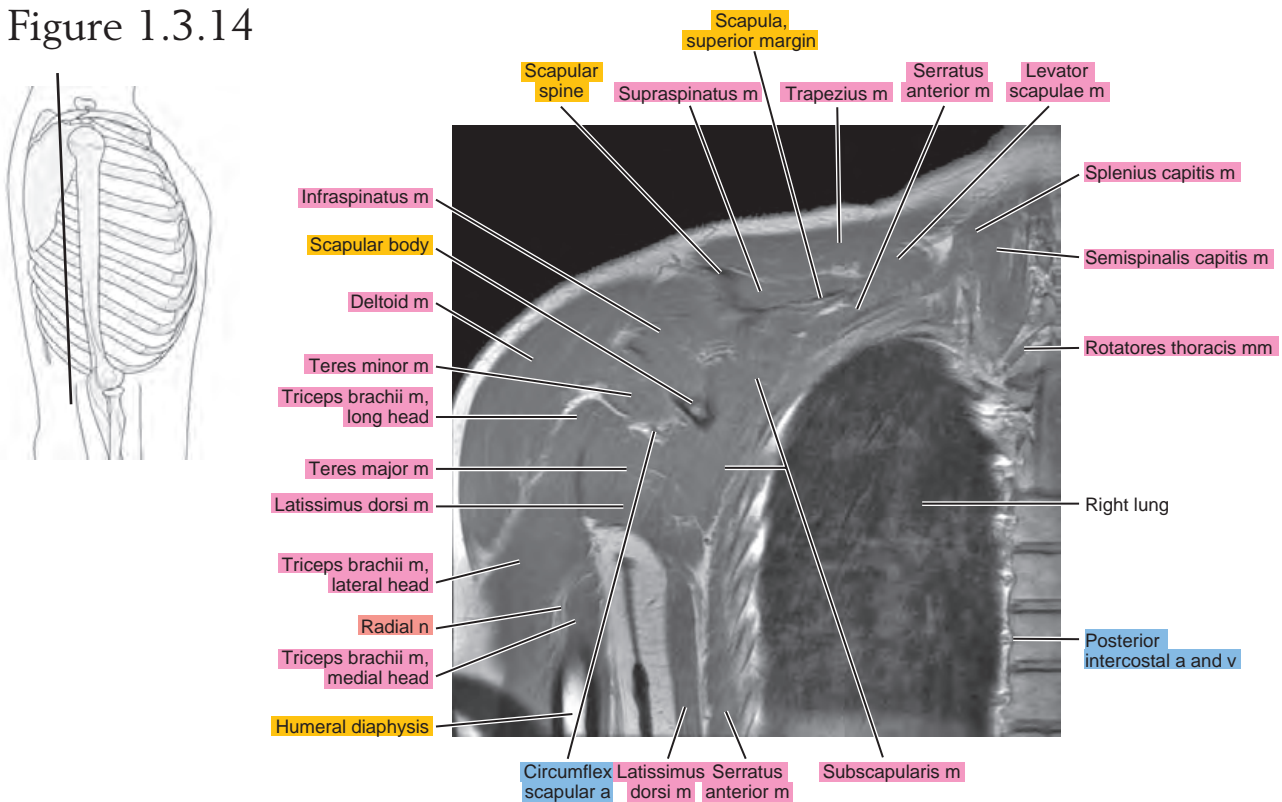


Figure 1.3.15

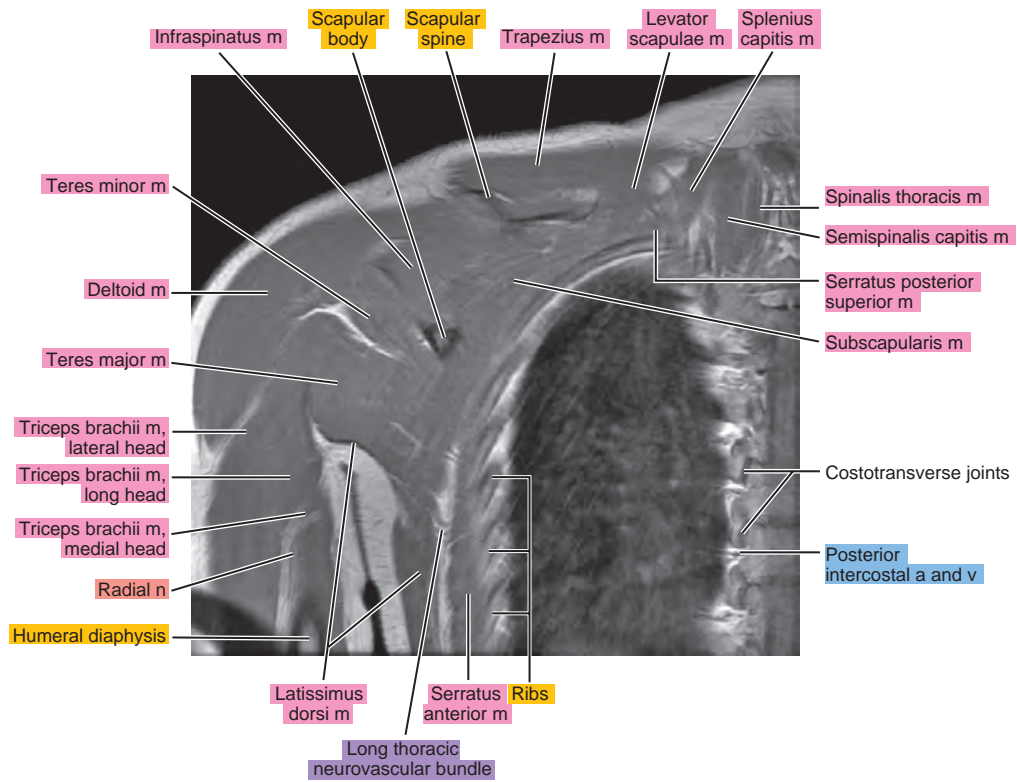
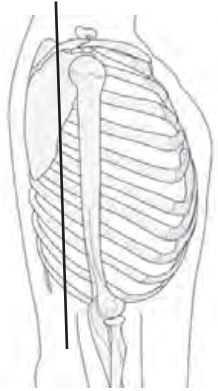


Figure 1.3.16

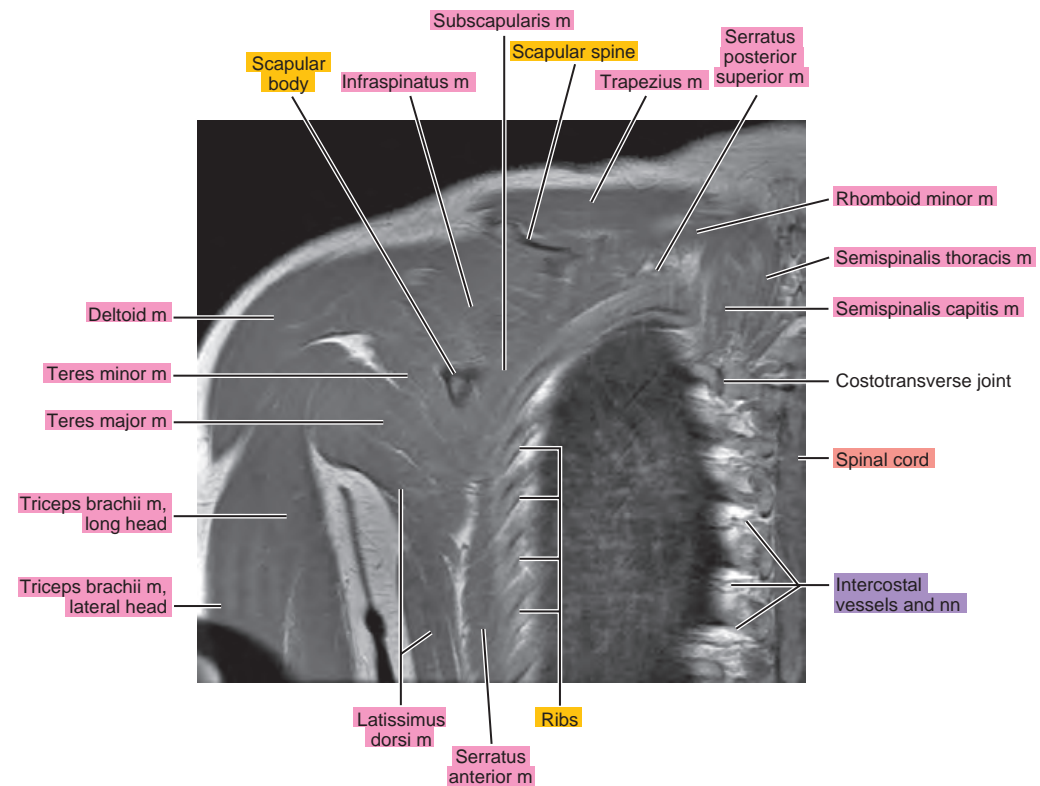
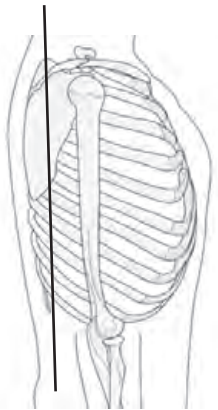


Figure 1.3.17

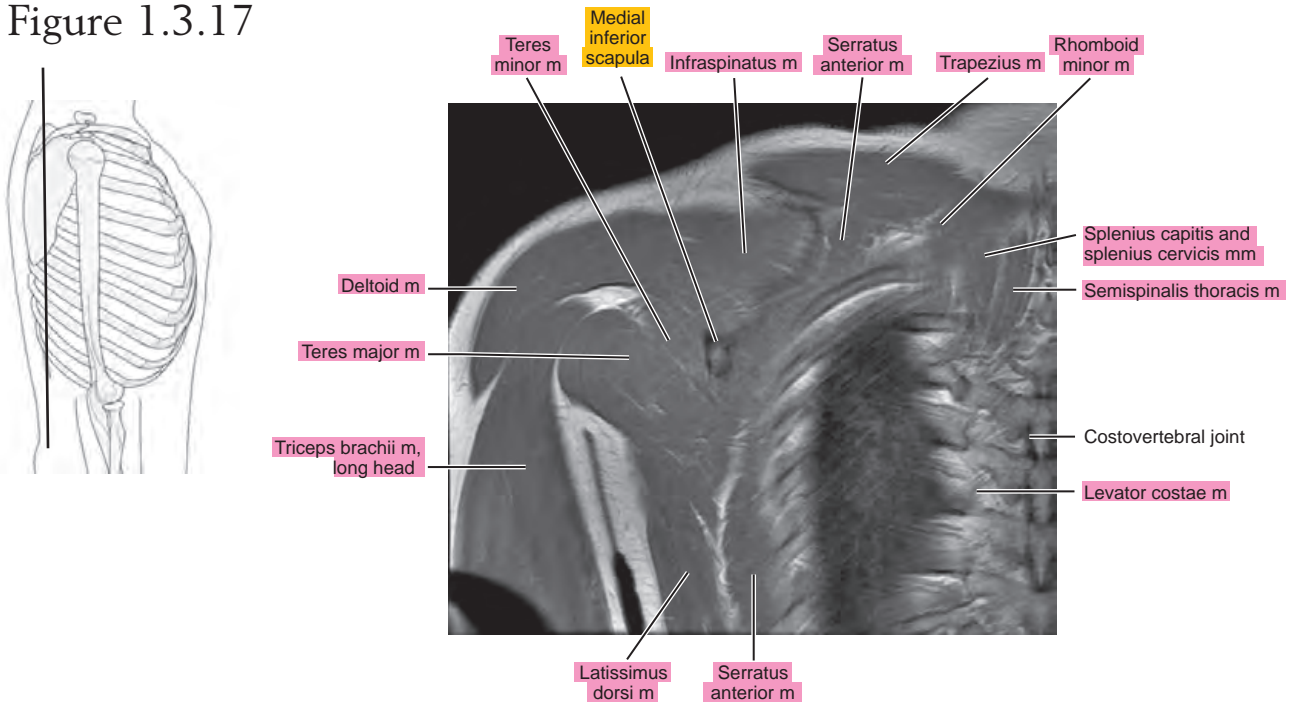


Figure 1.3.18

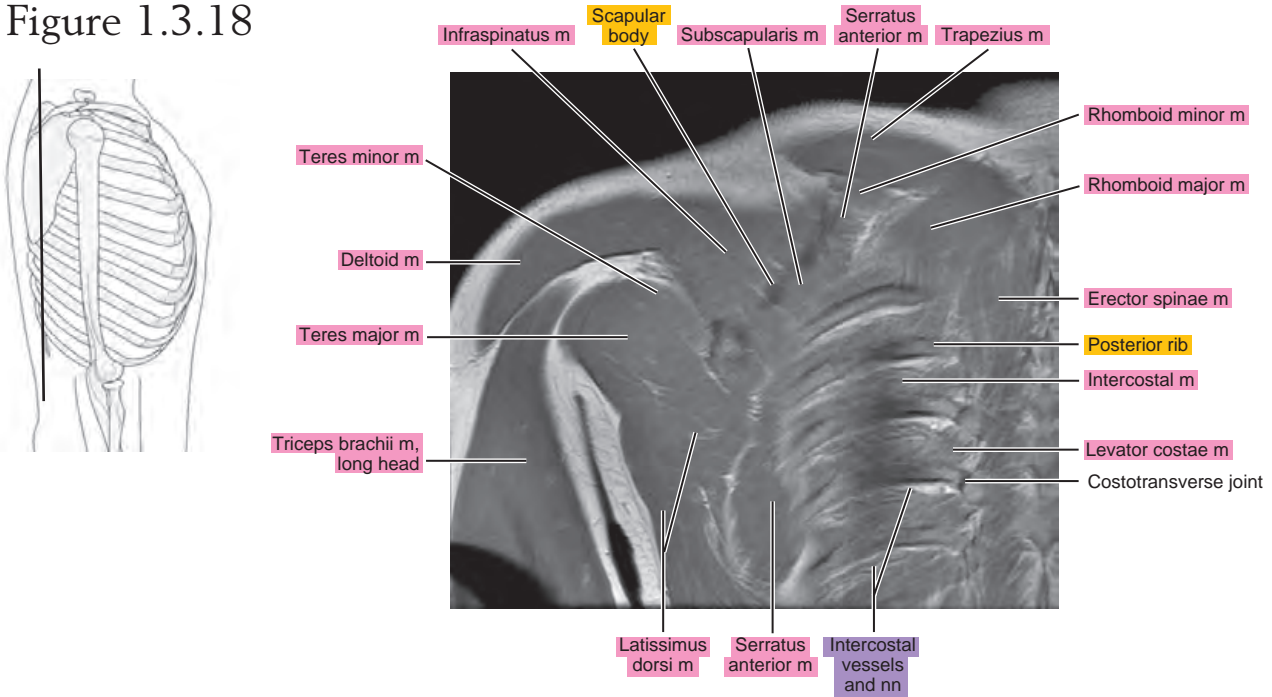


Figure 1.3.19

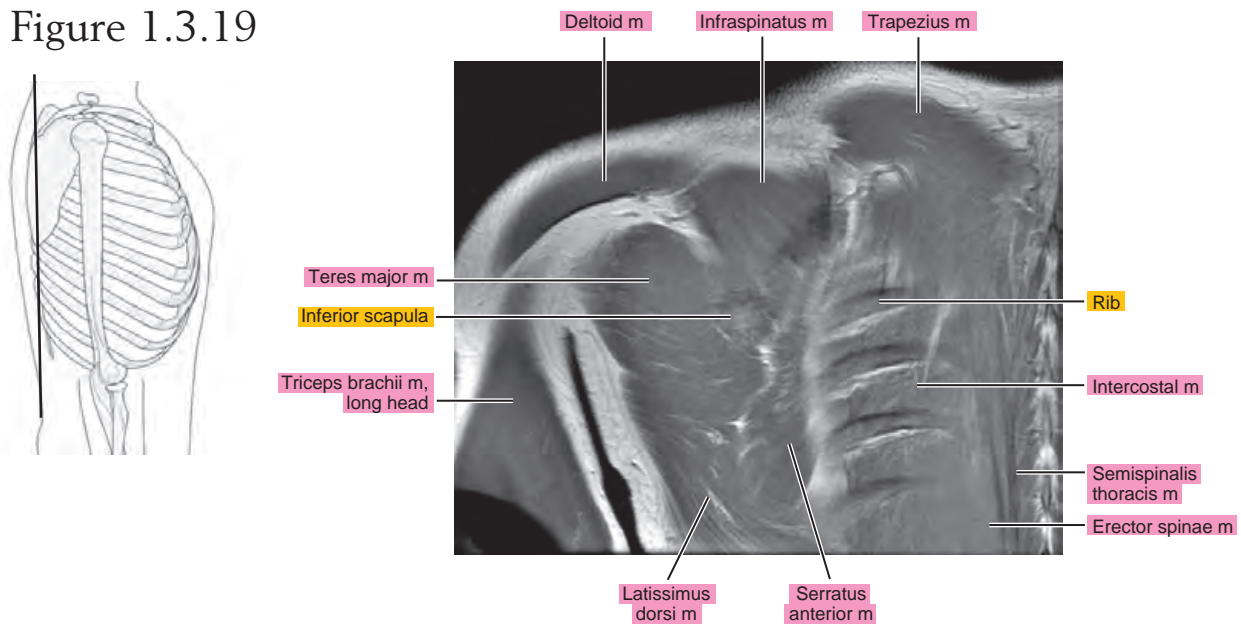
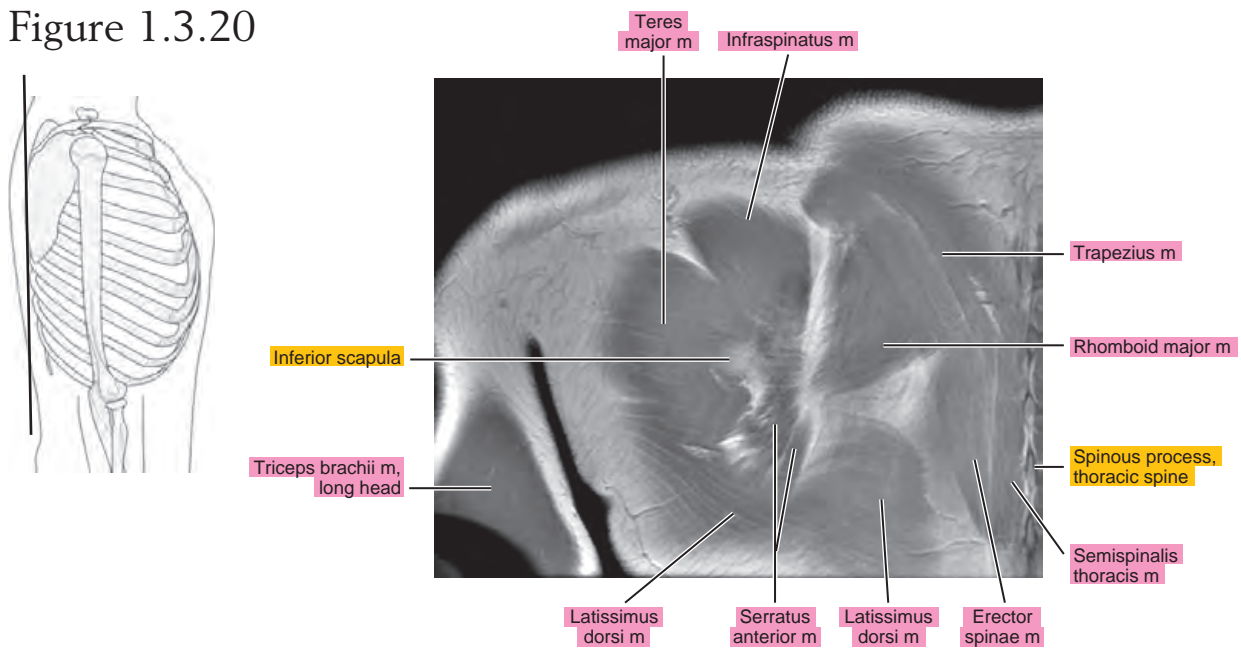


Figure 1.3.20



Chapter
2

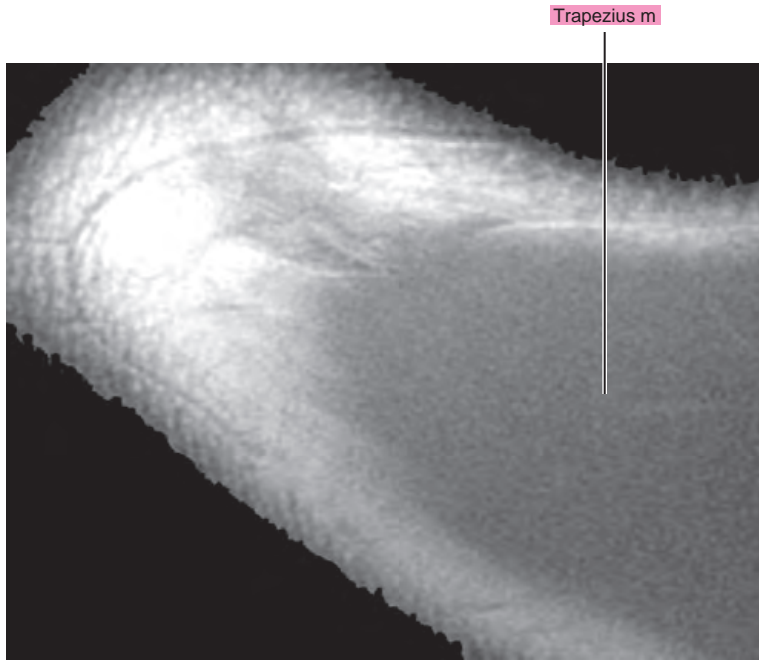
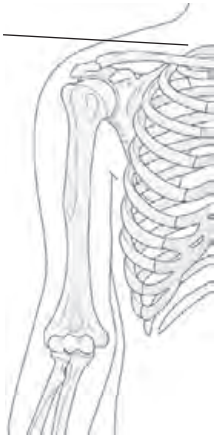MRI of the Shoulder

Table 2-1. Muscles of the Shoulder

MUSCLE	ORIGIN	INSERTION	NERVE SUPPLY
Pectoralis major	Medial half of the anterior surface of the clavicle, side and front of the sternum as far as the 6th costal cartilage, front and surfaces of the cartilage of the 2nd through 6th ribs, osseous ends of the 6th and 7th ribs, and aponeurosis of external abdominal oblique	Crest of the greater tubercle of the humerus, lateral lip of the intertubercular groove, deltoid tubercle, and fibrous periosteum of the intertubercular sulcus	Lateral and medial pectoral (C5 and C6 for the clavicular part, and C7, C8, and T1 for the sternocostal part)
Pectoralis minor	Aponeurotic slips from the 2nd through 5th ribs, near costal cartilages	Anterior half of the medial border and upper surface of the coracoid process of the scapula	Medial and lateral pectoral (C6, C7, C8)
Subclavius	First rib and its cartilage	Inferior surface of the clavicle between the costal and coracoid tuberosities	Nerve to subclavian (C5 or C5 and C6)
Deltoid	Lateral border and upper surface of the lateral third of the clavicle, the acromion, and the scapular spine	Deltoid tuberosity of the humerus	Axillary (C5, C6)
Supraspinatus	Supraspinous fossa and investing fascia	Shoulder capsule and superior facet of the greater tubercle of the humerus	Suprascapular (C4, C5, C6)
Infraspinatus	Infraspinous fossa, scapular spine, investing (deep) fascia, and adjacent aponeurotic septa	Shoulder capsule and middle facet of the greater tubercle of the humerus	Suprascapular (C4, C5, C6)
Teres minor	Upper two thirds of the axillary border of the scapula	Shoulder capsule and inferior facet of the greater tubercle of the humerus	Axillary (C4, C5, C6)
Subscapularis	Subscapularis fossa	Shoulder capsule and lesser tubercle of humerus and its shaft immediately below the tubercle	Two or three subscapular branches from posterior cord and upper and lower subscapular (C5, C6, C7)
Teres major	Inferior angle of the scapula	Medial lip of the intertubercular groove of the humerus	Lower subscapular (C6, C7)
Latissimus dorsi	Spine and interspinous ligaments of the lower five or six thoracic vertebrae, upper lumbar vertebrae, thoracodorsal fascia, posterior third of the crest of the ilium, and the lateral surface and upper edge of the lower three or four ribs	Muscle tendon inserts onto the ventral side of the lesser tubercle of the humerus and onto the floor of the intertubercular groove ventral to the tendon of the teres major. The tendon may extend to the greater tubercle of the humerus.	Thoracodorsal (C6, C7, C8)

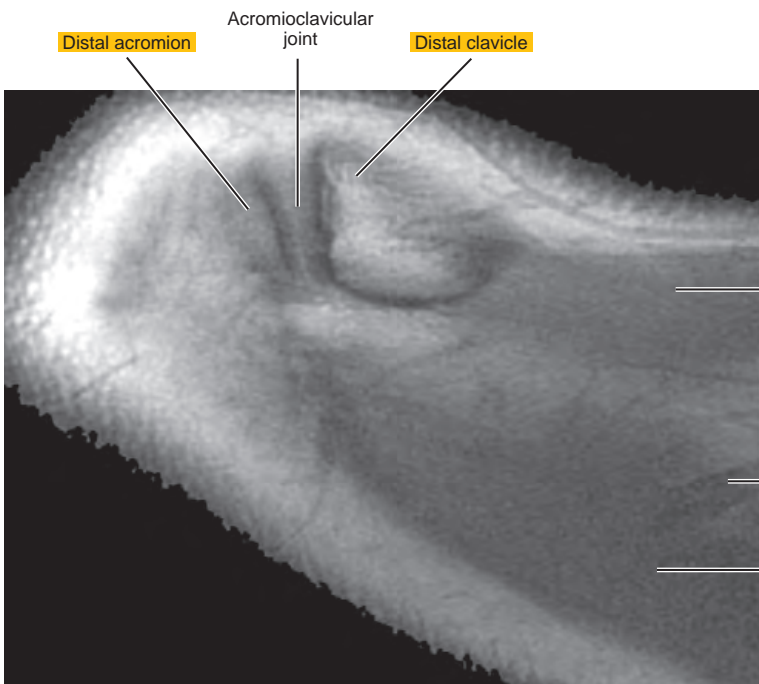
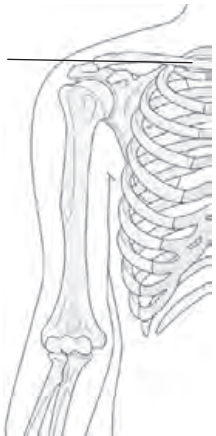AXIAL

Figure 2.1.1



artery = a
arteries = aa
vein = v
veins = vv
muscle = m
muscles = mm
tendon = t
tendons = tt
nerve = n
nerves = nn
ligament = lig
ligaments = lig
nerve & vessels
bone

Figure 2.1.2



Trapezius m

Thoracoacromial a,
clavicular branch

Trapezius m

Figure 2.1.3

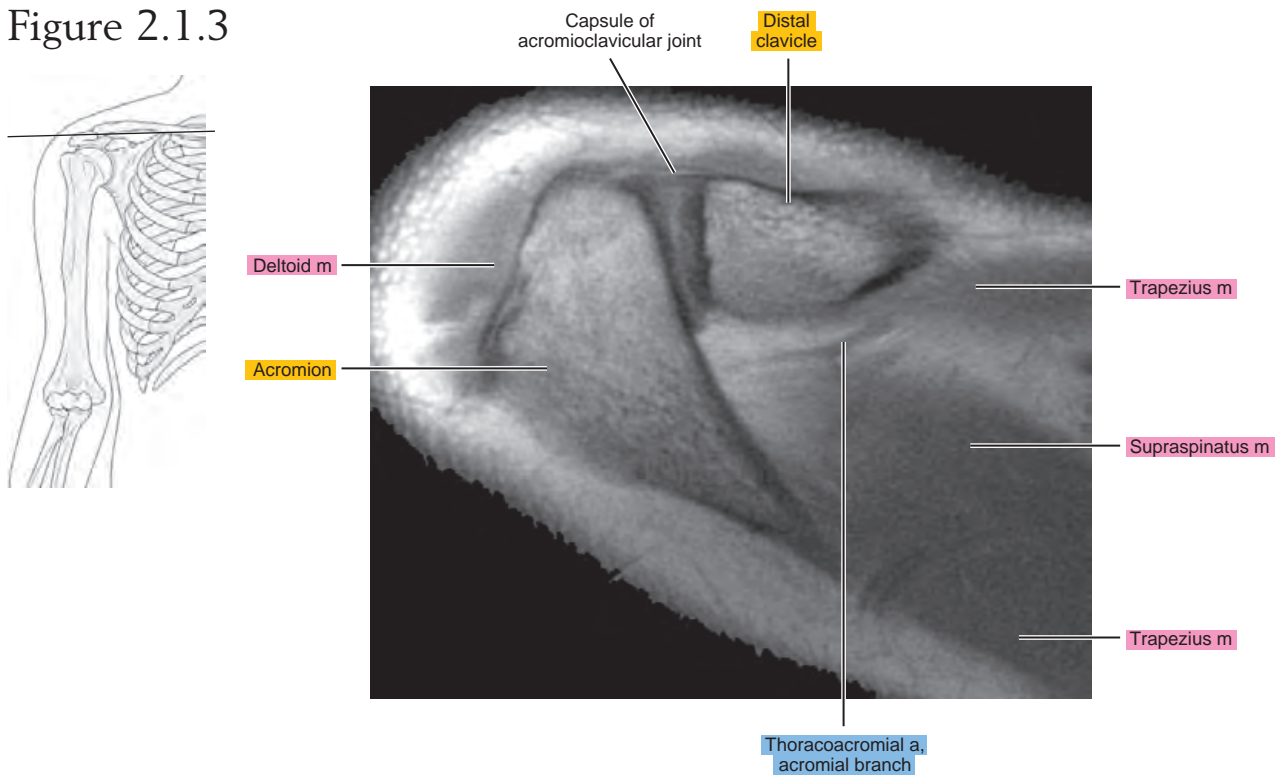


Figure 2.1.4

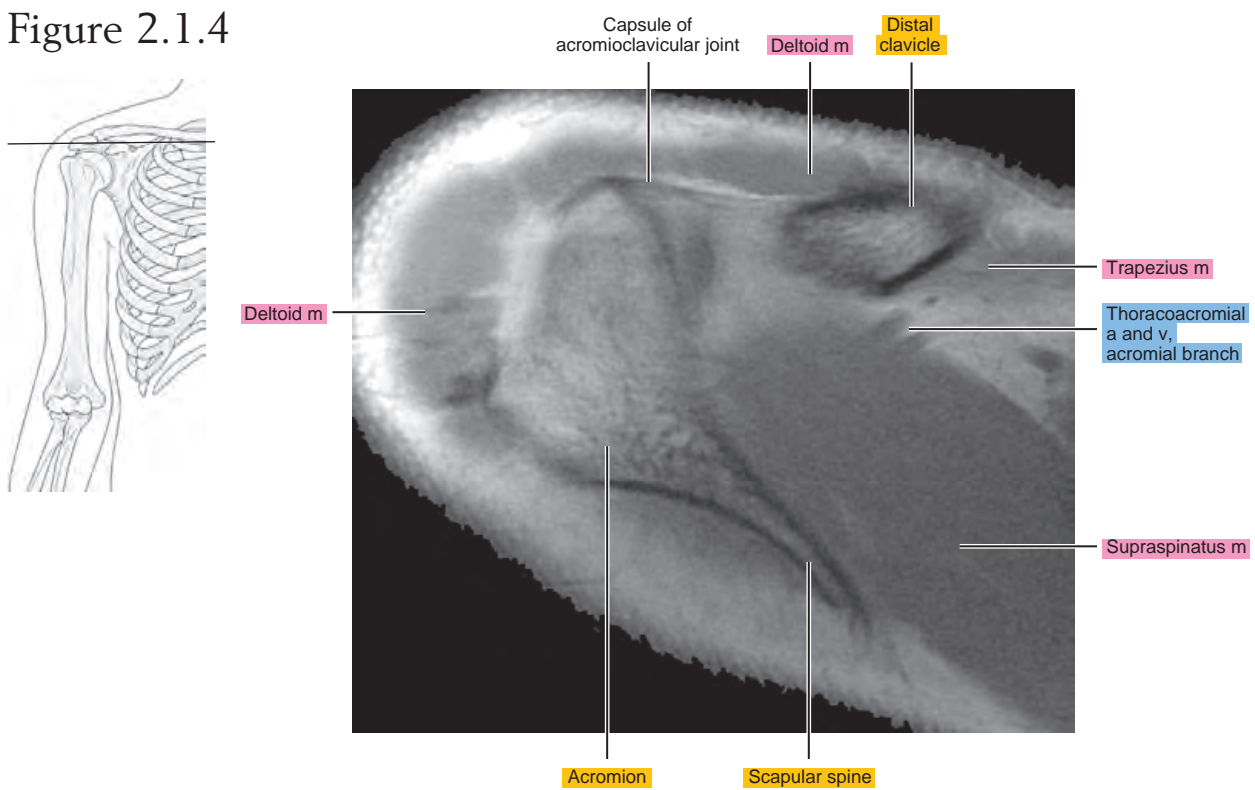


Figure 2.1.5

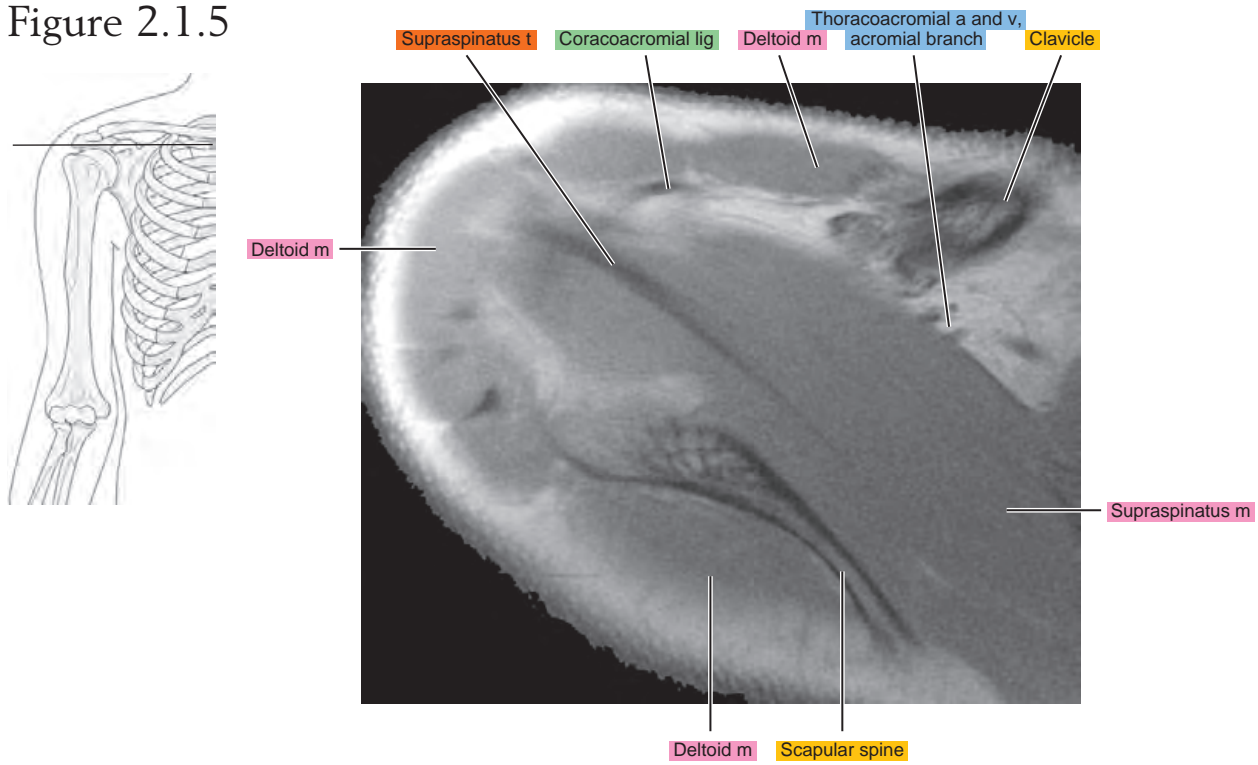


Figure 2.1.6

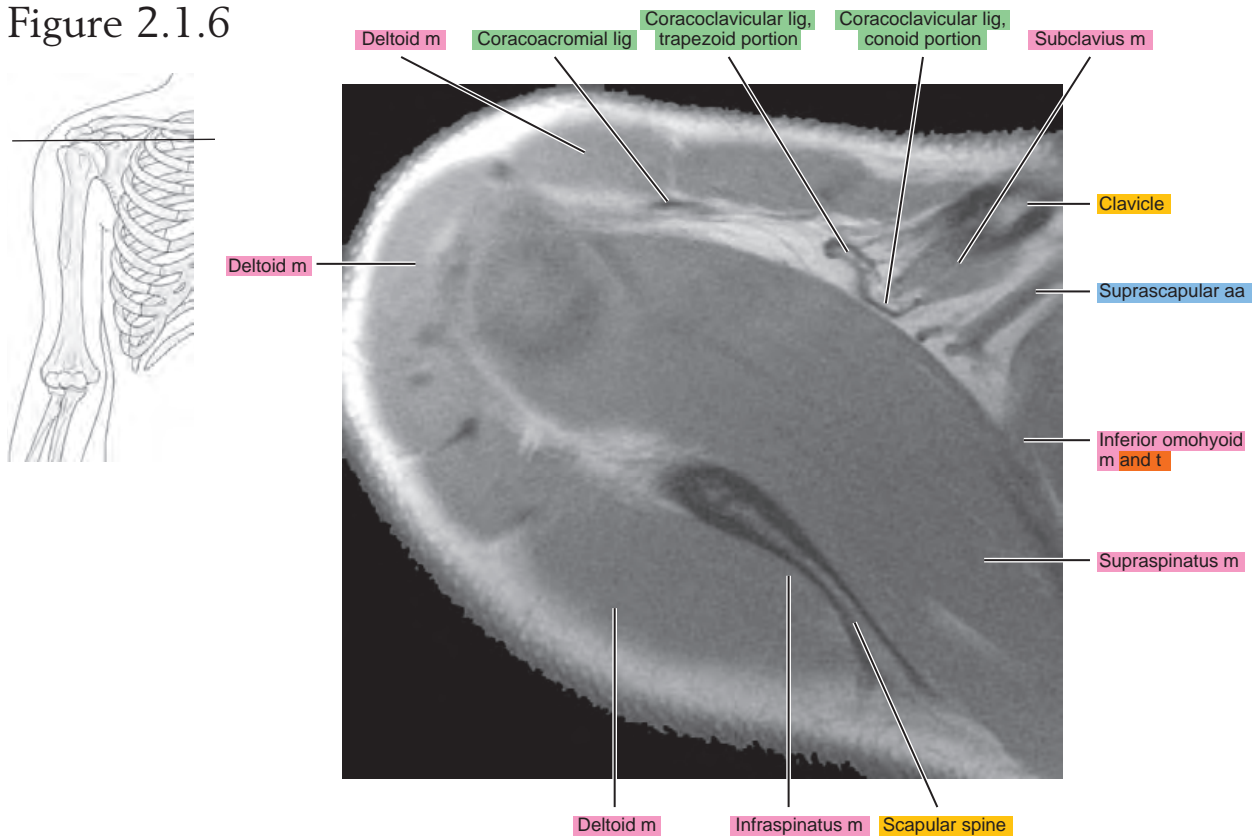


Figure 2.1.7

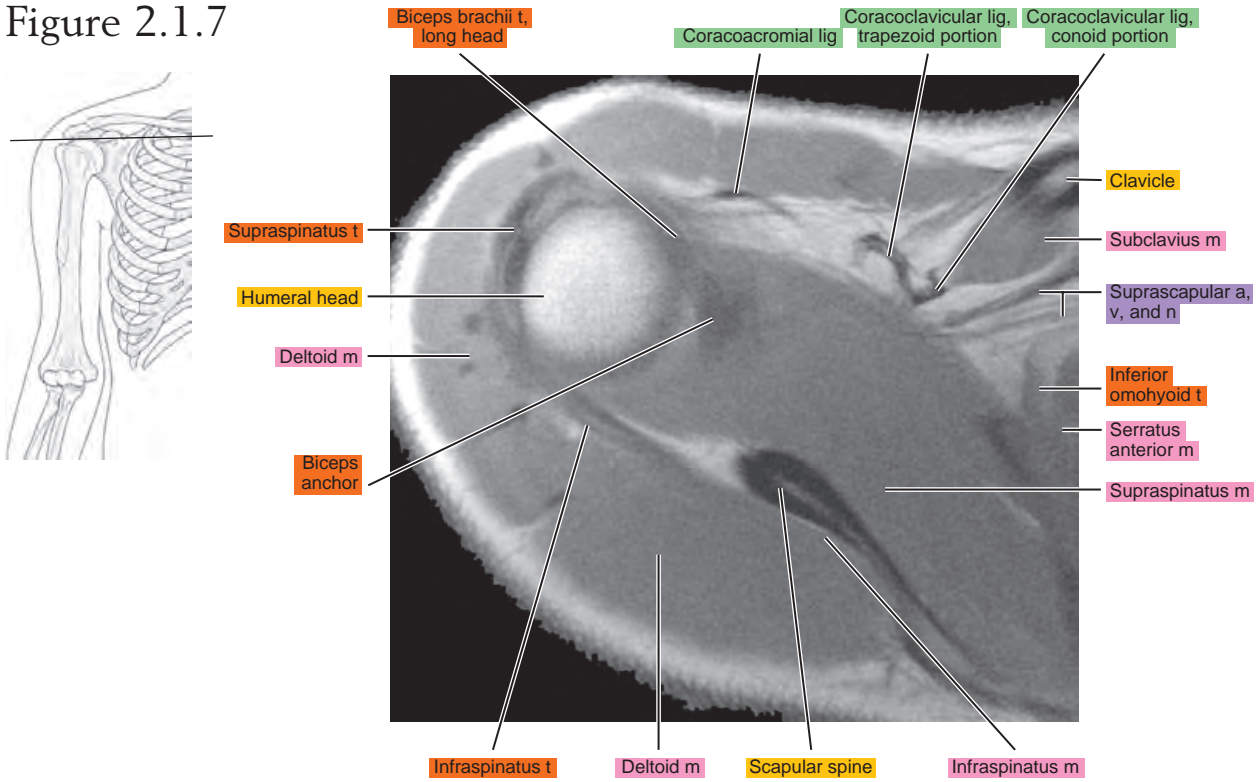


Figure 2.1.8

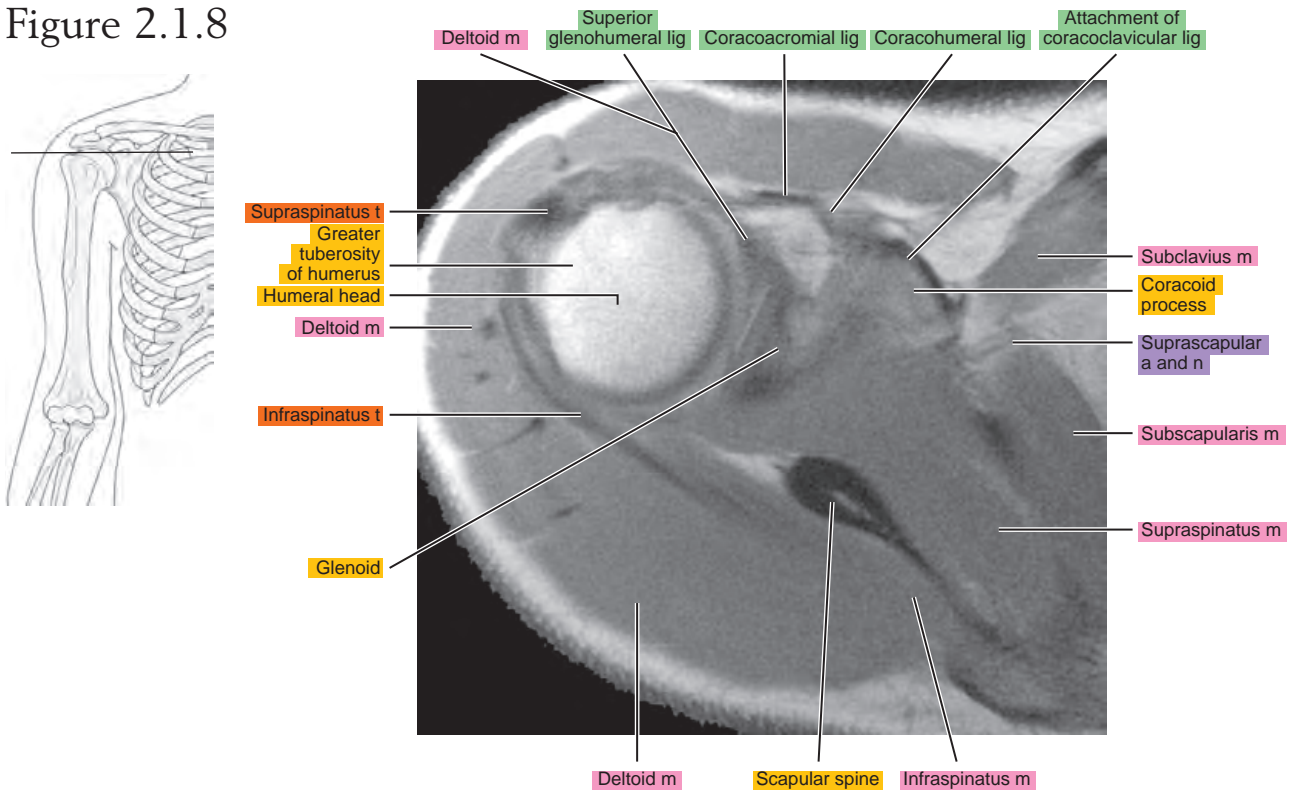


Figure 2.1.9

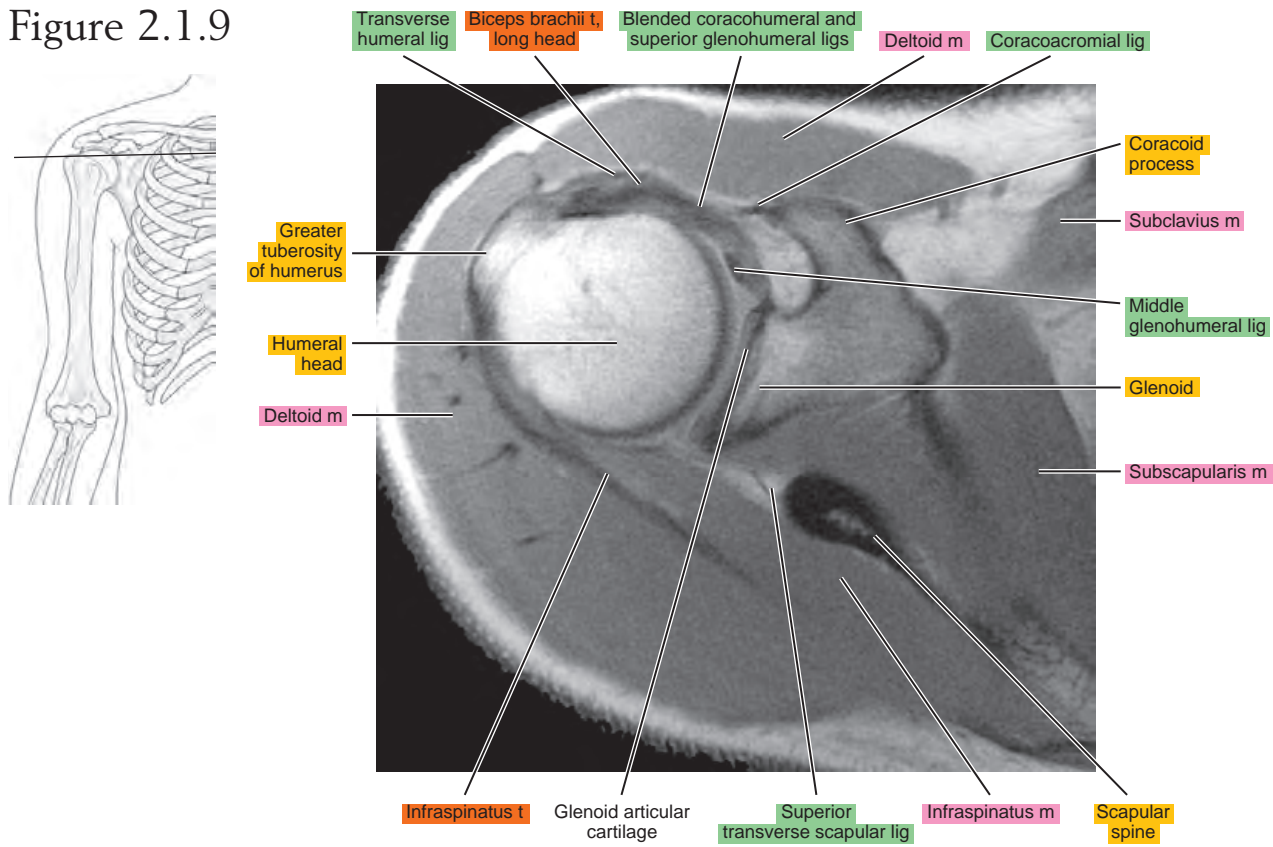


Figure 2.1.10

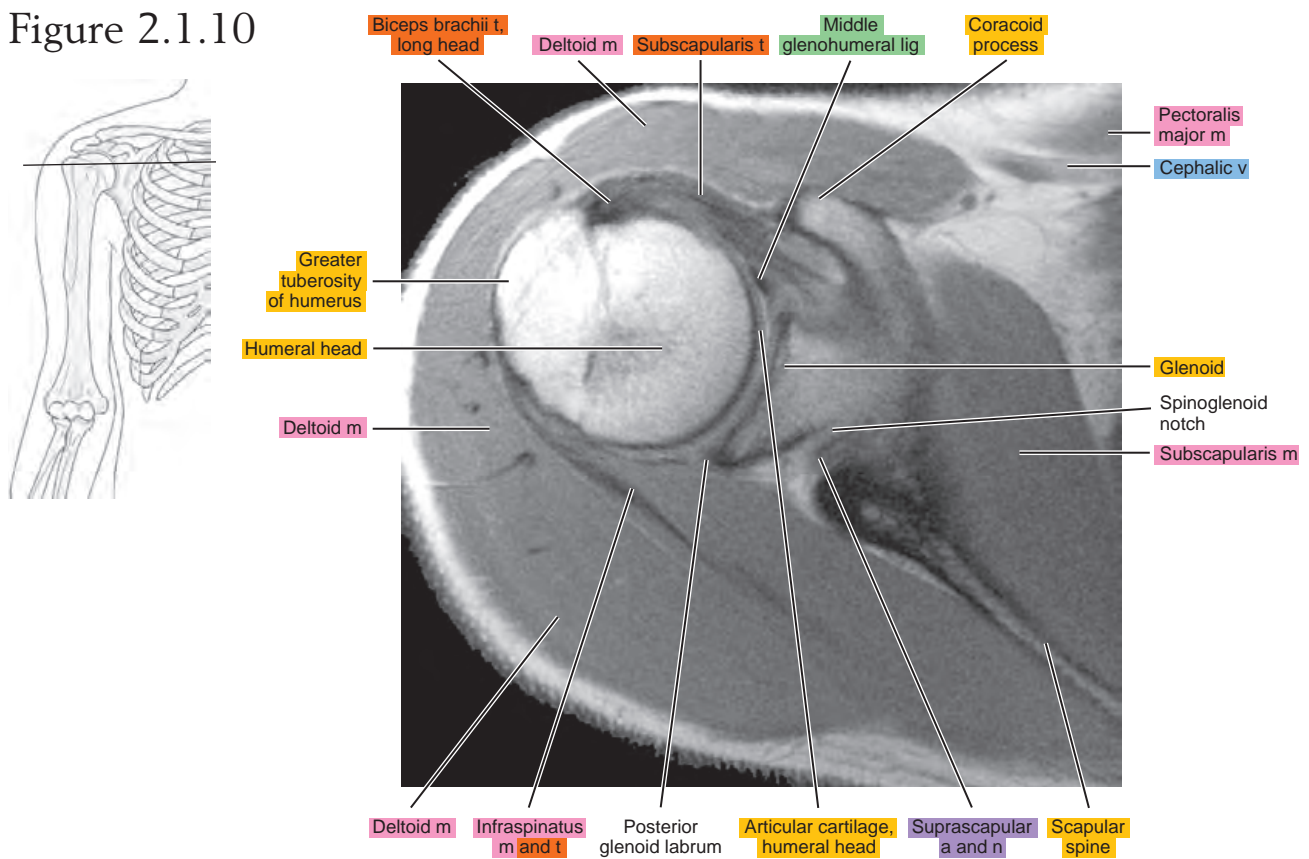


Figure 2.1.11

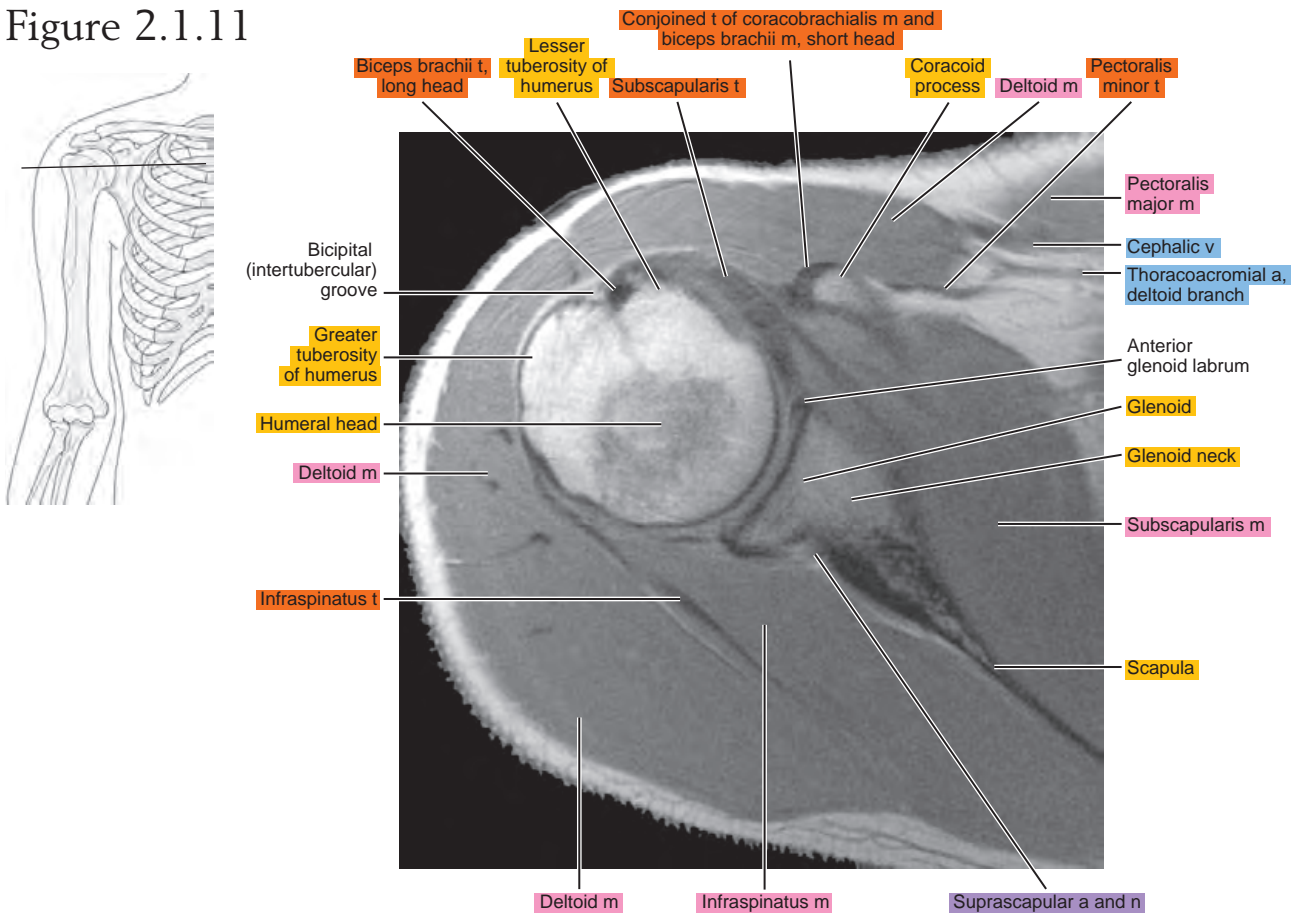


Figure 2.1.12

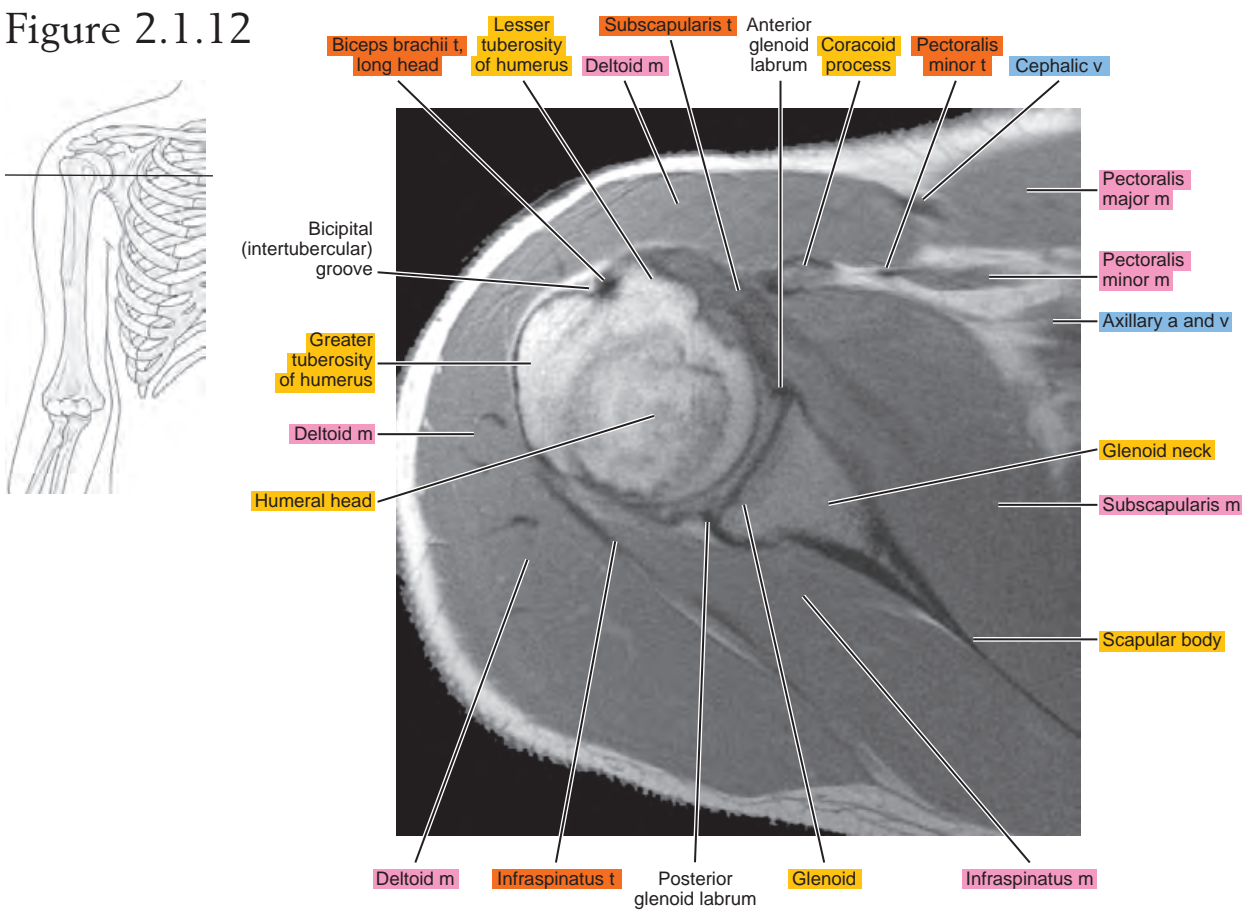


Figure 2.1.13

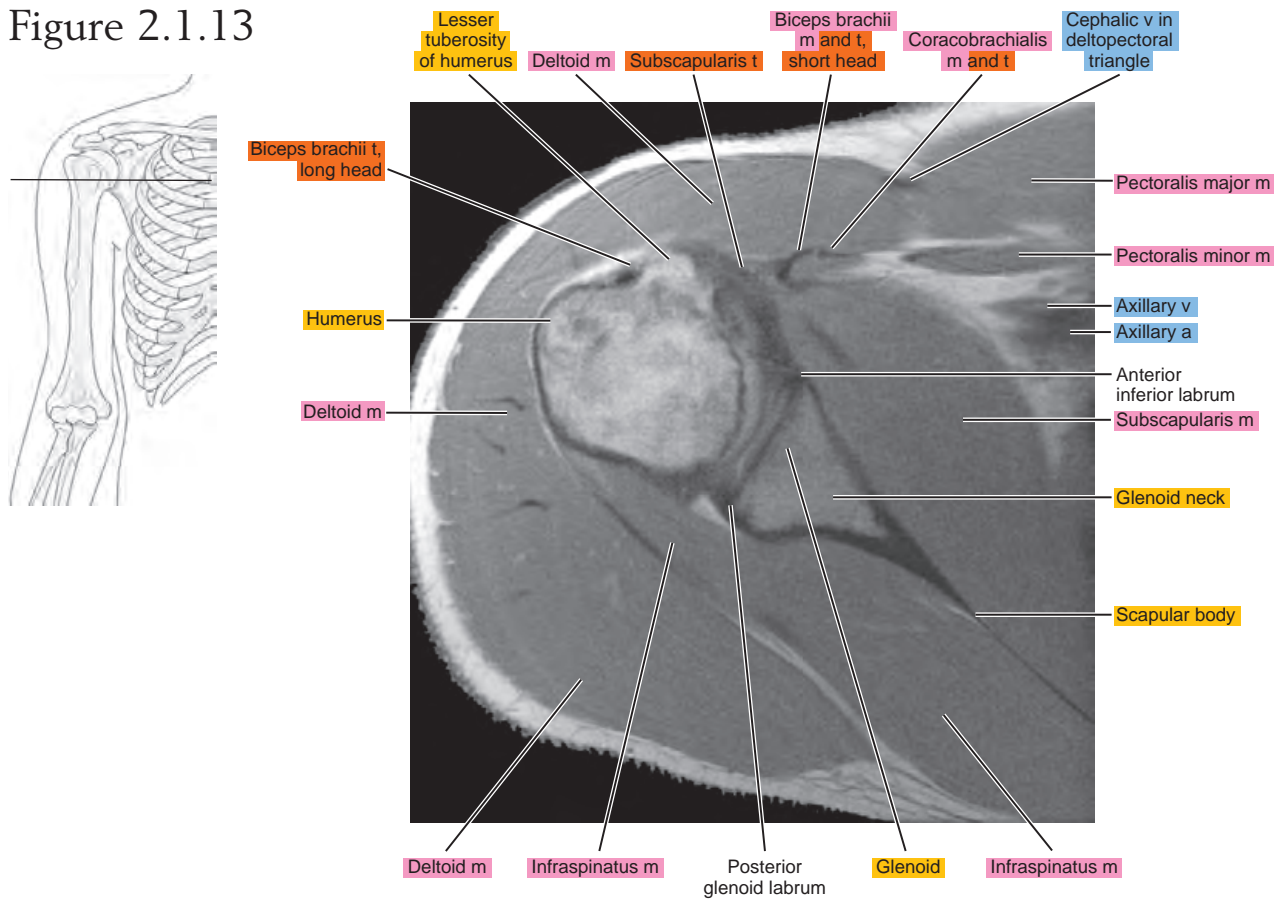


Figure 2.1.14

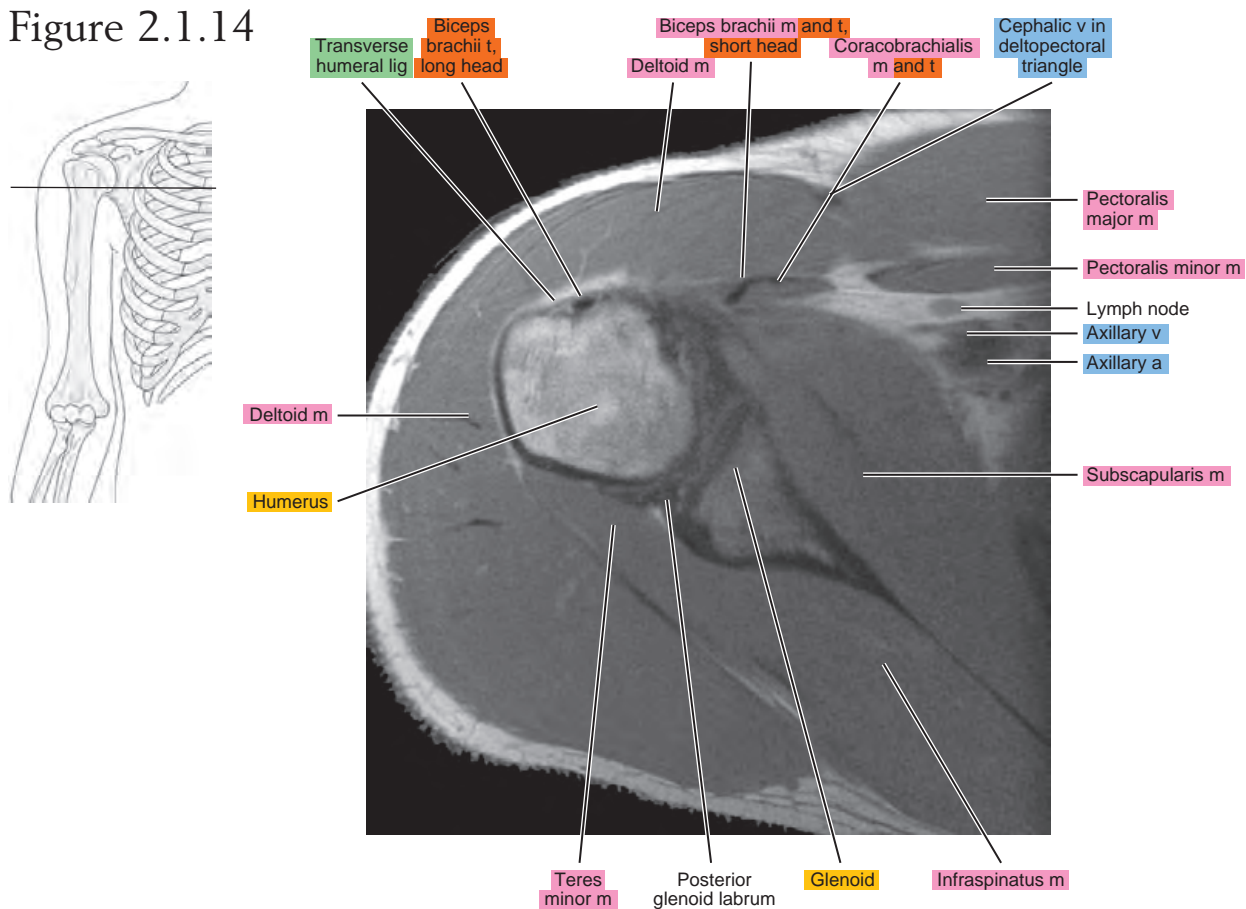


Figure 2.1.15

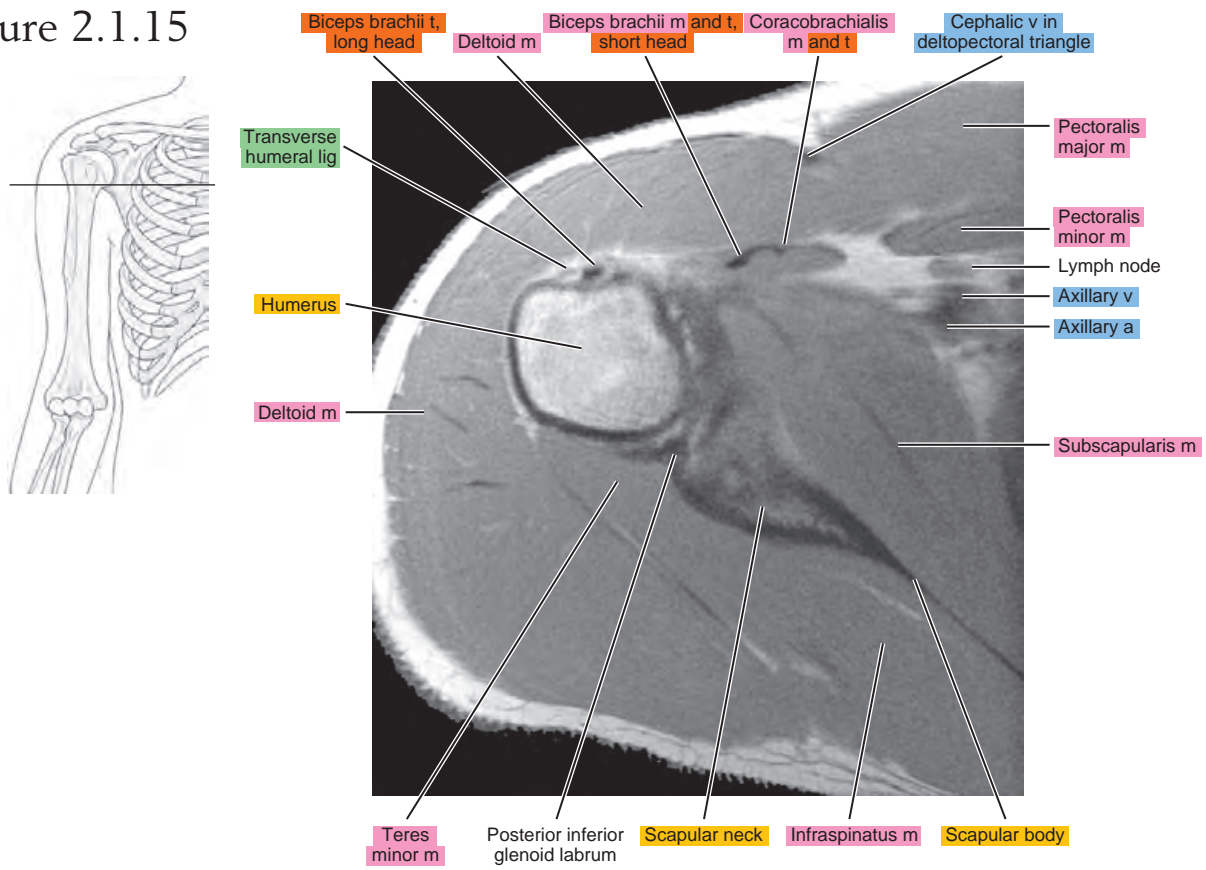


Figure 2.1.16

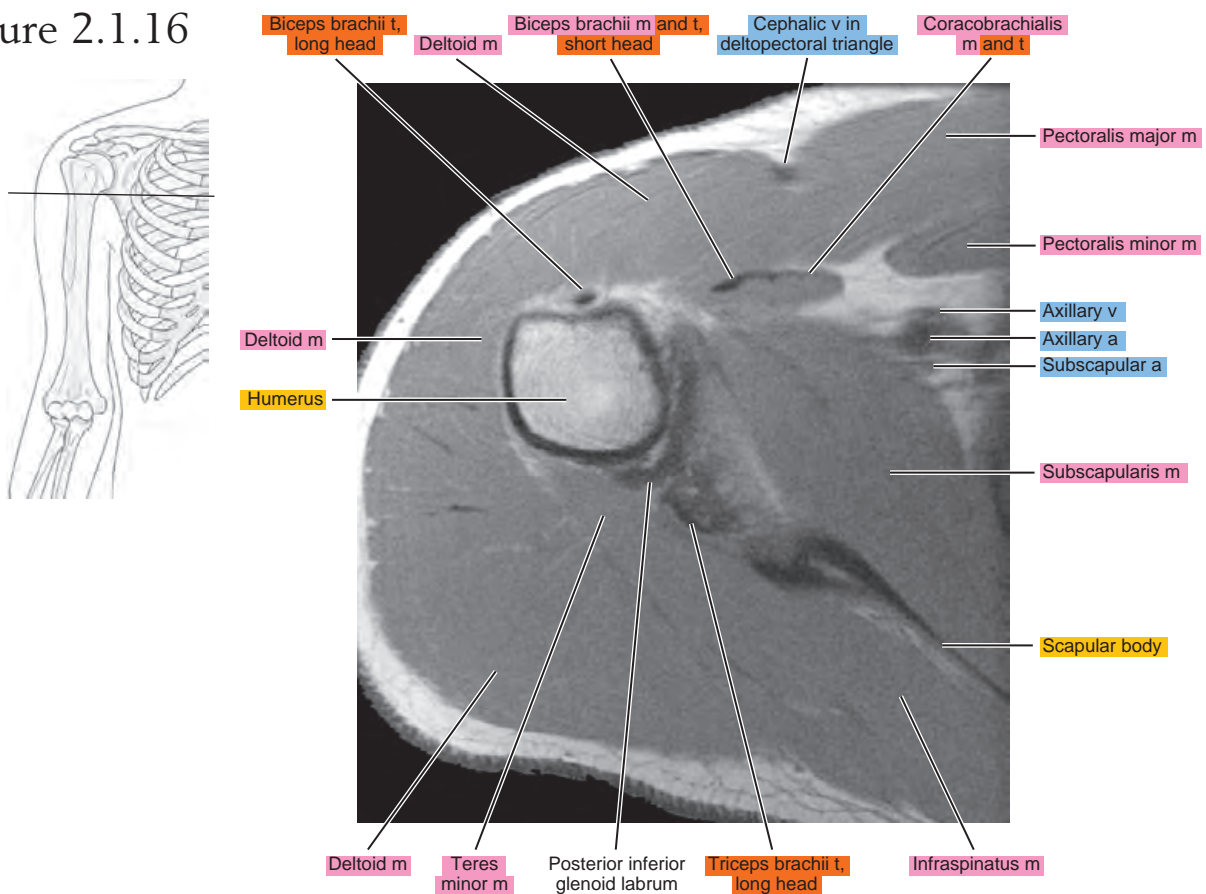


Figure 2.1.17

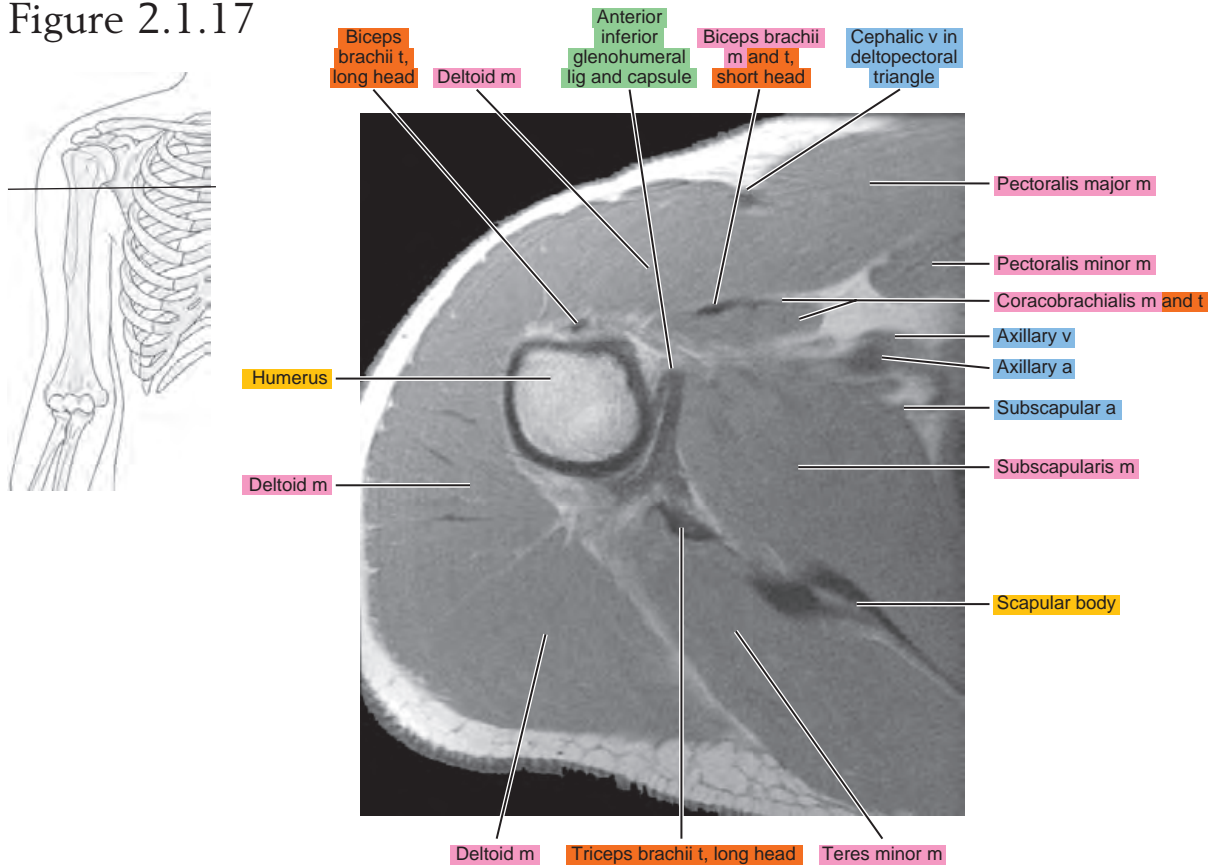


Figure 2.1.18

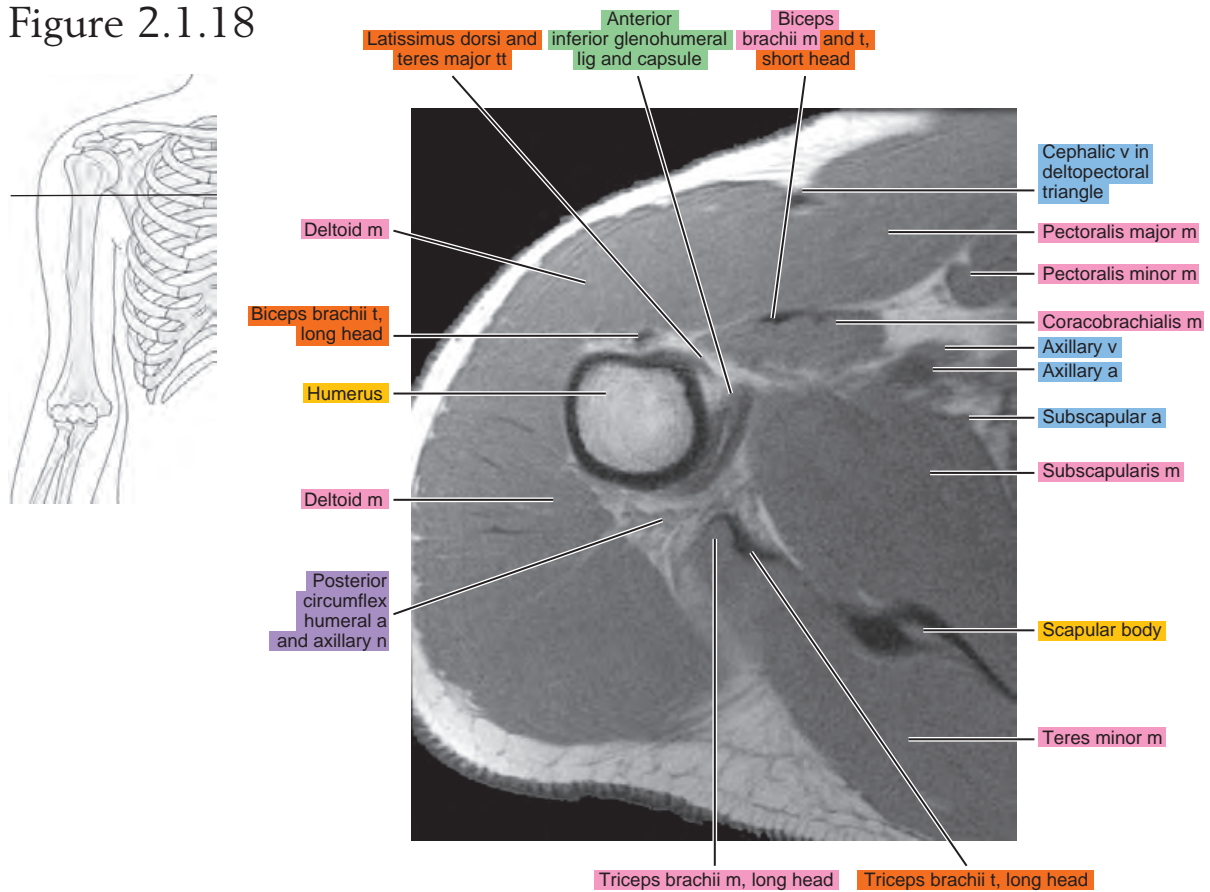


Figure 2.1.19

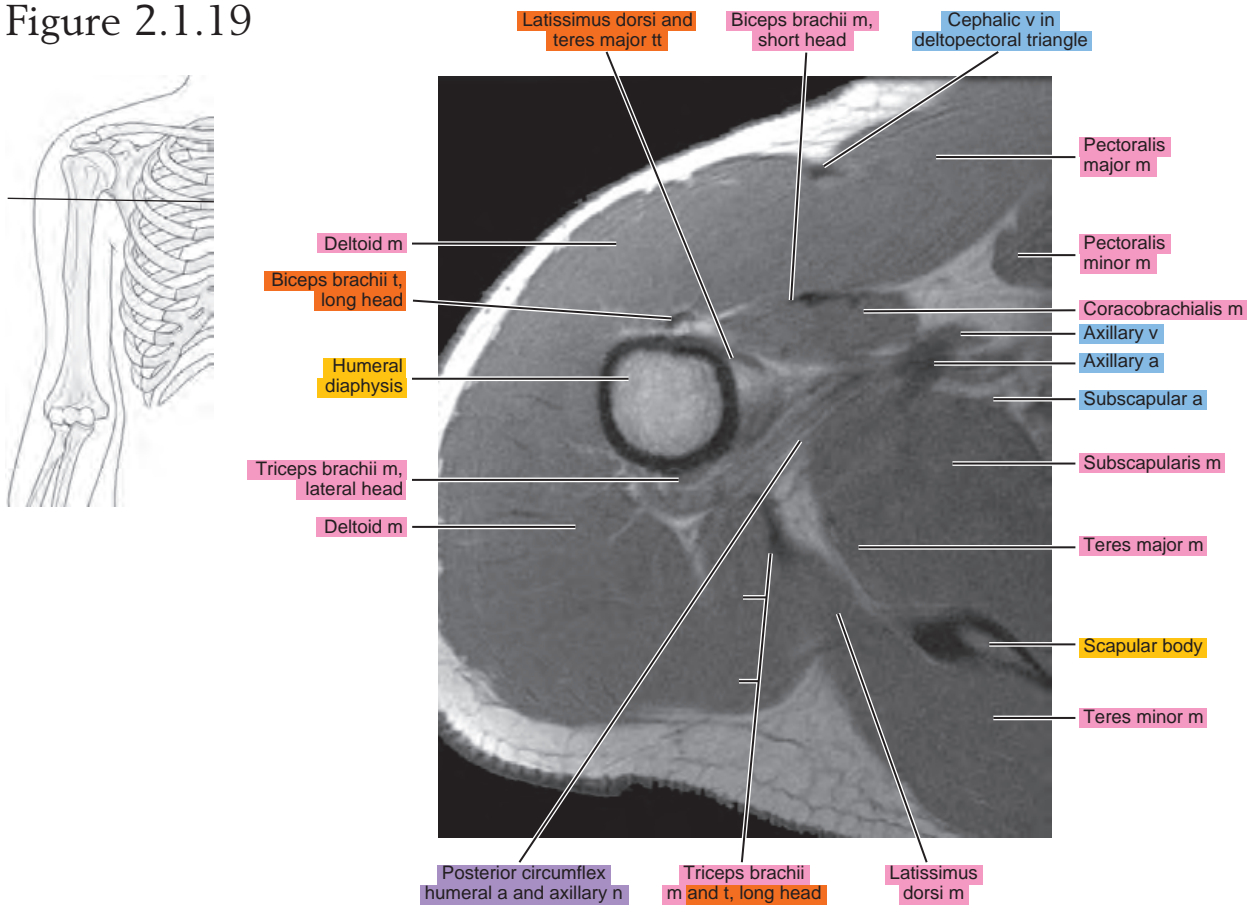
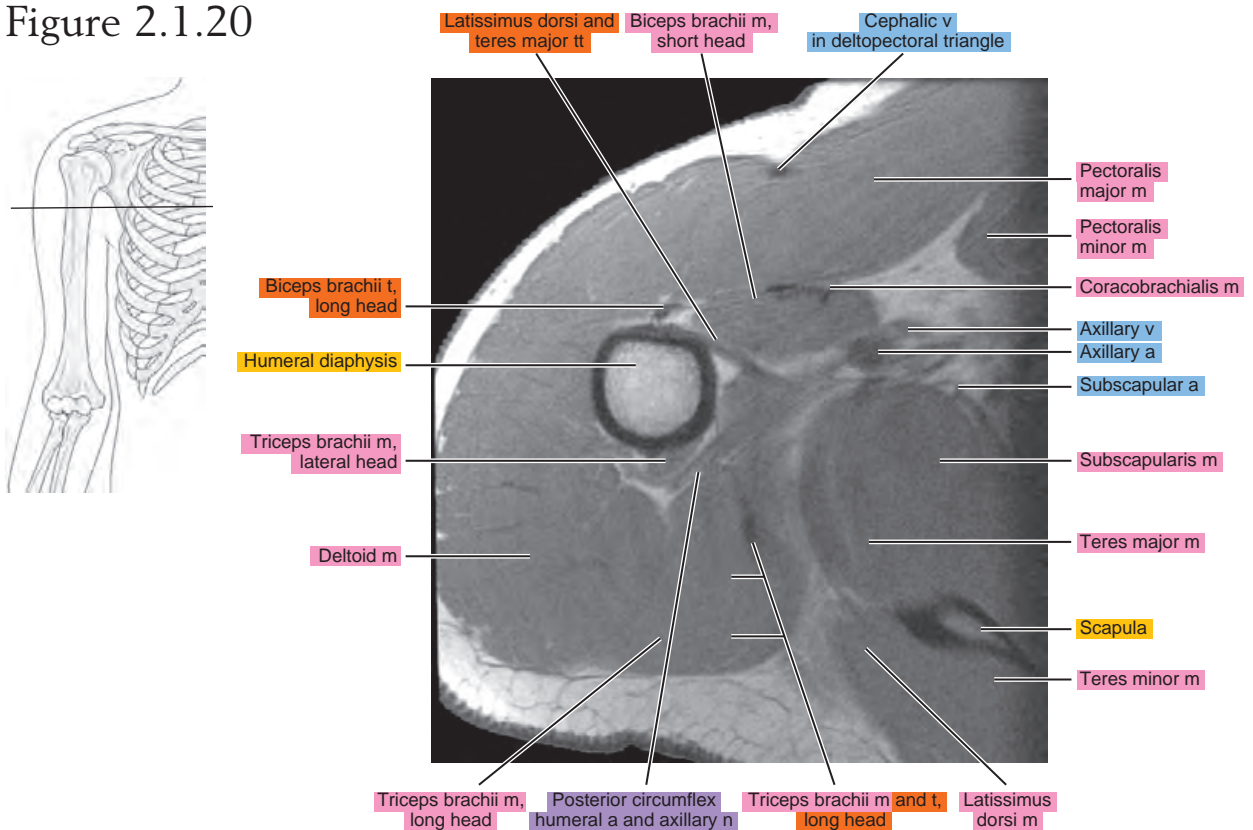
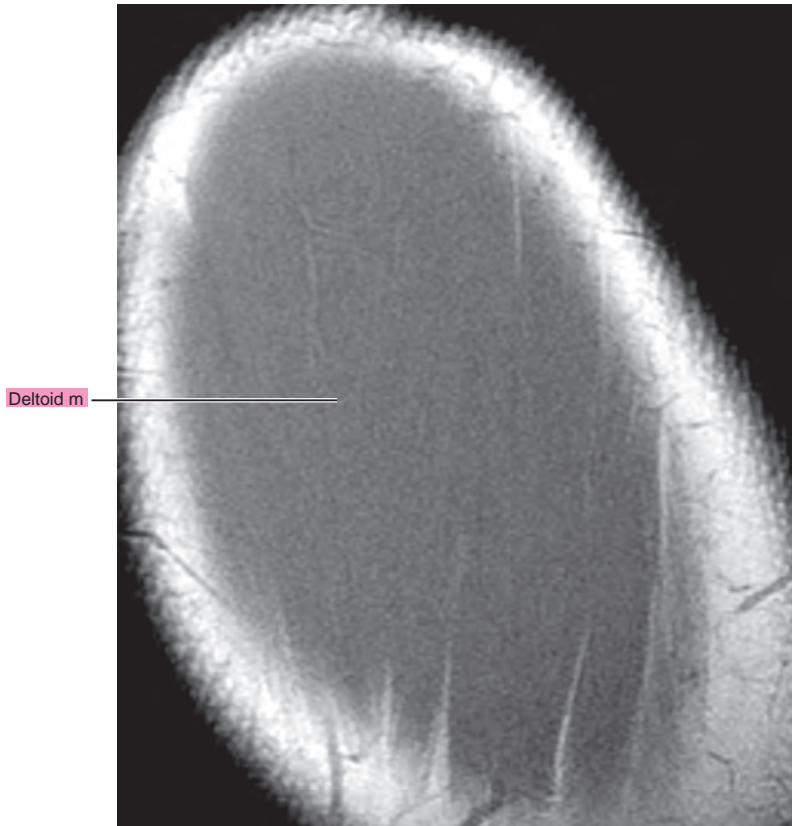
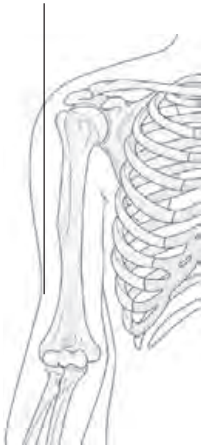


Figure 2.1.20



OBLIQUE SAGITTAL

Figure 2.2.1



artery = a
arteries = aa
vein = v
veins = vv
muscle = m
muscles = mm
tendon = t
tendons = tt
nerve = n
nerves = nn
ligament = lig
ligaments = ligs
nerve & vessels
bone

Figure 2.2.2

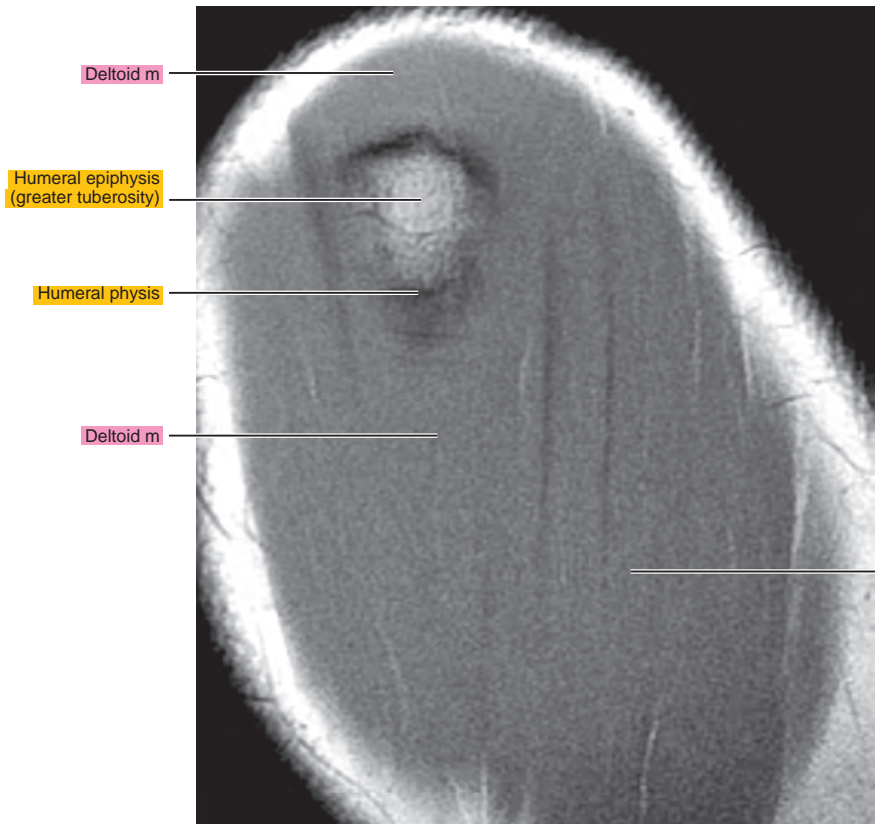
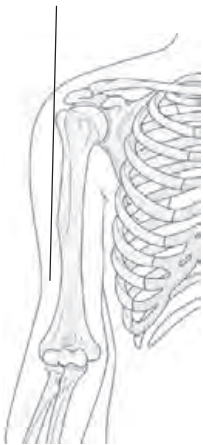


Figure 2.2.3

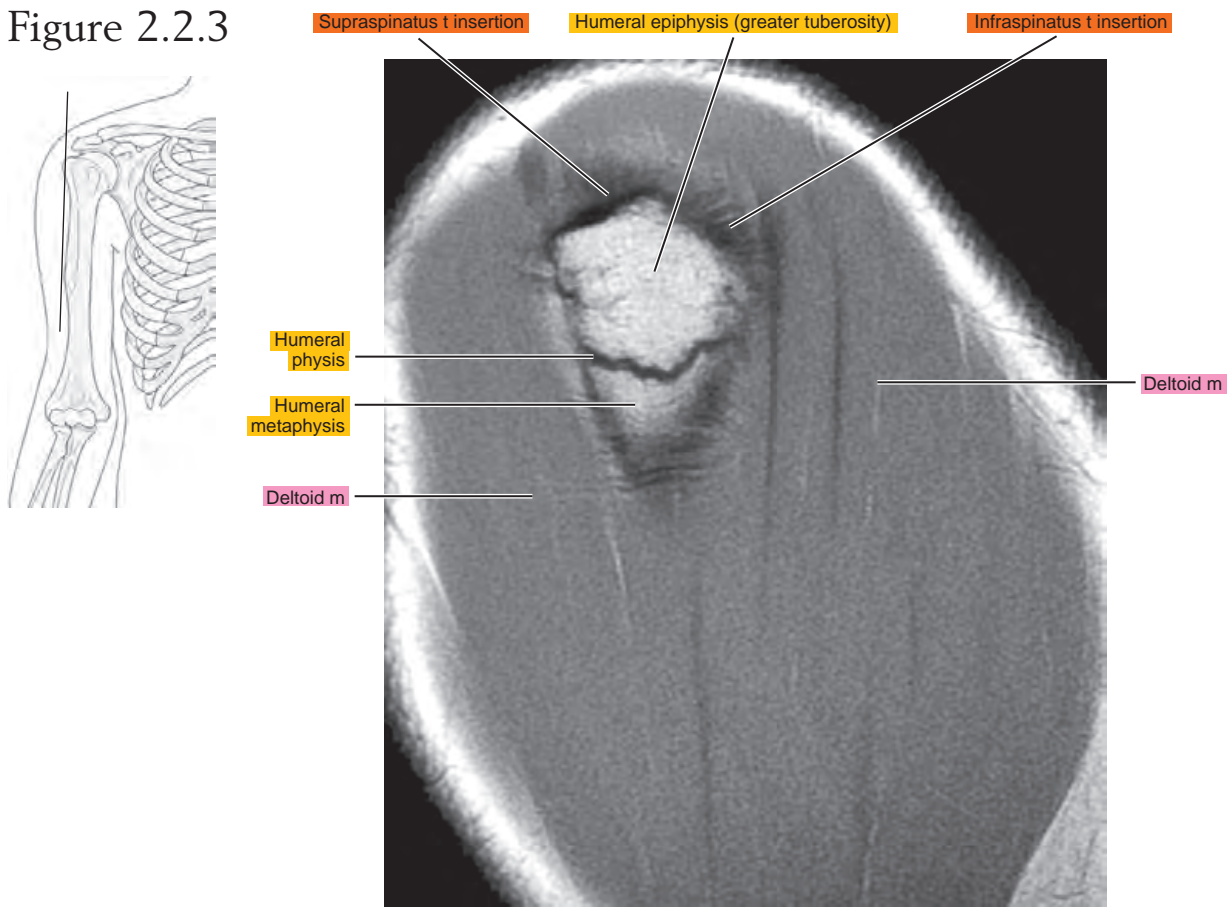


Figure 2.2.4

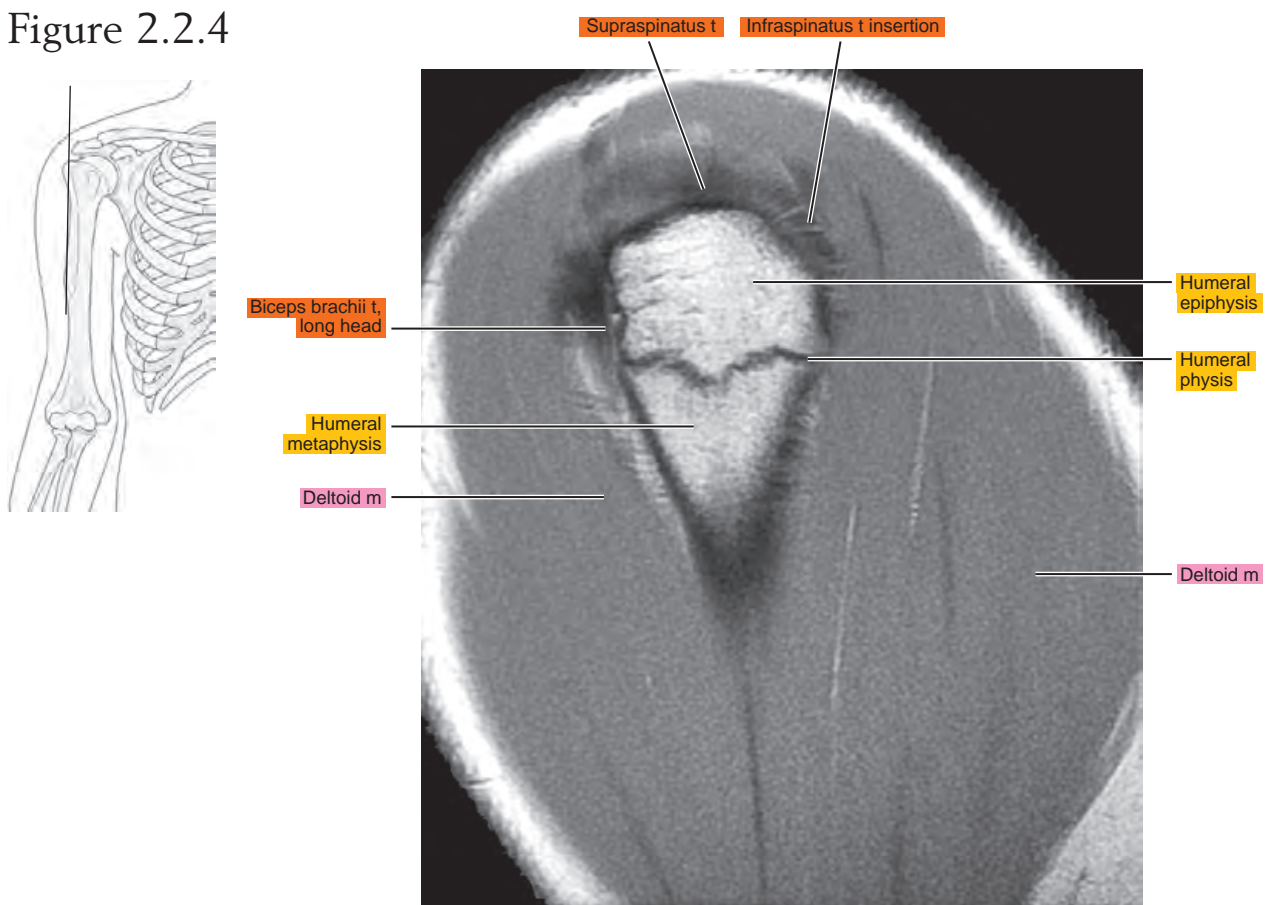


Figure 2.2.5

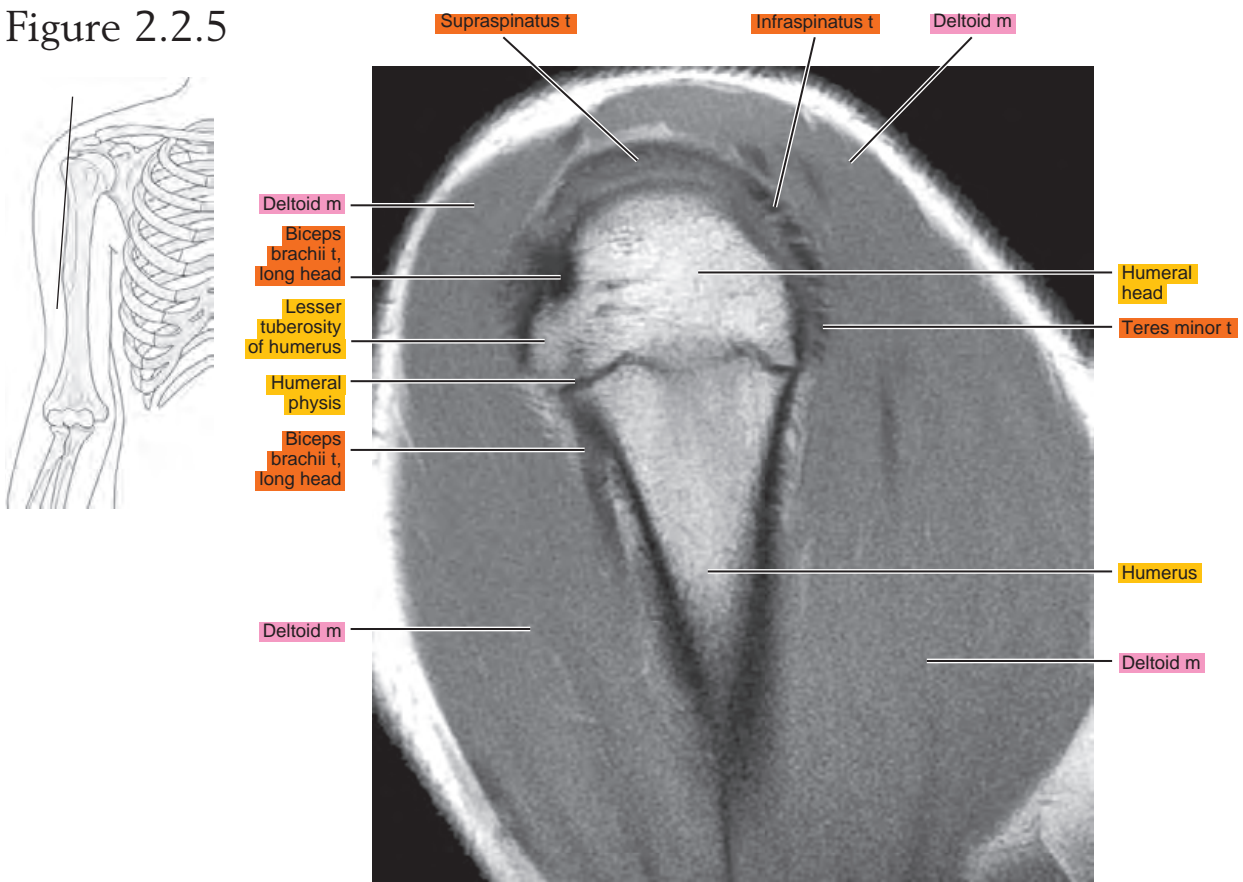


Figure 2.2.6

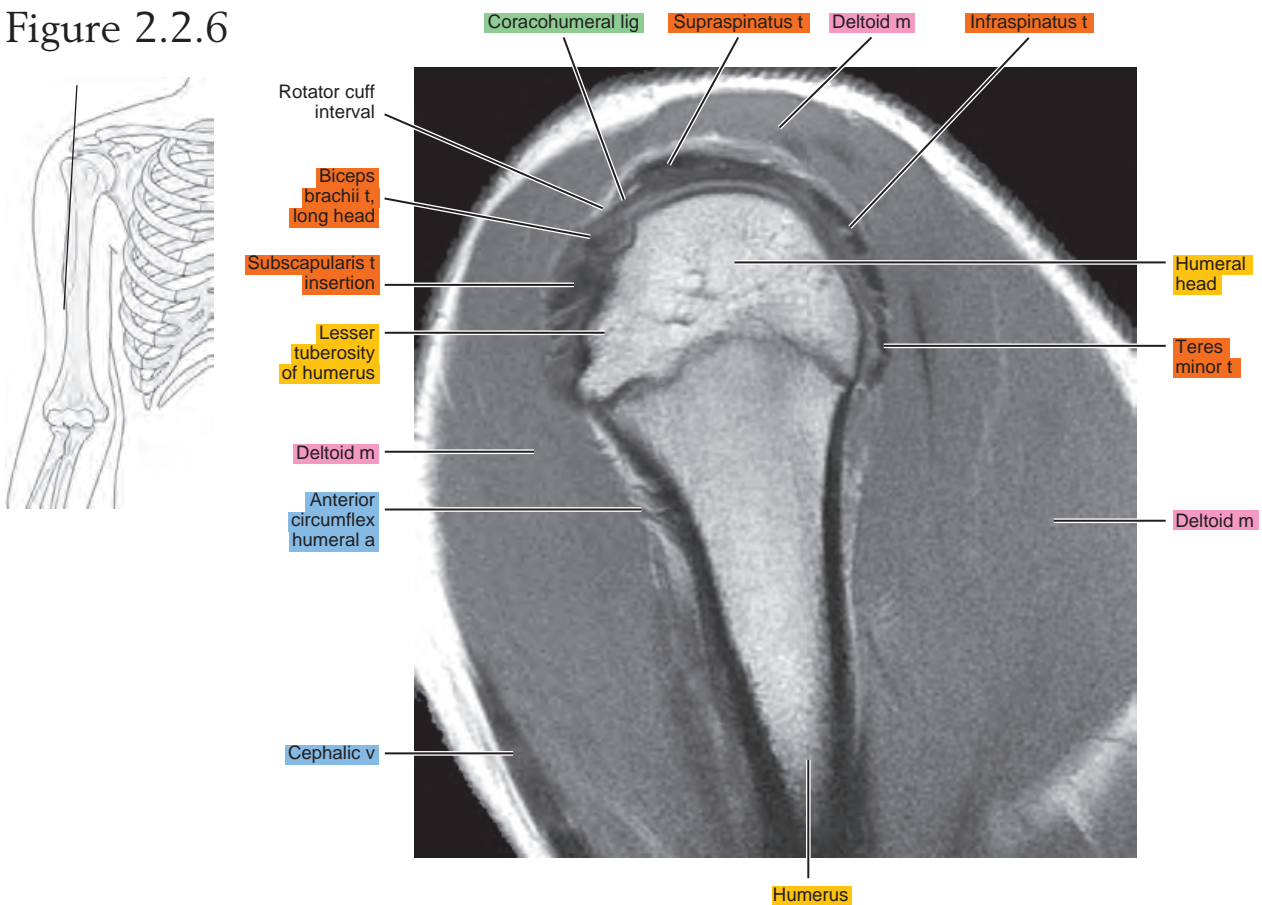


Figure 2.2.7

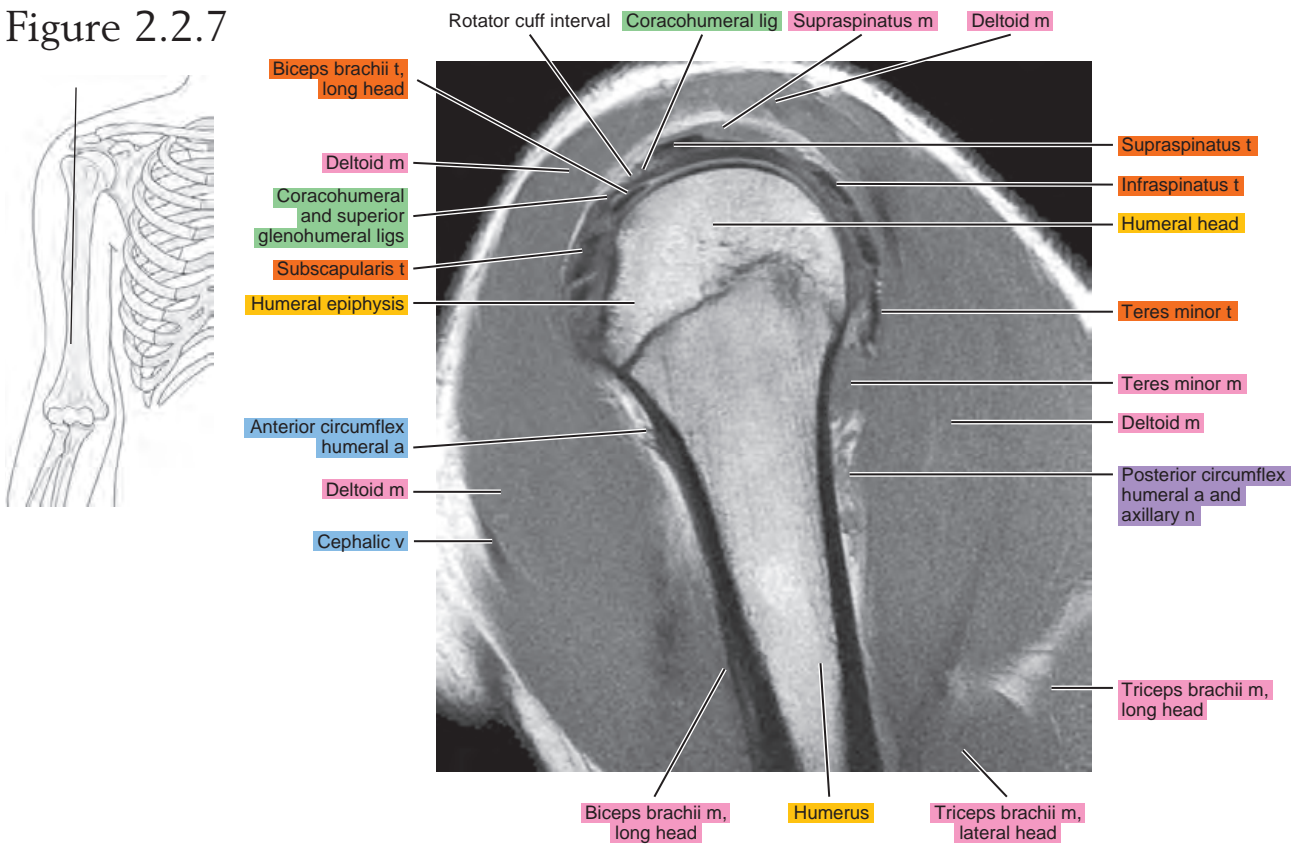


Figure 2.2.8

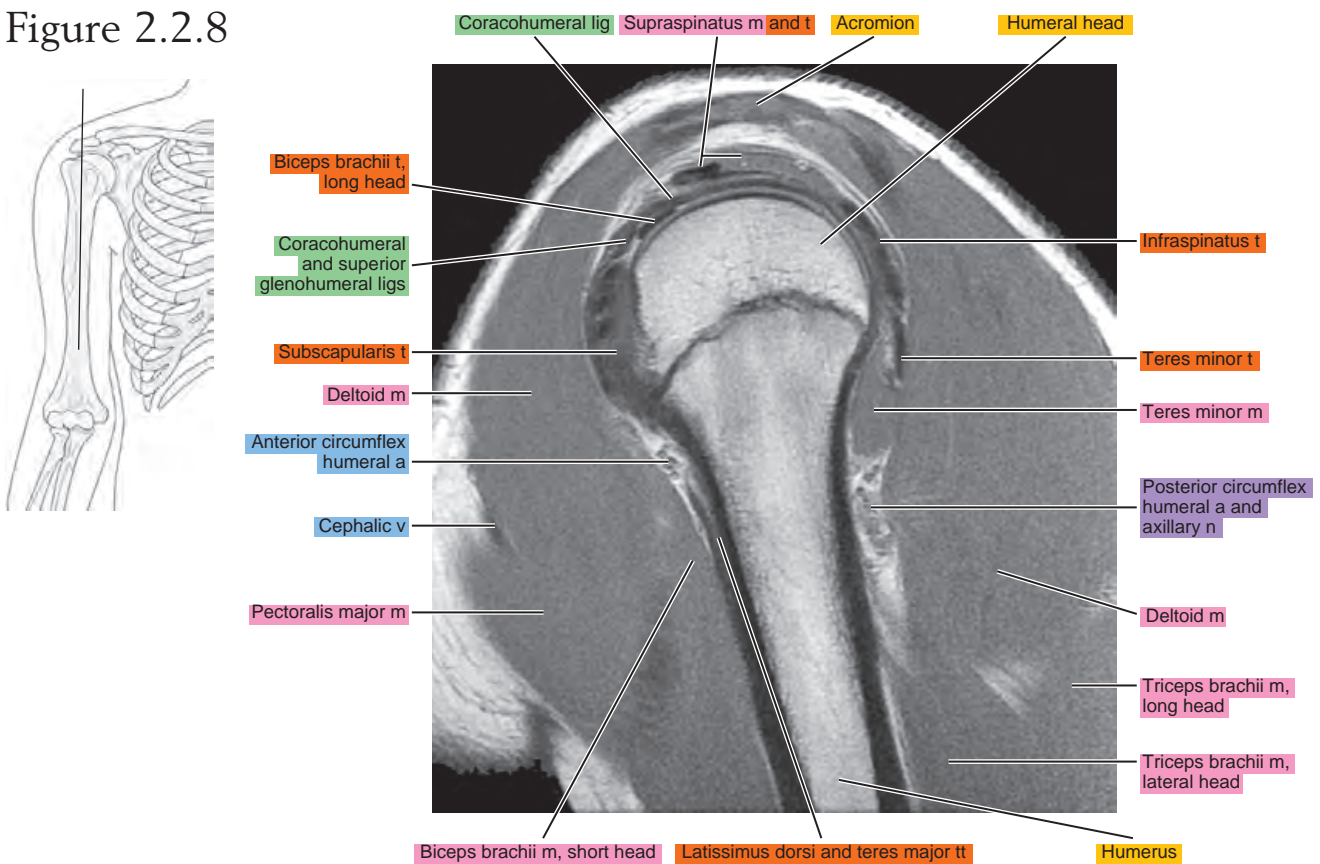


Figure 2.2.9

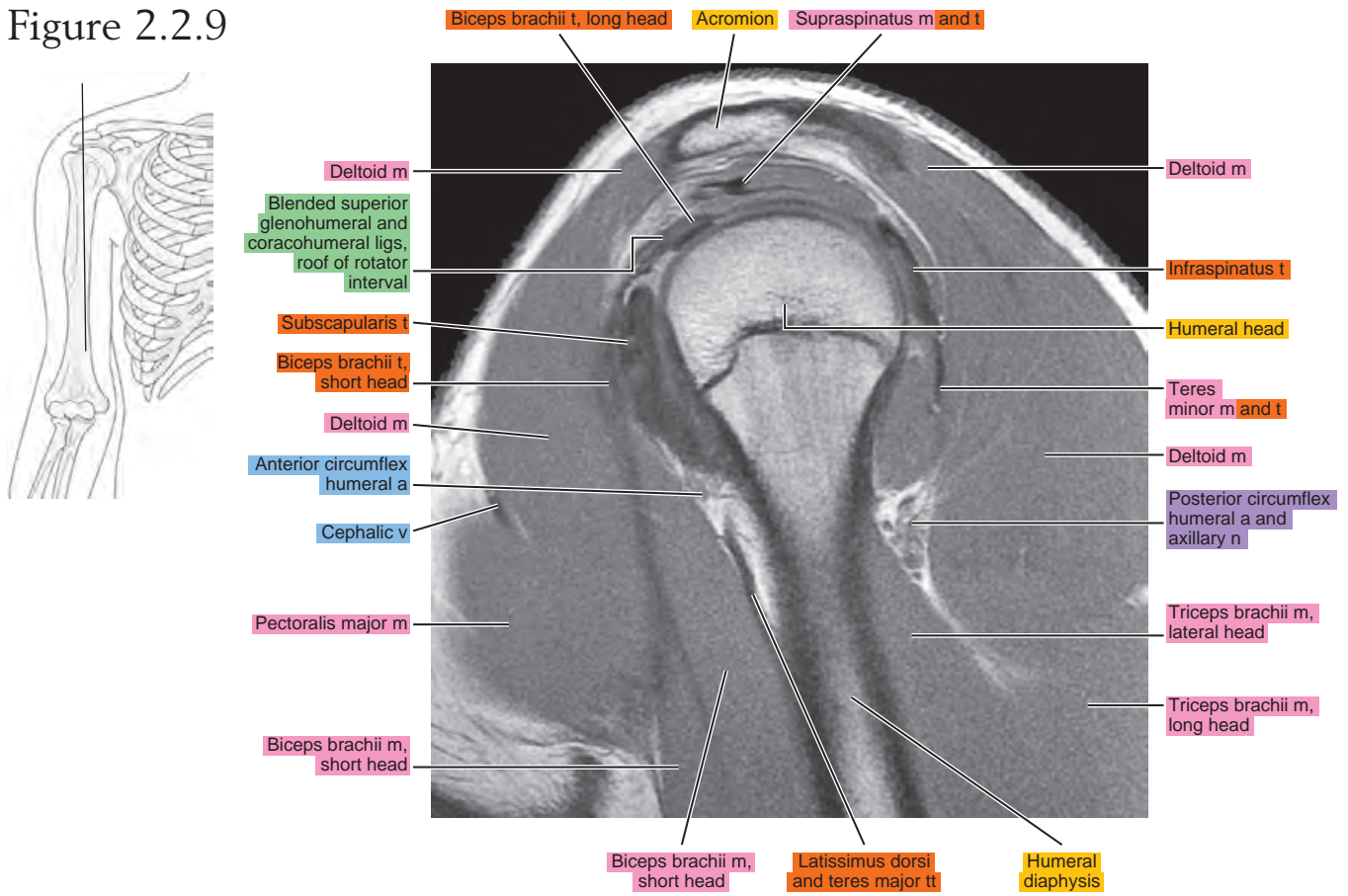


Figure 2.2.10

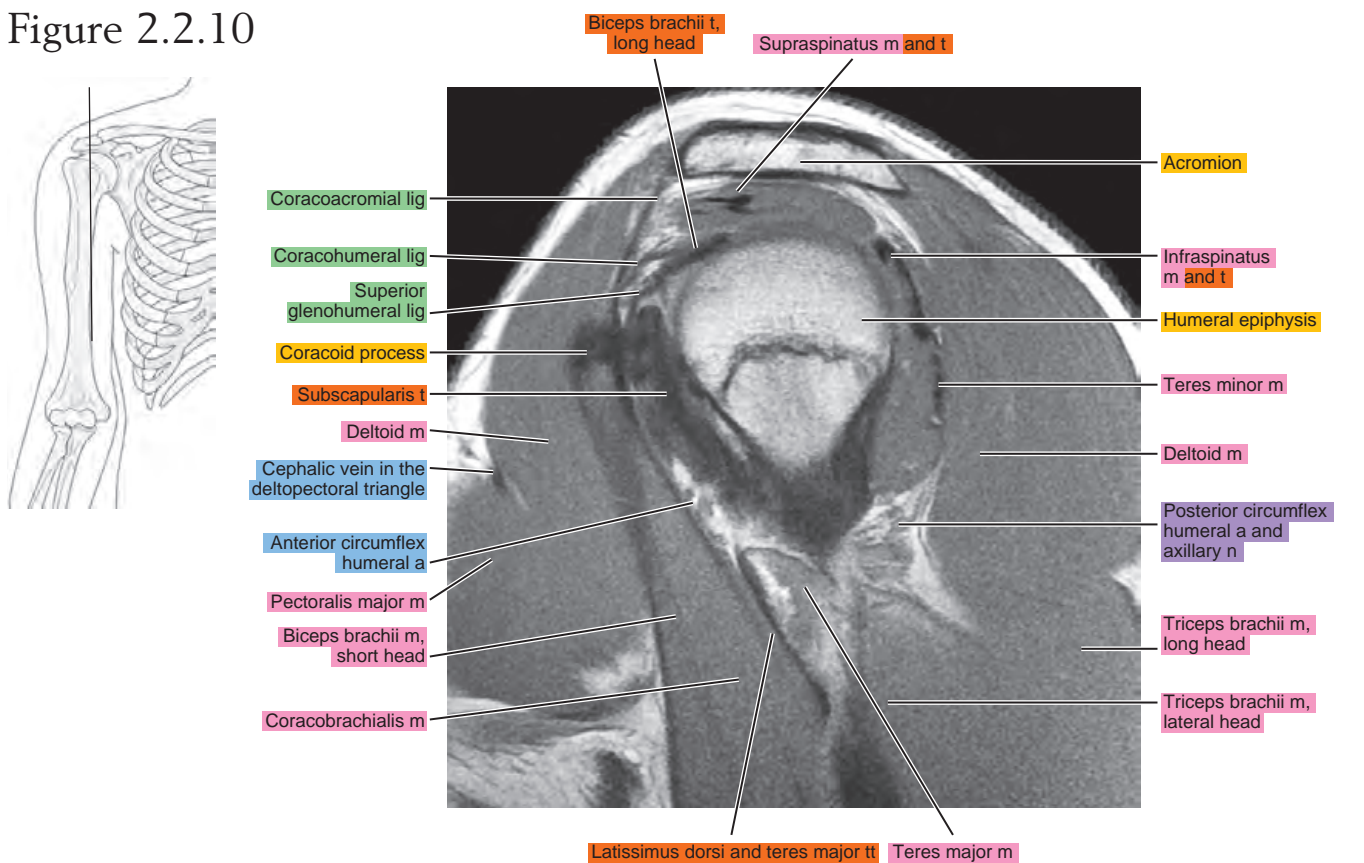


Figure 2.2.11

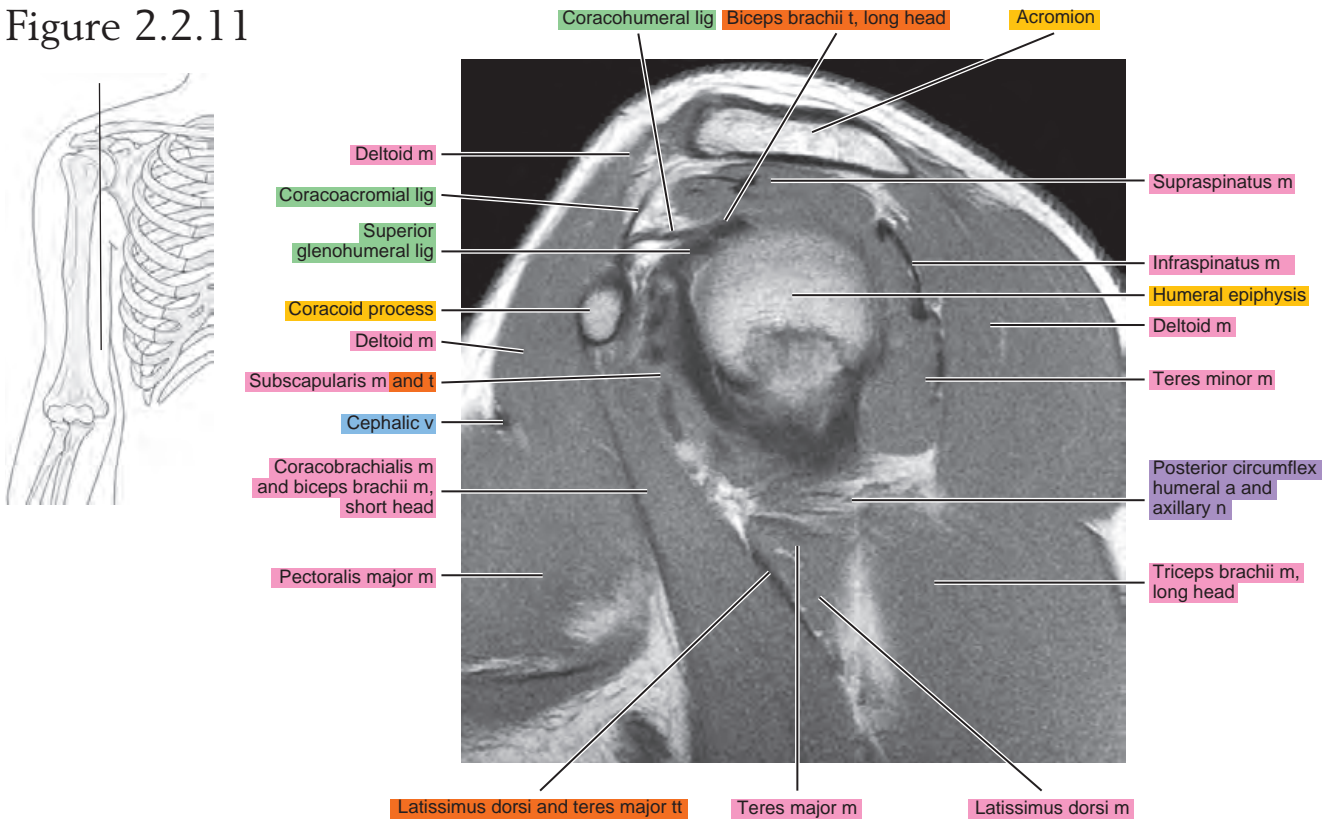


Figure 2.2.12

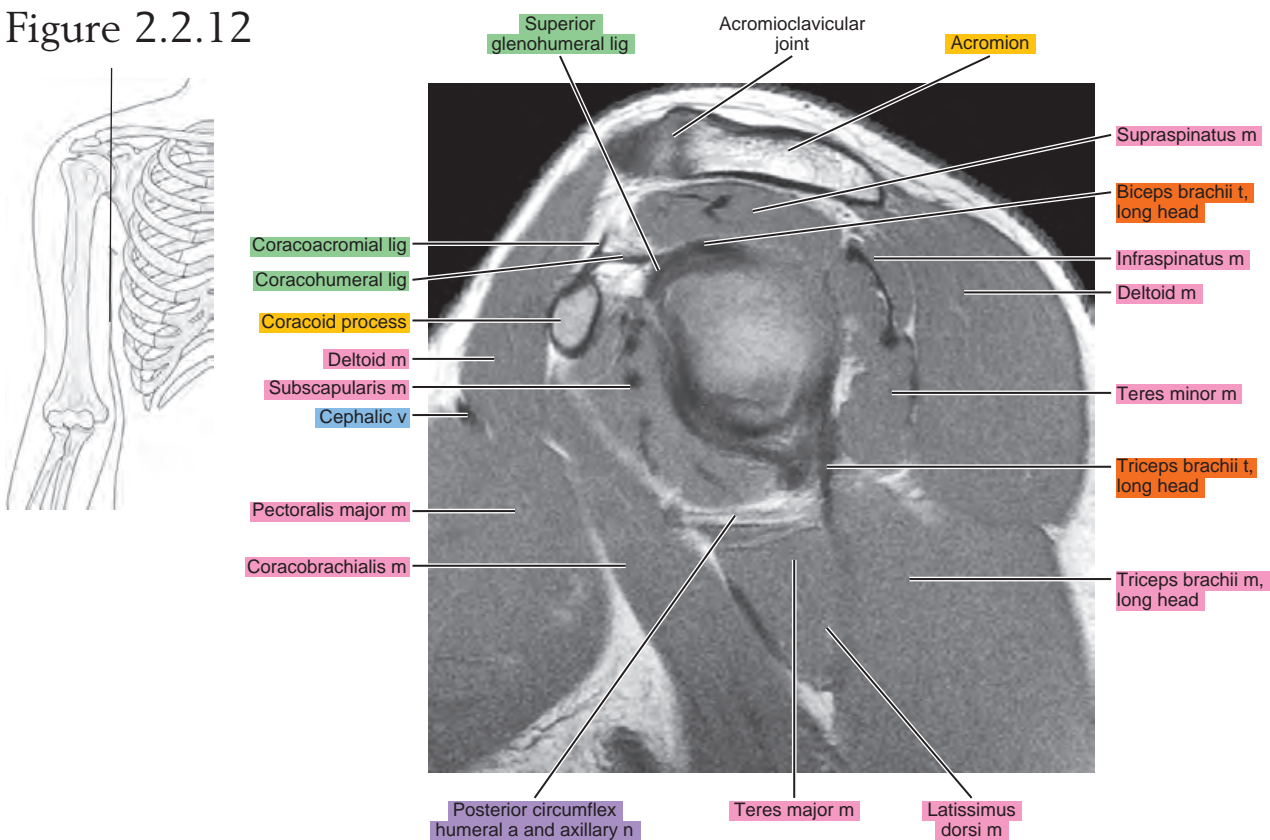


Figure 2.2.13

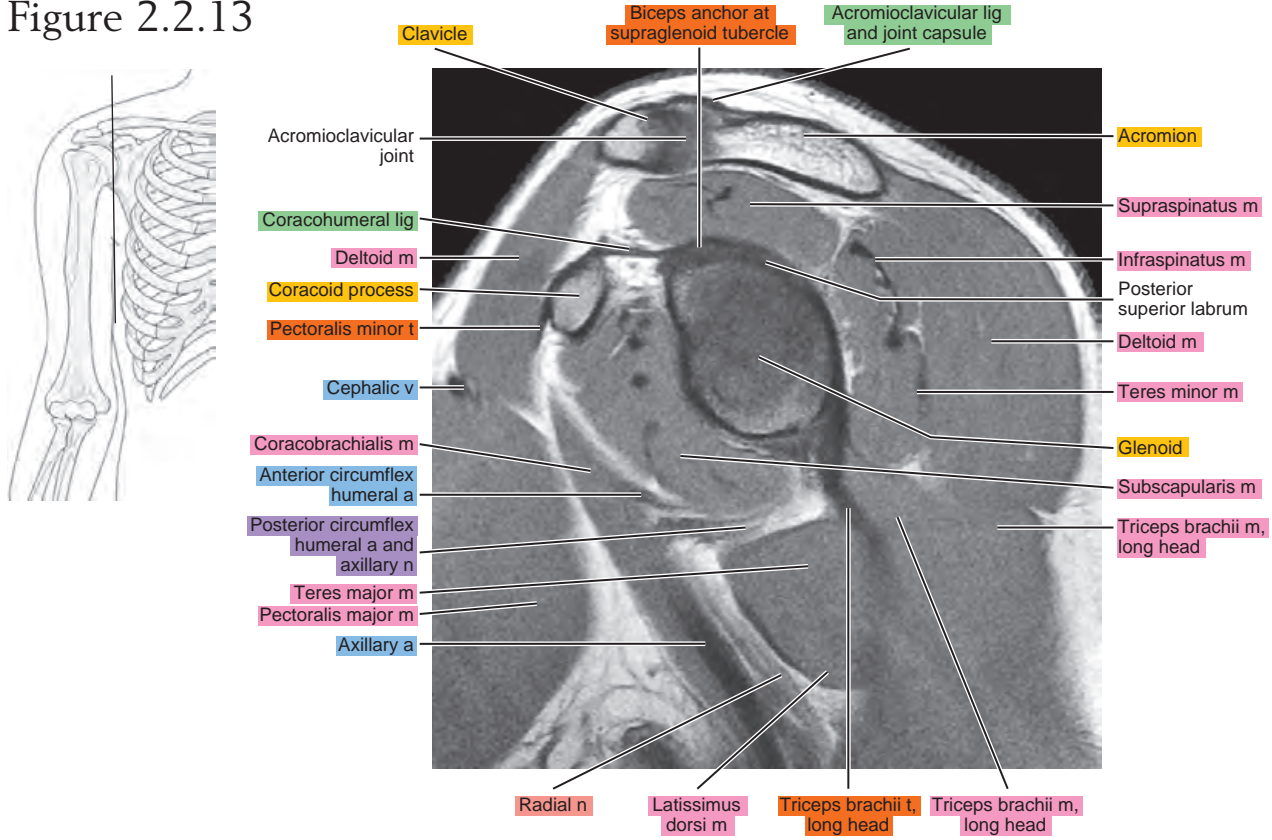


Figure 2.2.14

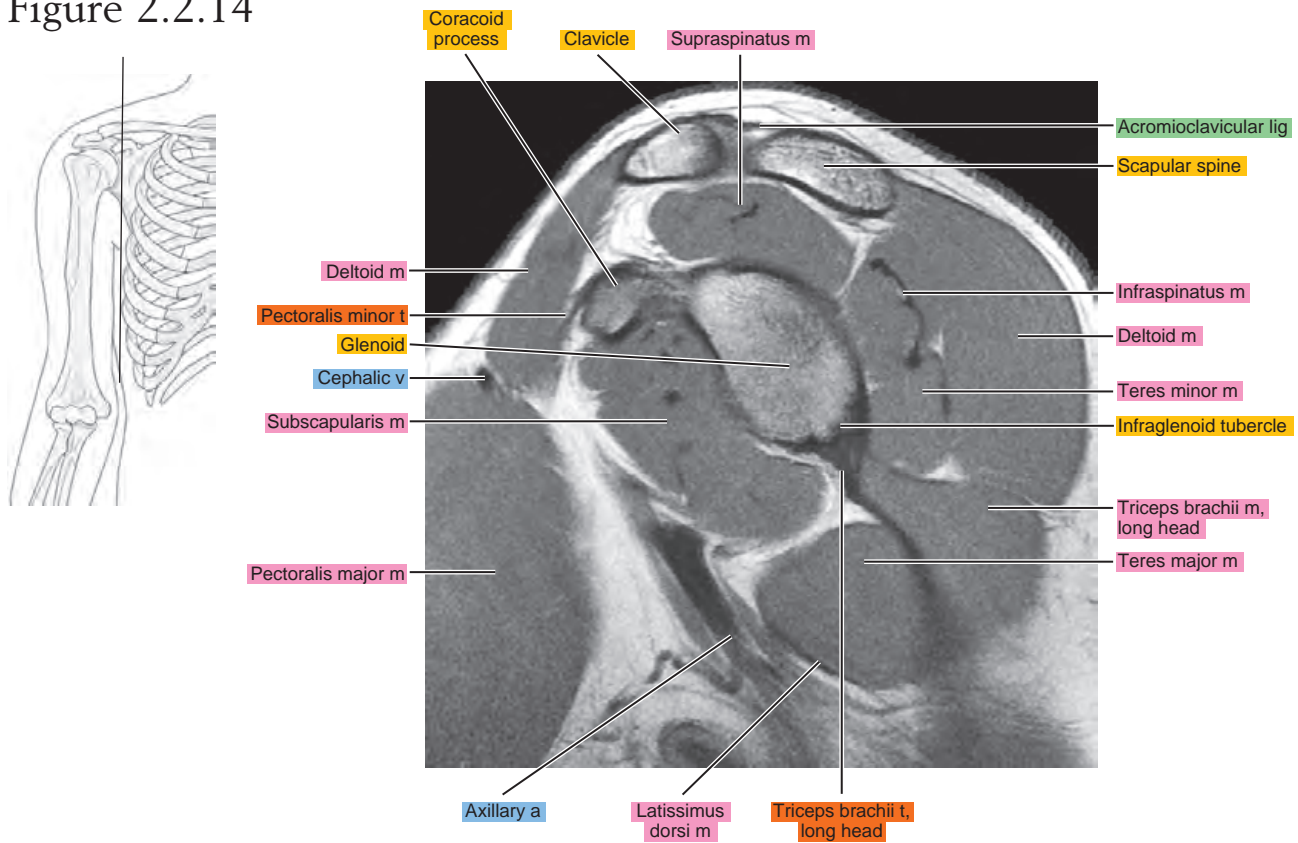


Figure 2.2.15

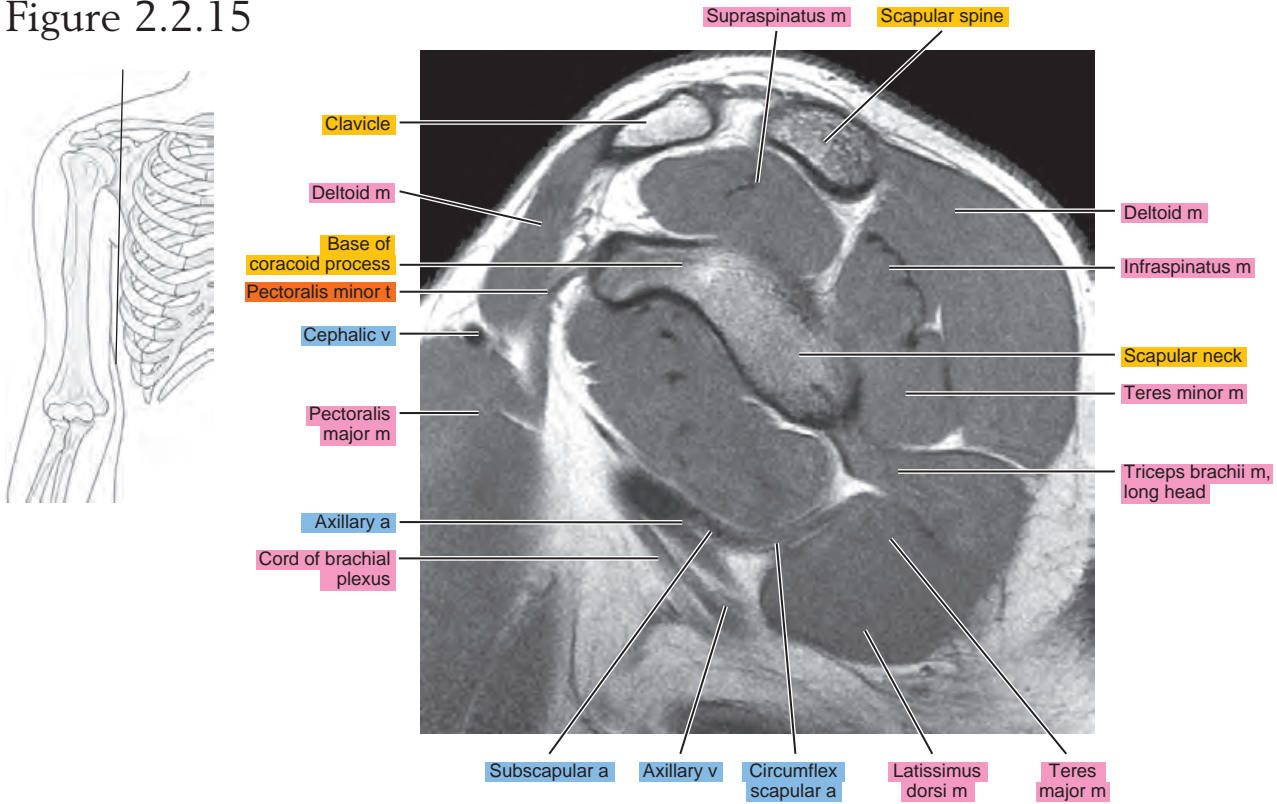


Figure 2.2.16

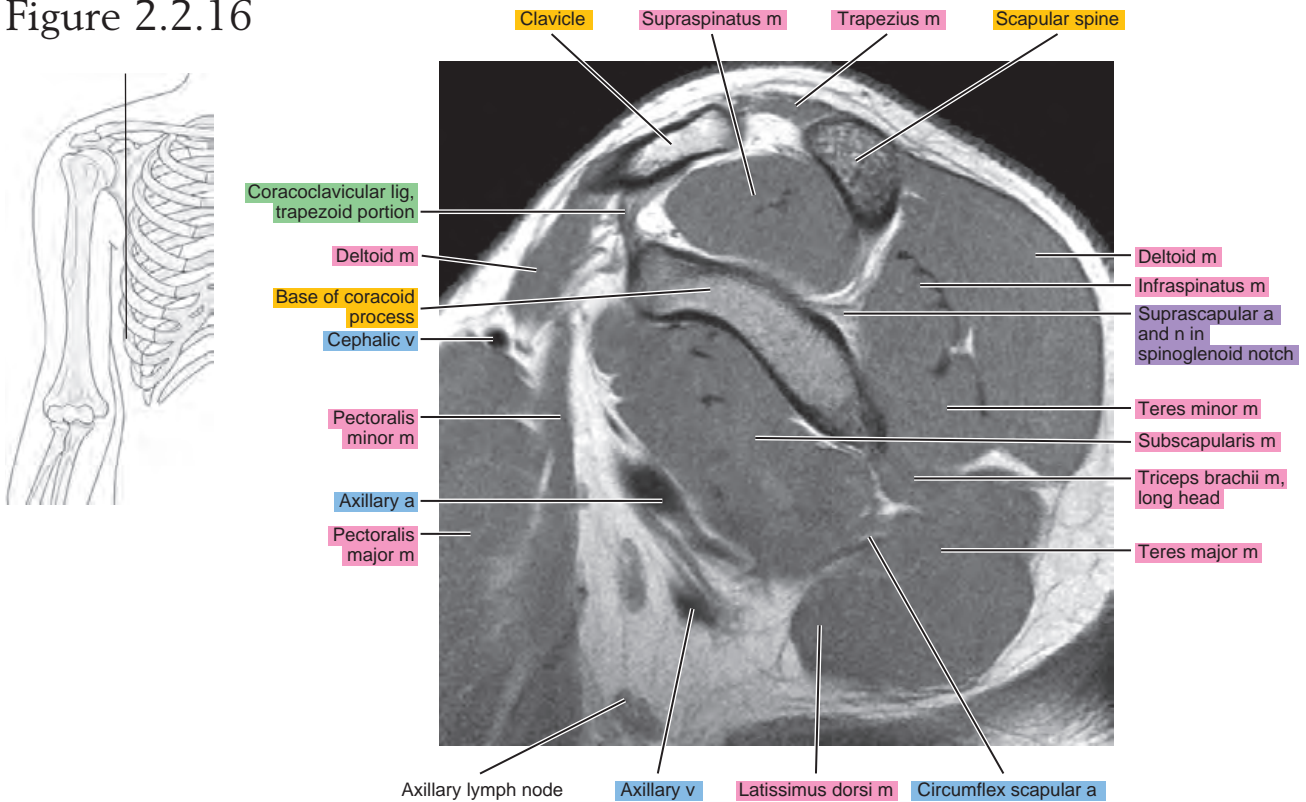


Figure 2.2.17

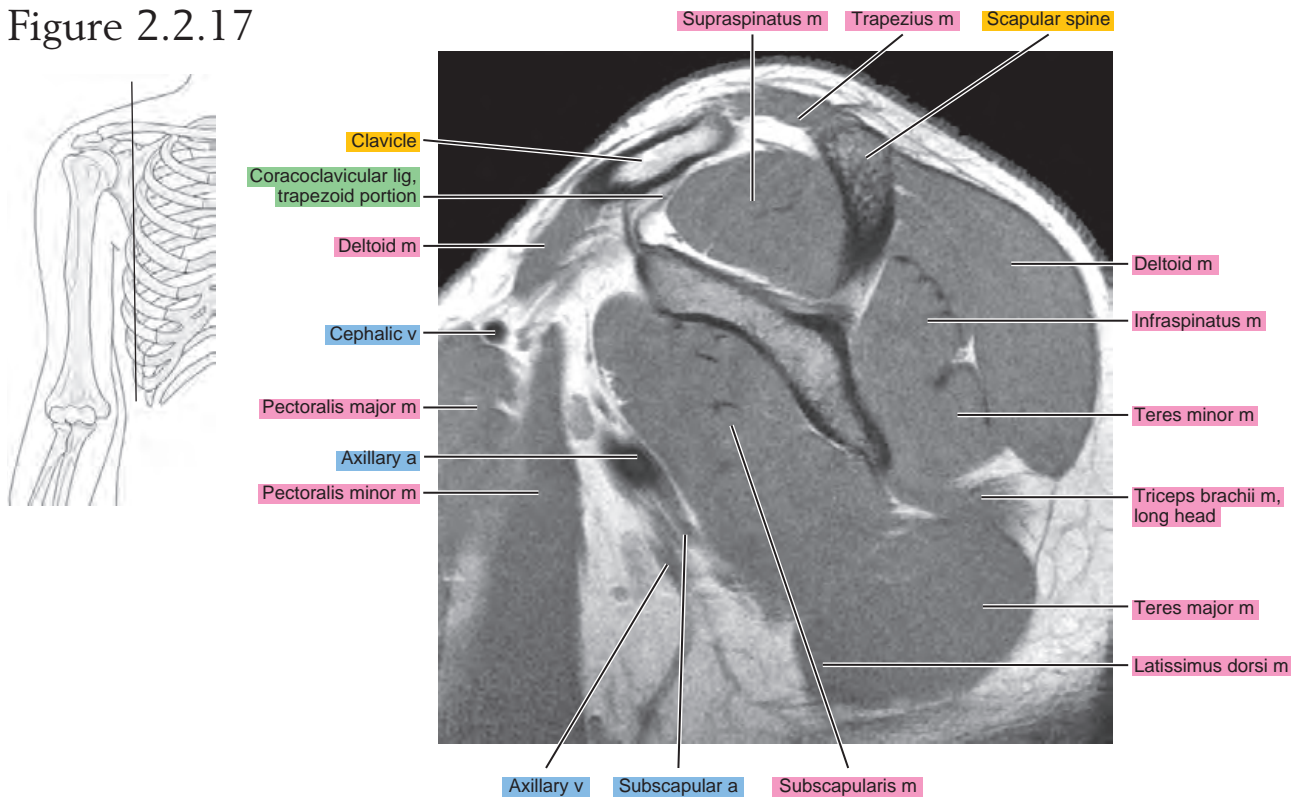


Figure 2.2.18

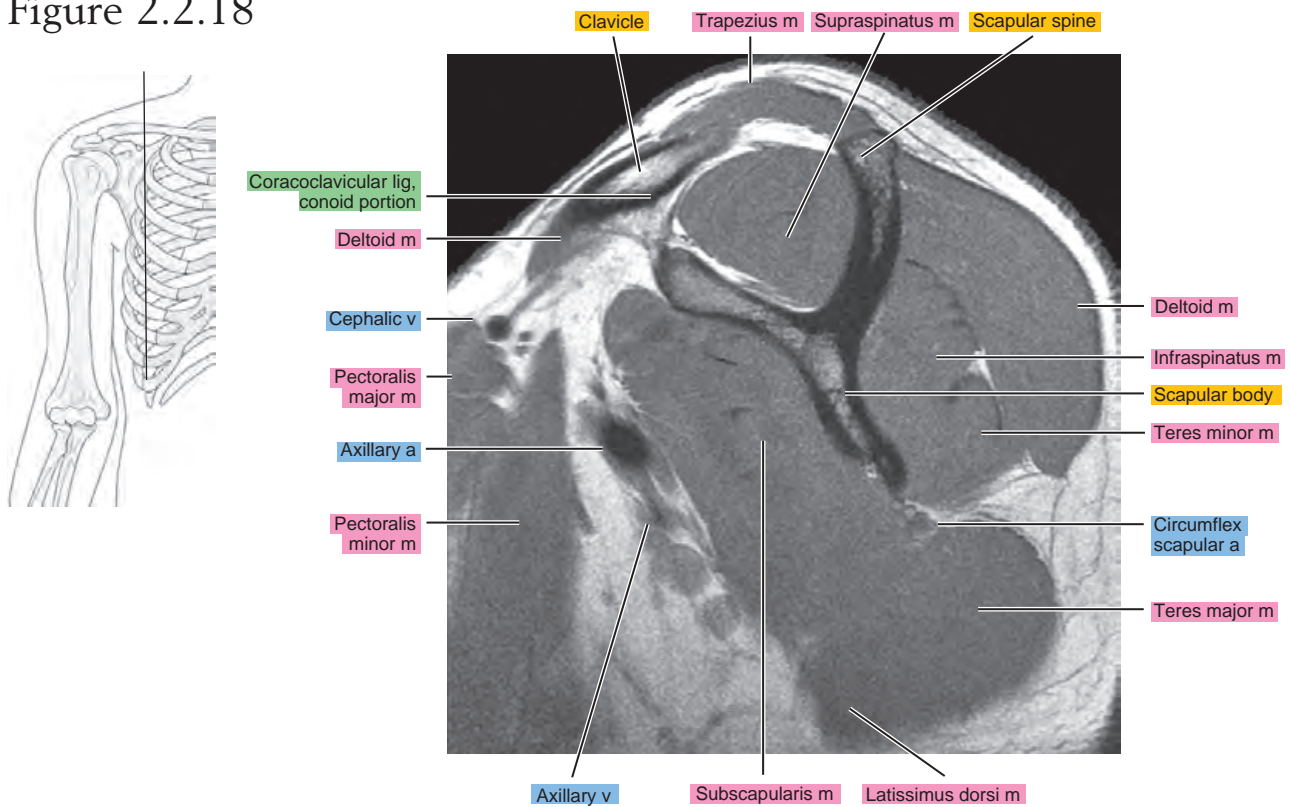


Figure 2.2.19

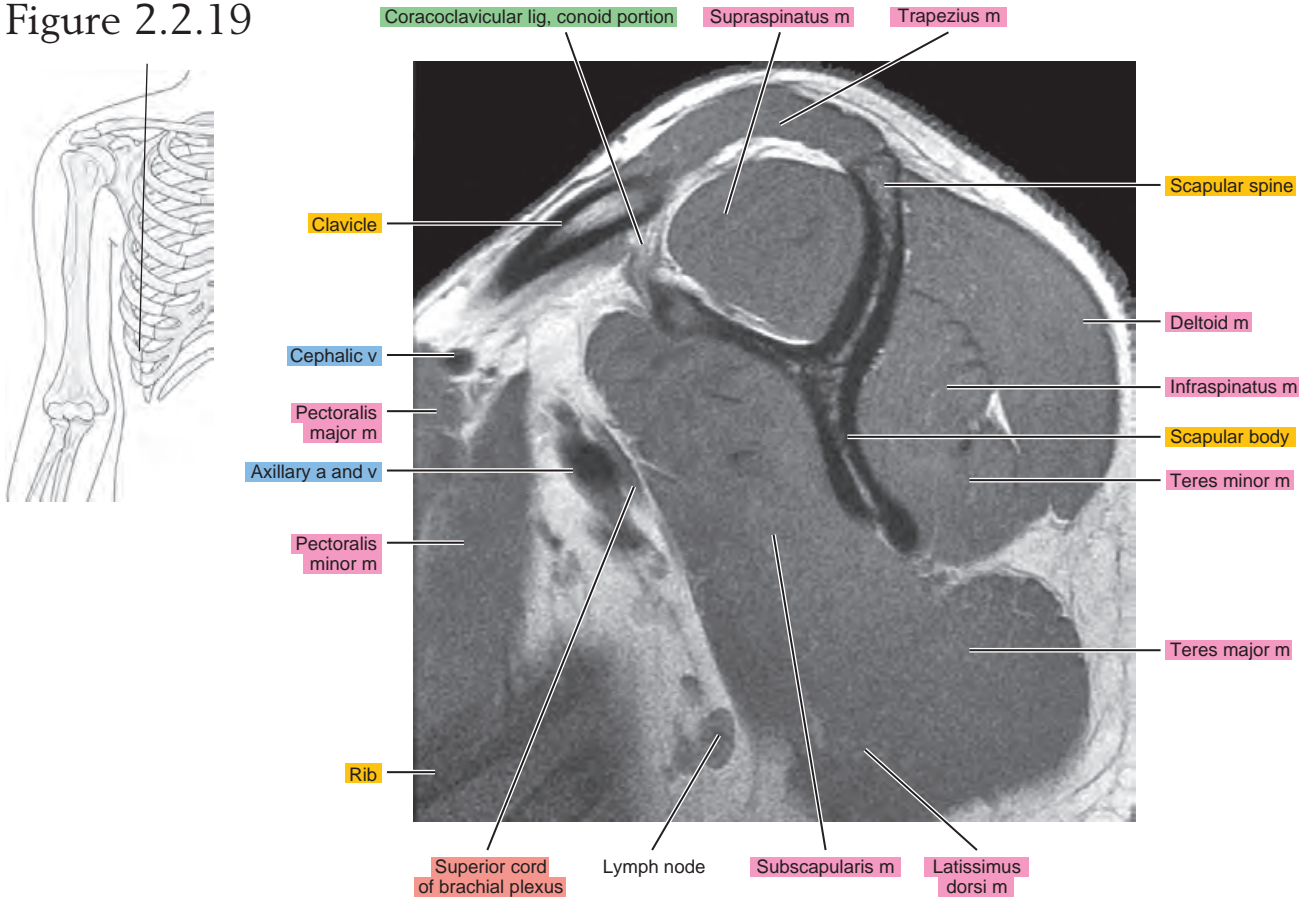
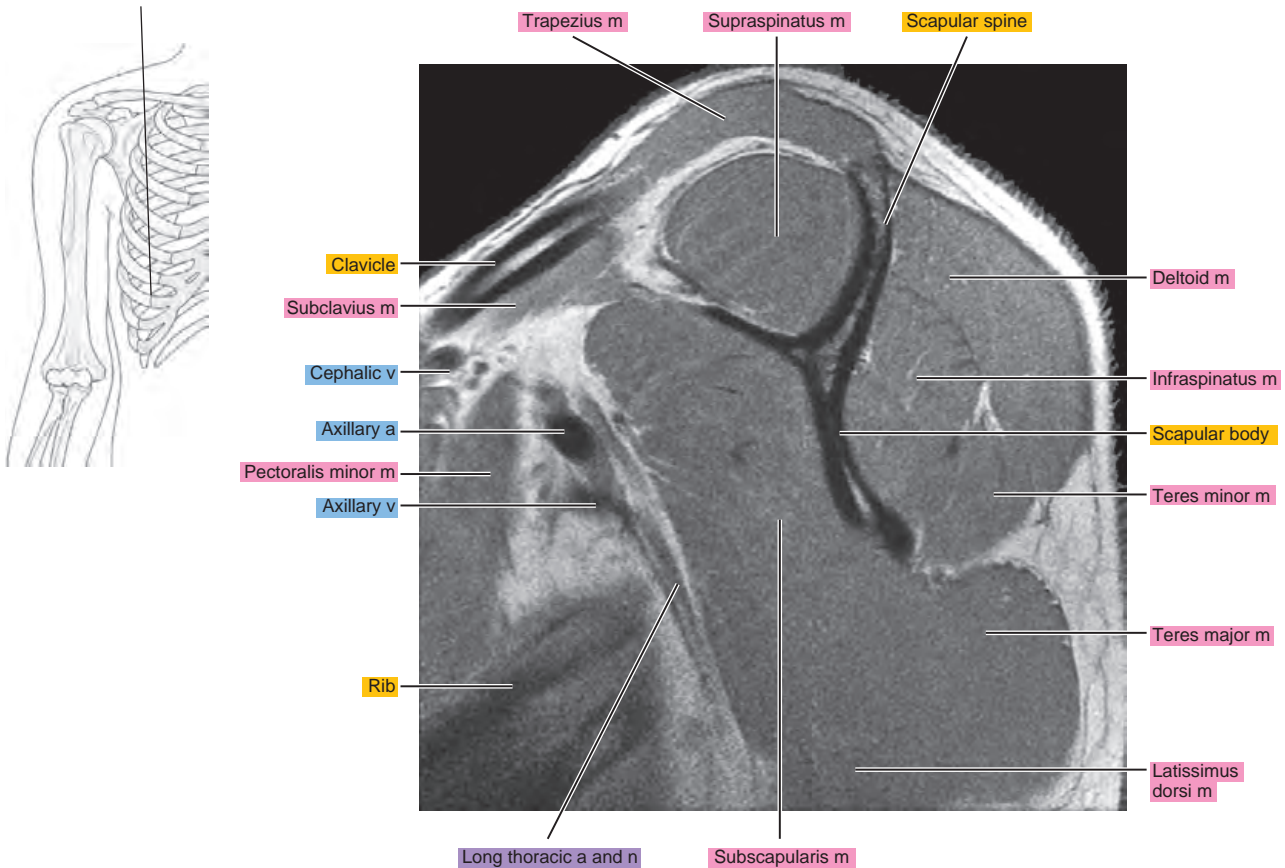


Figure 2.2.20



OBLIQUE CORONAL

Figure 2.3.1

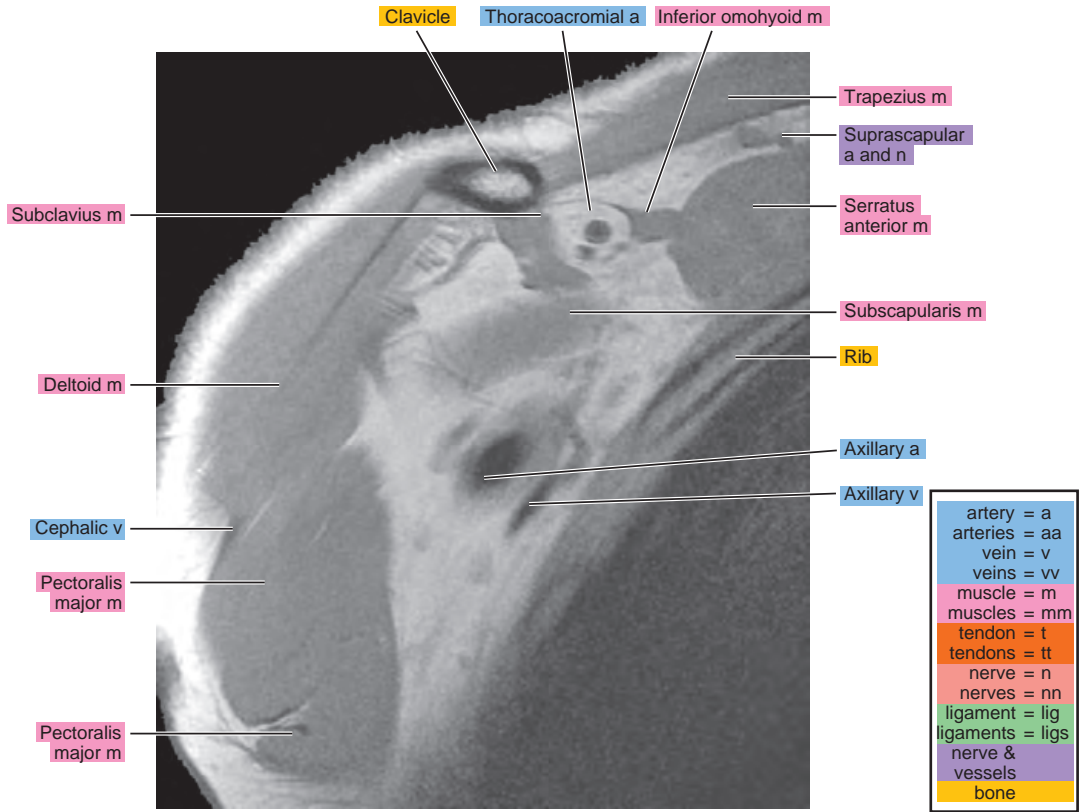
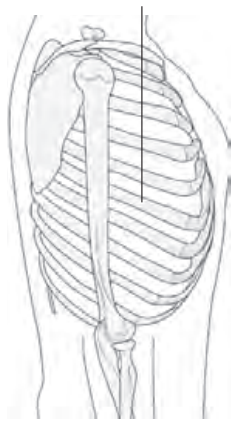


Figure 2.3.2

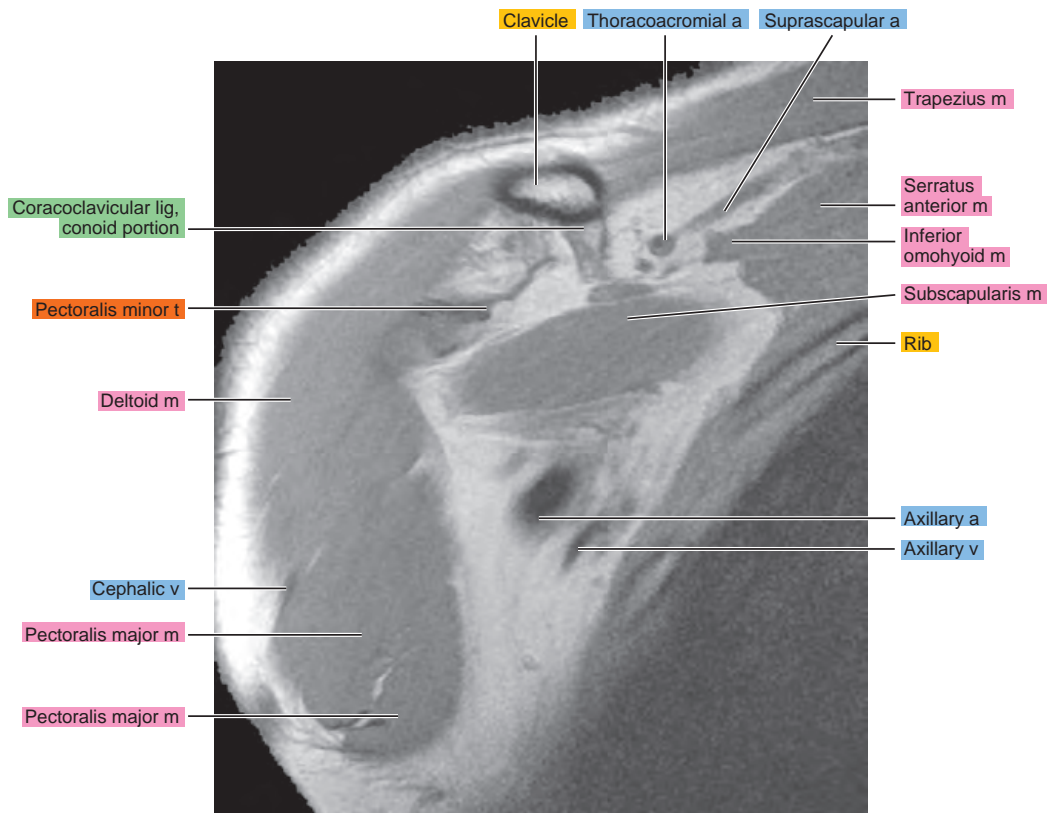
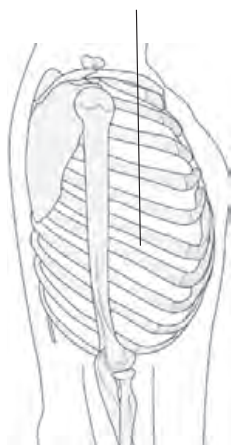


Figure 2.3.3

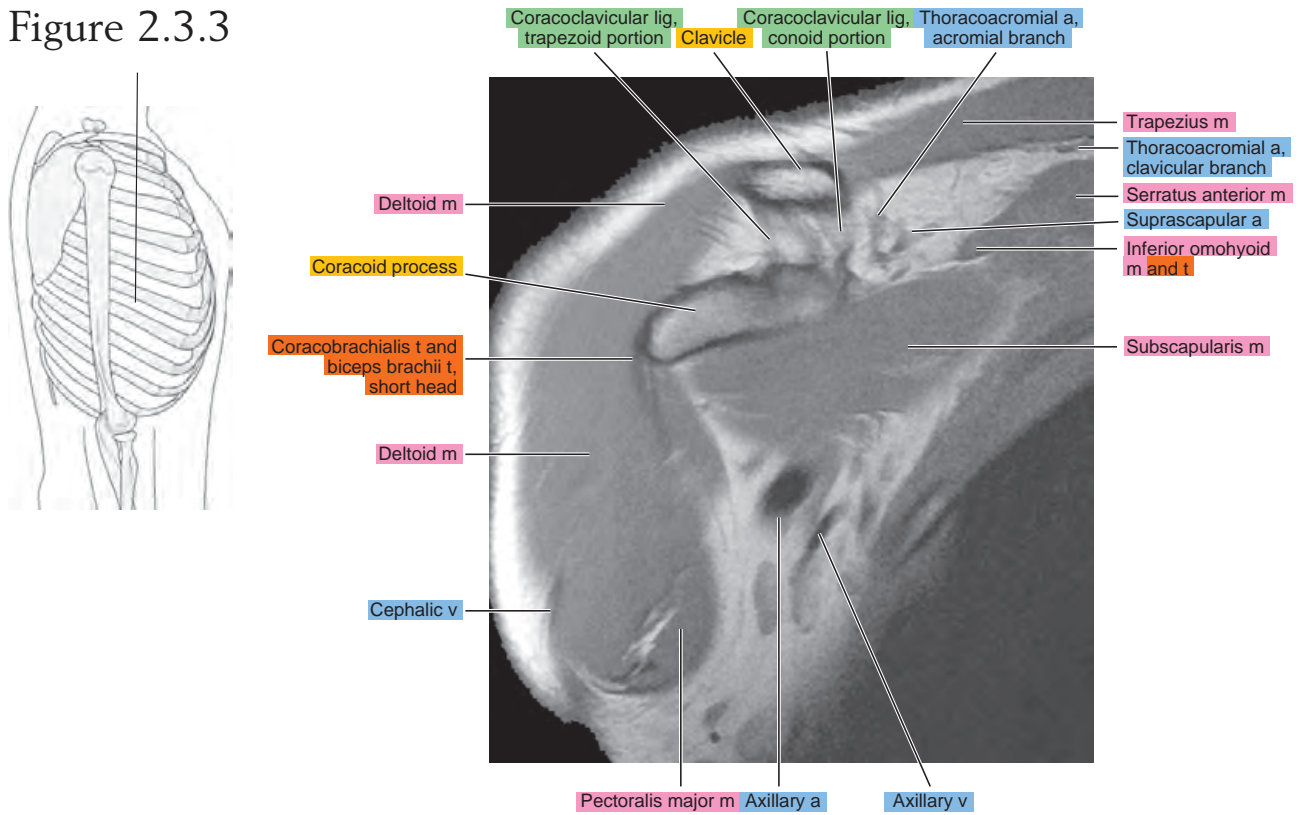


Figure 2.3.4

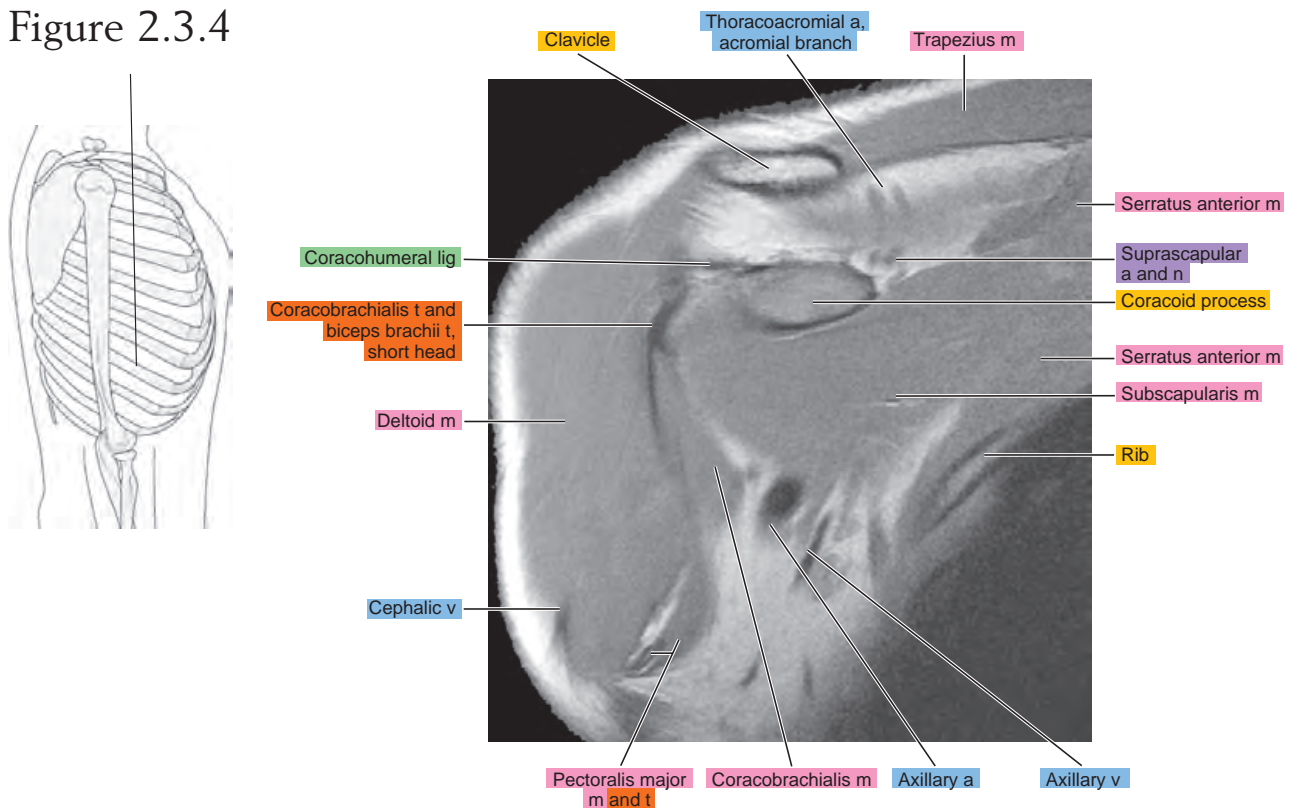


Figure 2.3.5

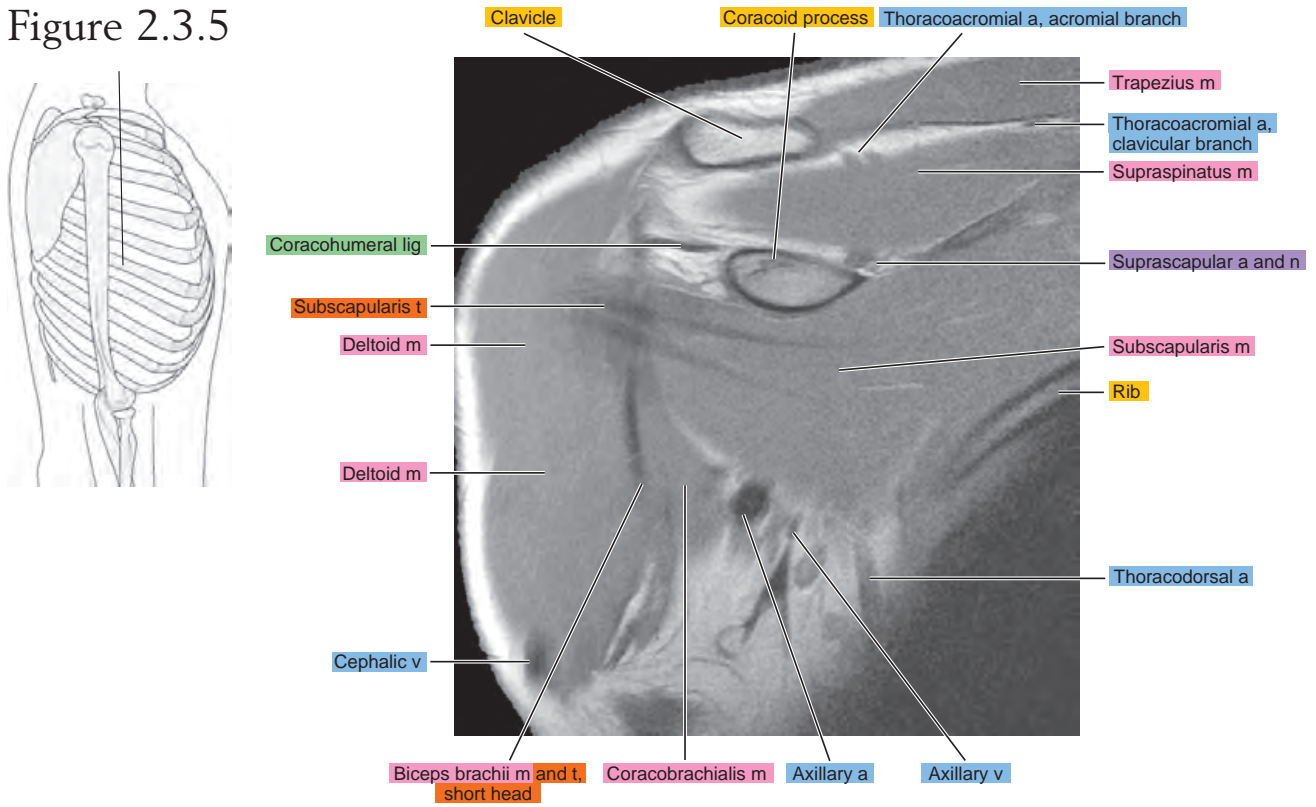


Figure 2.3.6

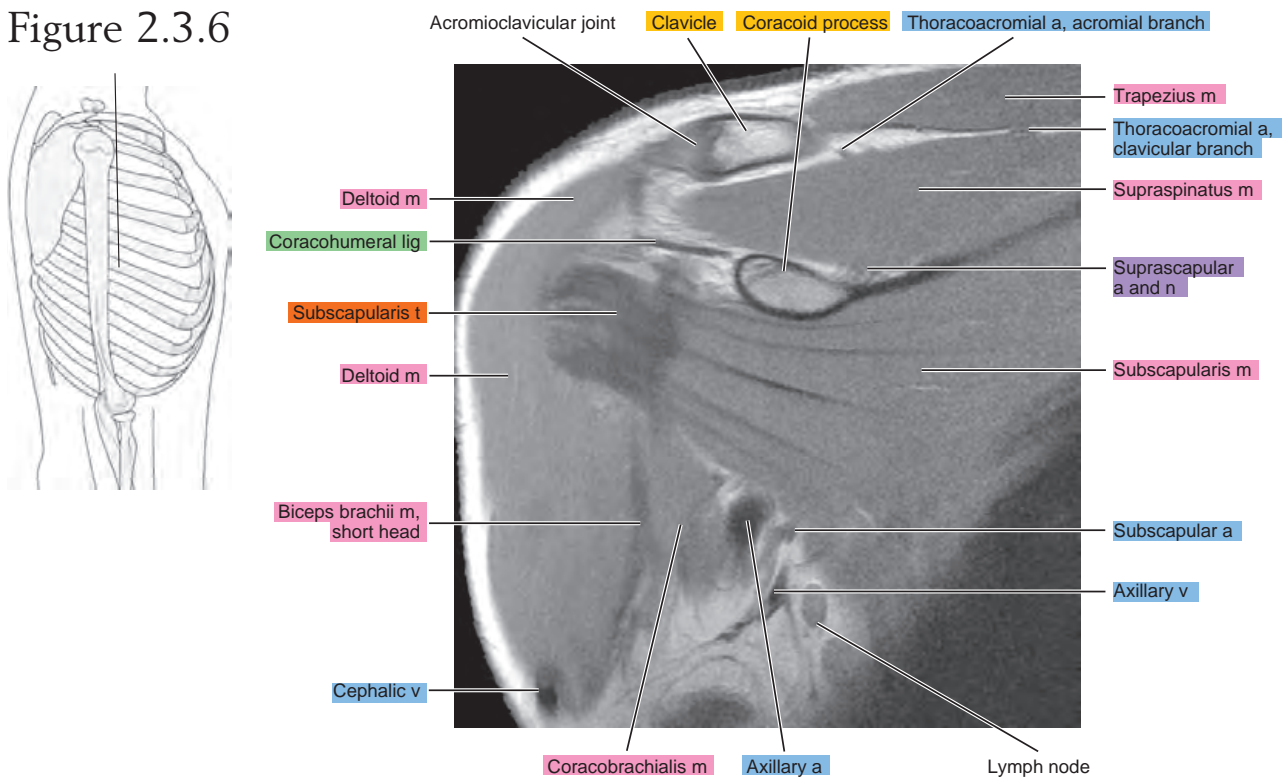


Figure 2.3.7

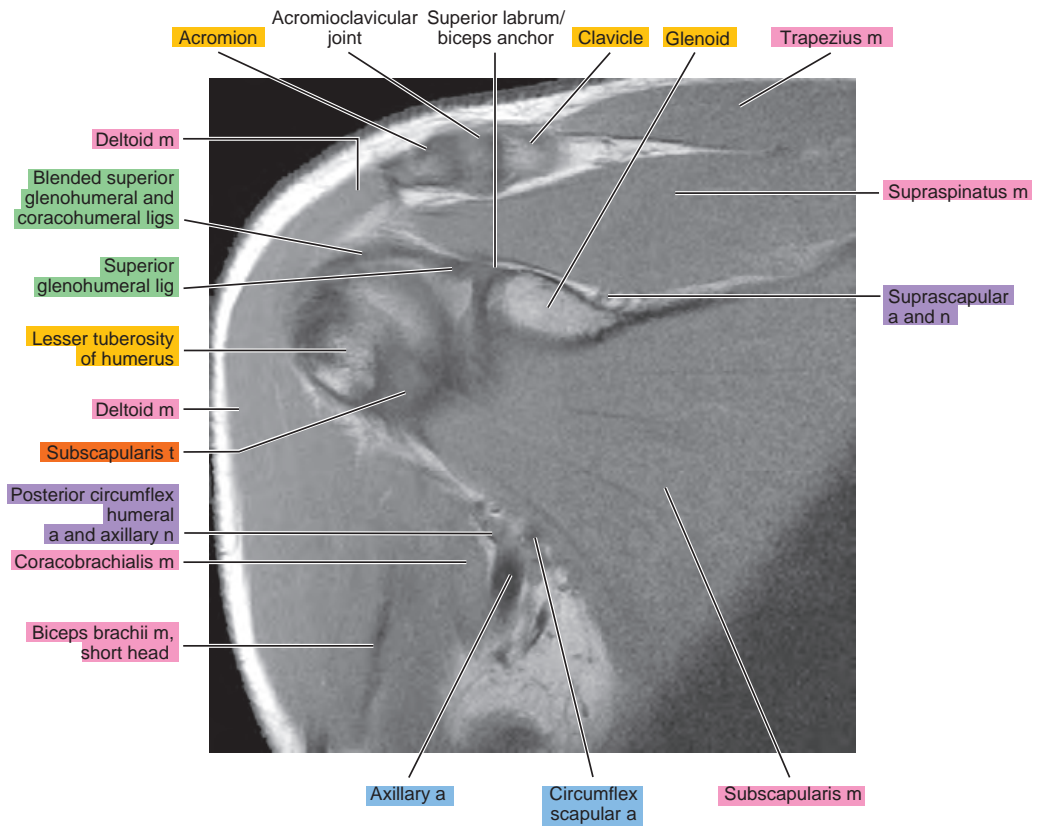
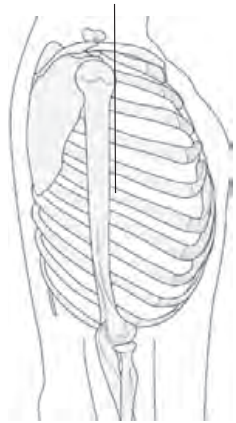


Figure 2.3.8

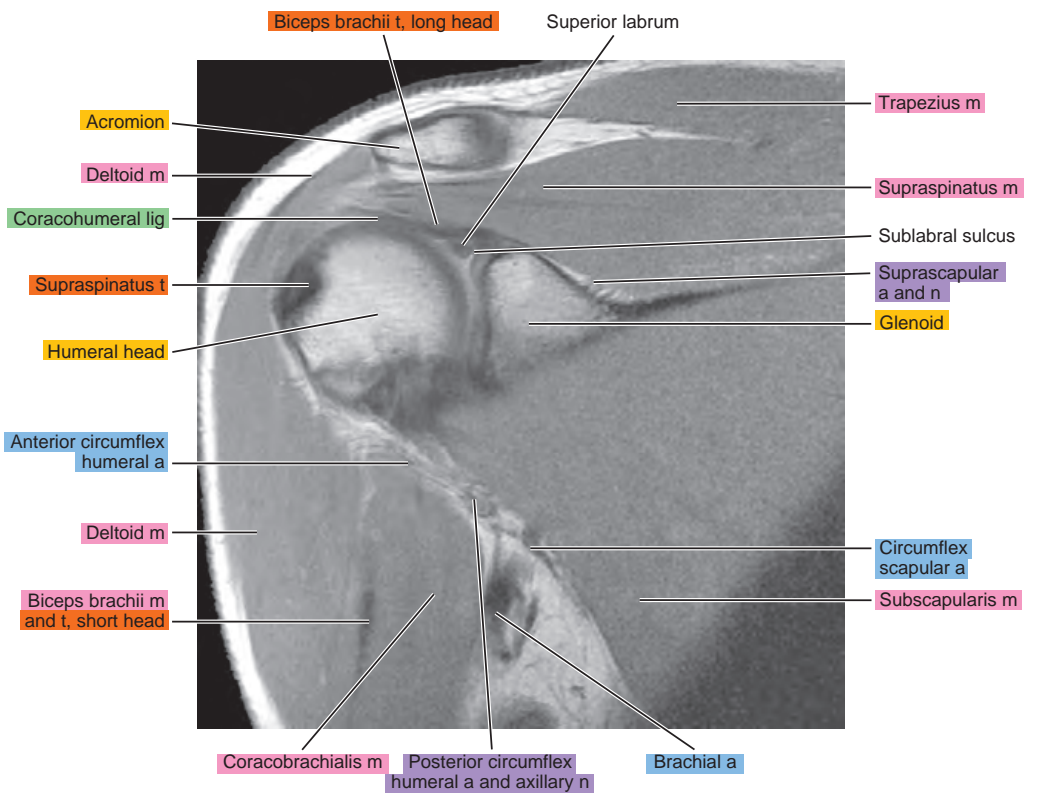
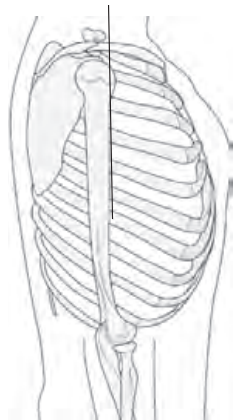


Figure 2.3.9

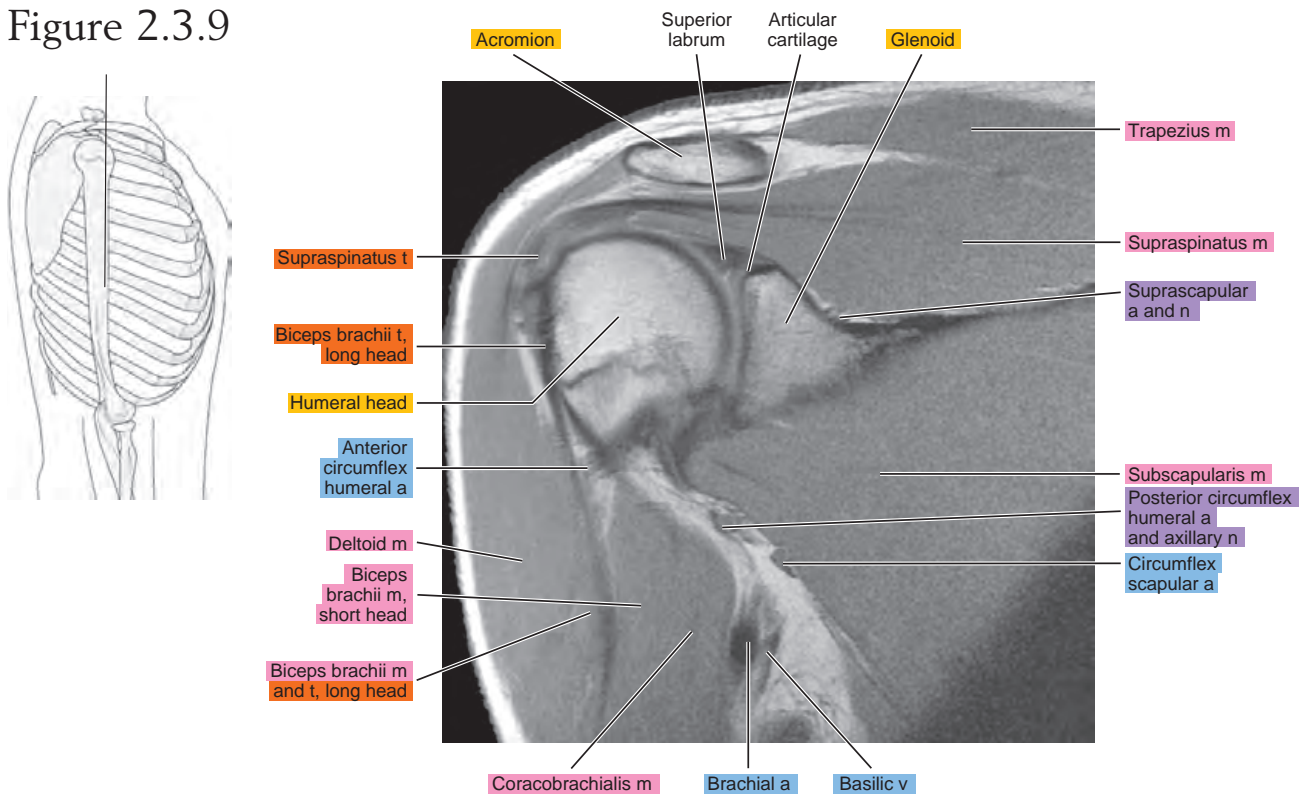


Figure 2.3.10

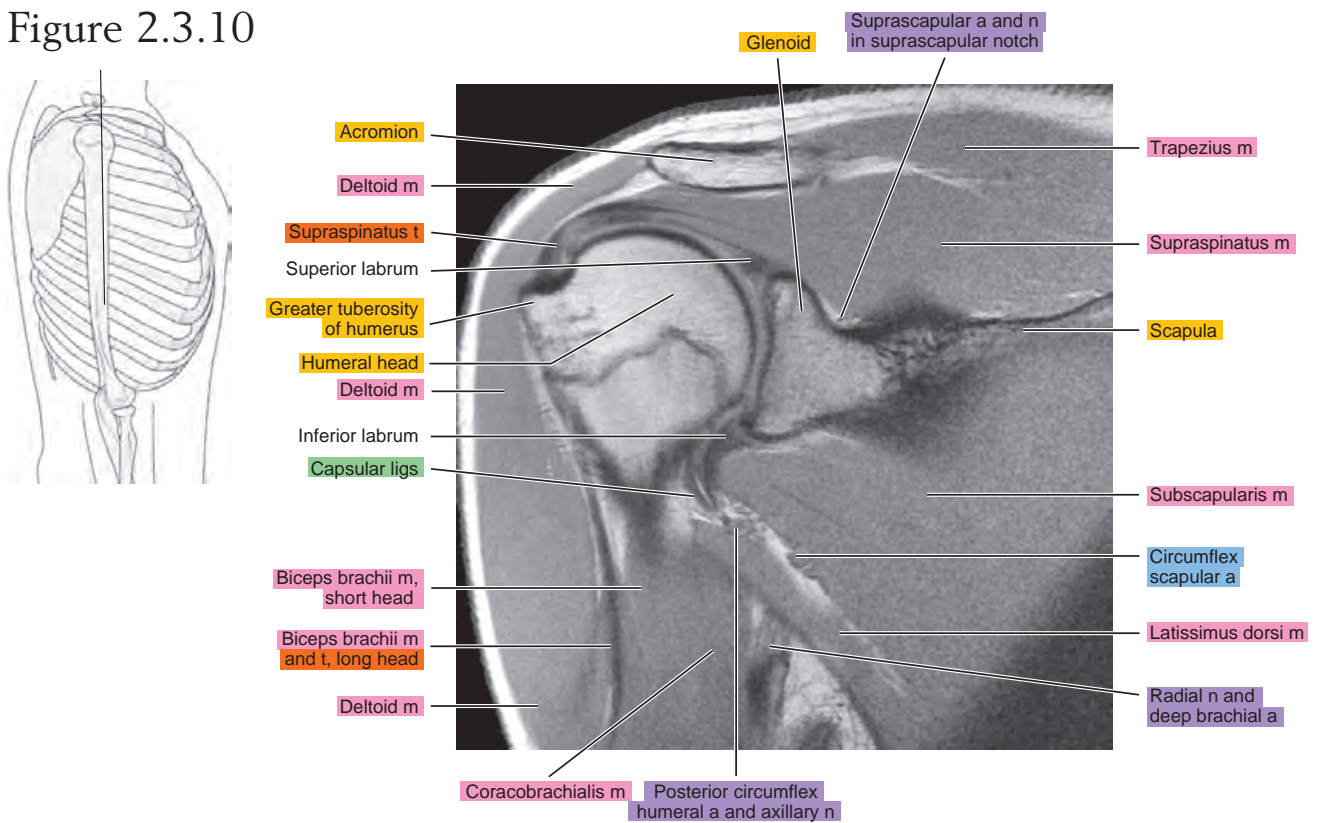


Figure 2.3.11

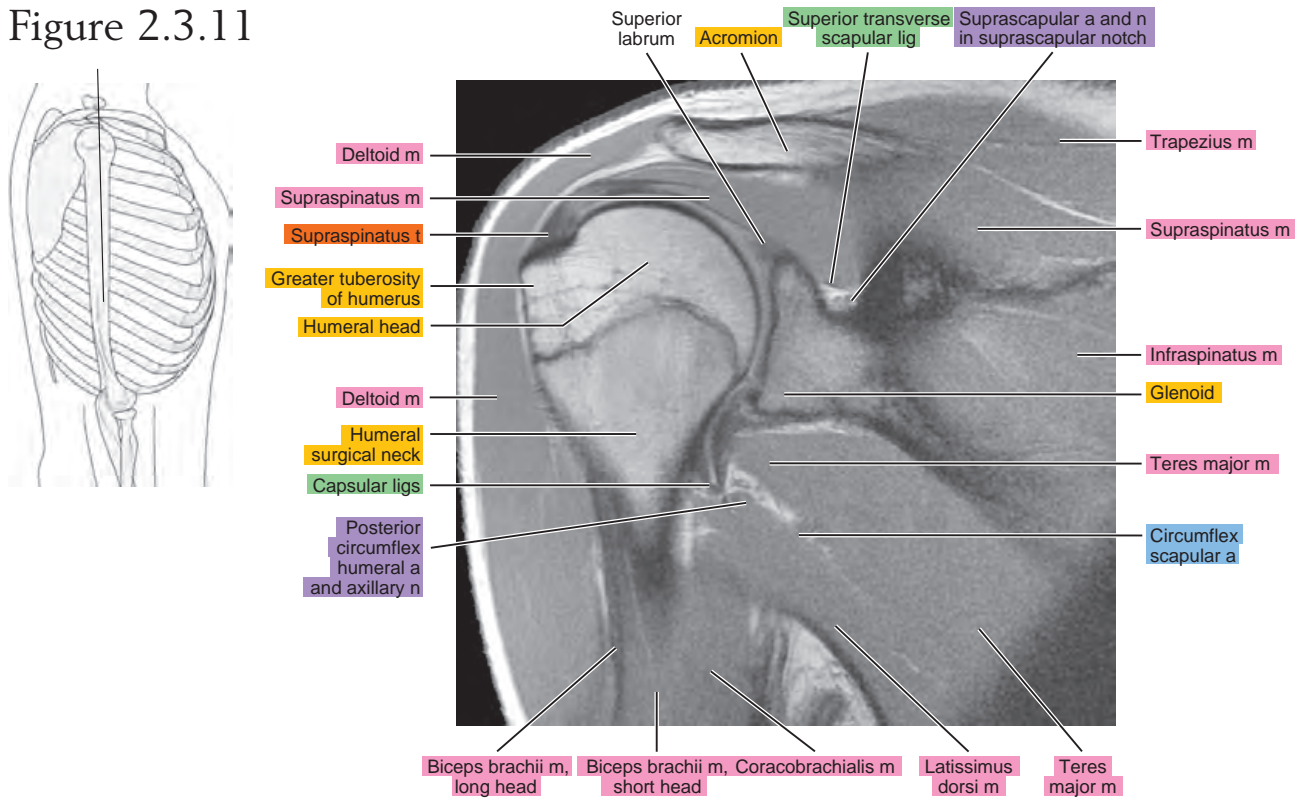


Figure 2.3.12

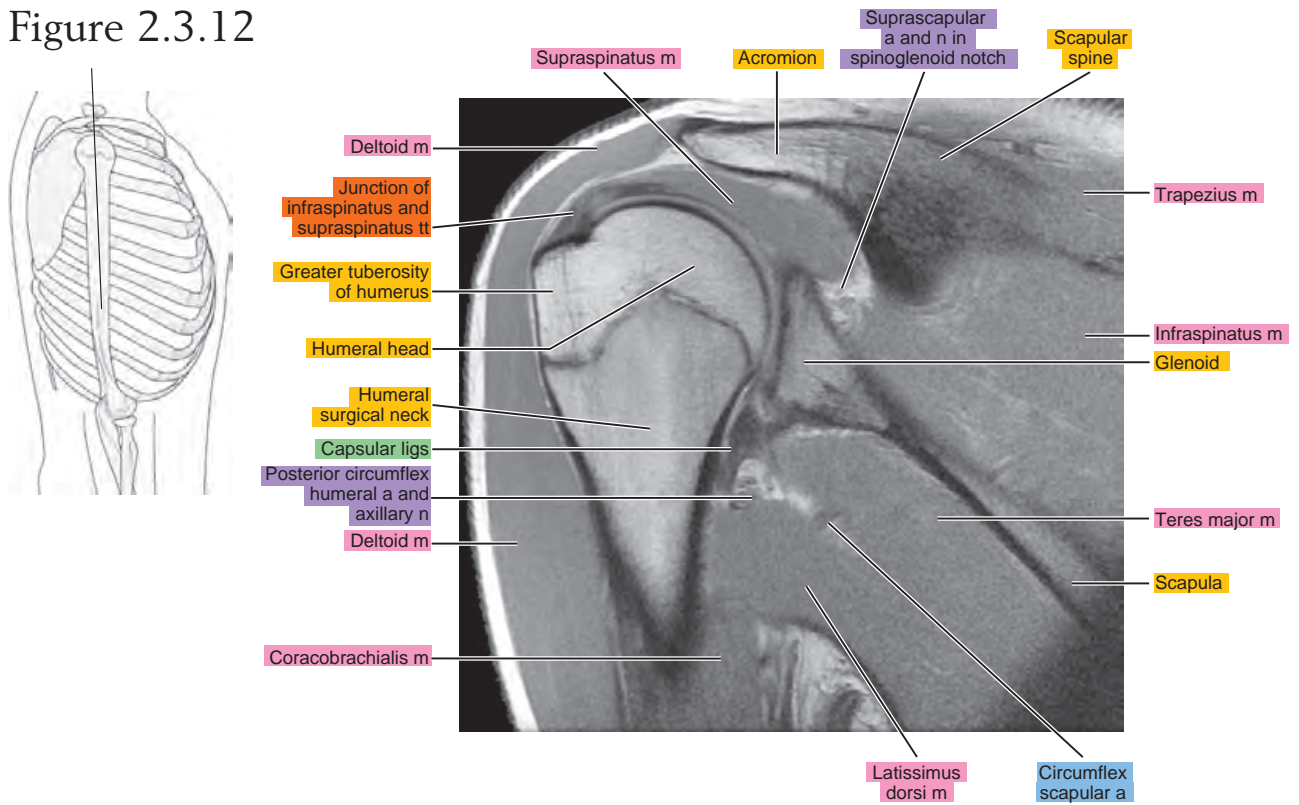


Figure 2.3.13

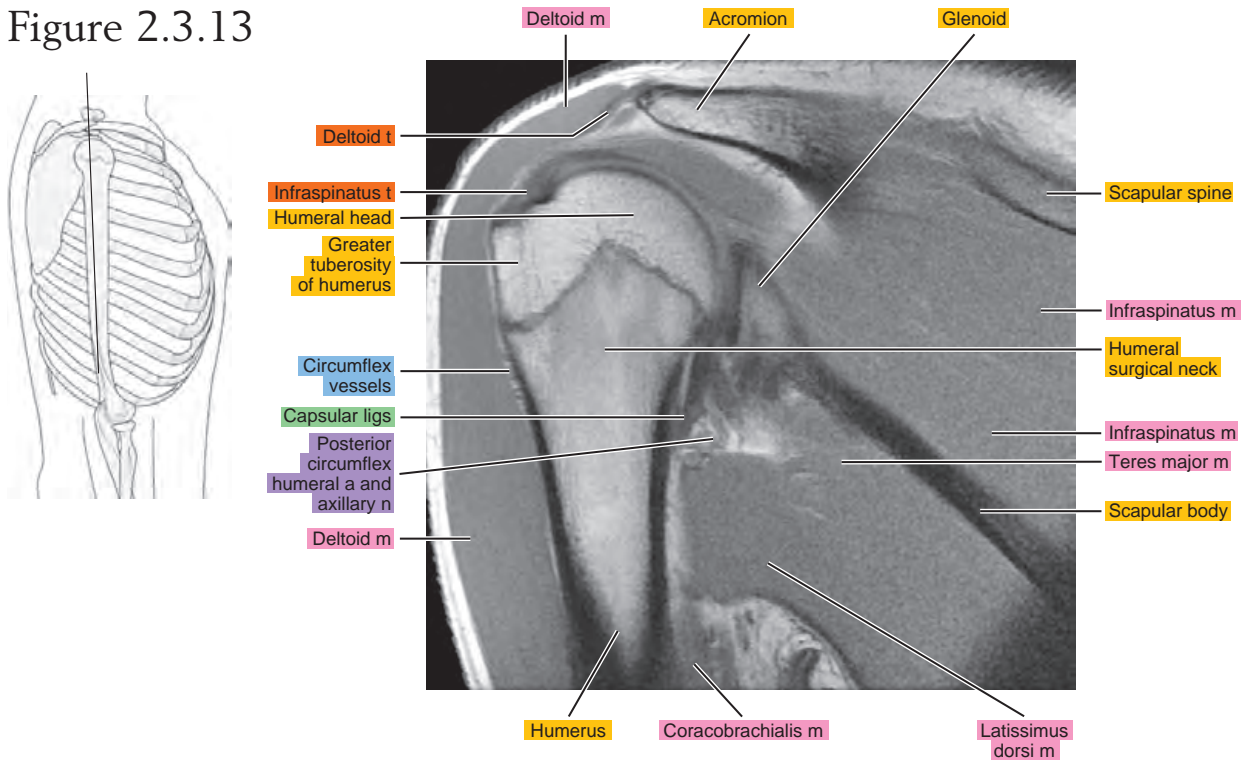


Figure 2.3.14

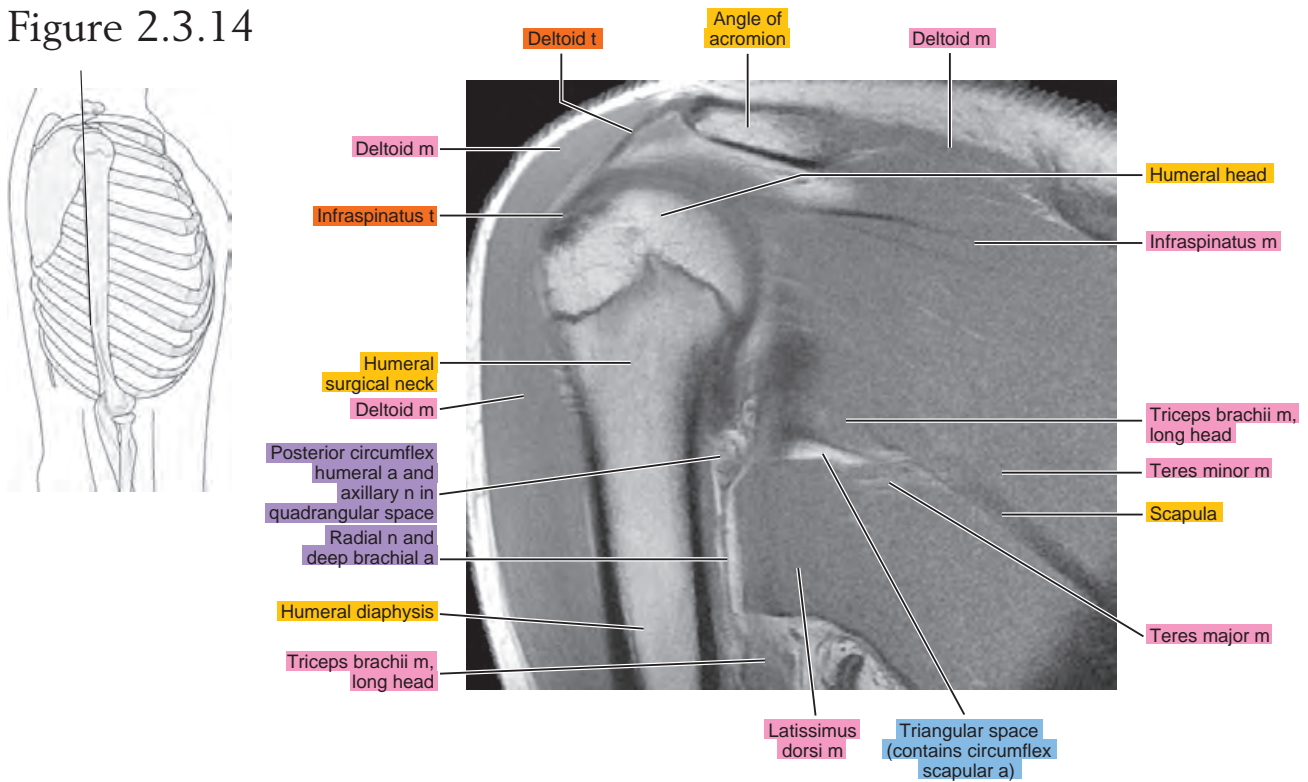


Figure 2.3.15

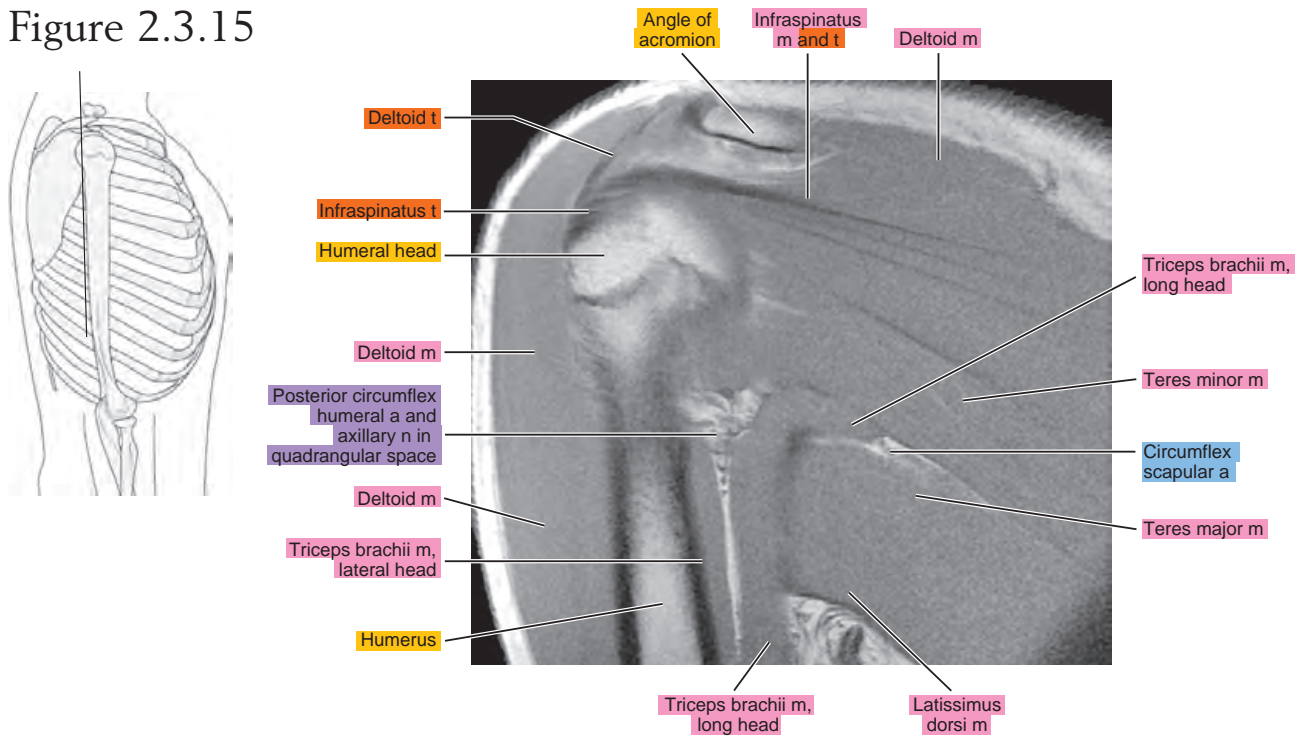


Figure 2.3.16

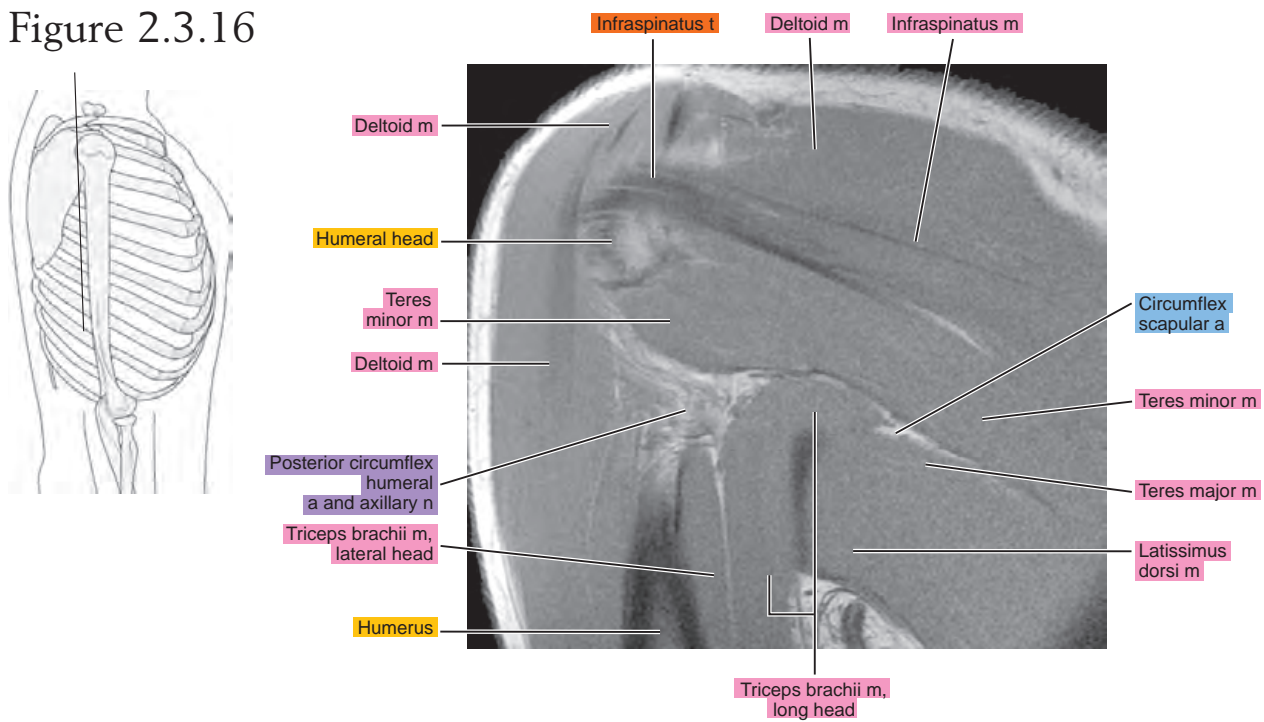


Figure 2.3.17

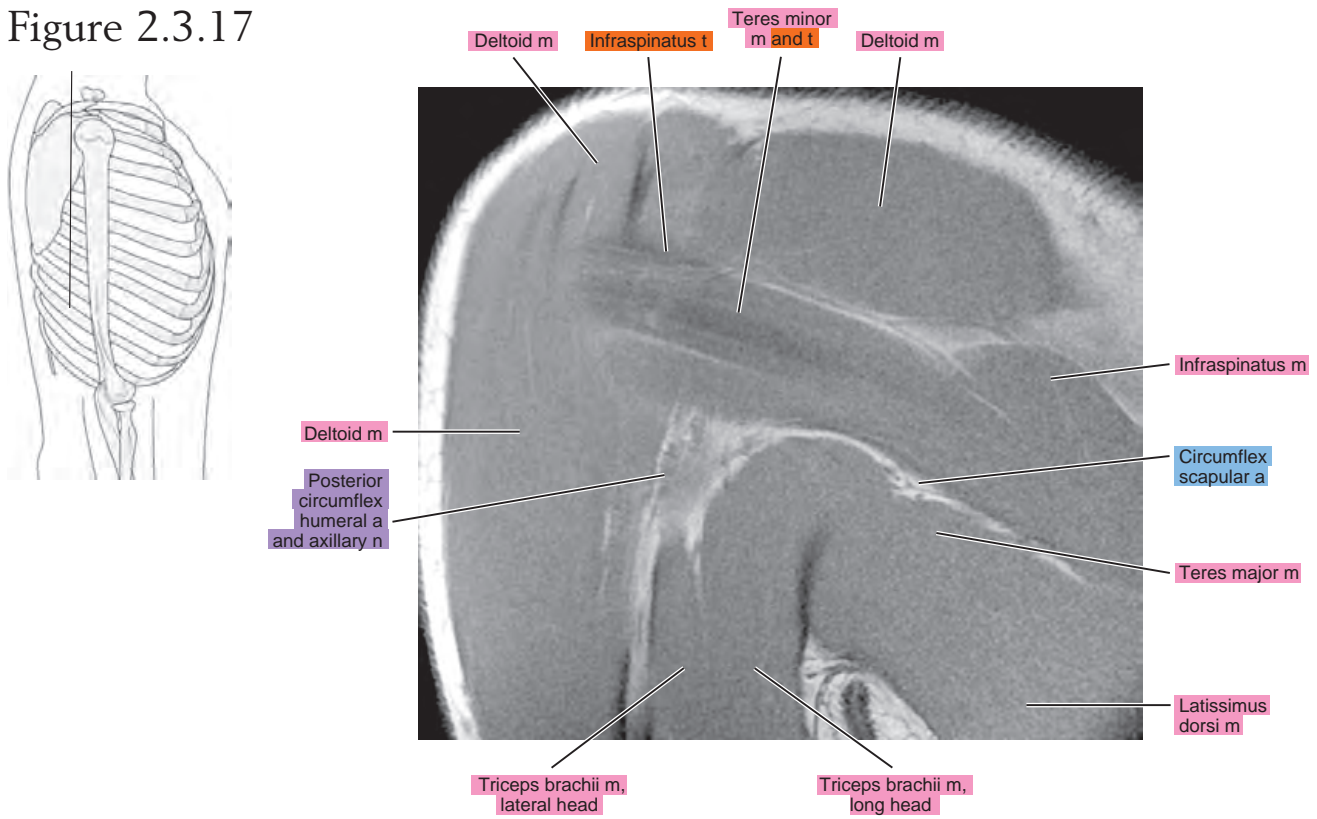


Figure 2.3.18

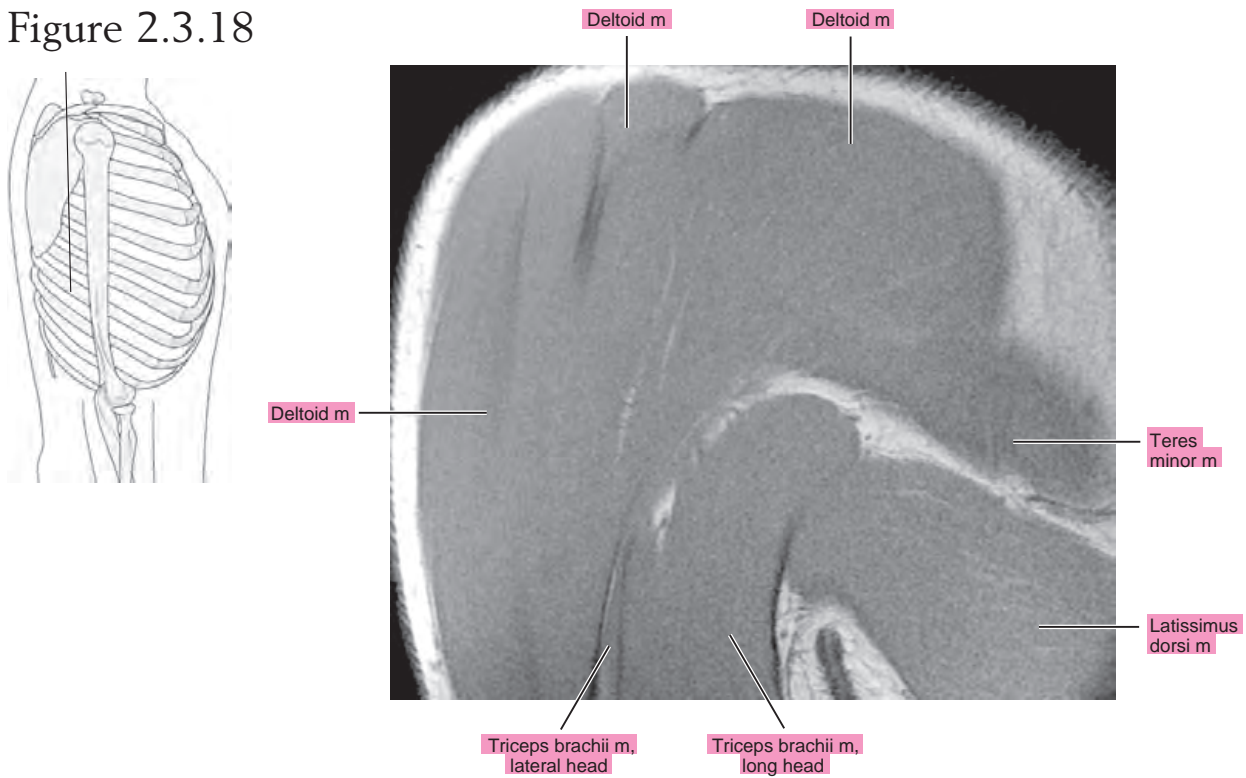


Figure 2.3.19

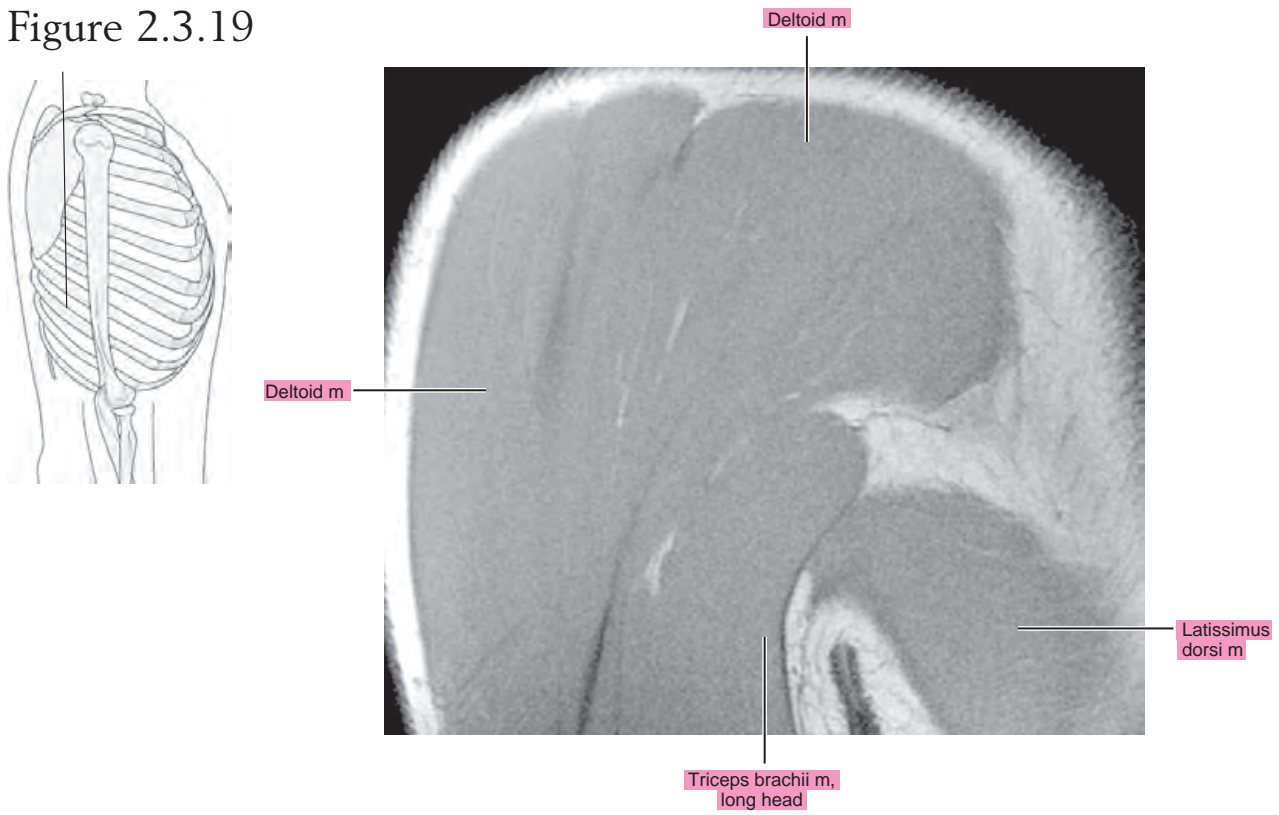
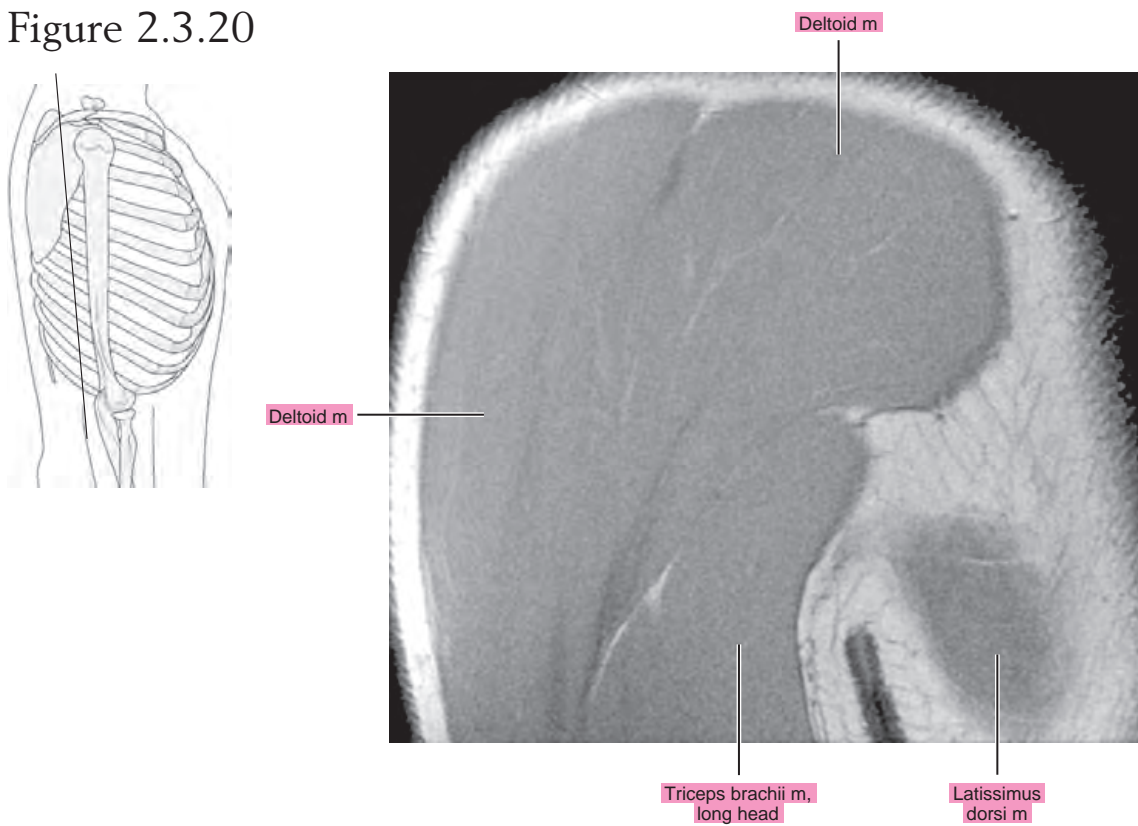


Figure 2.3.20

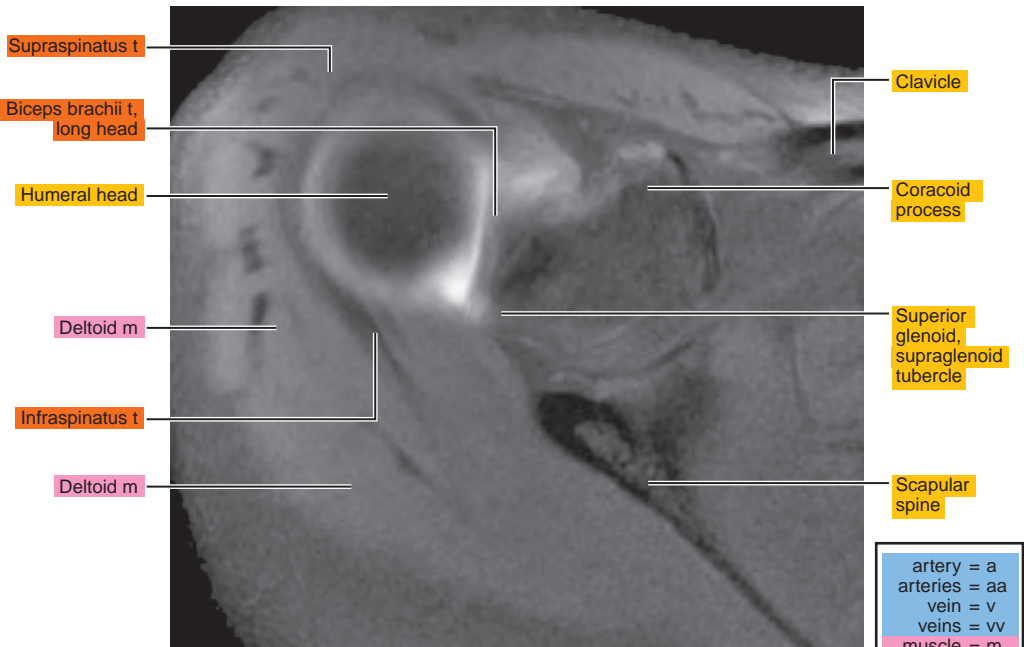
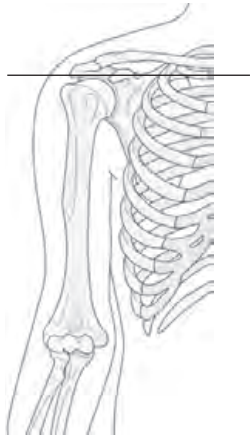

Chapter
3

**MR Arthrography
of the Shoulder**

AXIAL

Figure 3.1.1



artery = a
arteries = aa
vein = v
veins = vv
muscle = m
muscles = mm
tendon = t
tendons = tt
nerve = n
nerves = nn
ligament = lig
ligaments = lig
nerve & vessels
bone

Figure 3.1.2

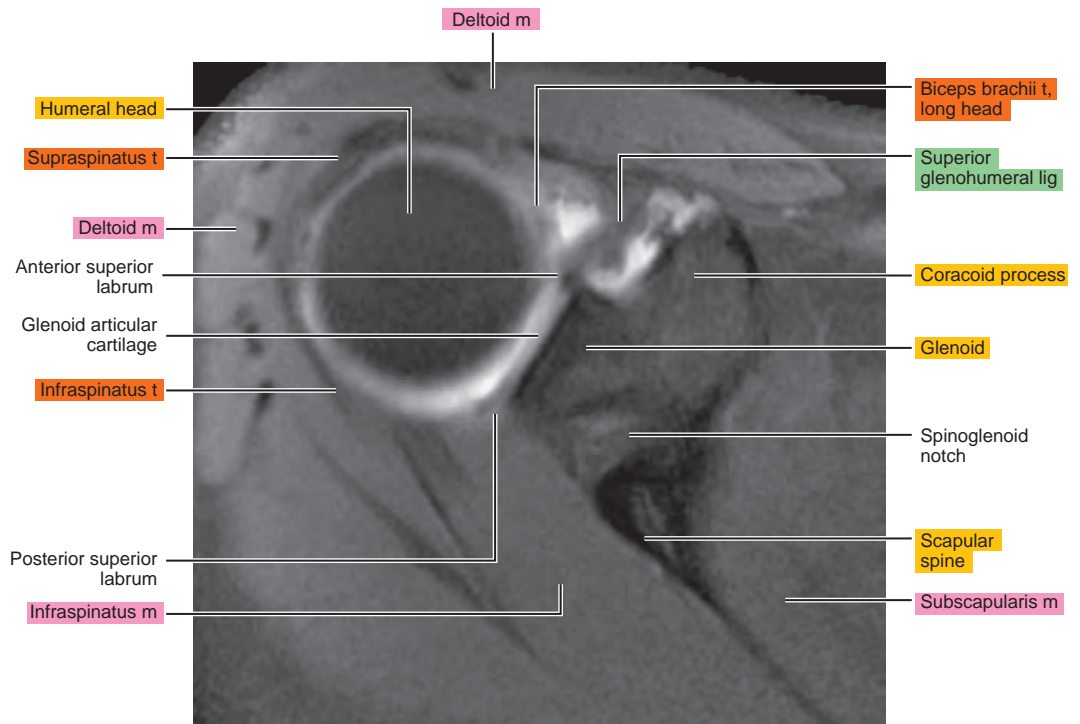
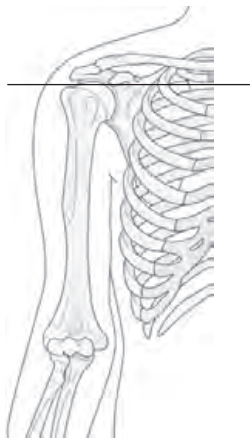

Figure 3.1.3

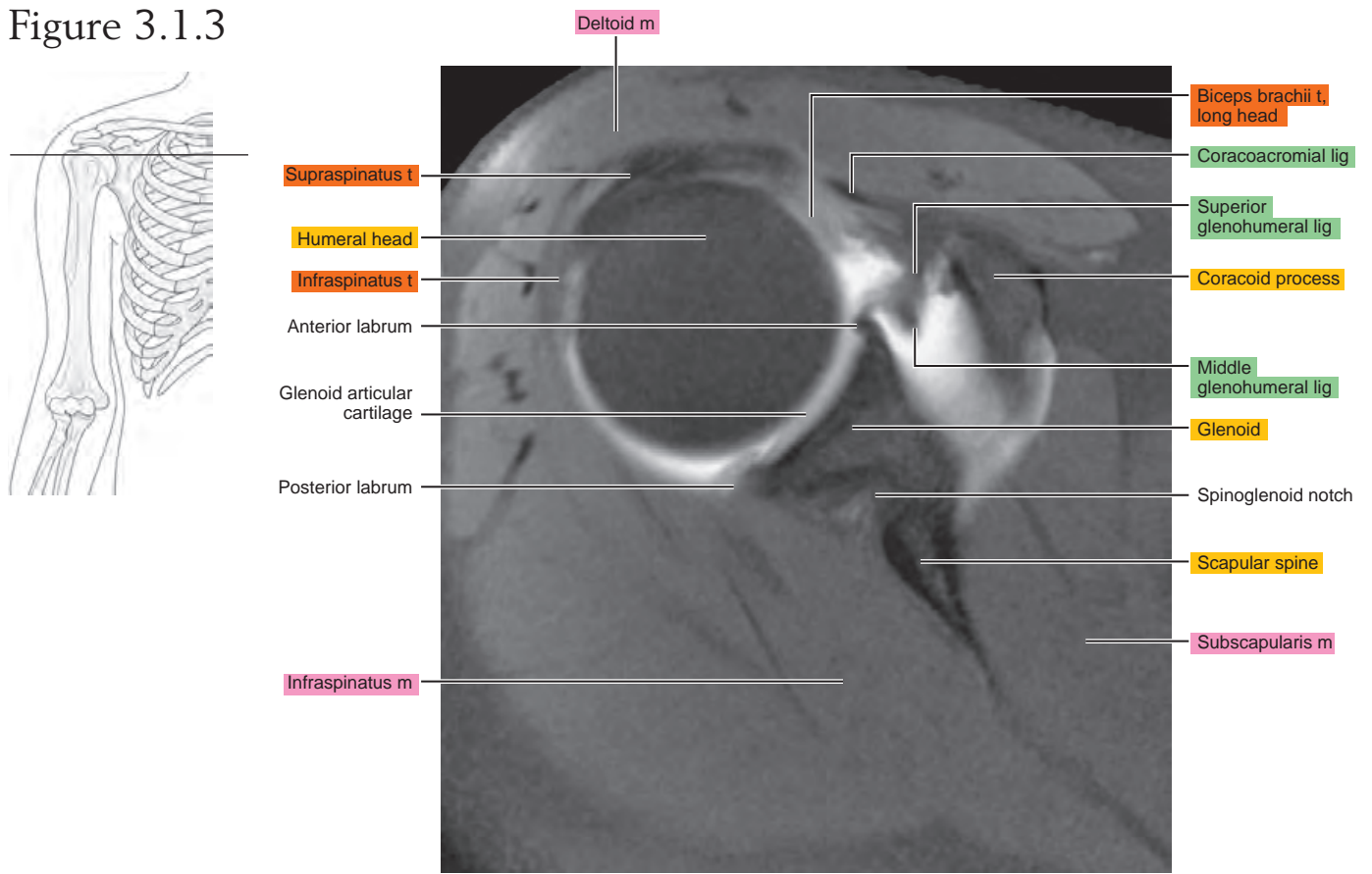


Figure 3.1.4

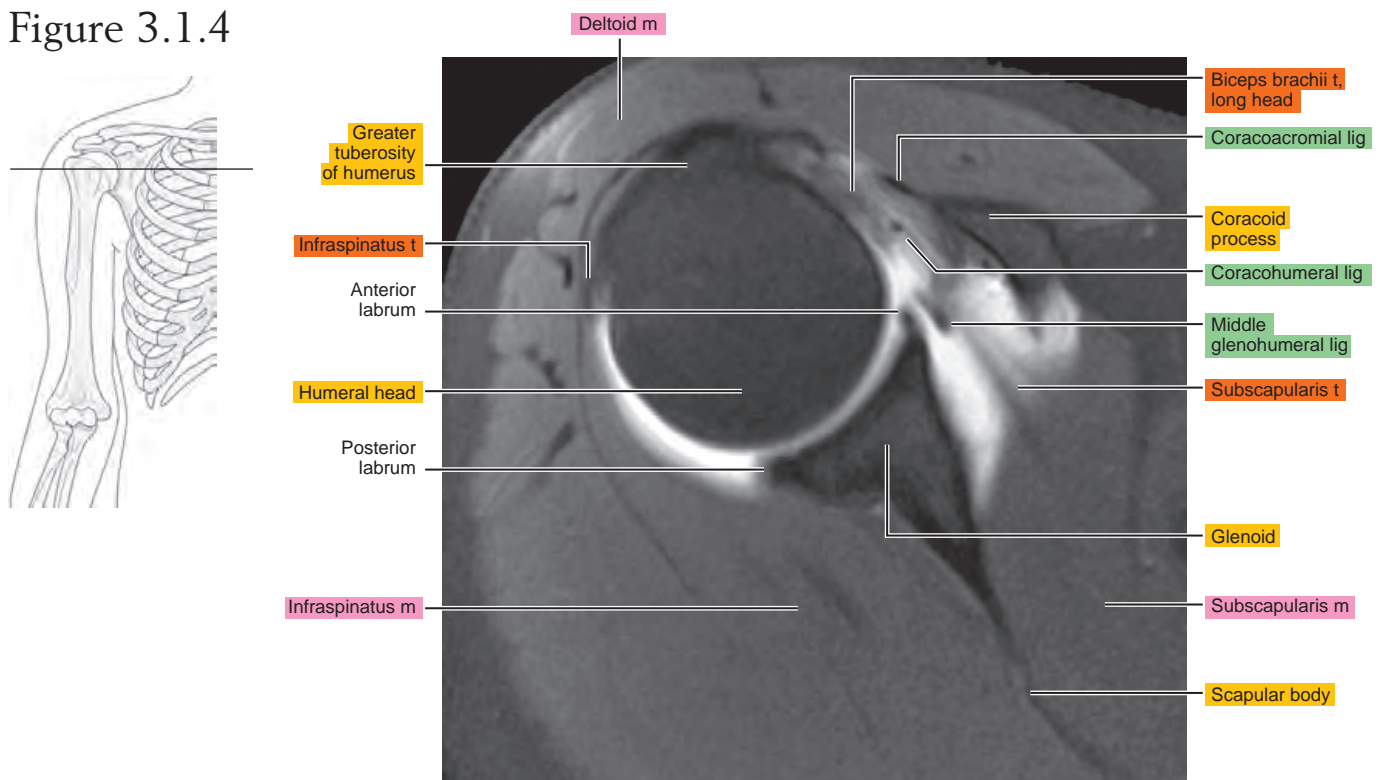


Figure 3.1.5

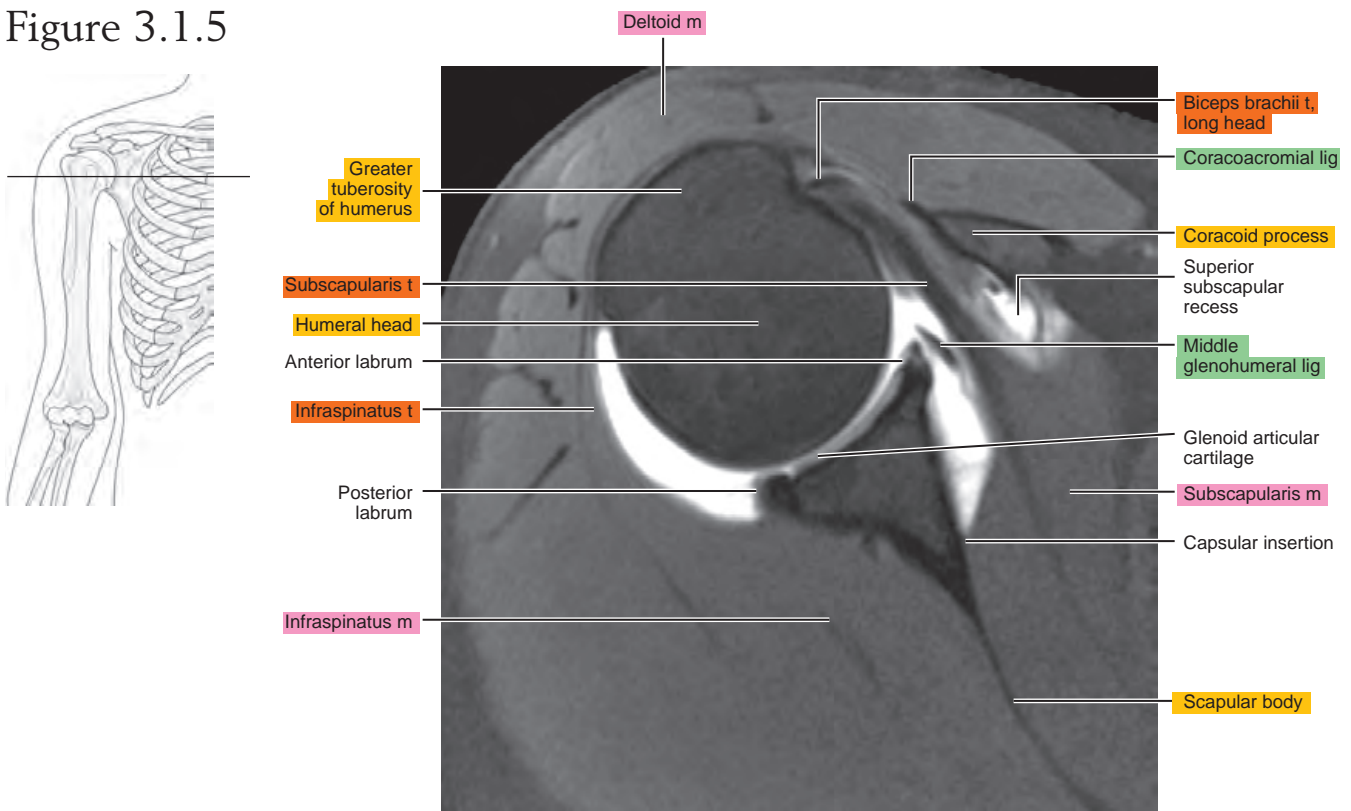


Figure 3.1.6

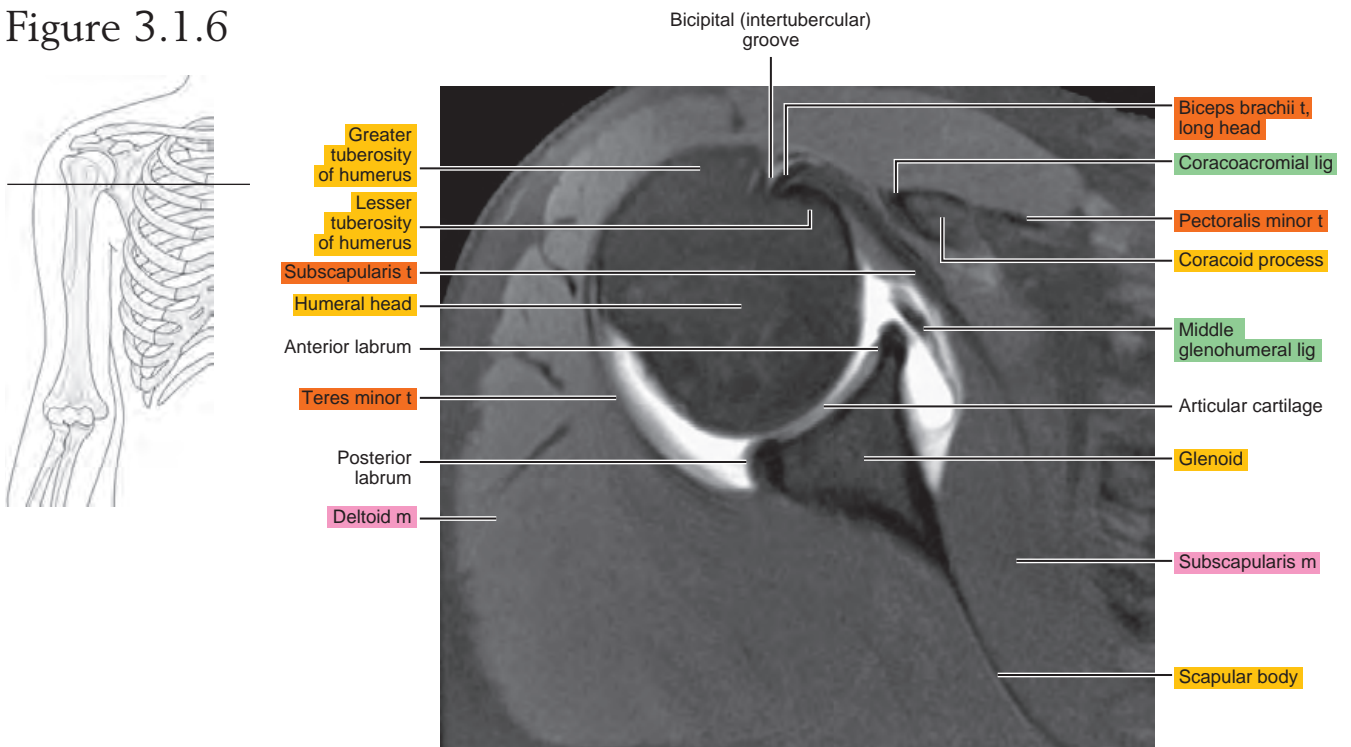


Figure 3.1.7

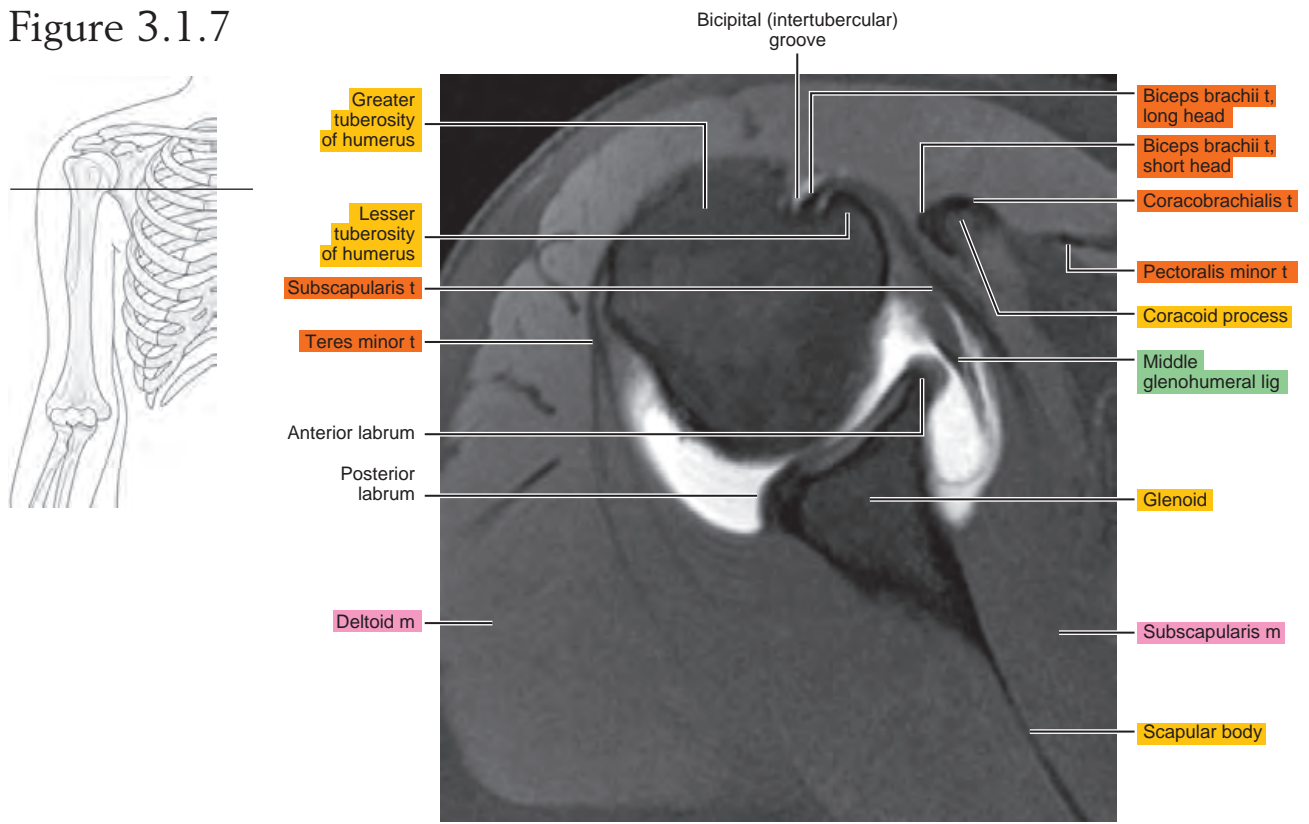


Figure 3.1.8

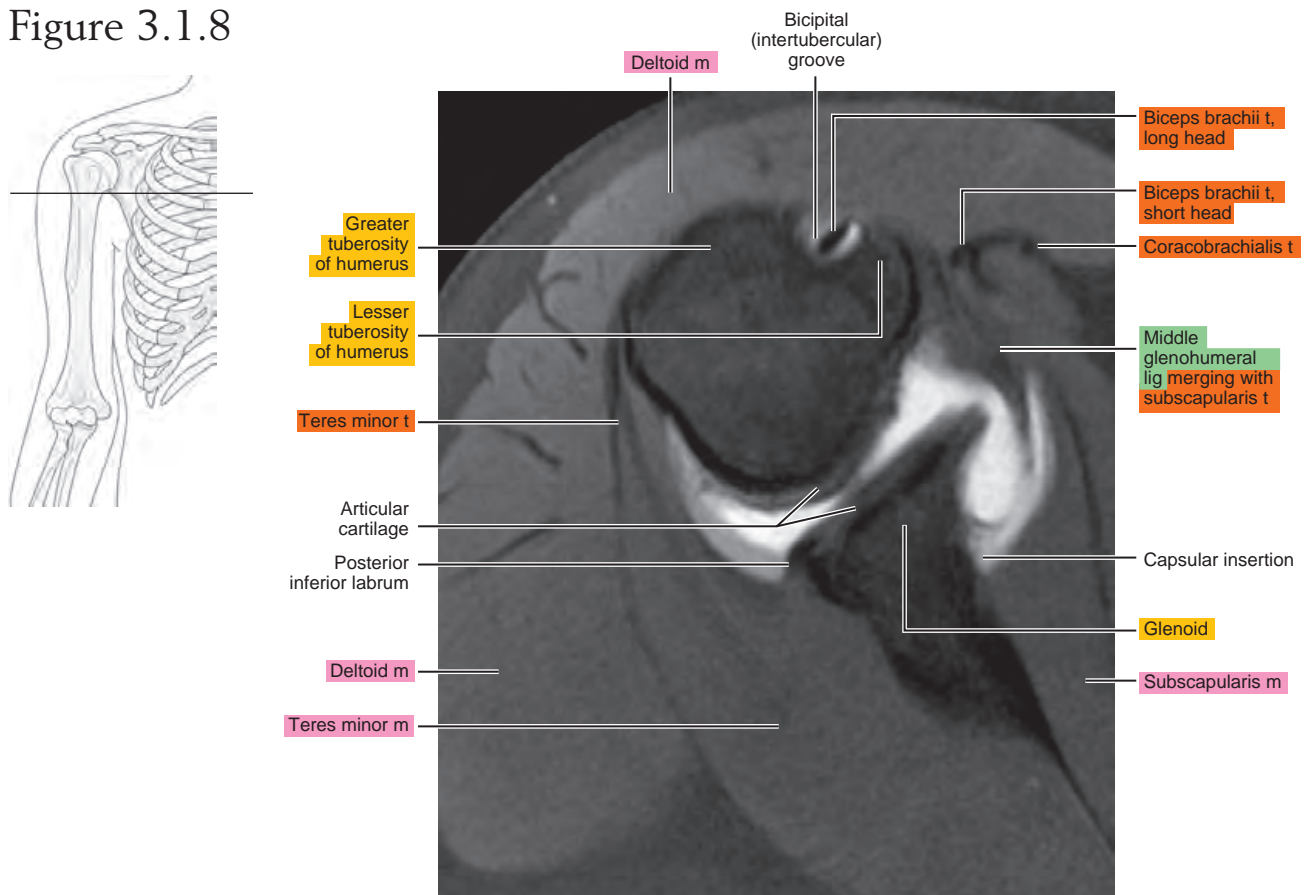


Figure 3.1.9

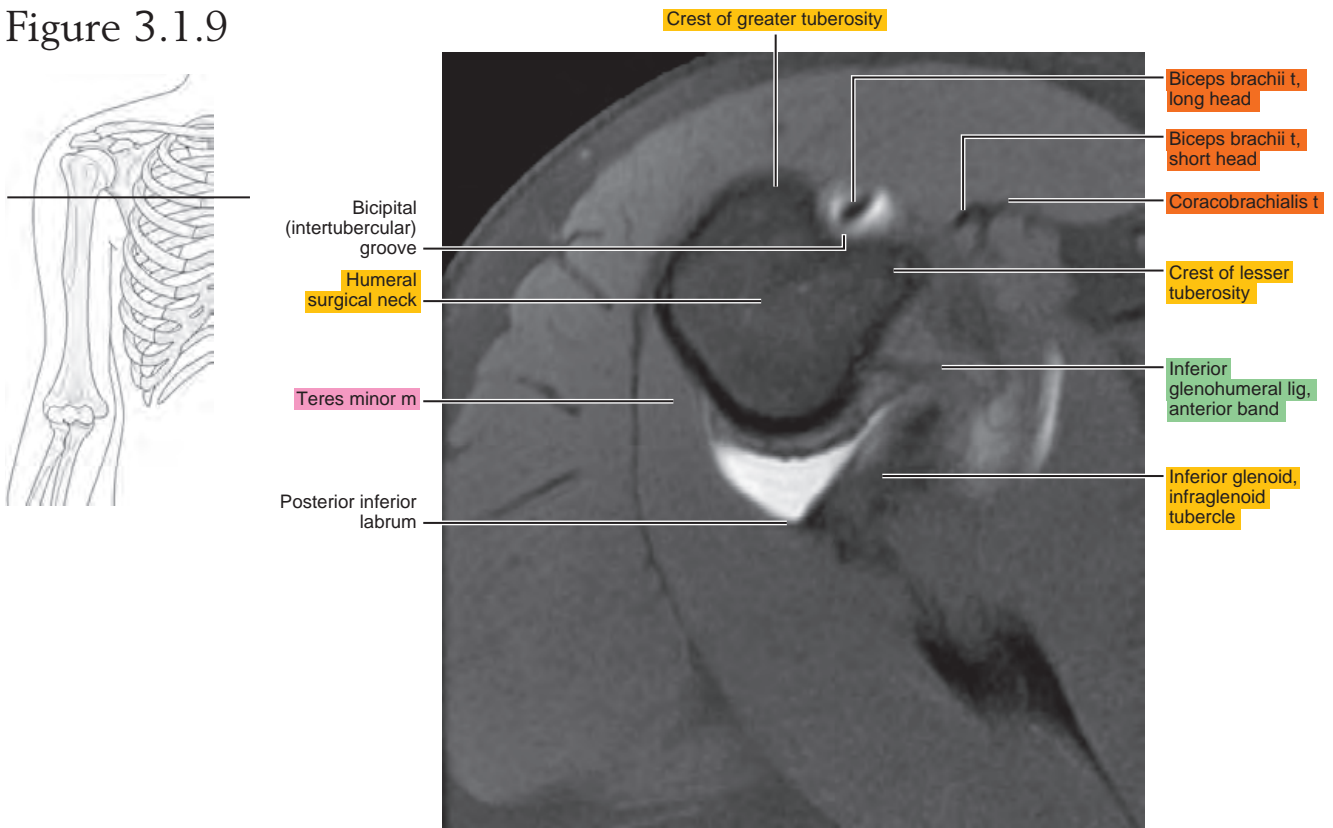
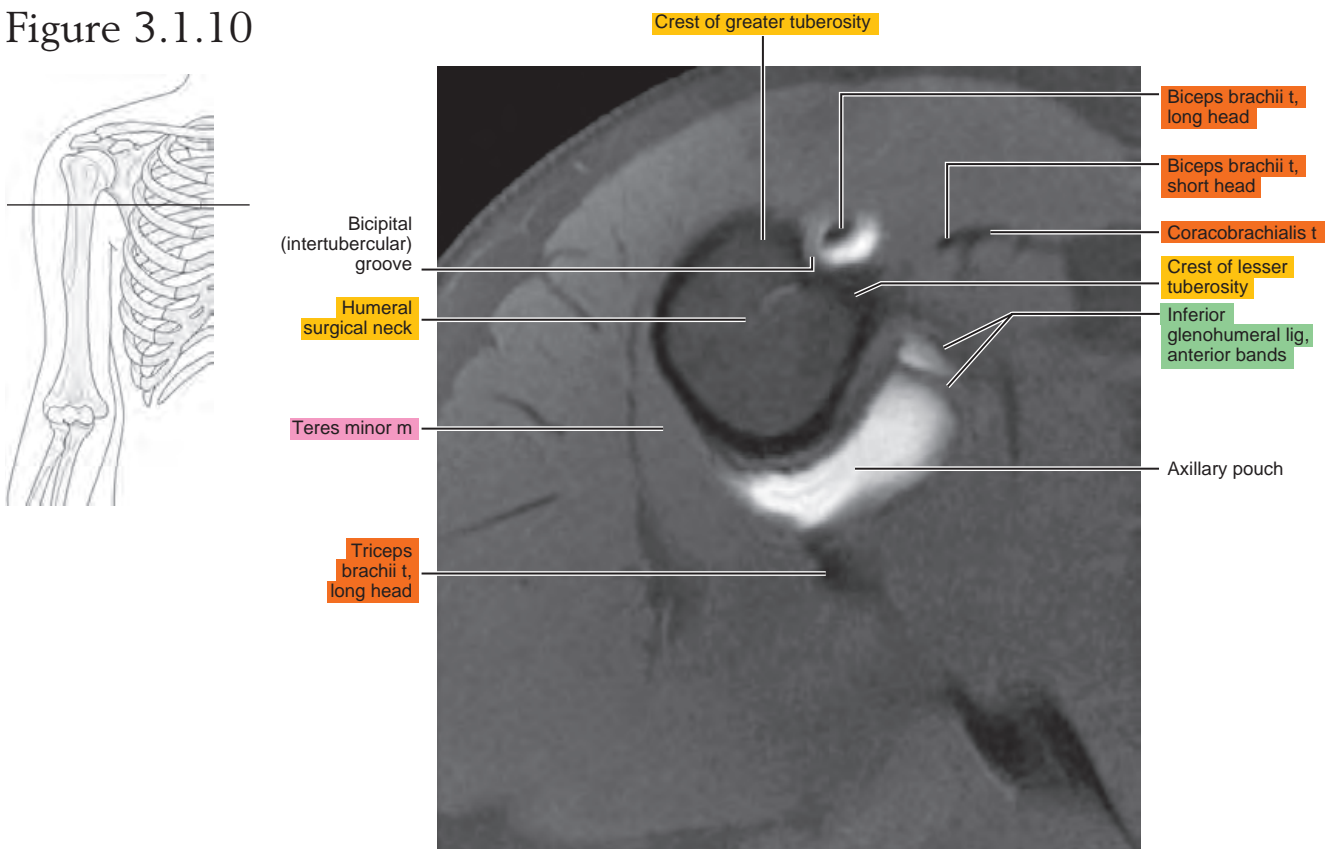


Figure 3.1.10



OBLIQUE SAGITTAL

Figure 3.2.1

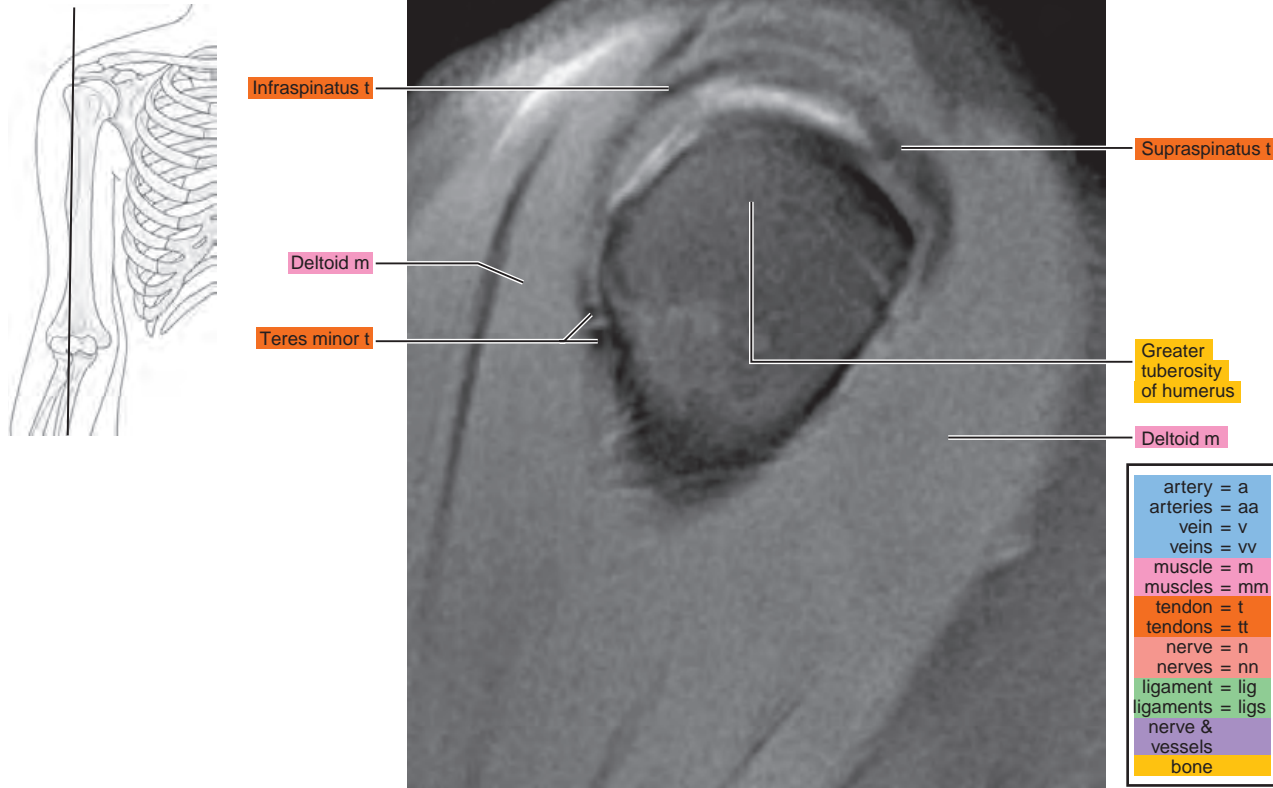


Figure 3.2.2

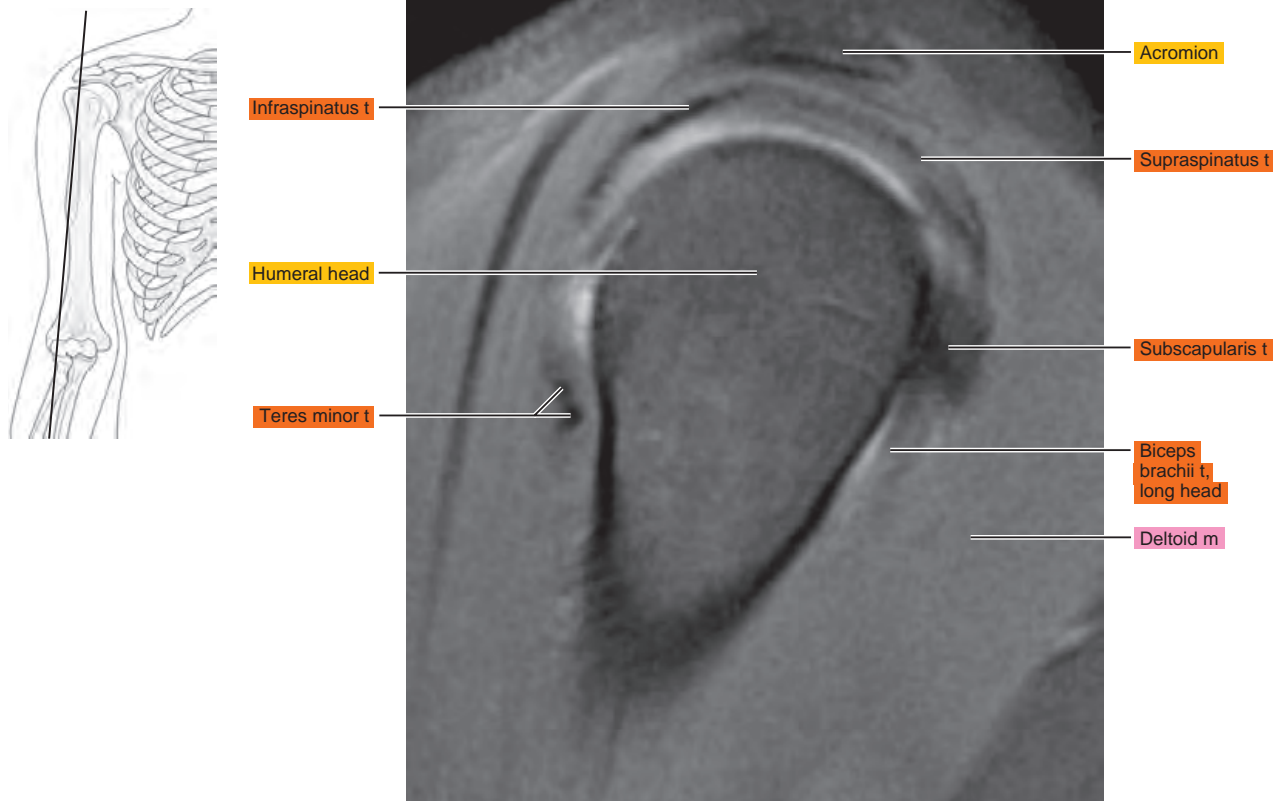


Figure 3.2.3

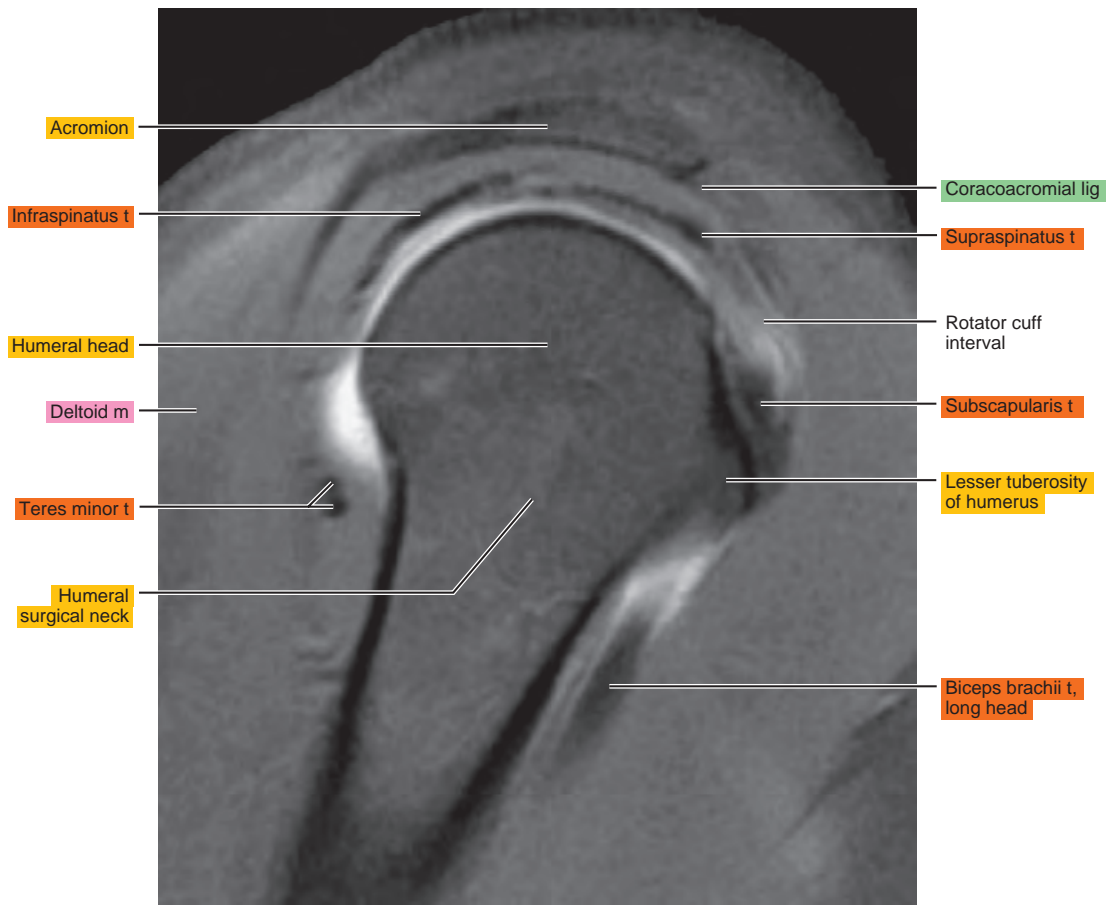
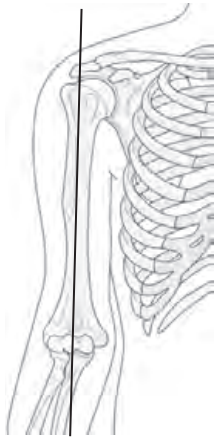


Figure 3.2.4

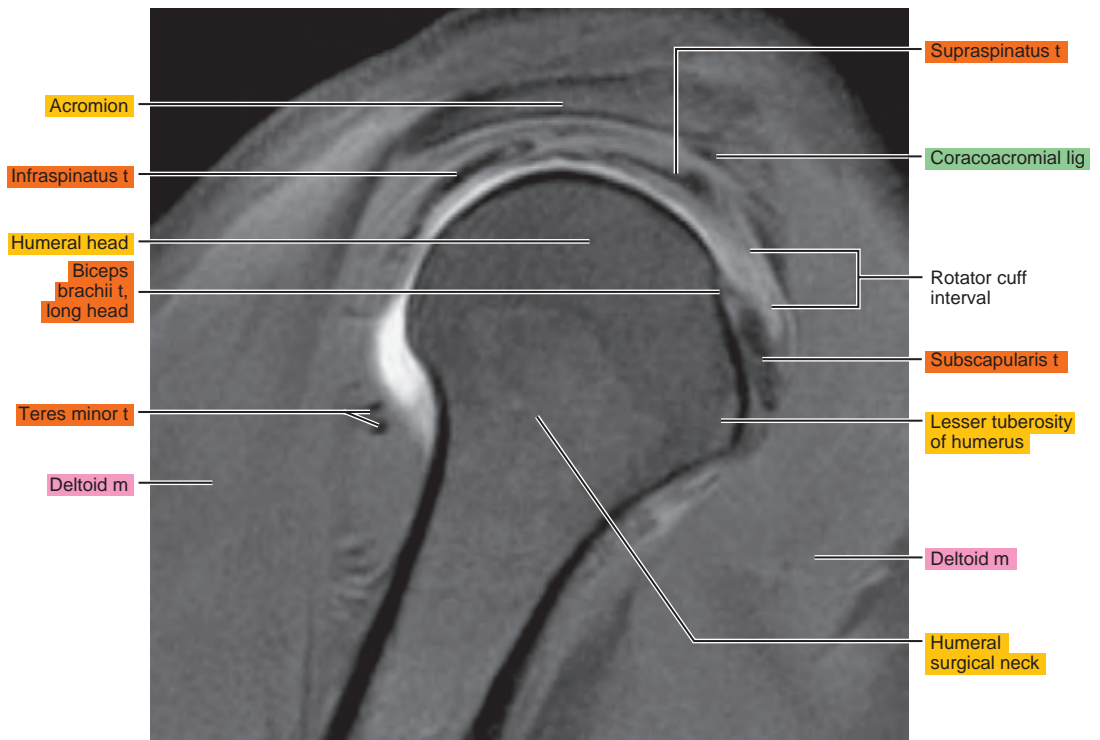
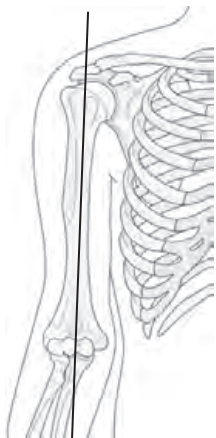


Figure 3.2.5

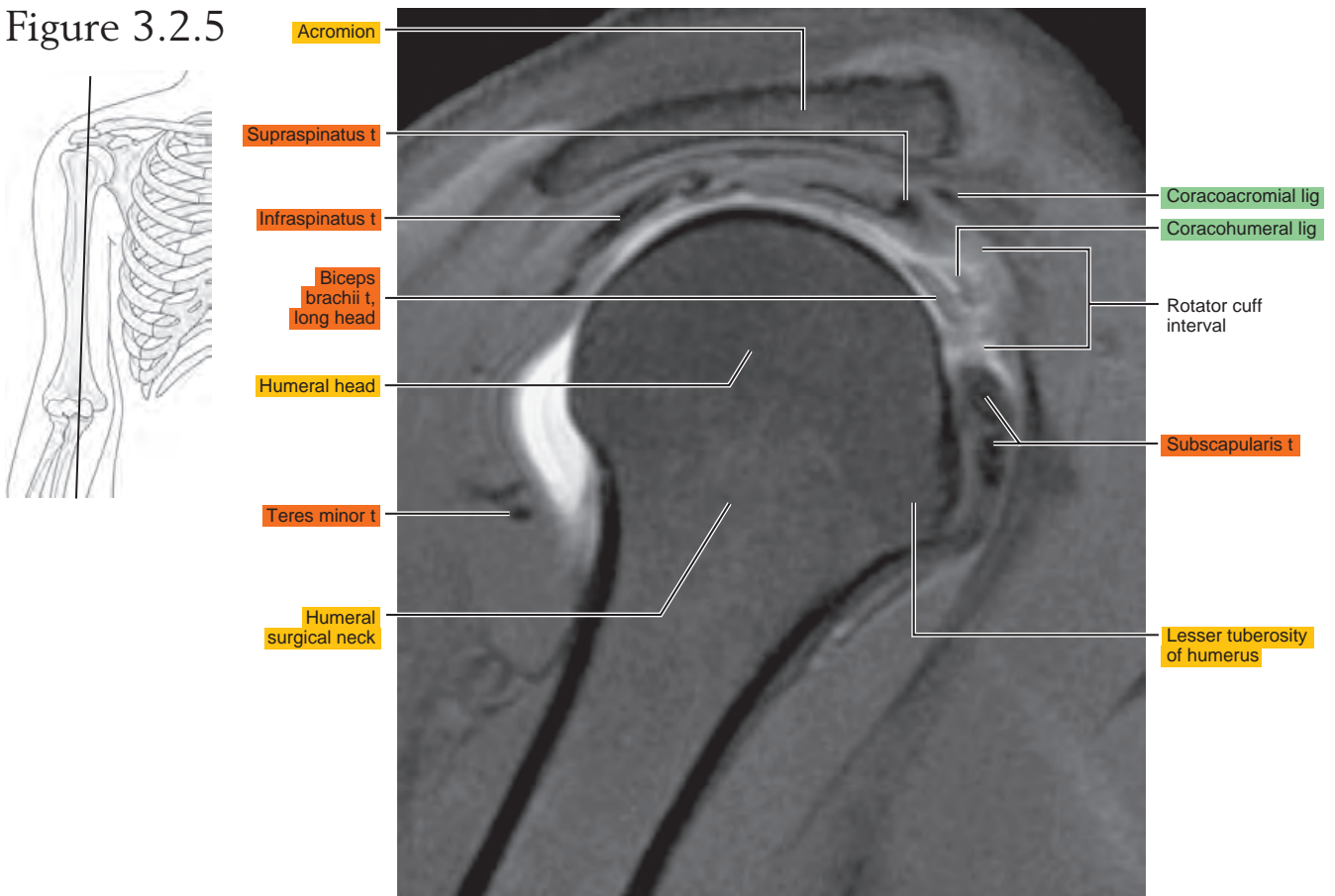


Figure 3.2.6

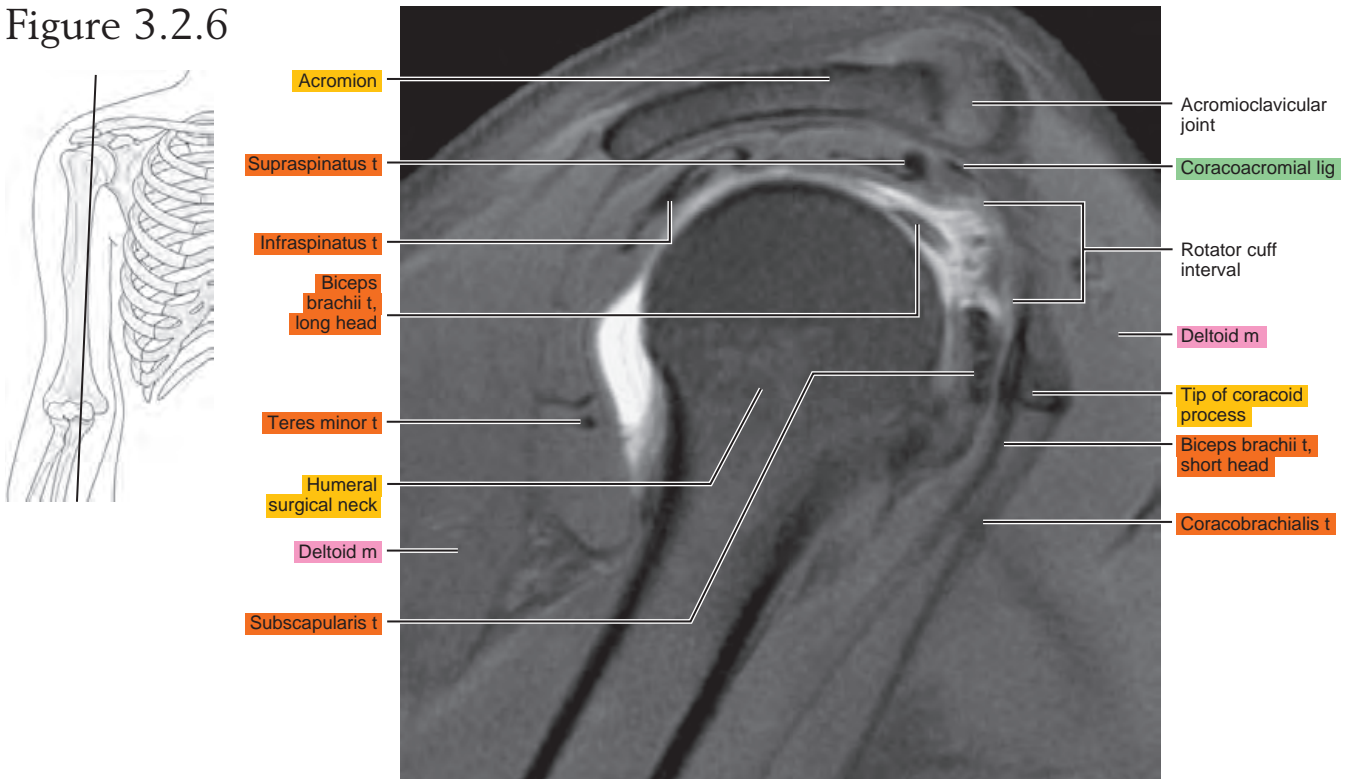


Figure 3.2.7

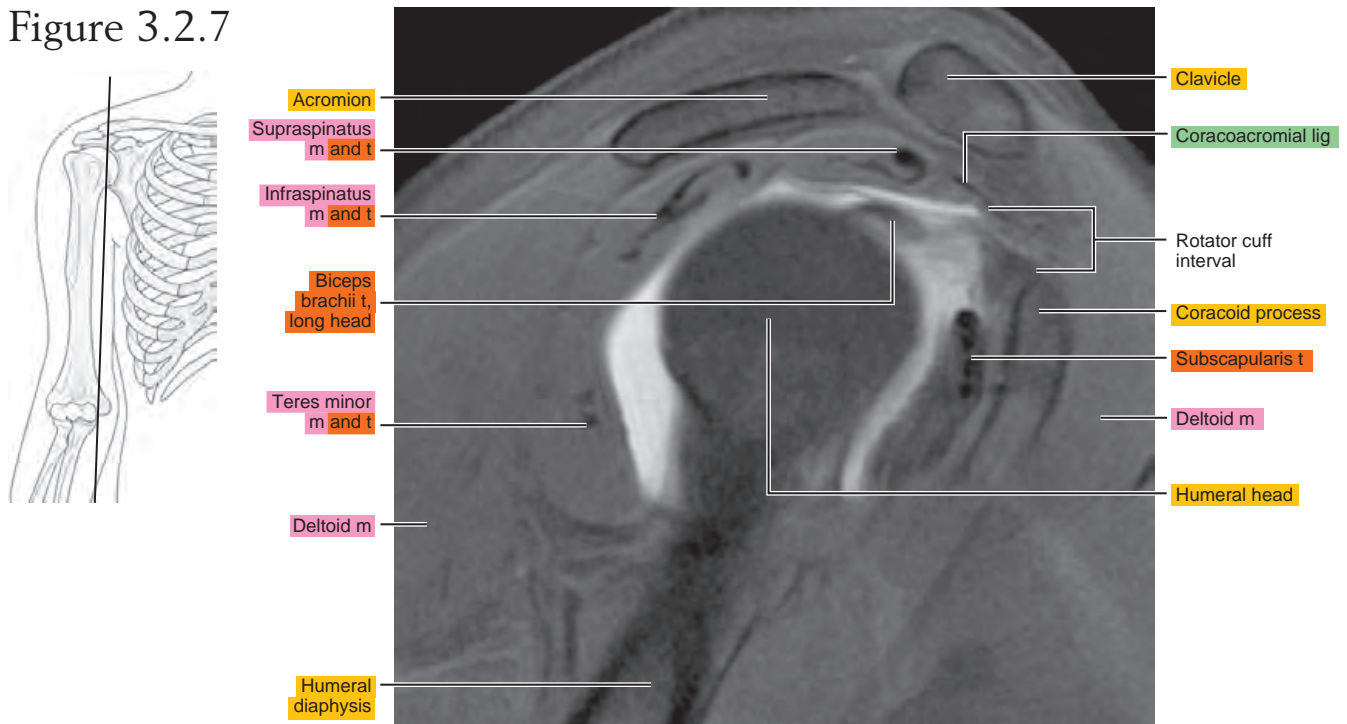


Figure 3.2.8

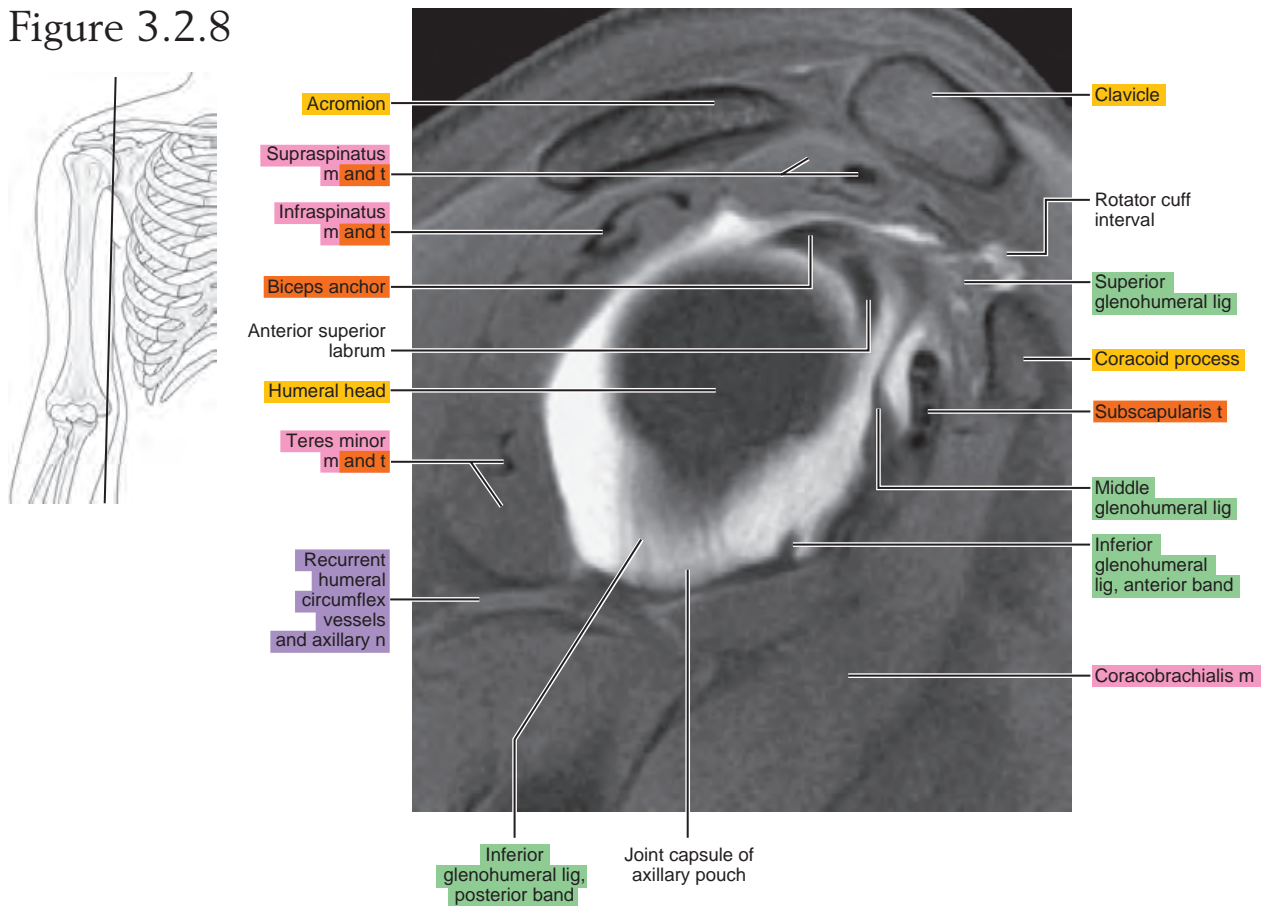


Figure 3.2.9

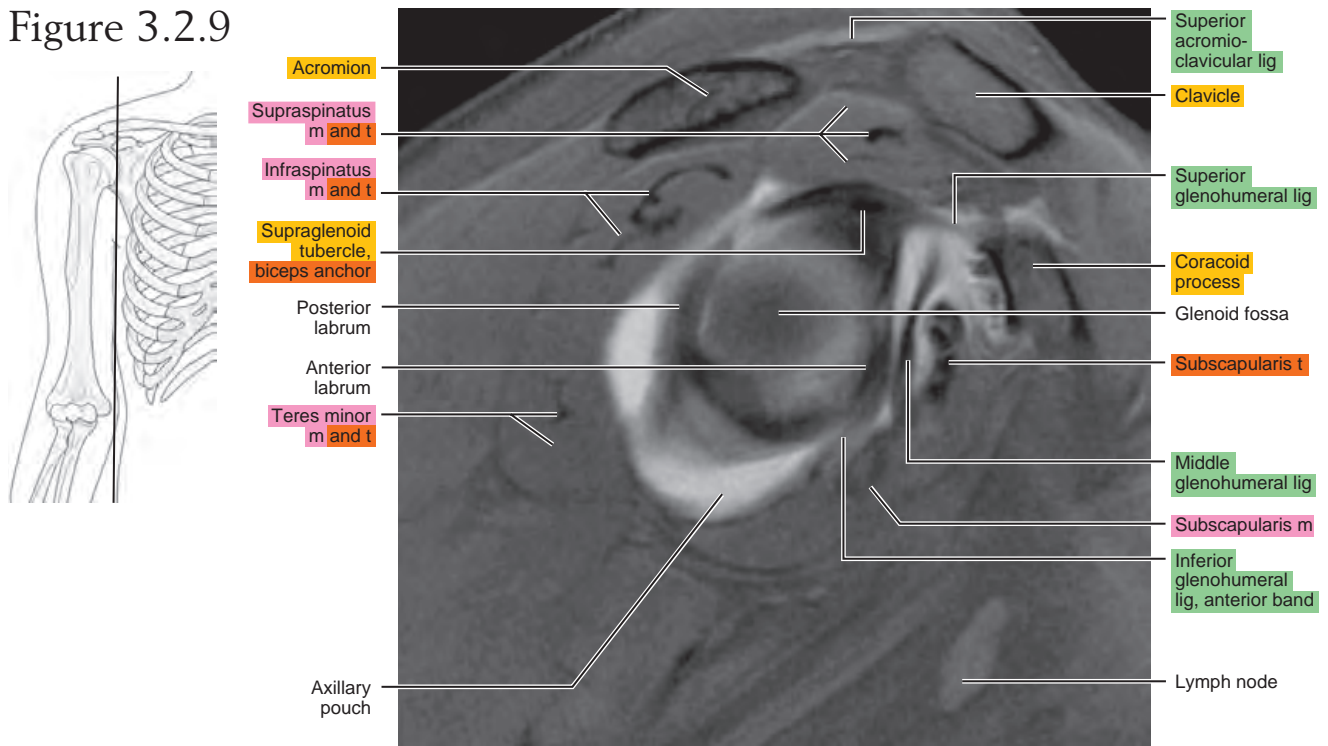


Figure 3.2.10

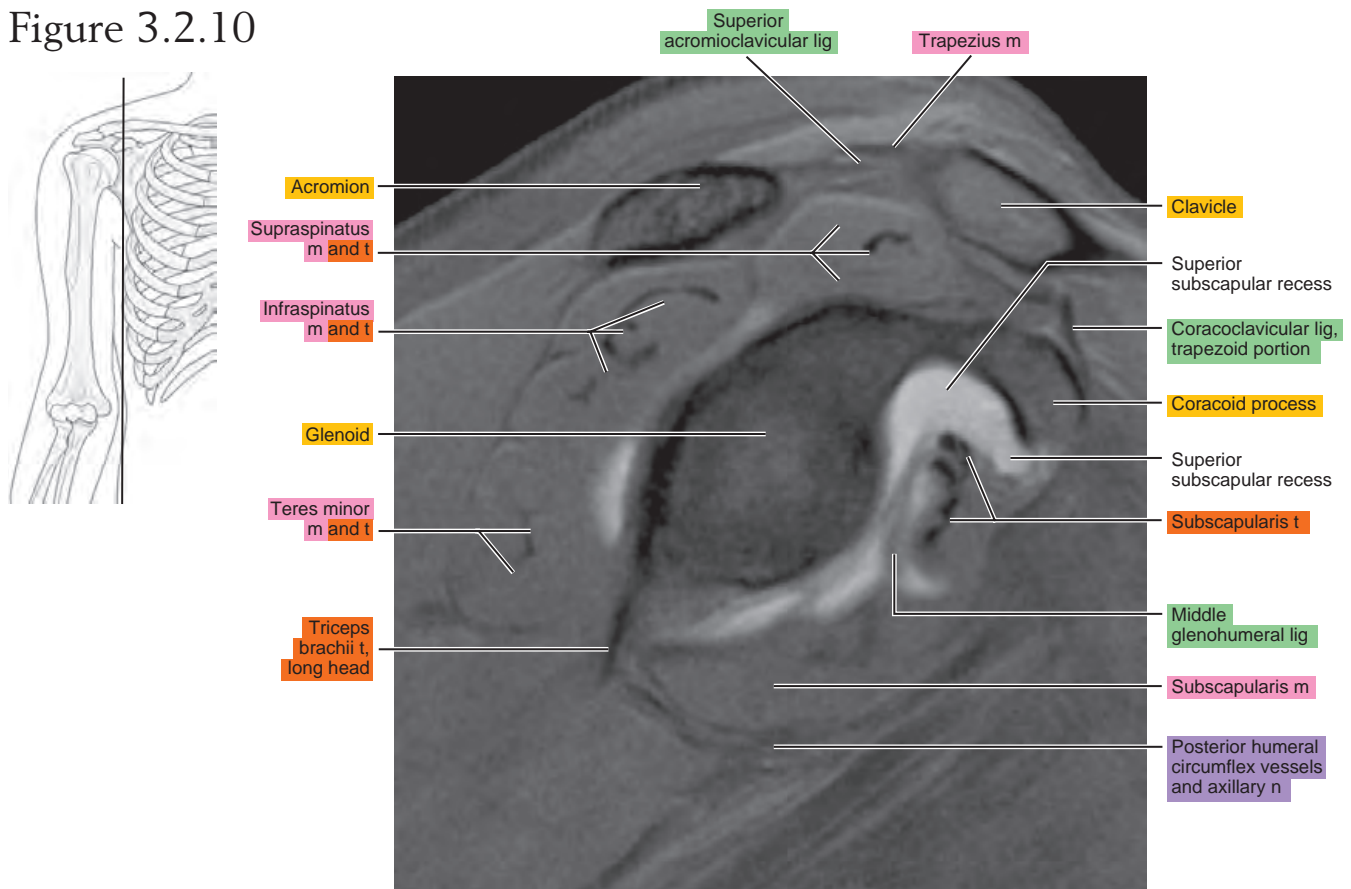
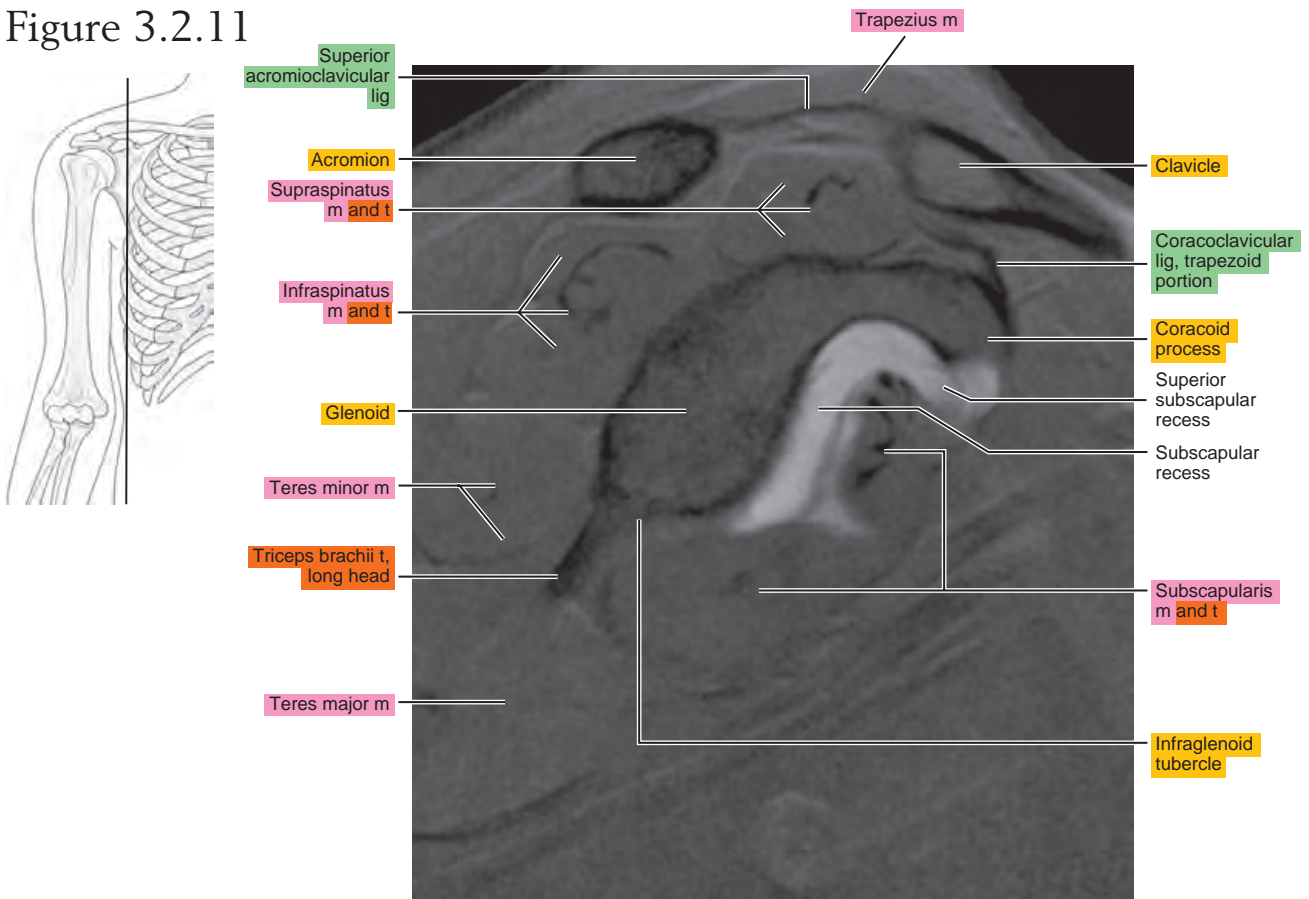


Figure 3.2.11



OBLIQUE CORONAL

Figure 3.3.1

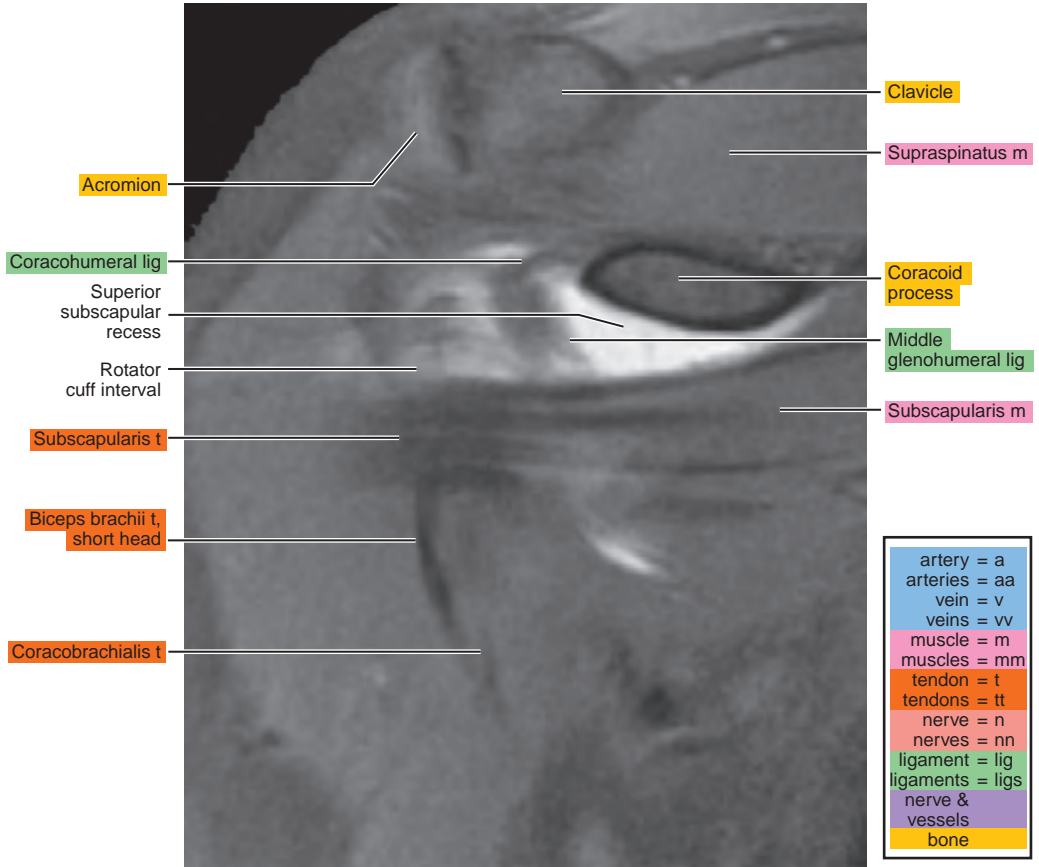
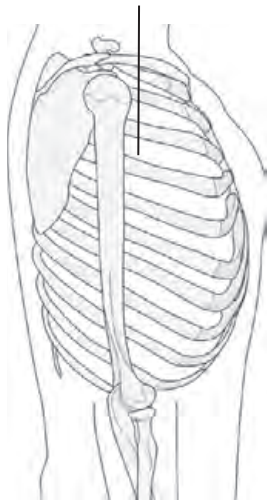


Figure 3.3.2

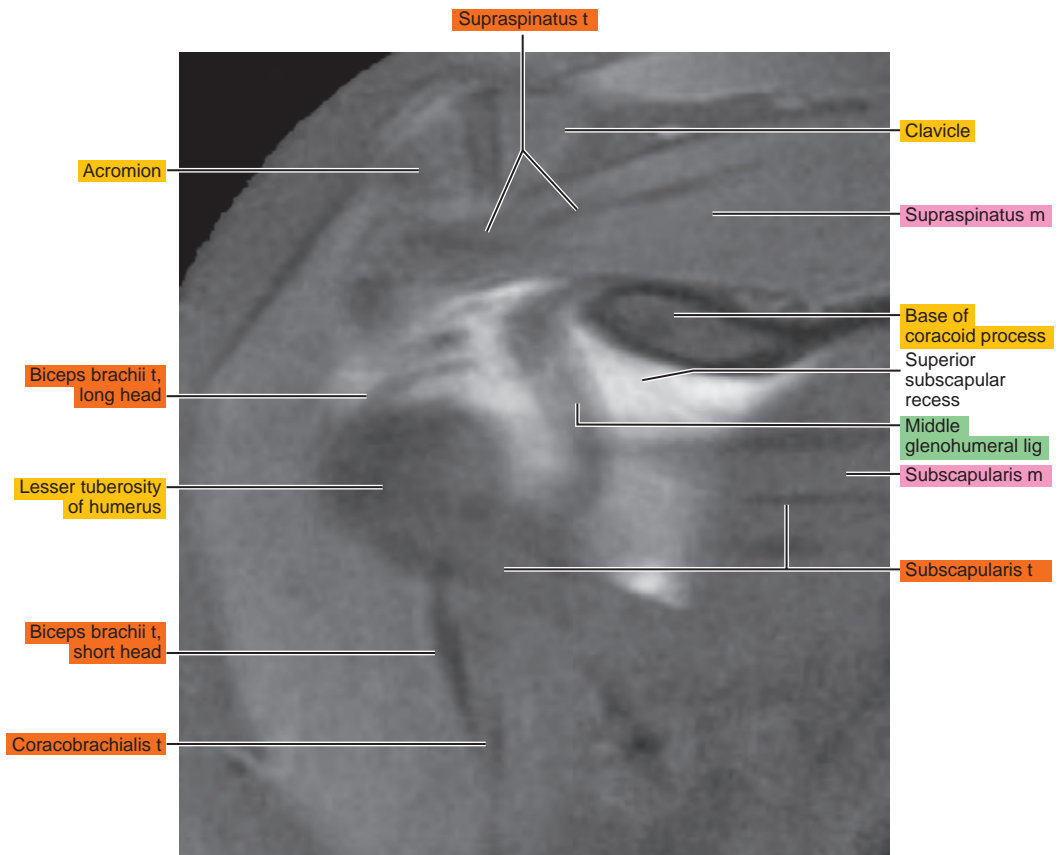
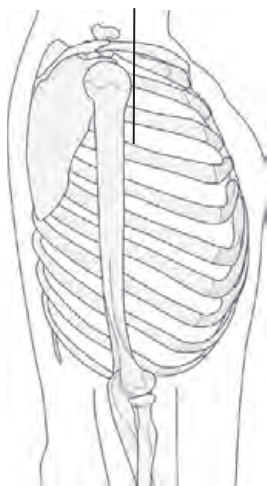


Figure 3.3.3

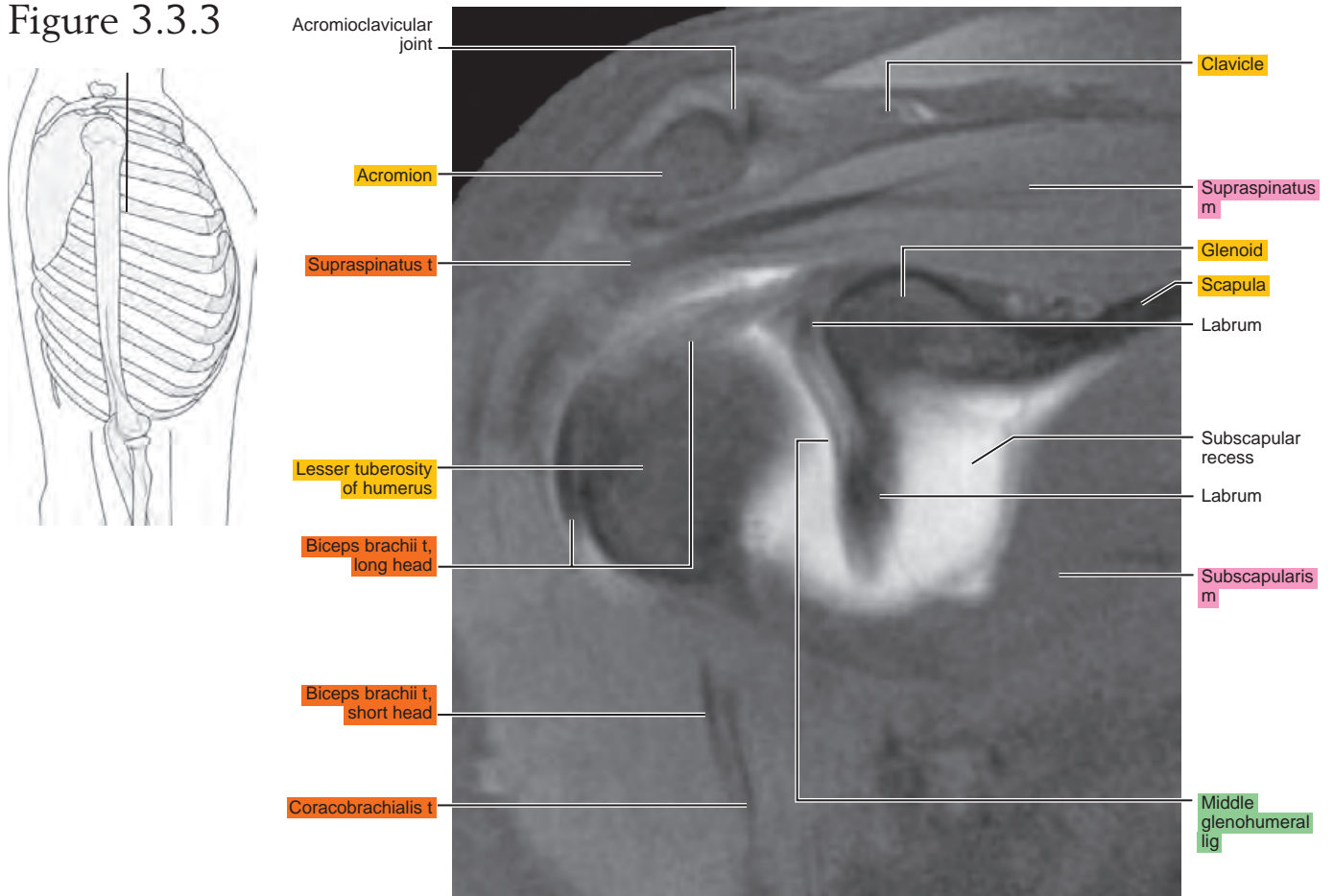


Figure 3.3.4

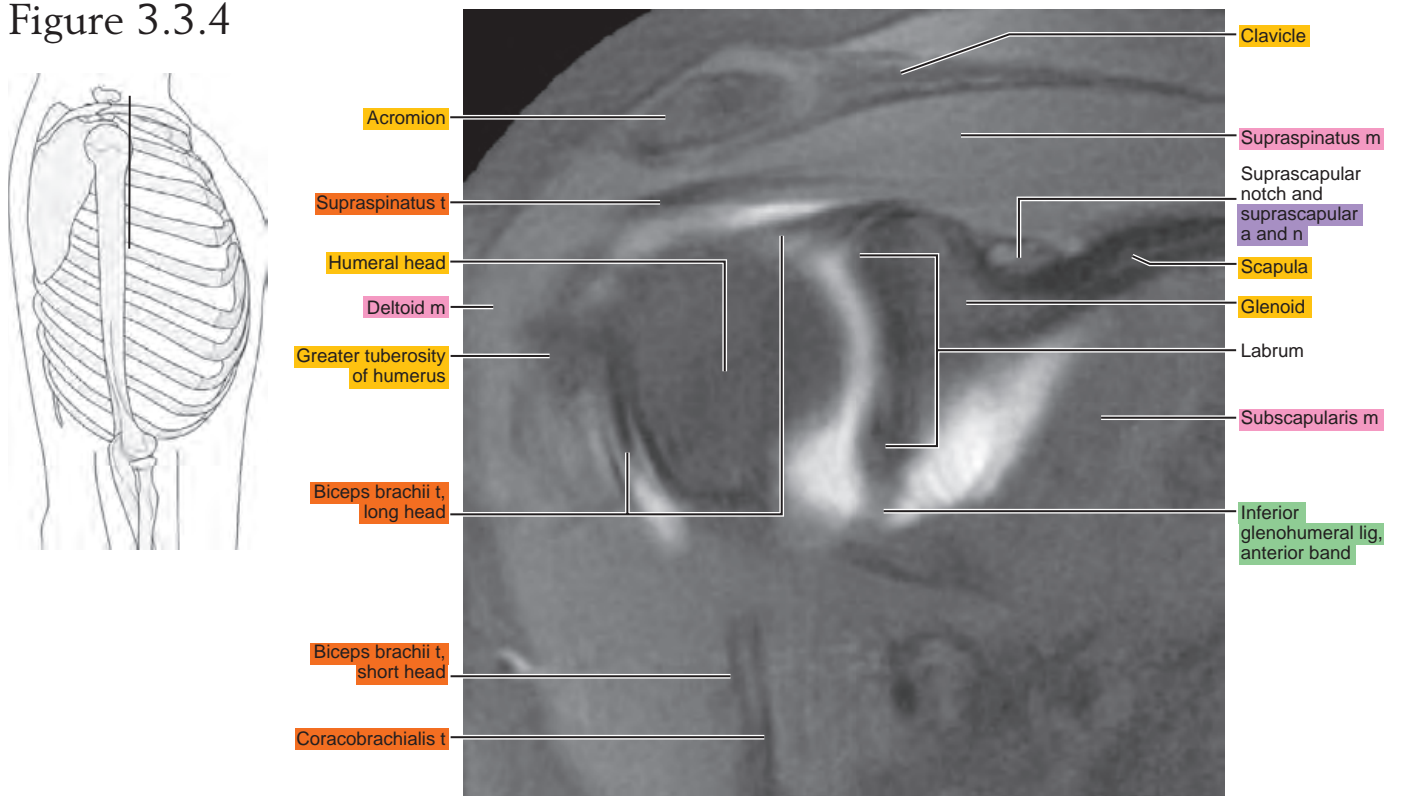


Figure 3.3.5

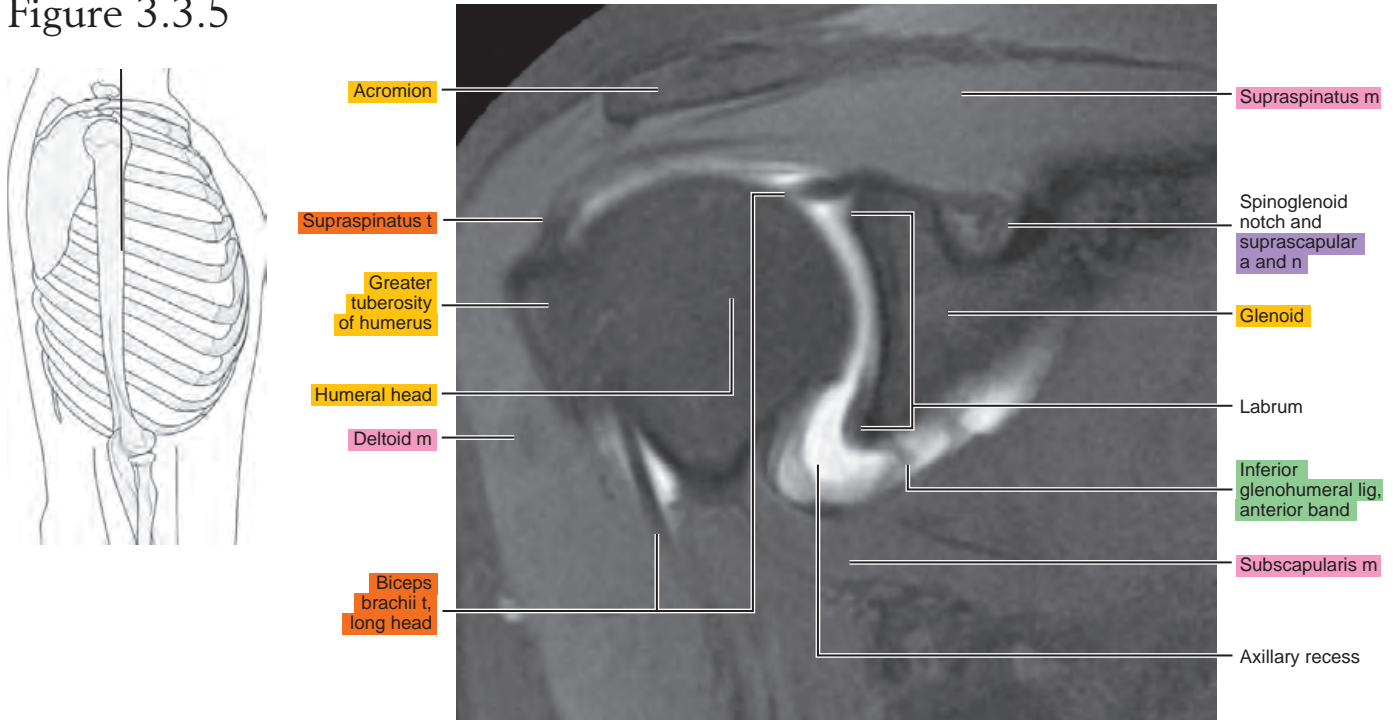


Figure 3.3.6

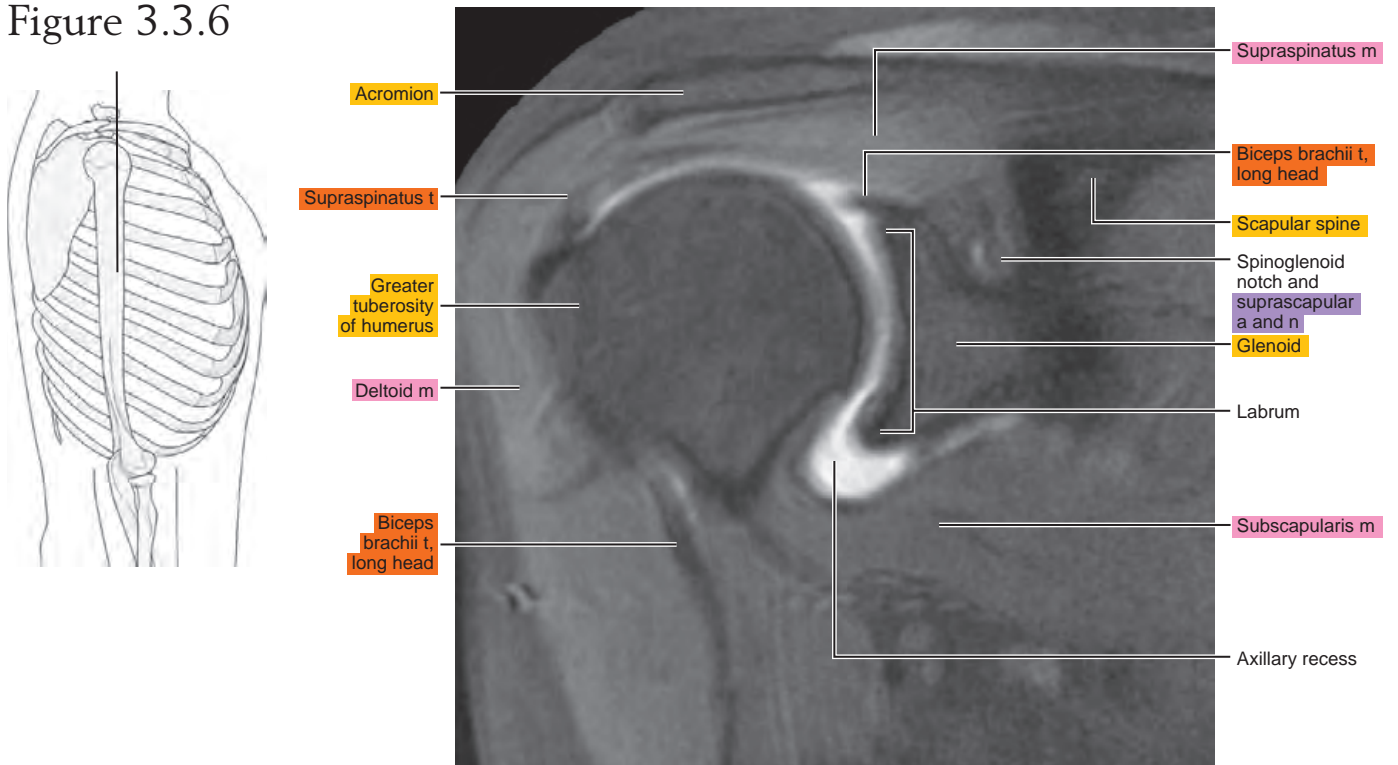


Figure 3.3.7

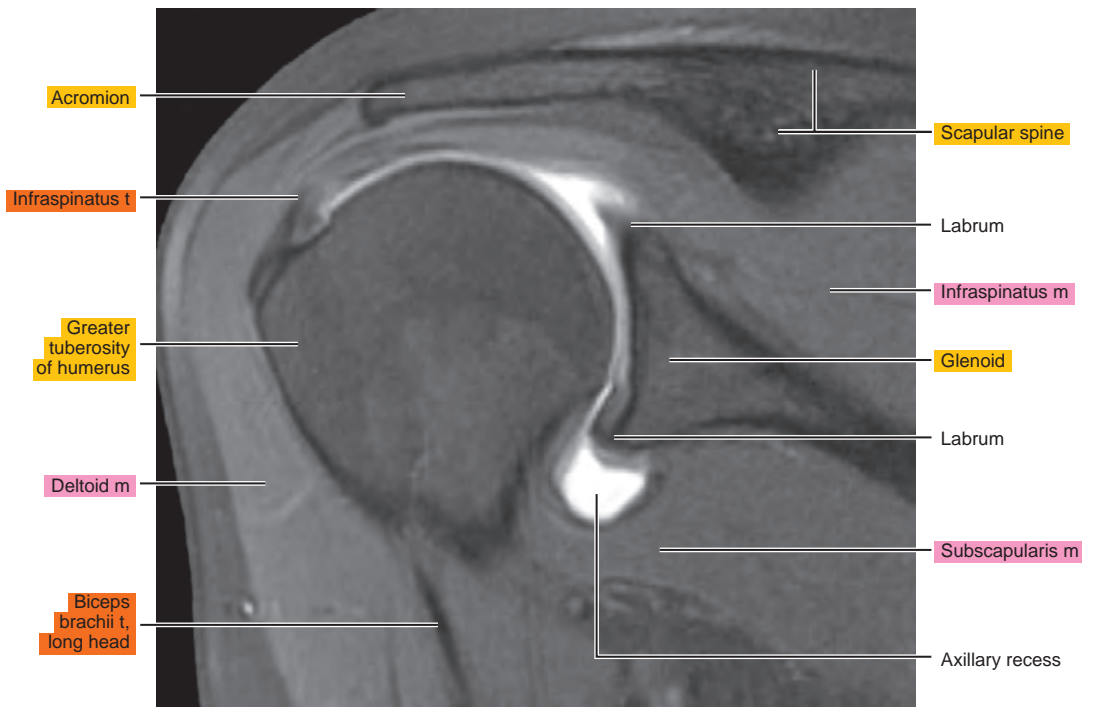
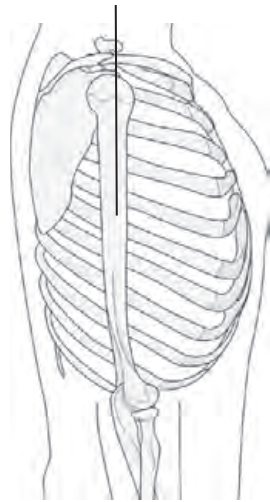


Figure 3.3.8

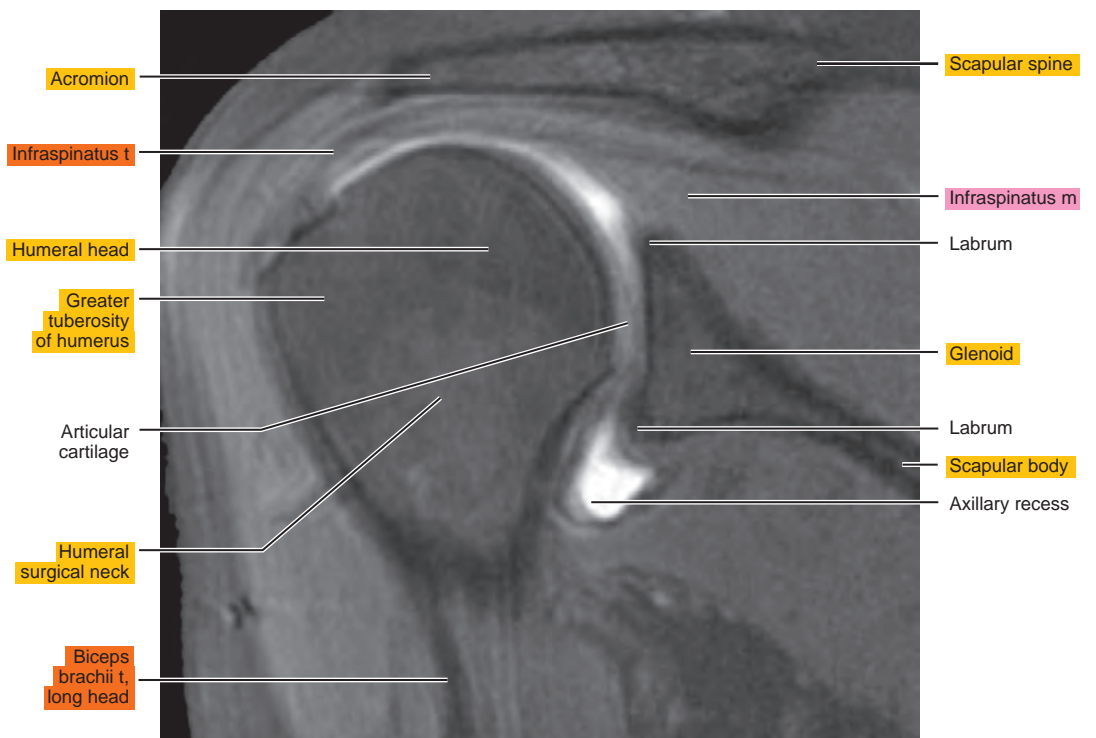
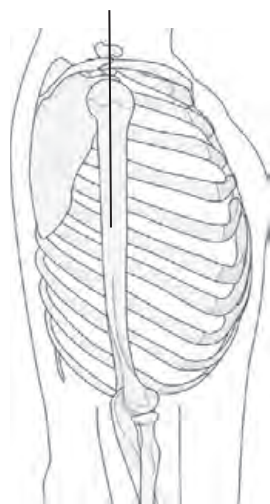


Figure 3.3.9

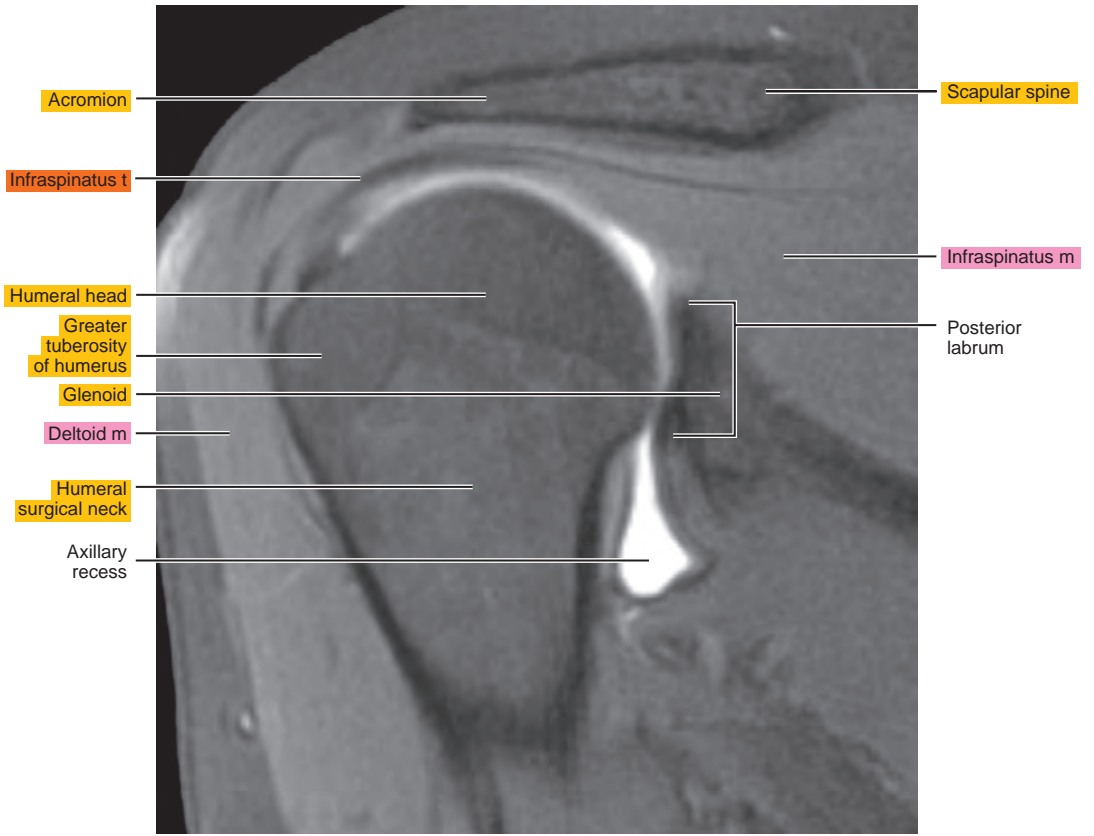
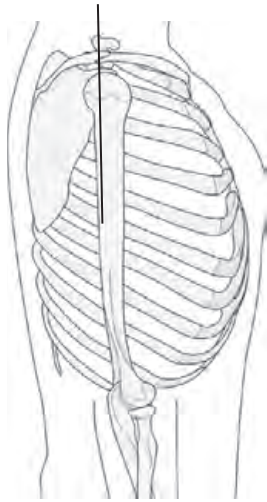


Figure 3.3.10

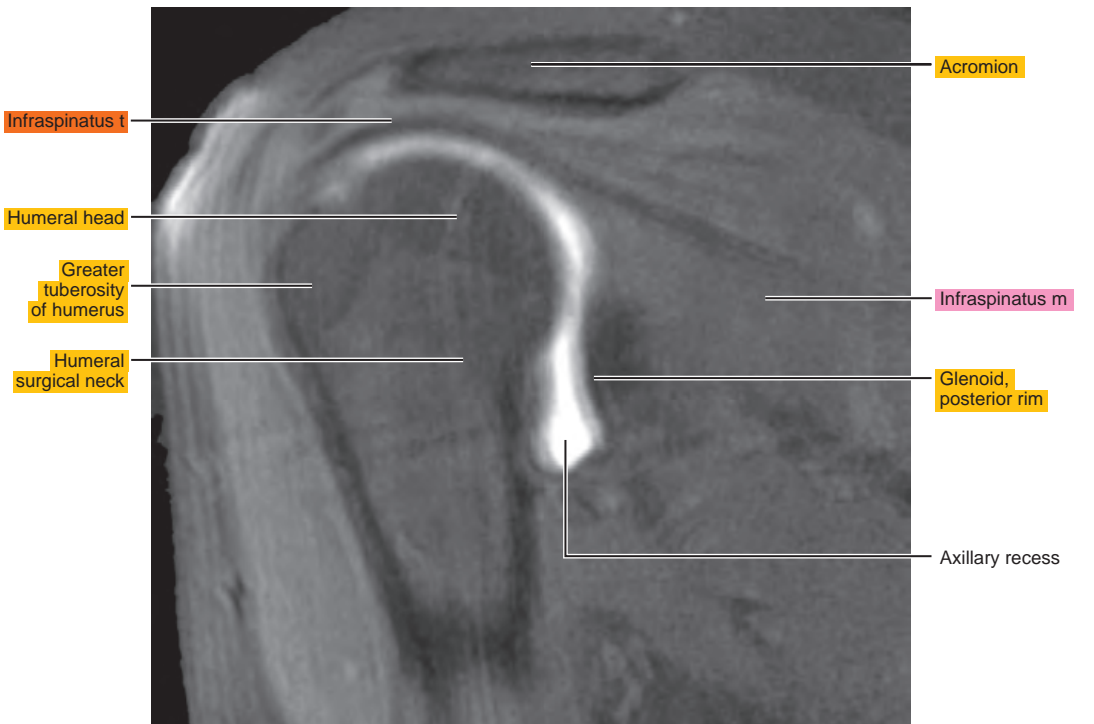
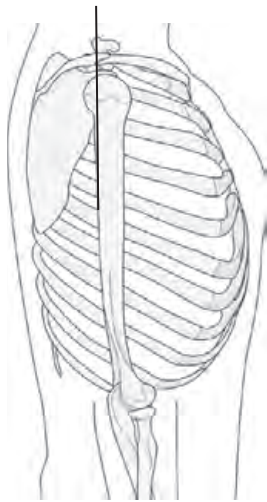


Figure 3.3.11

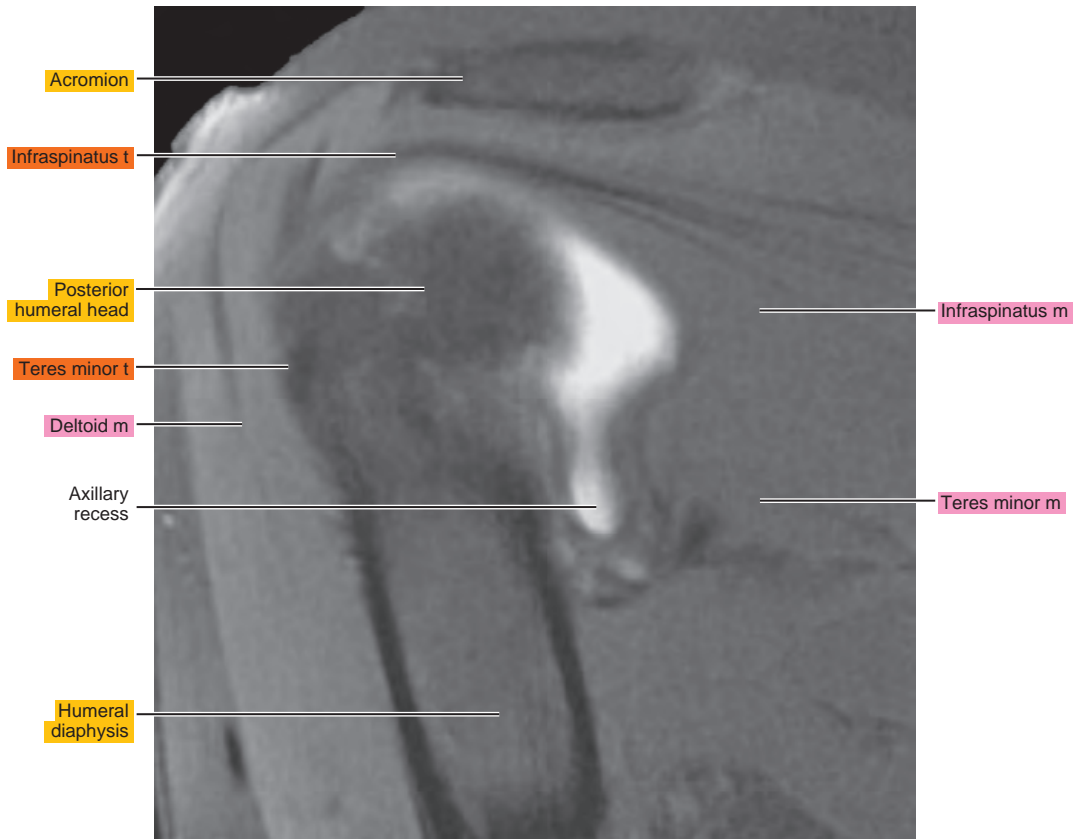
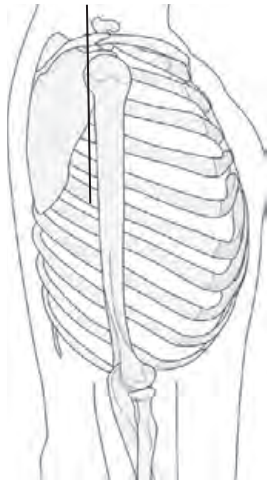
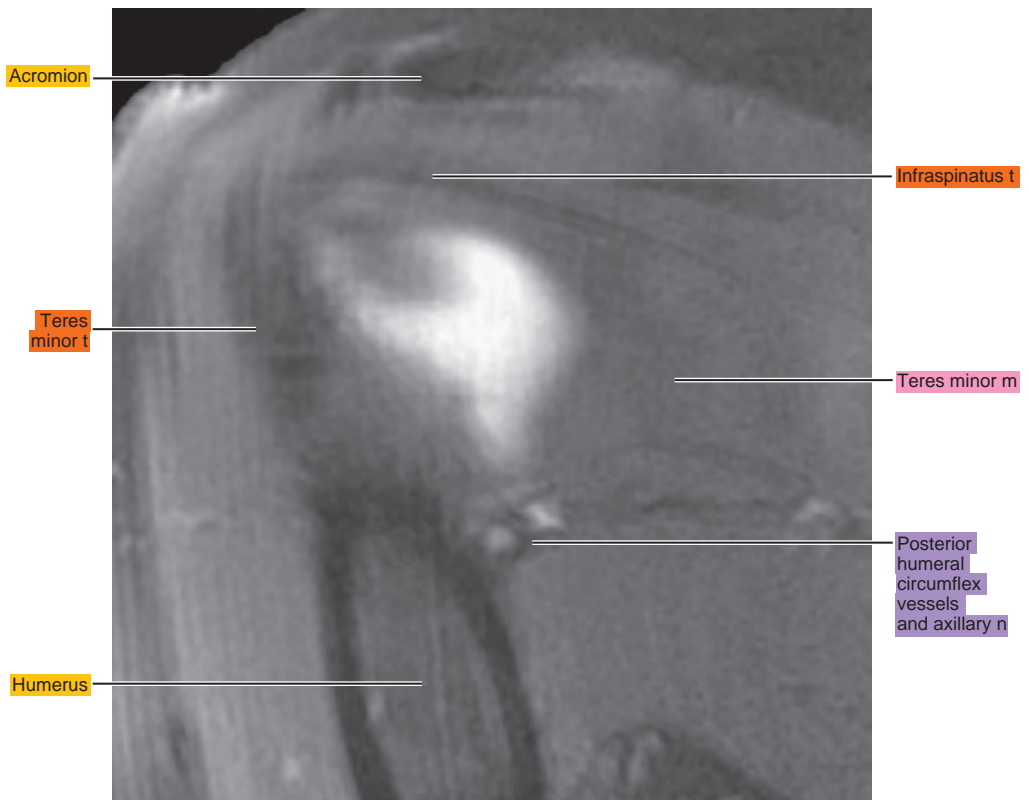
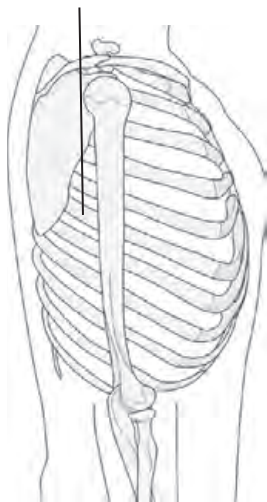


Figure 3.3.12



ABER (ABDUCTION AND EXTERNAL ROTATION)

Figure 3.4.1

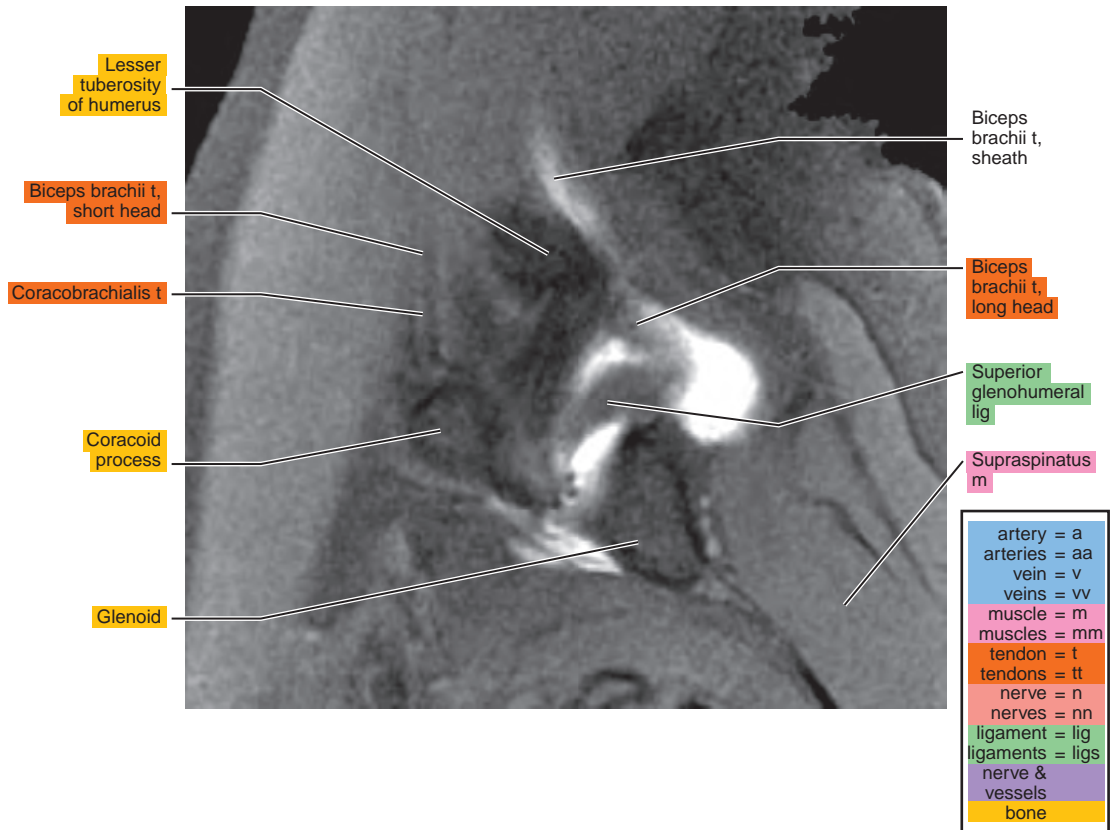
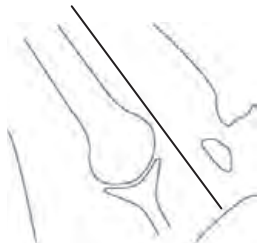


Figure 3.4.2

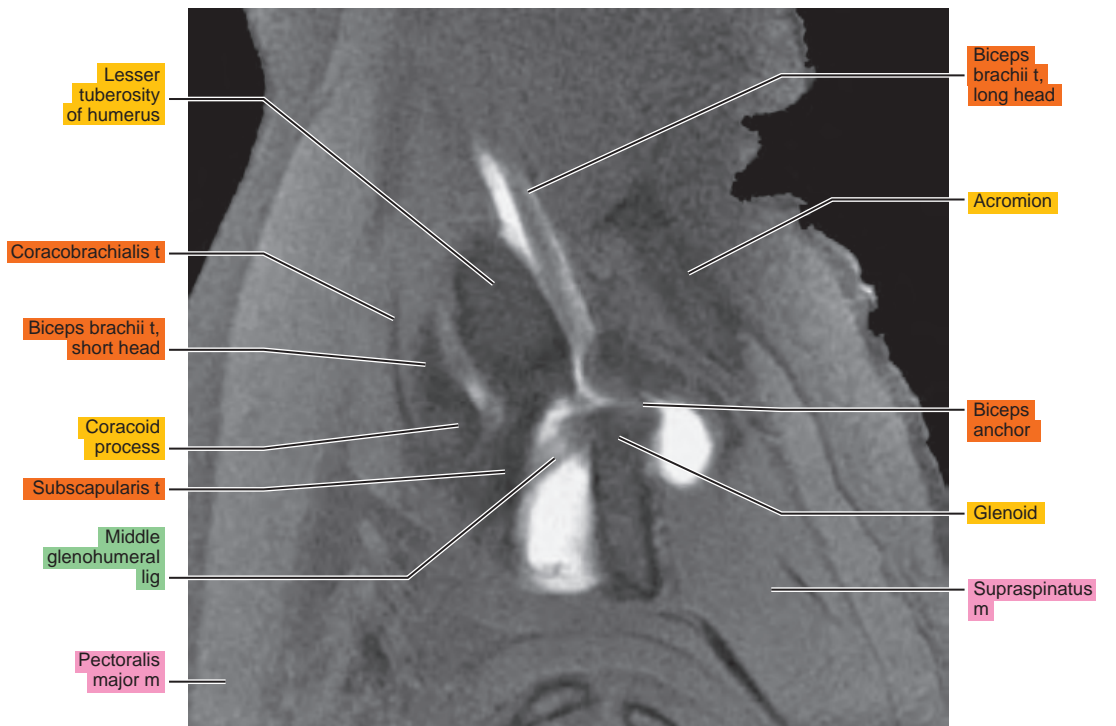
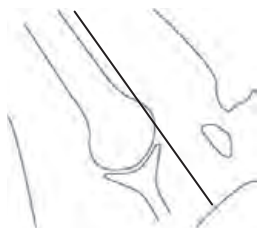


Figure 3.4.3

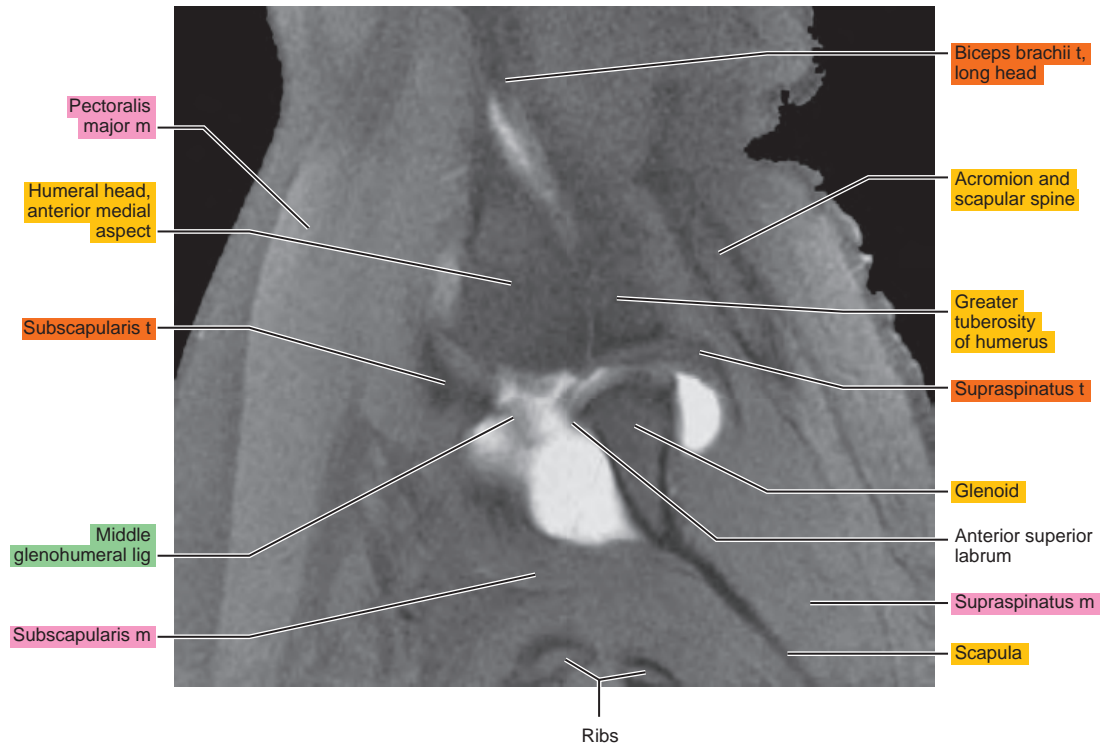
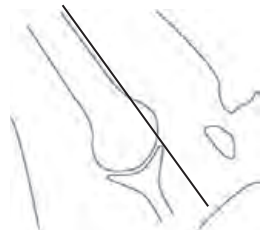


Figure 3.4.4

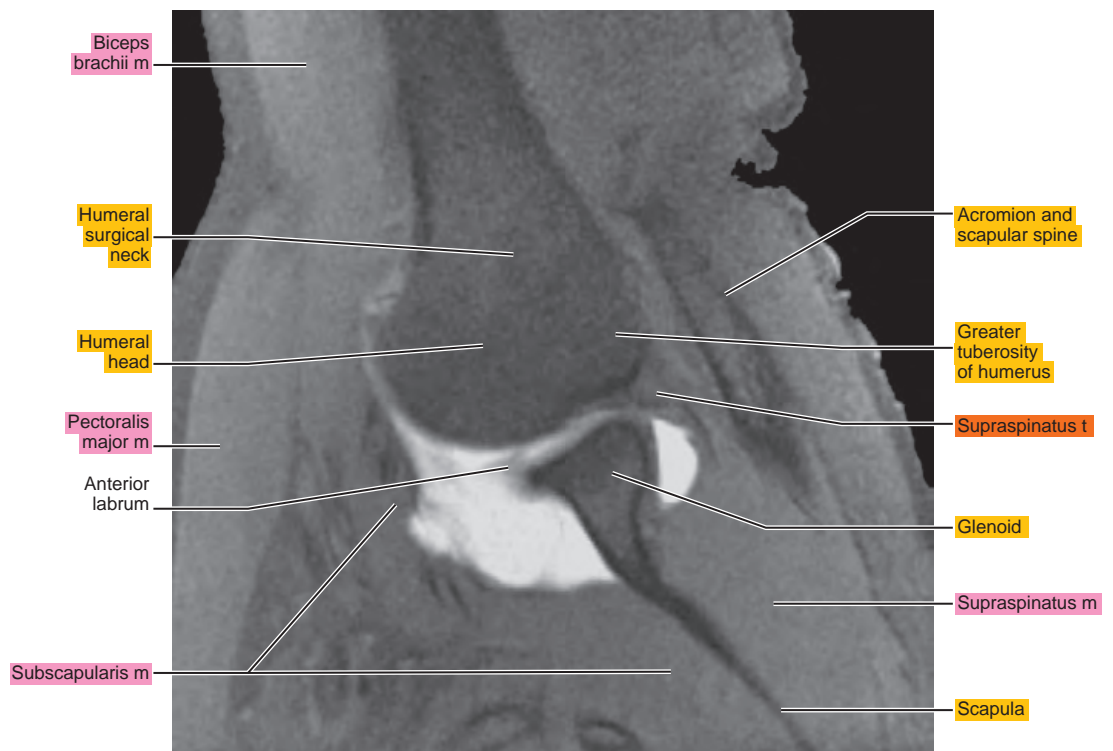
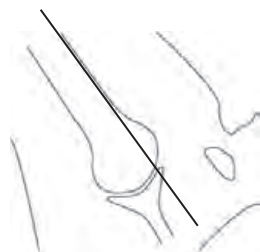

Figure 3.4.5

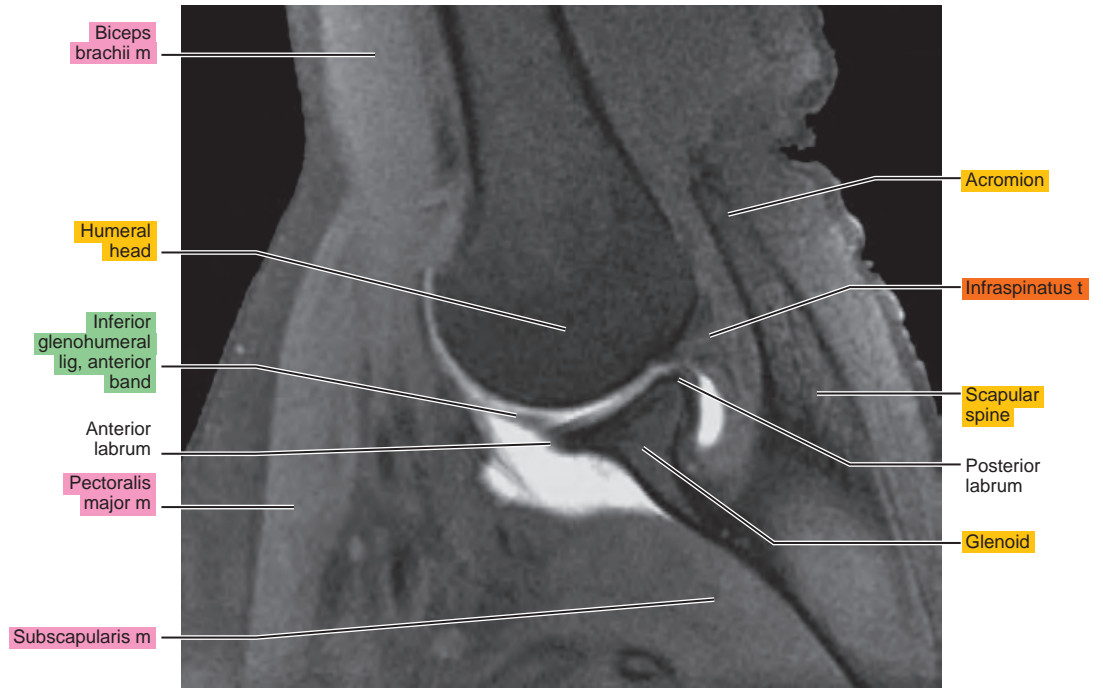
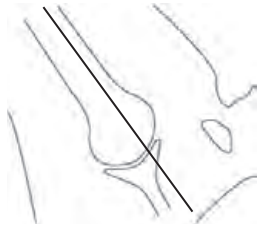


Figure 3.4.6

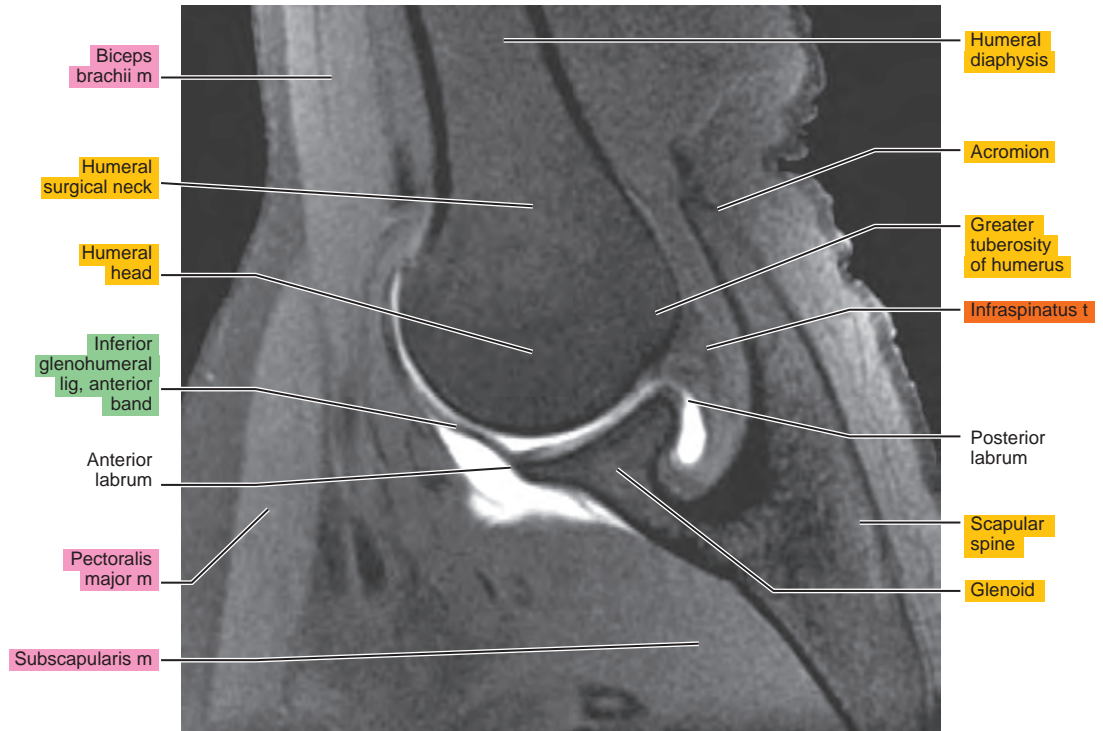



Figure 3.4.7

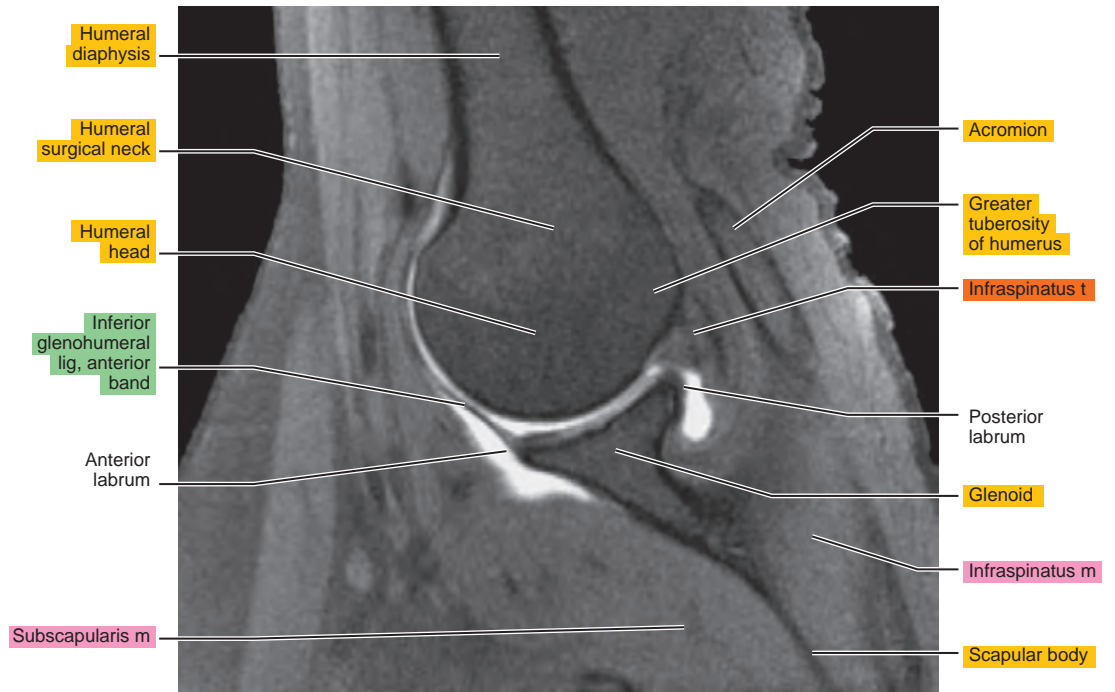
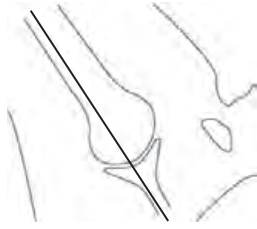


Figure 3.4.8

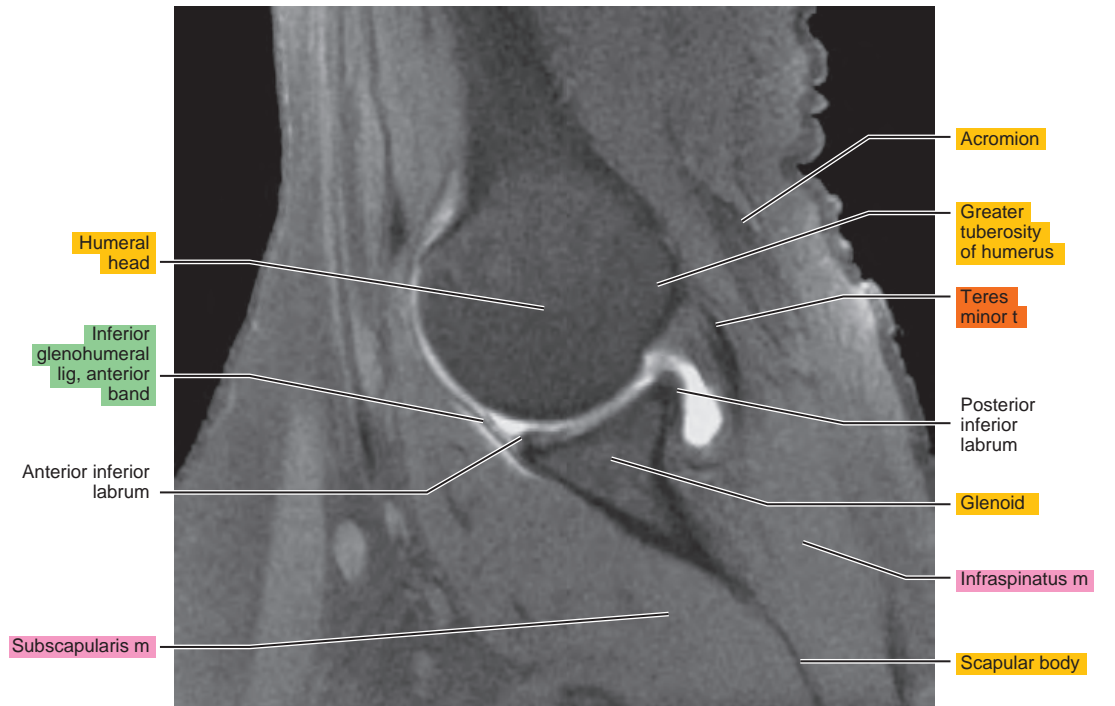
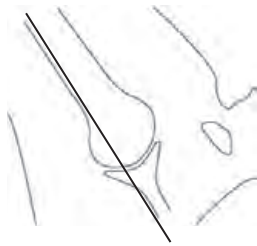


Figure 3.4.9

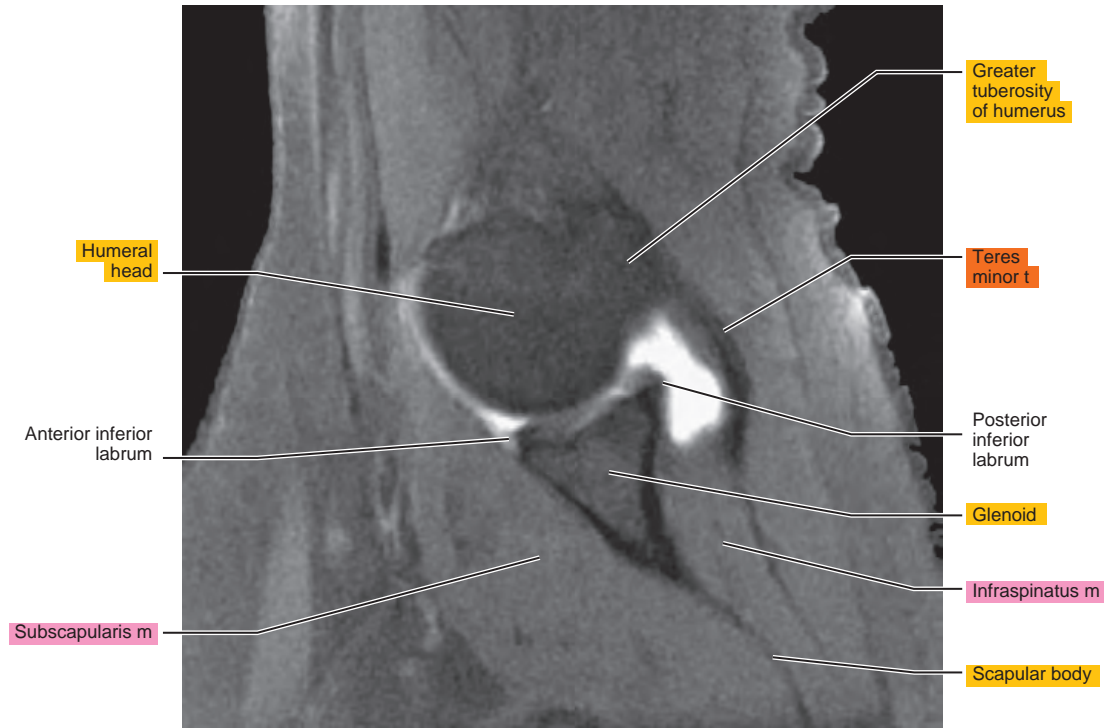



Figure 3.4.10

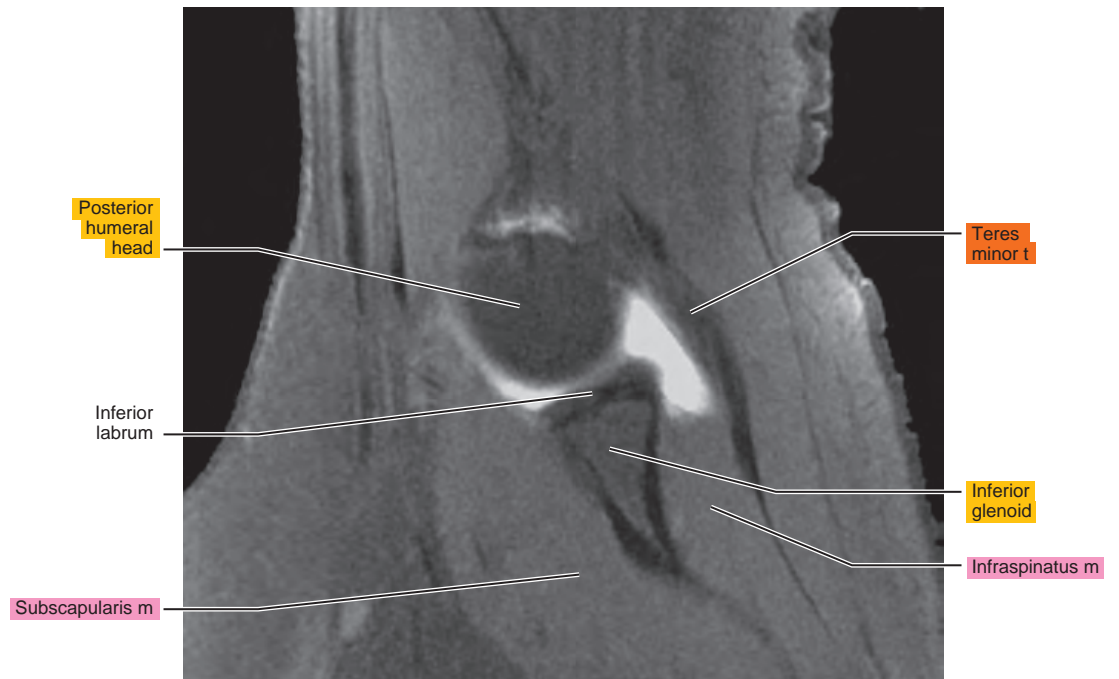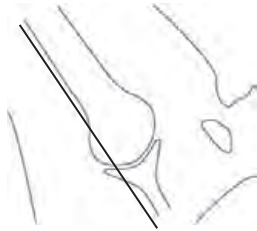
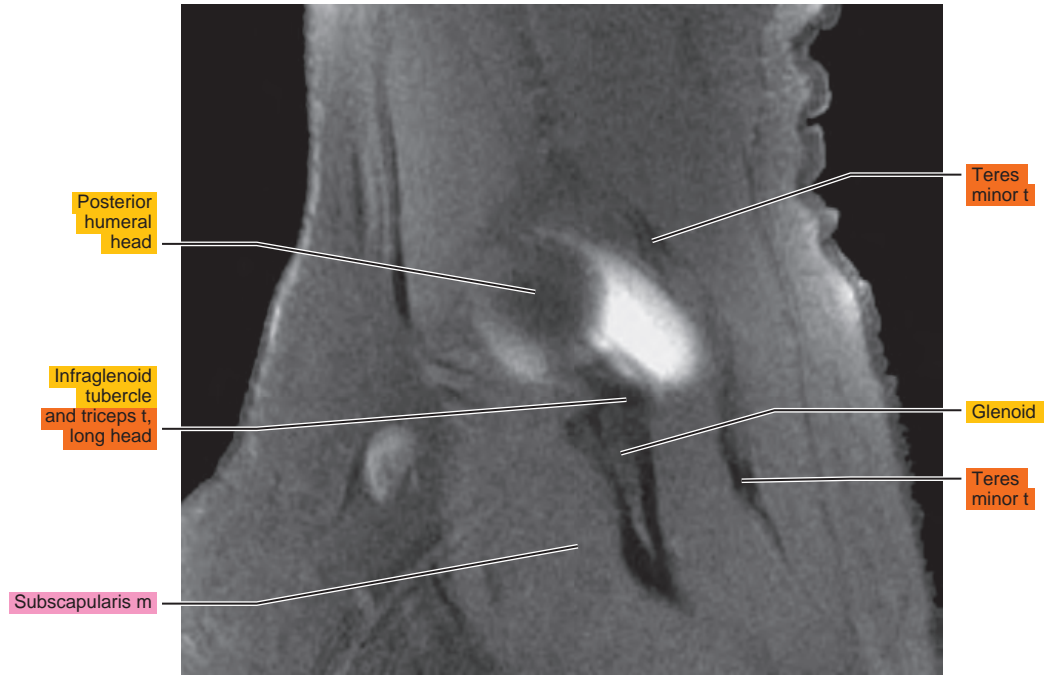
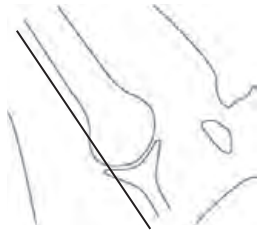


Figure 3.4.11



Chapter
4

MRI of the Arm

Table 4-1. Muscles of the Upper Arm

MUSCLE	ORIGIN	INSERTION	NERVE SUPPLY
Coracobrachialis	Coracoid process	Shaft of the humerus above the middle of the bone	Musculocutaneous (C5, C6, C7)
Biceps brachii	Short head, coracoid process; long head, supraglenoid tubercle; superior part of glenoid labrum	Tuberosity of the radius and by aponeurotic expansion to the fascia on the ulnar side of the forearm	Musculocutaneous (C5, C6)
Brachialis	Distal half of anterior surface of humerus	Coronoid process and tuberosity of the ulna	Musculocutaneous (C5, C6)
Triceps	Long head, infraglenoid tuberosity of the scapula; lateral head, from the posterior surface of the humerus; medial head, from the posterior surface of the humerus below the radial groove and dorsal surfaces of the medial and lateral intermuscular septa	Primary tendon inserts onto the olecranon process of the ulna and laterally, by expansion over the anconeus, into the dorsal fascia of the forearm	Radial (C6, C7, C8)

AXIAL

Figure 4.1.1

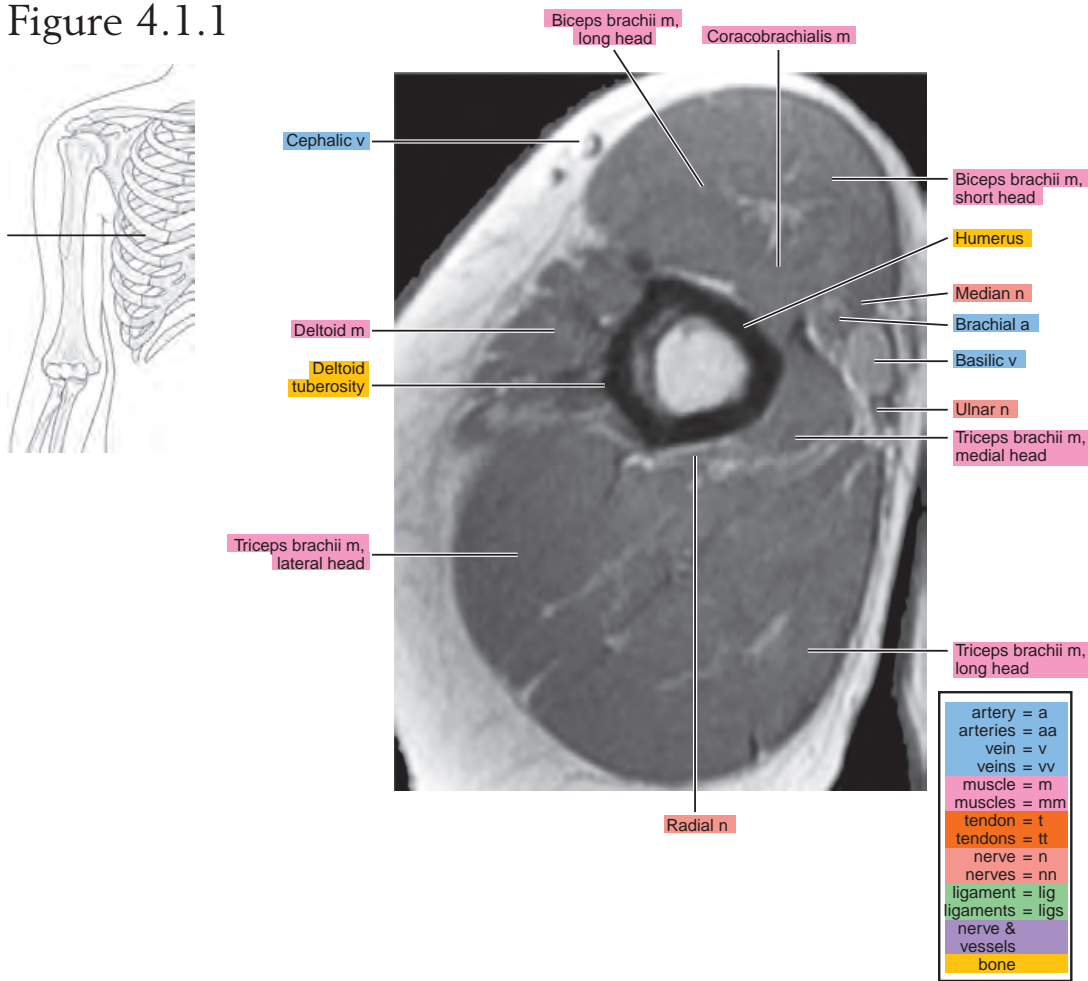


Figure 4.1.2

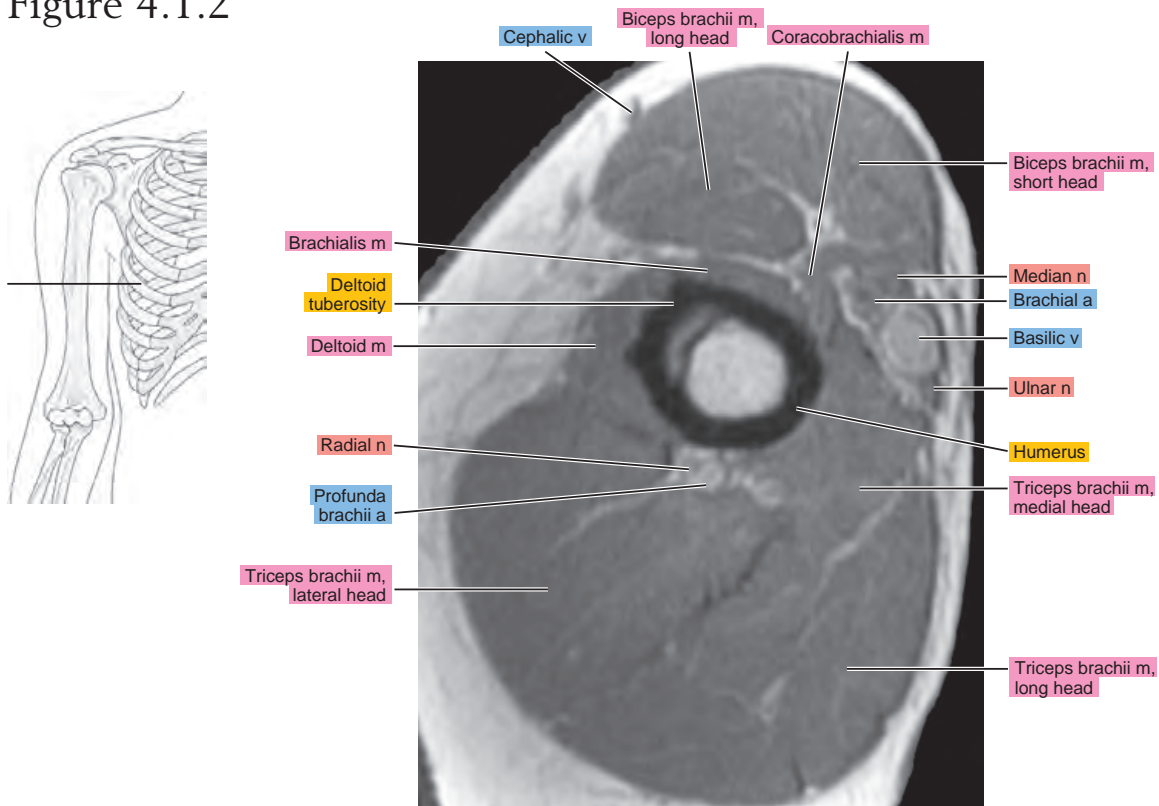


Figure 4.1.3

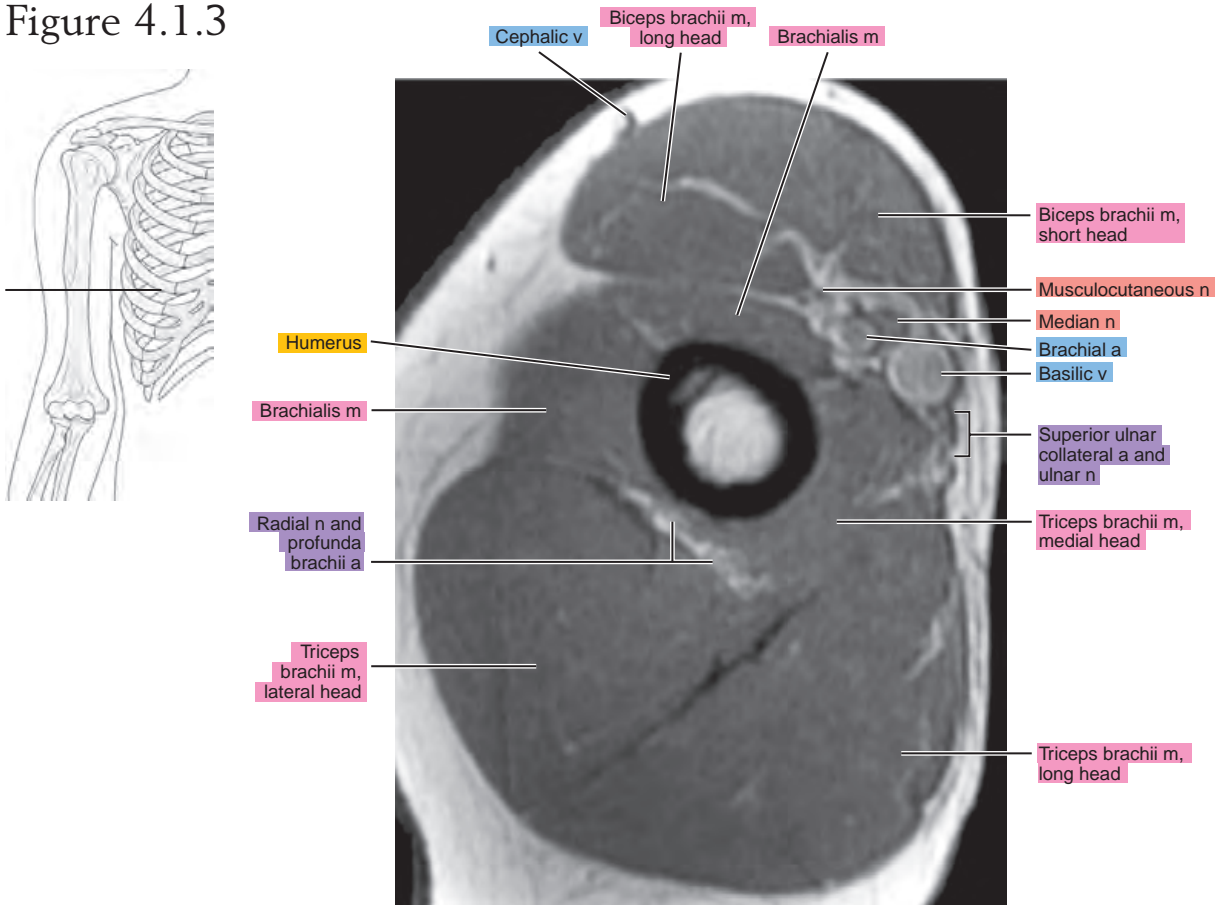


Figure 4.1.4

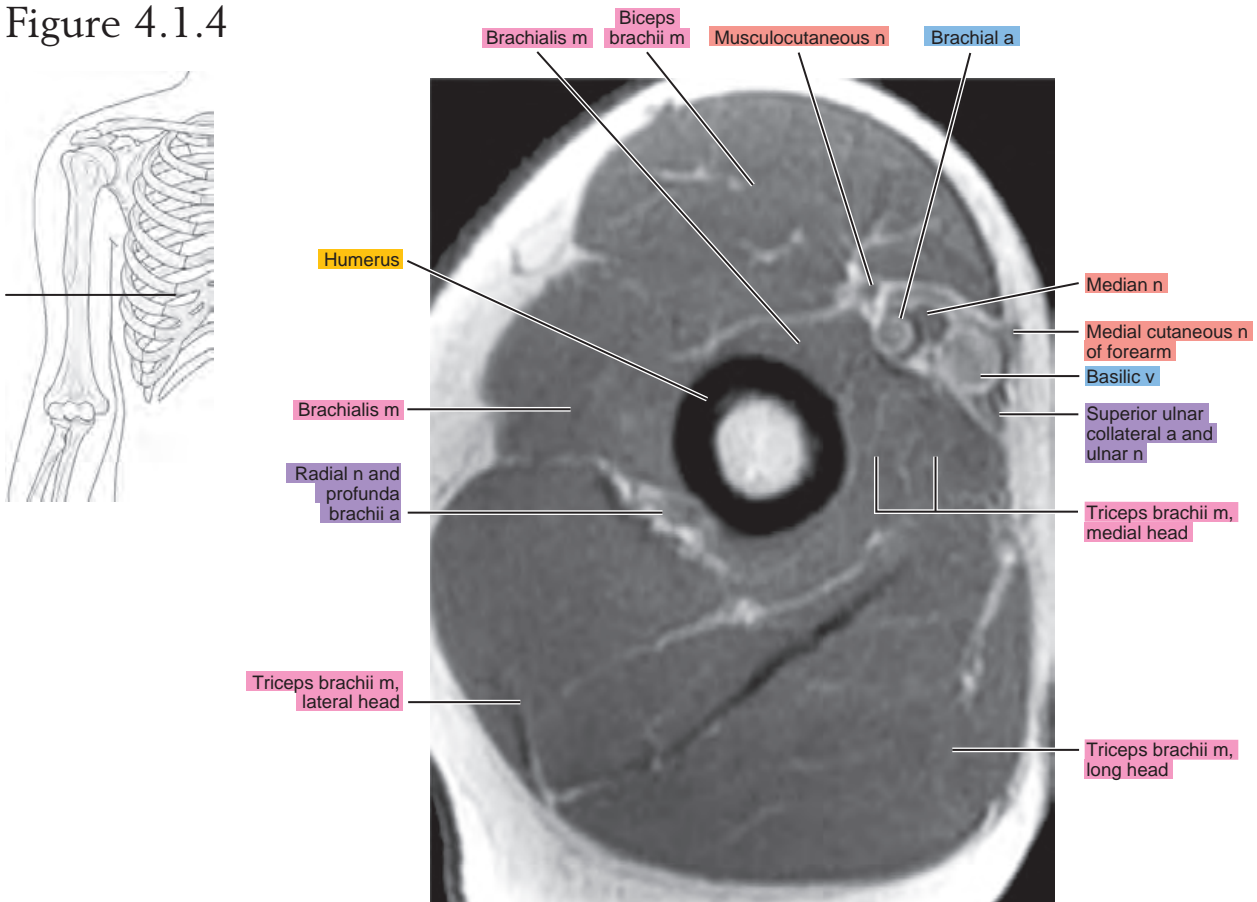


Figure 4.1.5

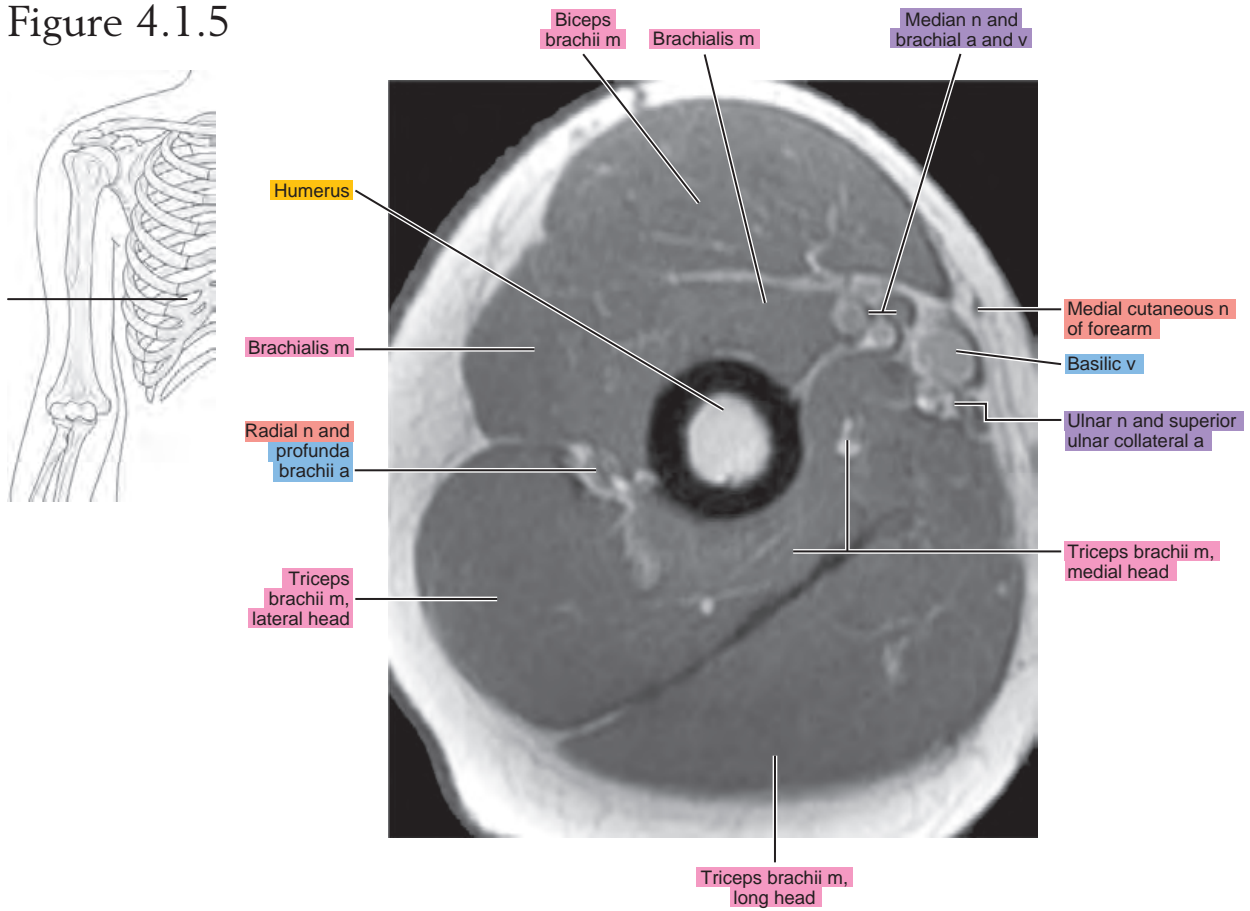


Figure 4.1.6

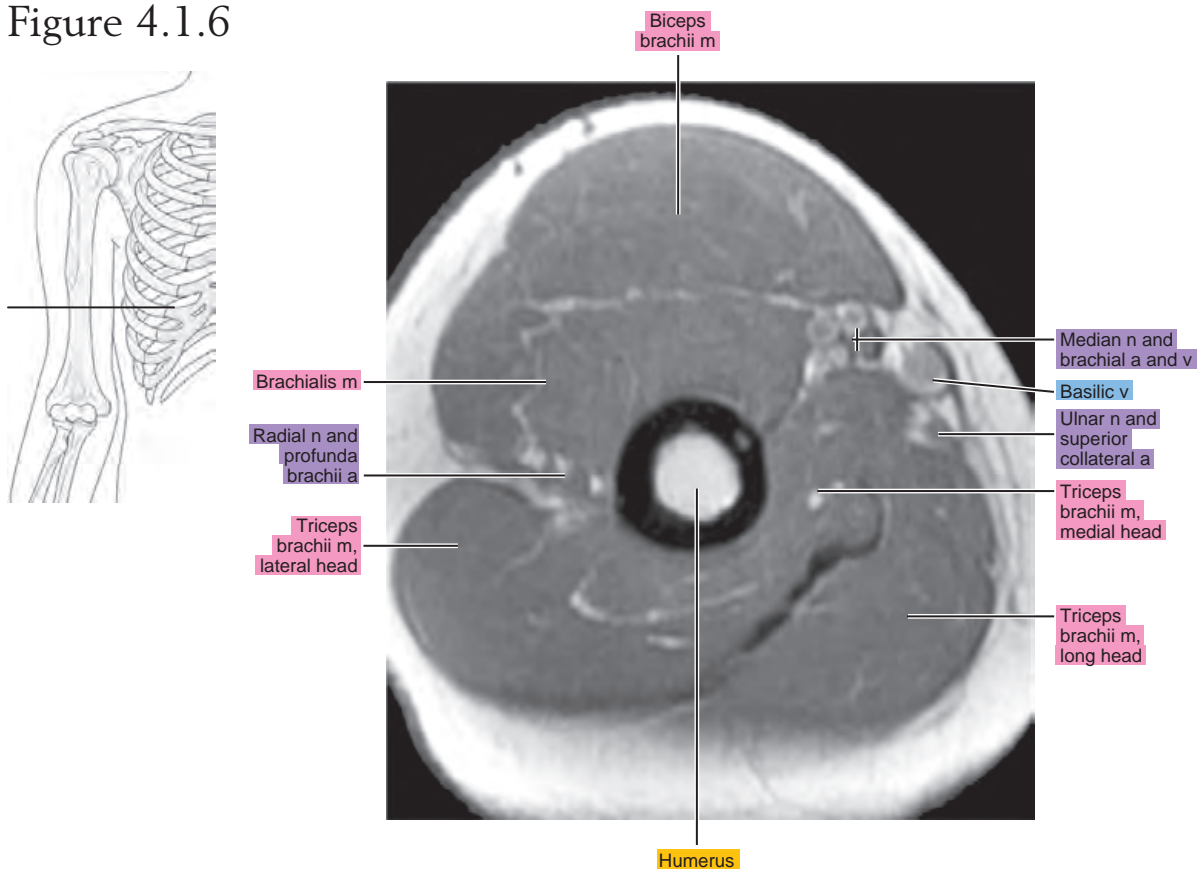


Figure 4.1.7

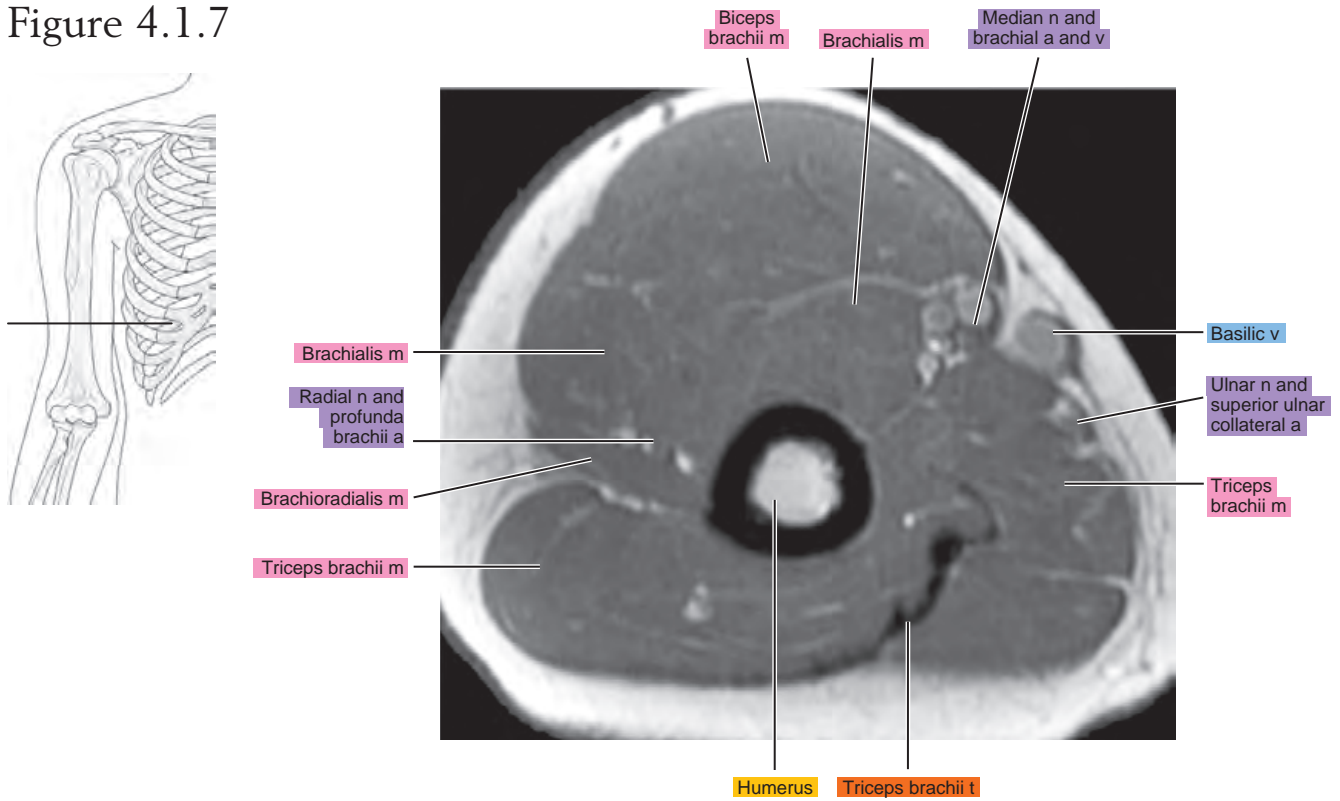


Figure 4.1.8

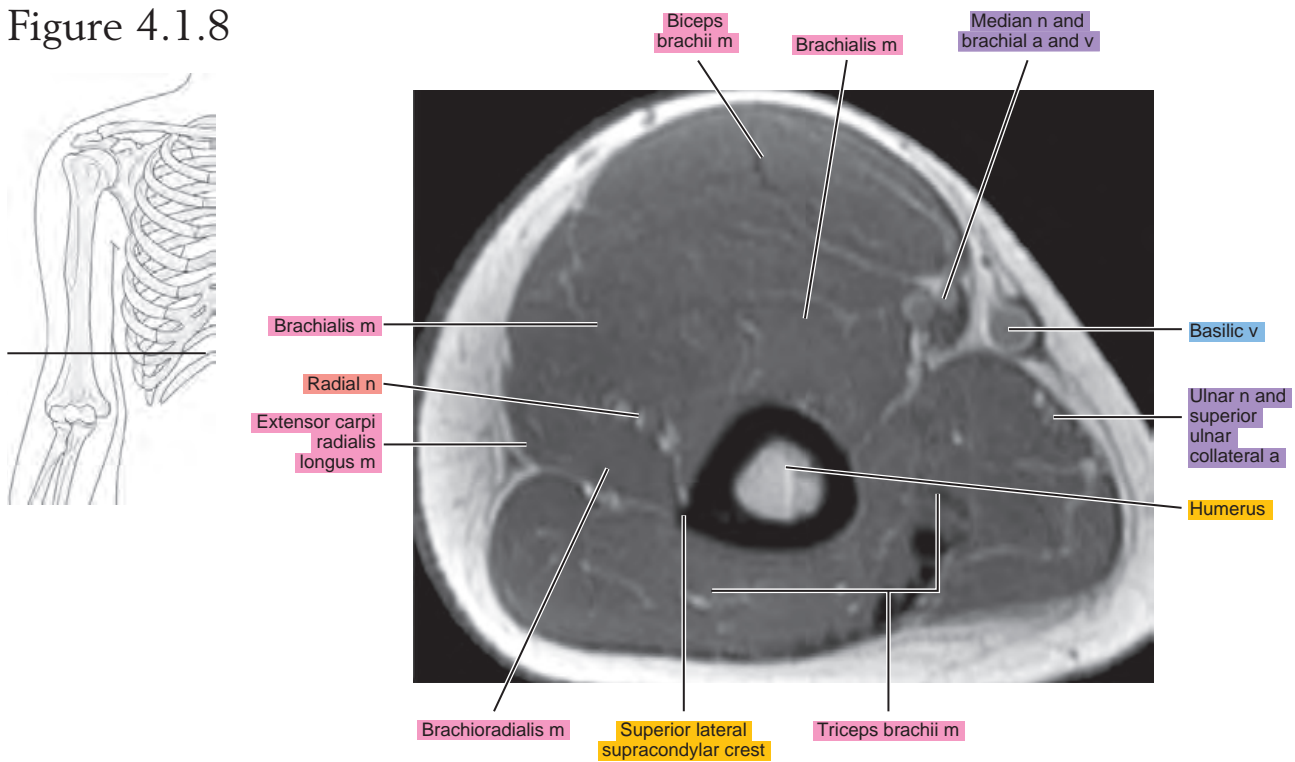


Figure 4.1.9

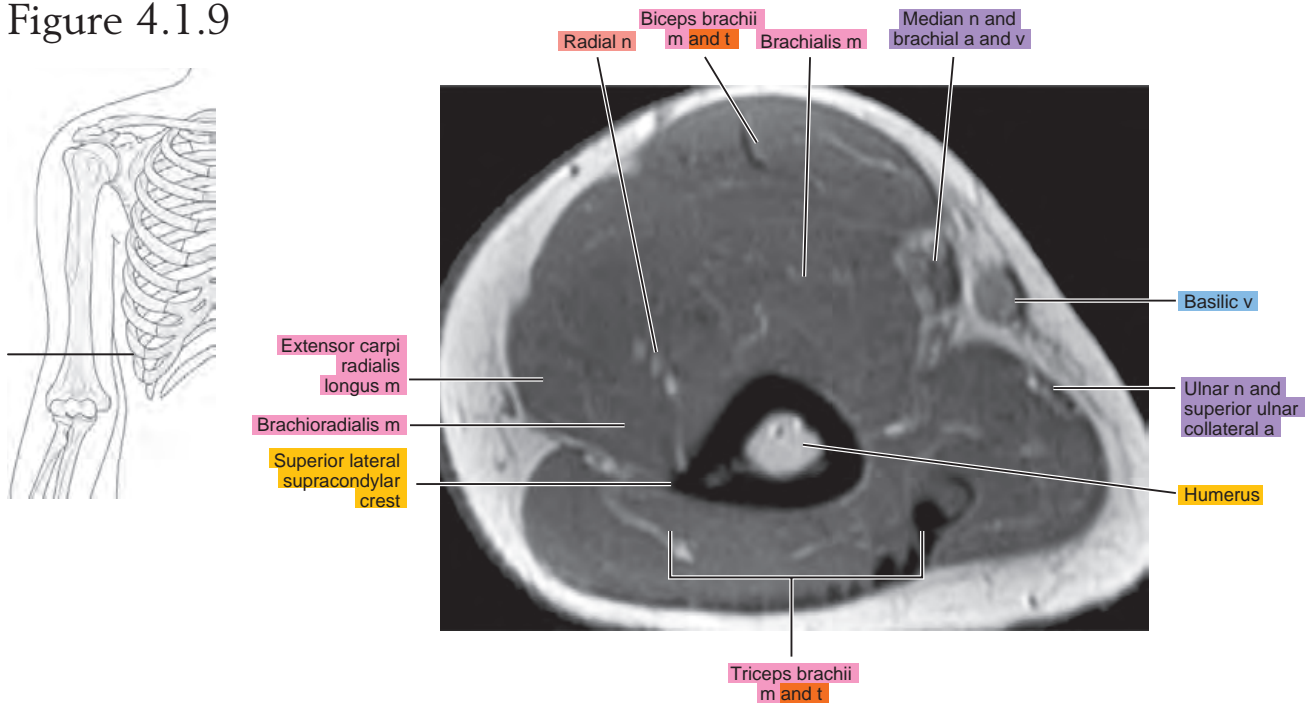


Figure 4.1.10

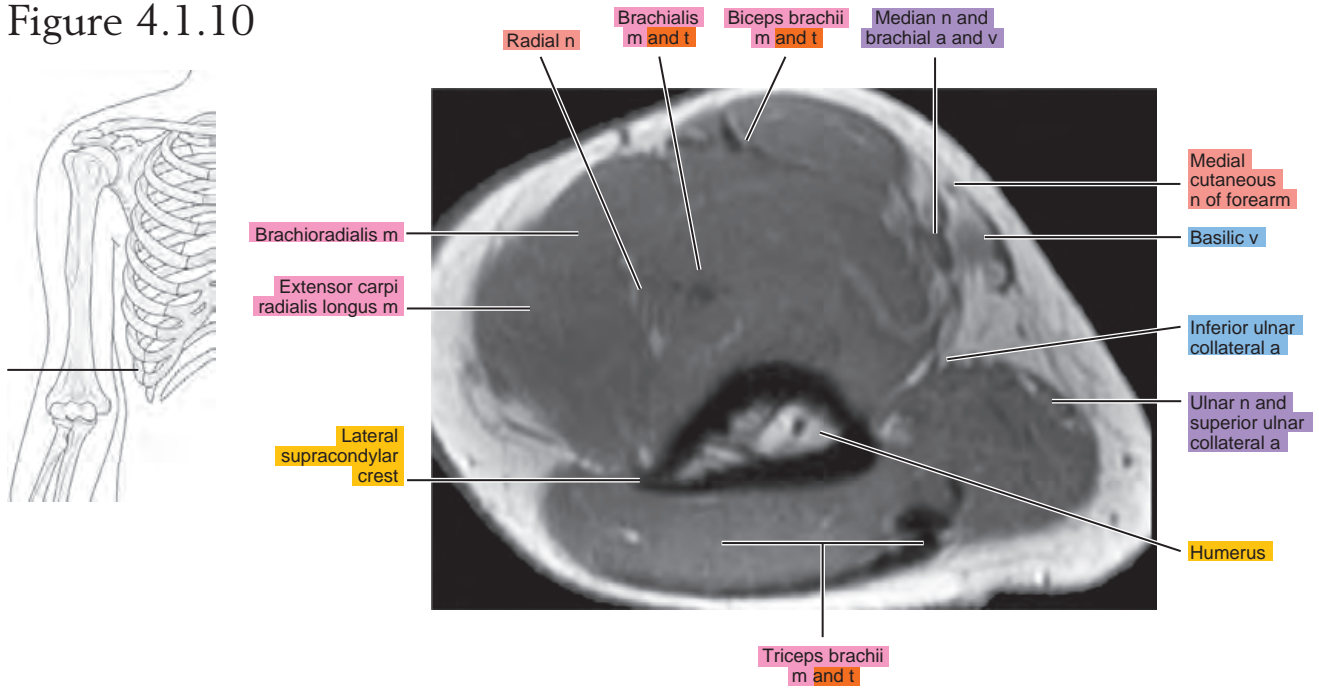
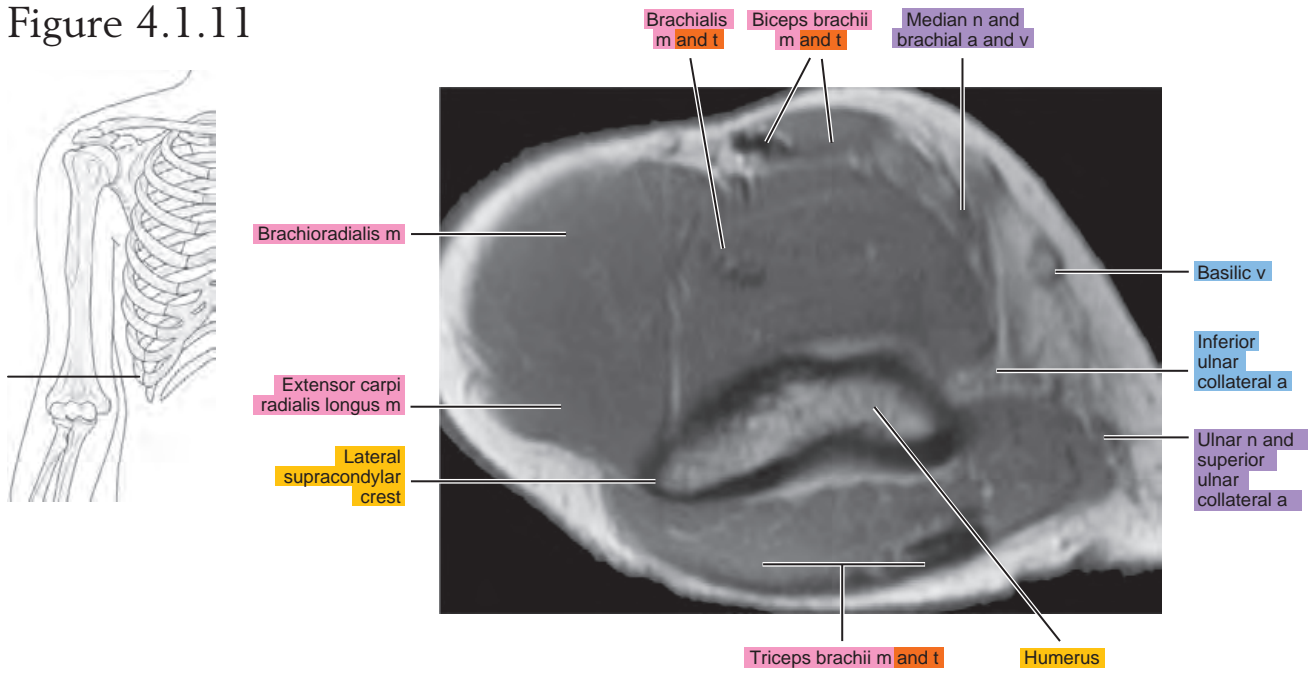


Figure 4.1.11



SAGITTAL

Figure 4.2.1

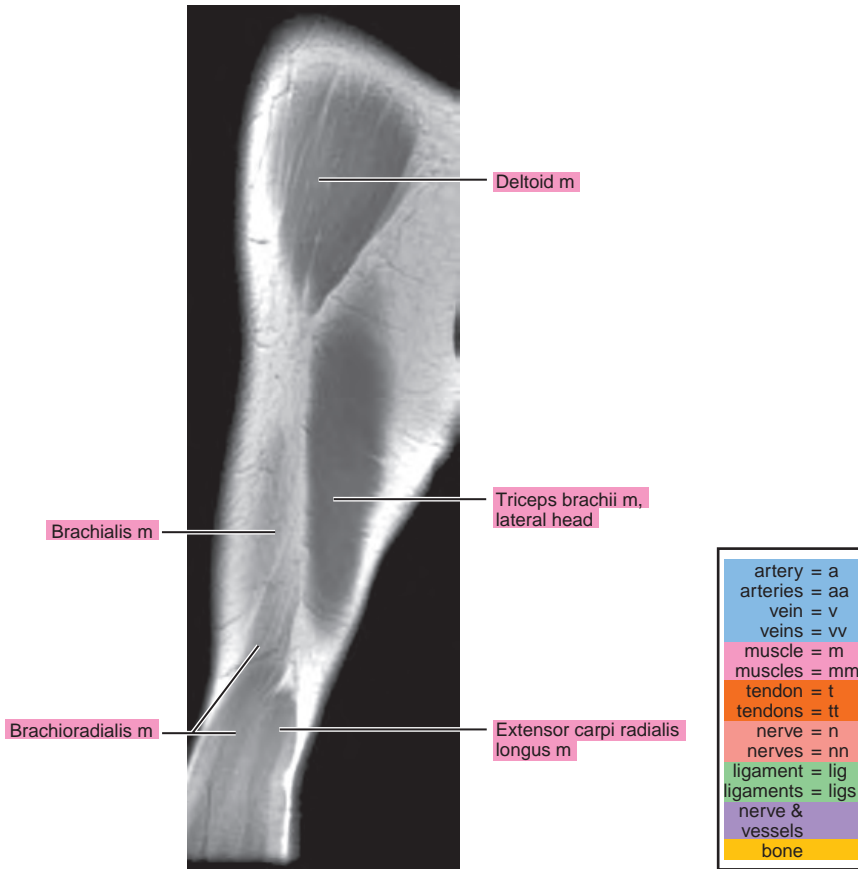
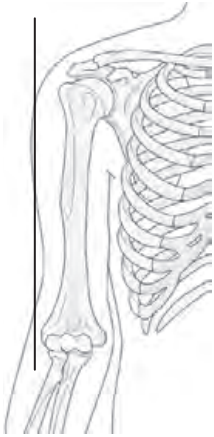


Figure 4.2.2

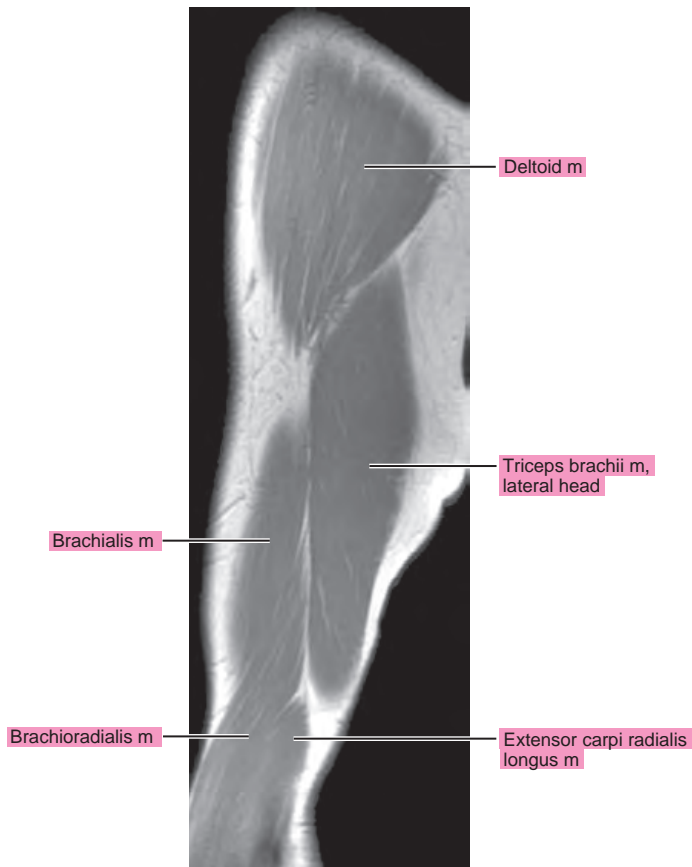
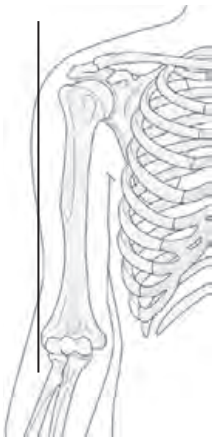


Figure 4.2.3

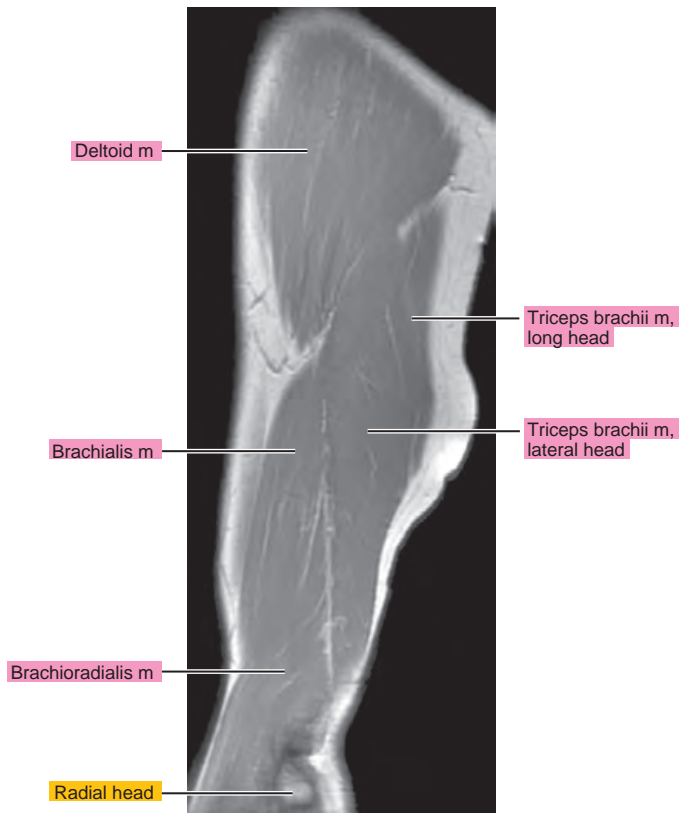
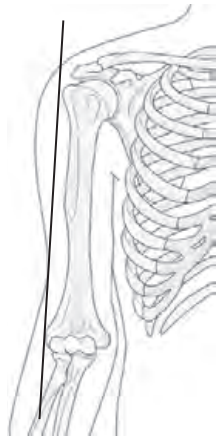


Figure 4.2.4

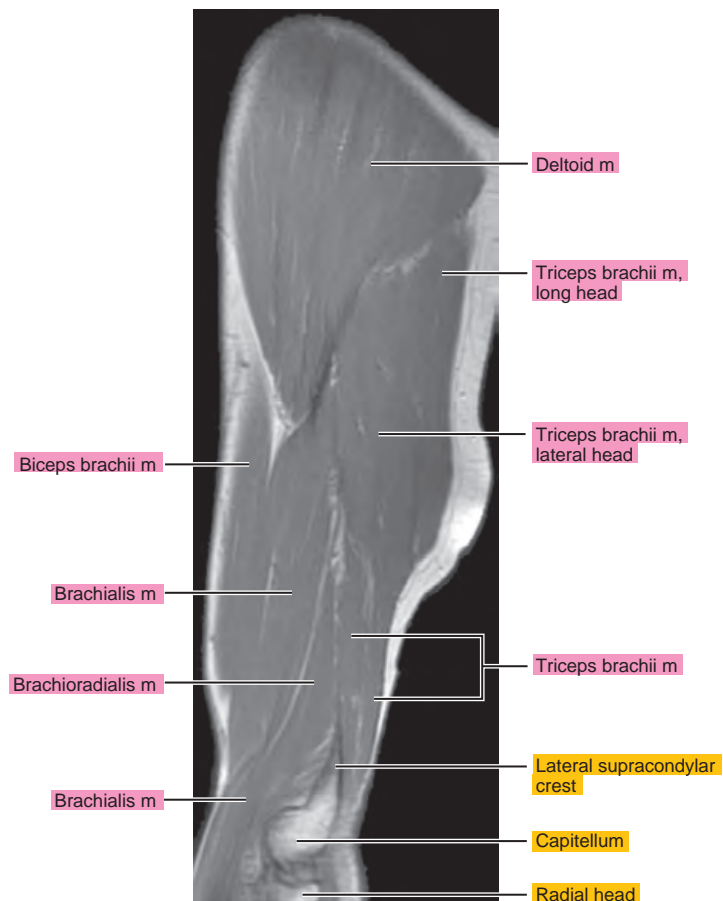
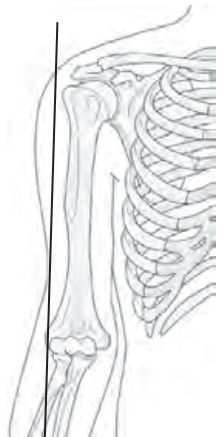


Figure 4.2.5

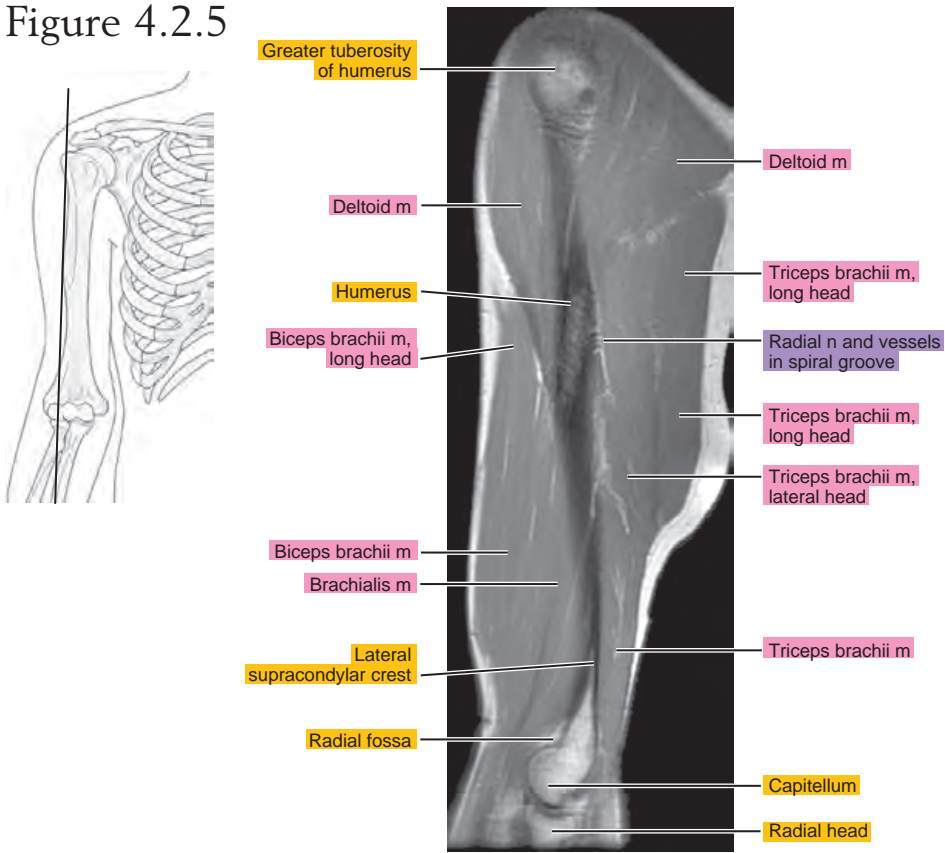


Figure 4.2.6

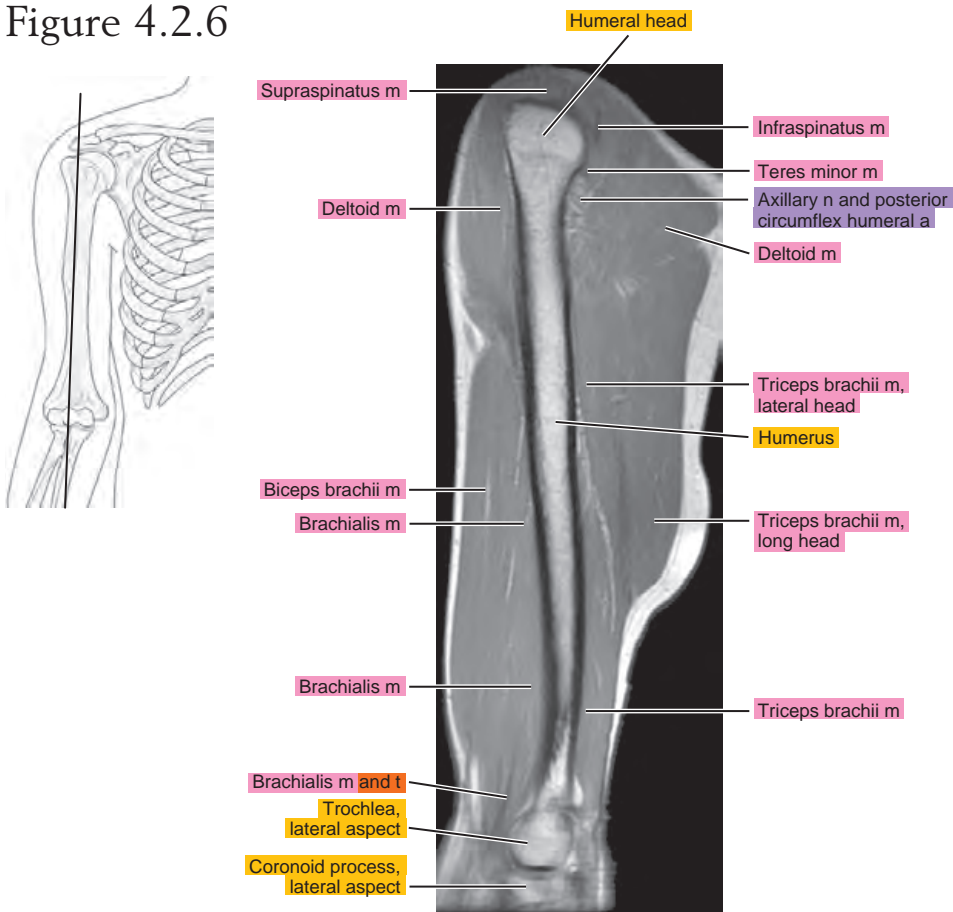


Figure 4.2.7

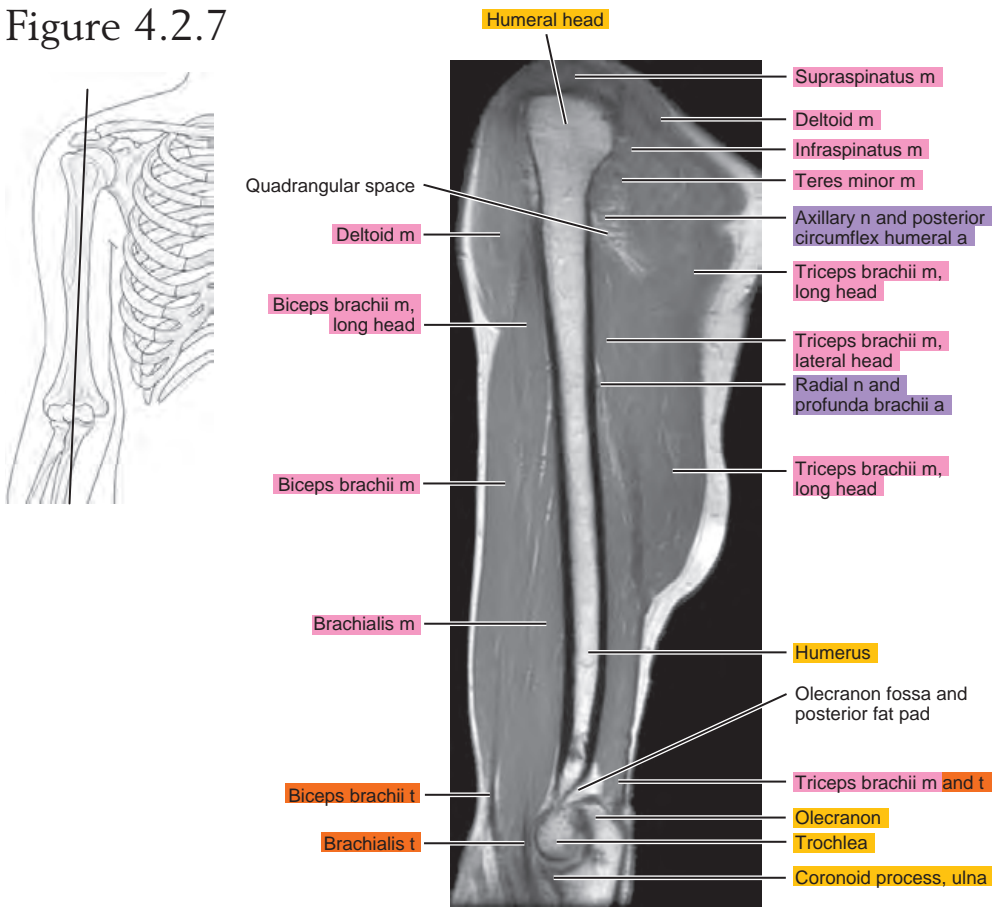


Figure 4.2.8

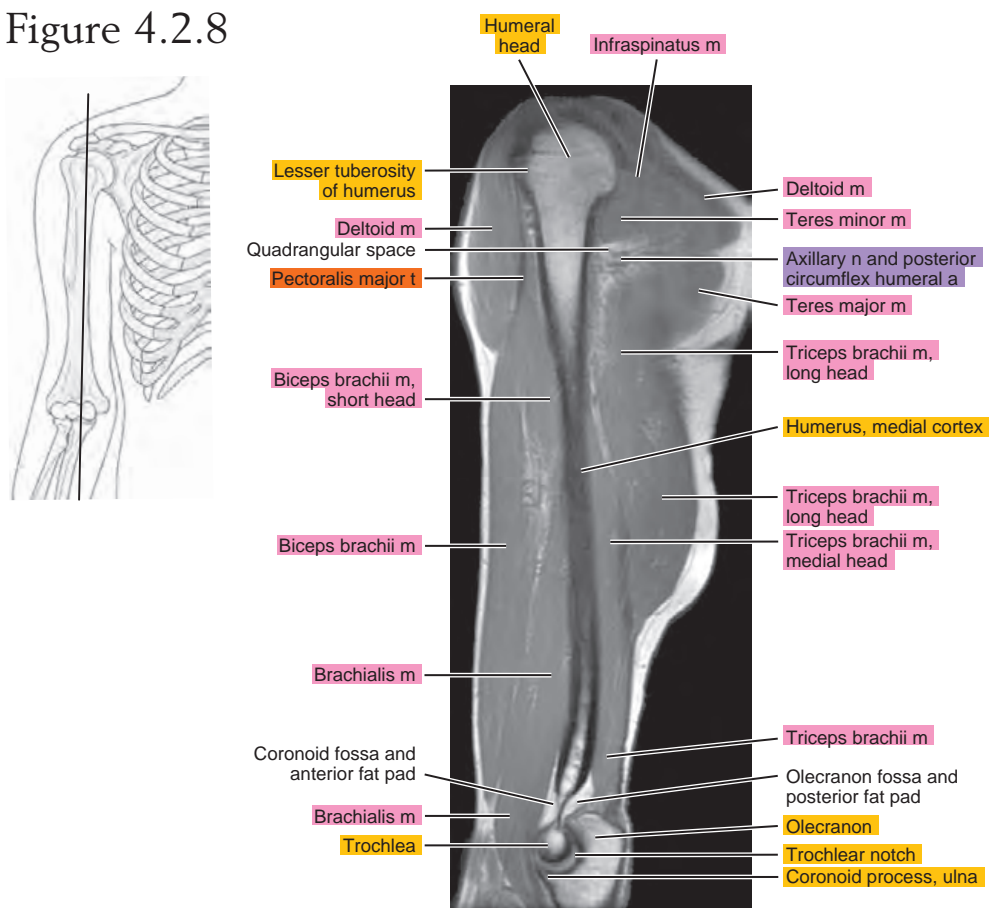


Figure 4.2.9

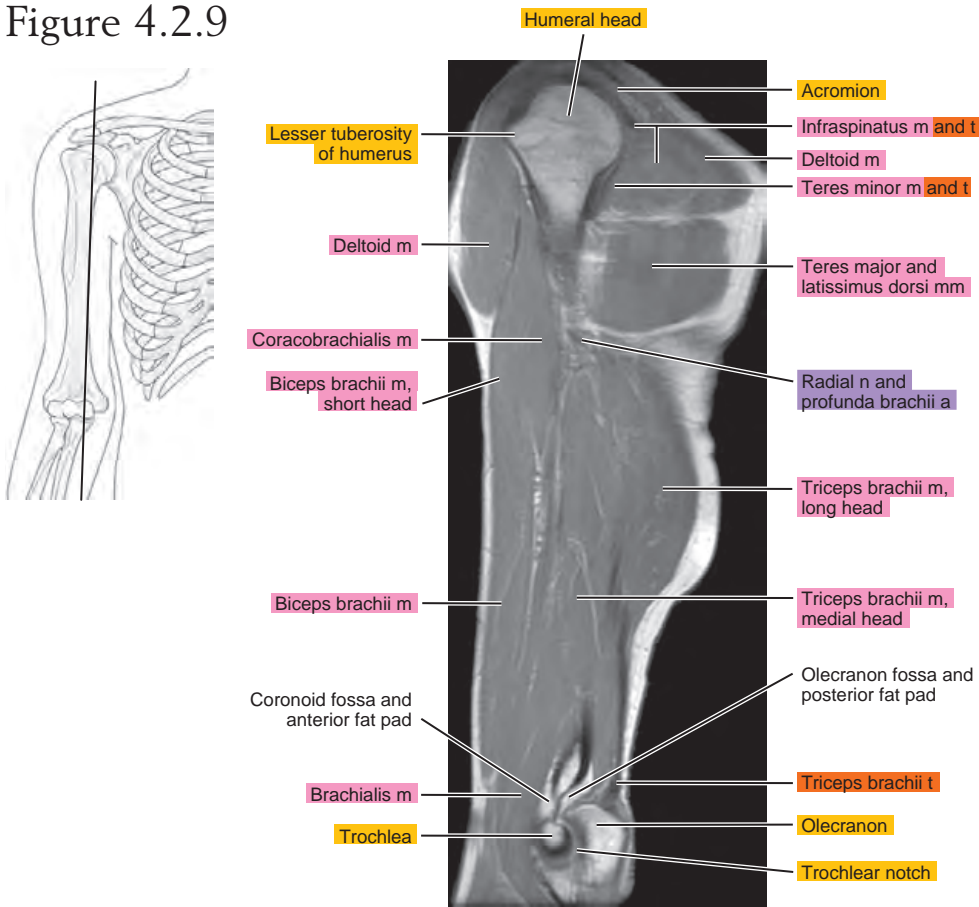


Figure 4.2.10

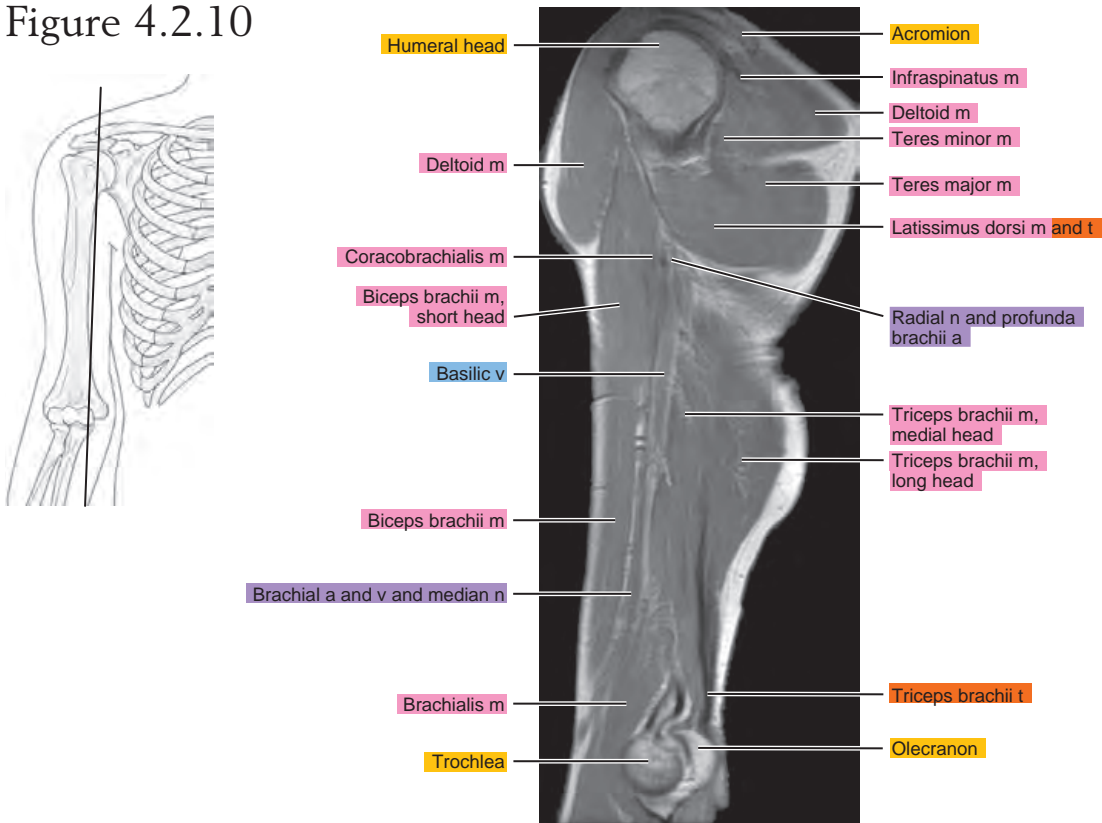


Figure 4.2.11

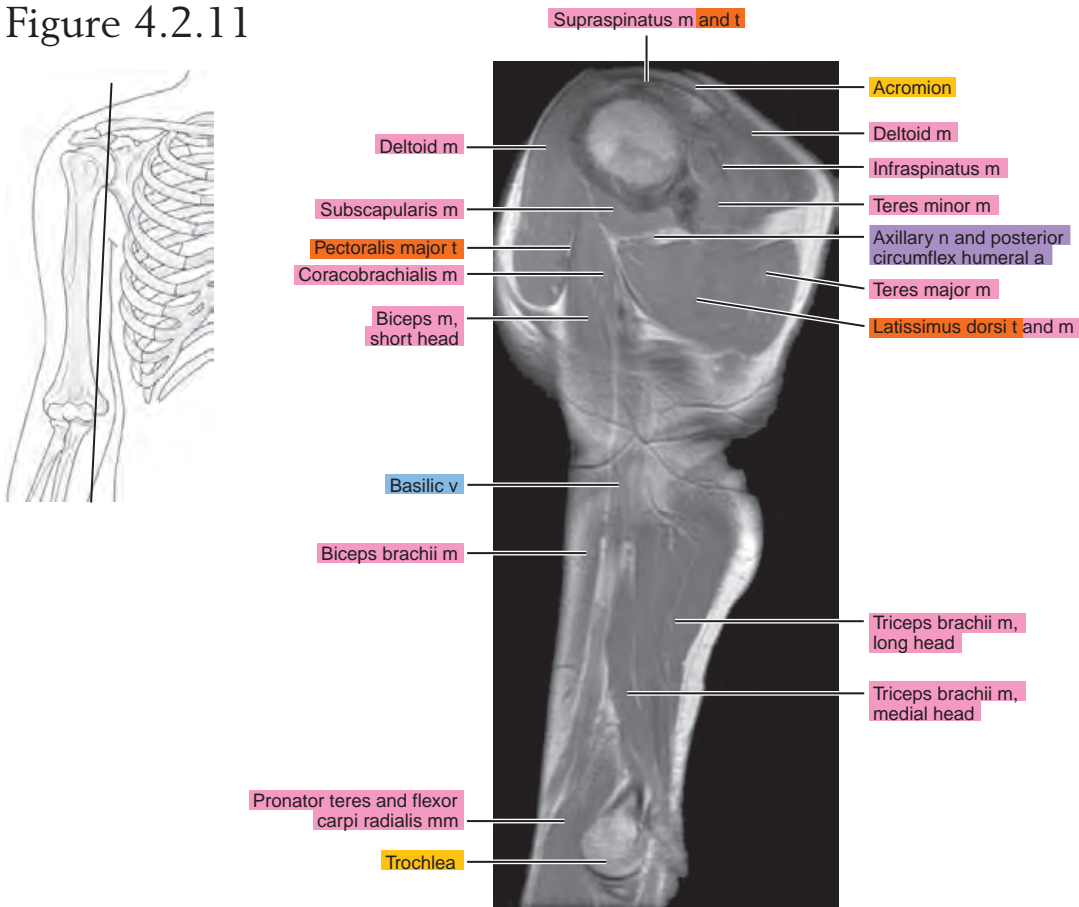


Figure 4.2.12

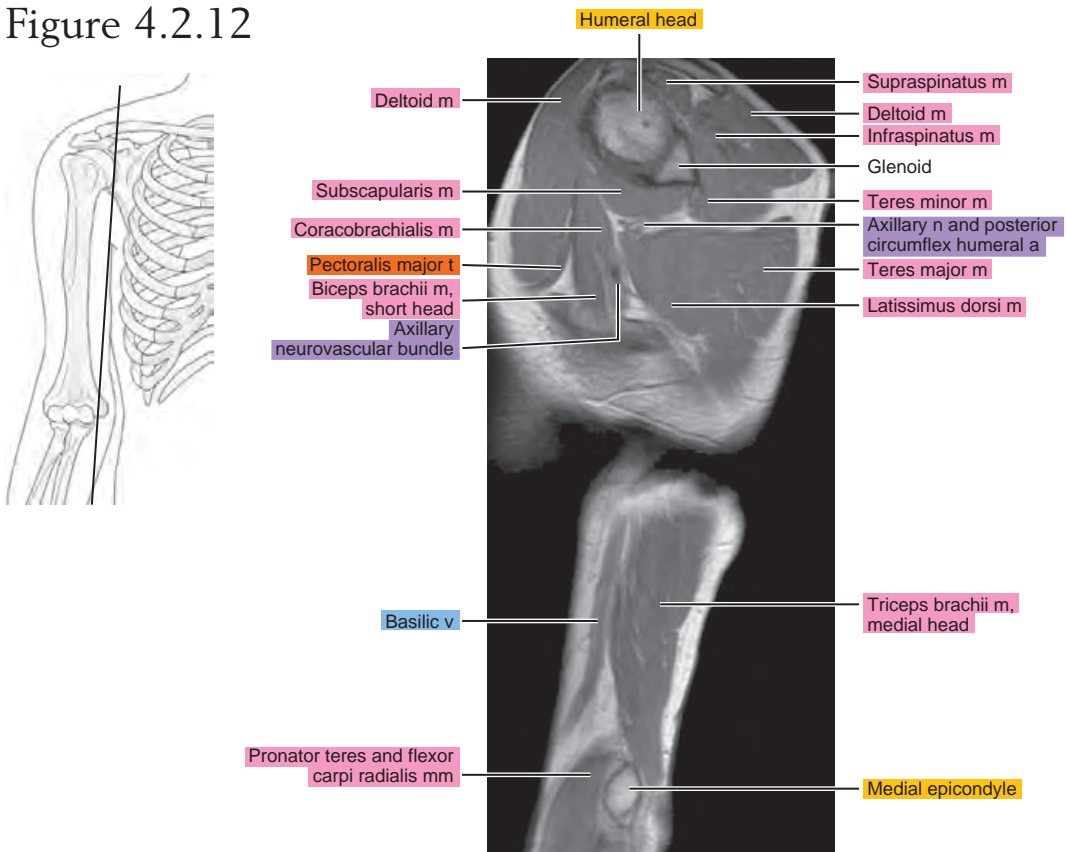
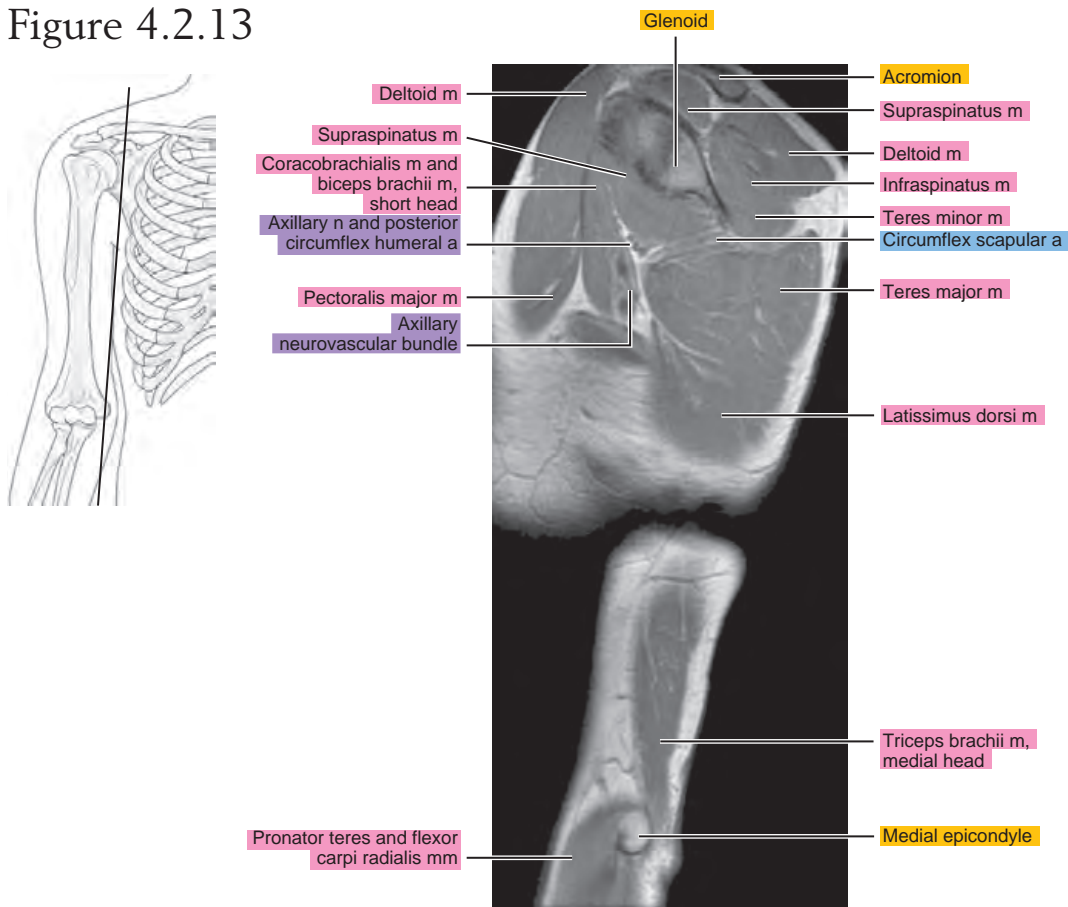


Figure 4.2.13



CORONAL

Figure 4.3.1

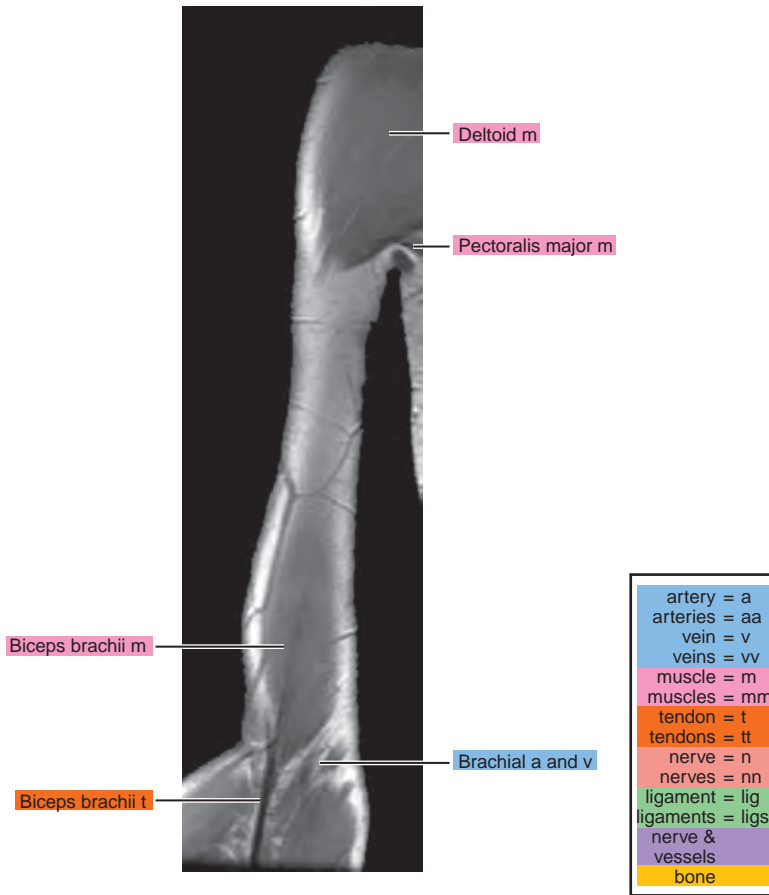
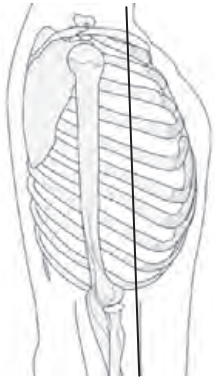


Figure 4.3.2

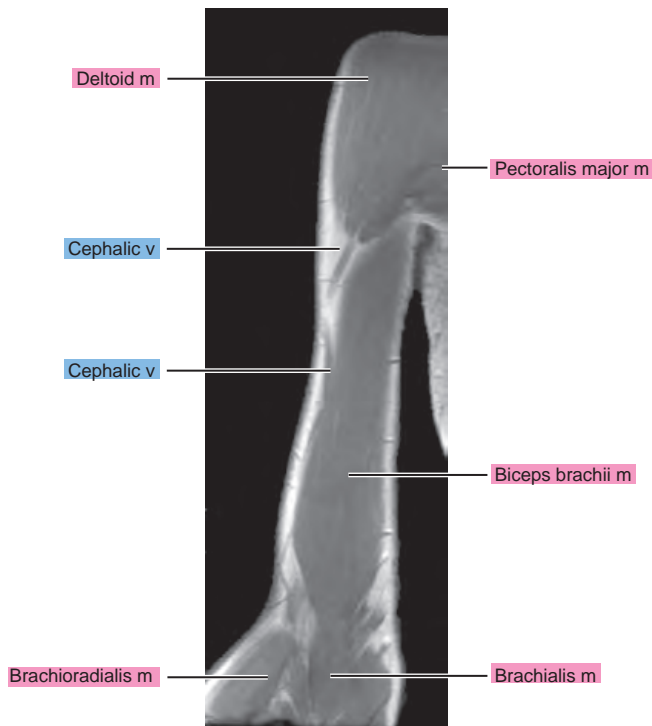
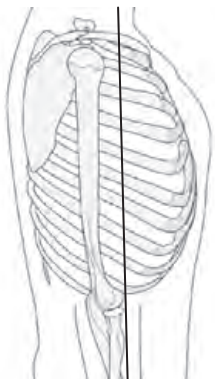


Figure 4.3.3

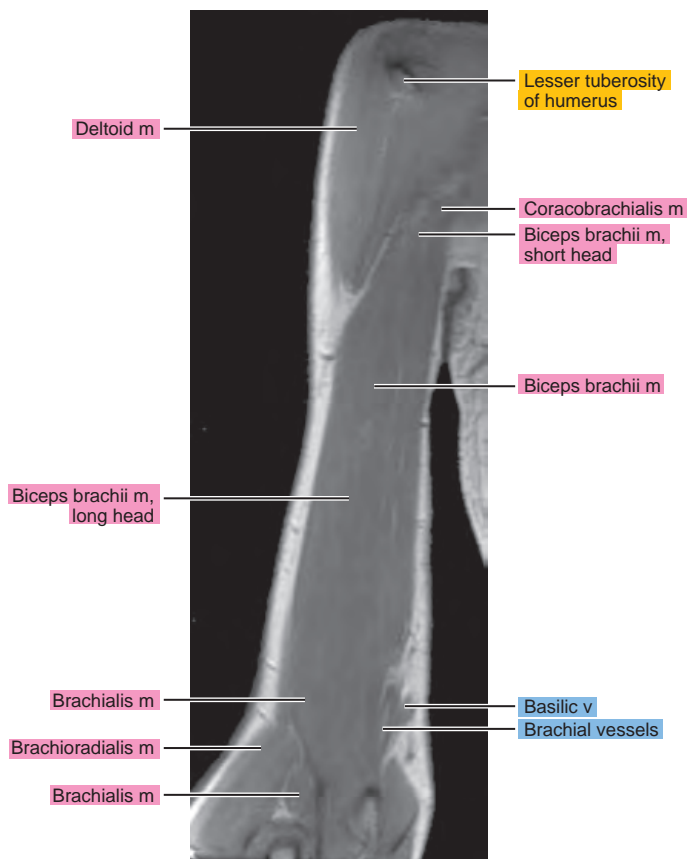
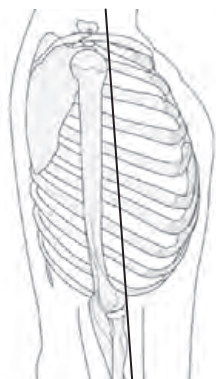


Figure 4.3.4

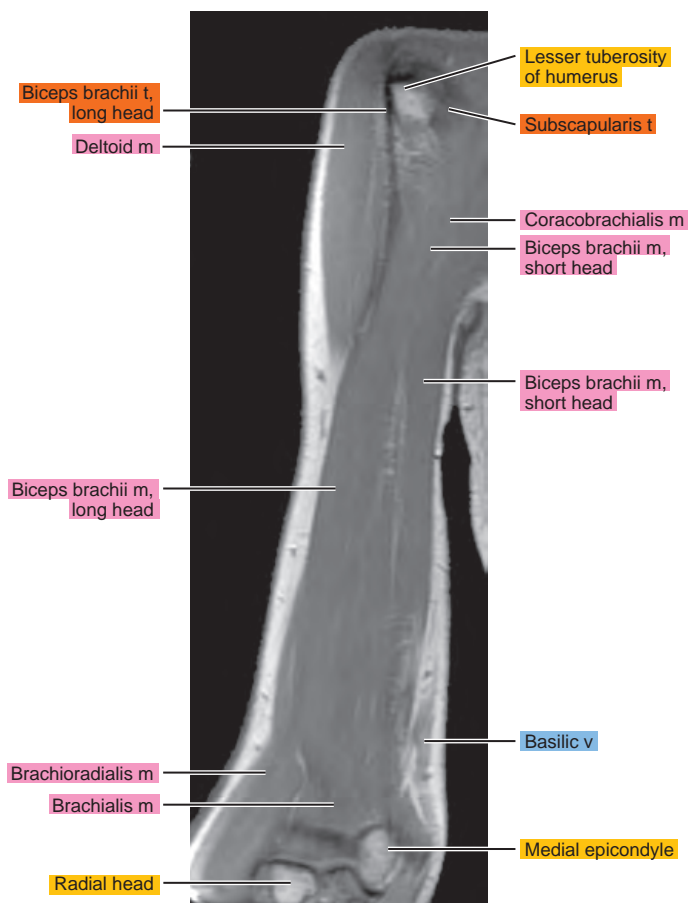
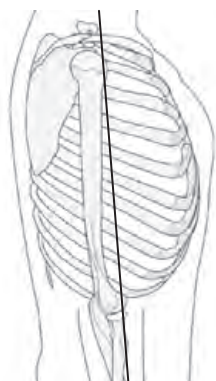


Figure 4.3.5

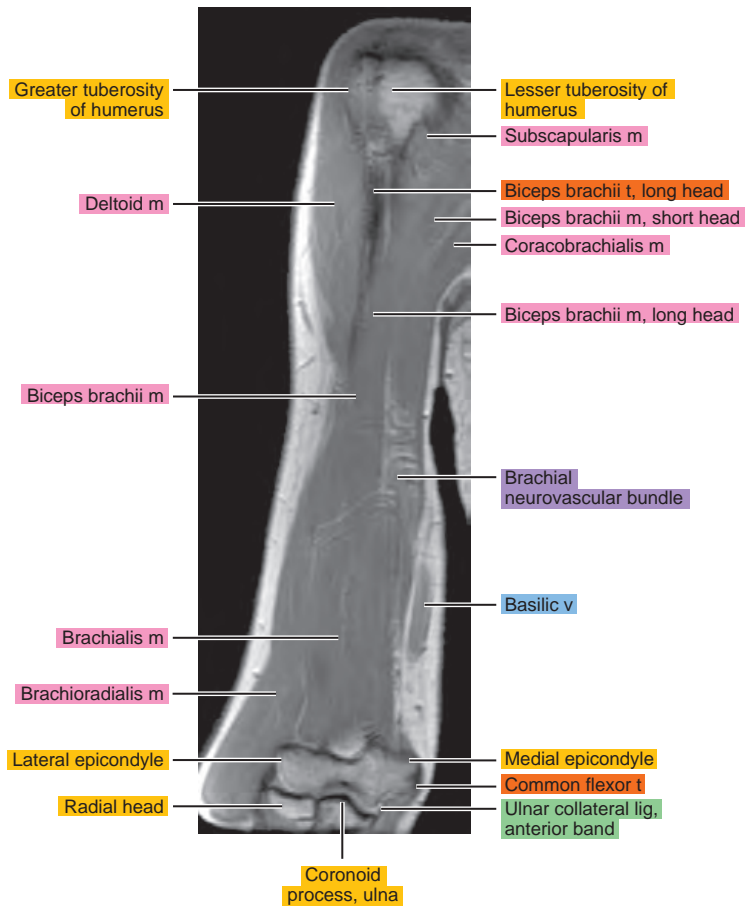
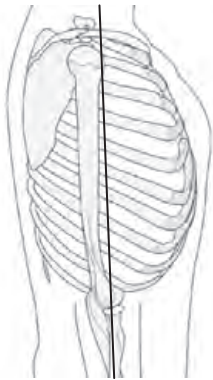


Figure 4.3.6

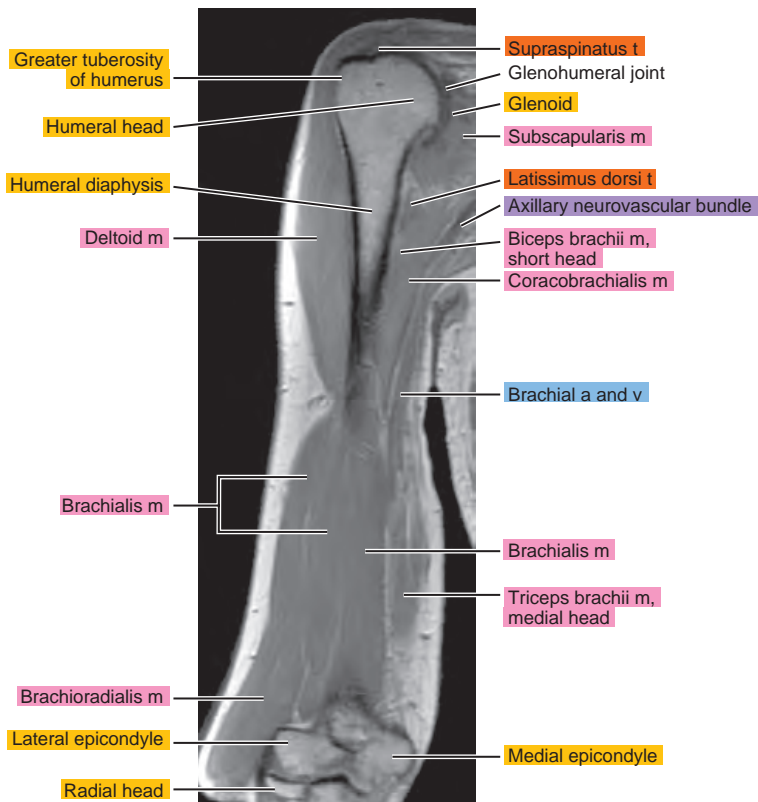
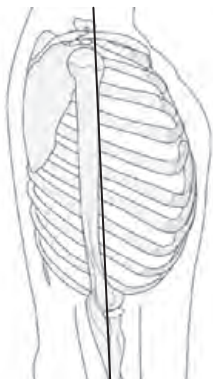


Figure 4.3.7

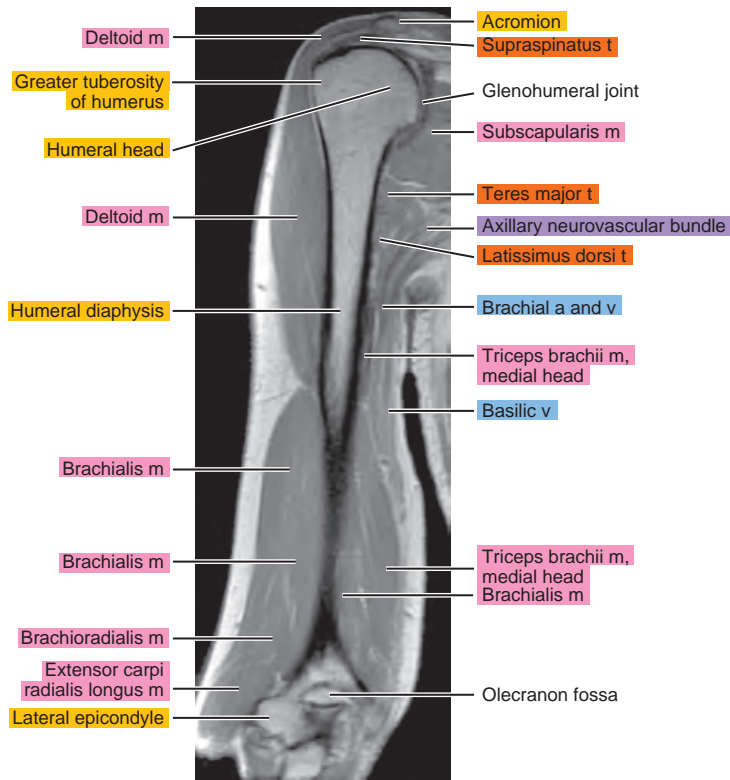
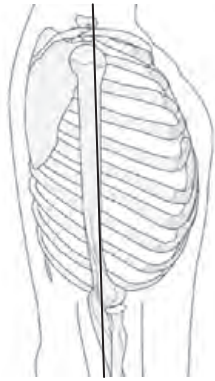


Figure 4.3.8

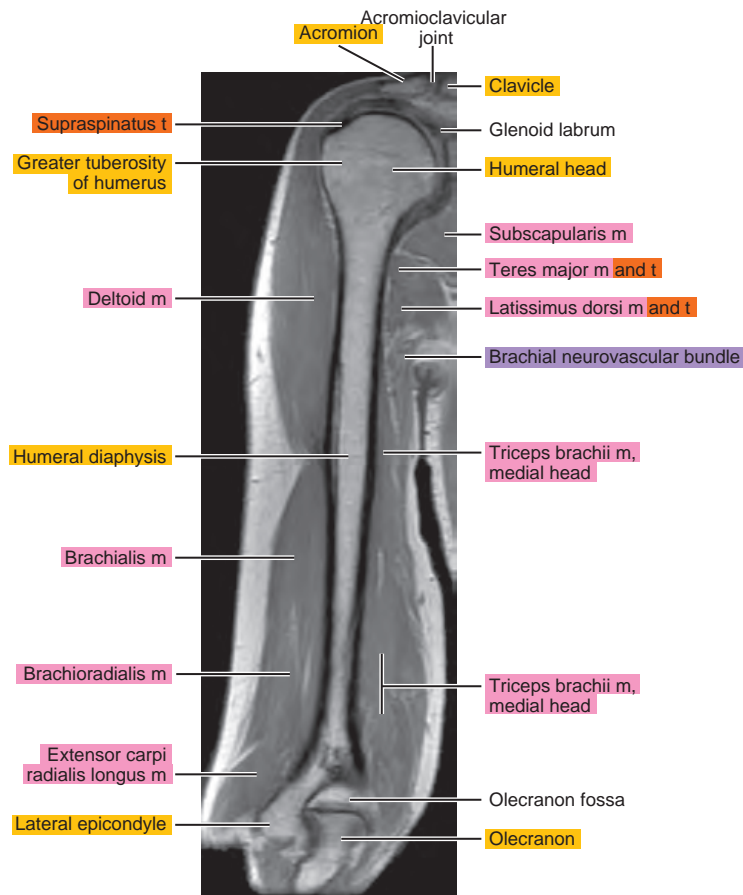
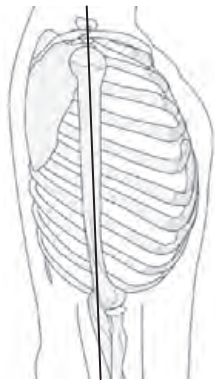


Figure 4.3.9

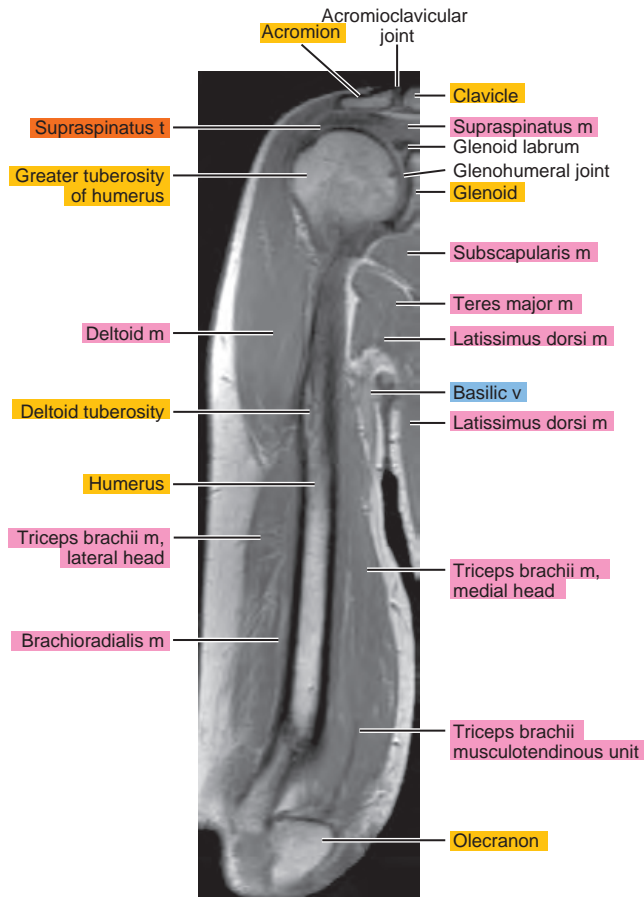
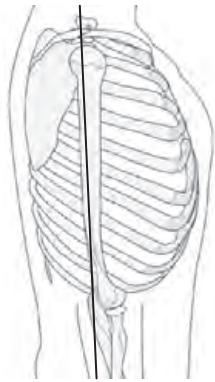


Figure 4.3.10

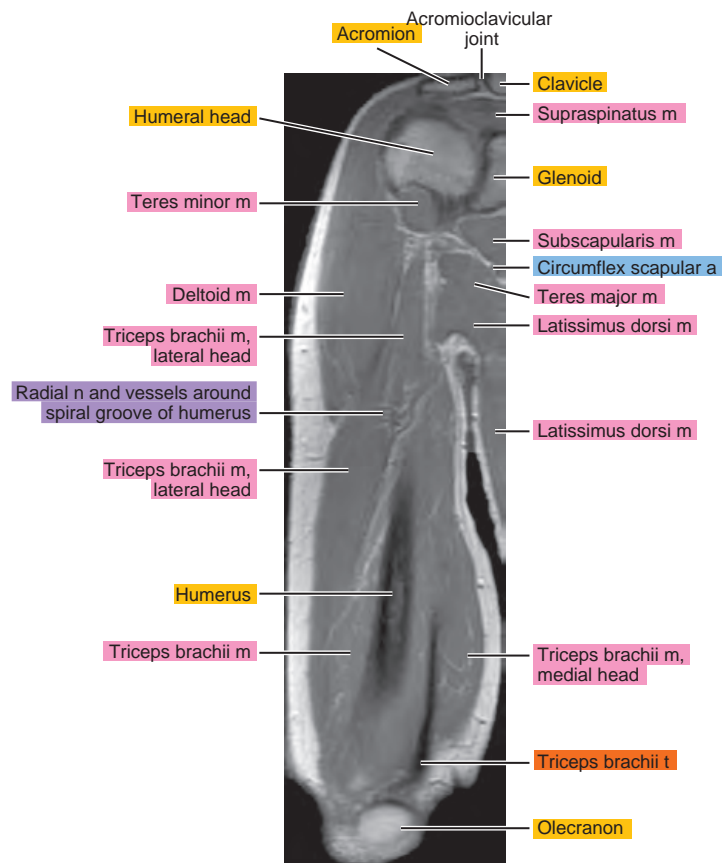
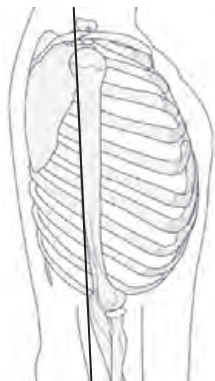


Figure 4.3.11

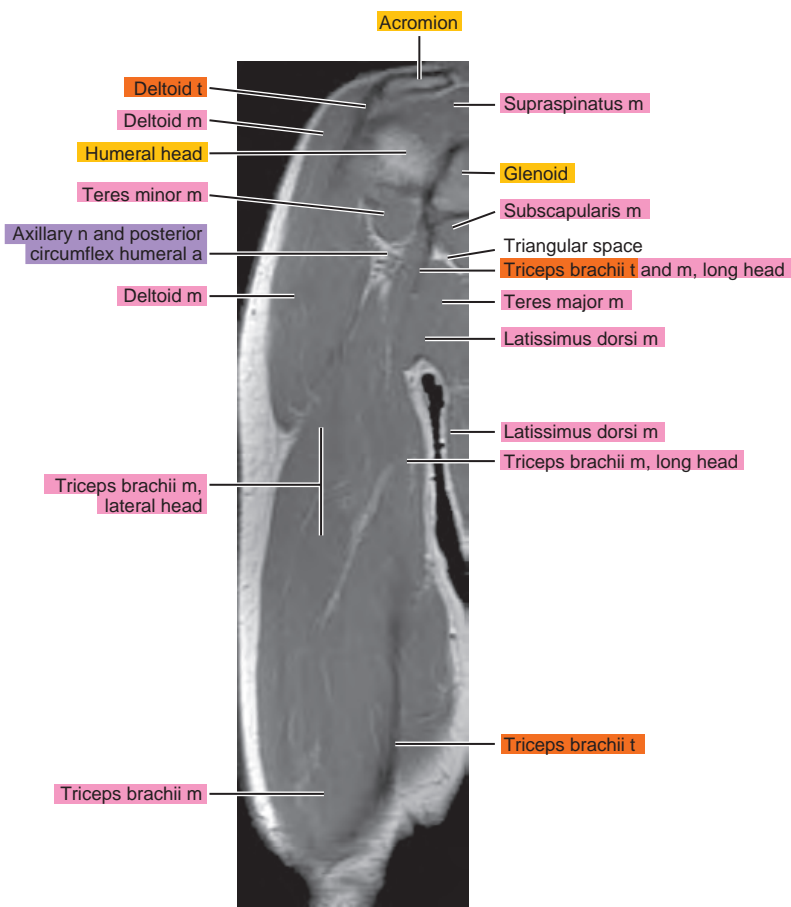
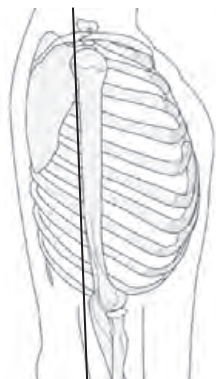


Figure 4.3.12

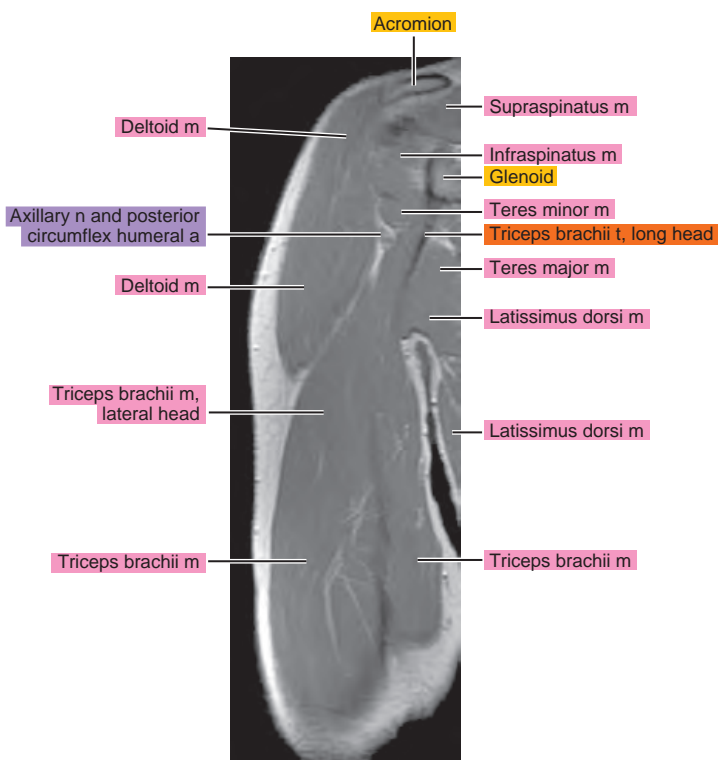
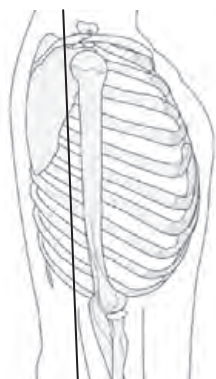


Figure 4.3.13

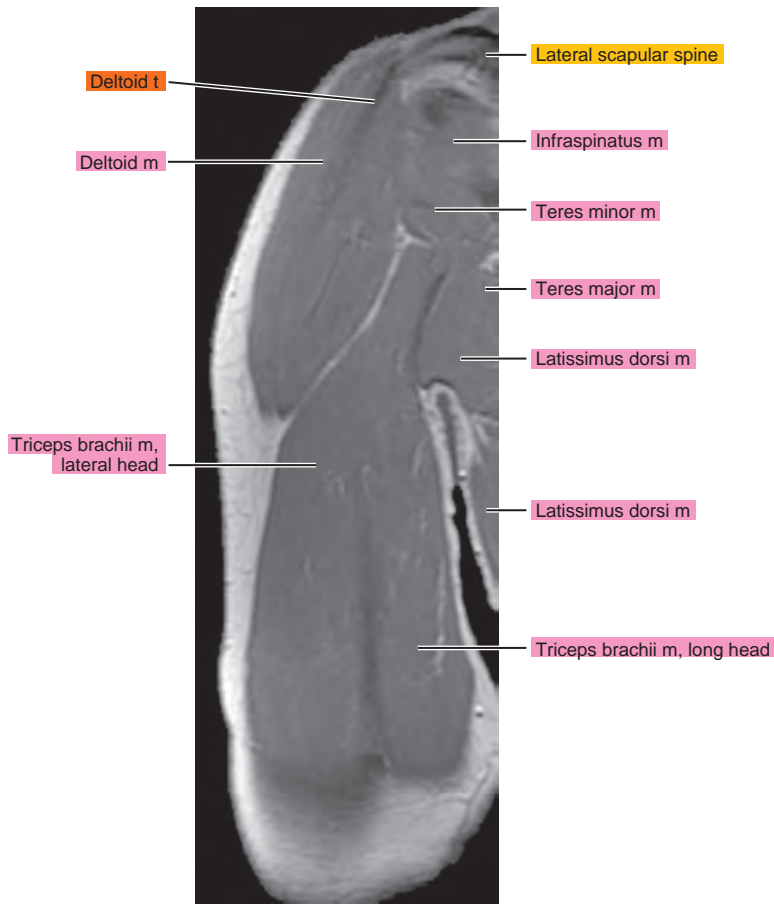
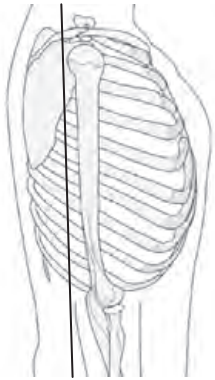


Figure 4.3.14

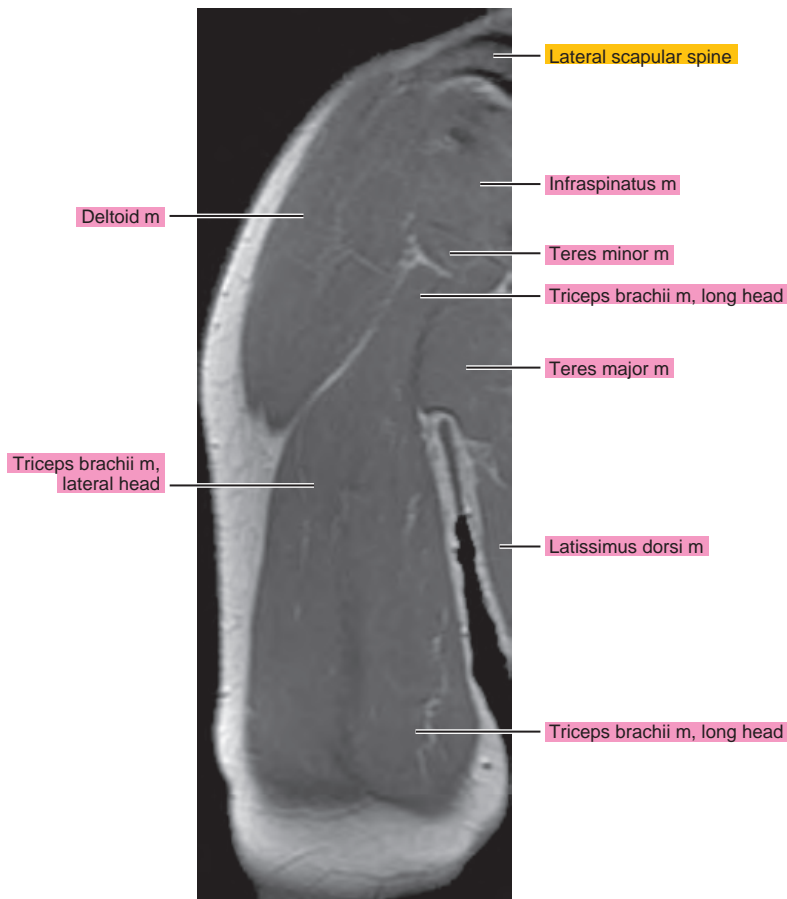
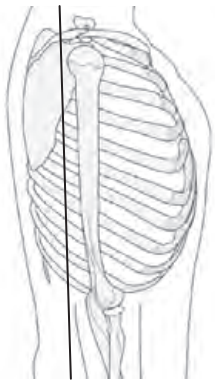


Figure 4.3.15

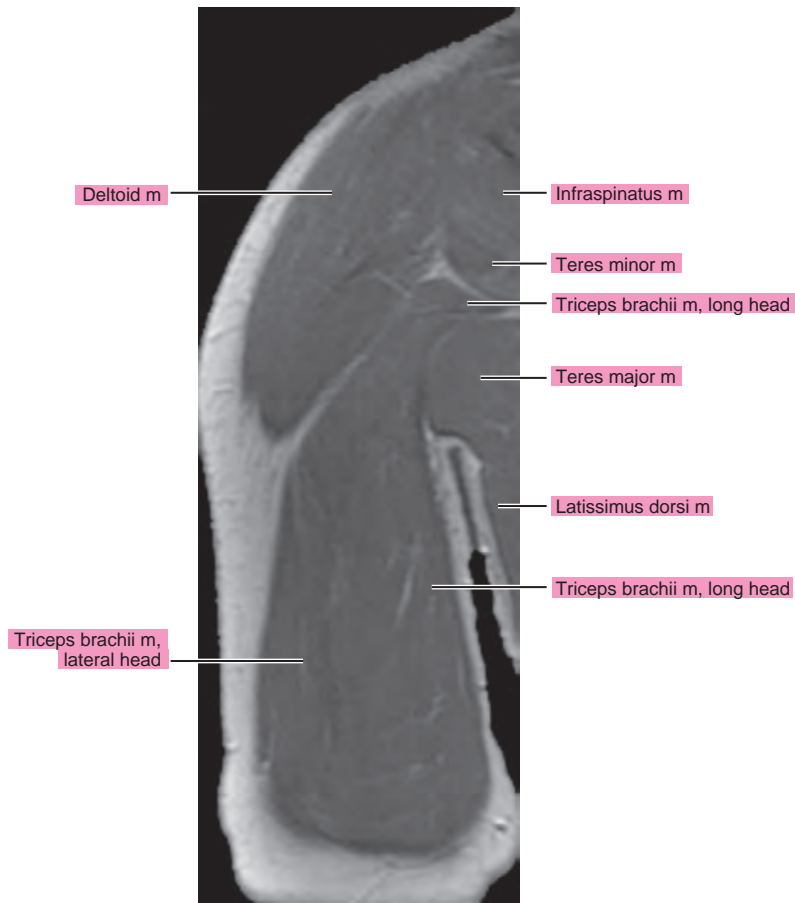
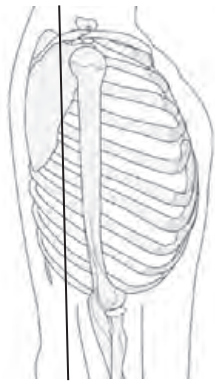


Figure 4.3.16

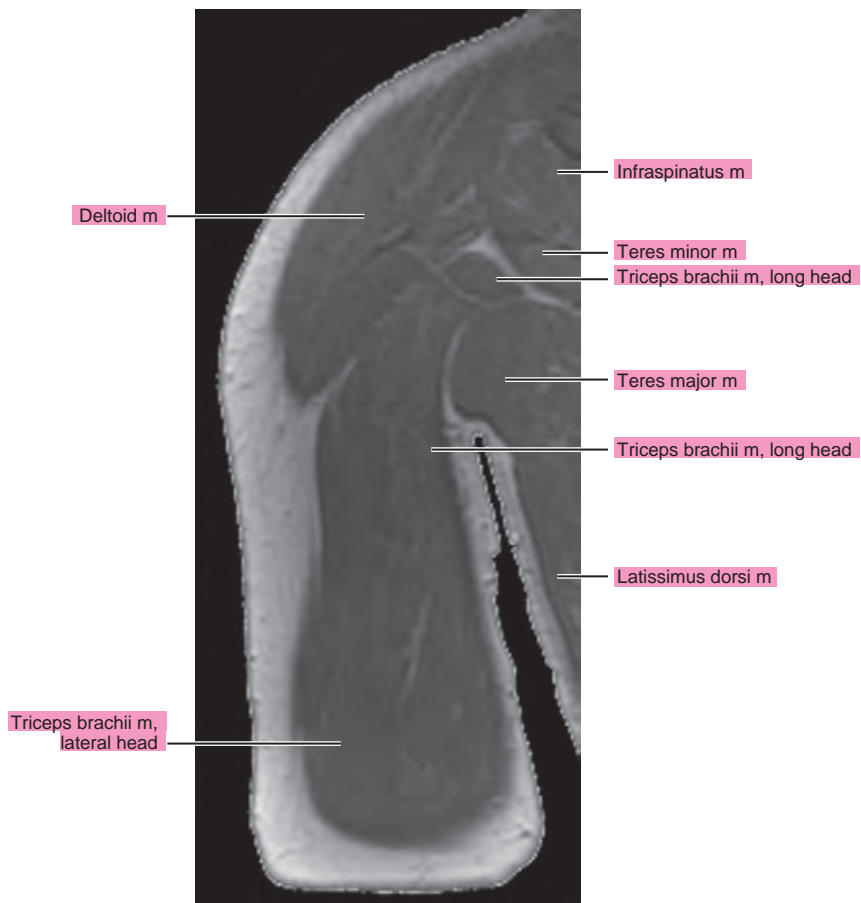
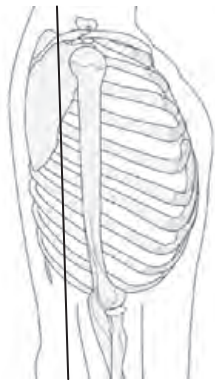


Figure 4.3.17

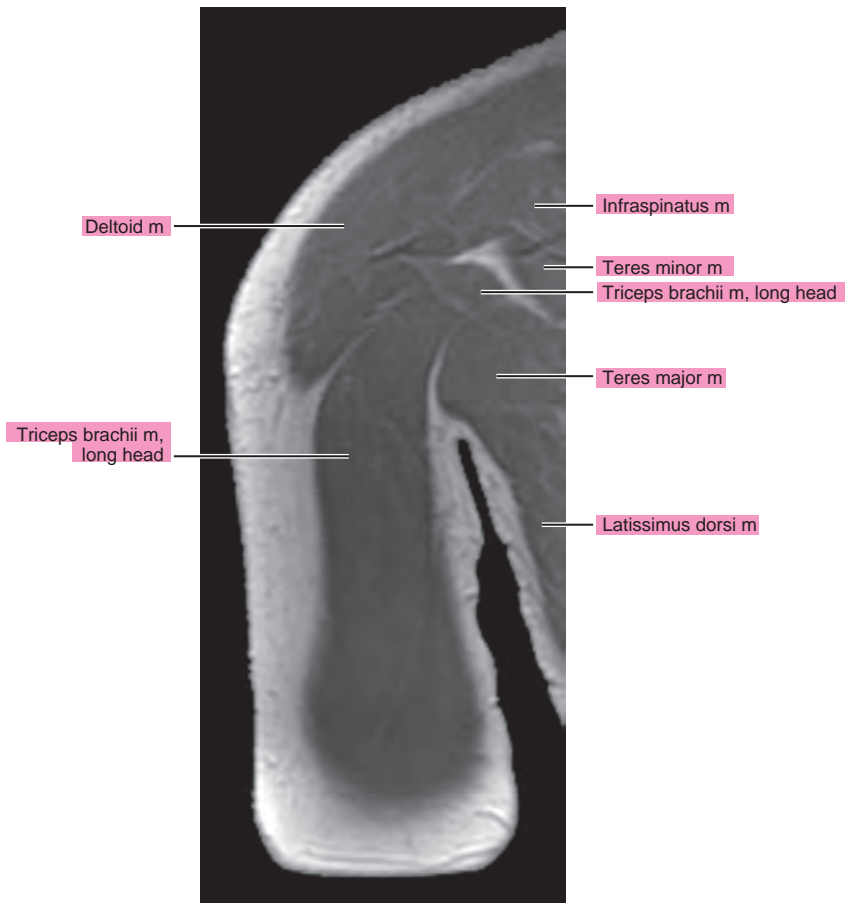
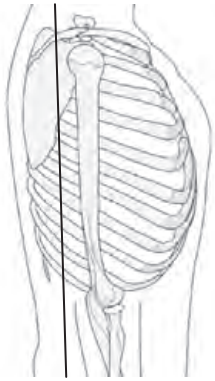
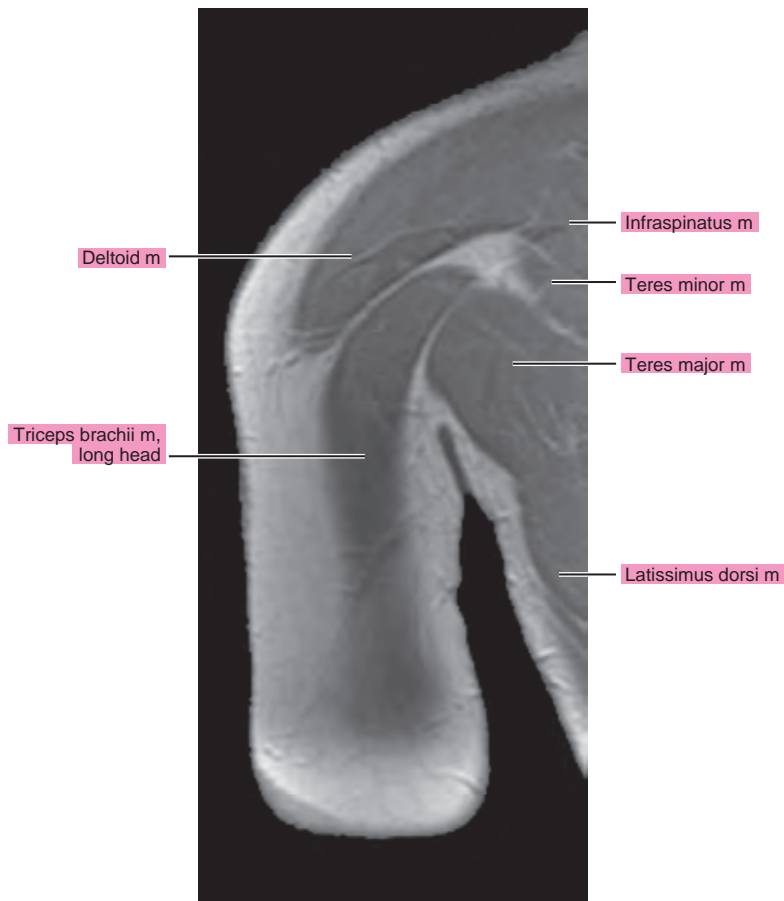
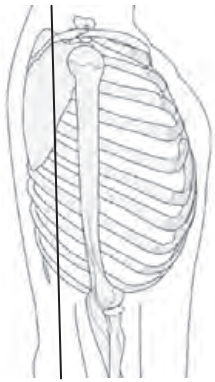


Figure 4.3.18

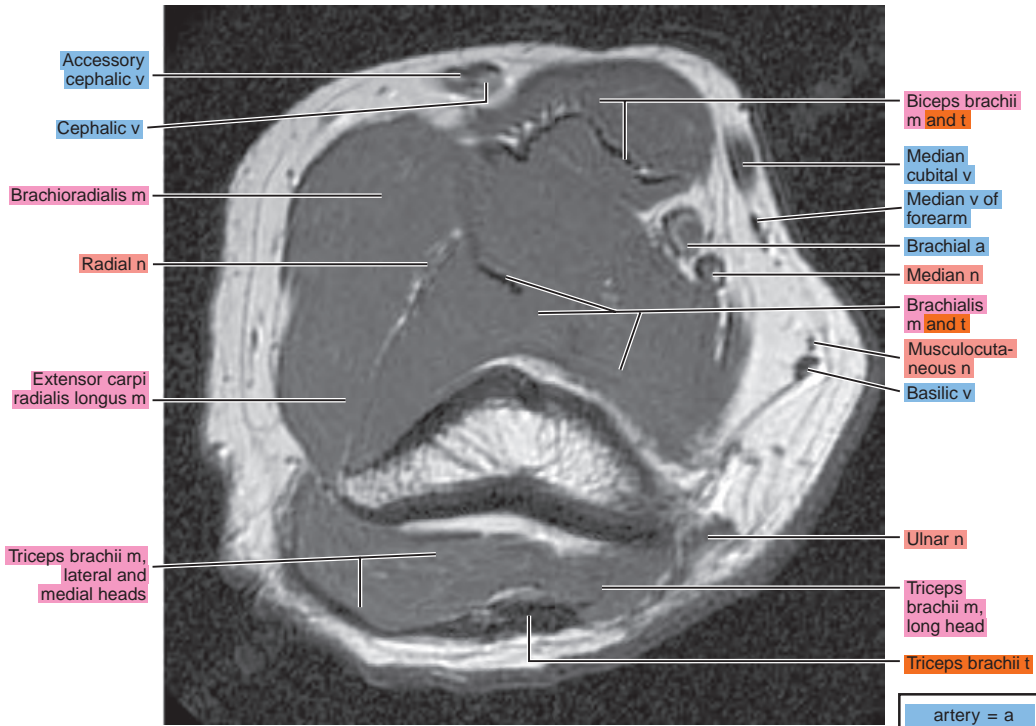
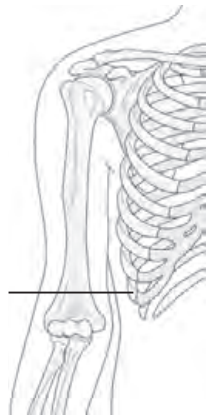


Chapter
5

MRI of the Elbow

AXIAL

Figure 5.1.1

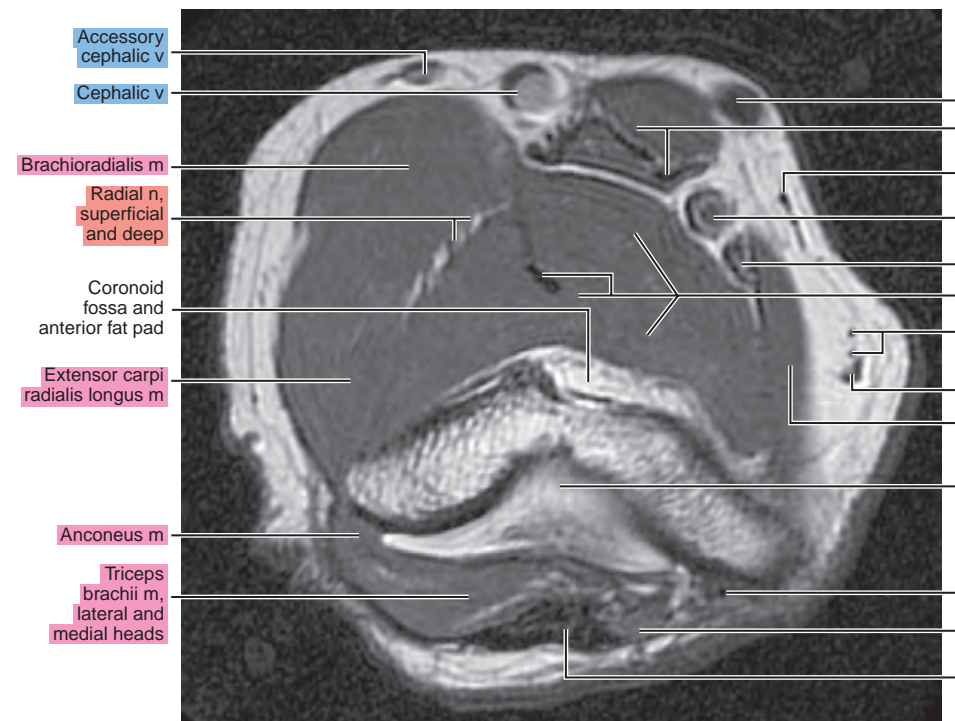
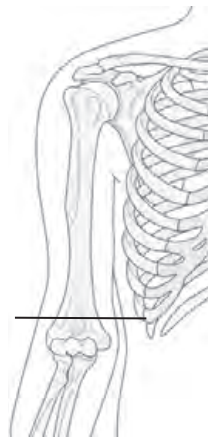

Accessory cephalic v
Cephalic v
Brachioradialis m
Radial n
Extensor carpi radialis longus m
Triceps brachii m, lateral and medial heads

Biceps brachii m and t
Median cubital v
Median v of forearm
Brachial a
Median n
Brachialis m and t
Musculocutaneous n
Basilic v
Ulnar n
Triceps brachii m, long head
Triceps brachii t

artery = a
arteries = aa
vein = v
veins = vv
muscle = m
muscles = mm
tendon = t
tendons = tt
nerve = n
nerves = nn
ligament = lig
ligaments = lig
nerve & vessels
bone

Figure 5.1.2



Accessory cephalic v
Cephalic v
Brachioradialis m
Radial n, superficial and deep
Coronoid fossa and anterior fat pad
Extensor carpi radialis longus m
Anconeus m
Triceps brachii m, lateral and medial heads

Median cubital v
Biceps brachii m and t
Median v of forearm
Brachial a
Median n
Brachialis m and t
Musculocutaneous n
Basilic v
Pronator teres m
Olecranon fossa and posterior fat pad
Ulnar n
Triceps brachii m, long head
Triceps brachii t

Figure 5.1.3

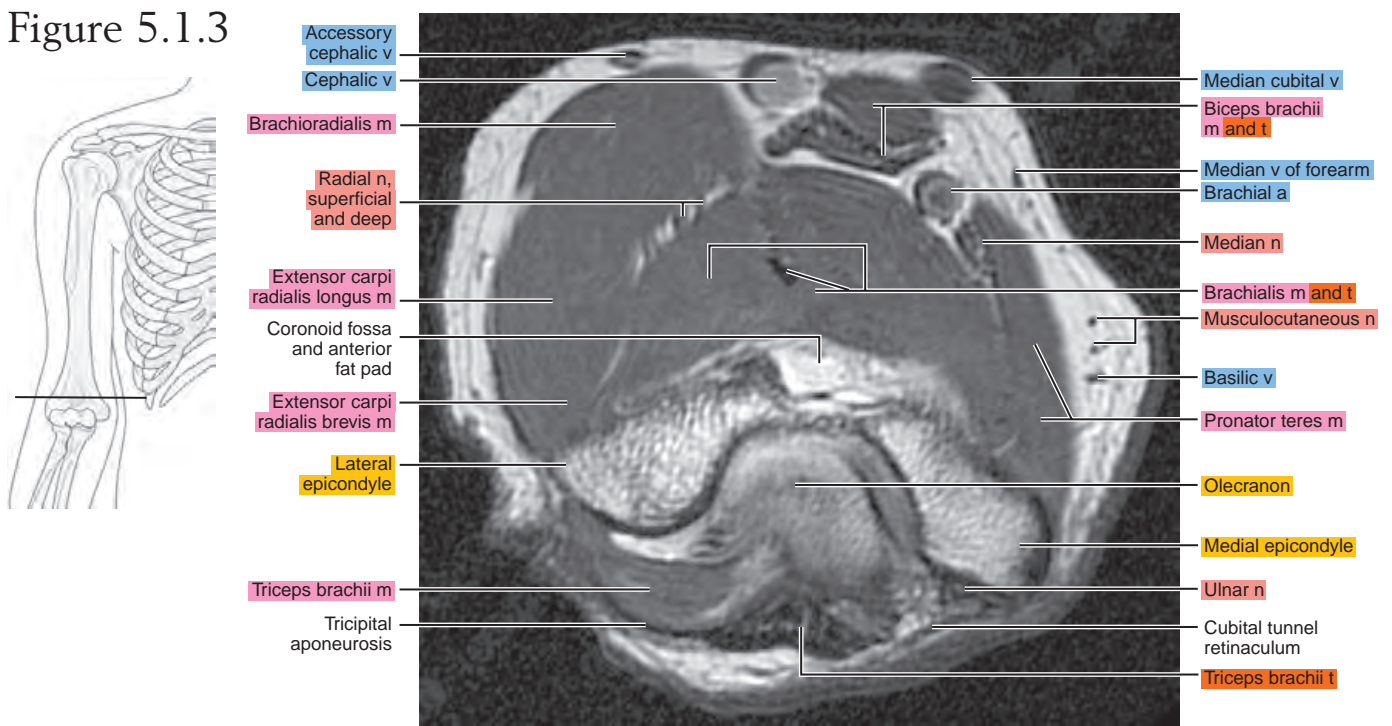


Figure 5.1.4

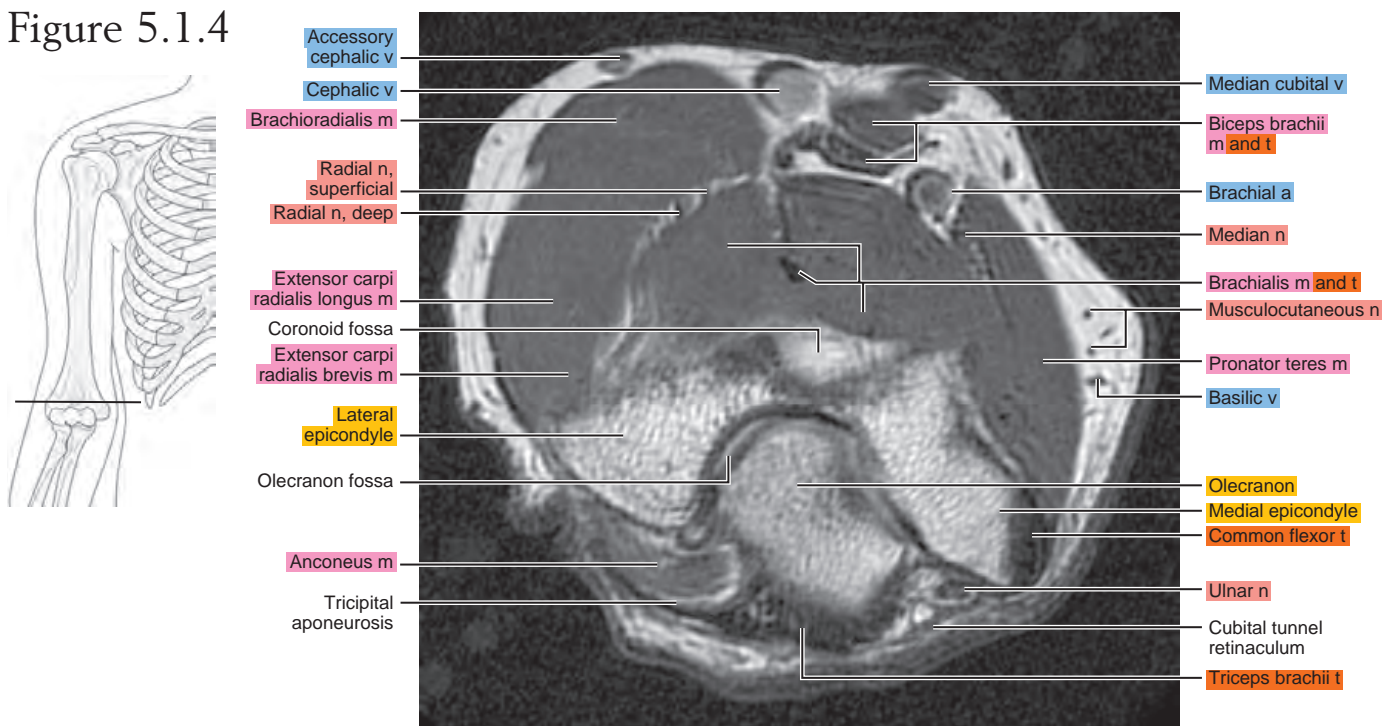


Figure 5.1.5

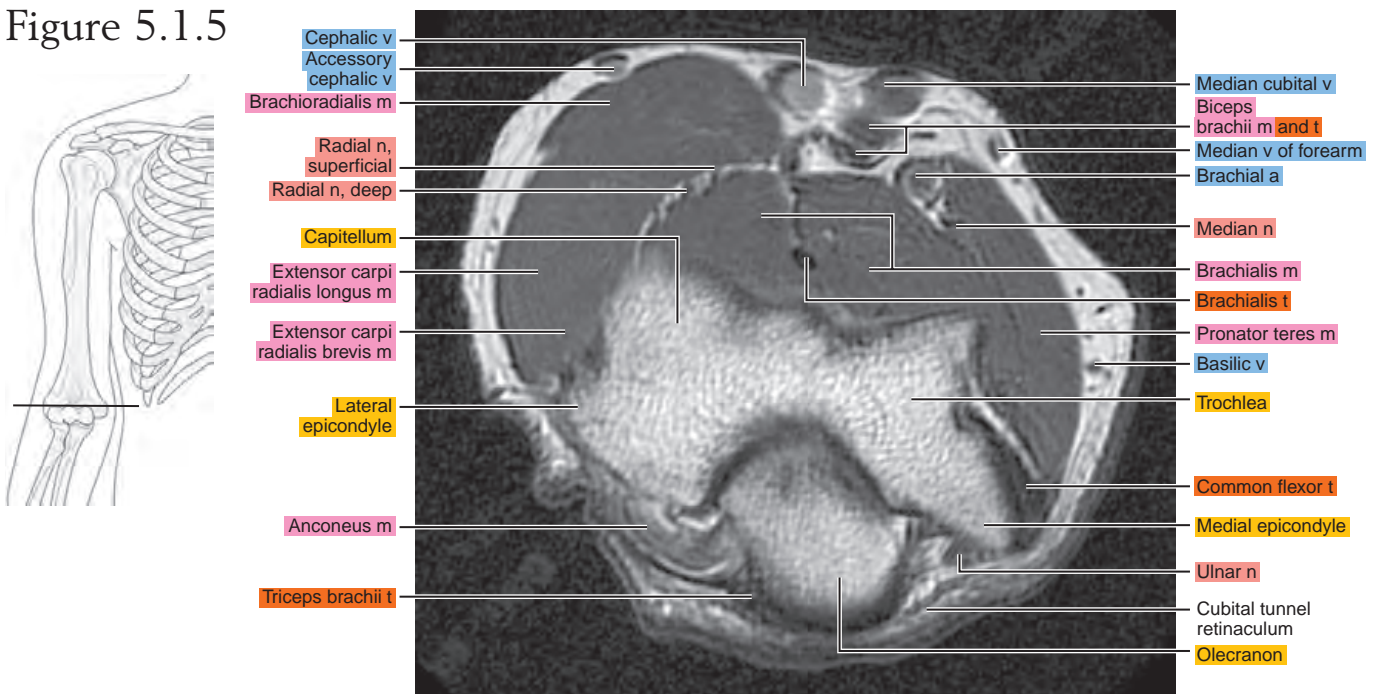
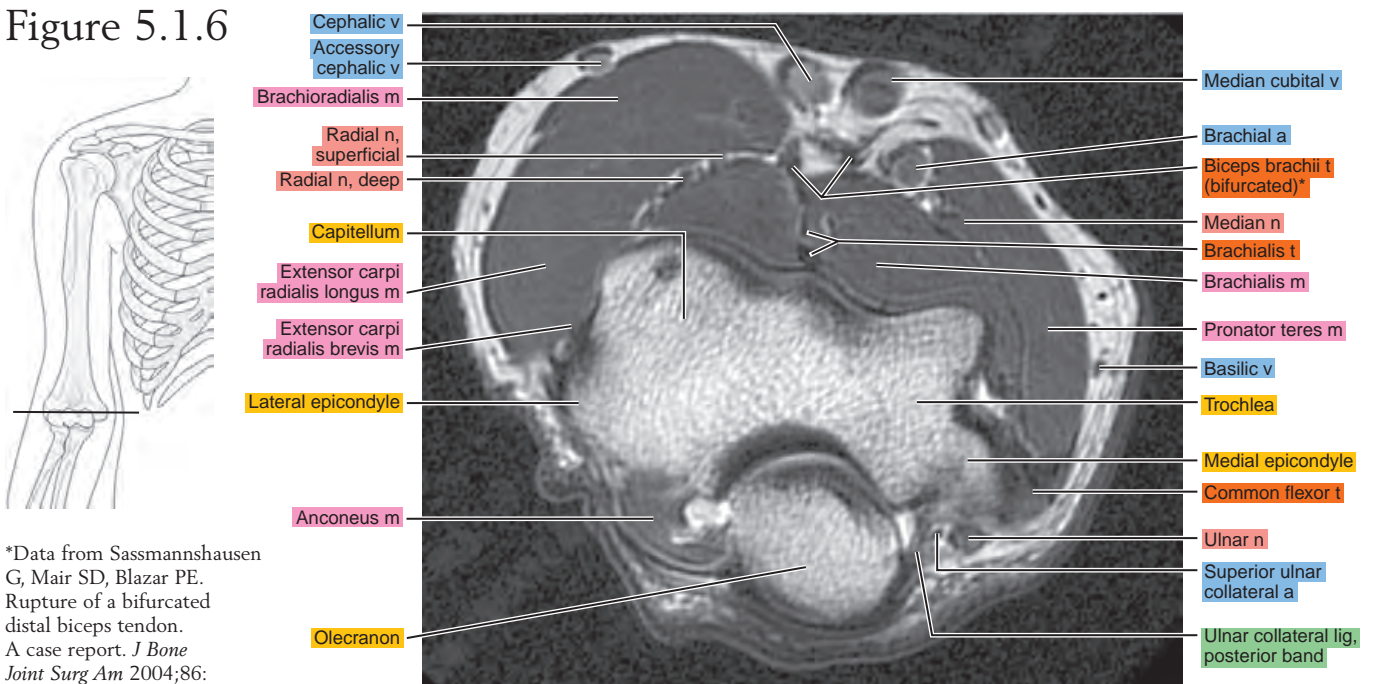
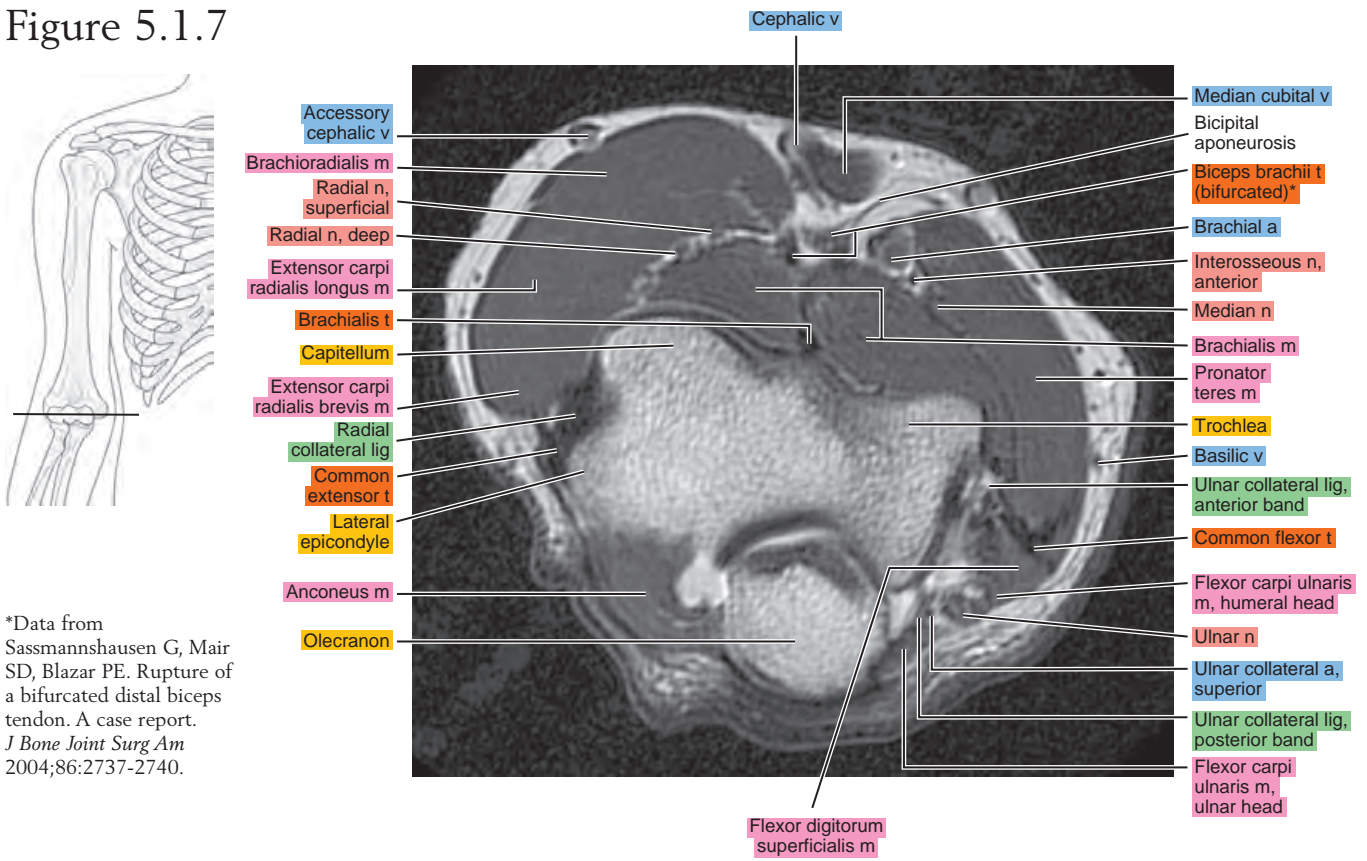


Figure 5.1.6



*Data from Sassmannshausen G, Mair SD, Blazar PE. Rupture of a bifurcated distal biceps tendon. A case report. *J Bone Joint Surg Am* 2004;86: 2737-2740.

Figure 5.1.7



*Data from
Sassmannshausen G, Mair SD, Blazar PE. Rupture of a bifurcated distal biceps tendon. A case report. *J Bone Joint Surg Am* 2004;86:2737-2740.

Figure 5.1.8

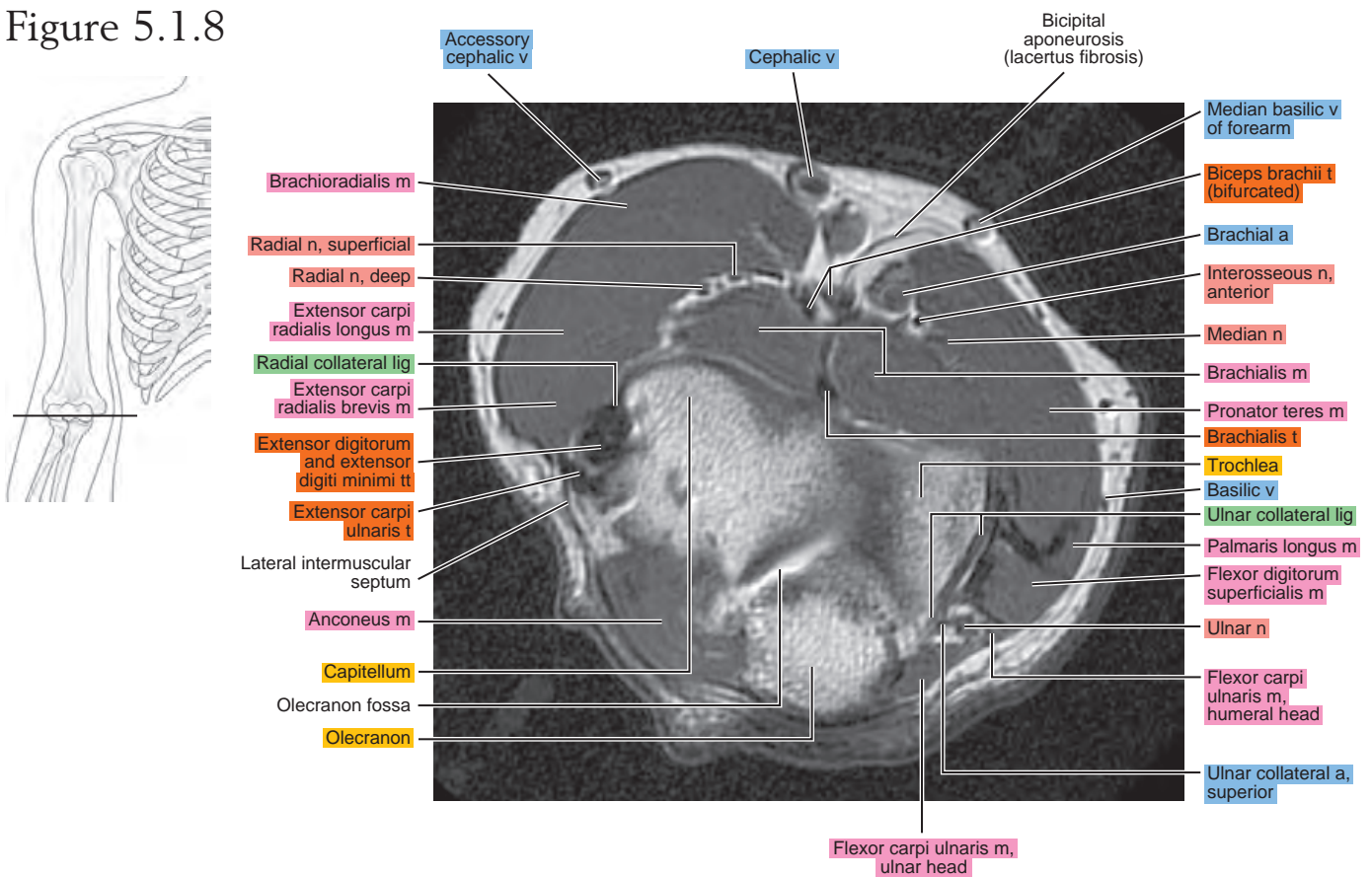


Figure 5.1.9

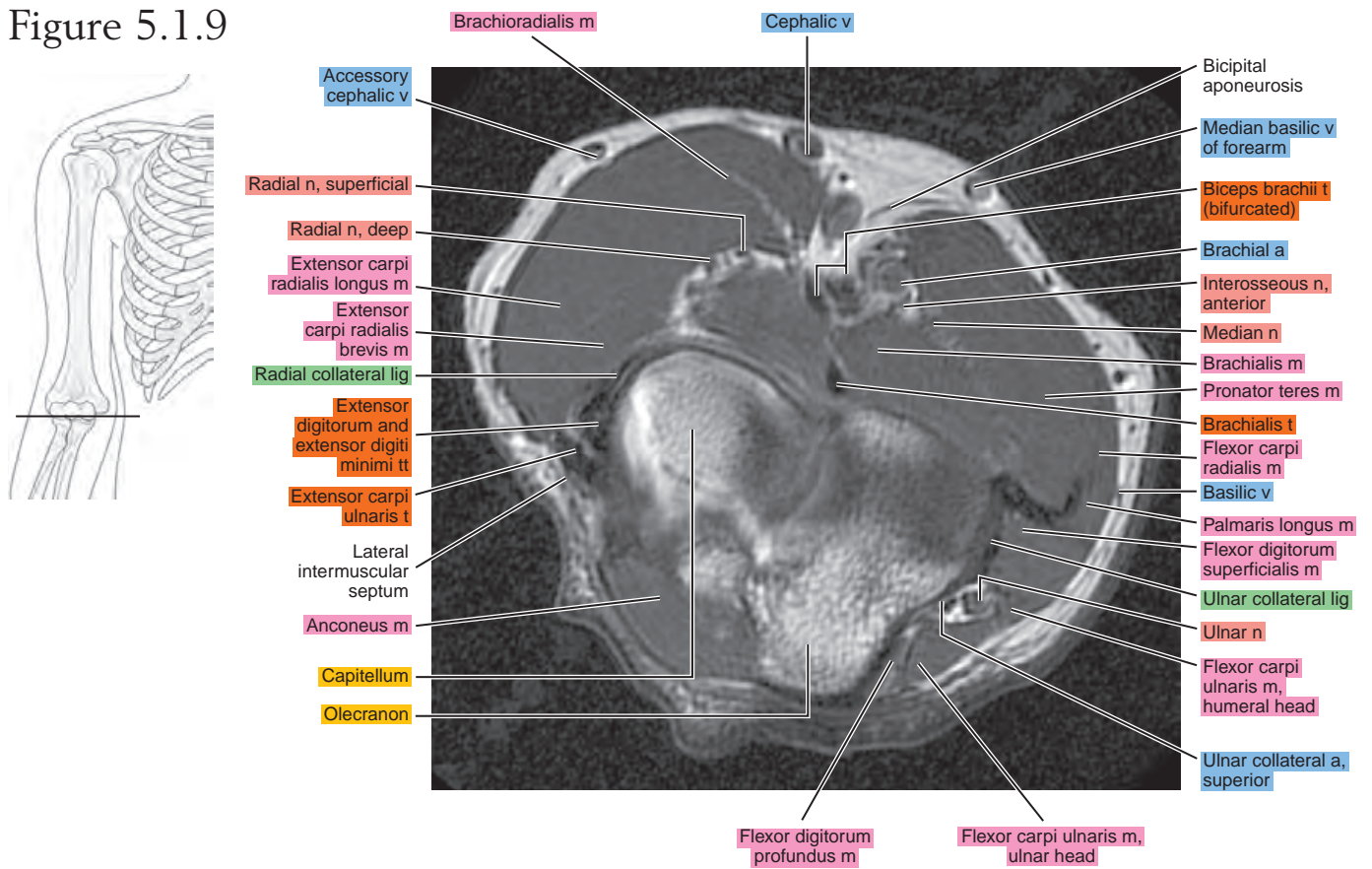


Figure 5.1.10

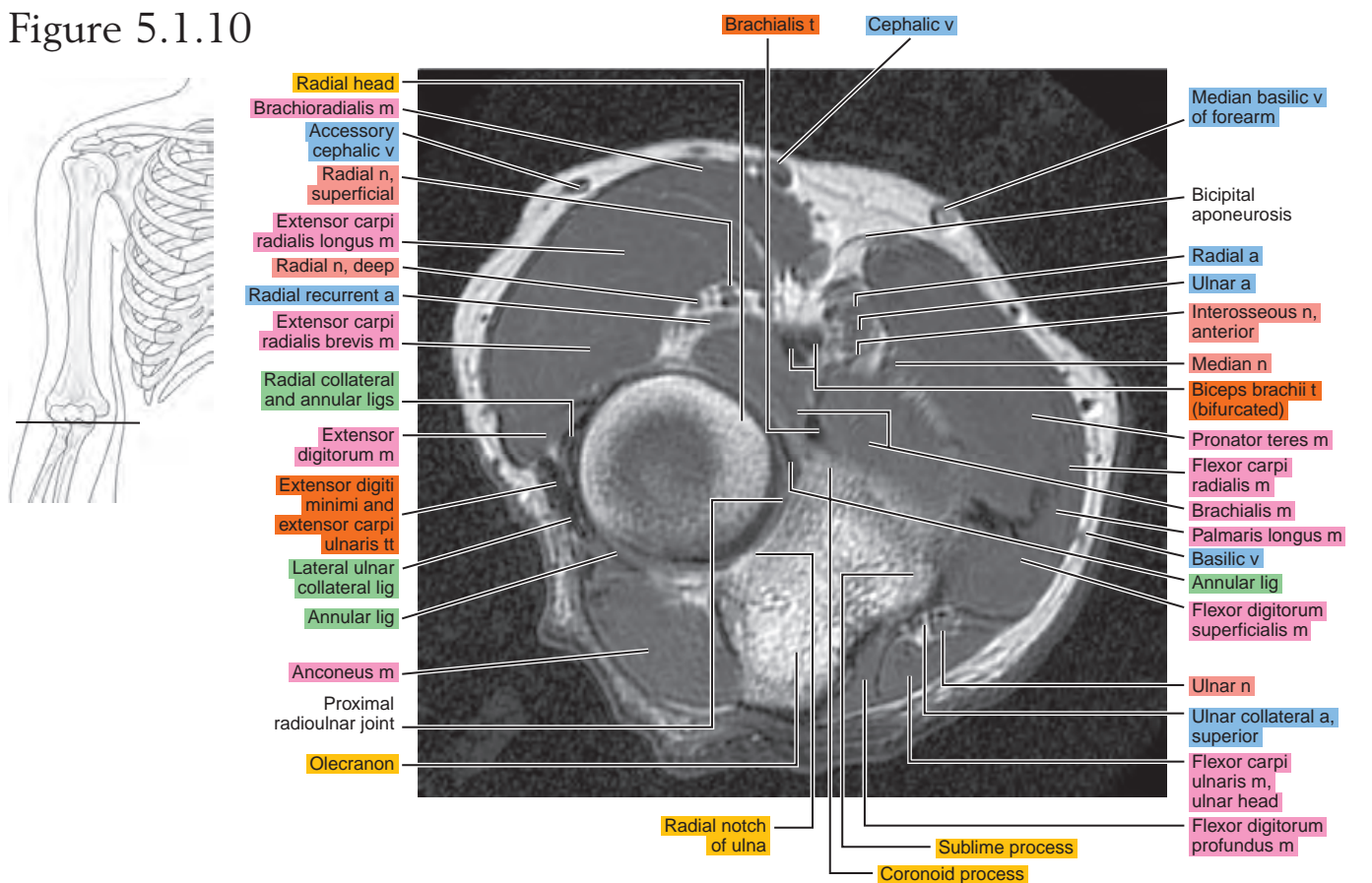


Figure 5.1.11

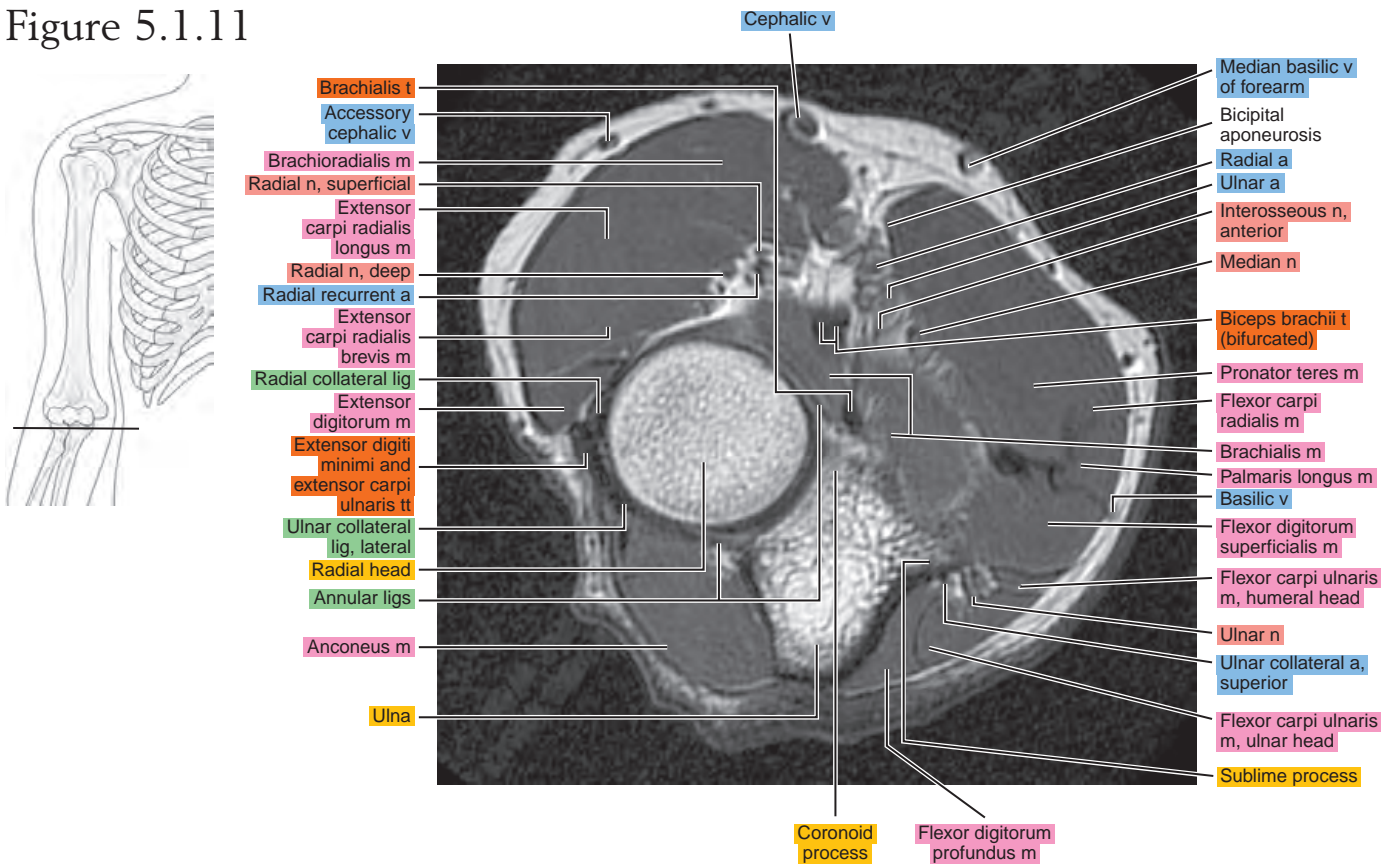


Figure 5.1.12

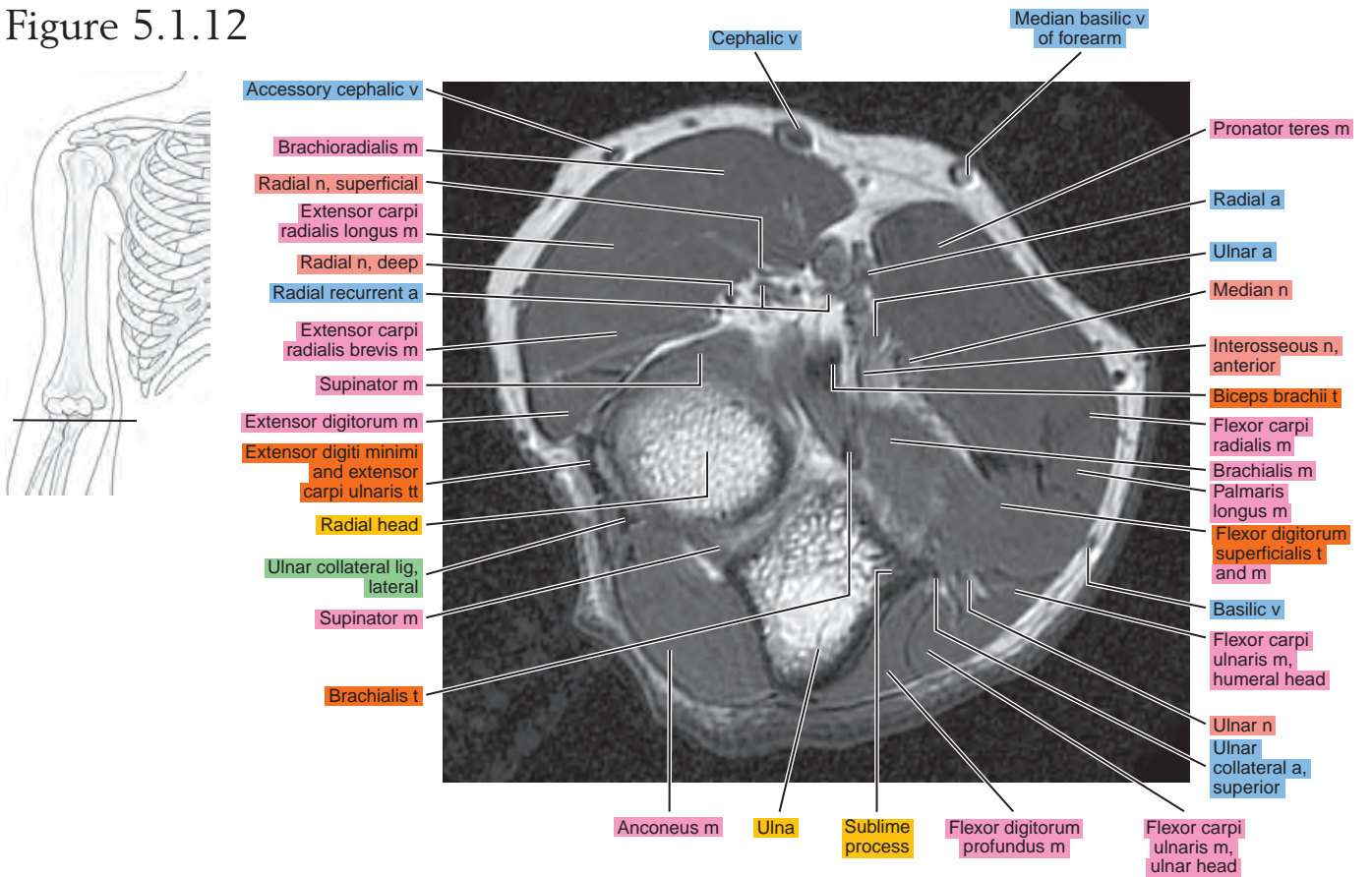


Figure 5.1.13

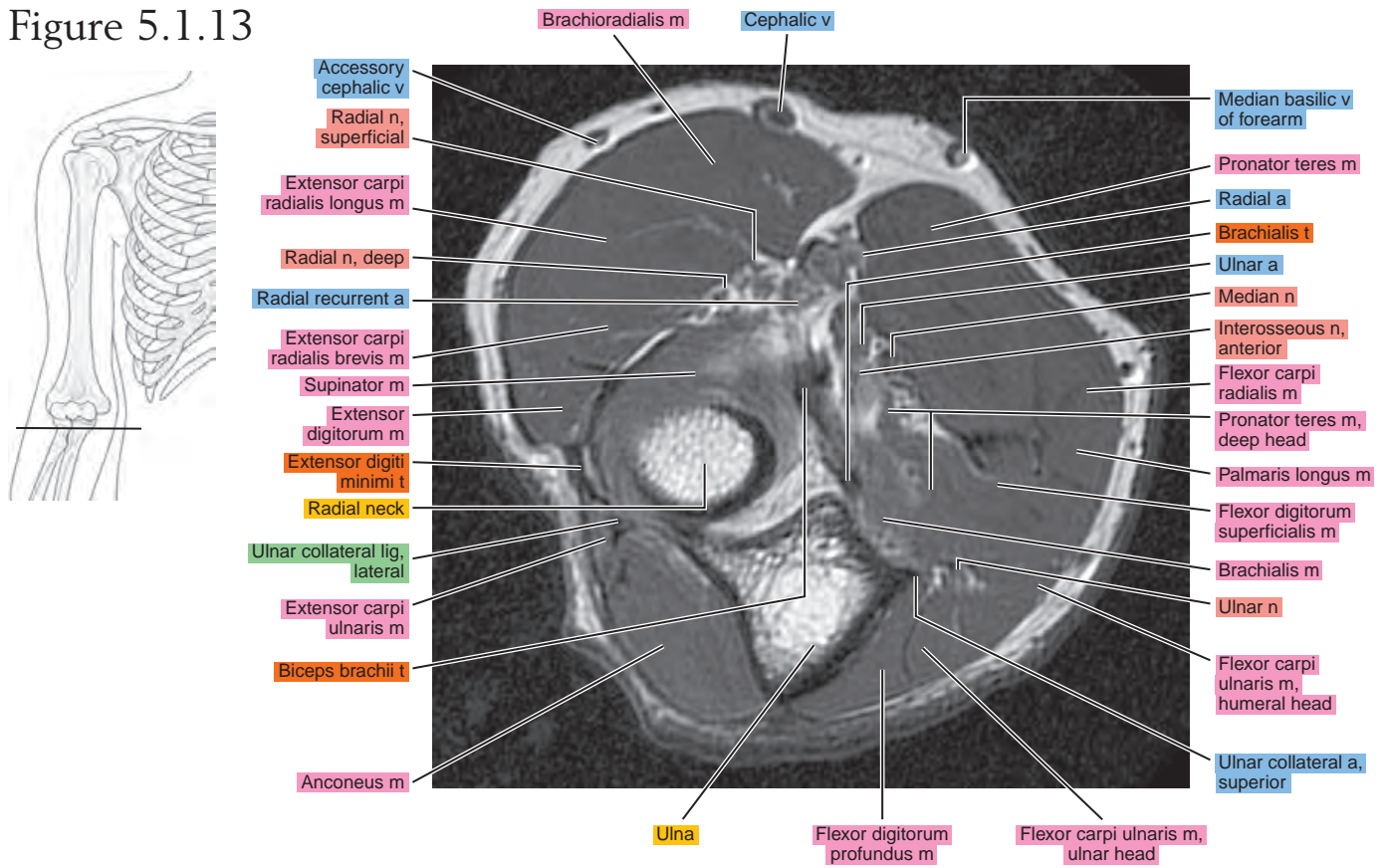


Figure 5.1.14

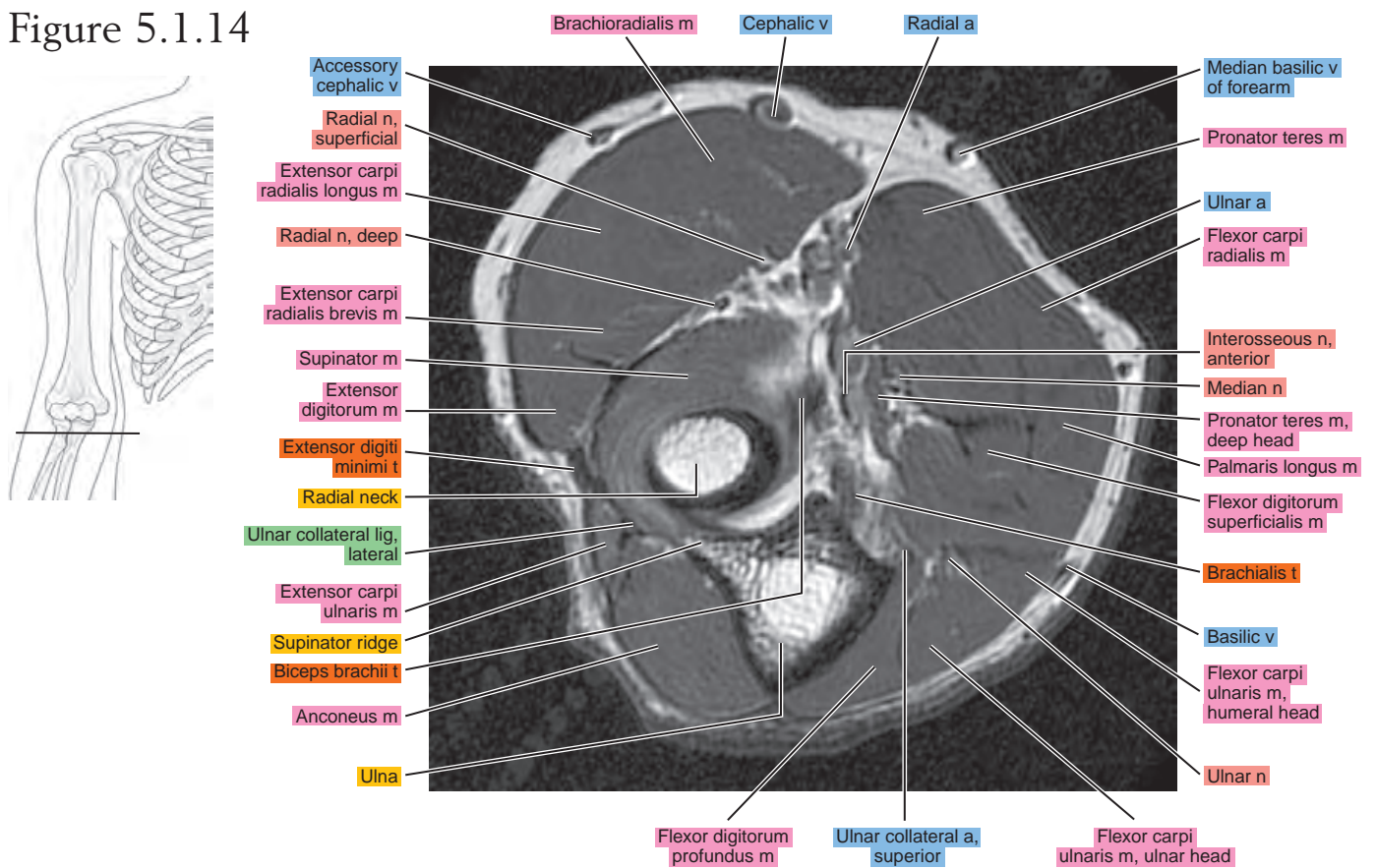


Figure 5.1.15

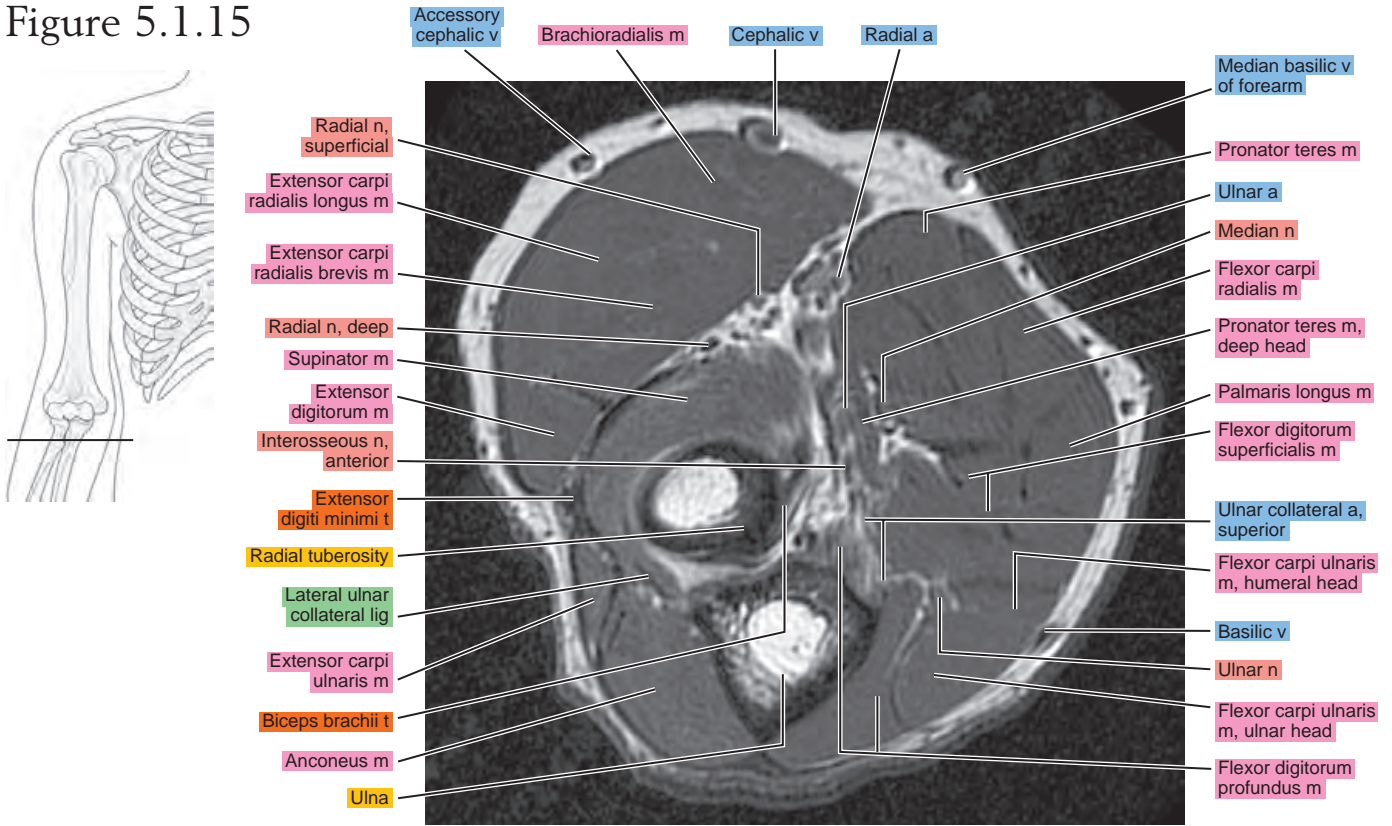


Figure 5.1.16

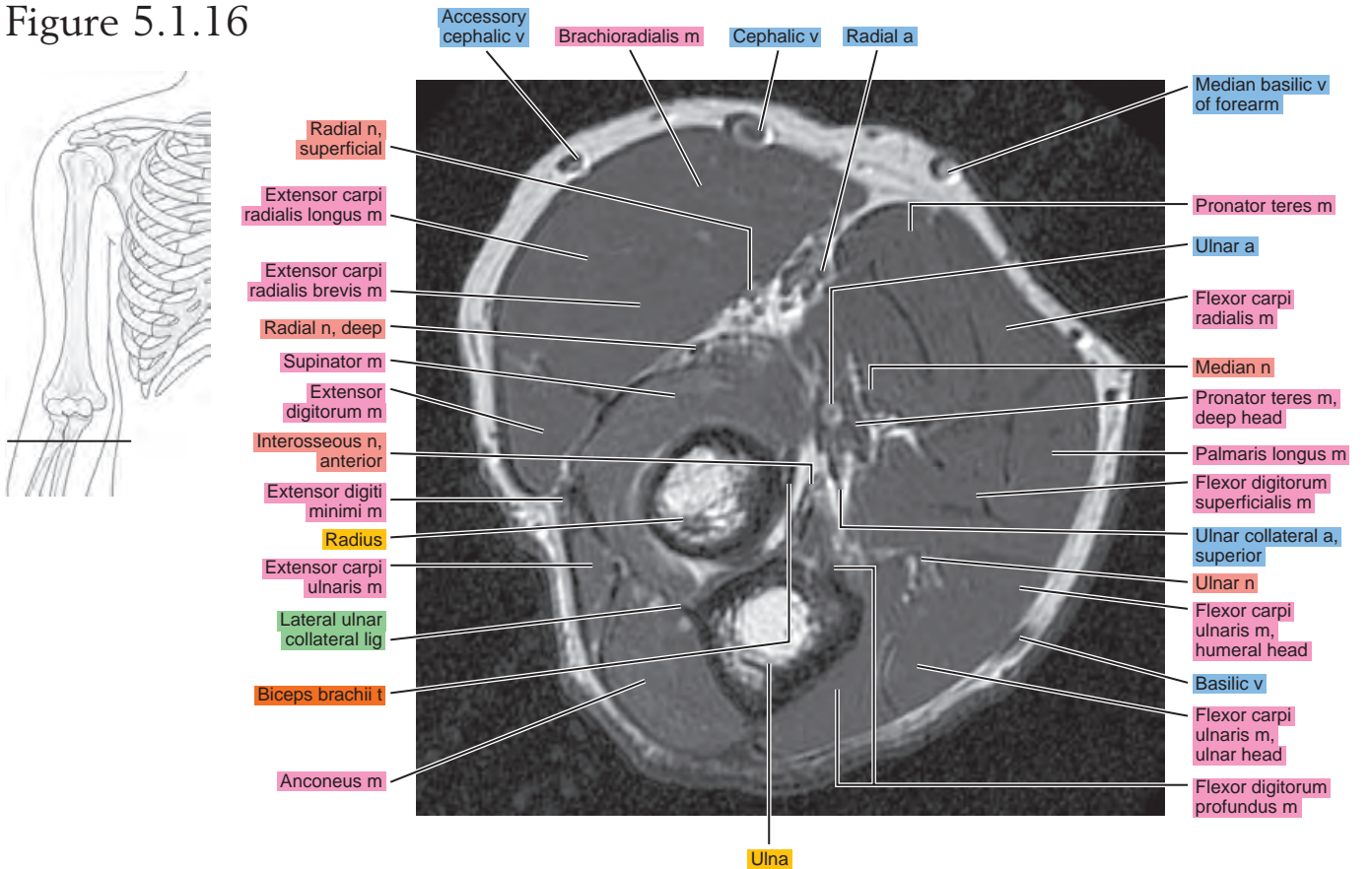


Figure 5.1.17

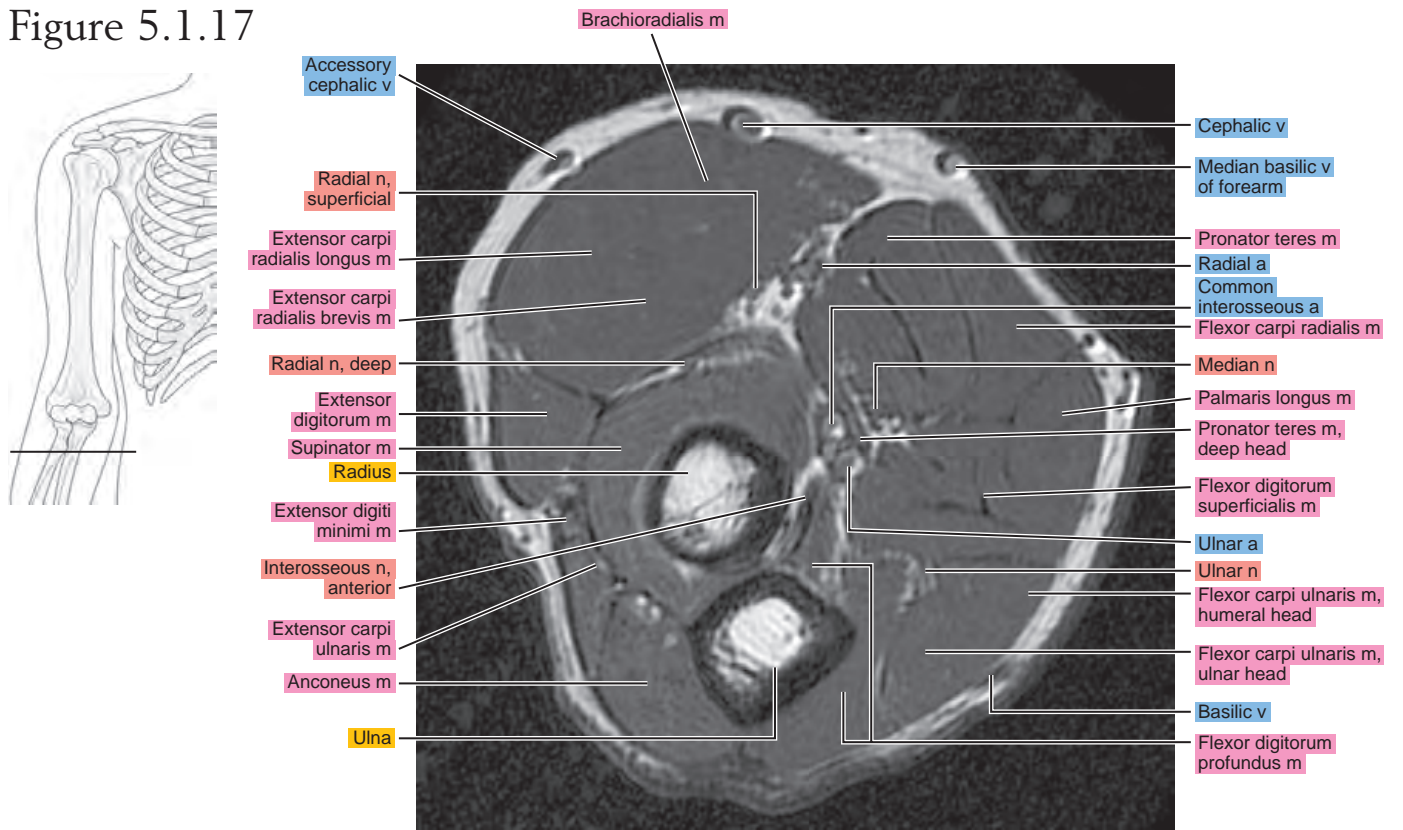


Figure 5.1.18

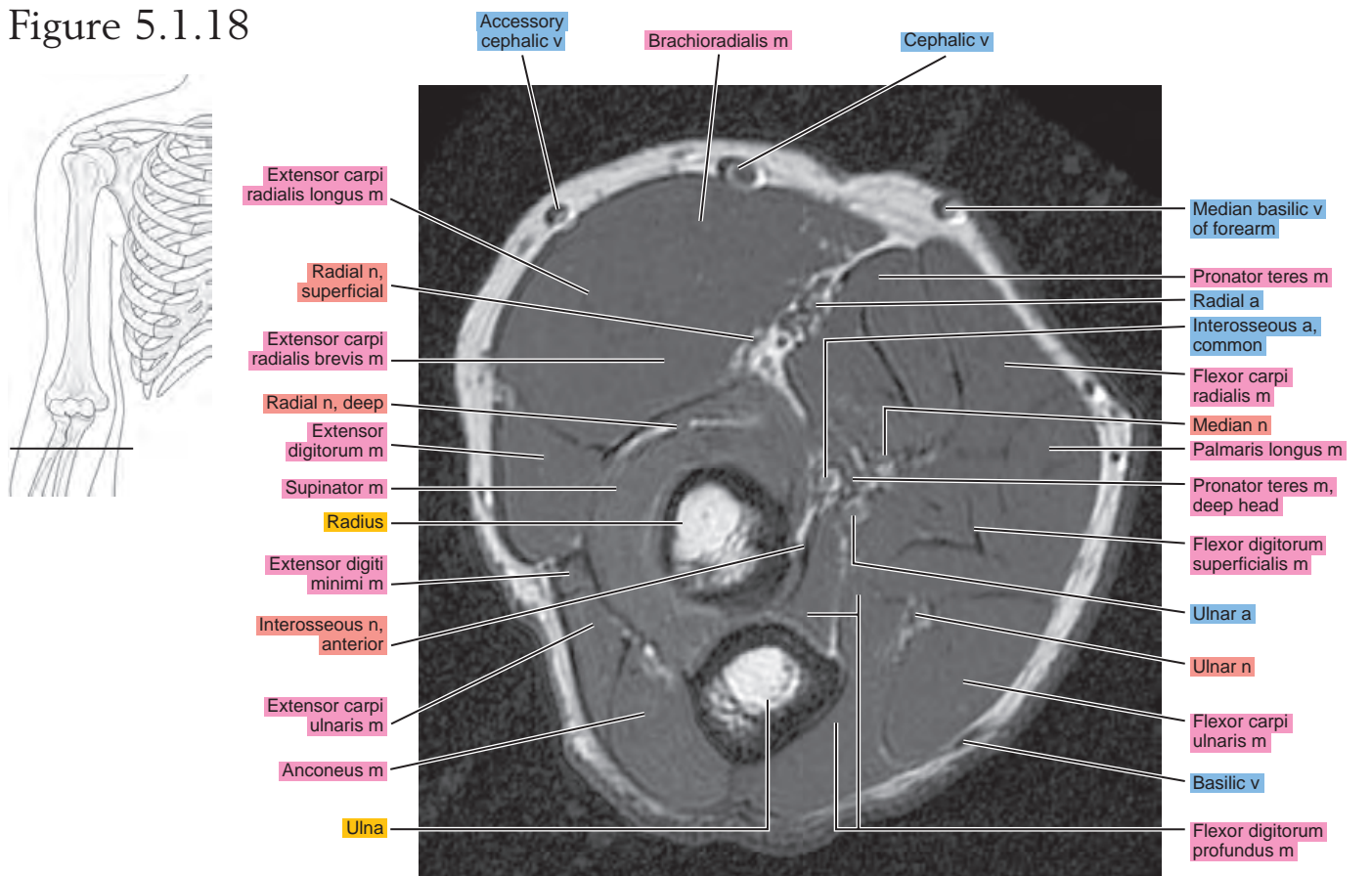


Figure 5.1.19

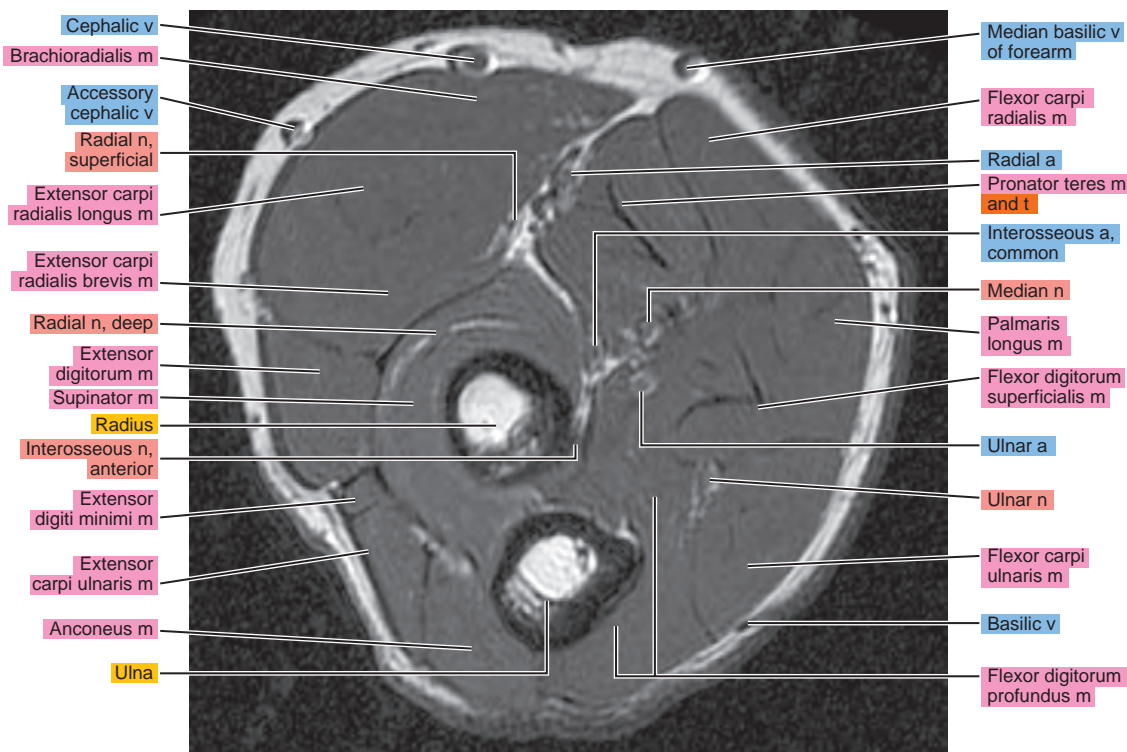
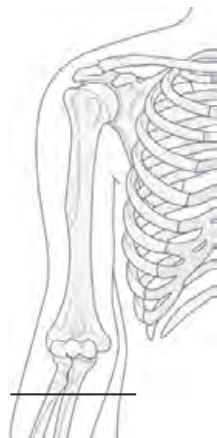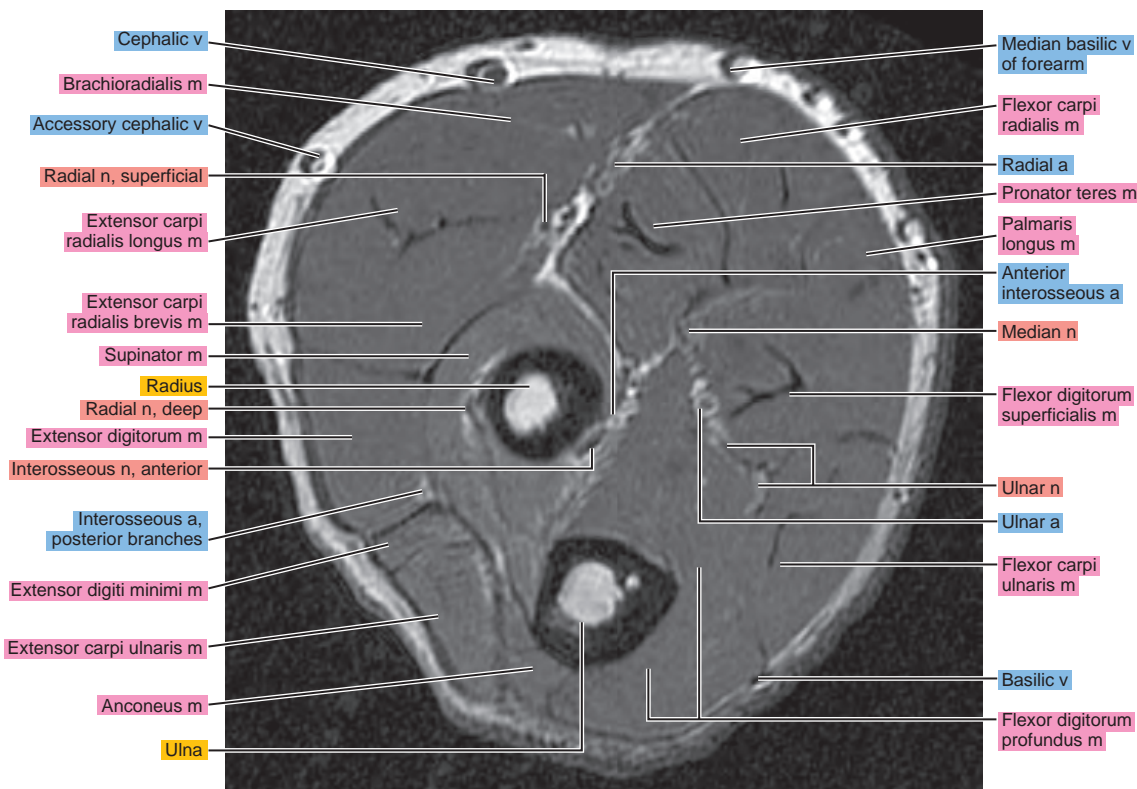
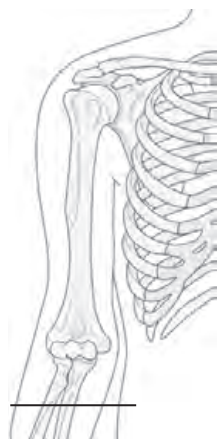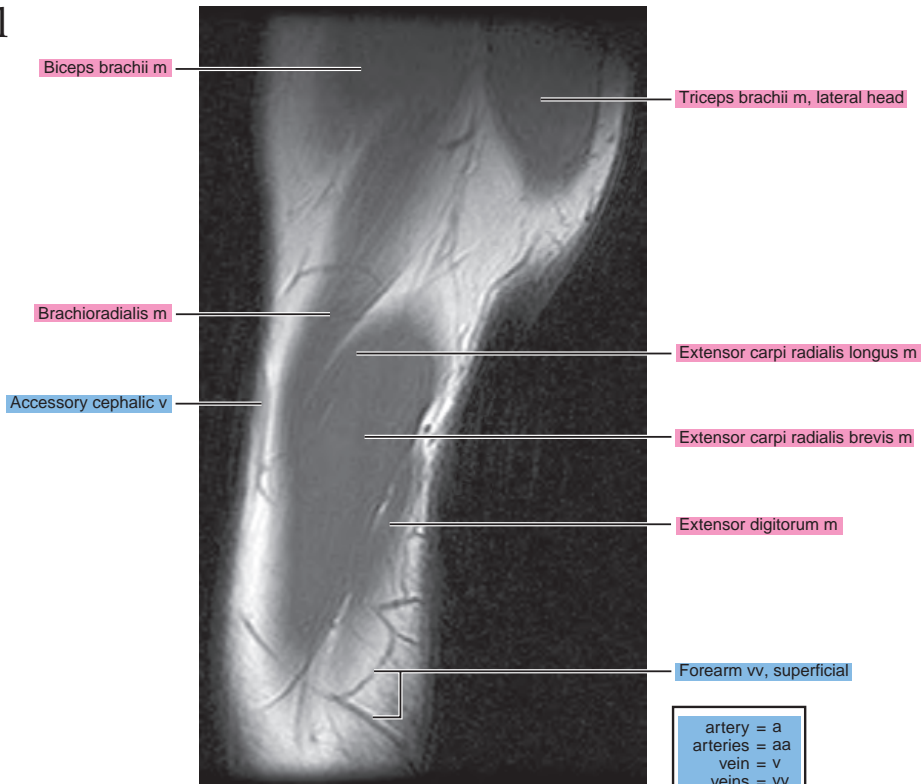


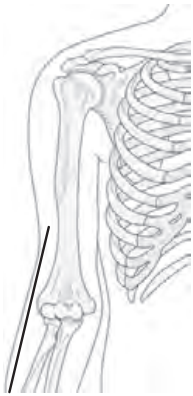Figure 5.1.20



OBLIQUE SAGITTAL

Figure 5.2.1



artery = a
arteries = aa
vein = v
veins = vv
muscle = m
muscles = mm
tendon = t
tendons = tt
nerve = n
nerves = nn
ligament = lig
ligaments = lig
nerve & vessels
bone

Figure 5.2.2

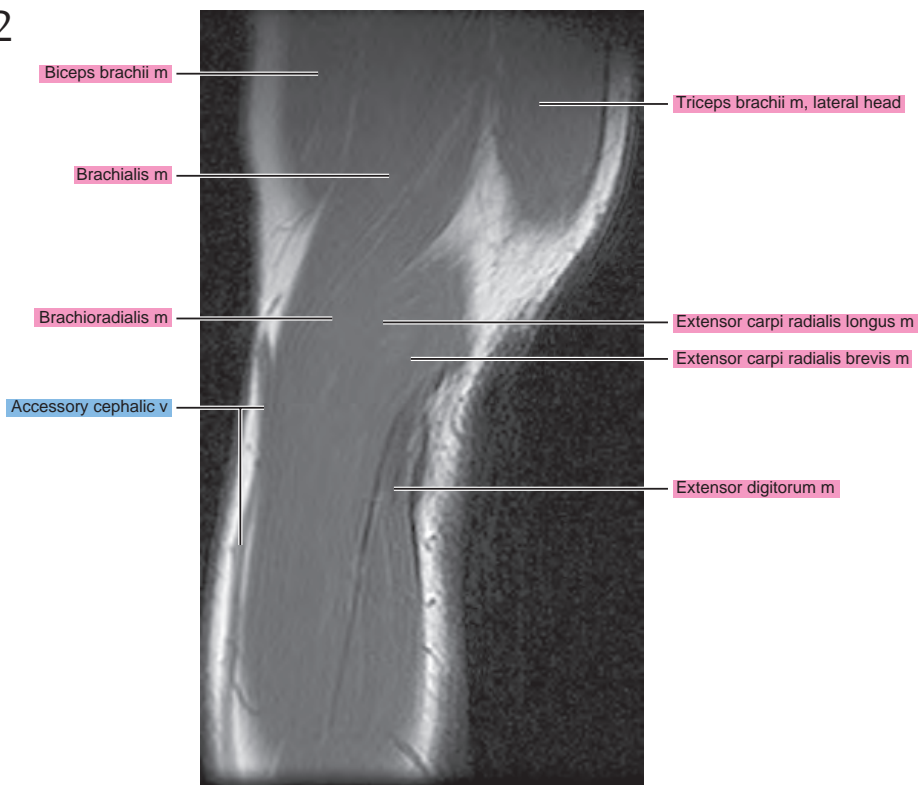
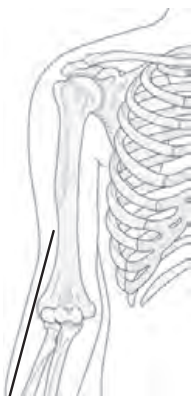

Figure 5.2.3

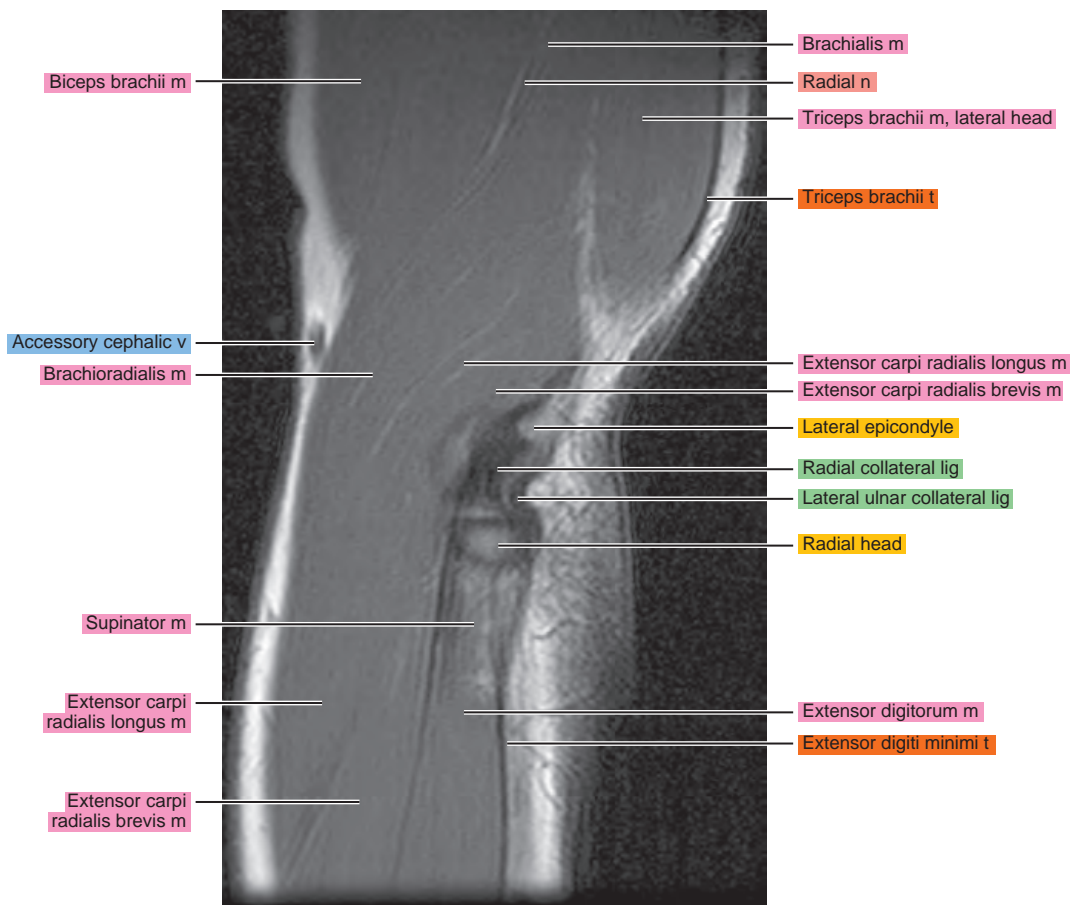
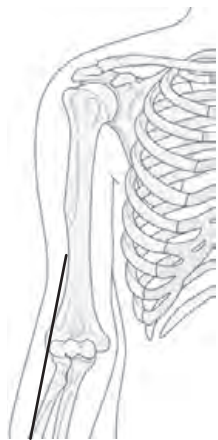


Figure 5.2.4

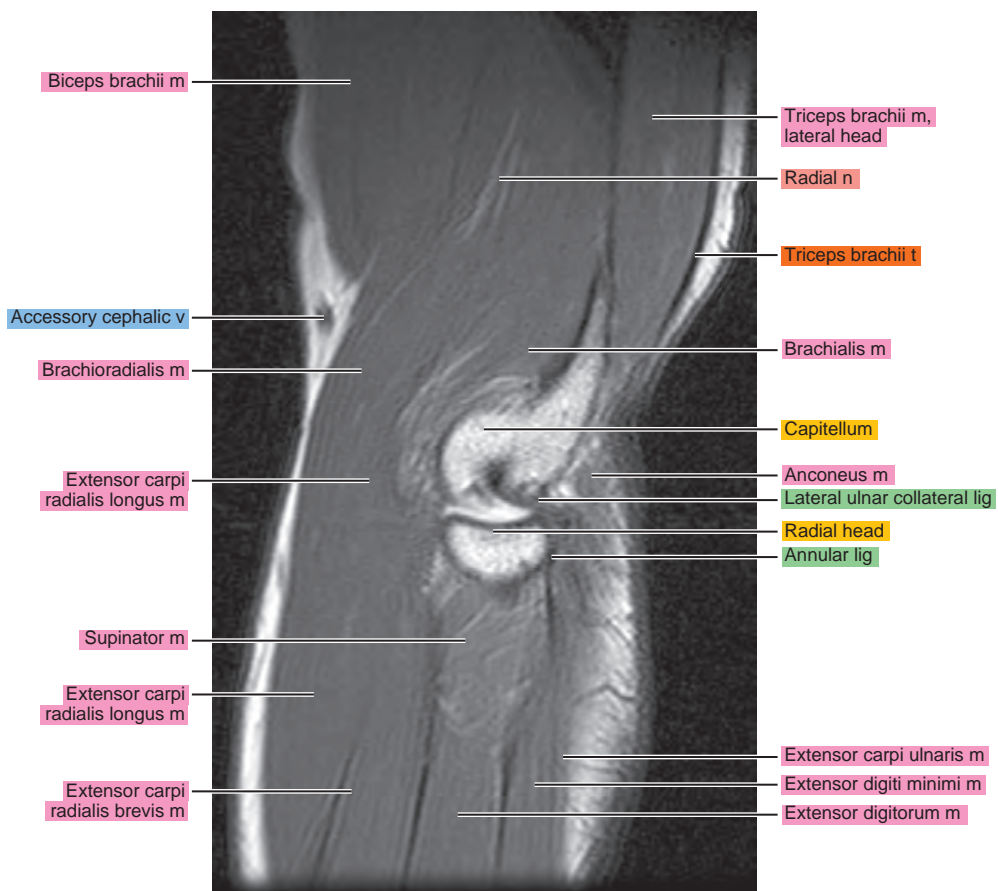
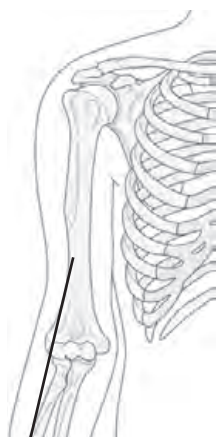


Figure 5.2.5

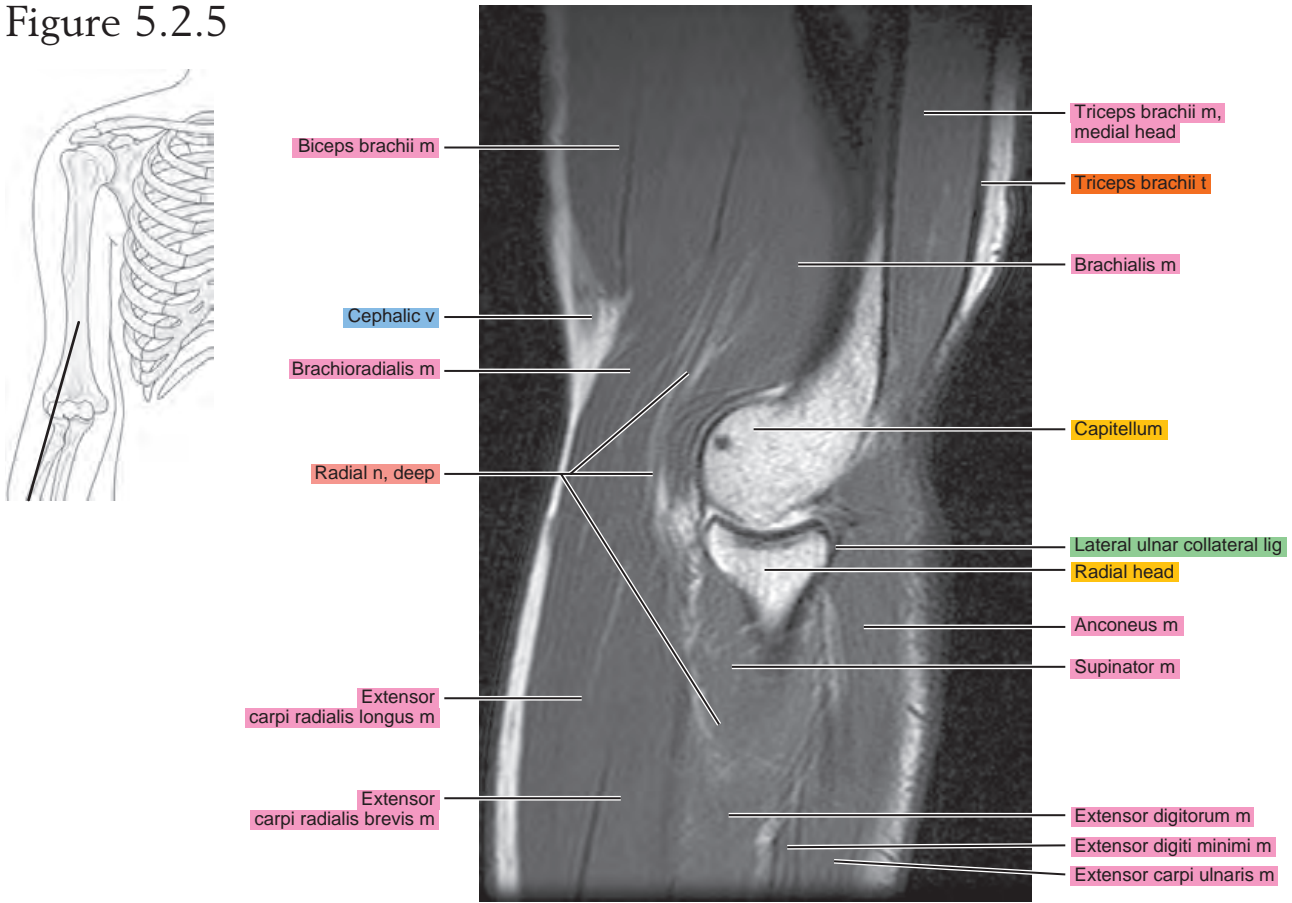


Figure 5.2.6

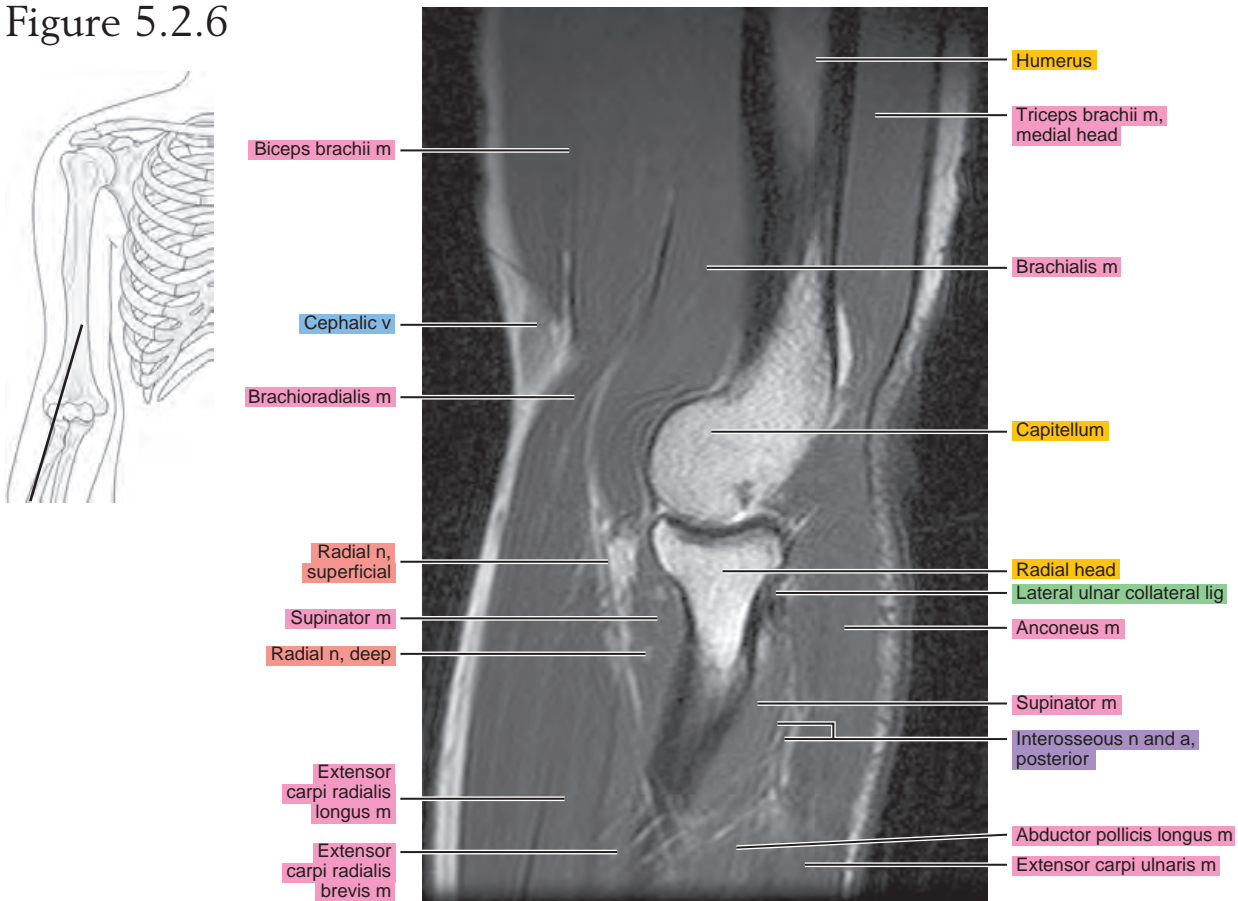


Figure 5.2.7

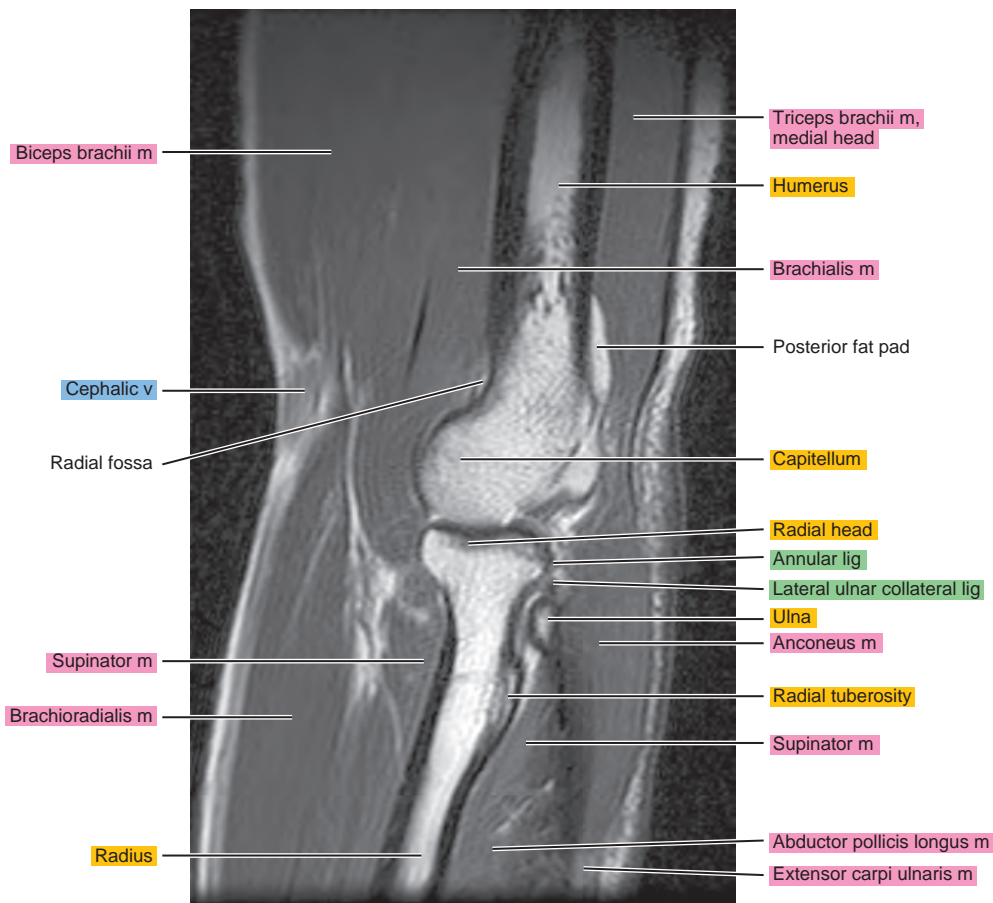
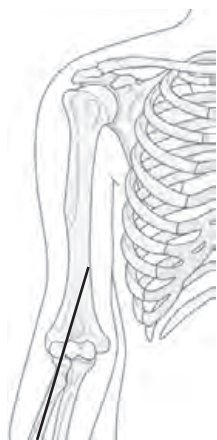


Figure 5.2.8

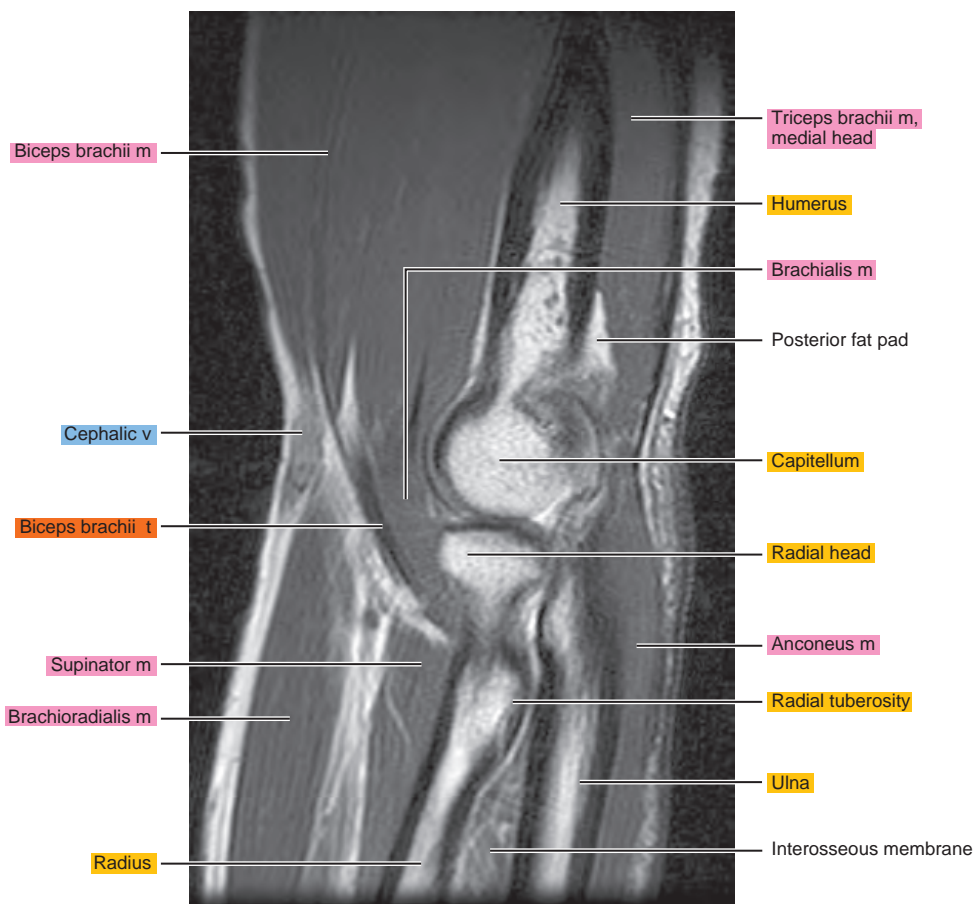
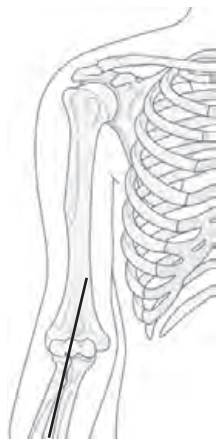


Figure 5.2.9

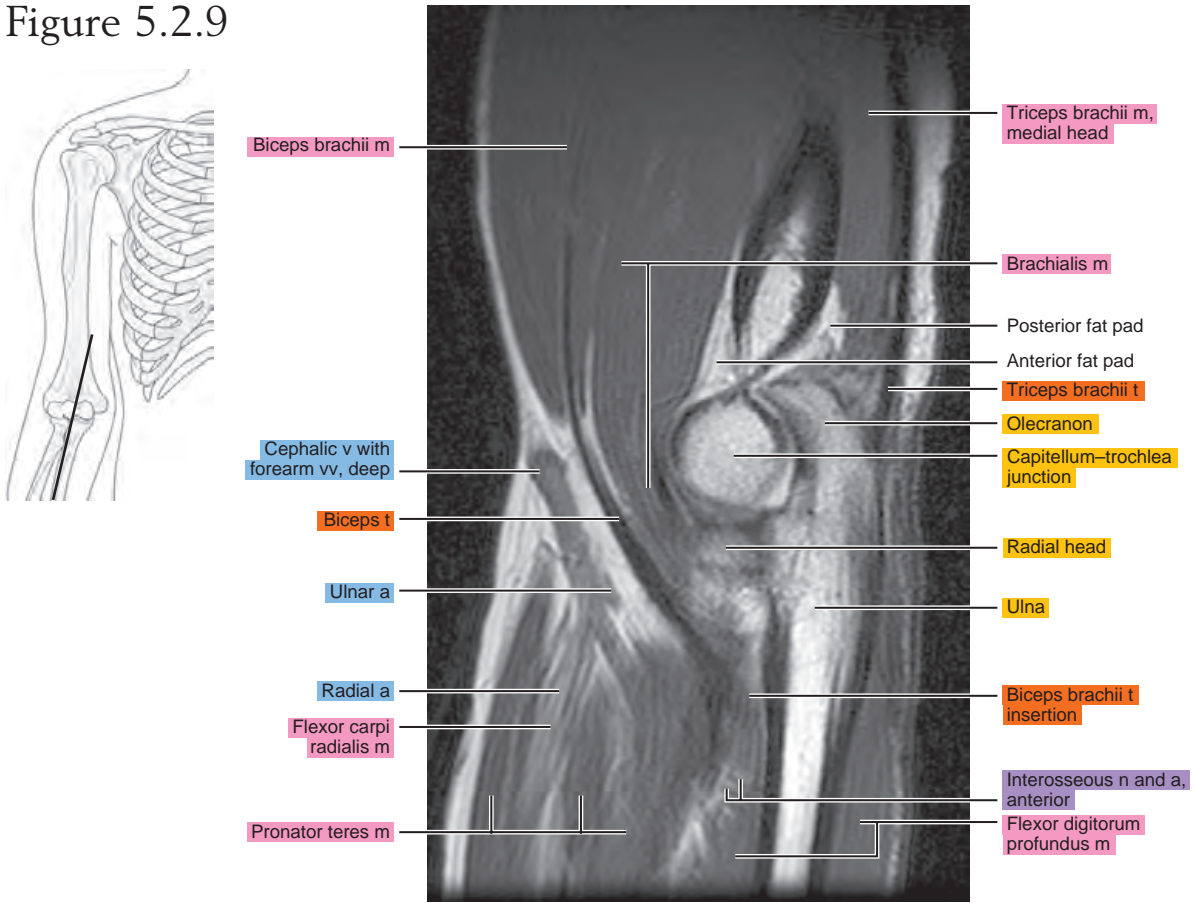


Figure 5.2.10

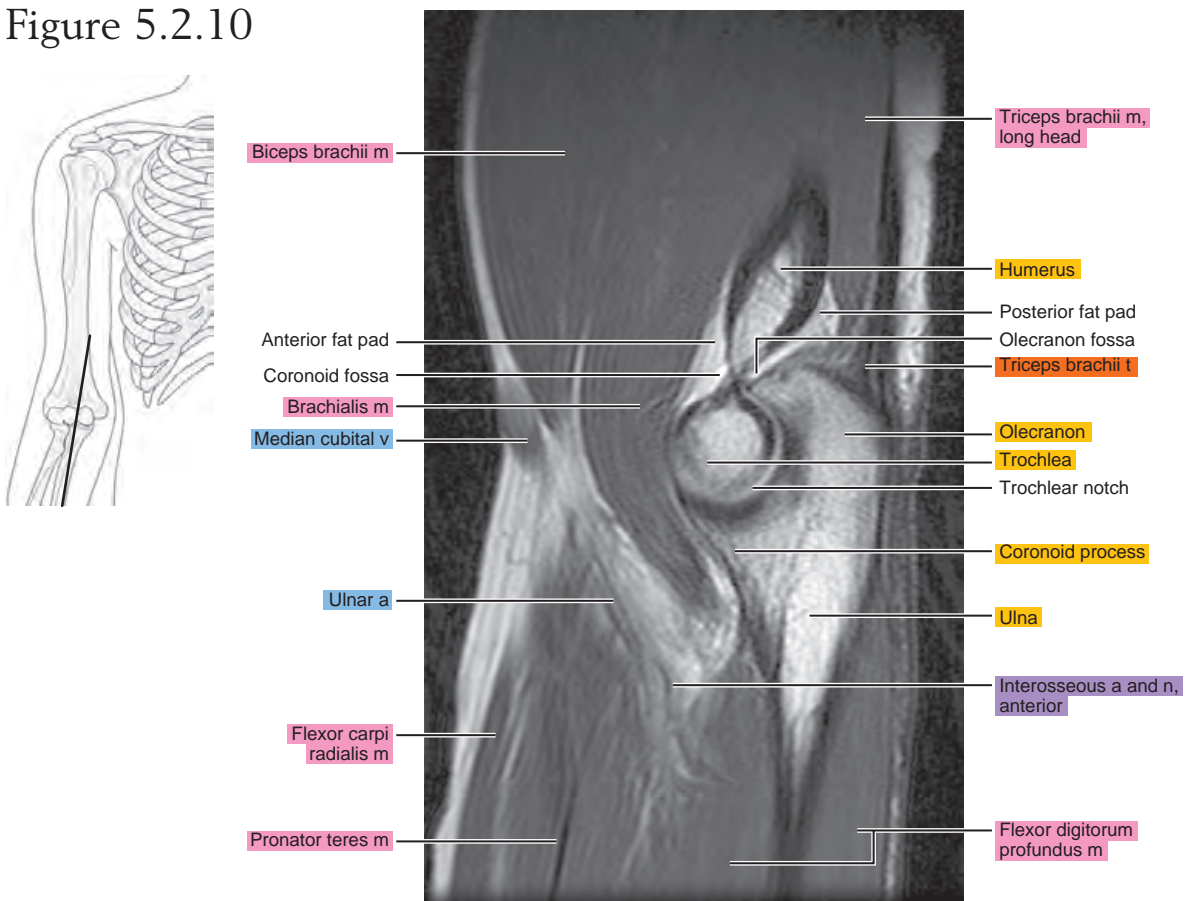


Figure 5.2.11

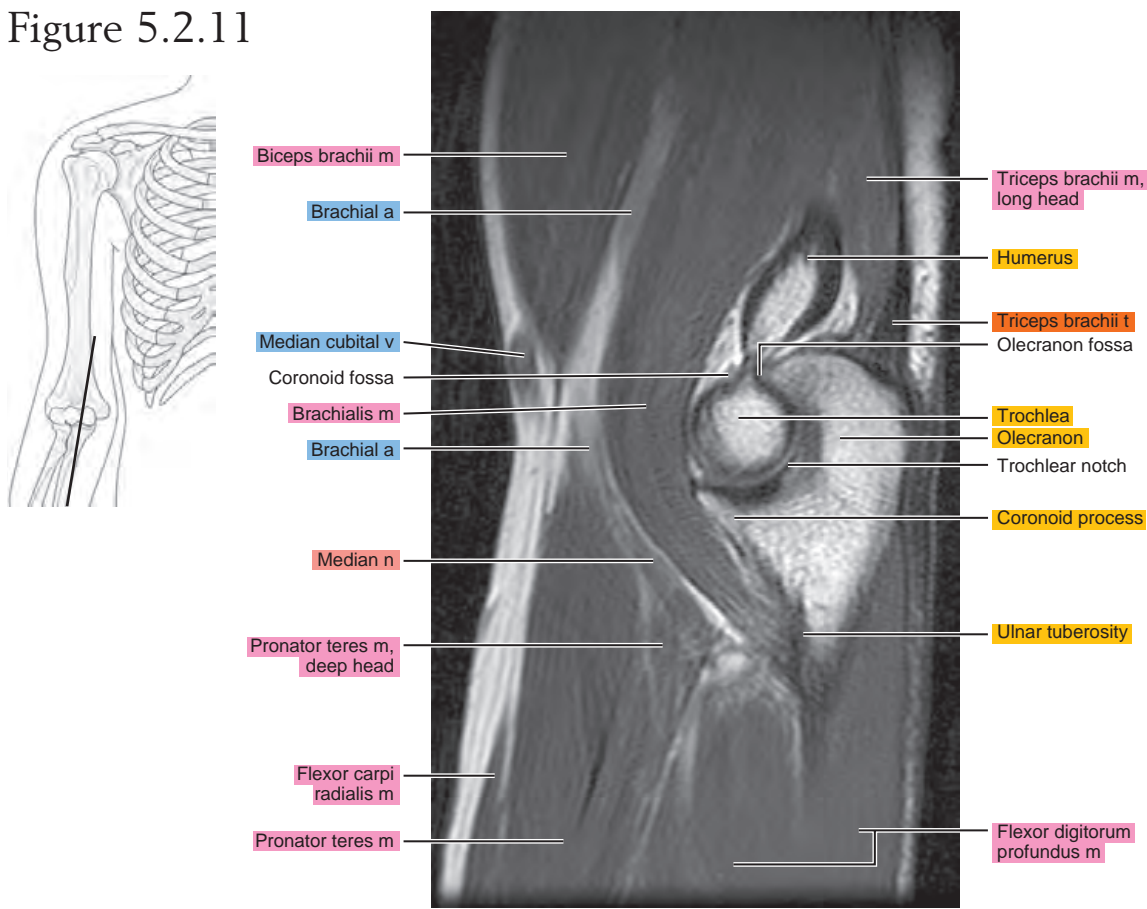


Figure 5.2.12

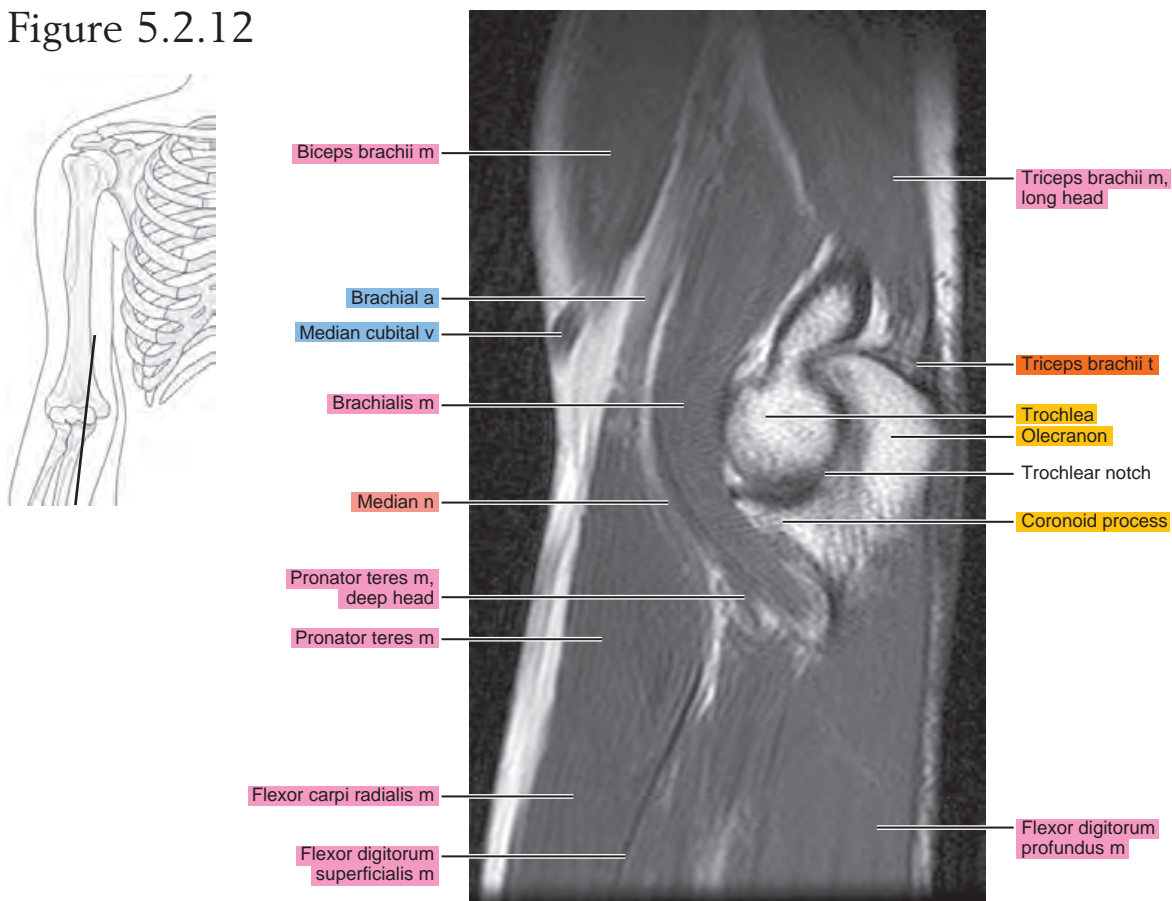


Figure 5.2.13

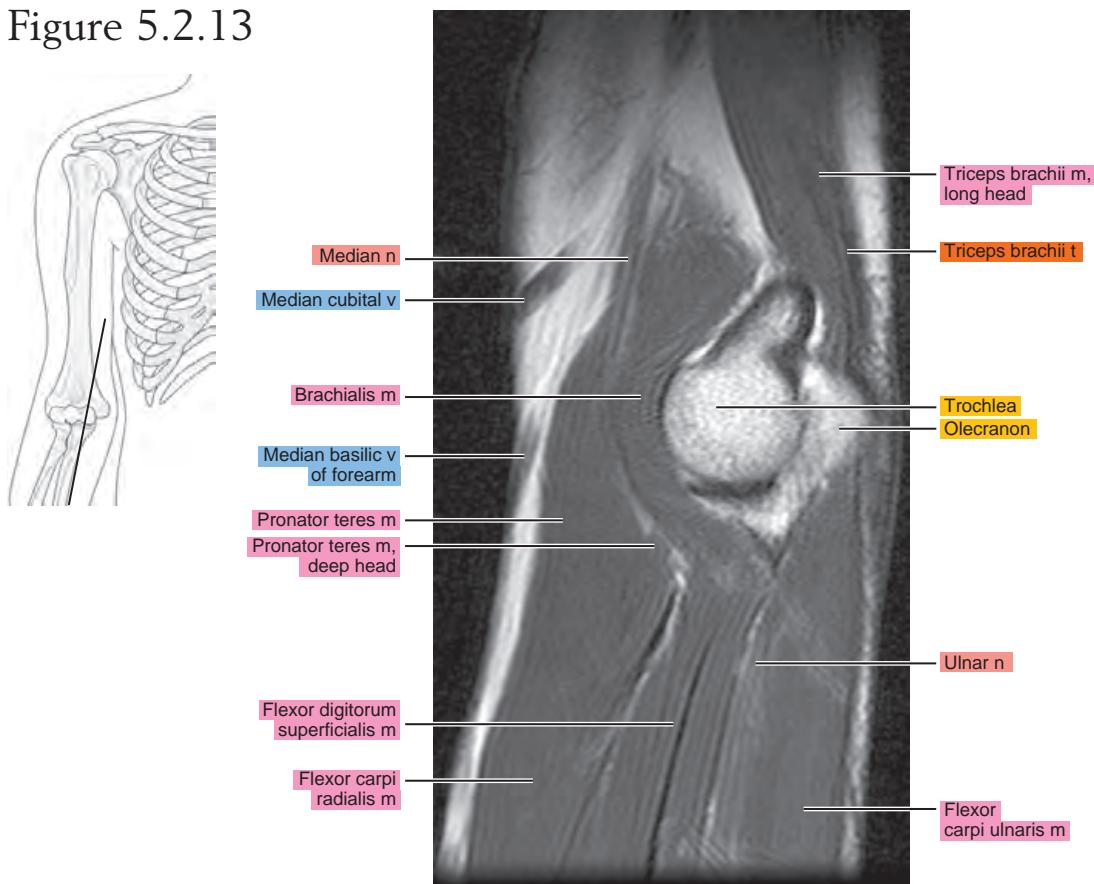


Figure 5.2.14

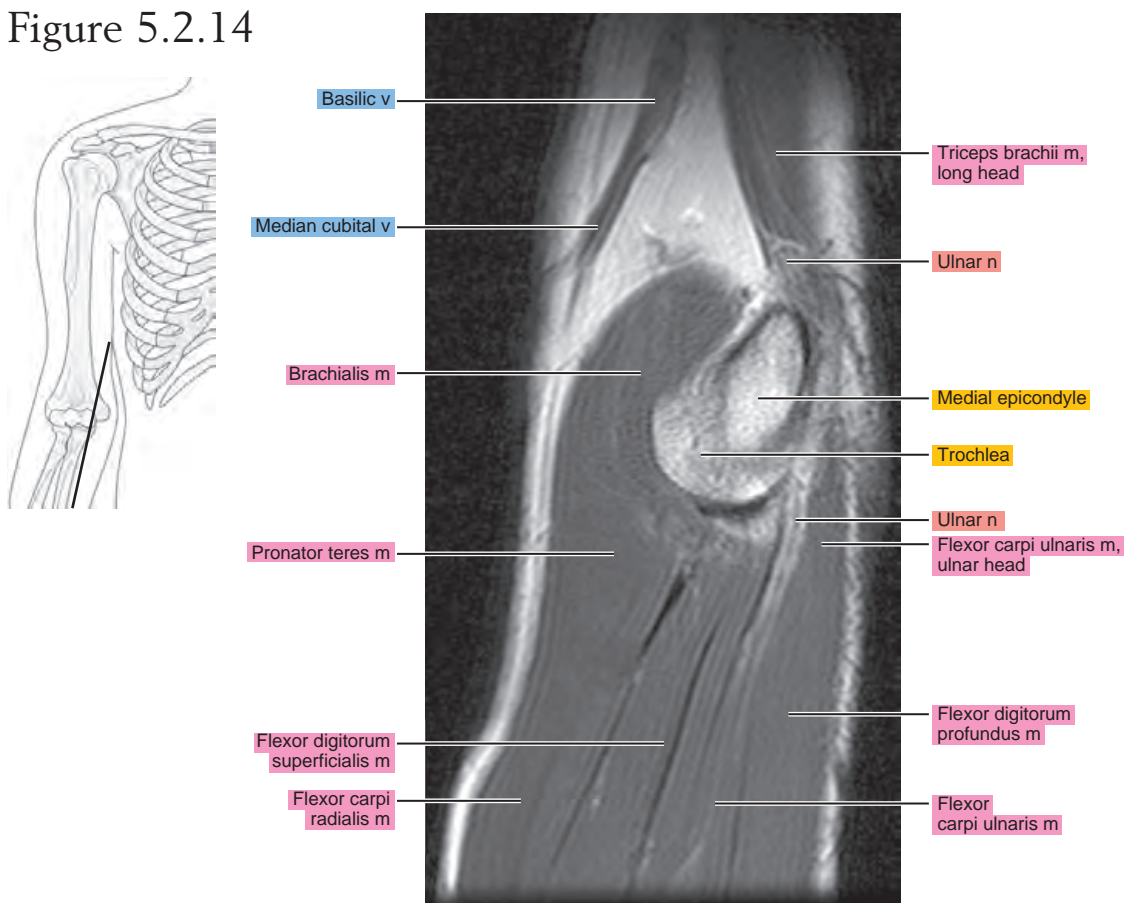


Figure 5.2.15

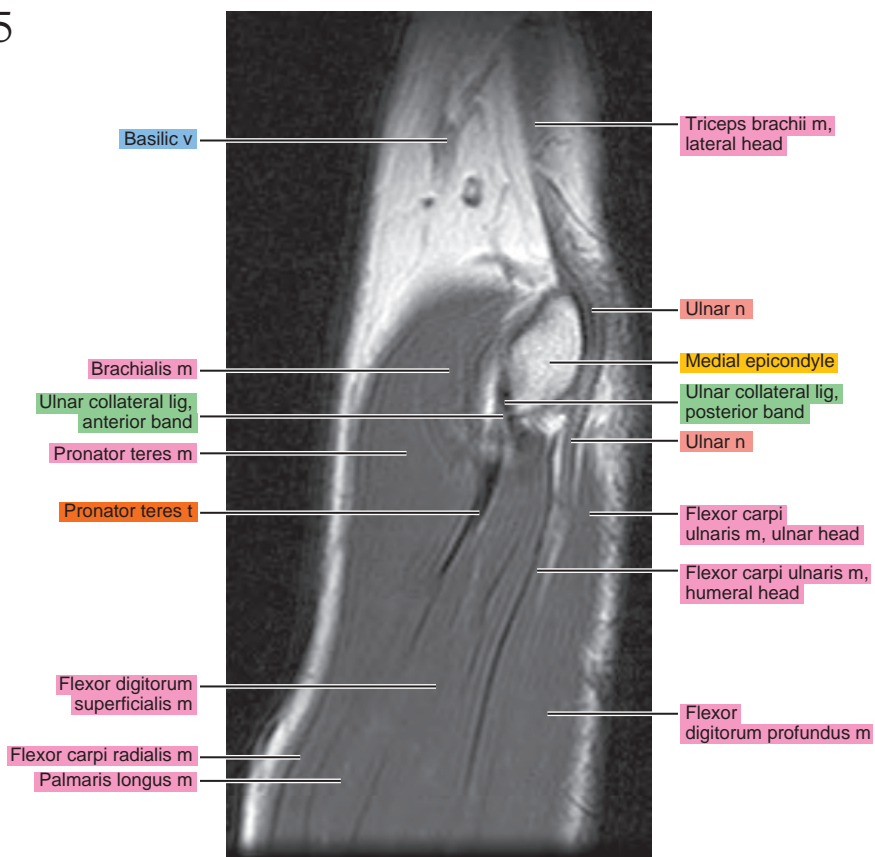
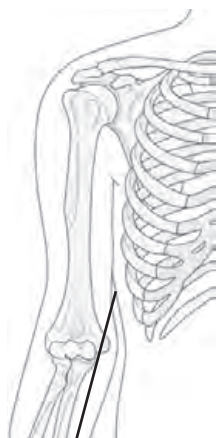


Figure 5.2.16

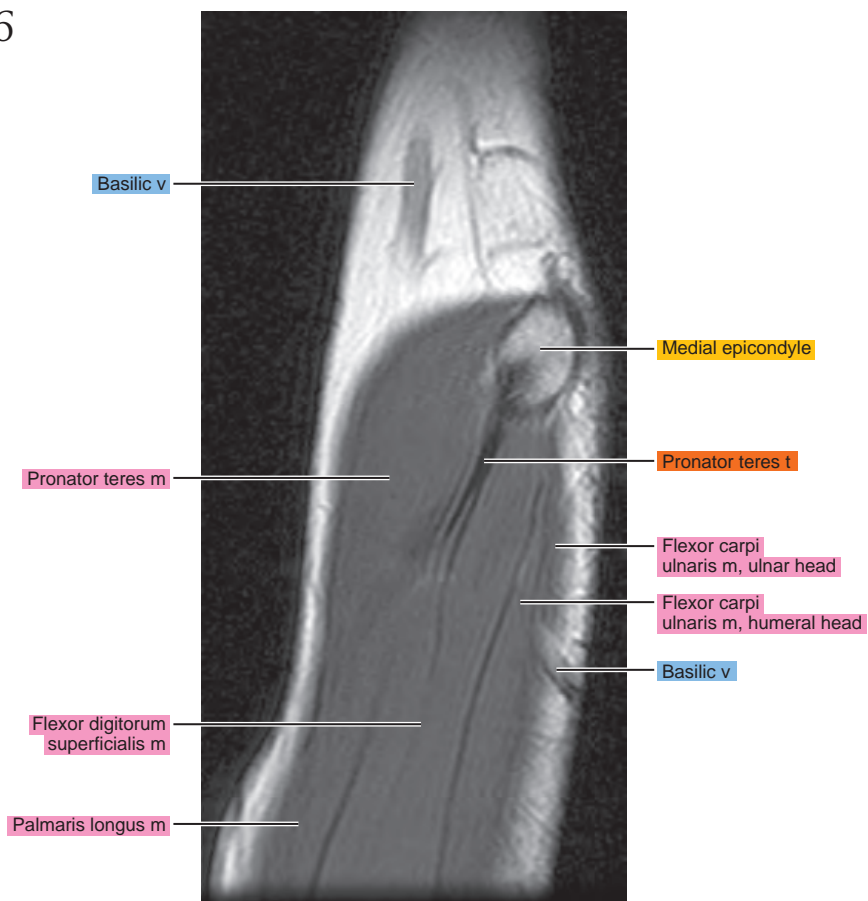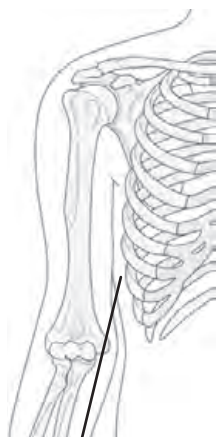
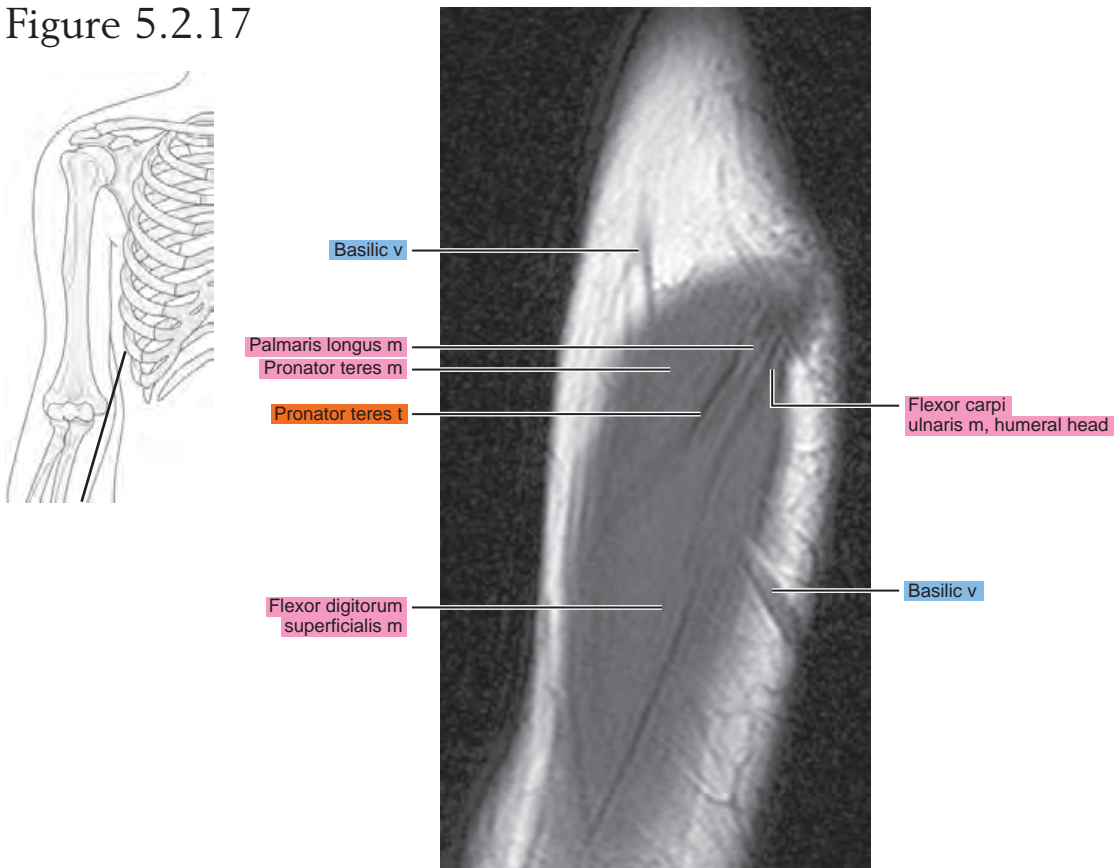


Figure 5.2.17



OBLIQUE CORONAL

Figure 5.3.1

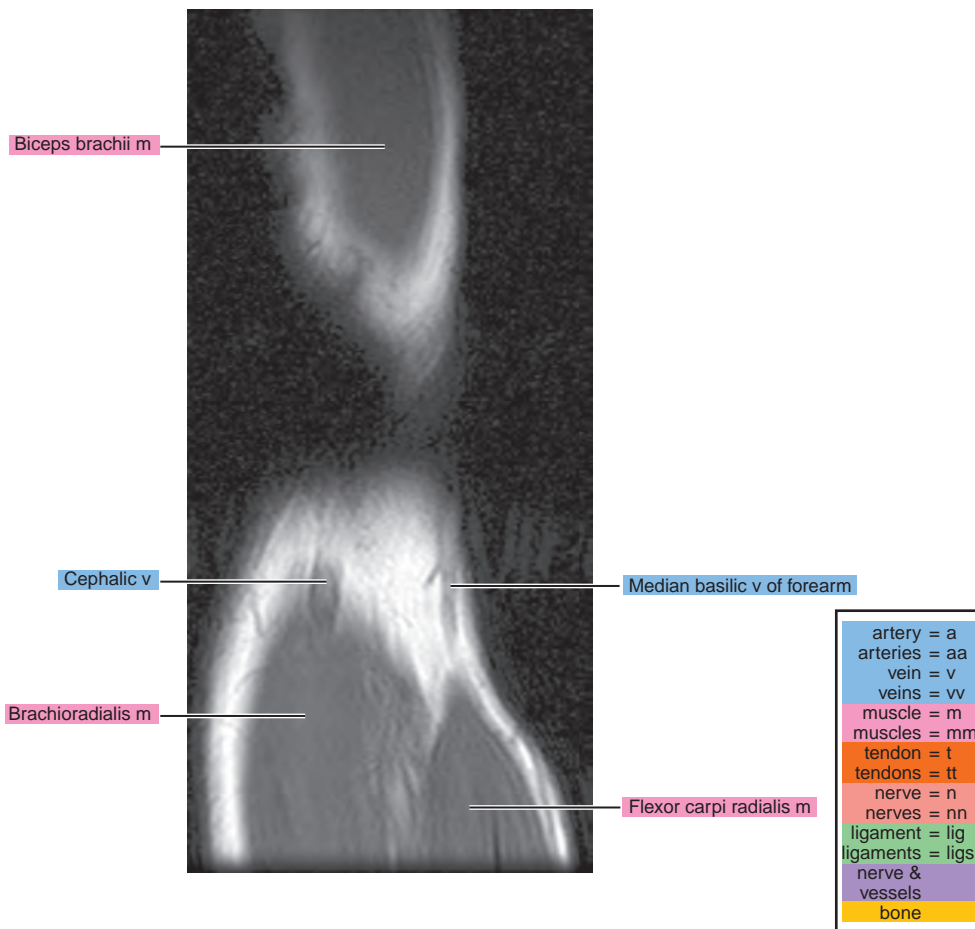
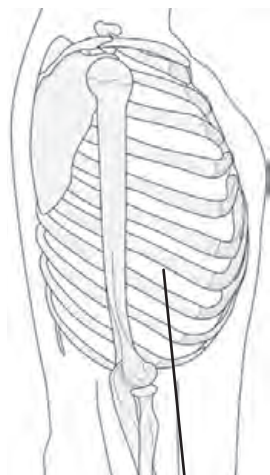


Figure 5.3.2

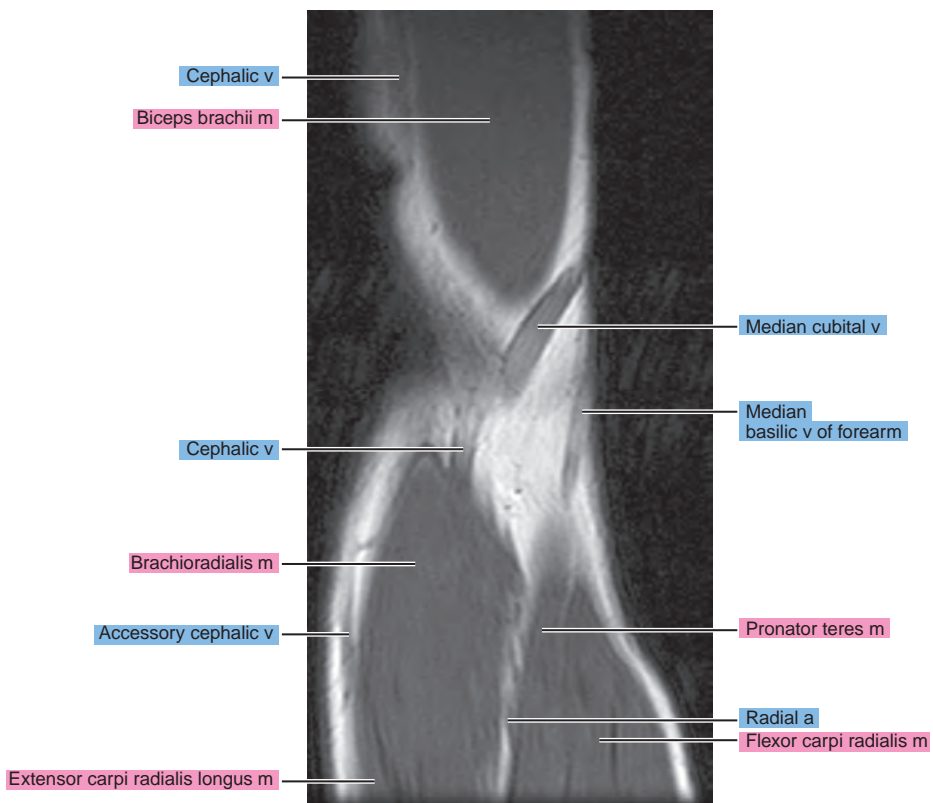
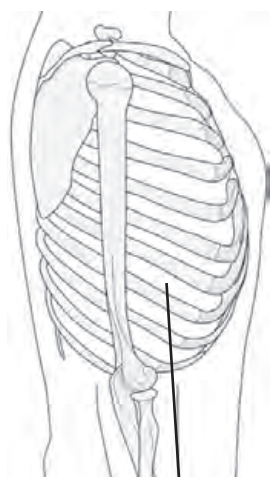


Figure 5.3.3

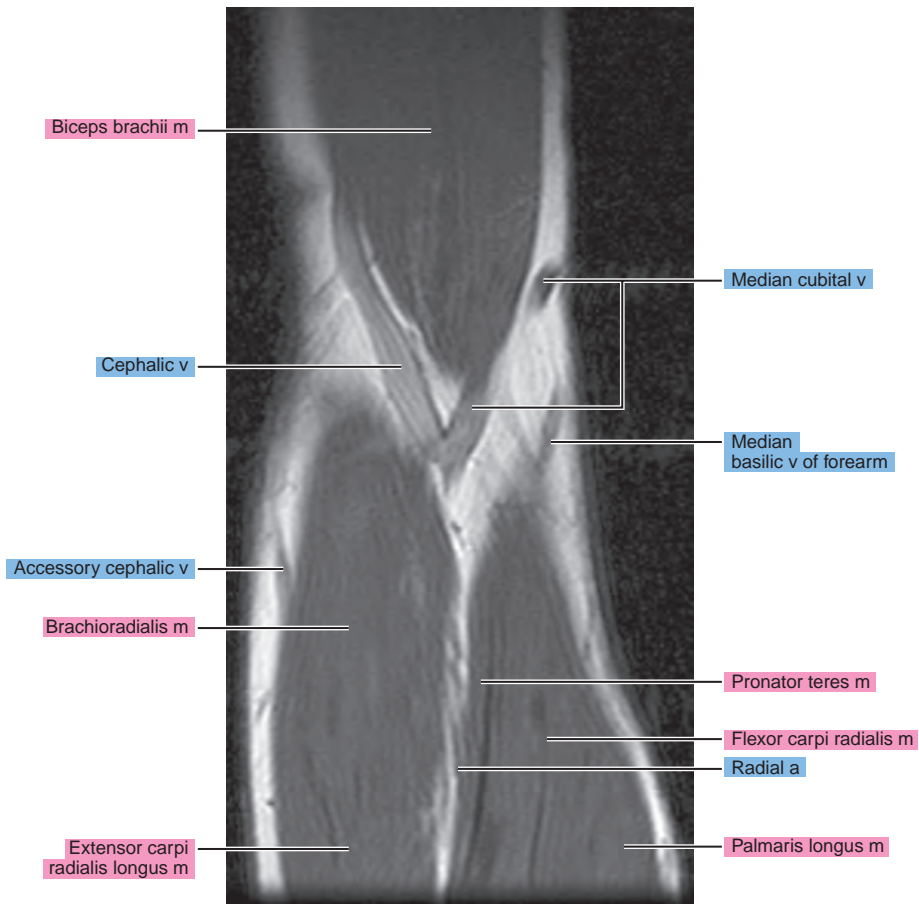
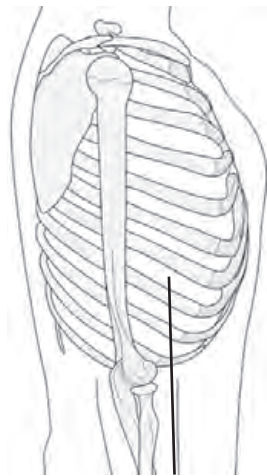


Figure 5.3.4

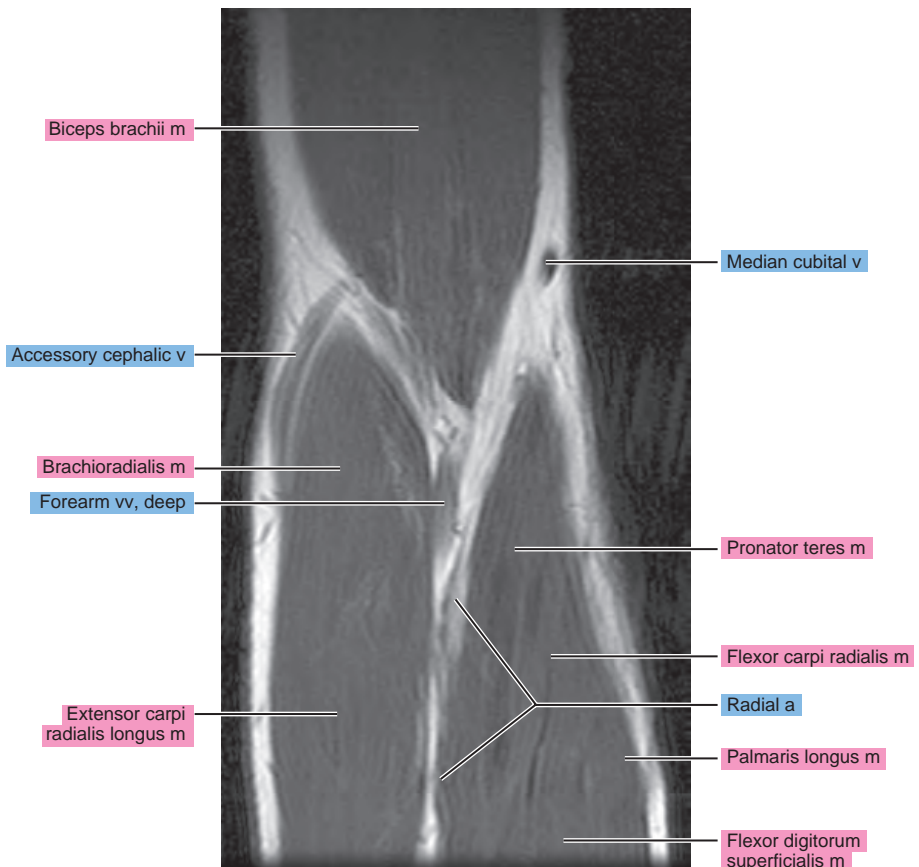
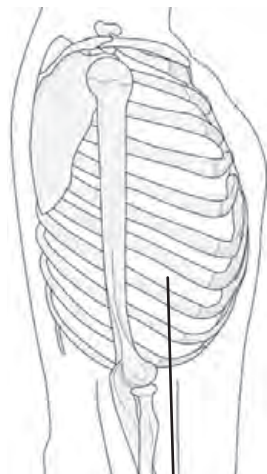


Figure 5.3.5

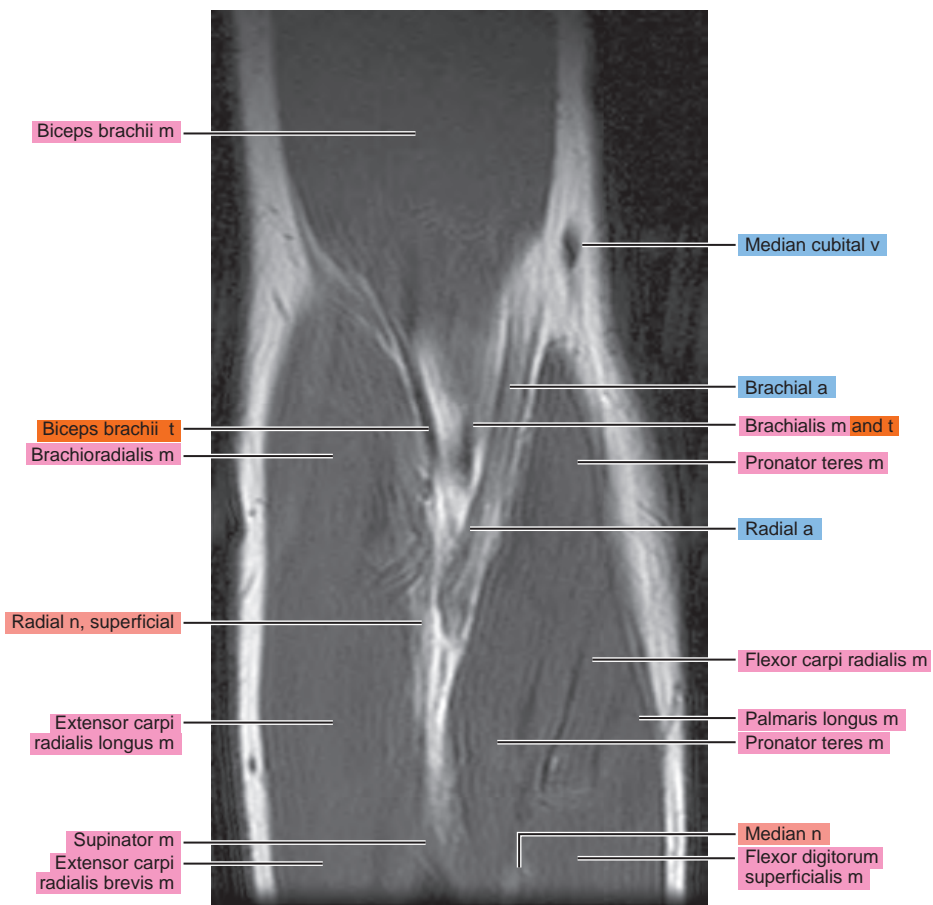
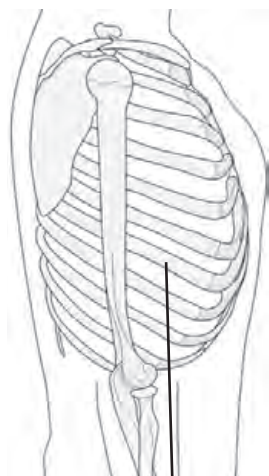


Figure 5.3.6

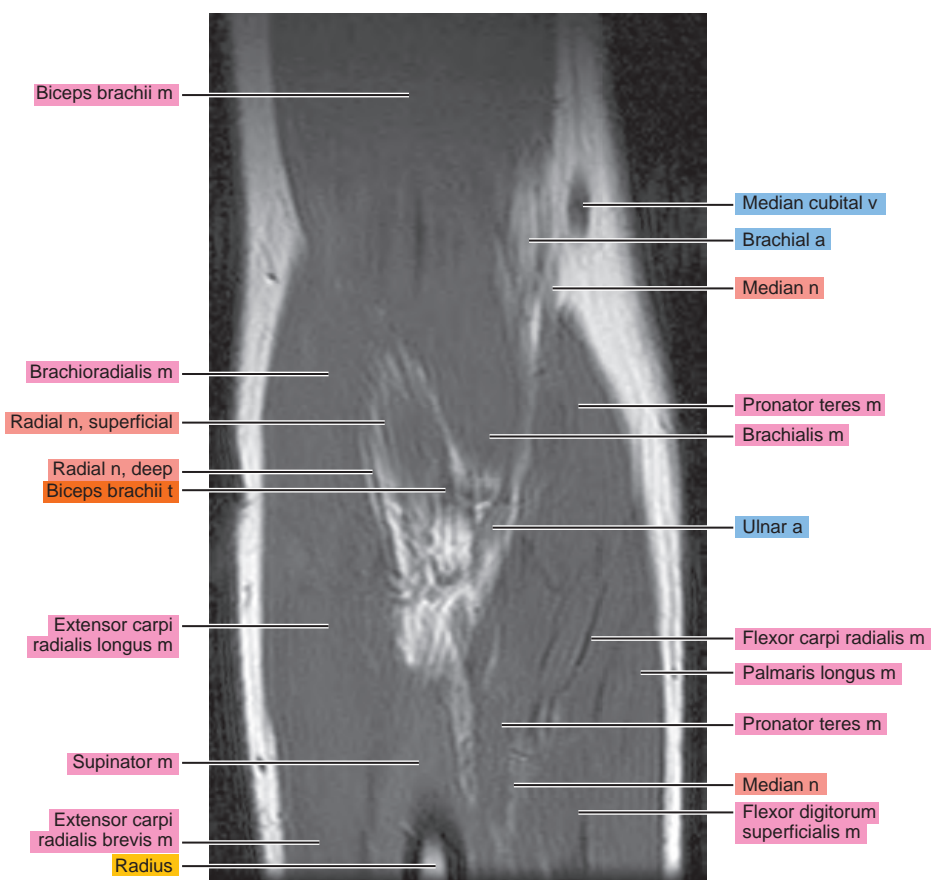
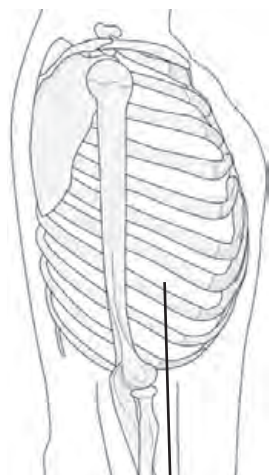


Figure 5.3.7

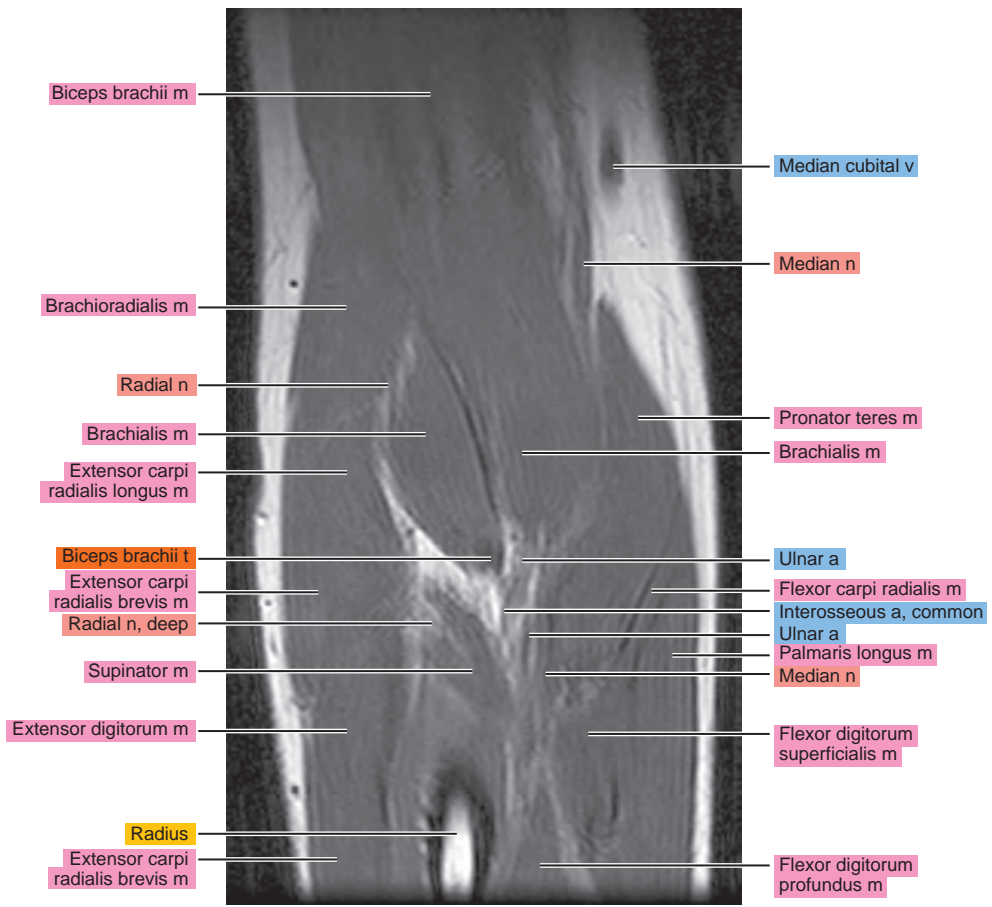
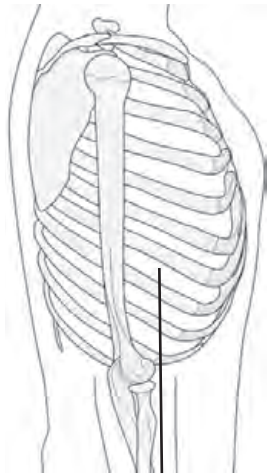


Figure 5.3.8

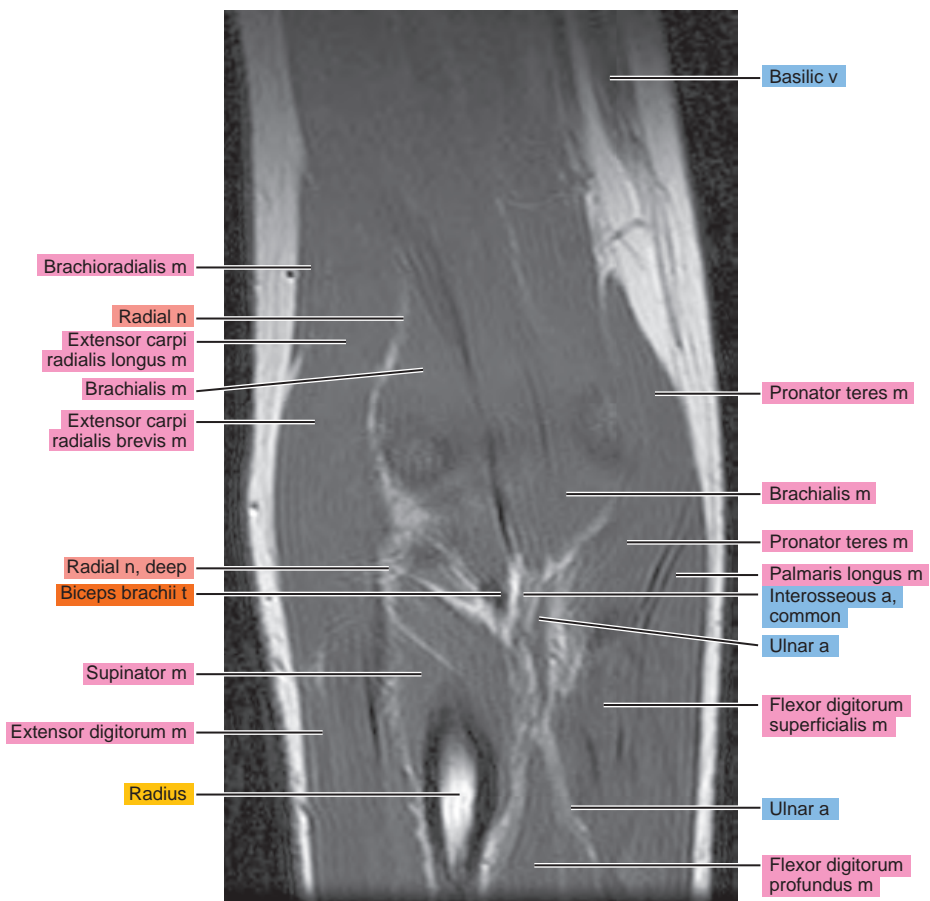
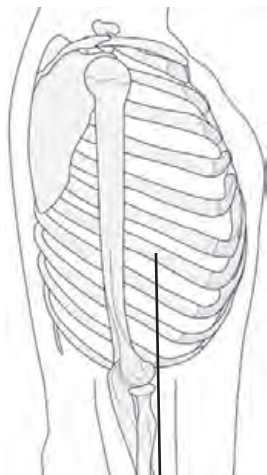


Figure 5.3.9

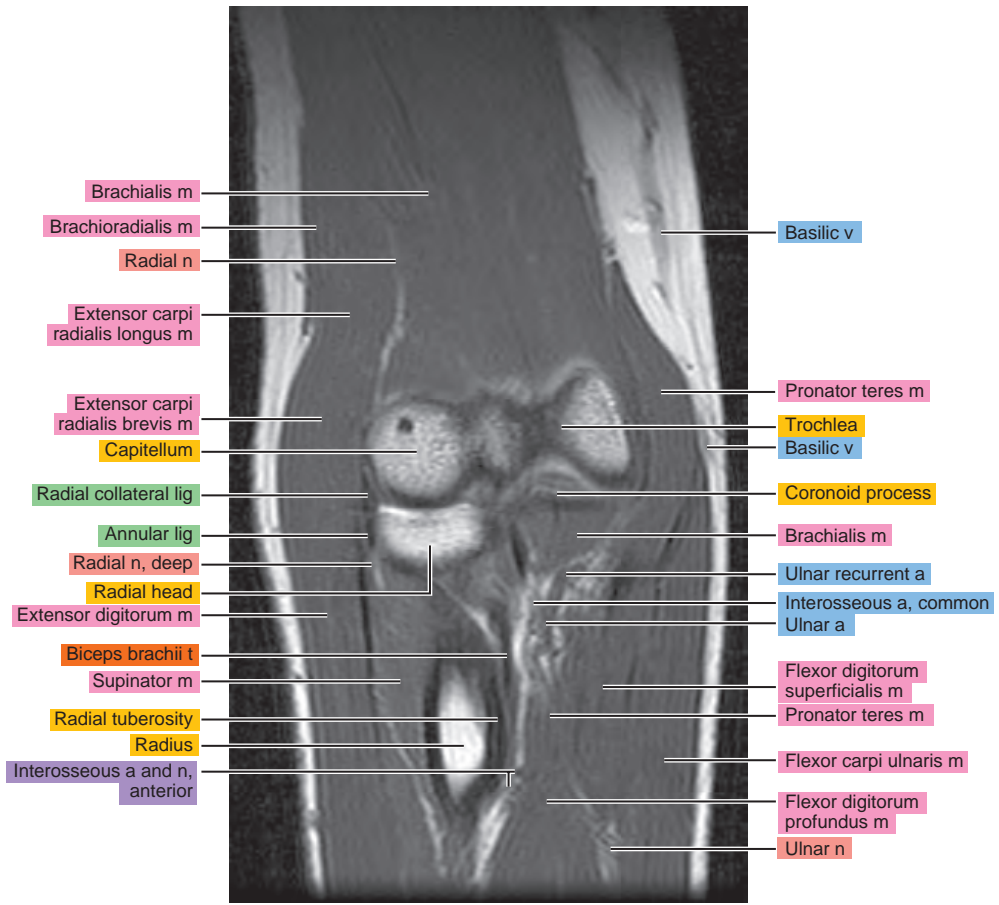
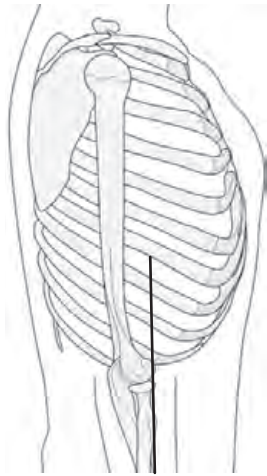


Figure 5.3.10

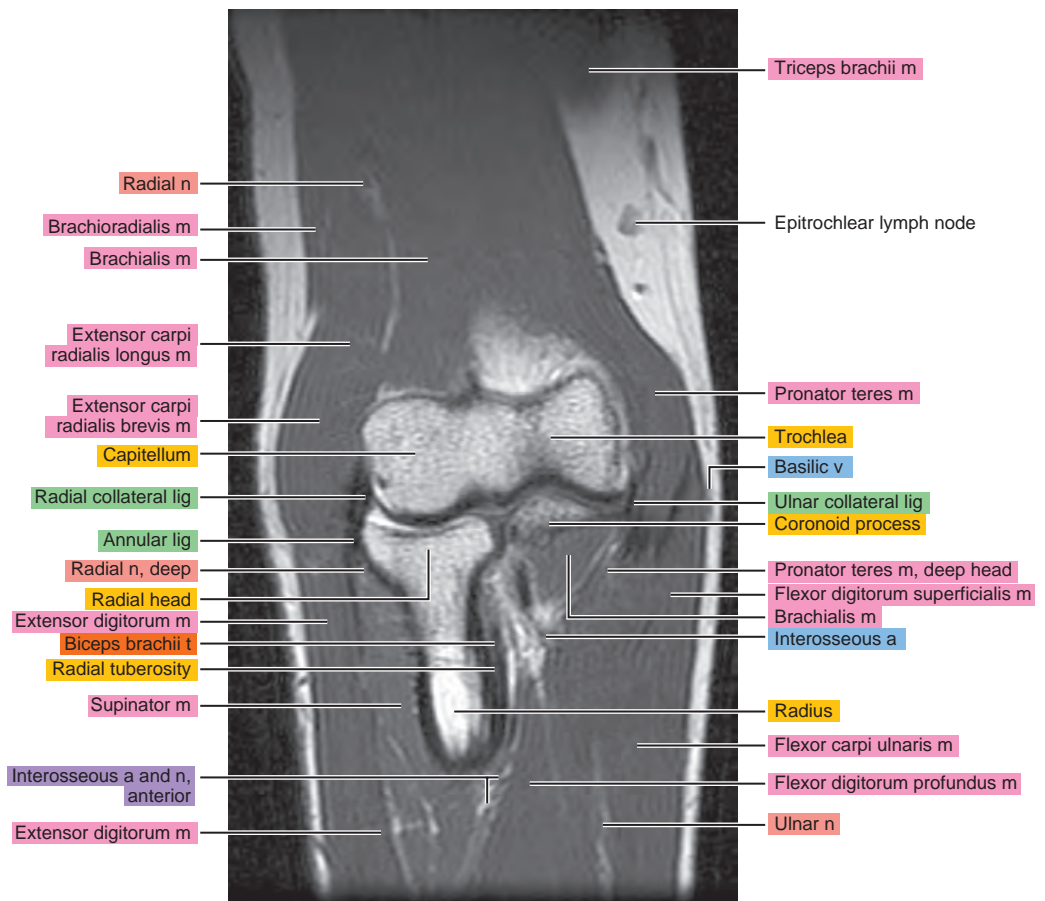
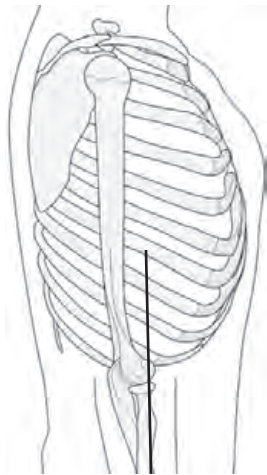


Figure 5.3.11

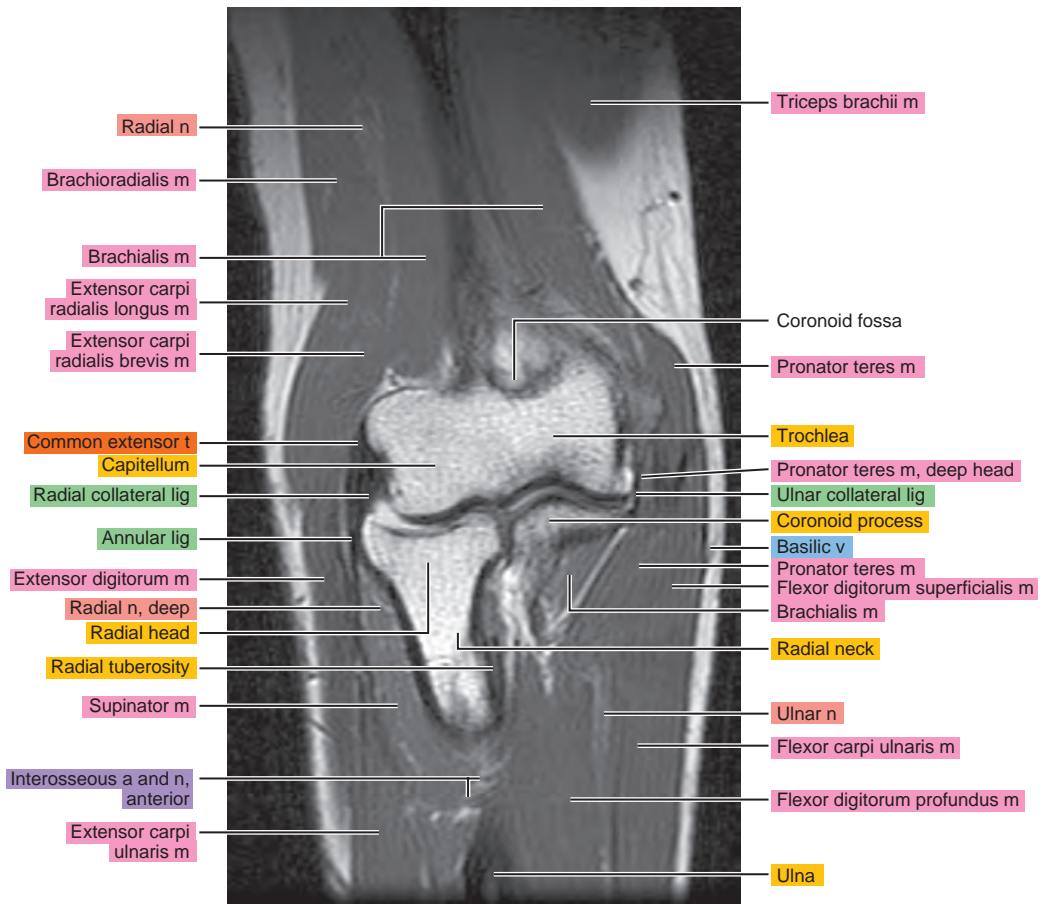
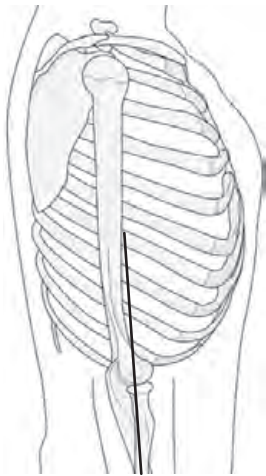


Figure 5.3.12

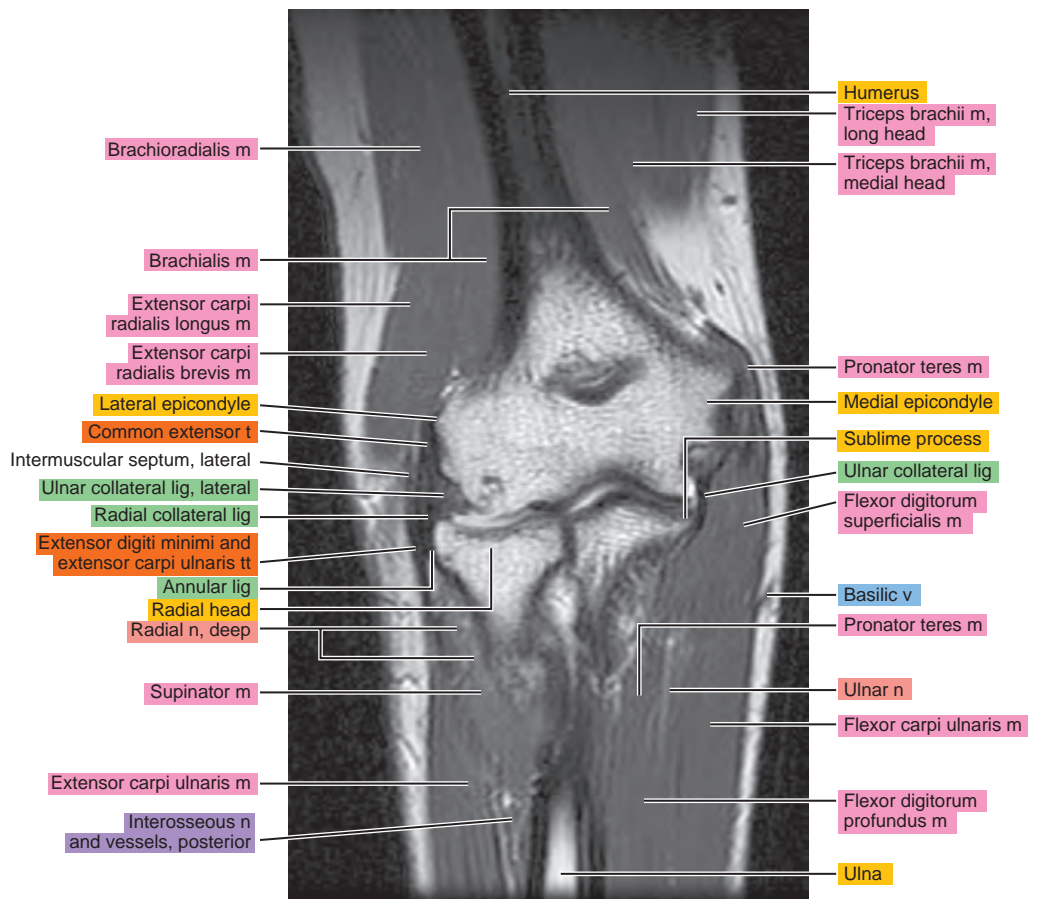
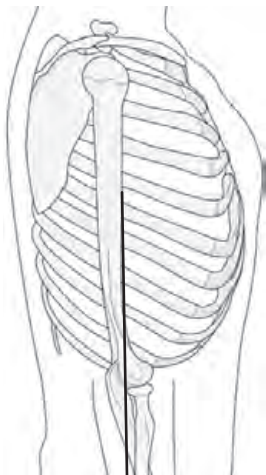


Figure 5.3.13

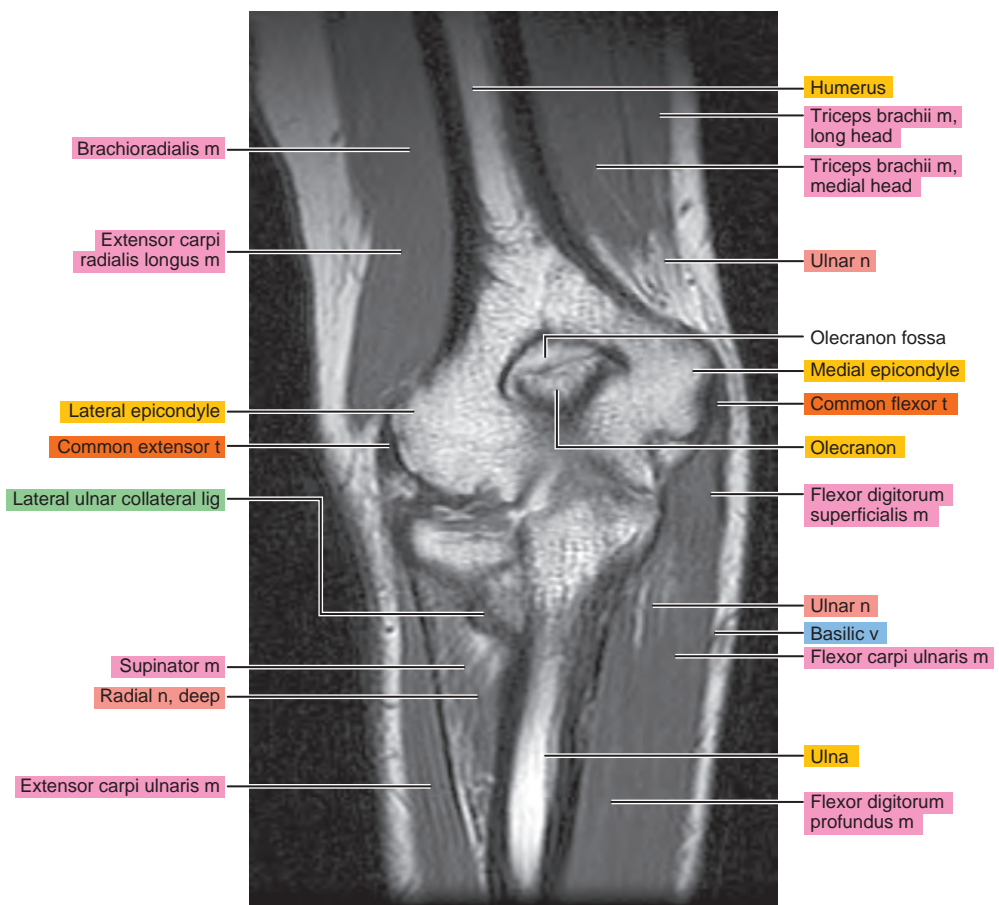
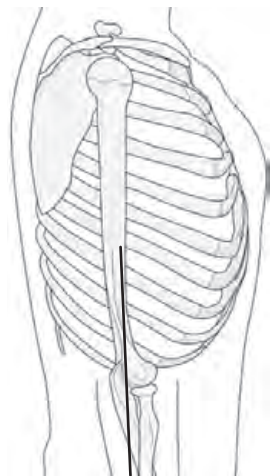


Figure 5.3.14

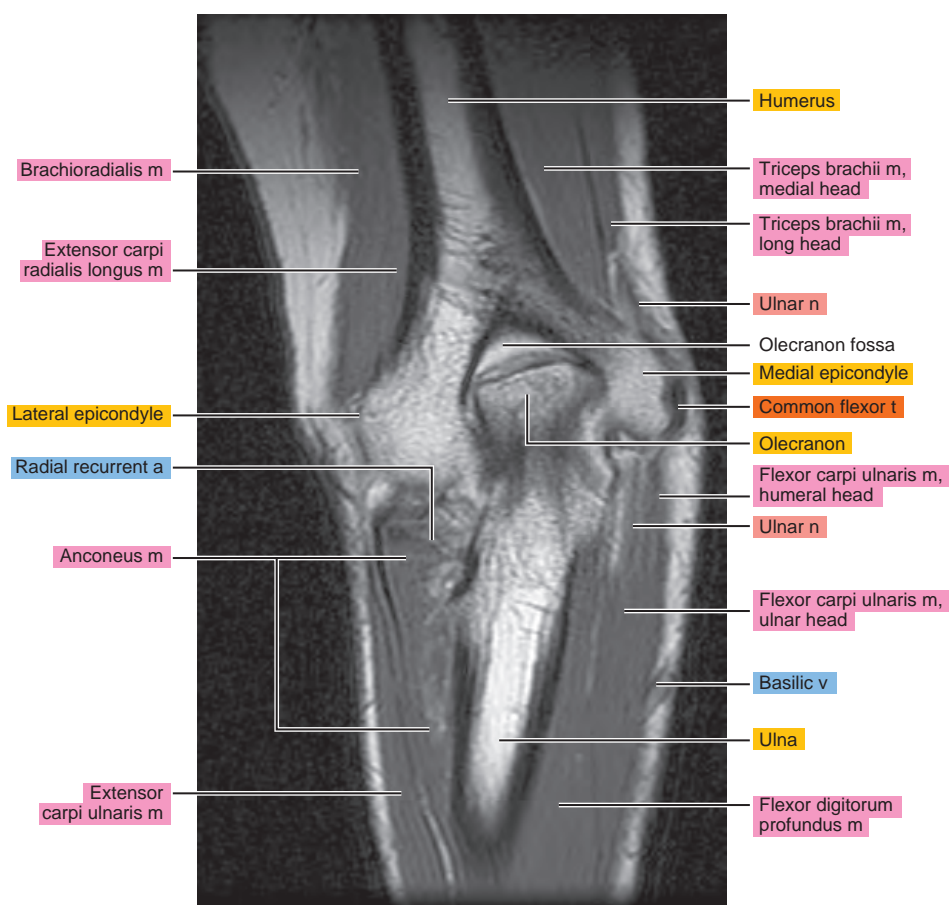
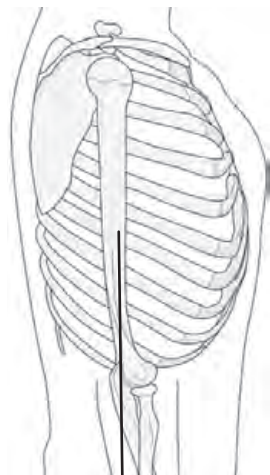


Figure 5.3.15

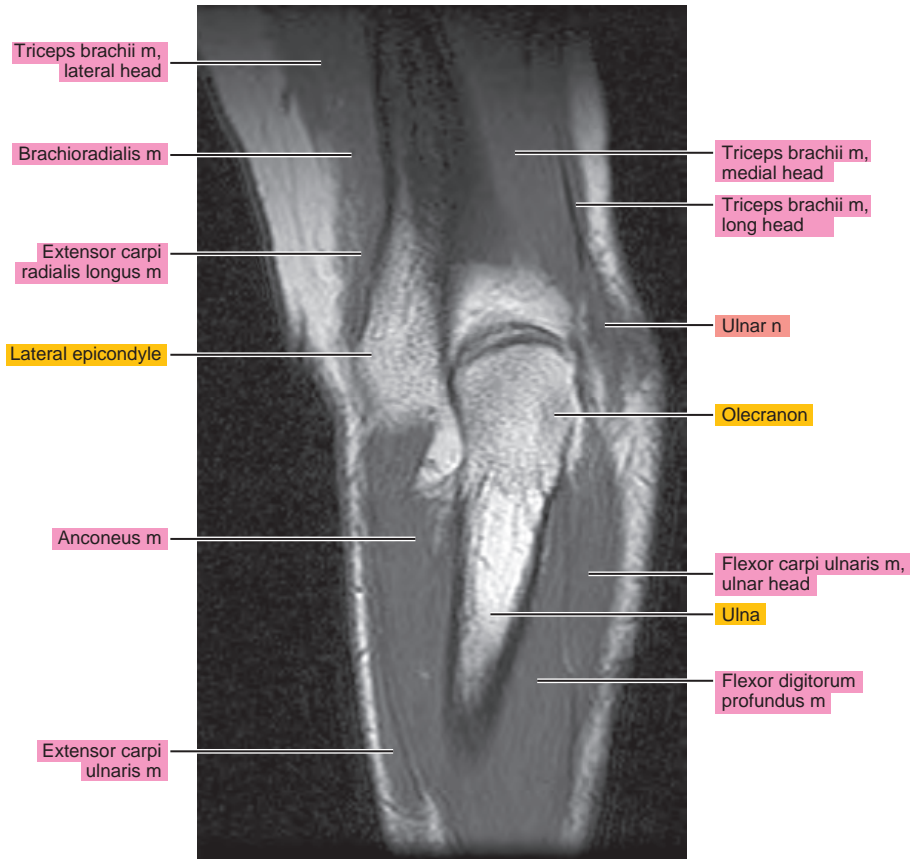
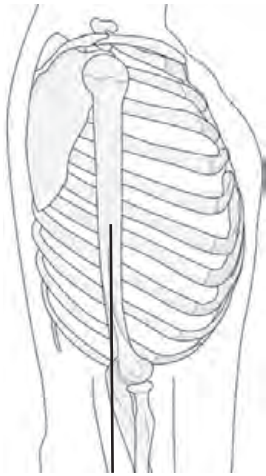


Figure 5.3.16

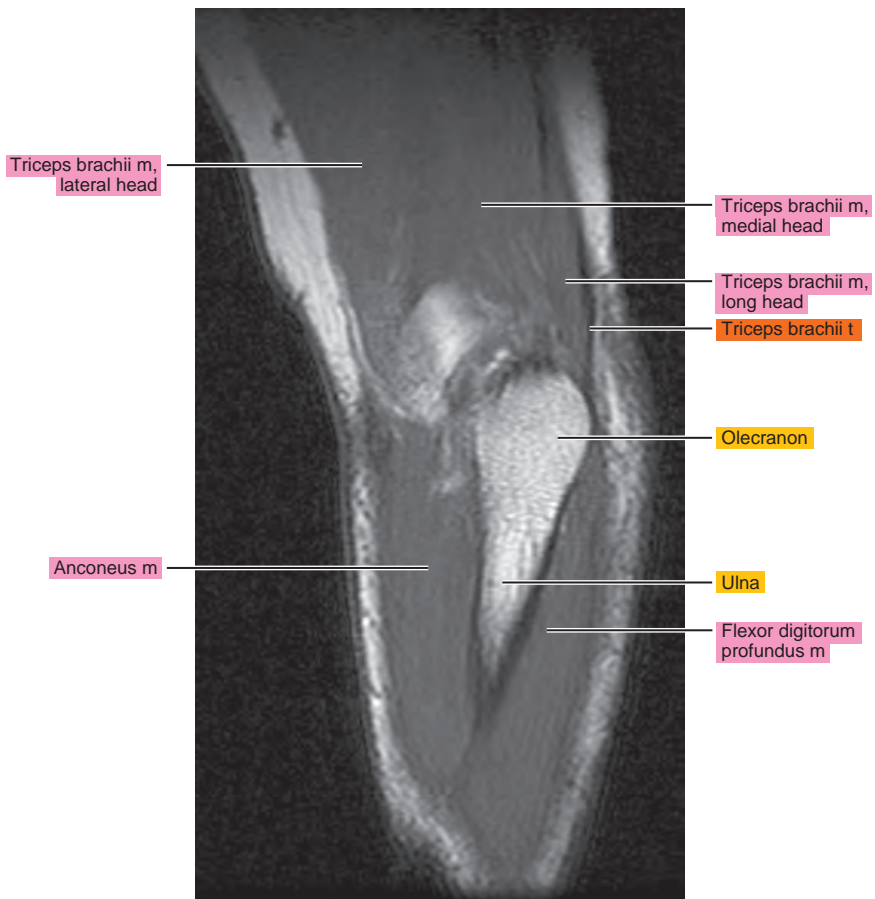
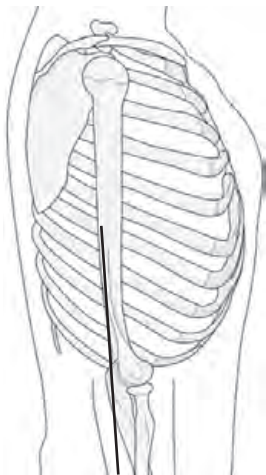
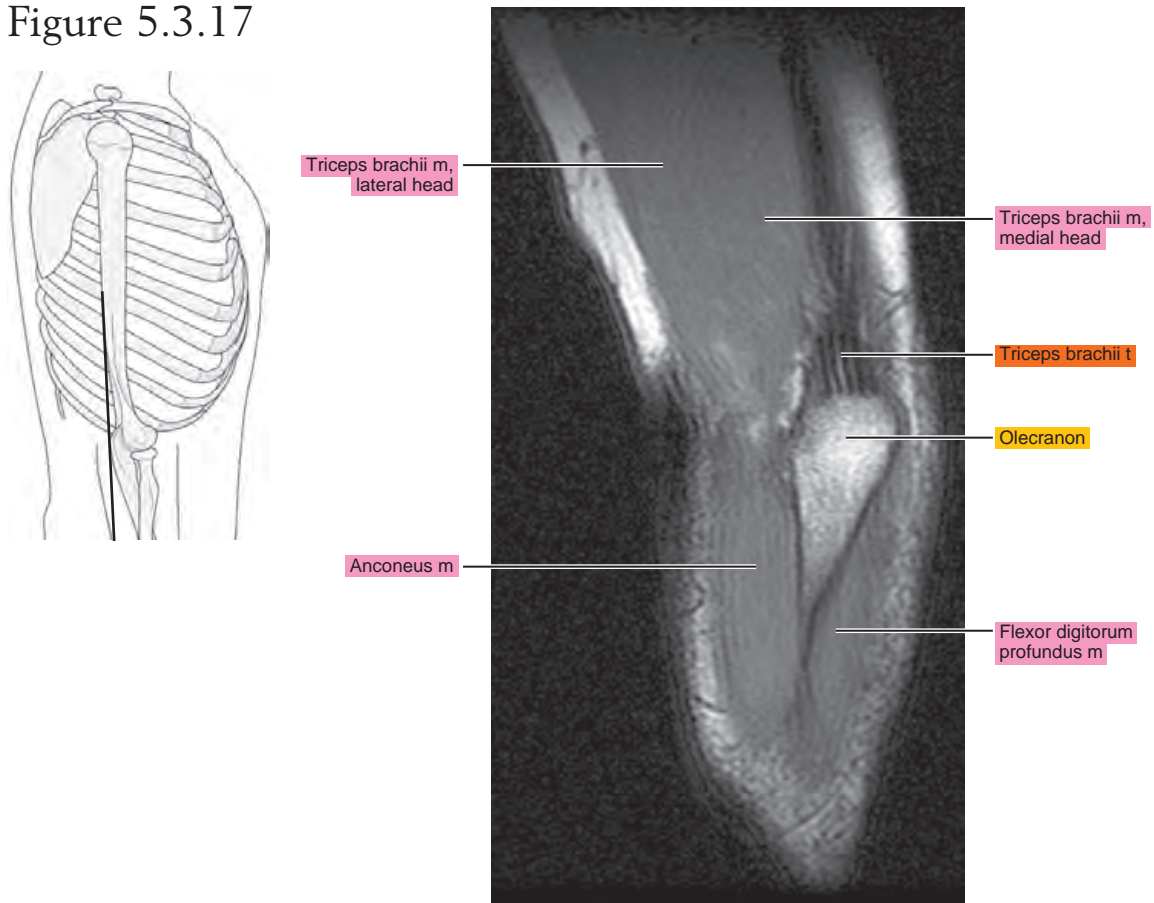


Figure 5.3.17



Chapter
6

MRI of the Forearm

Table 6-1. Muscles of the Forearm

MUSCLE	ORIGIN	INSERTION	NERVE SUPPLY
Anconeus	Posterior surface of the lateral epicondyle, and adjacent capsular ligament of the elbow	Onto the radial side of the olecranon and adjacent shaft of the ulna	Nerve to anconeus (C7, C8, T1)
Brachioradialis	Upper two thirds of the lateral epicondylar ridge of the humerus and the anterior surface of the lateral intermuscular septum	Lateral side of the base of the styloid process of the radius	Radial (C5, C6, C7)
Extensor carpi radialis longus	Lower third of the lateral epicondylar ridge, lateral intermuscular septum, and extensor tendons from the lateral epicondyle	Lateral aspect of the base of the second metacarpal	Radial (C5, C6, C7)
Extensor carpi radialis brevis	Common extensor tendon from the lateral epicondyle, intermuscular septa, and radial collateral ligament of the elbow joint	Dorsal aspect of the base of the third metacarpal	Radial or deep radial (posterior interosseus) (C7, C8)
Extensor digitorum	Common extensor tendon	Dorsal digital fibrous expansion covering the dorsum of the proximal phalanx and sides of its base, base of the middle, and distal phalanges	Deep radial (posterior interosseus) (C7, C8)
Extensor digiti minimi	Intermuscular septa, overlying fascia, and common extensor tendon	Base of the proximal phalanx of the little finger	Deep radial (posterior interosseus) (C7, C8)
Extensor carpi ulnaris	Two heads: (1) distal dorsal aspect of the lateral epicondyle, and (2) proximal three fourths of the dorsal border of the ulna	Onto a tubercle at the base of the fifth metacarpal	Deep radial (posterior interosseus) (C7, C8)
Supinator	Dorsal aspect of the lateral epicondyle, ulnar depression distal to the radial notch, and supinator crest	Lateral surface of the radius between the anterior and posterior oblique lines	Deep radial (posterior interosseus) (C5, C6)
Abductor pollicis longus	Lateral edge of the proximal part of the middle third of the ulna, adjacent interosseous membrane, dorsal surface of the radius, and, occasionally, the intermuscular septa	Radial side of the ventral aspect of the base of the first metacarpal	Deep radial (posterior interosseus) (C7, C8)
Extensor pollicis brevis	Distal end of the middle third of the radius in its dorsal surface, interosseous membrane, and, occasionally, the ulna	Base of the proximal phalanx of the thumb or into the capsule the metacarpophalangeal joint	Deep radial (posterior of interosseus) (C7, C8)
Extensor pollicis longus	Middle third of the dorsal surface of the ulna adjacent to the interosseous membrane	Base of the distal phalanx of the thumb	Deep radial (posterior interosseus) (C7, C8)
Extensor indicis	Proximal part of the distal third of the posterior surface of the ulna interosseous membrane	Dorsal aponeurosis on the ulnar side of the index finger, adjacent to the base of the proximal phalanx	Deep radial (posterior interosseus) (C7, C8)
Pronator teres	Two heads: (1) humeral head (superior half of the ventral surface of the medial epicondyle), and (2) ulnar head (medial border of the coronoid process)	Onto the middle third of lateral surface of the radius	Median (C6, C7)
Flexor carpi radialis	Medial epicondyle of the humerus	Base of the second metacarpal and usually, base of the third metacarpal	Median (C6, C7)

Table 6-1. Muscles of the Forearm—cont'd

MUSCLE	ORIGIN	INSERTION	NERVE SUPPLY
Palmaris longus	Medial epicondyle	Flexor retinaculum and palmar aponeurosis	Median (C7, C8)
Flexor carpi ulnaris	Two heads: (1) medial epicondyle, and (2) medial side of the olecranon, upper two thirds of the dorsal border of the ulna	Primarily onto the pisiform	Ulnar (C7, C8)
Flexor digitorum superficialis	Two heads: (1) ulnar (ventral surface of the medial epicondyle, ulnar collateral ligament, ulnar tuberosity, medial border of coronoid process), and (2) radial (anterior oblique line and ventral border below the radial oblique line)	Ventral surface of the shaft of the middle phalanx of each finger	Median (C7, C8, T1)
Flexor digitorum profundus	Proximal three fourths of the medial and anterior surface of the ulna and interosseous membrane	Bases of the distal phalanges of the second to fifth digits	Median, anterior interosseous branch (C8, T1)
Flexor pollicis longus	Ventral surface of the radius, oblique line, and adjacent interosseous membrane	Base of the distal phalanx of the thumb	Median, anterior interosseous branch (C8, T1)
Pronator quadratus	Medial side, ventral surface of the distal fourth of the ulna	Distal quarter of the ventral surface of the radius	Median, anterior interosseous branch (C8, T1)

AXIAL

Figure 6.1.1

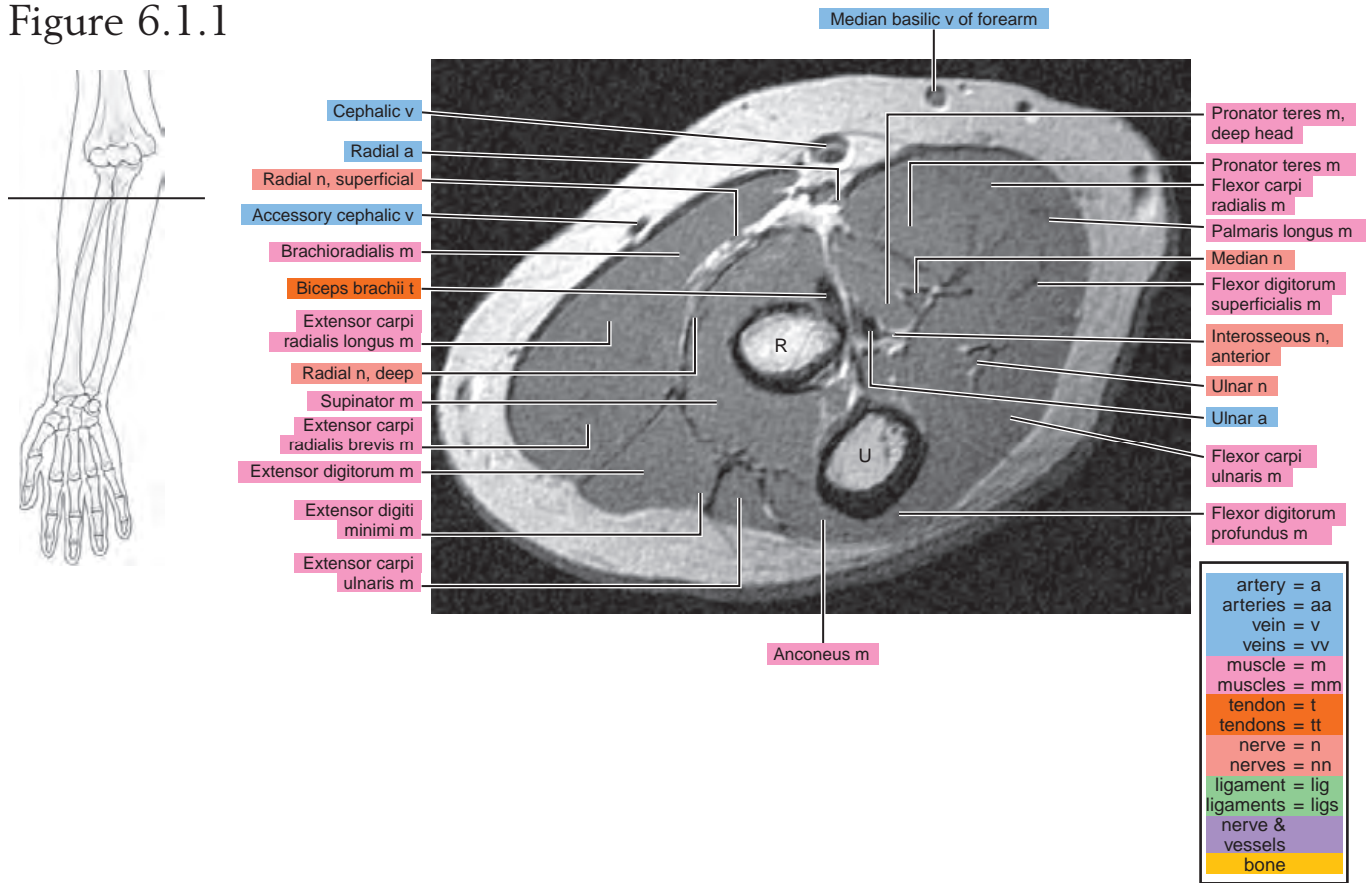


Figure 6.1.2

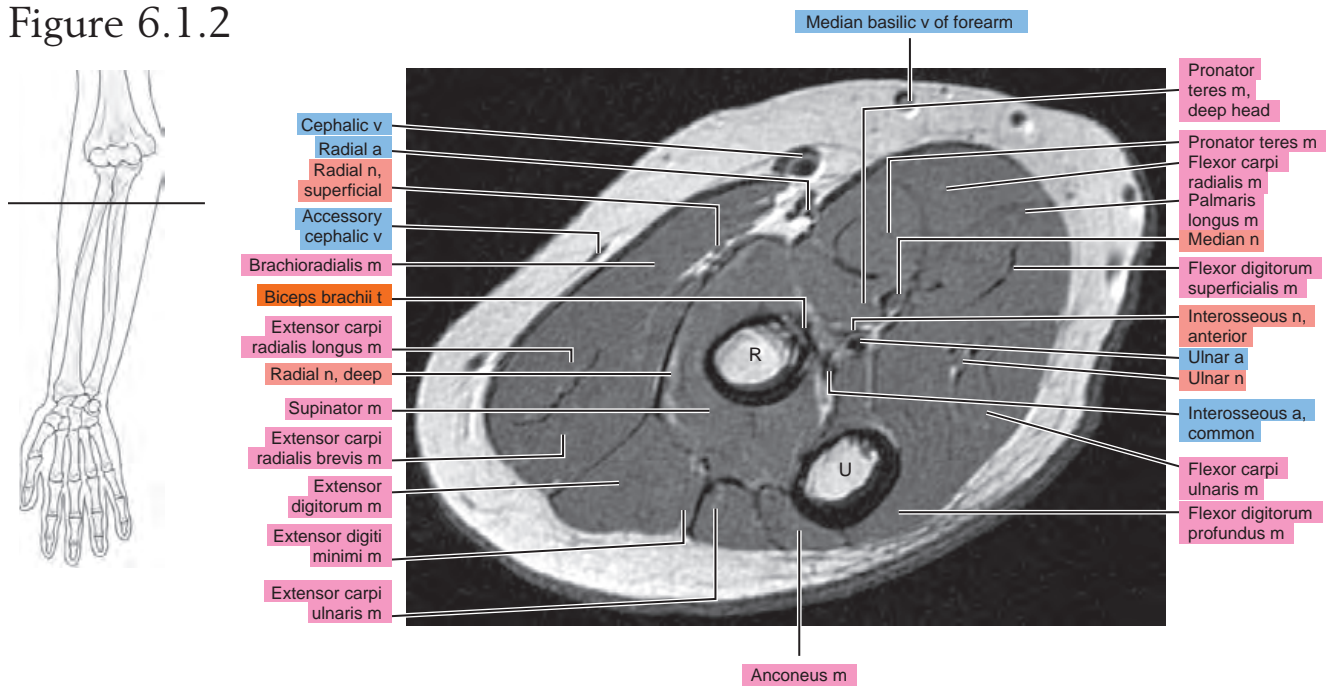


Figure 6.1.3

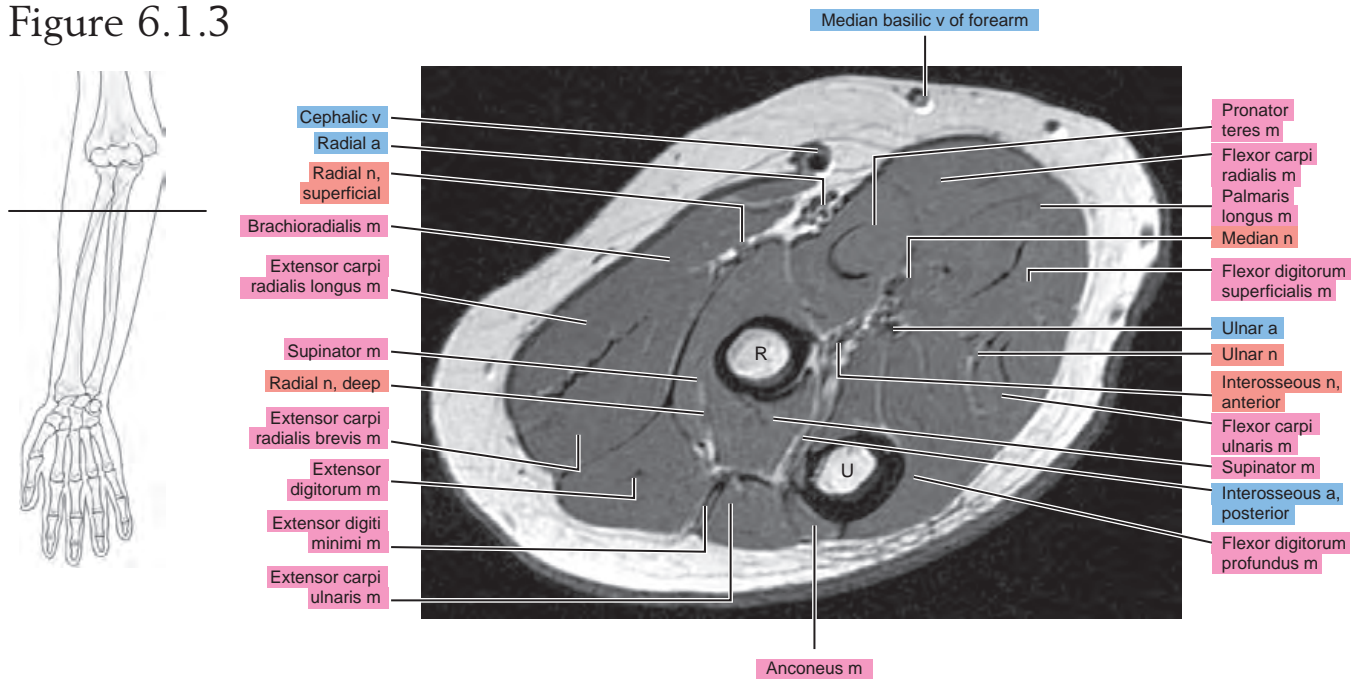


Figure 6.1.4

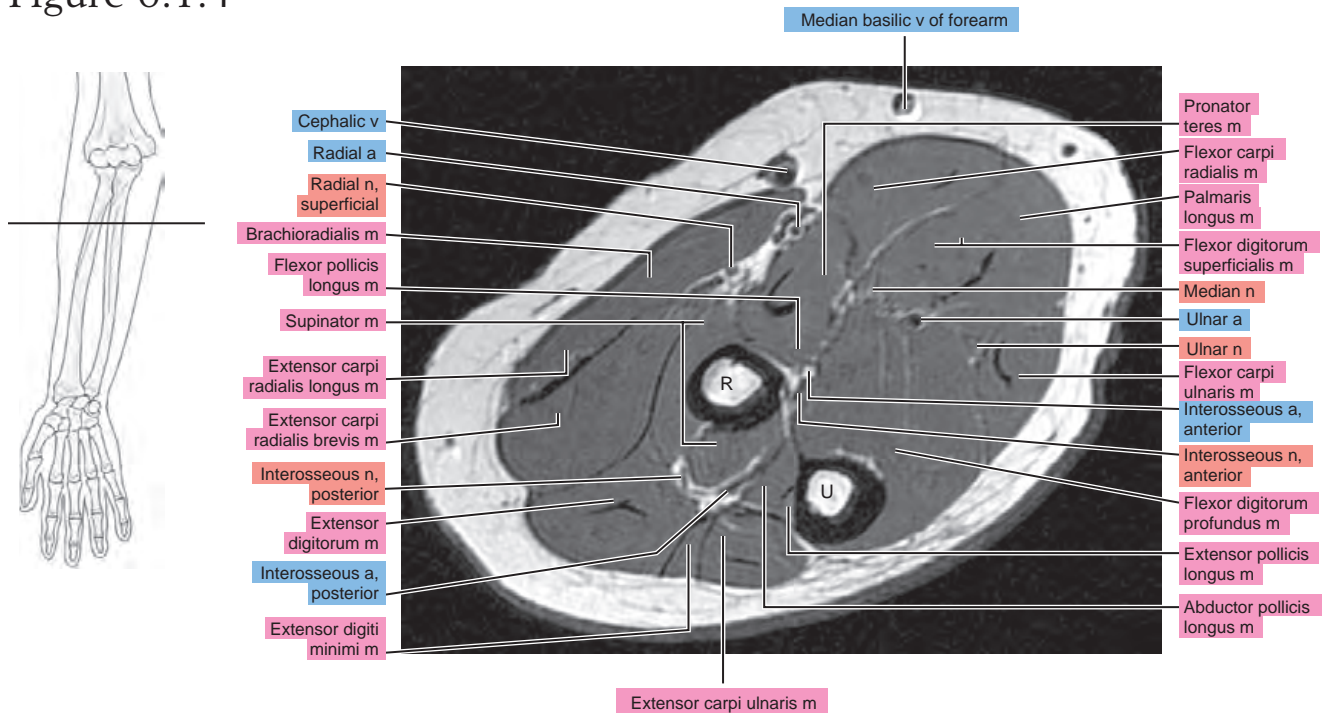


Figure 6.1.5

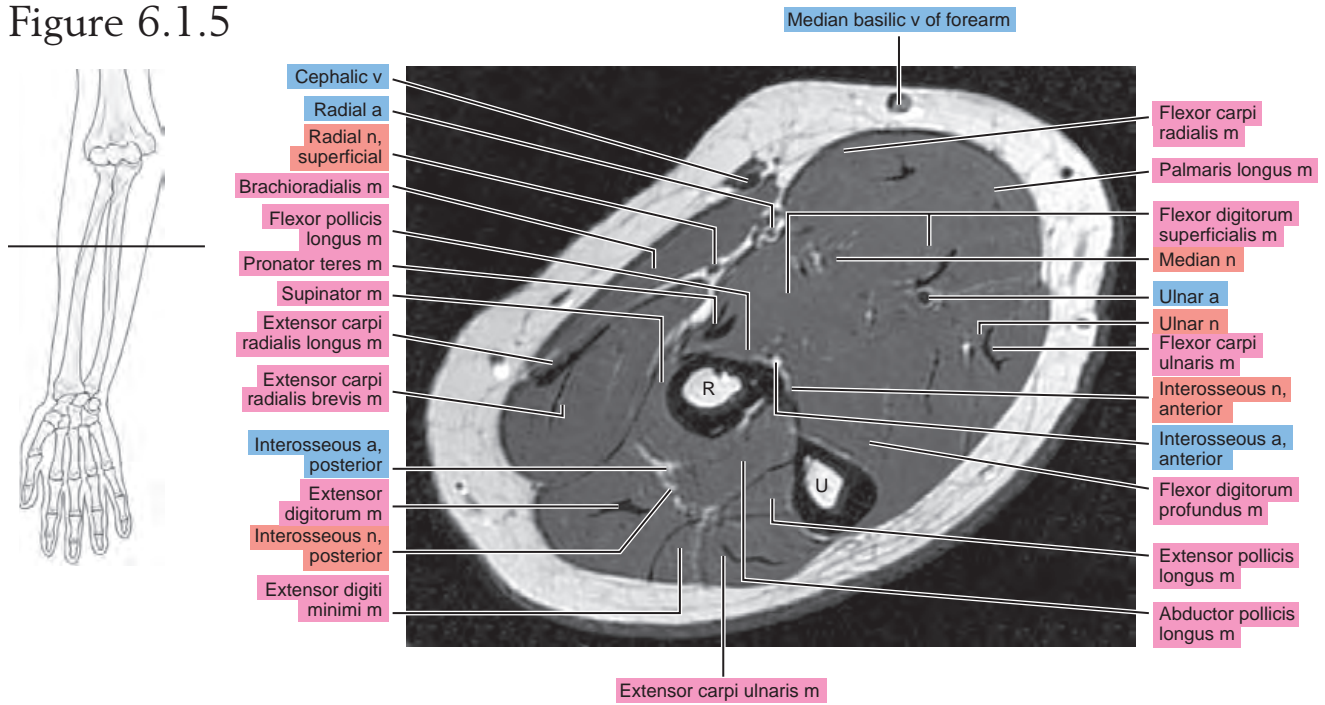


Figure 6.1.6

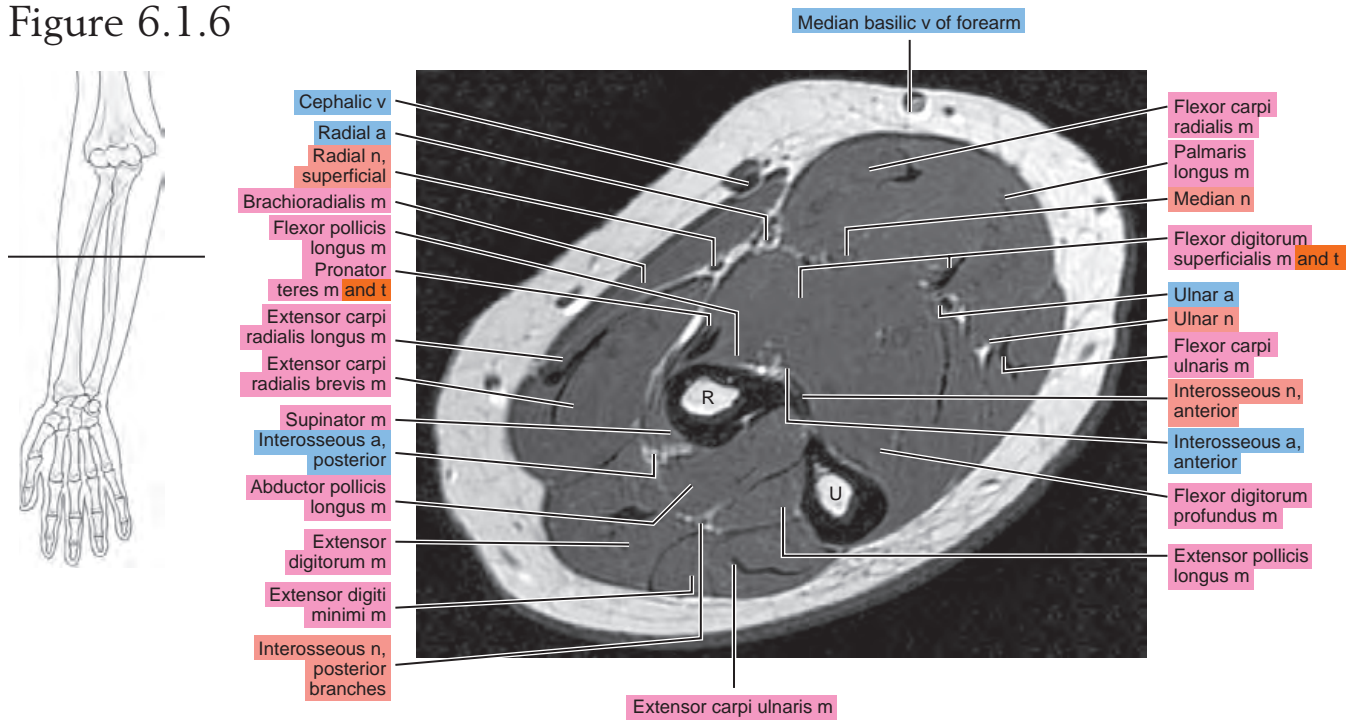


Figure 6.1.7

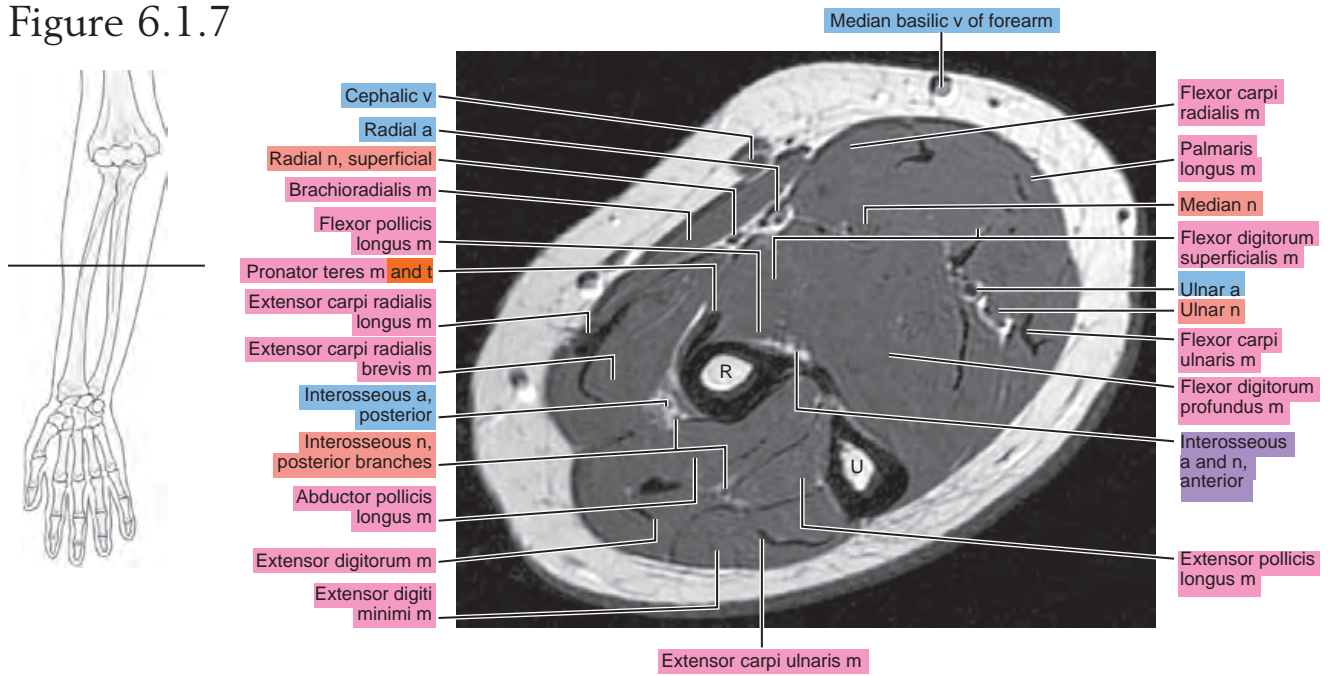


Figure 6.1.8

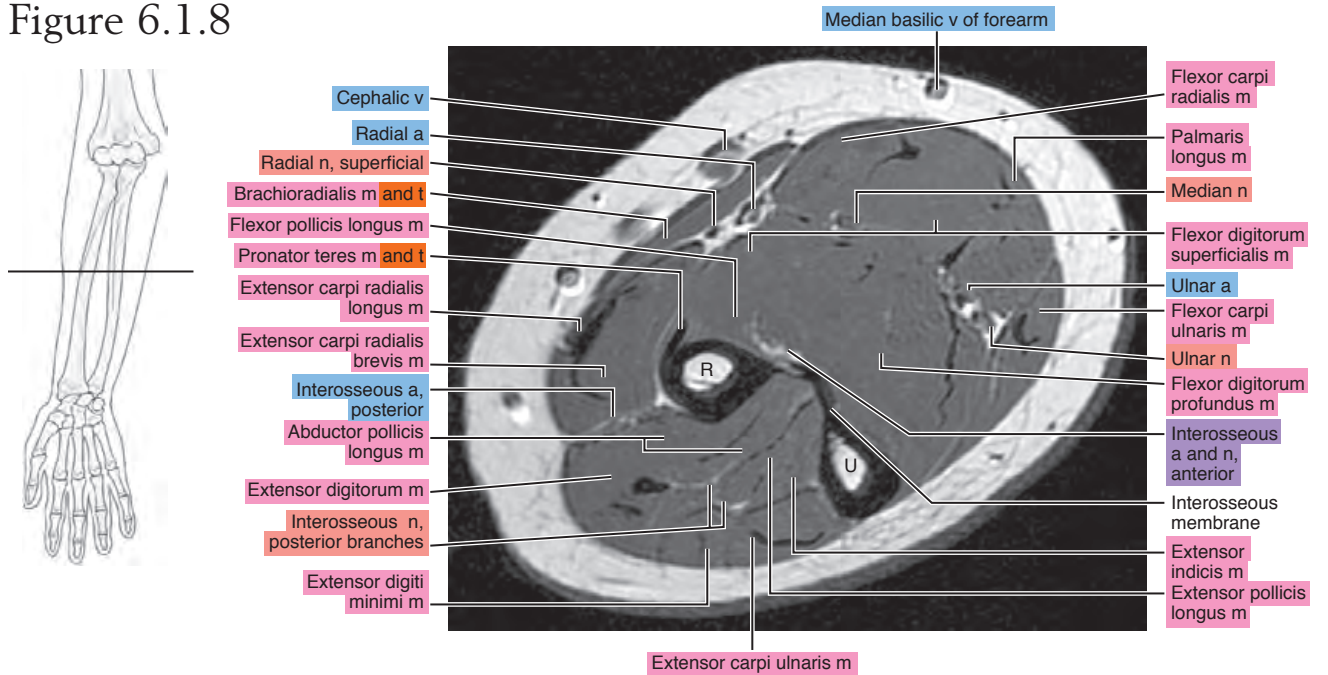


Figure 6.1.9

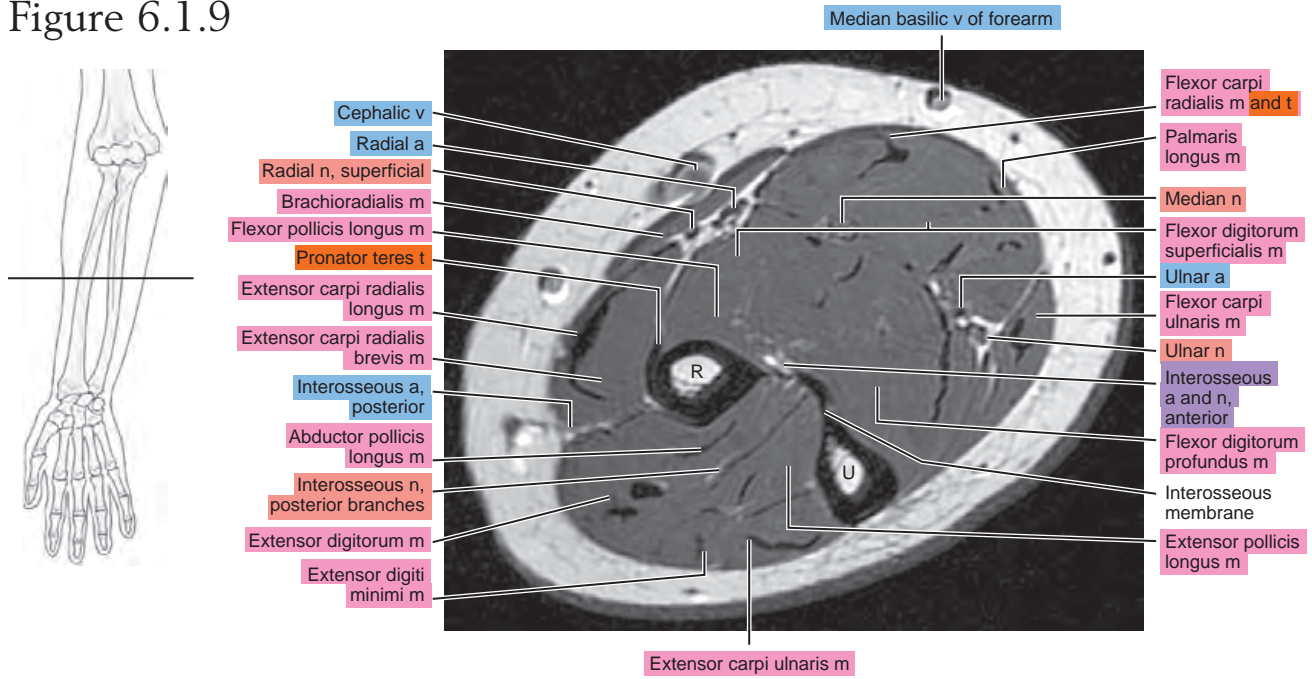


Figure 6.1.10

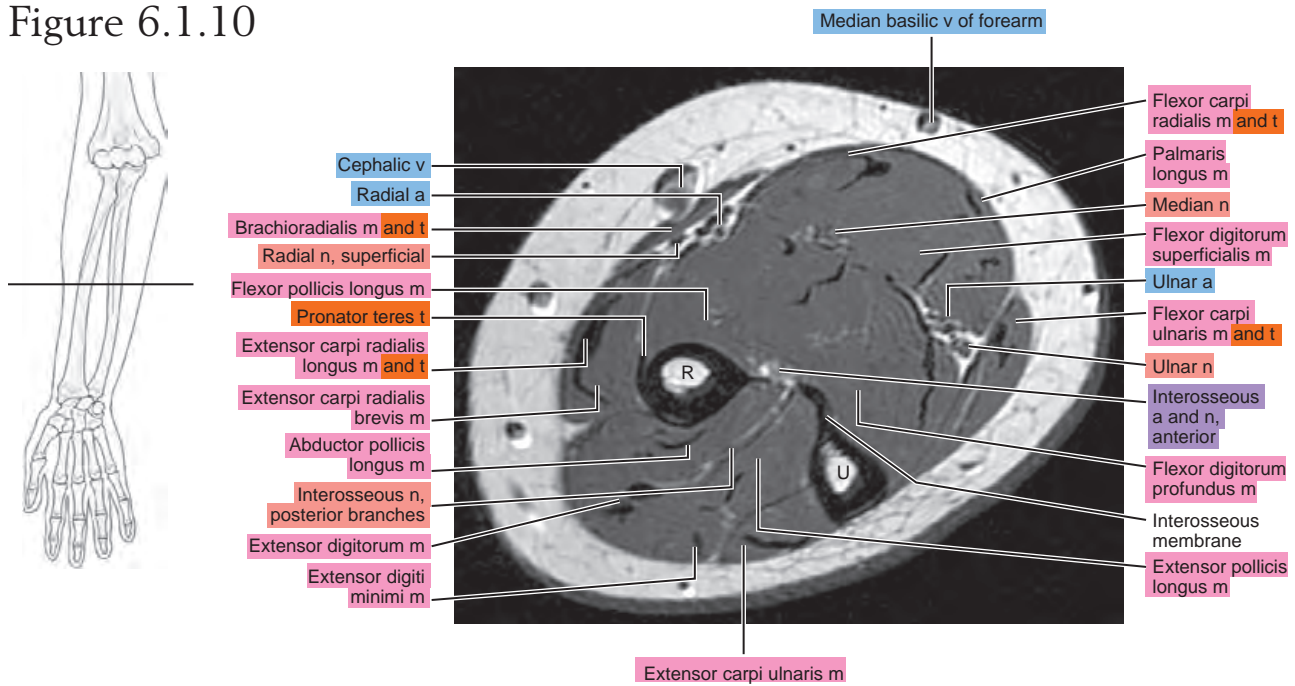


Figure 6.1.11

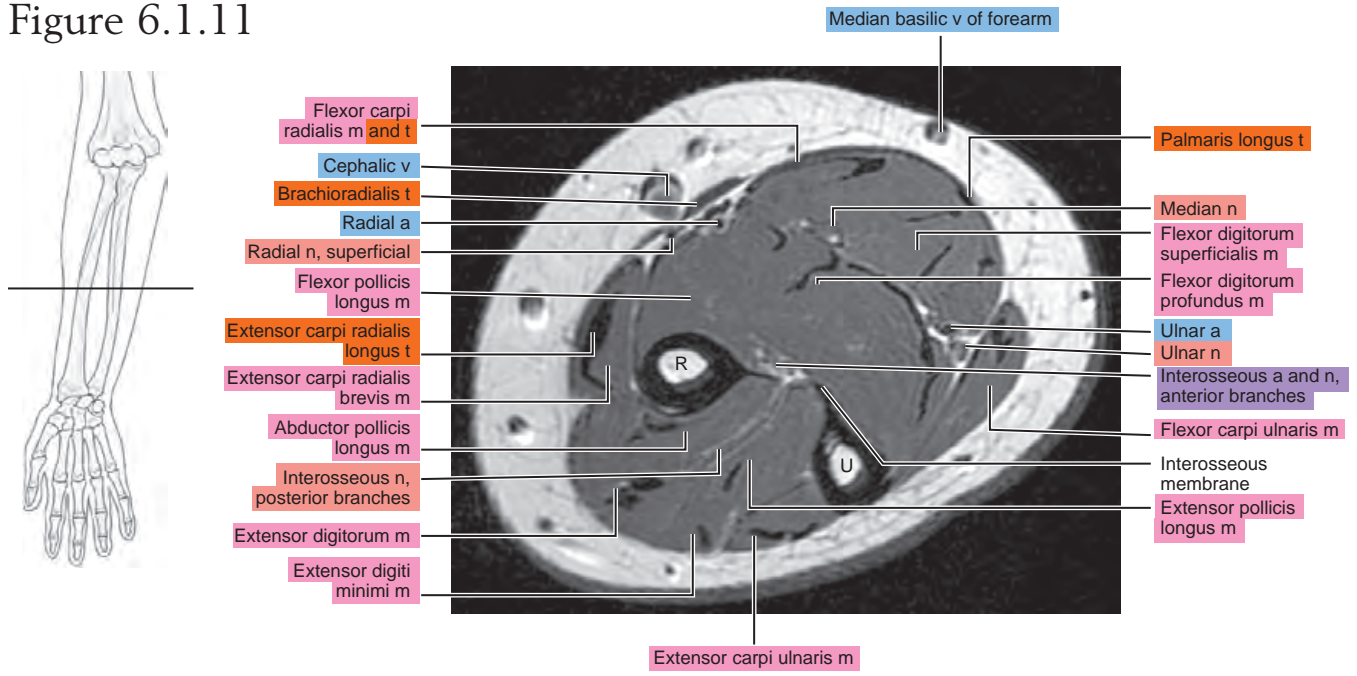


Figure 6.1.12

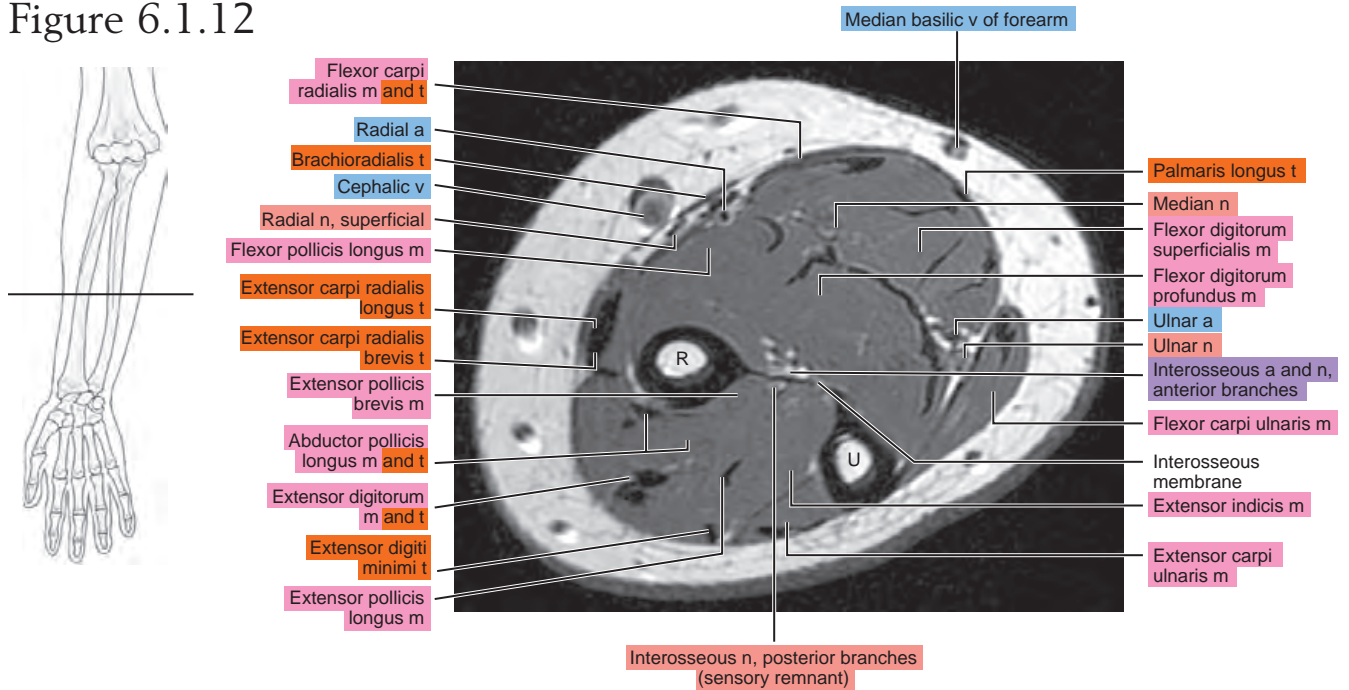


Figure 6.1.13

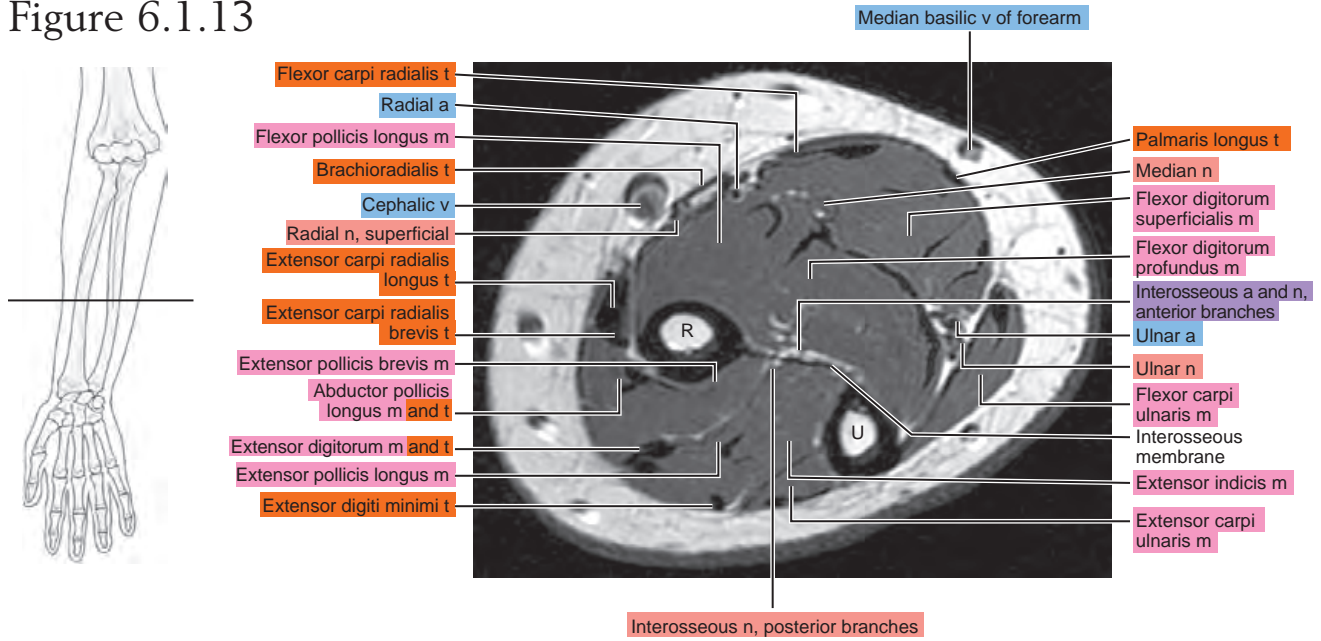


Figure 6.1.14

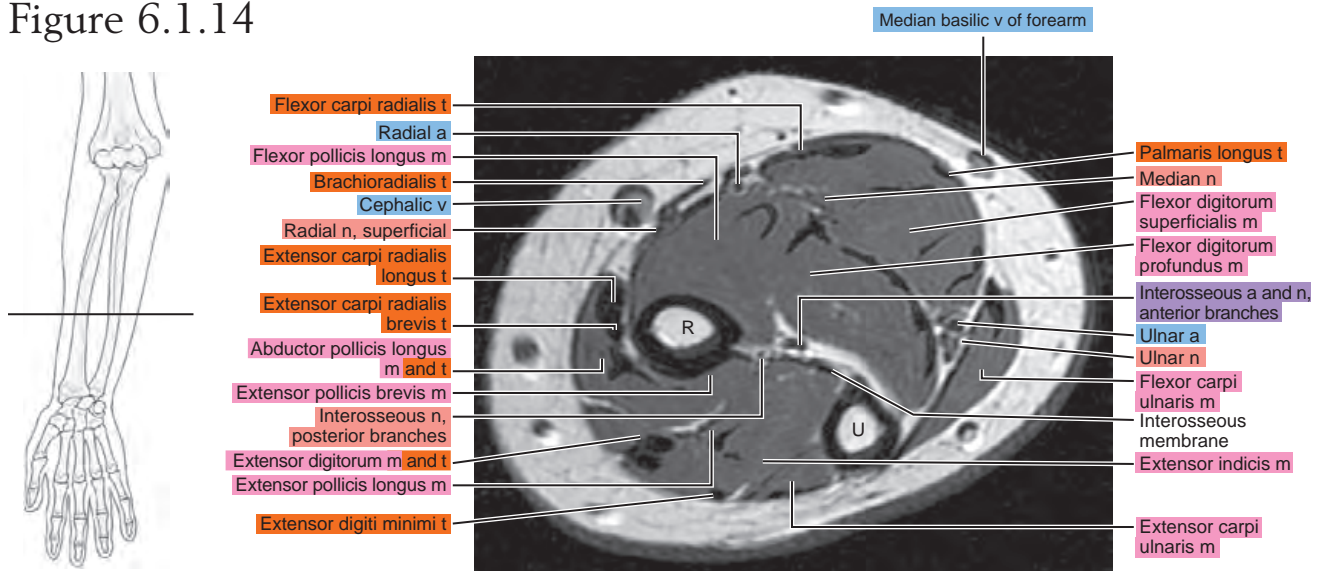


Figure 6.1.15

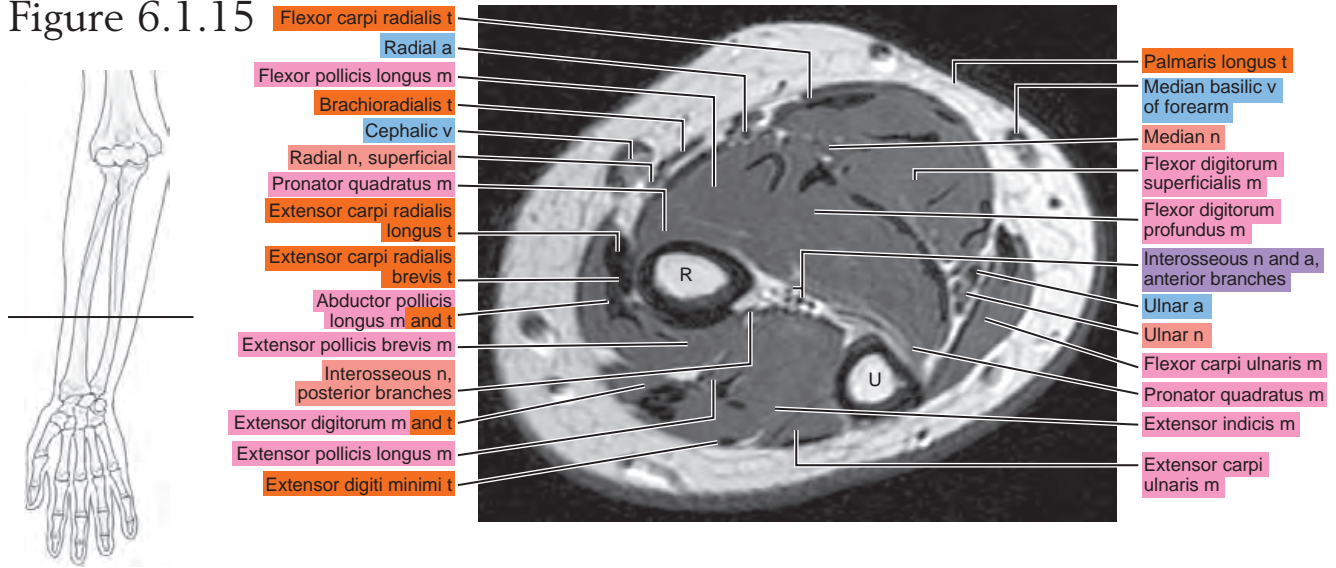


Figure 6.1.16

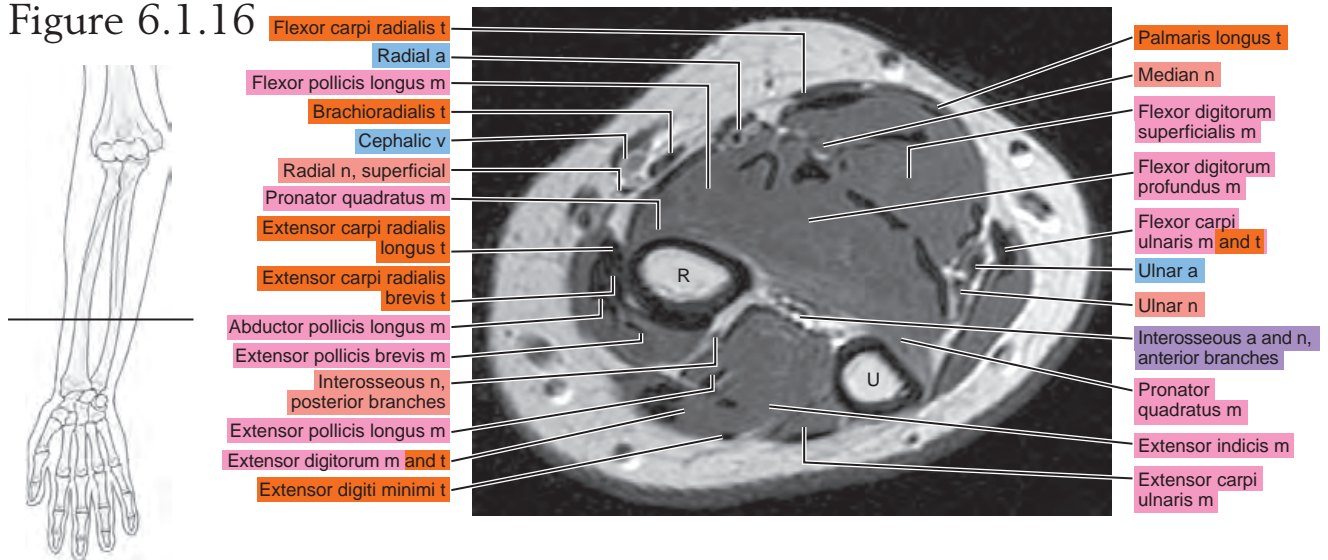


Figure 6.1.17

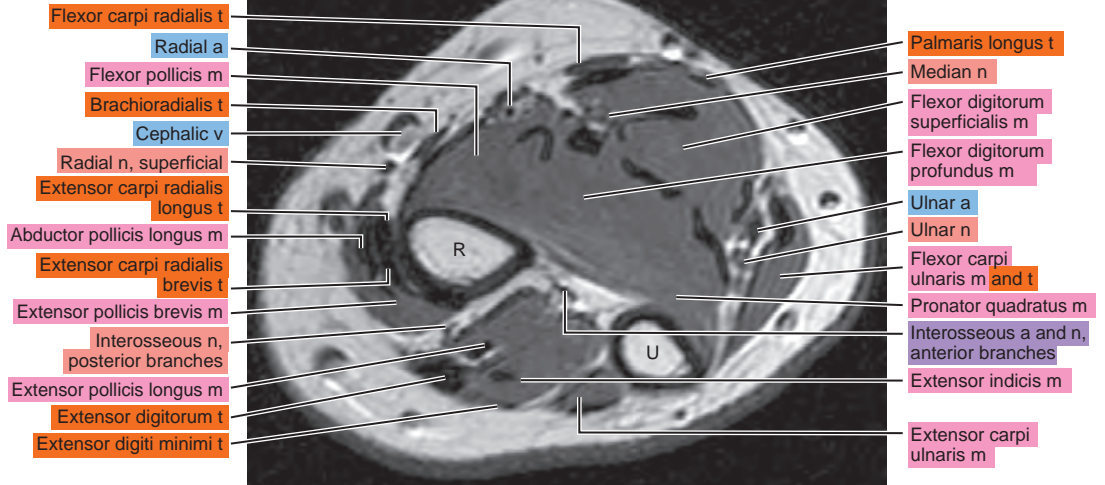
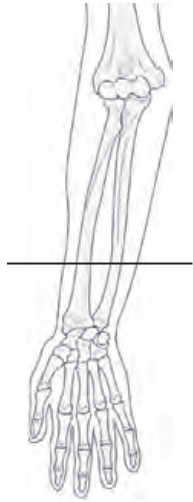


Figure 6.1.18

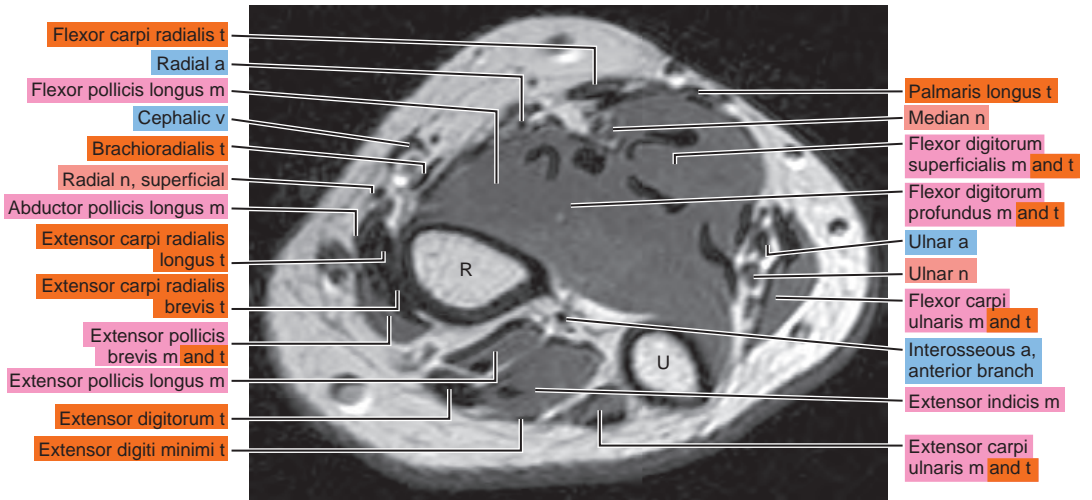
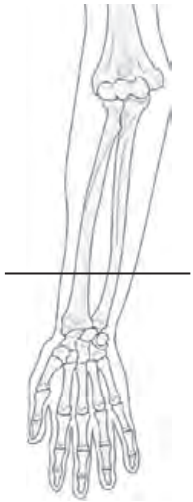


Figure 6.1.19

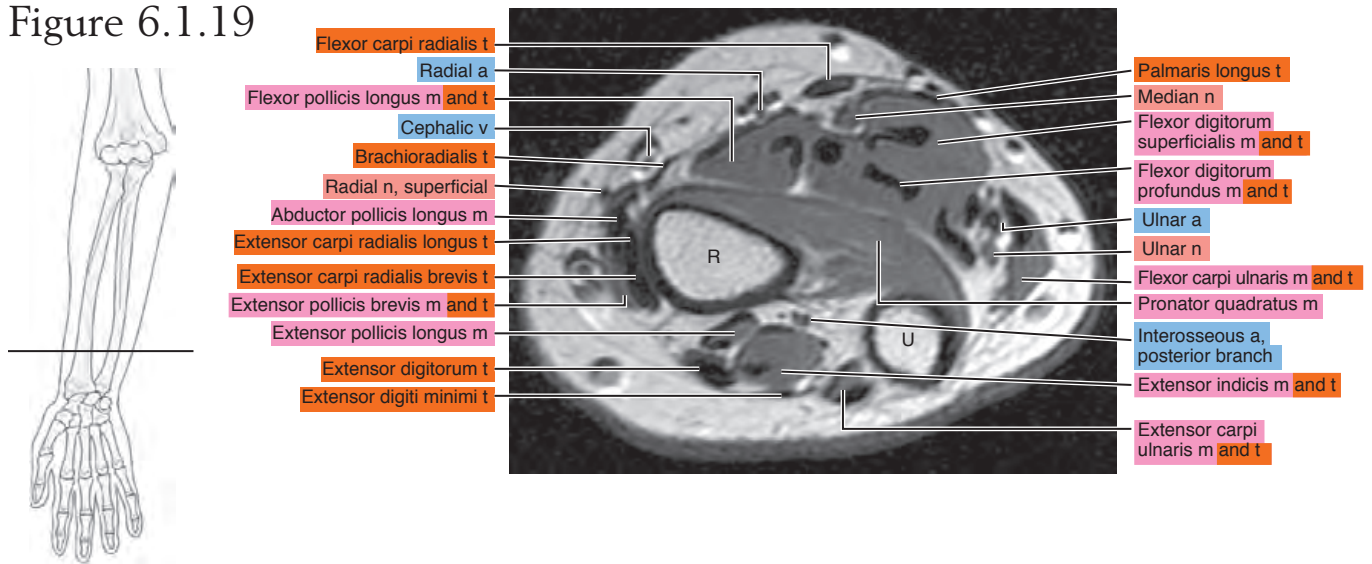
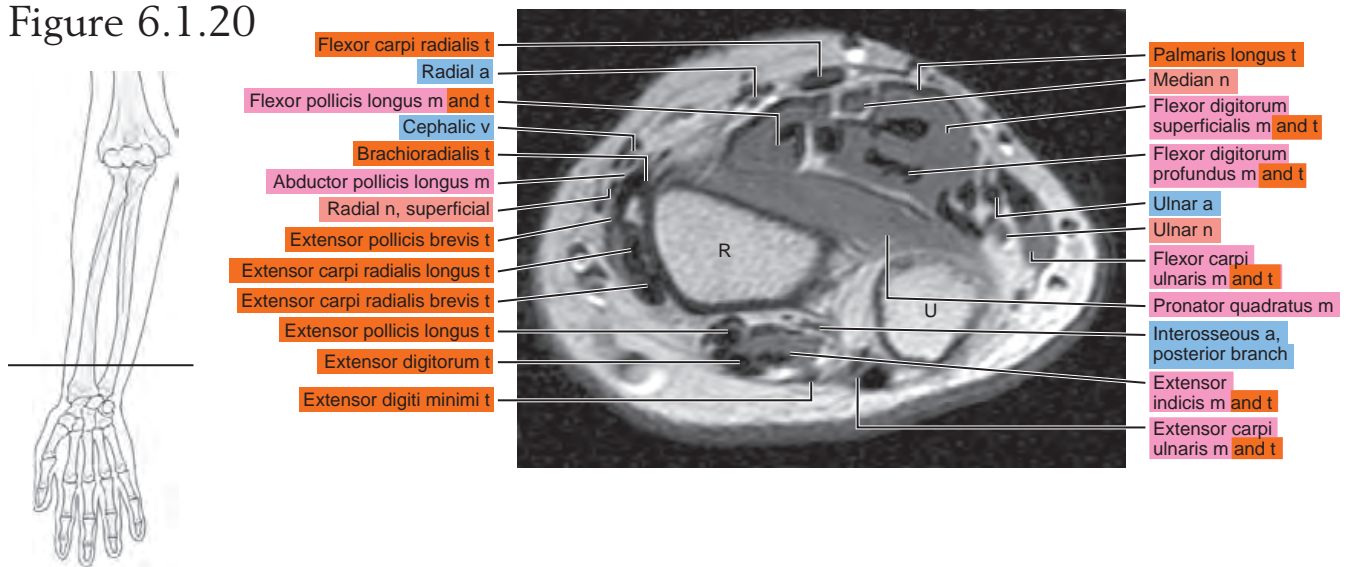


Figure 6.1.20



SAGITTAL

Figure 6.2.1

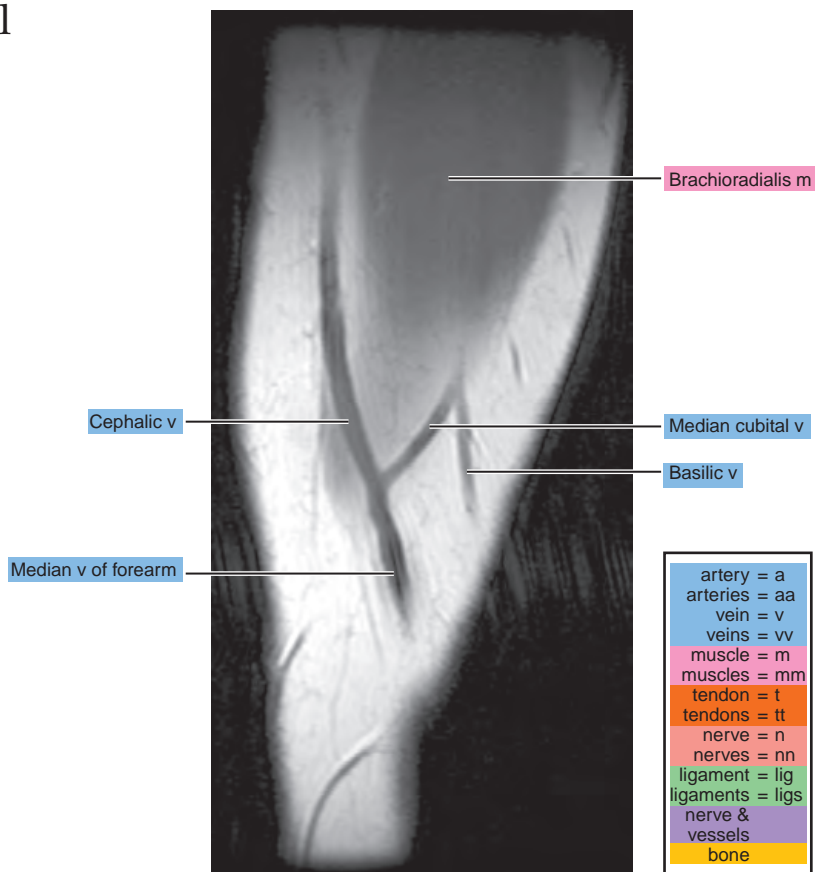


Figure 6.2.2

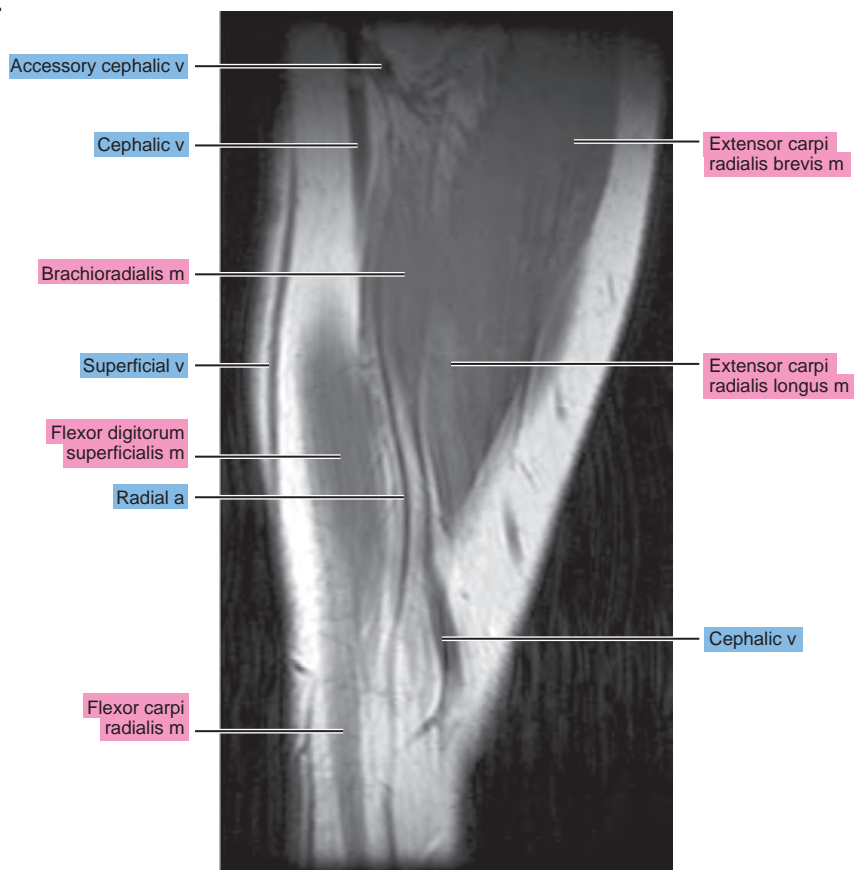


Figure 6.2.3

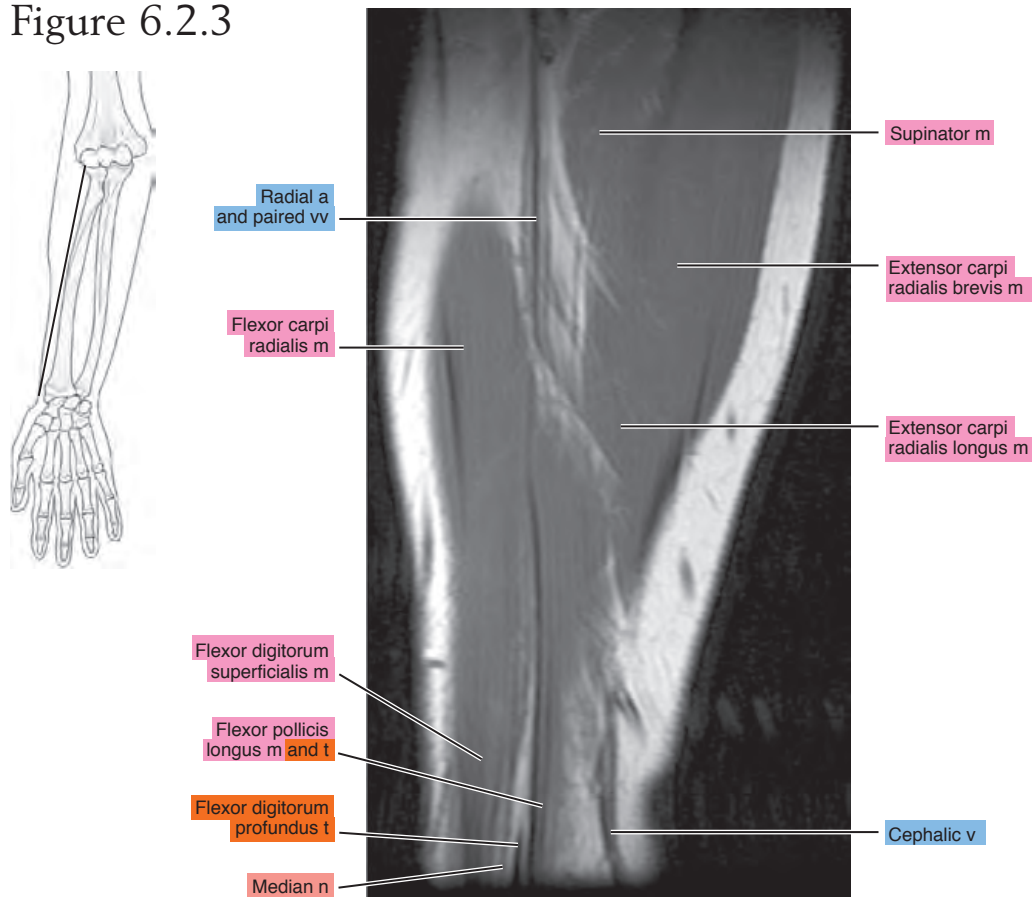


Figure 6.2.4

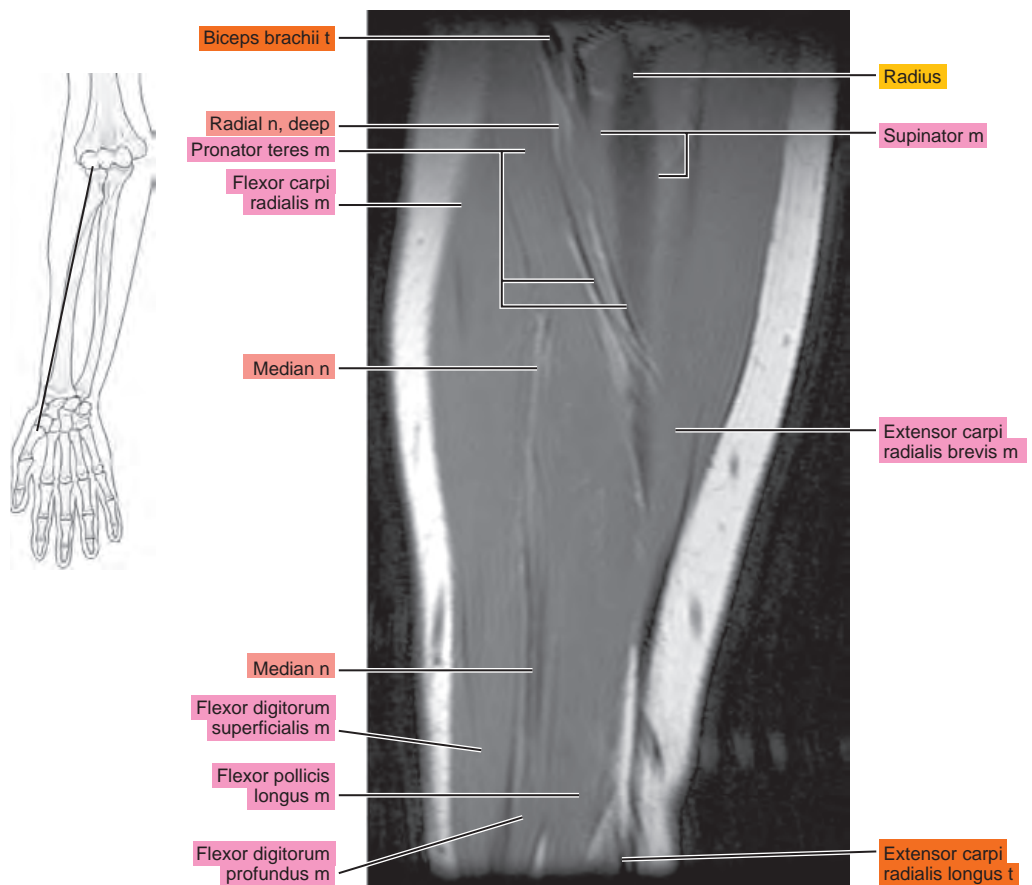


Figure 6.2.5

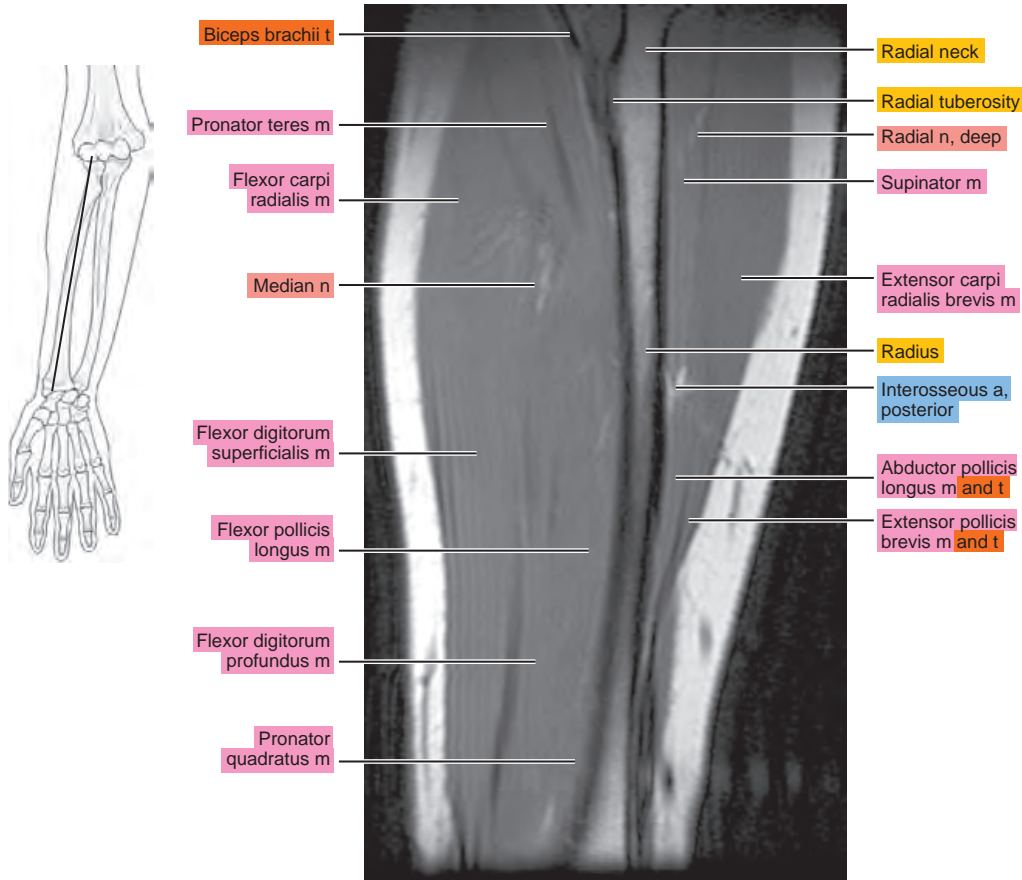


Figure 6.2.6

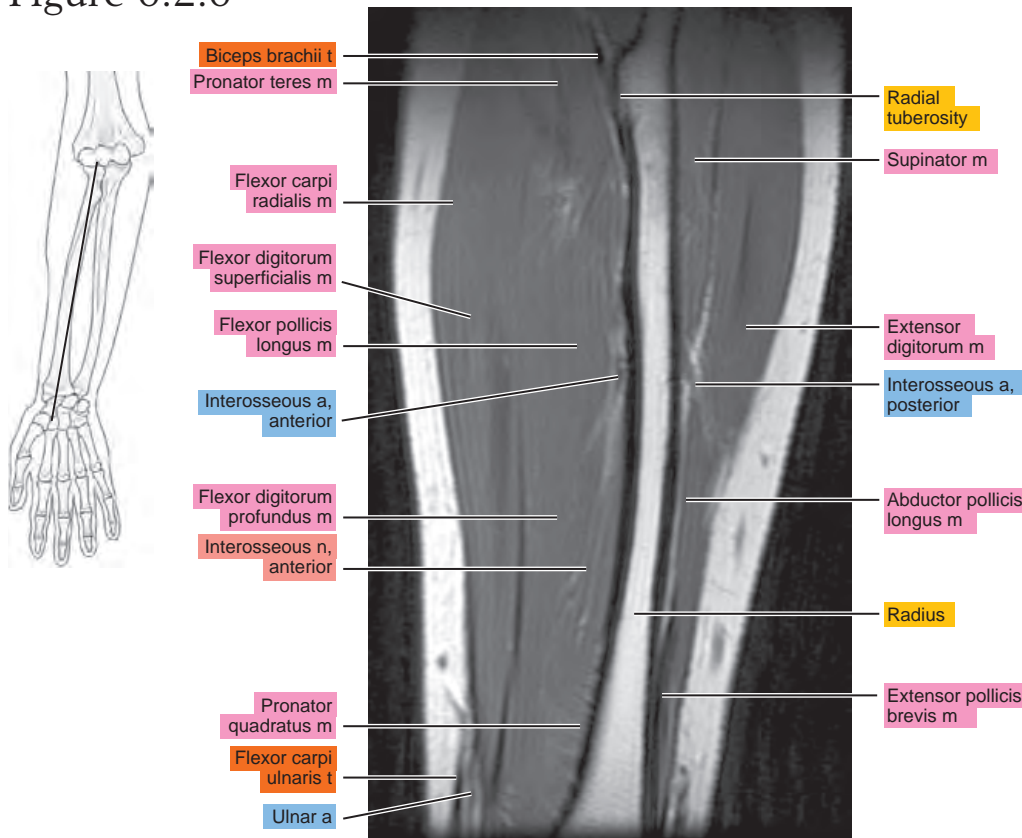


Figure 6.2.7

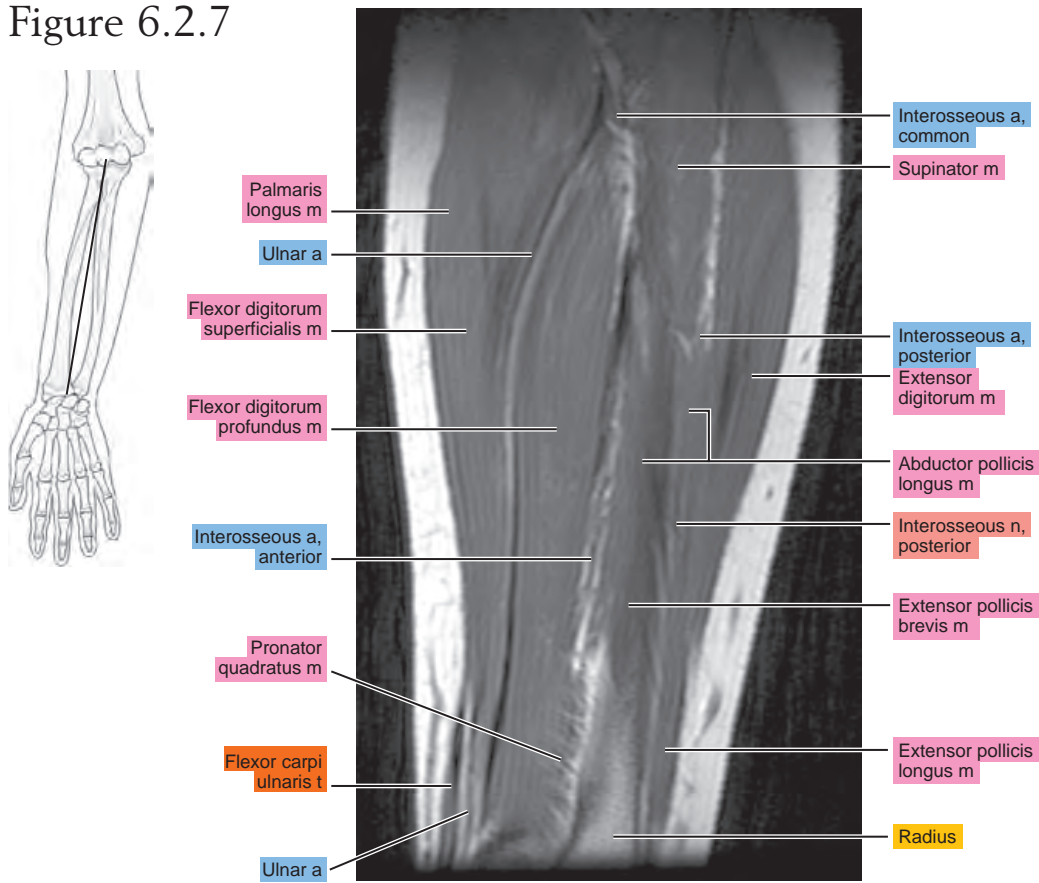


Figure 6.2.8

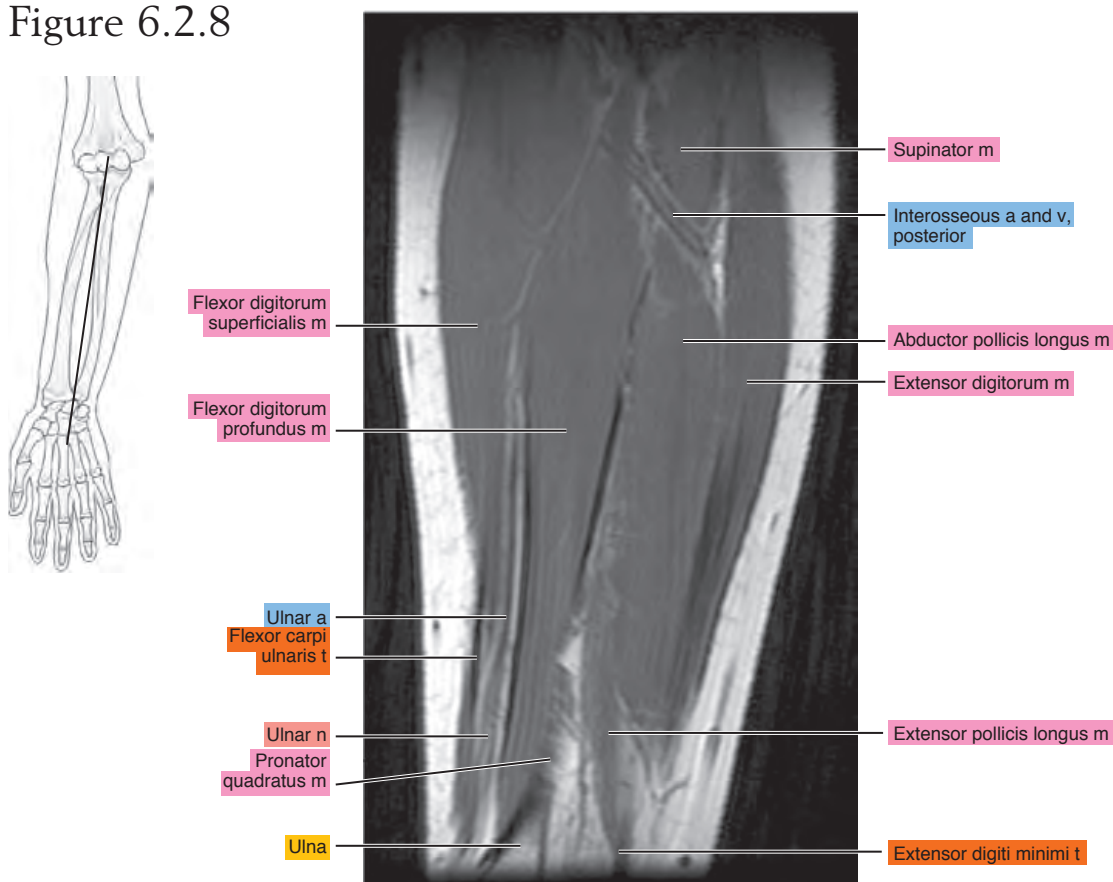


Figure 6.2.9

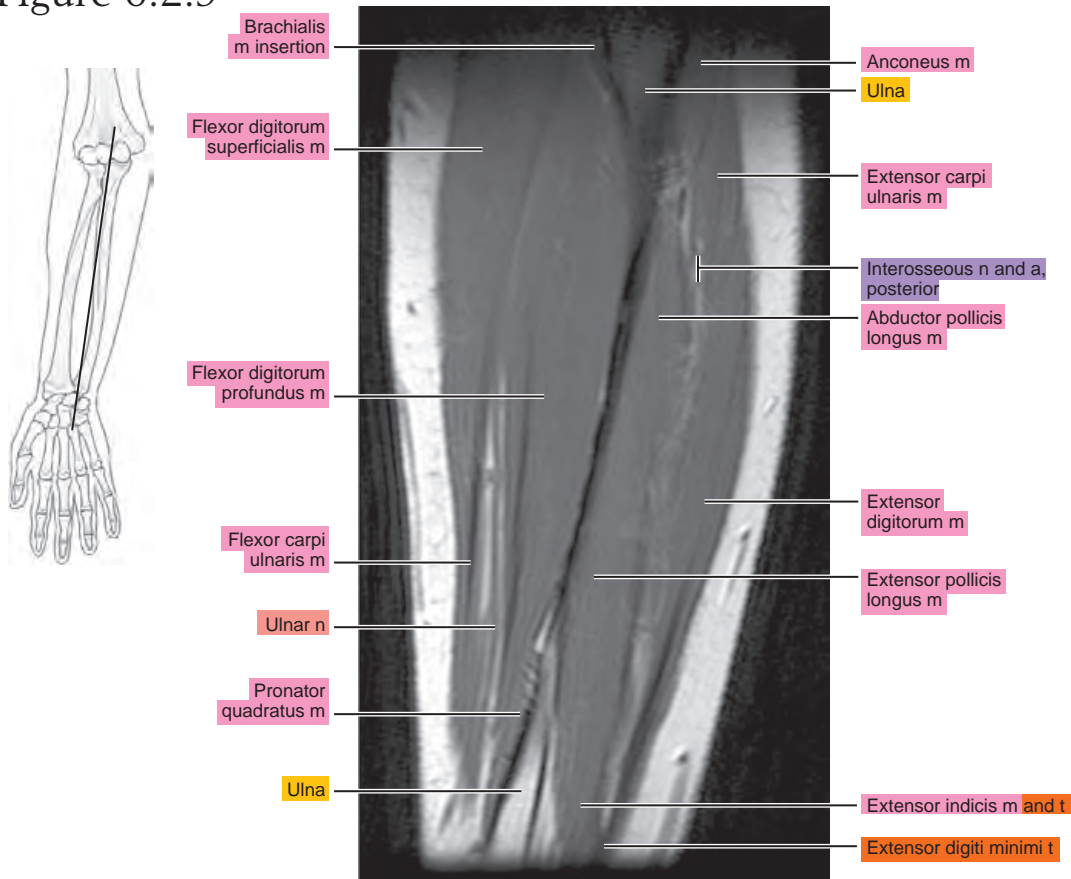


Figure 6.2.10

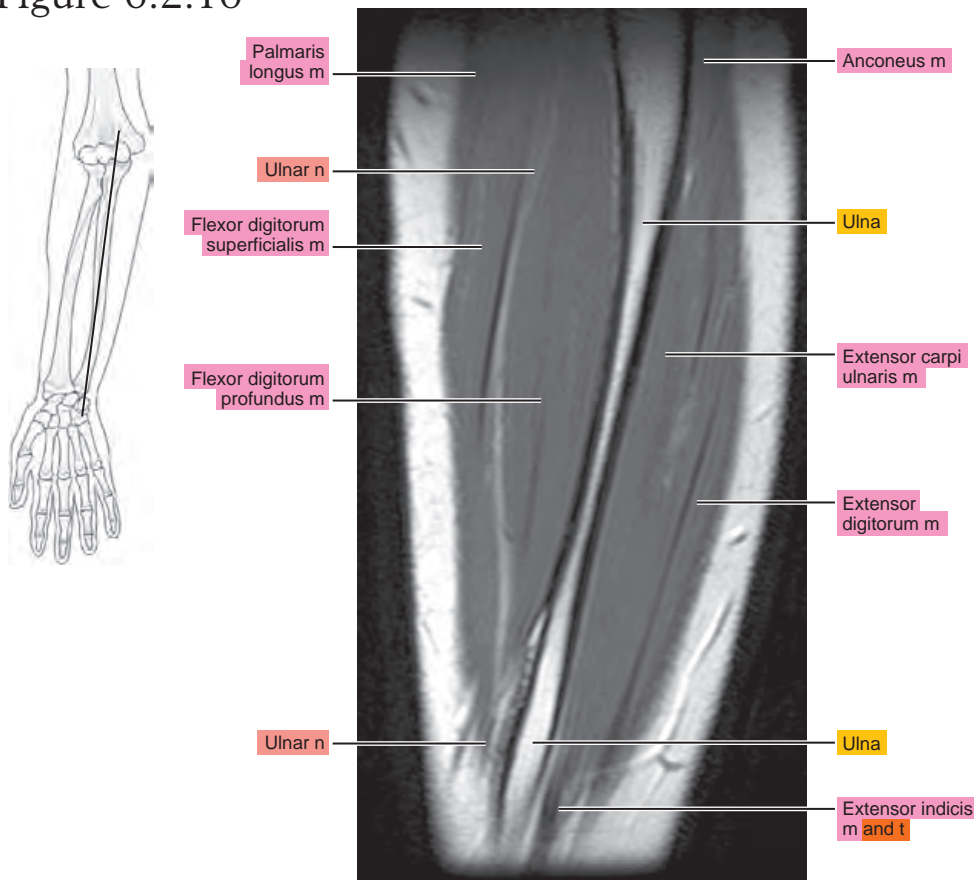


Figure 6.2.11

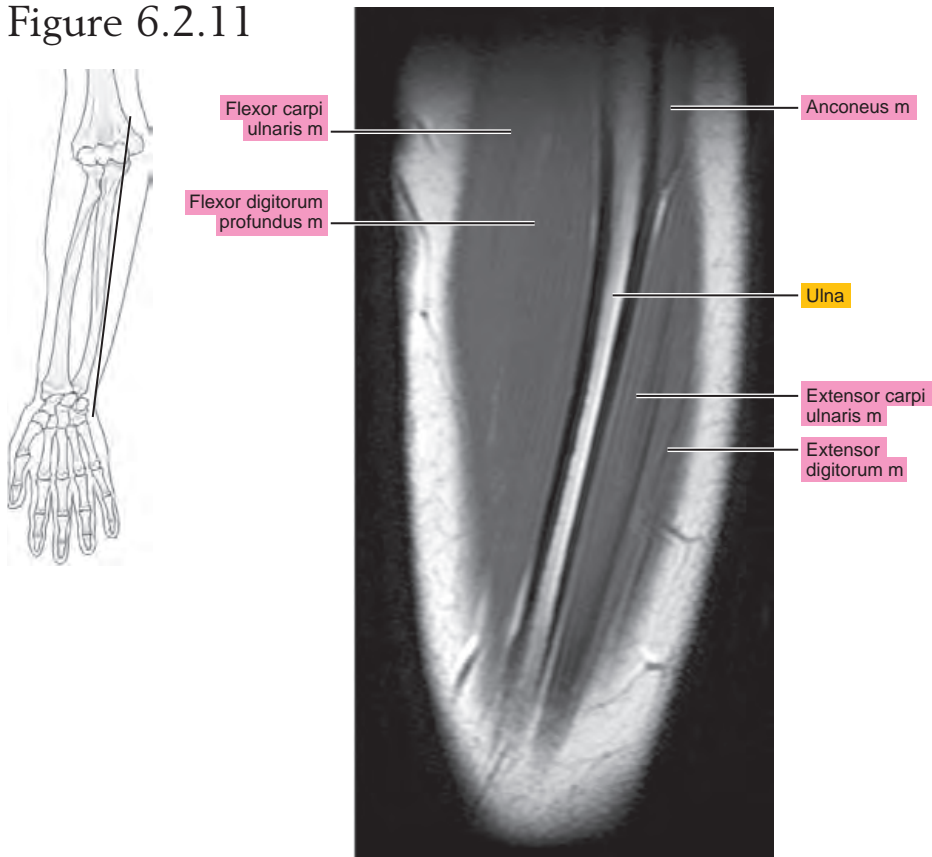
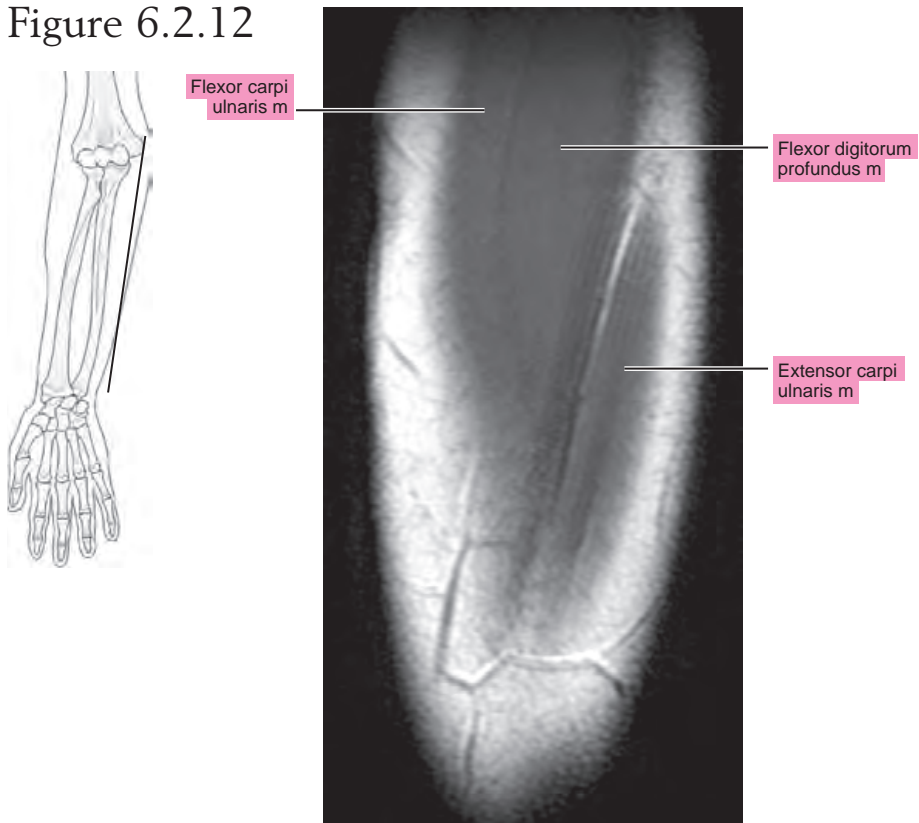


Figure 6.2.12



CORONAL

Figure 6.3.1

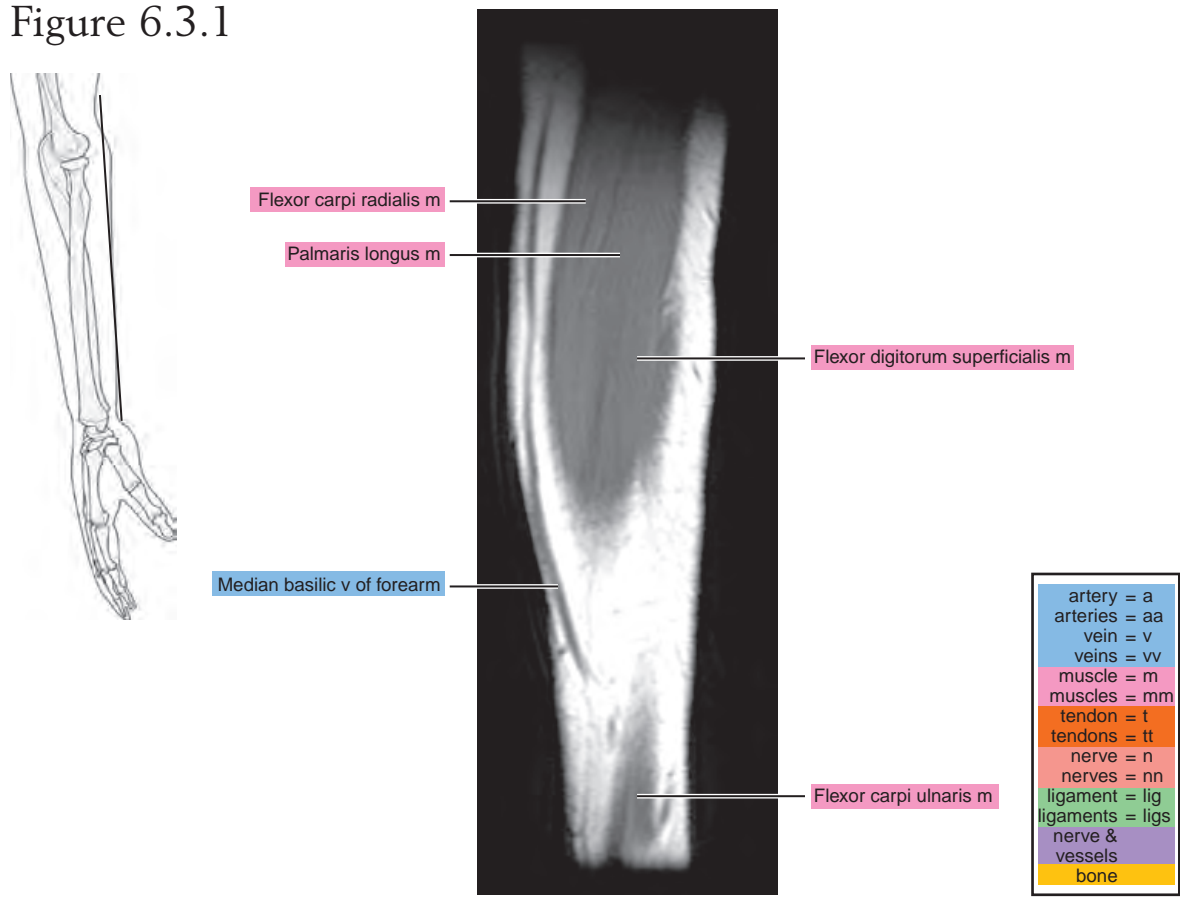


Figure 6.3.2

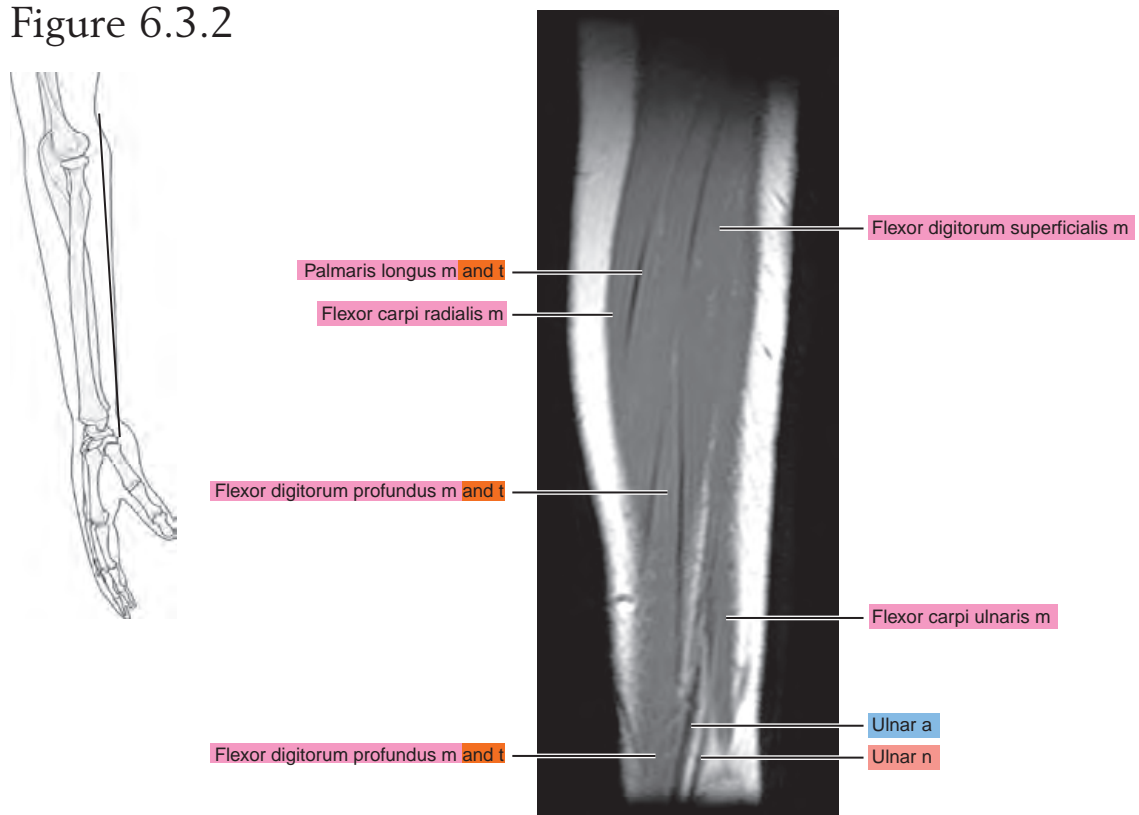


Figure 6.3.3

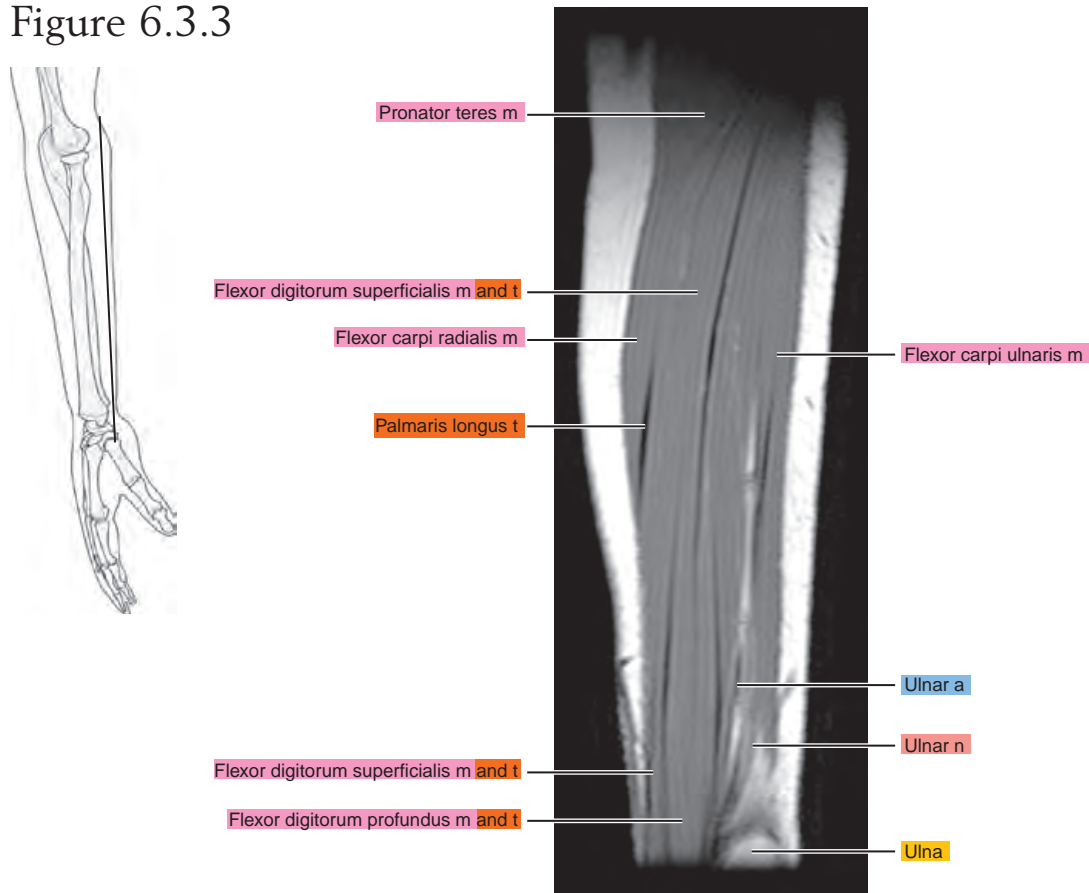


Figure 6.3.4

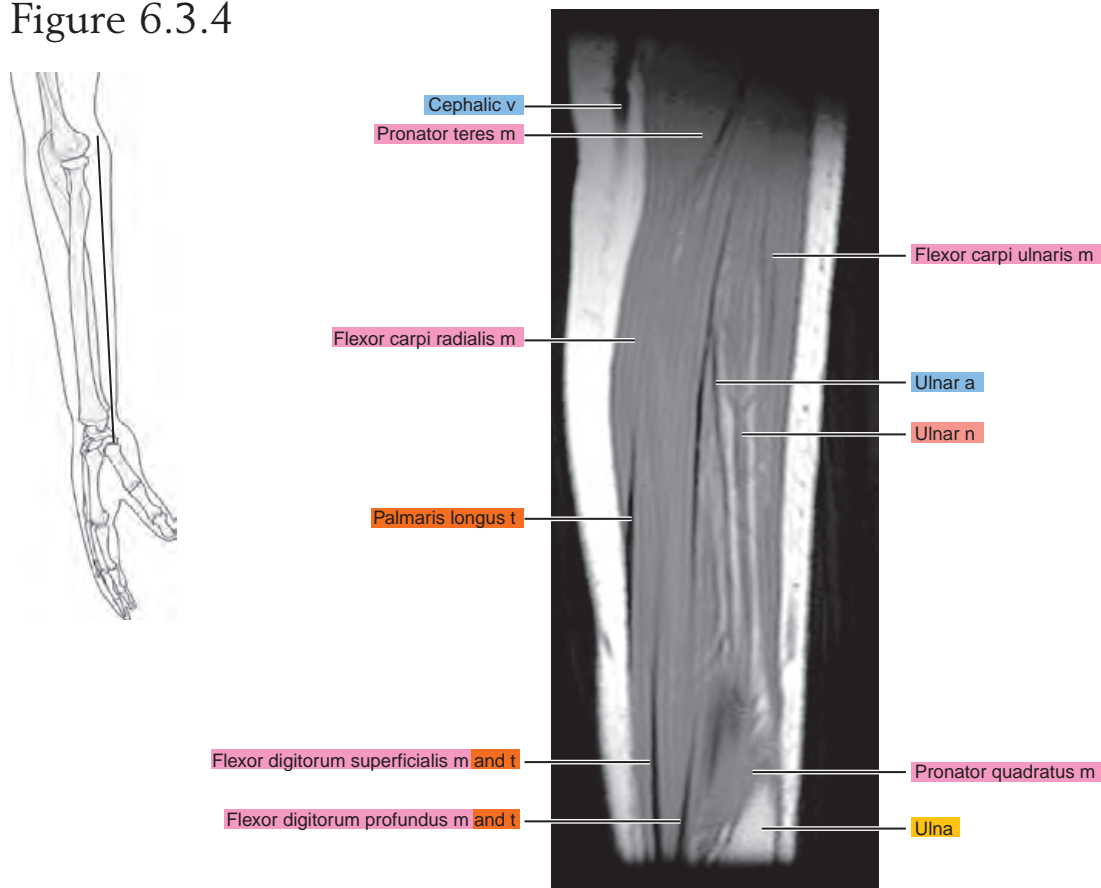


Figure 6.3.5

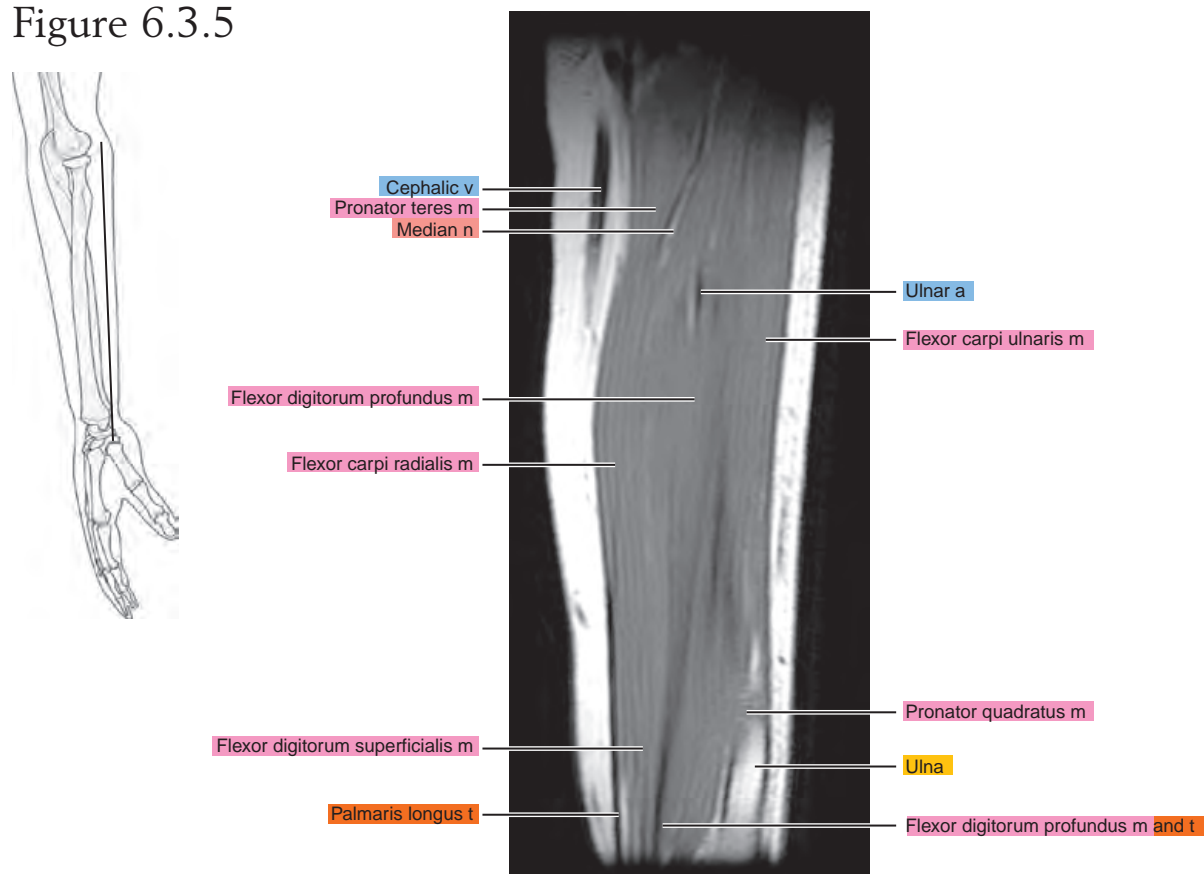


Figure 6.3.6

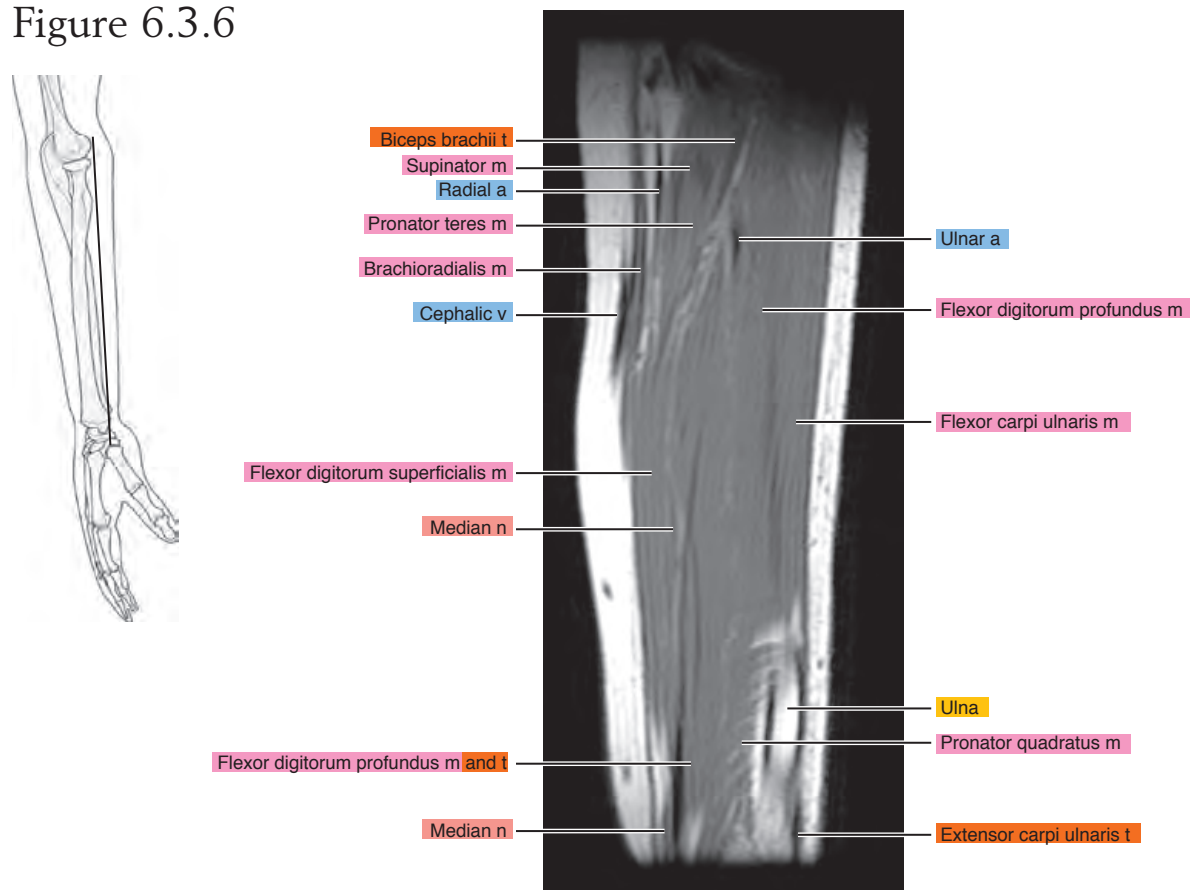


Figure 6.3.7

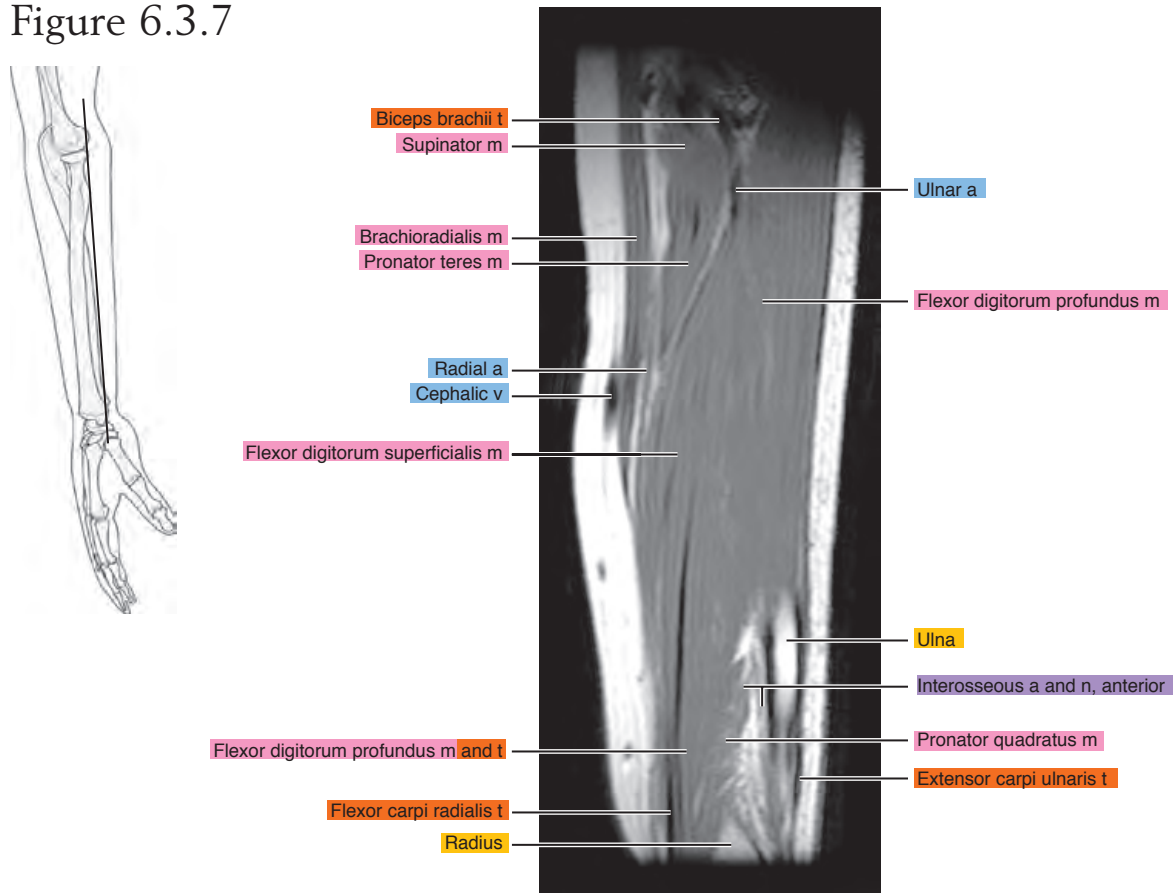


Figure 6.3.8

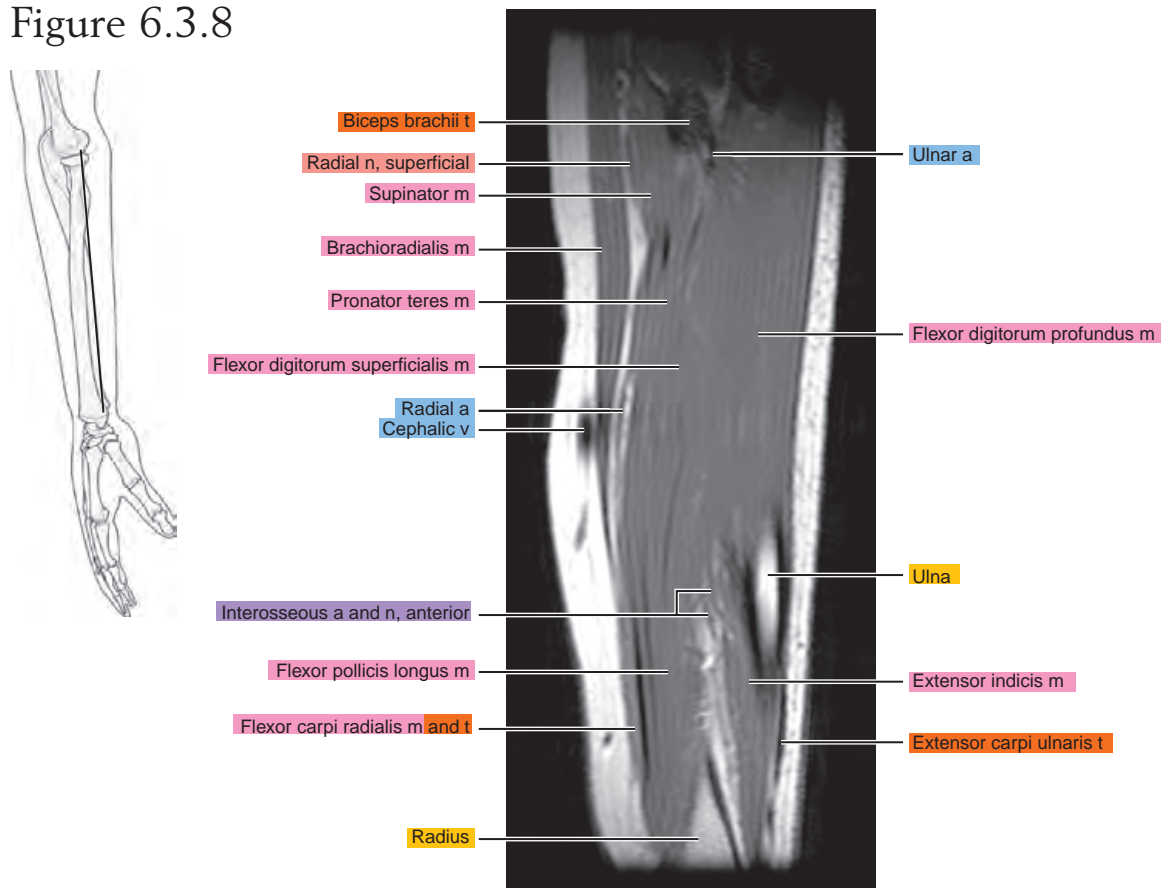


Figure 6.3.9

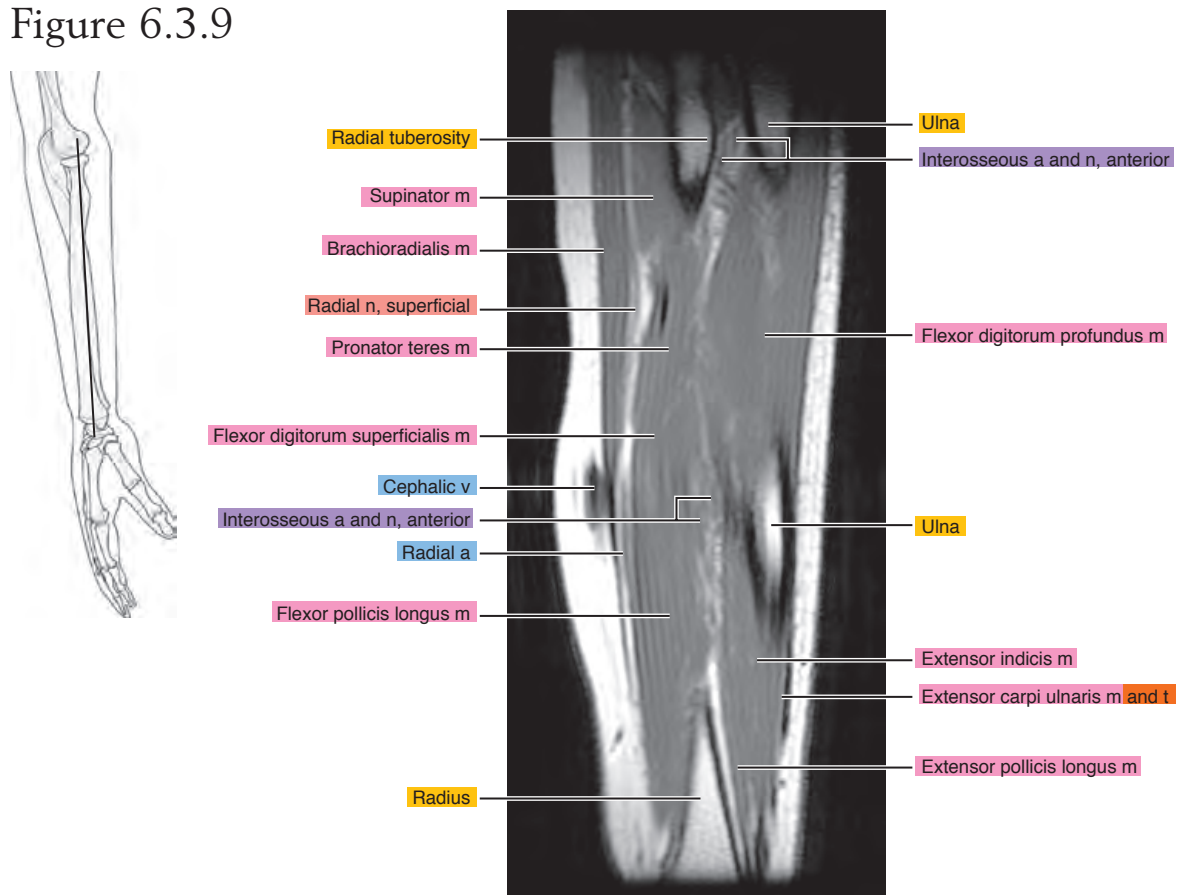


Figure 6.3.10

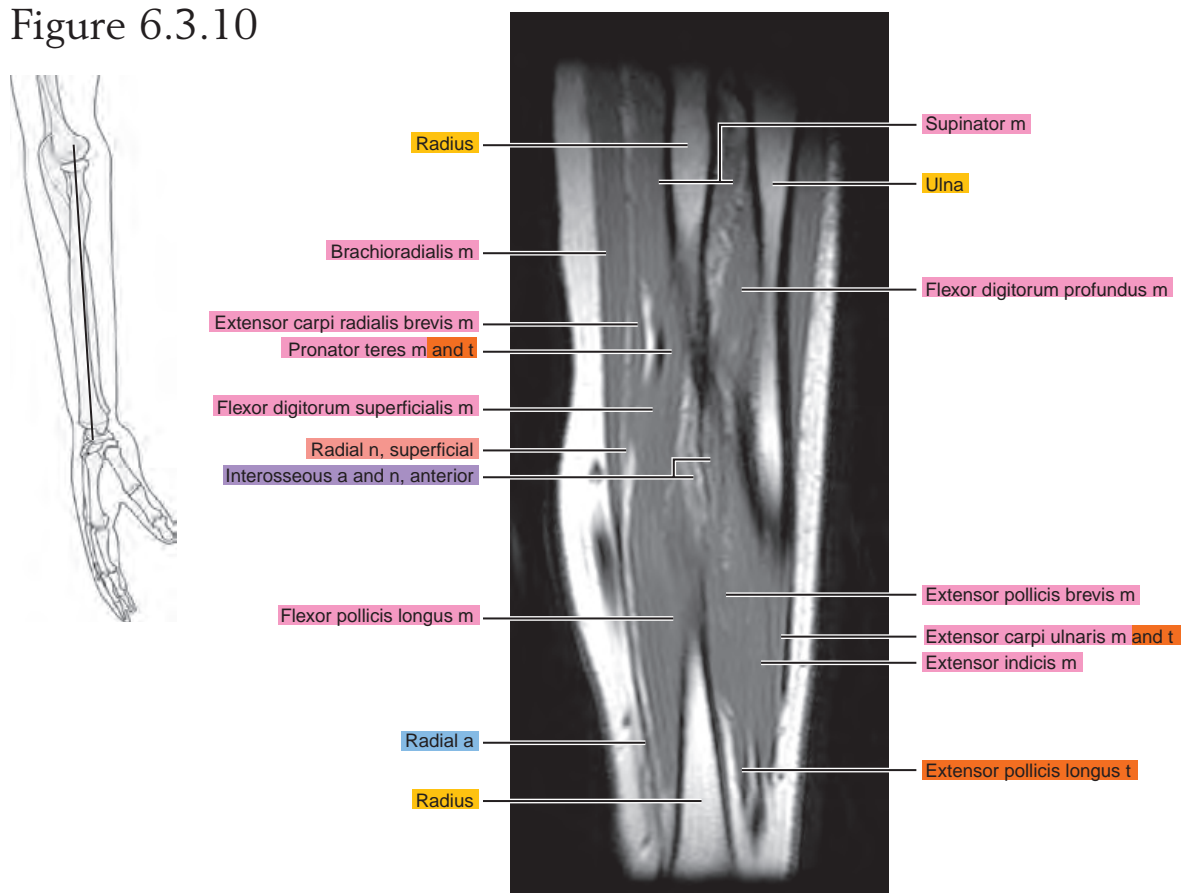


Figure 6.3.11

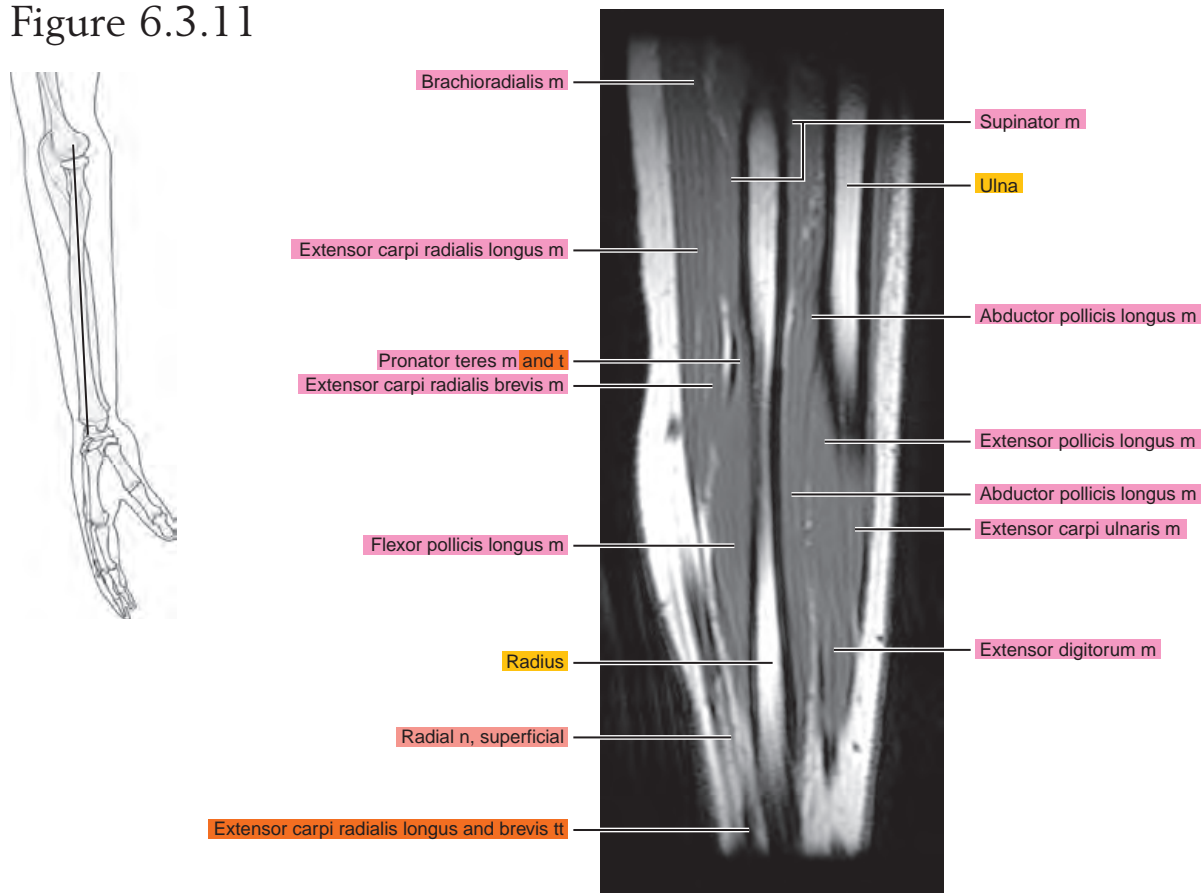


Figure 6.3.12

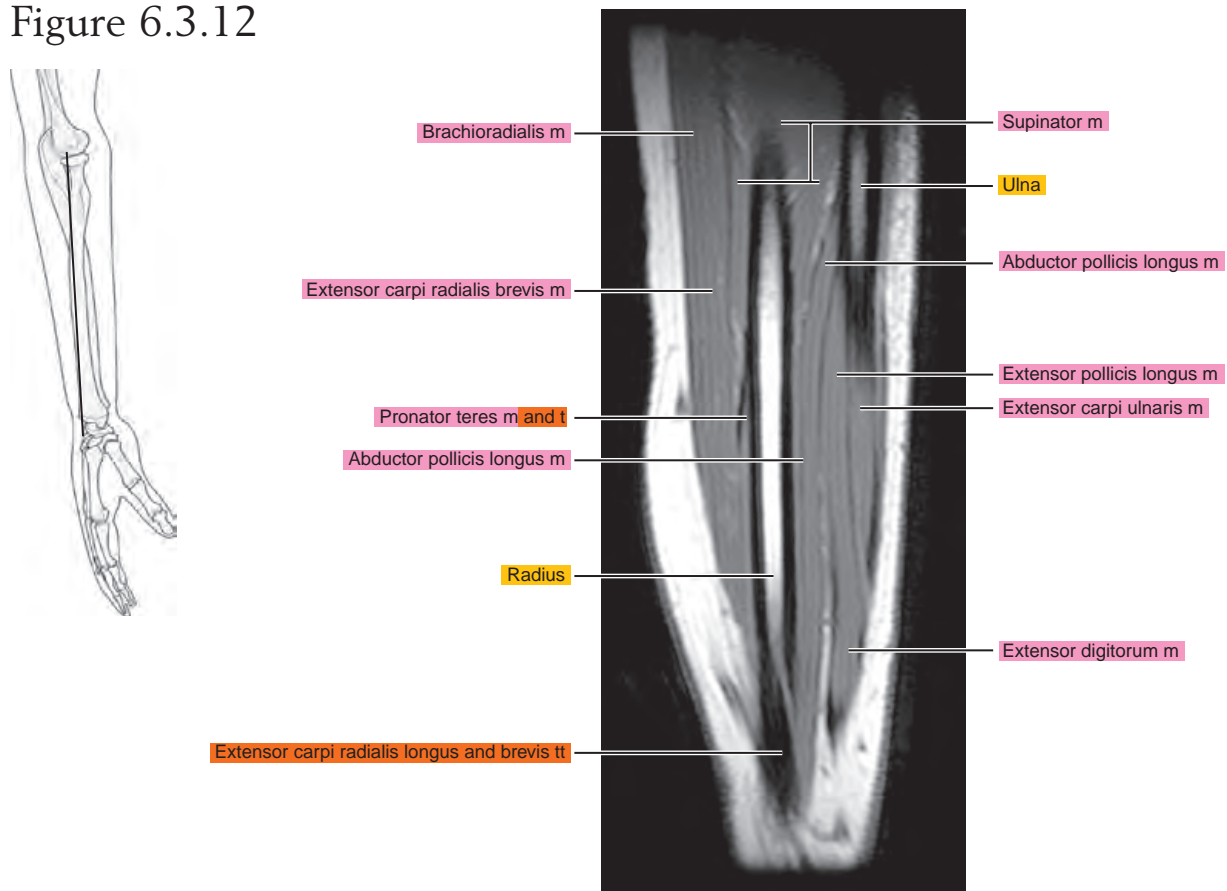


Figure 6.3.13

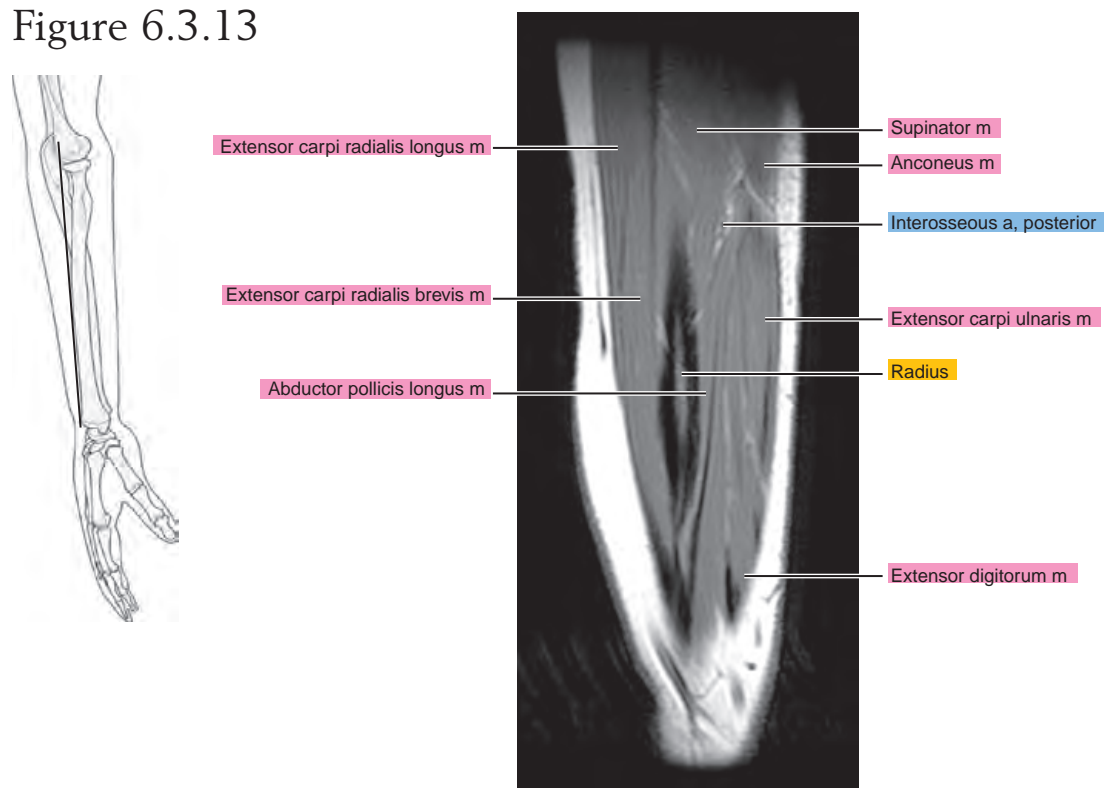


Figure 6.3.14

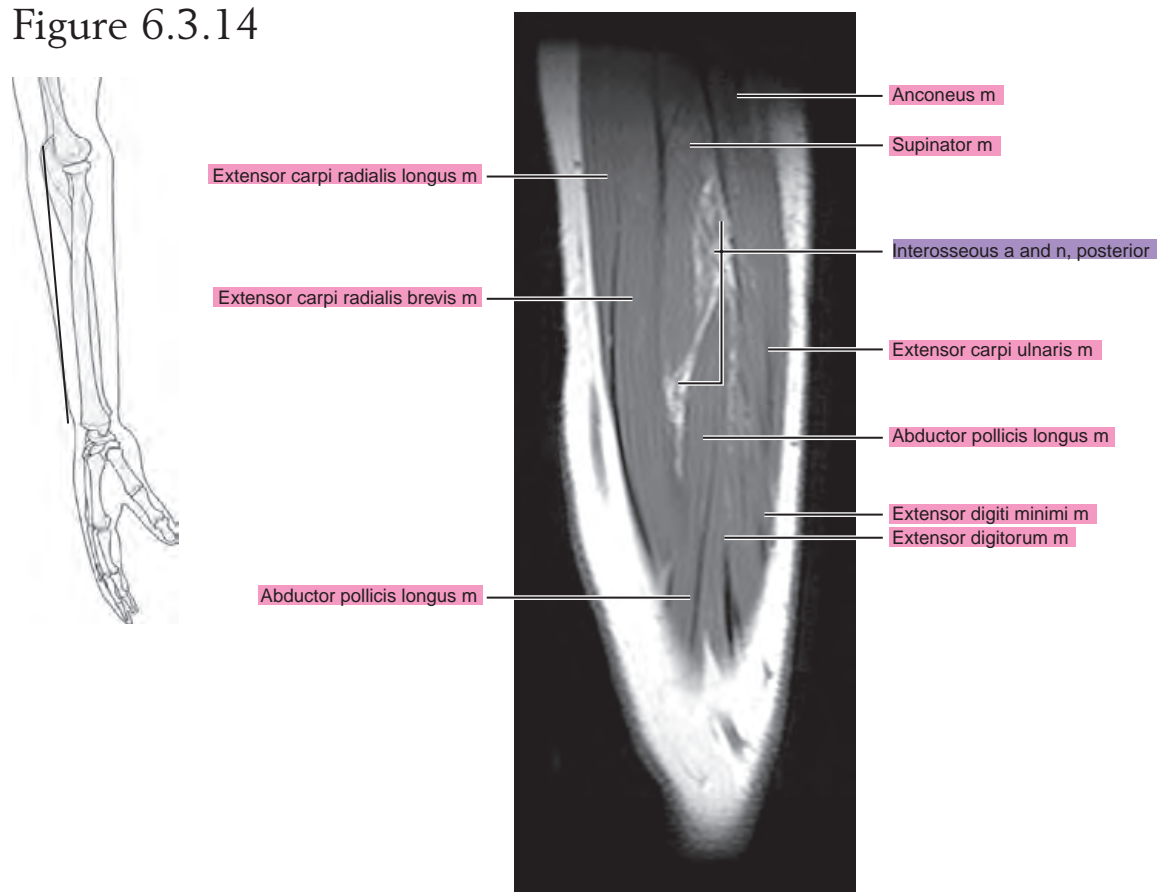


Figure 6.3.15

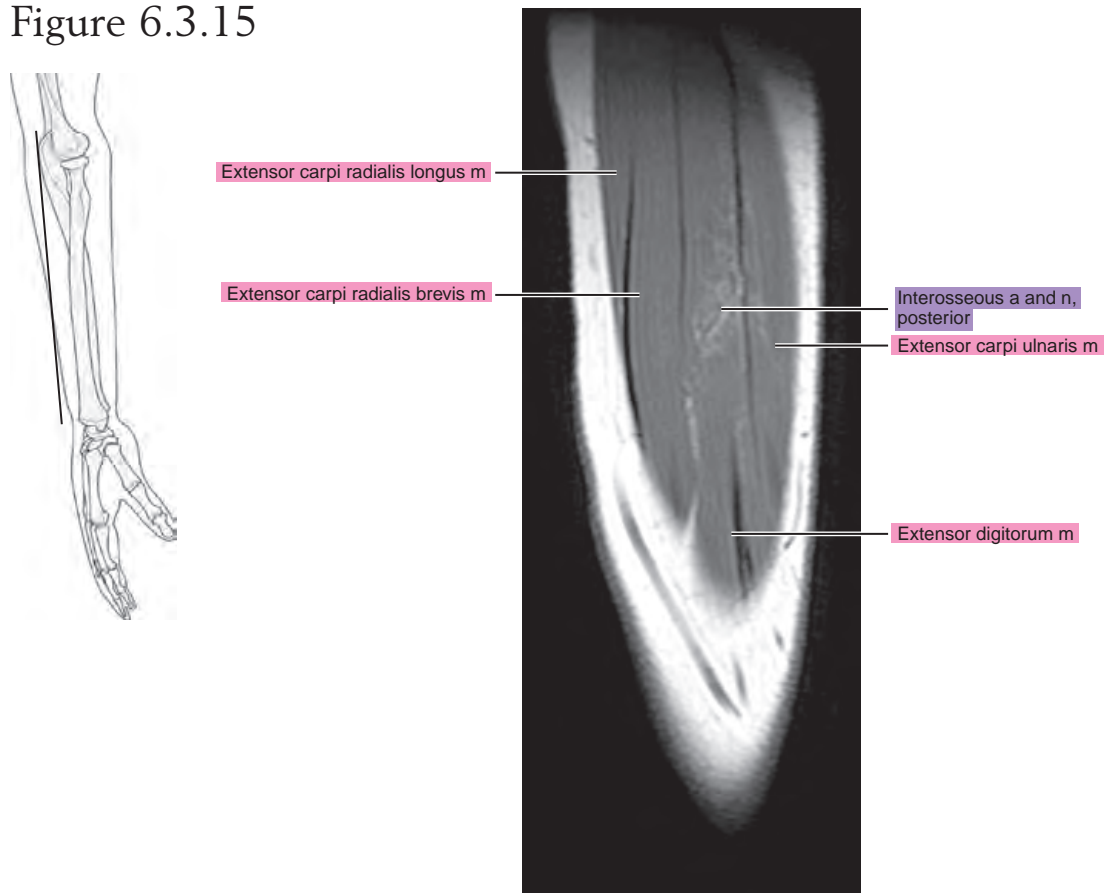
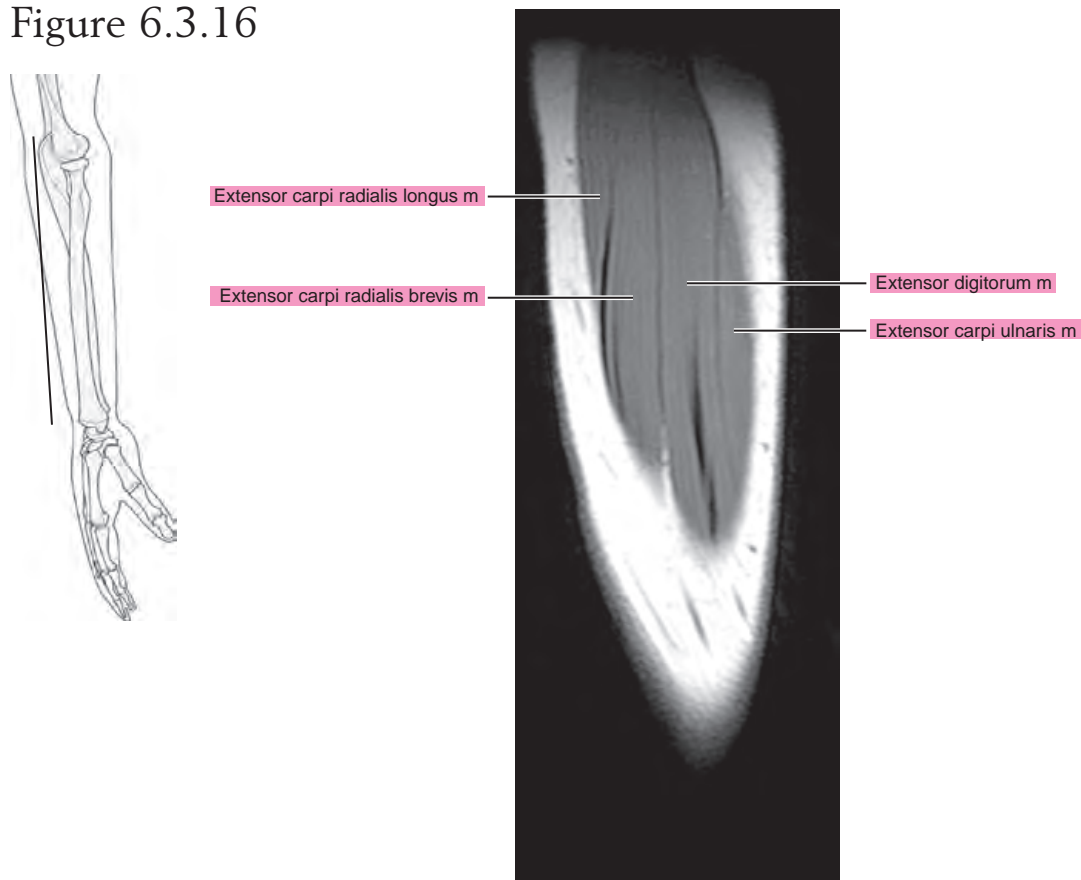


Figure 6.3.16

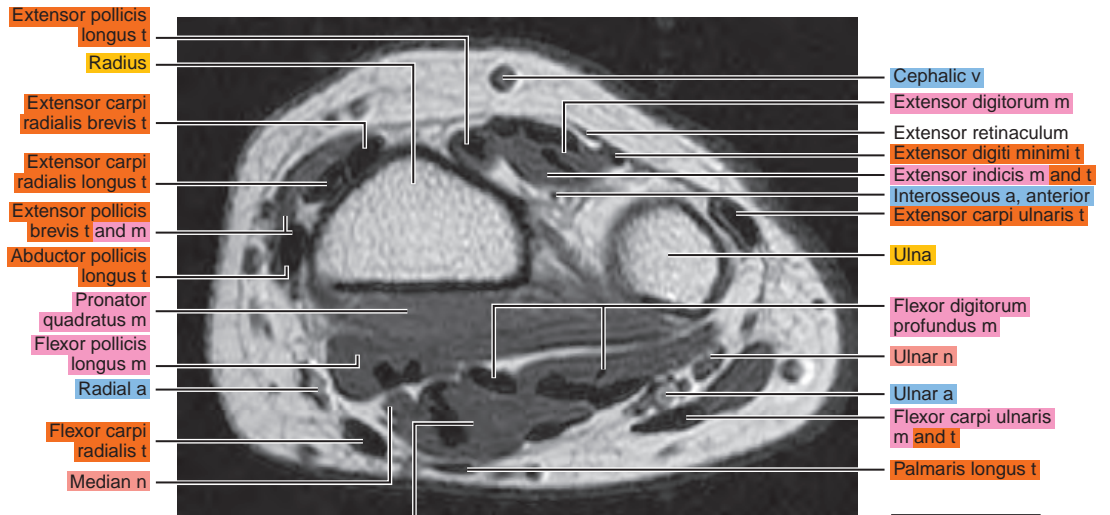
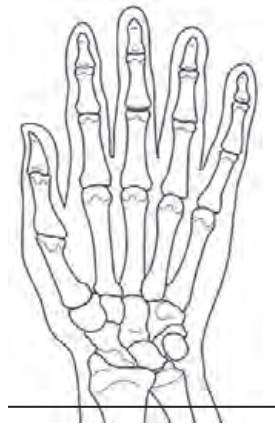

Chapter
7

MRI of the Wrist

AXIAL

Figure 7.1.1



artery = a
arteries = aa
vein = v
veins = vv
muscle = m
muscles = mm
tendon = t
tendons = tt
nerve = n
nerves = nn
ligament = lig
ligaments = lig
nerve & vessels
bone

Figure 7.1.2

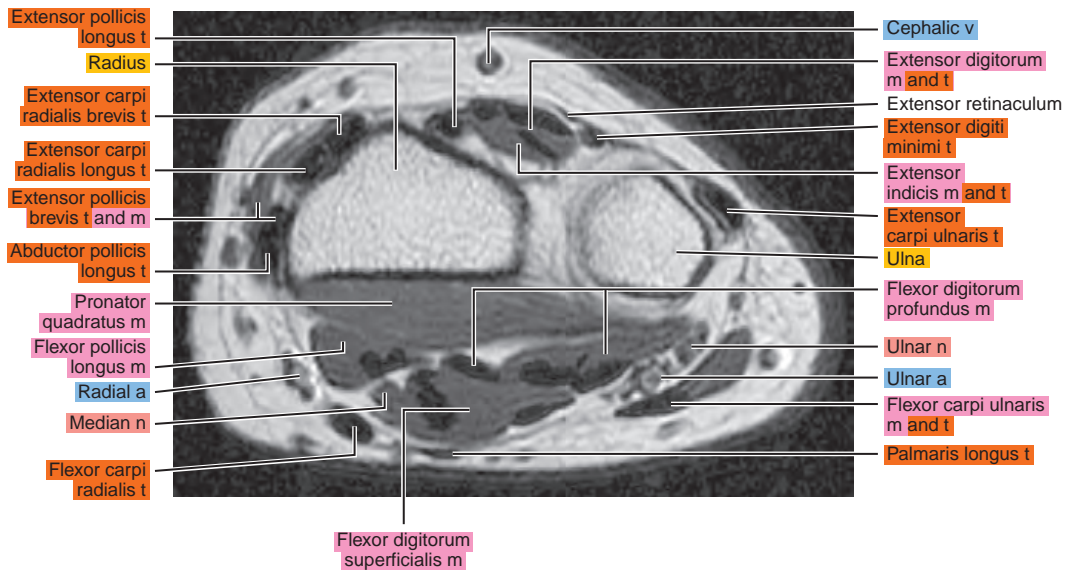
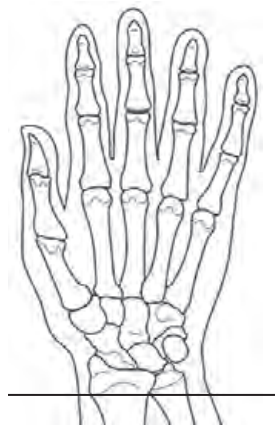

Figure 7.1.3

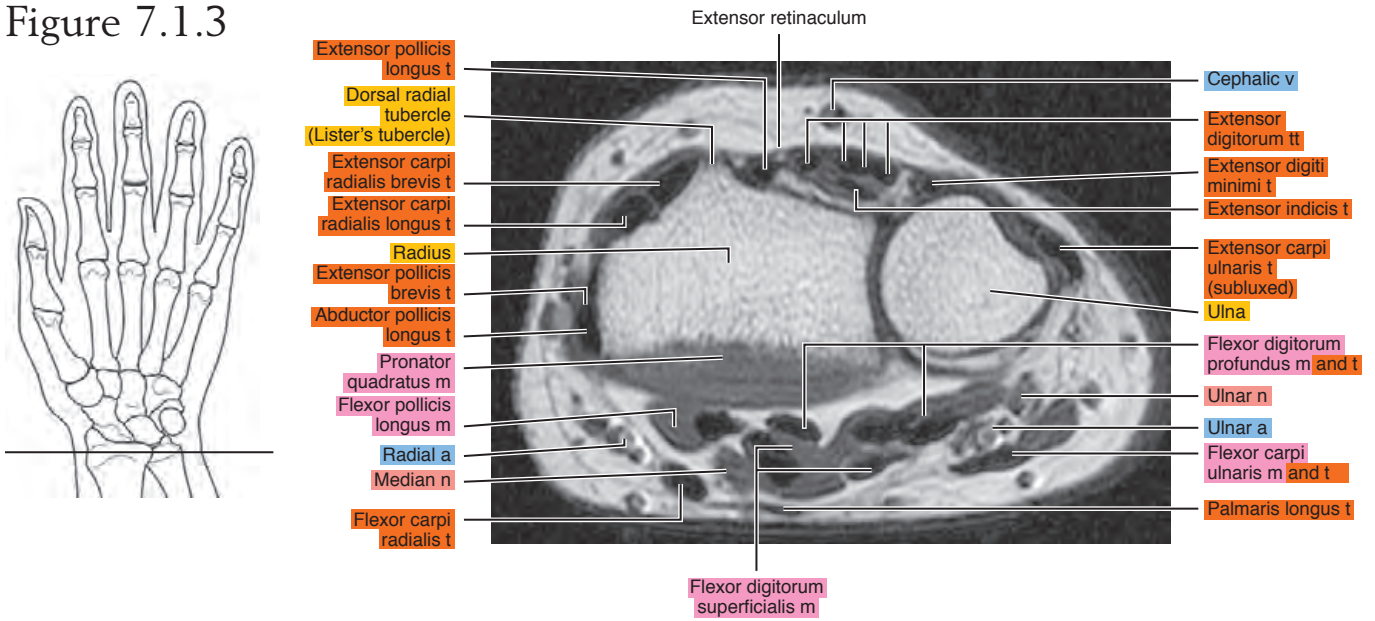


Figure 7.1.4

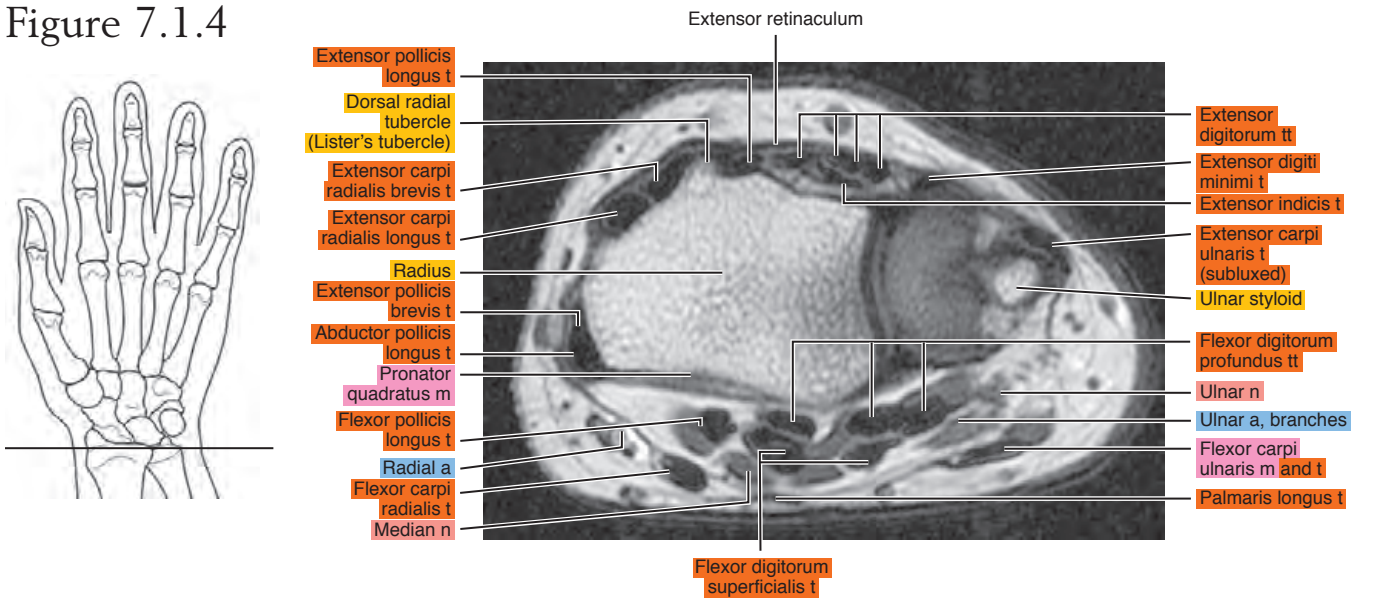


Figure 7.1.5

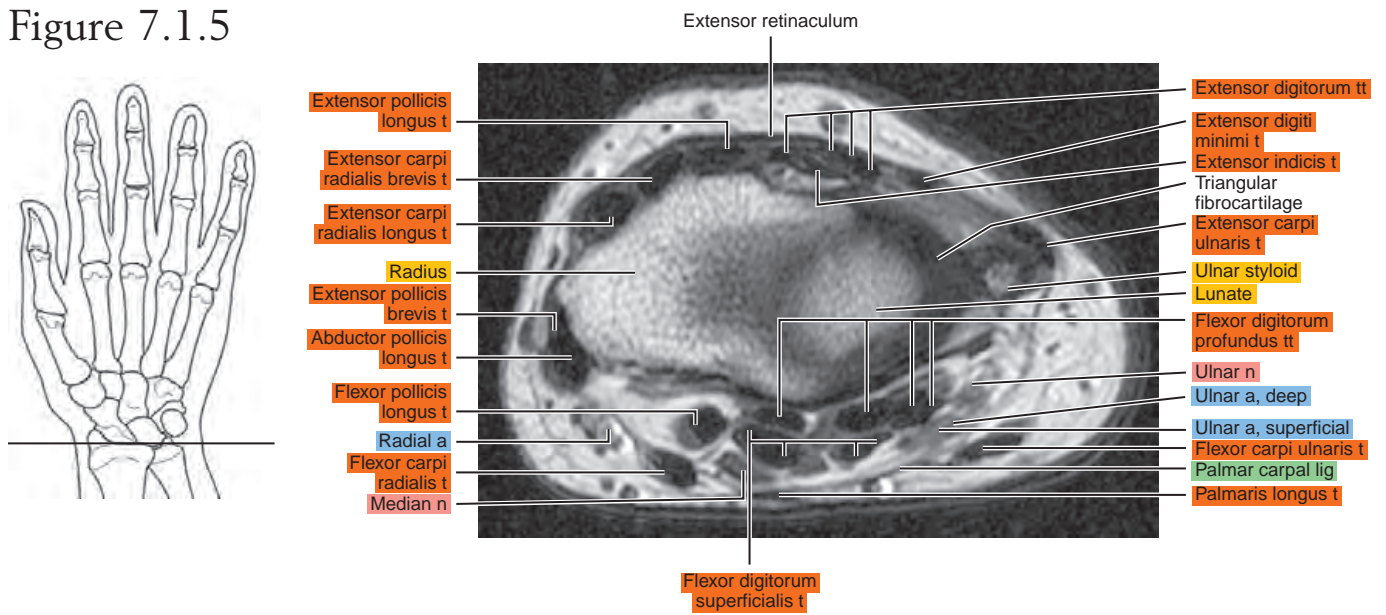


Figure 7.1.6

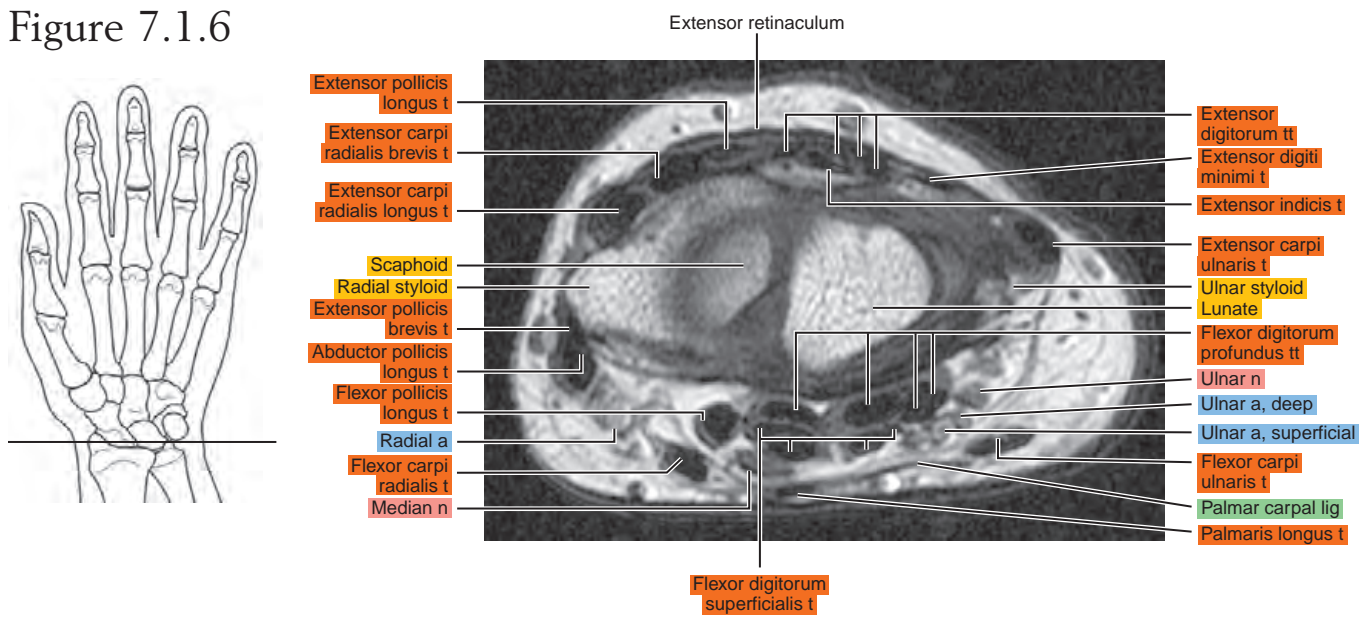


Figure 7.1.7

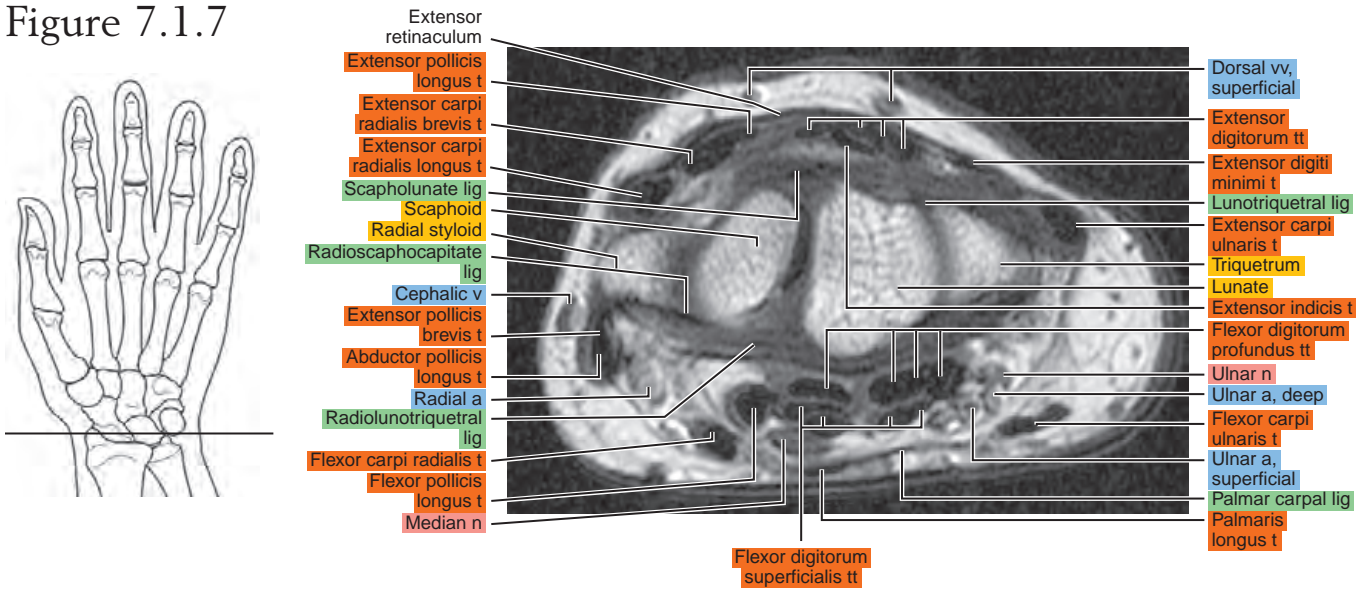


Figure 7.1.8

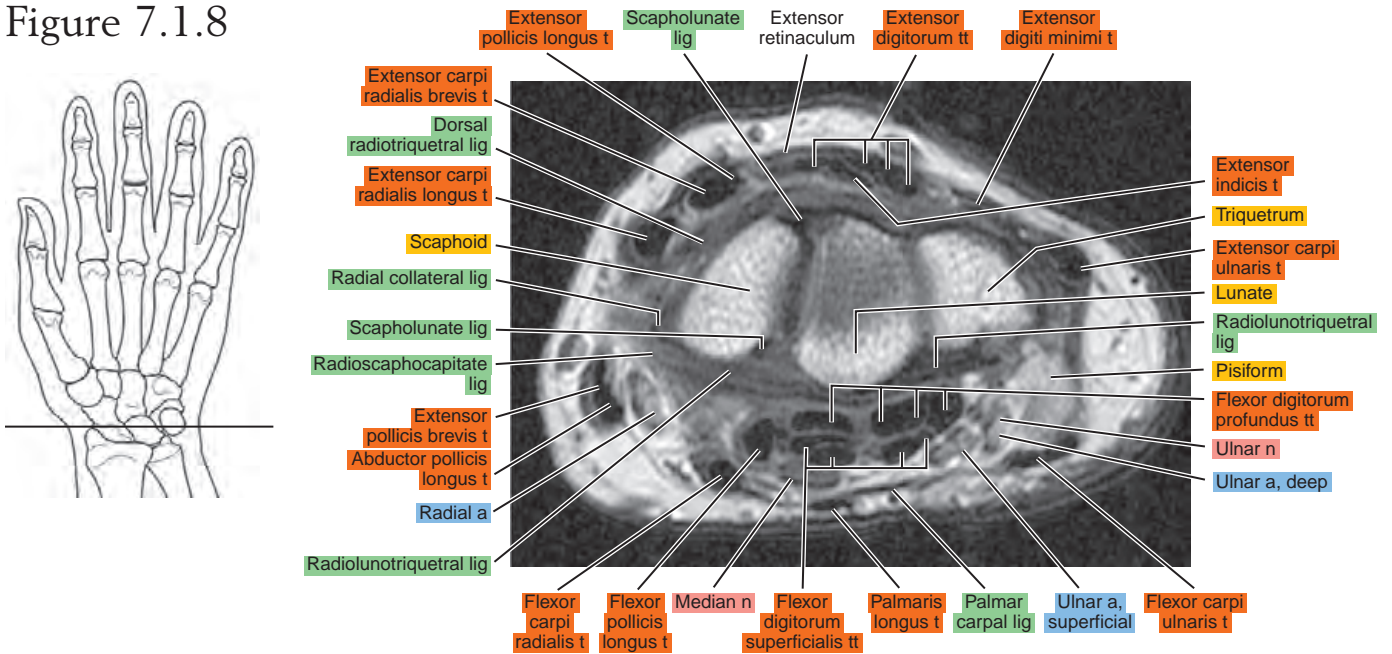


Figure 7.1.9

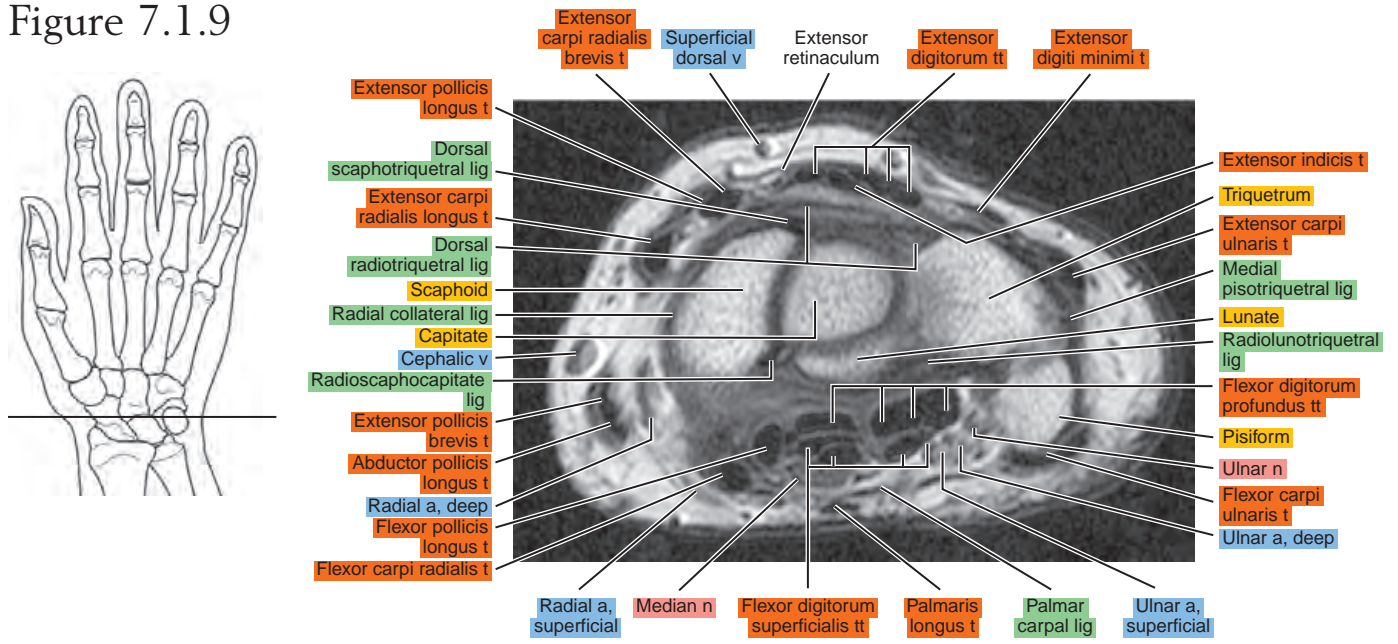


Figure 7.1.10

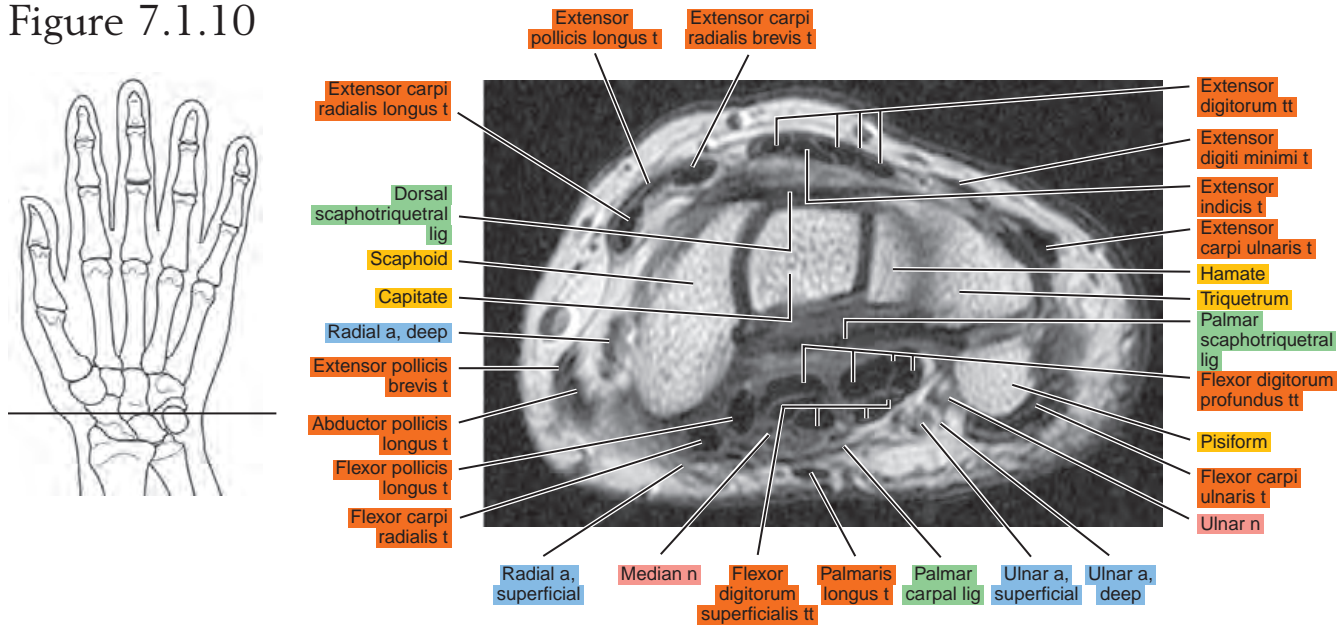


Figure 7.1.11

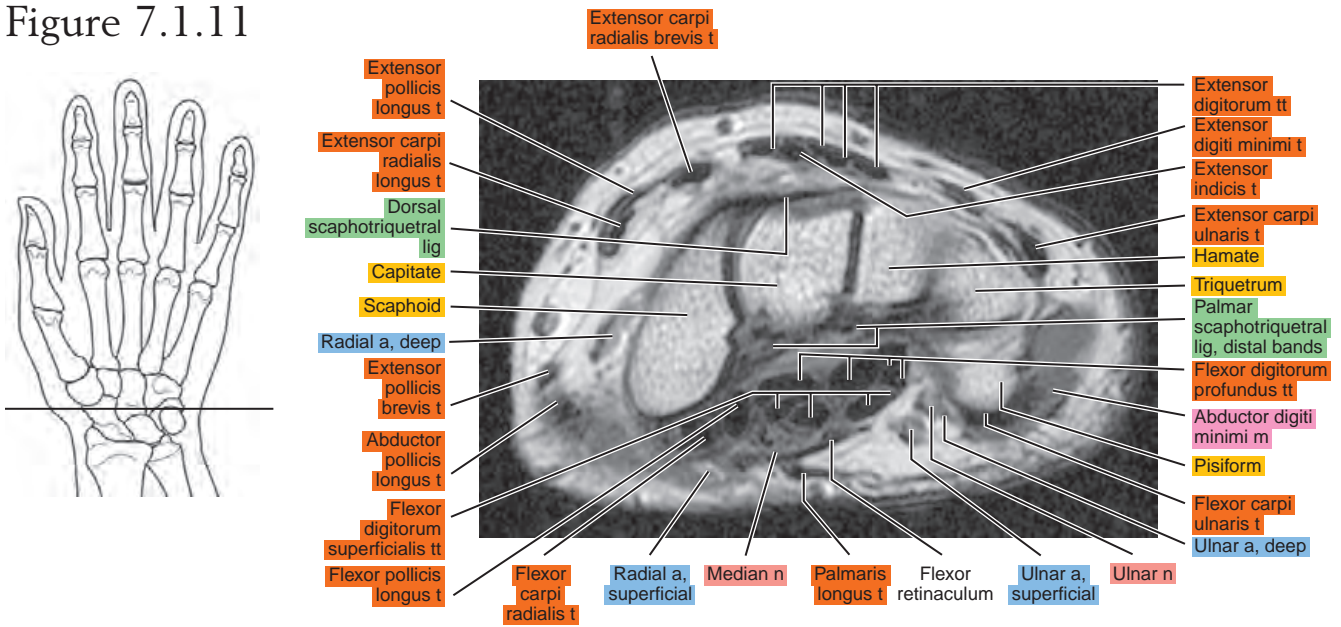


Figure 7.1.12

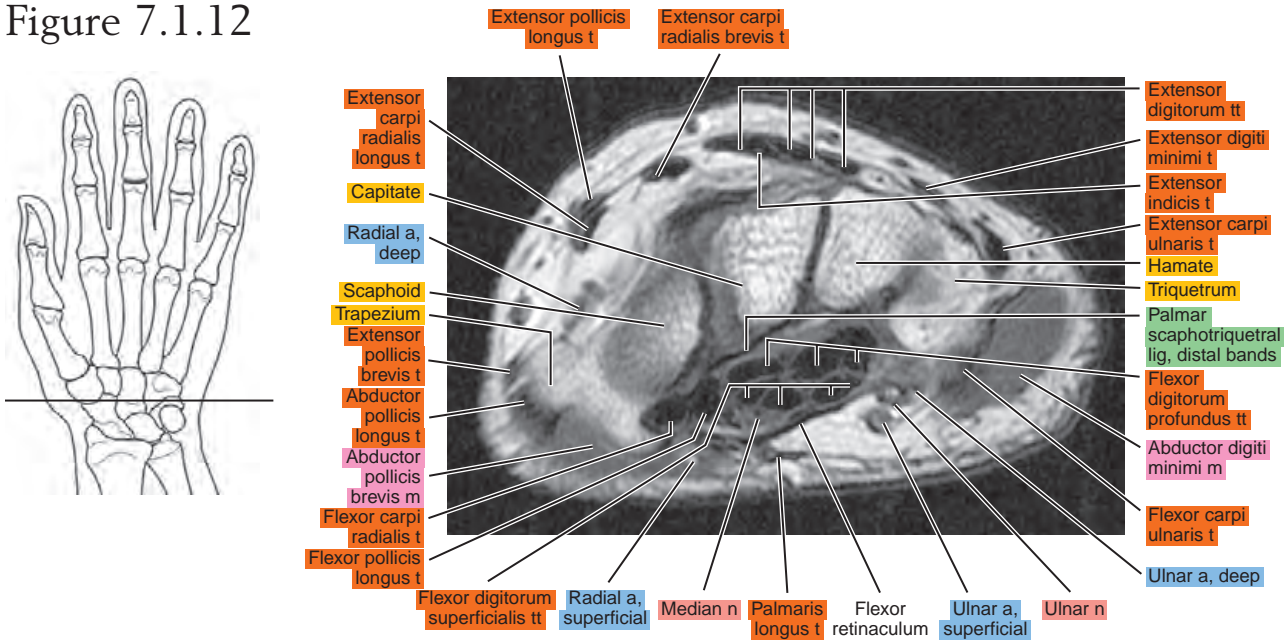


Figure 7.1.13

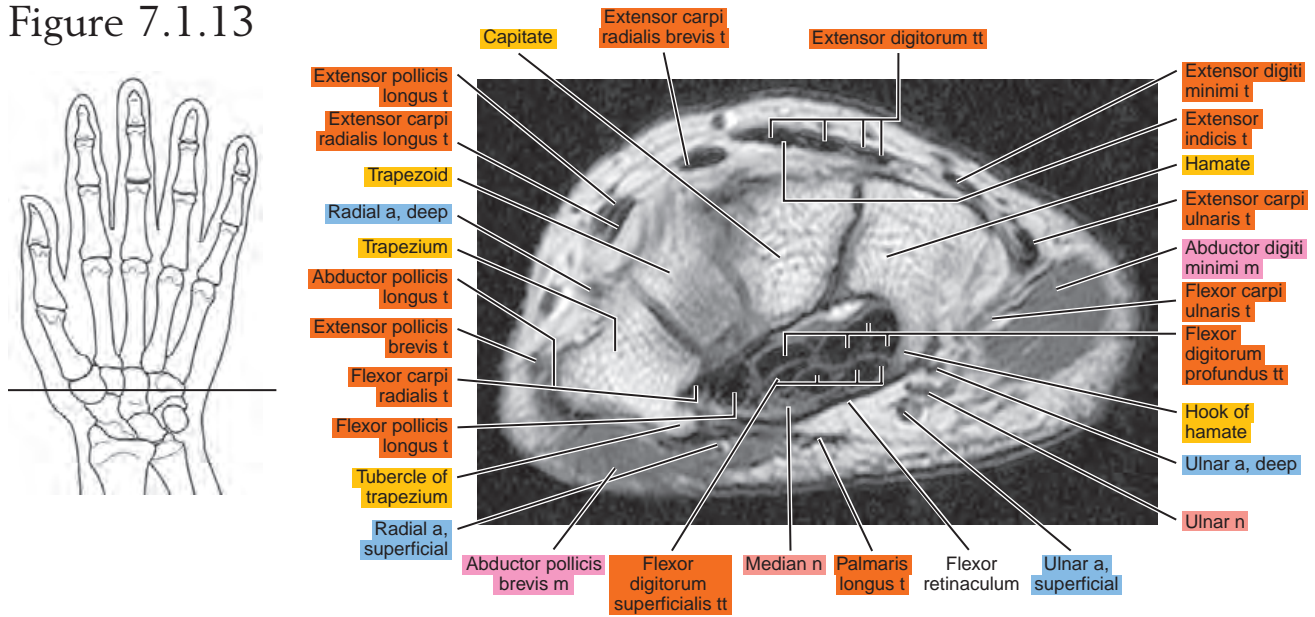


Figure 7.1.14

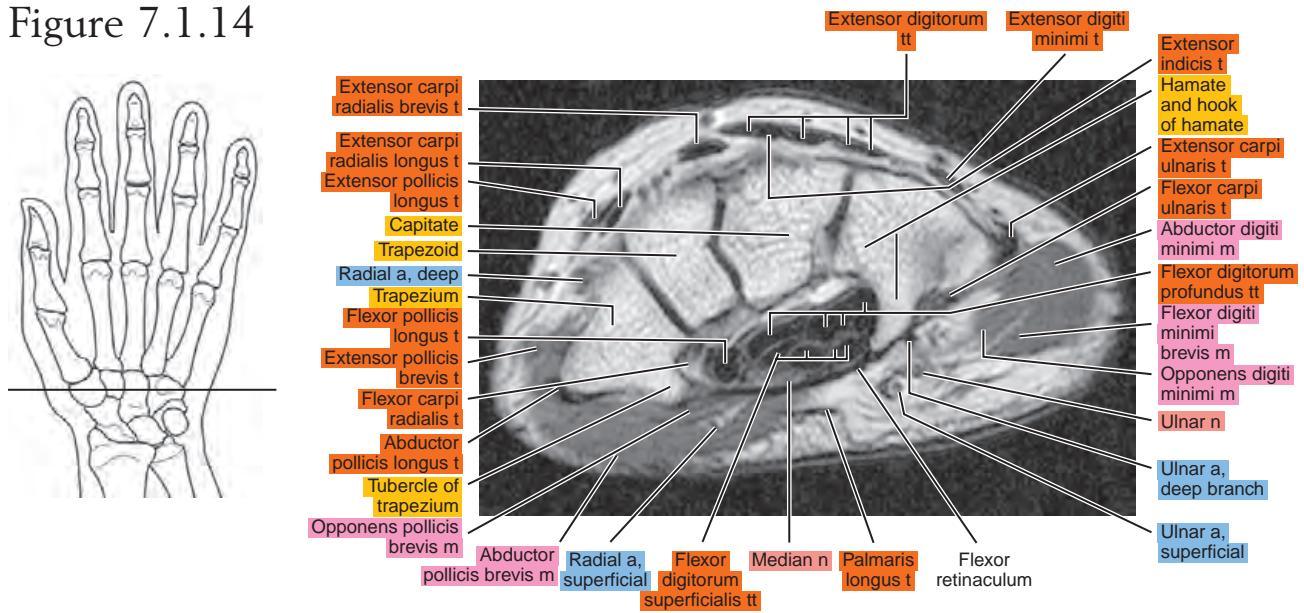


Figure 7.1.15

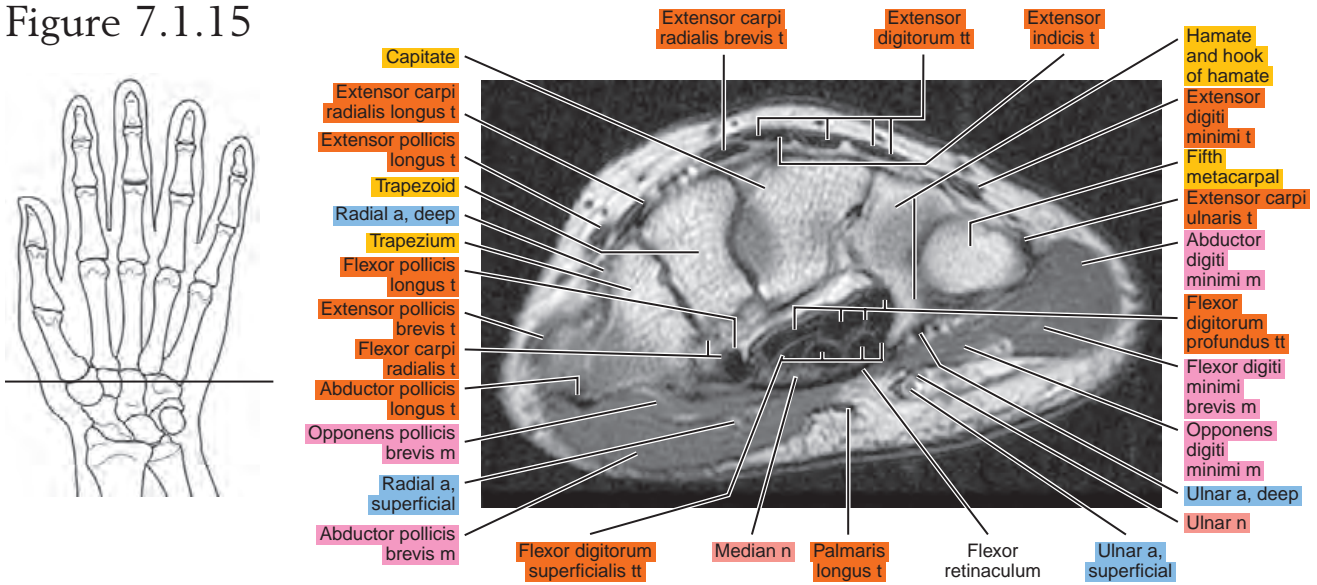


Figure 7.1.16

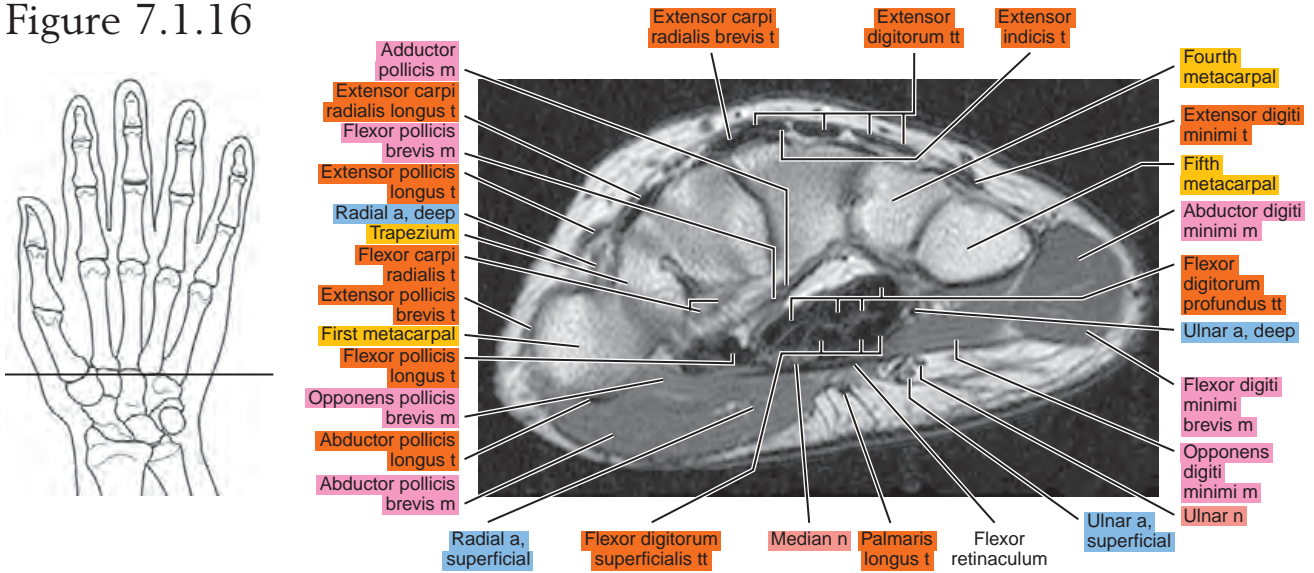


Figure 7.1.17

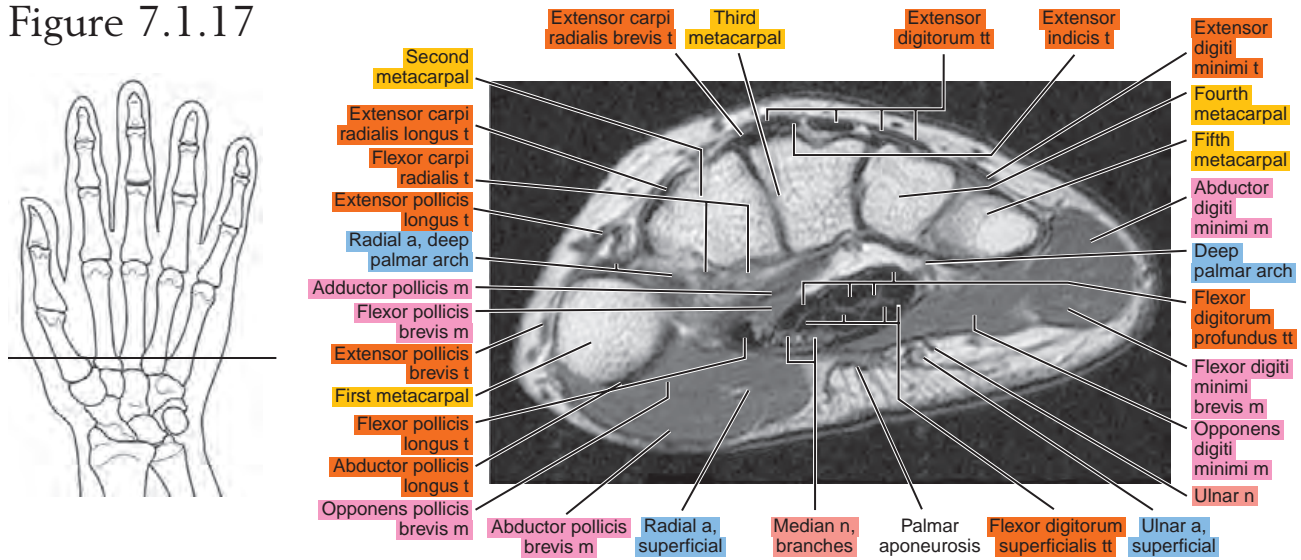
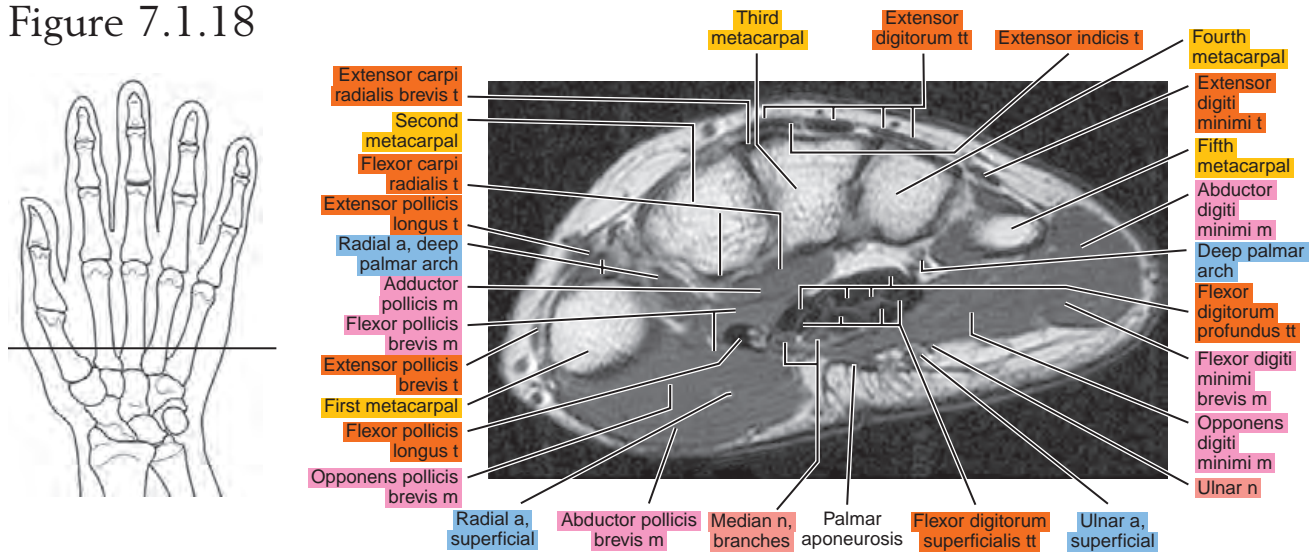


Figure 7.1.18



SAGITTAL

Figure 7.2.1

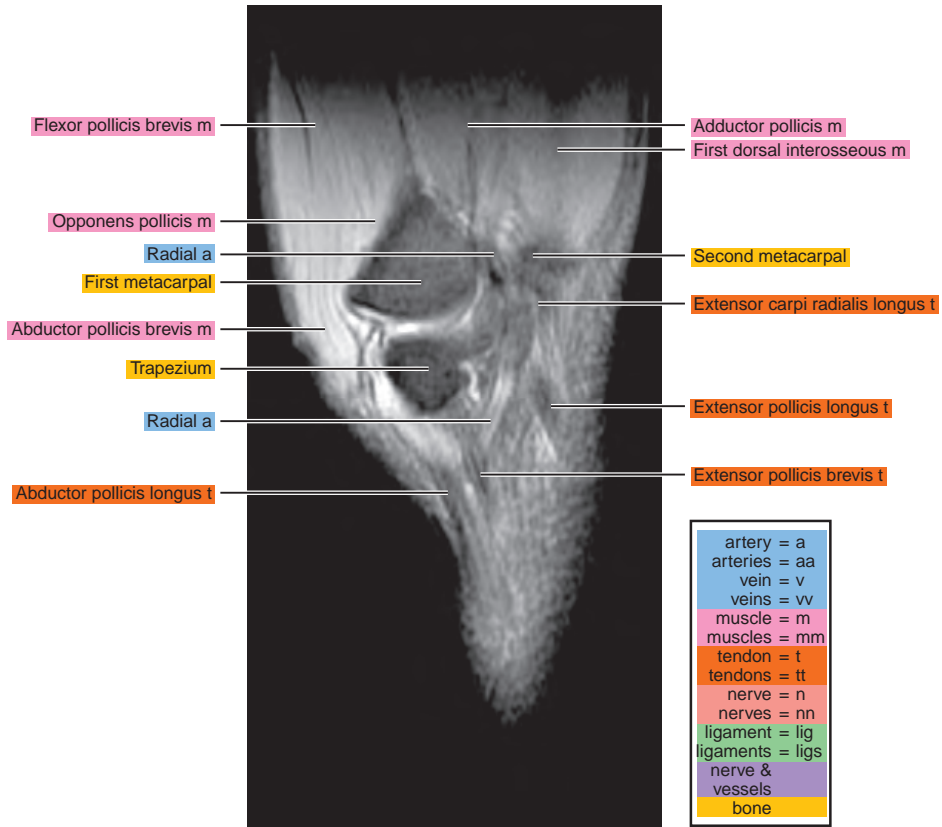
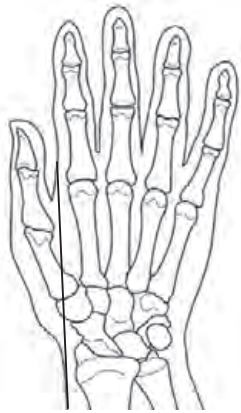

Figure 7.2.2

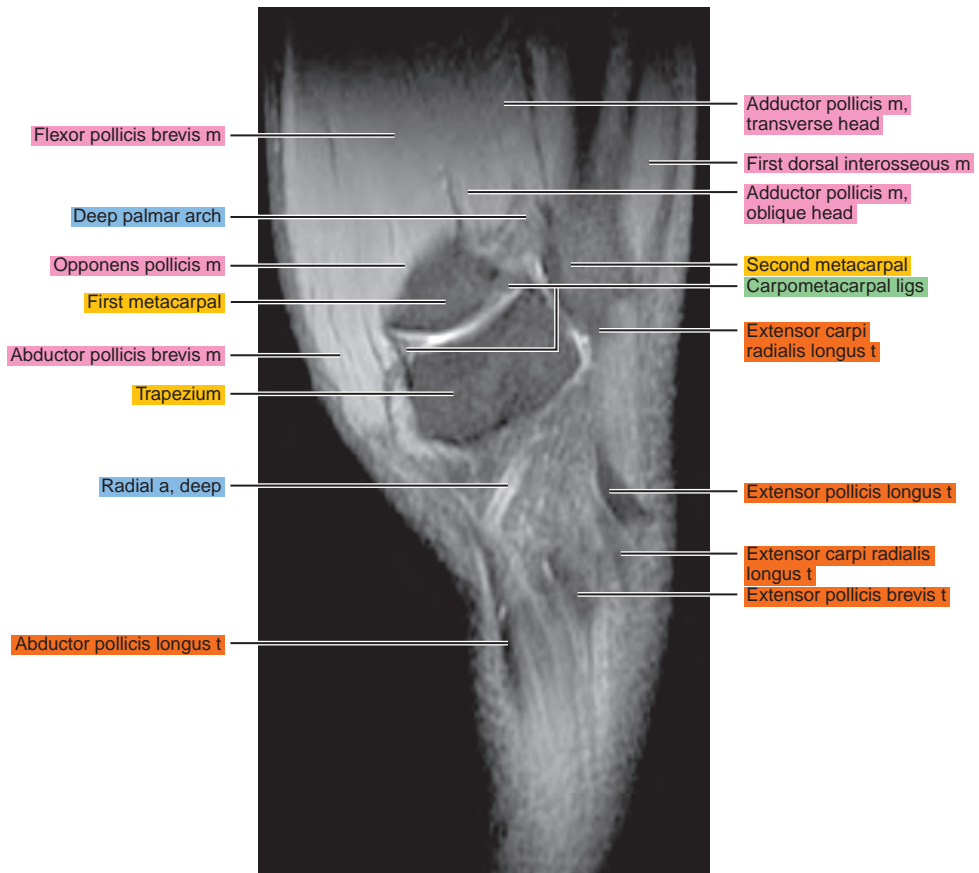
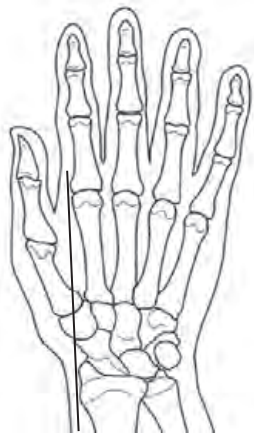

Figure 7.2.3

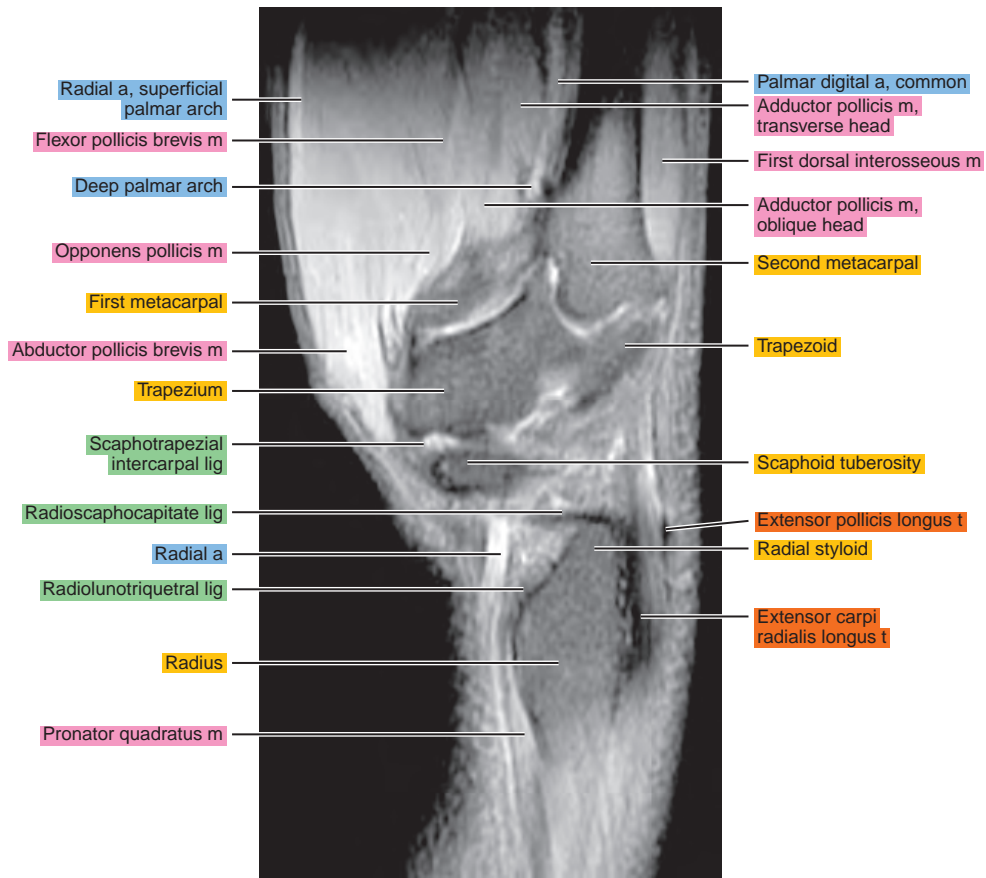
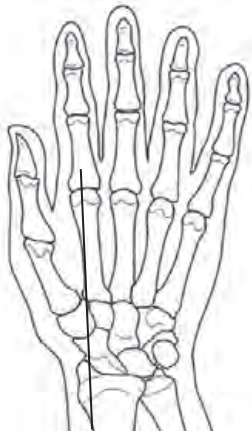

Figure 7.2.4

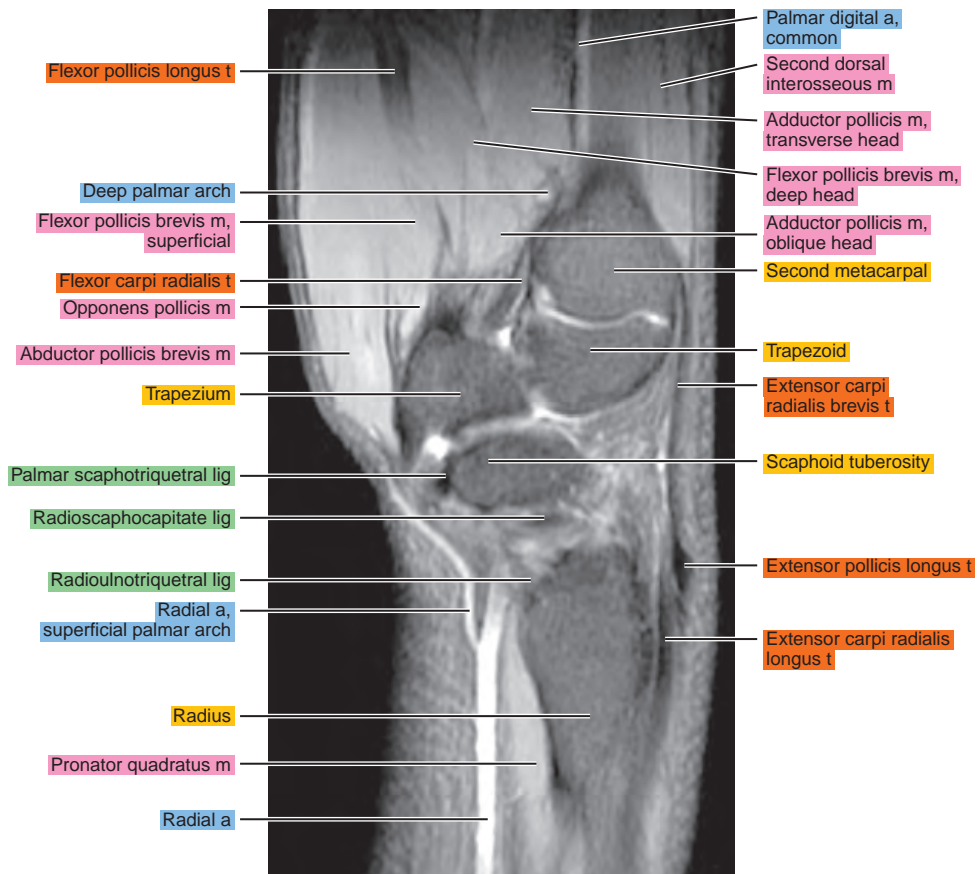
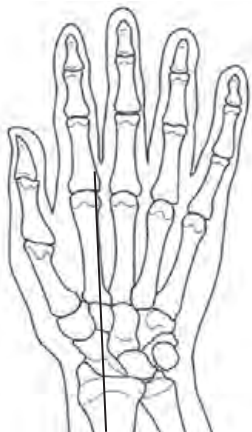

Figure 7.2.5

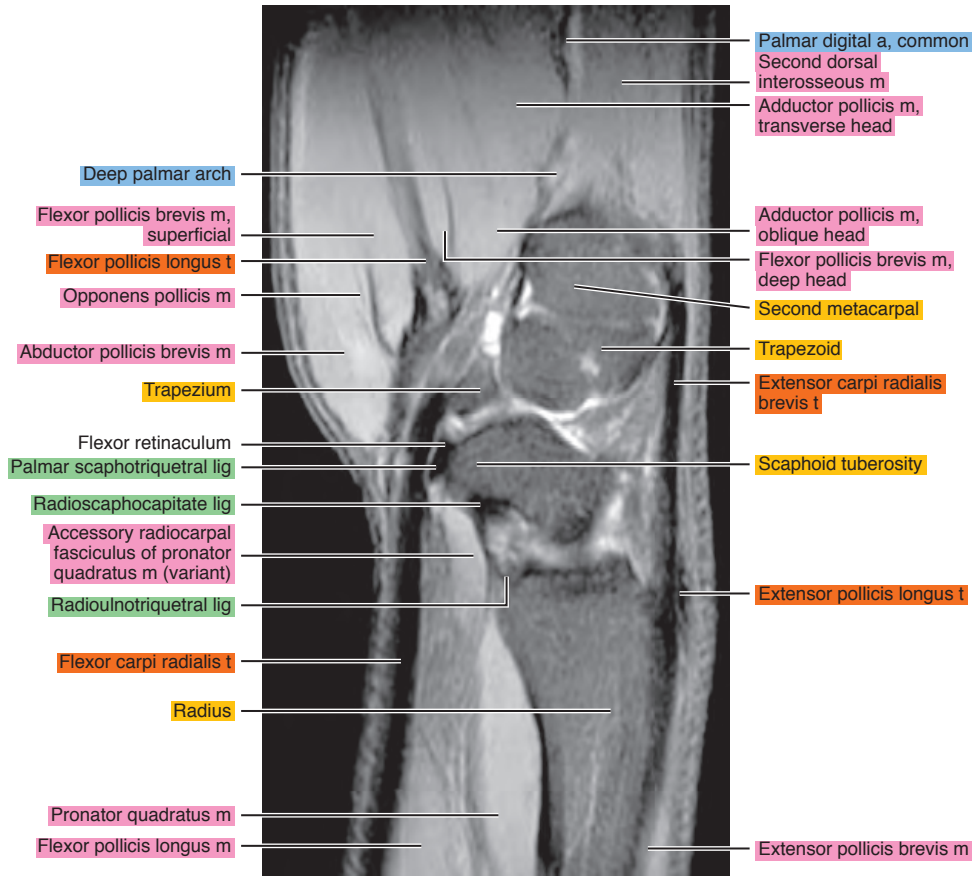
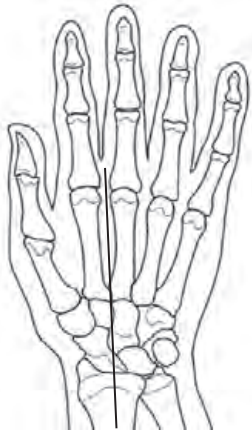

Figure 7.2.6

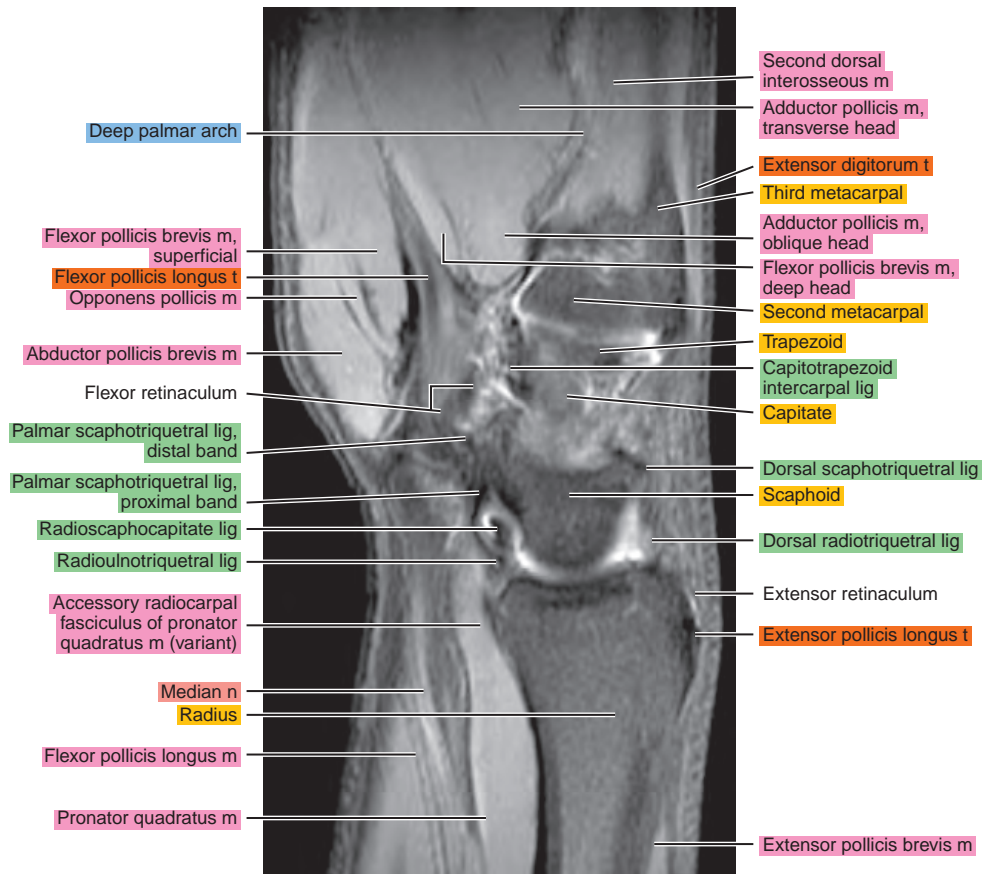
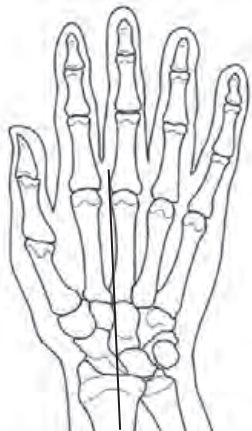

Figure 7.2.7

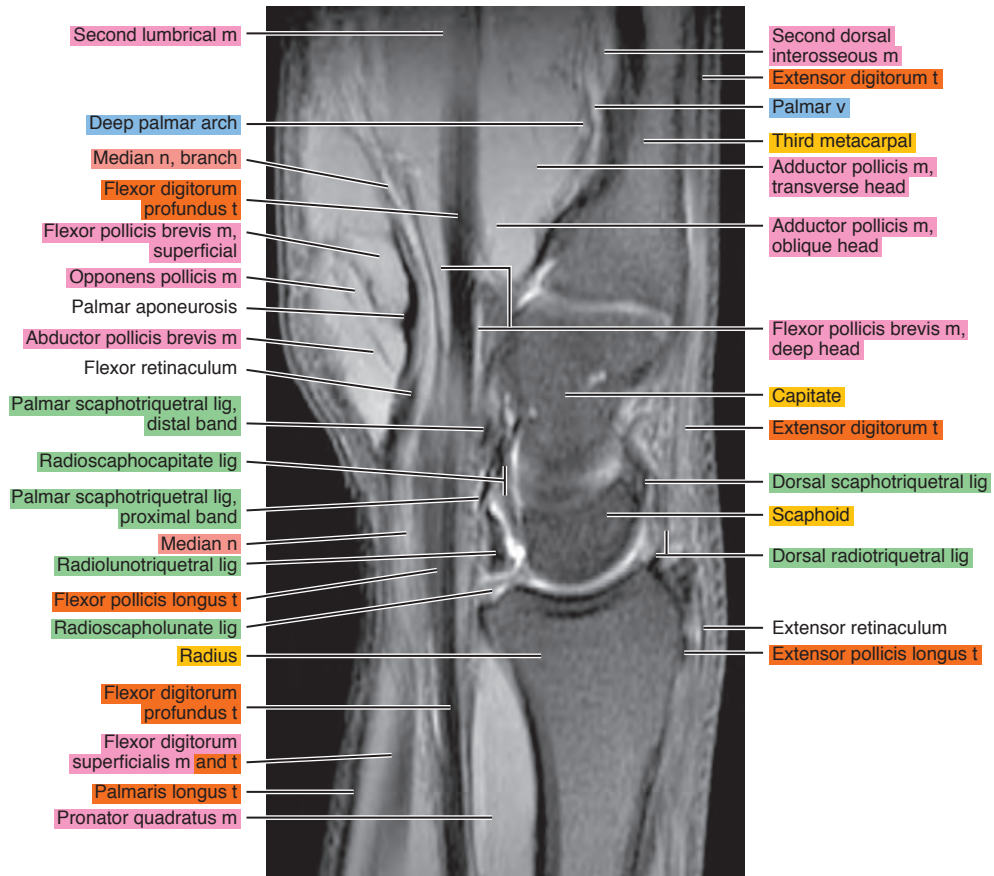
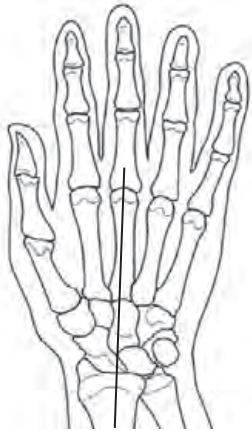

Figure 7.2.8

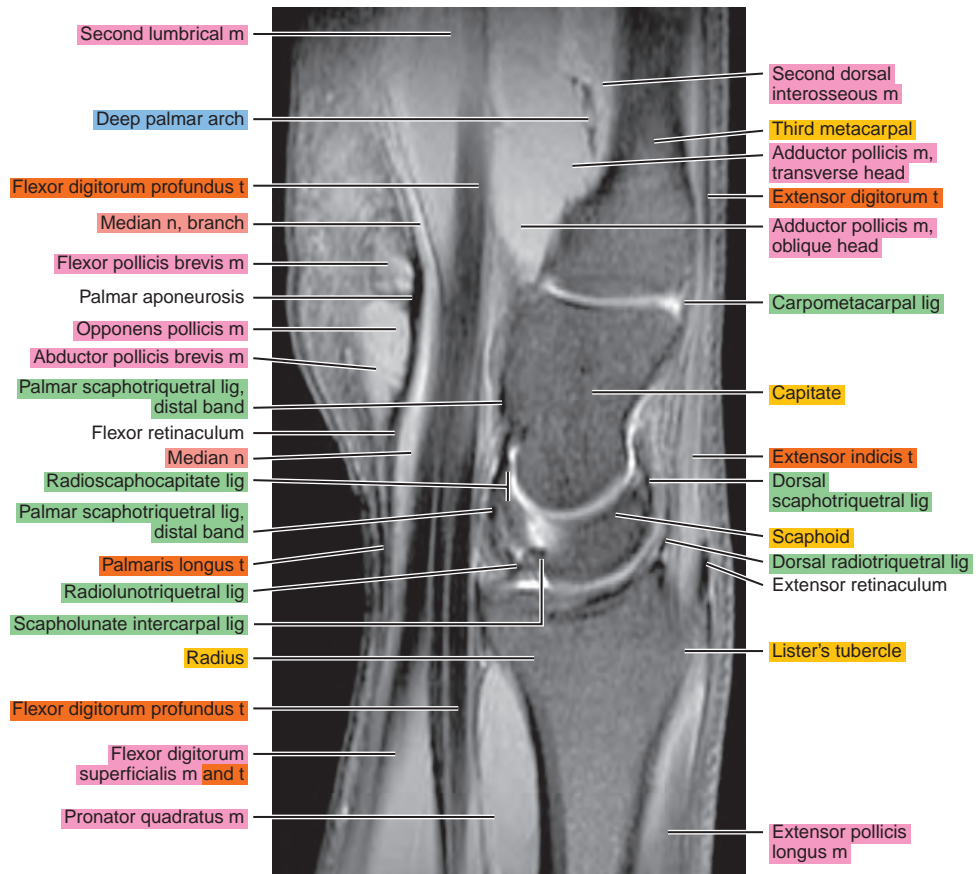
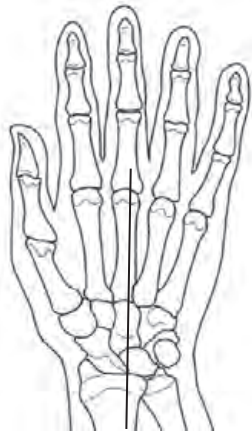

Figure 7.2.9

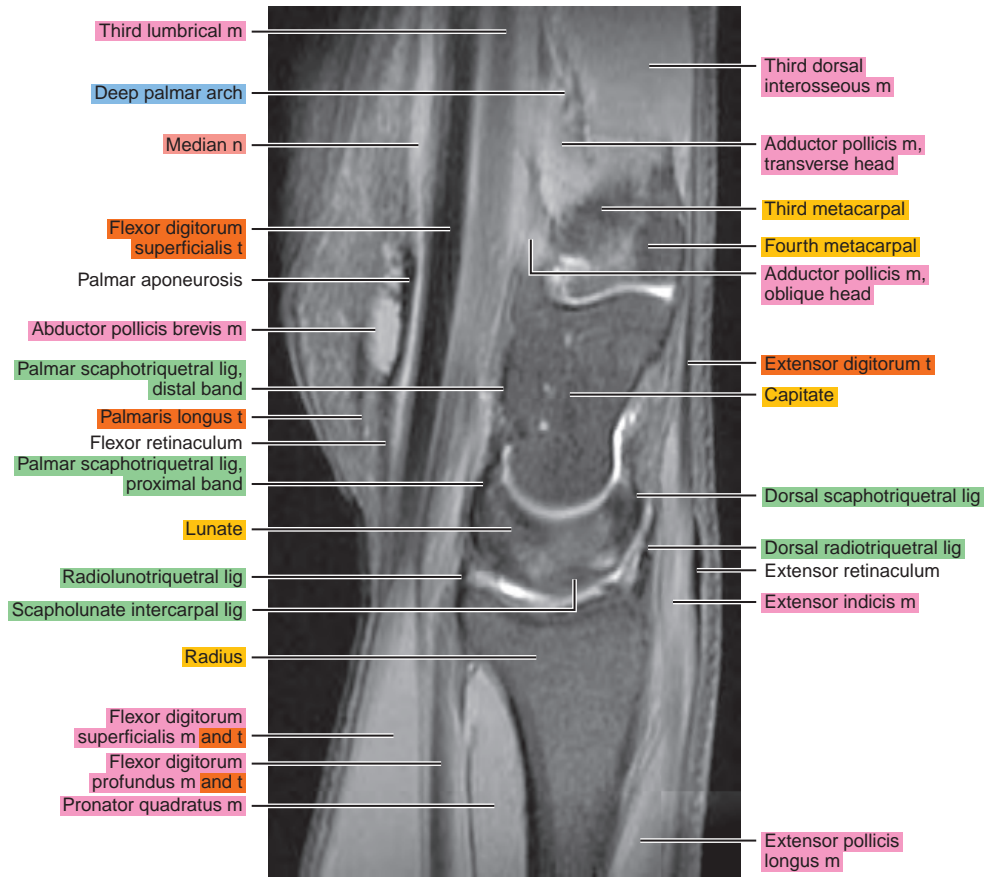
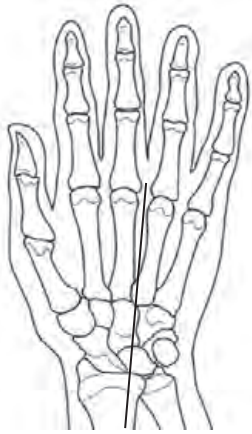

Figure 7.2.10

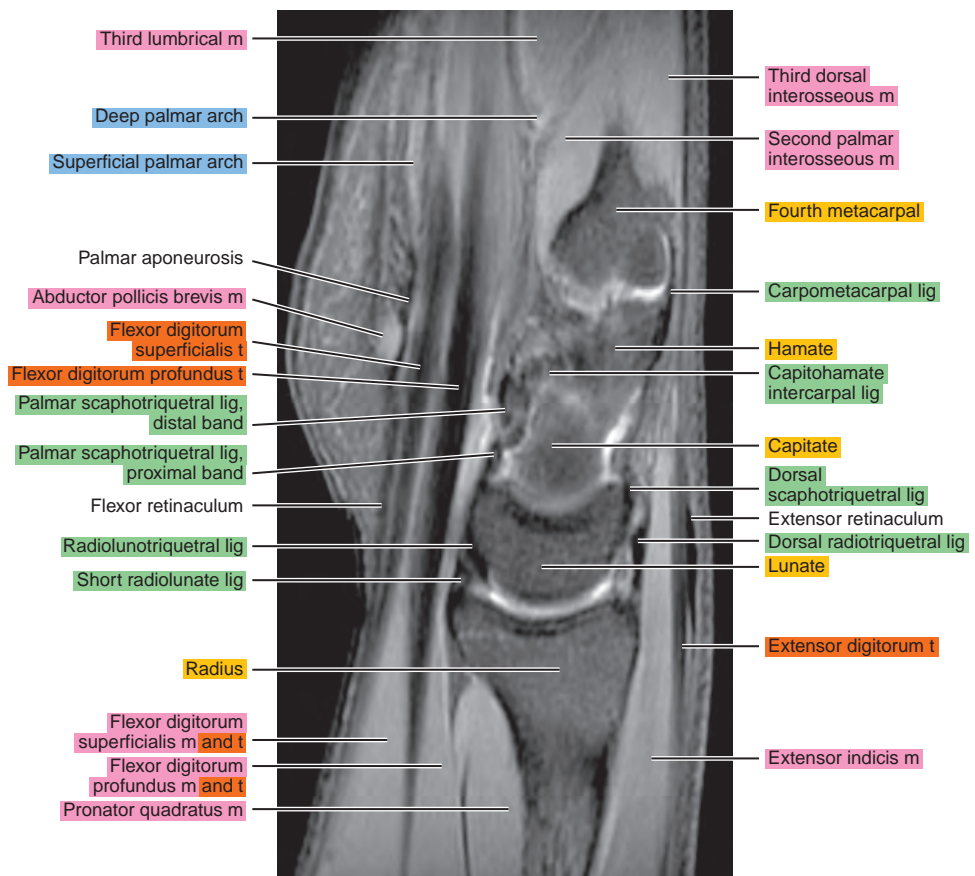
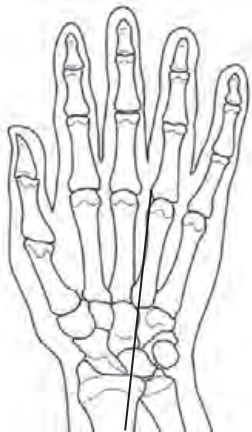

Figure 7.2.11

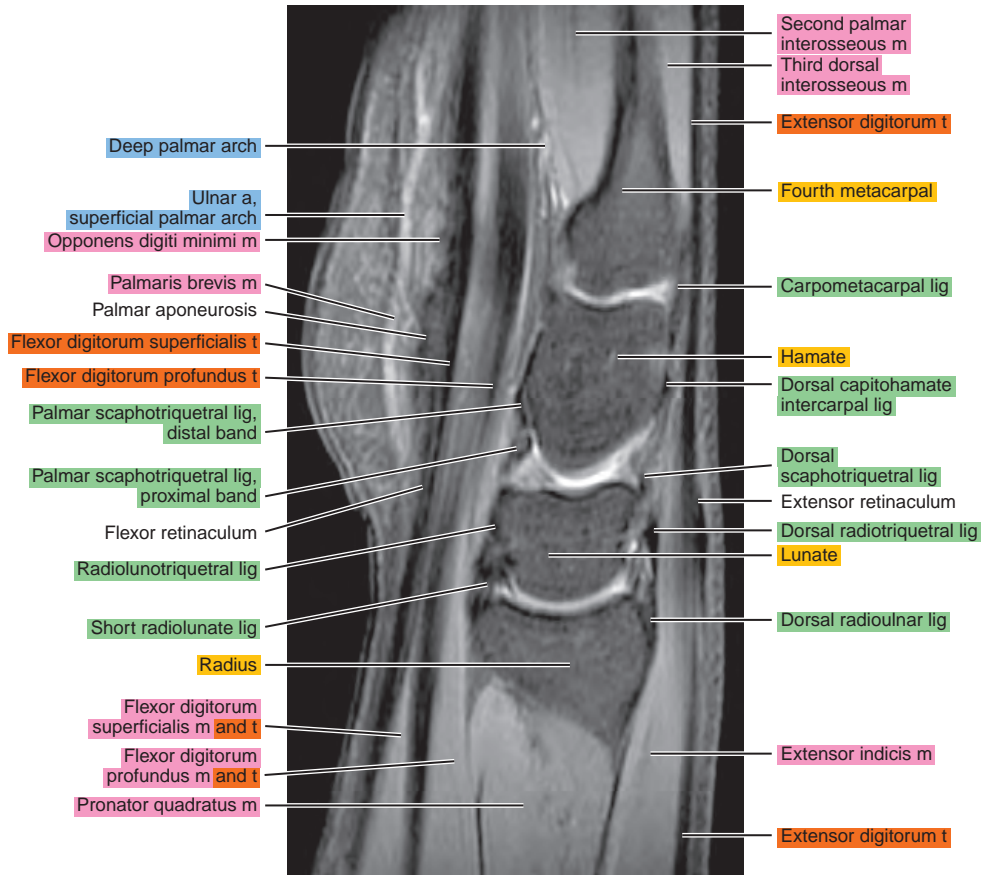
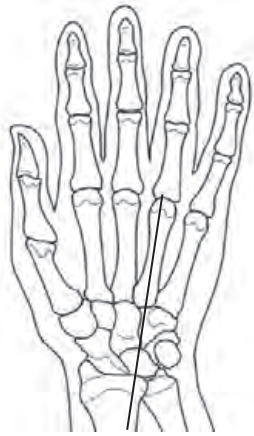

Figure 7.2.12

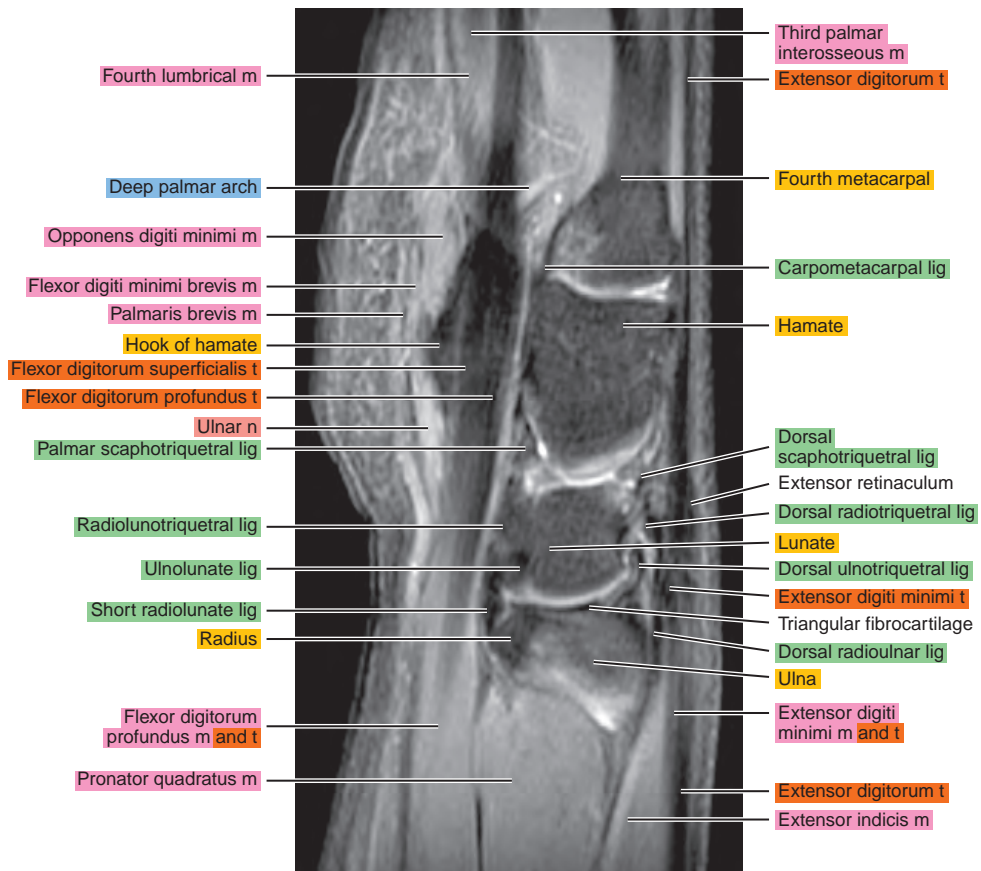
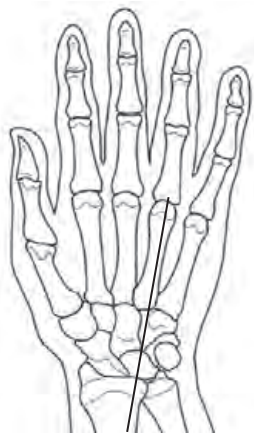

Figure 7.2.13

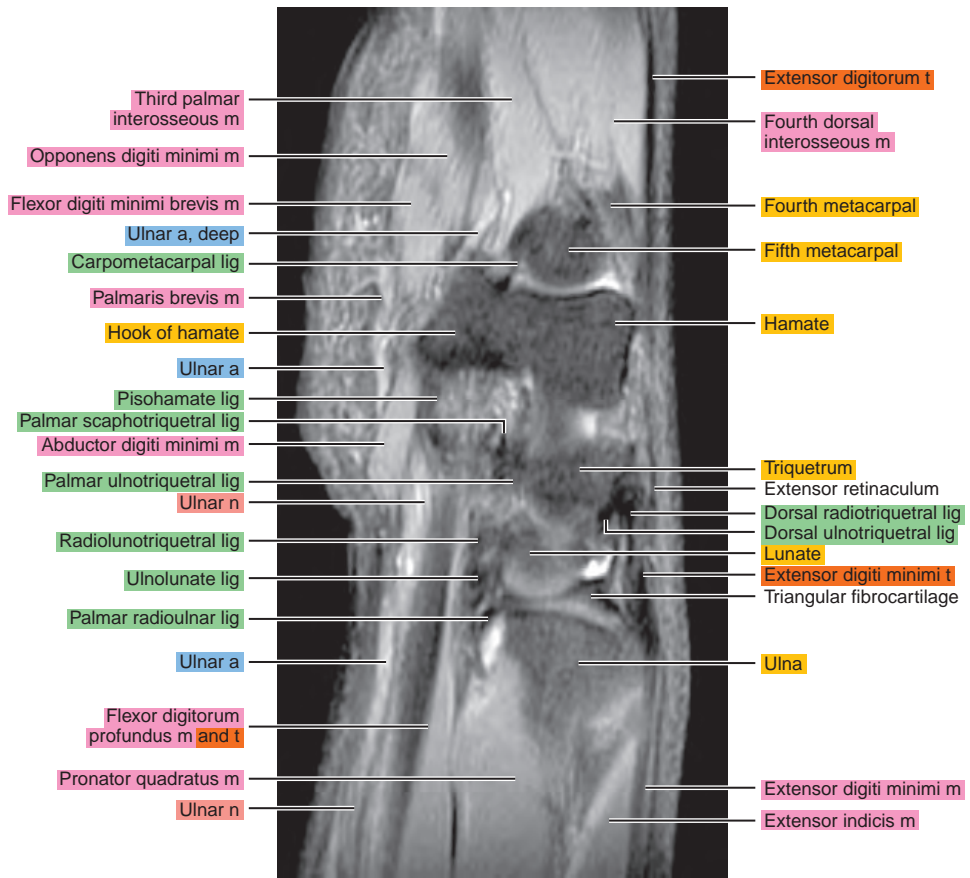
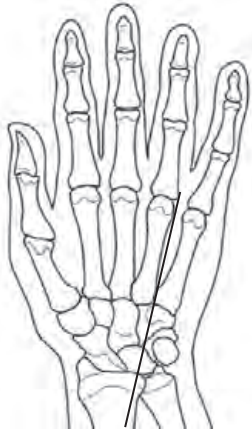

Figure 7.2.14

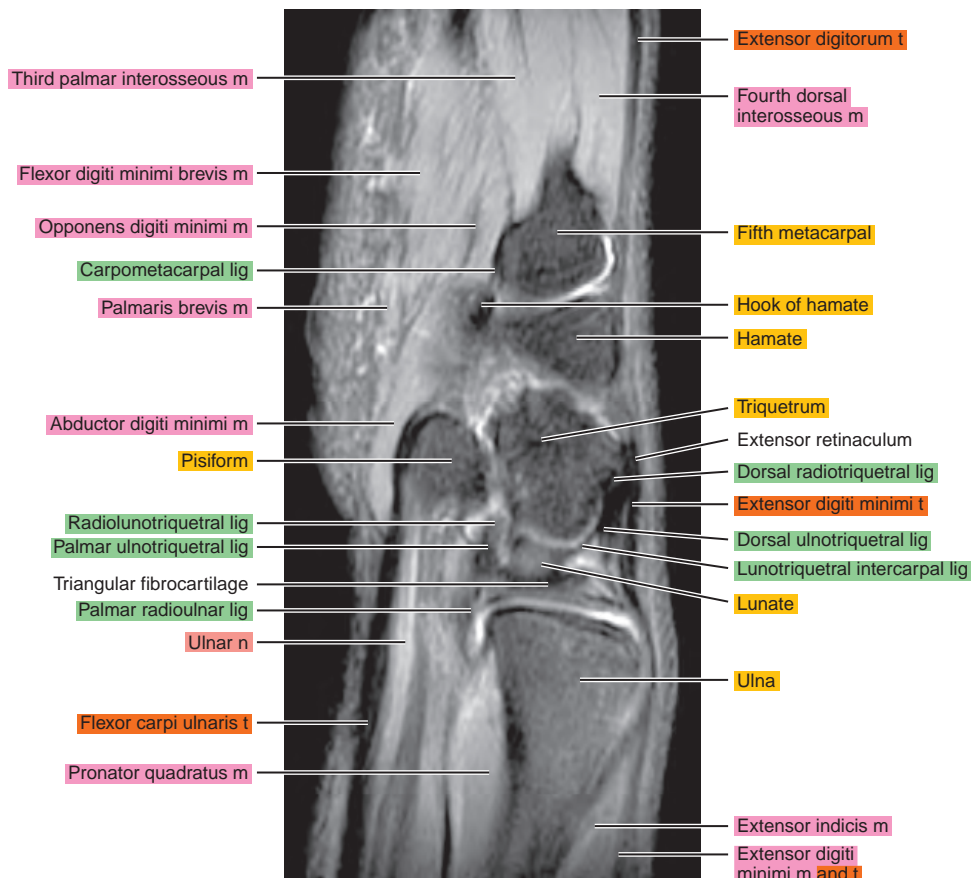
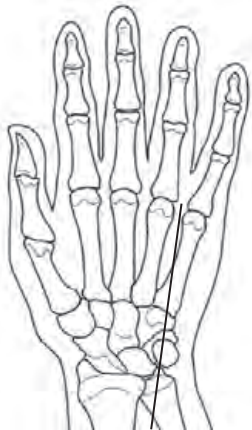


Figure 7.2.15

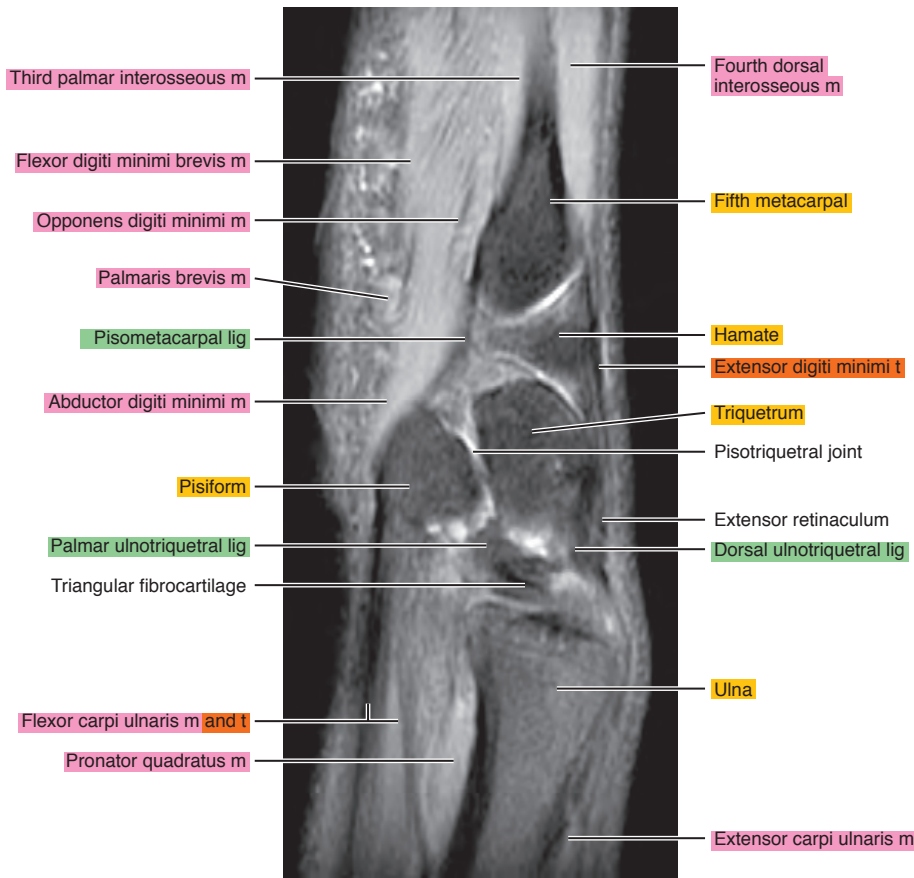
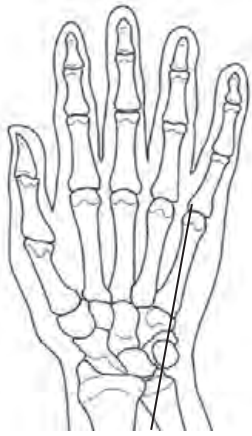

Figure 7.2.16

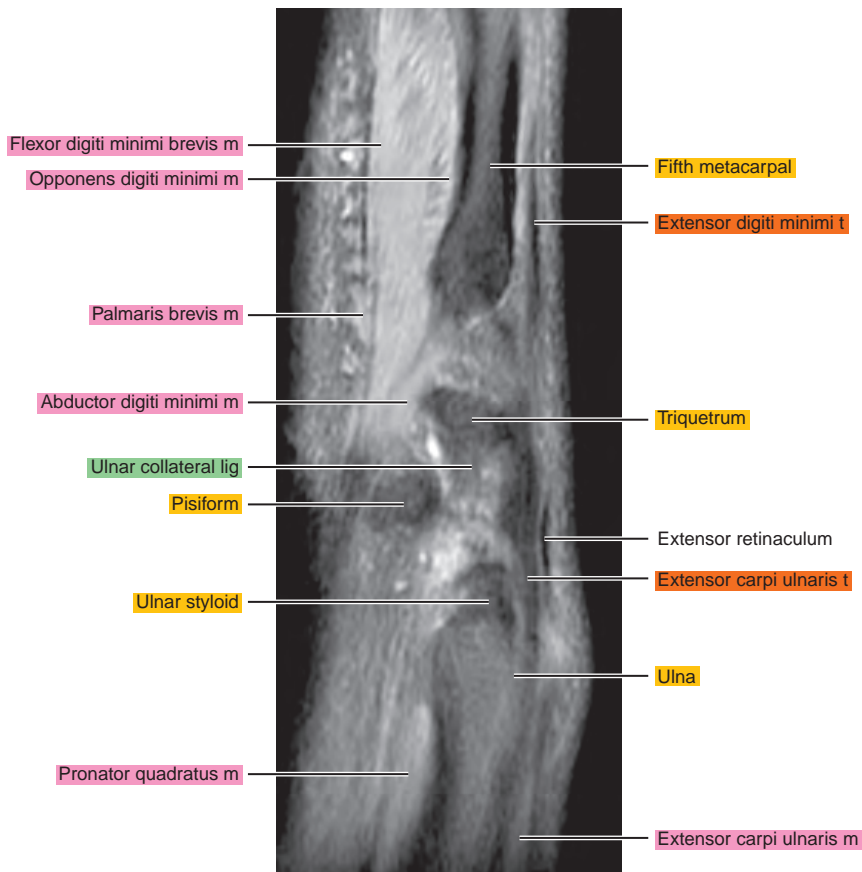
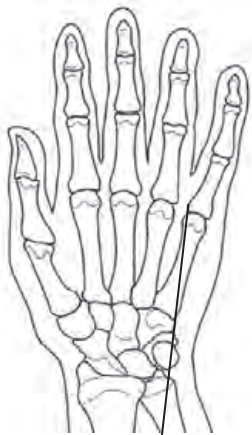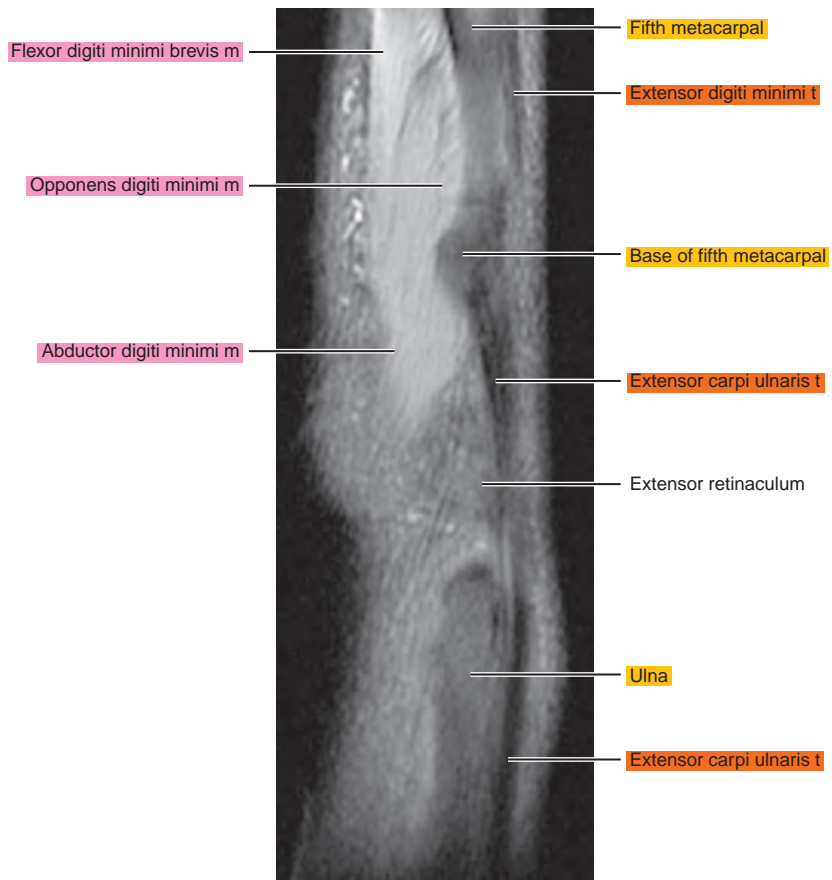

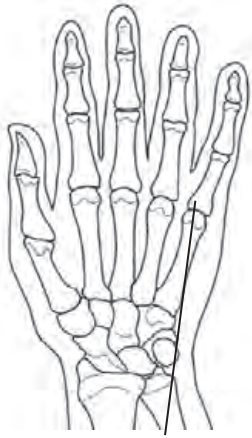
Figure 7.2.17



CORONAL

Figure 7.3.1

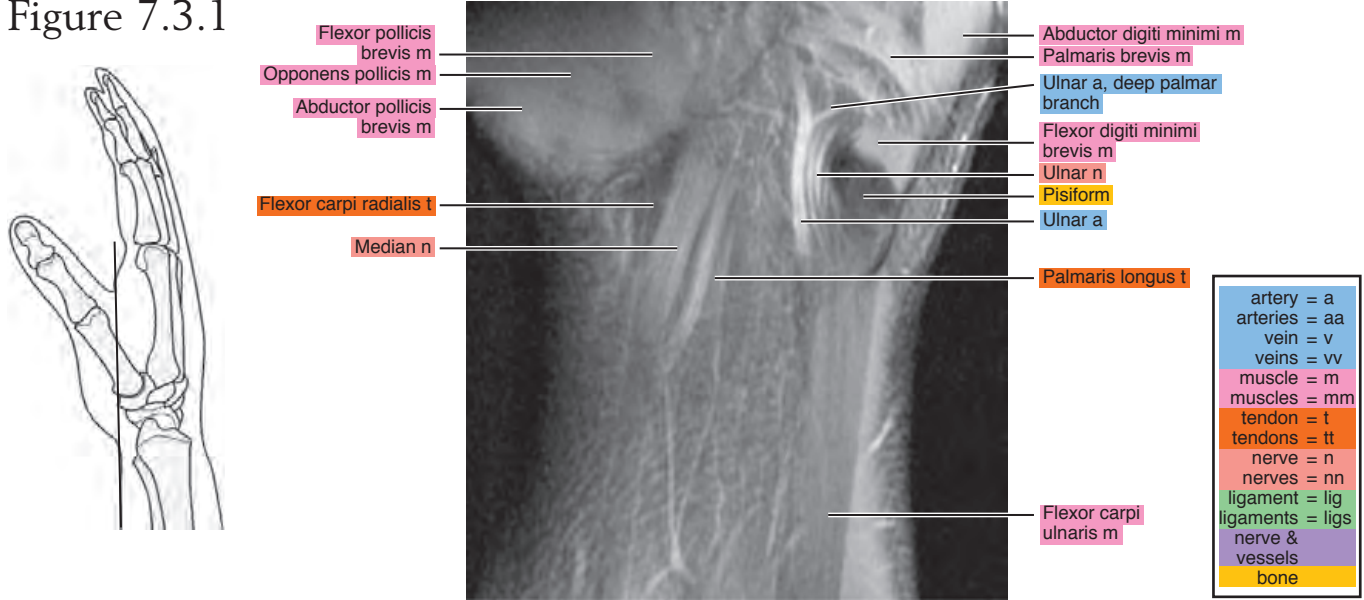


Figure 7.3.2

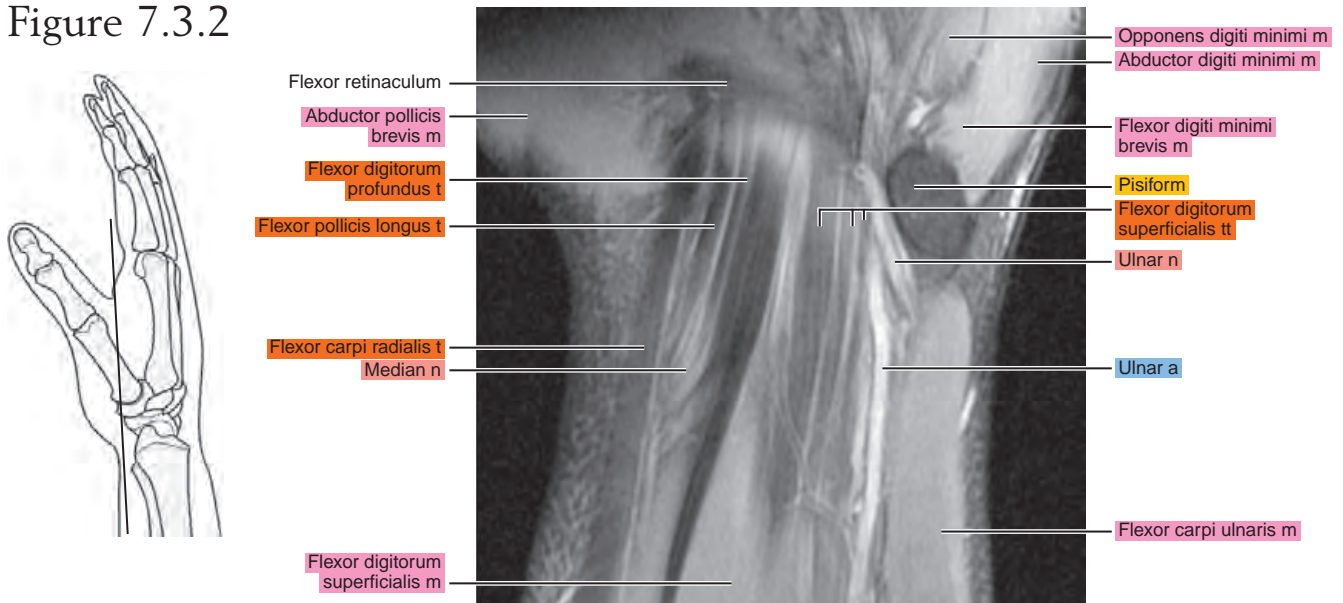


Figure 7.3.3

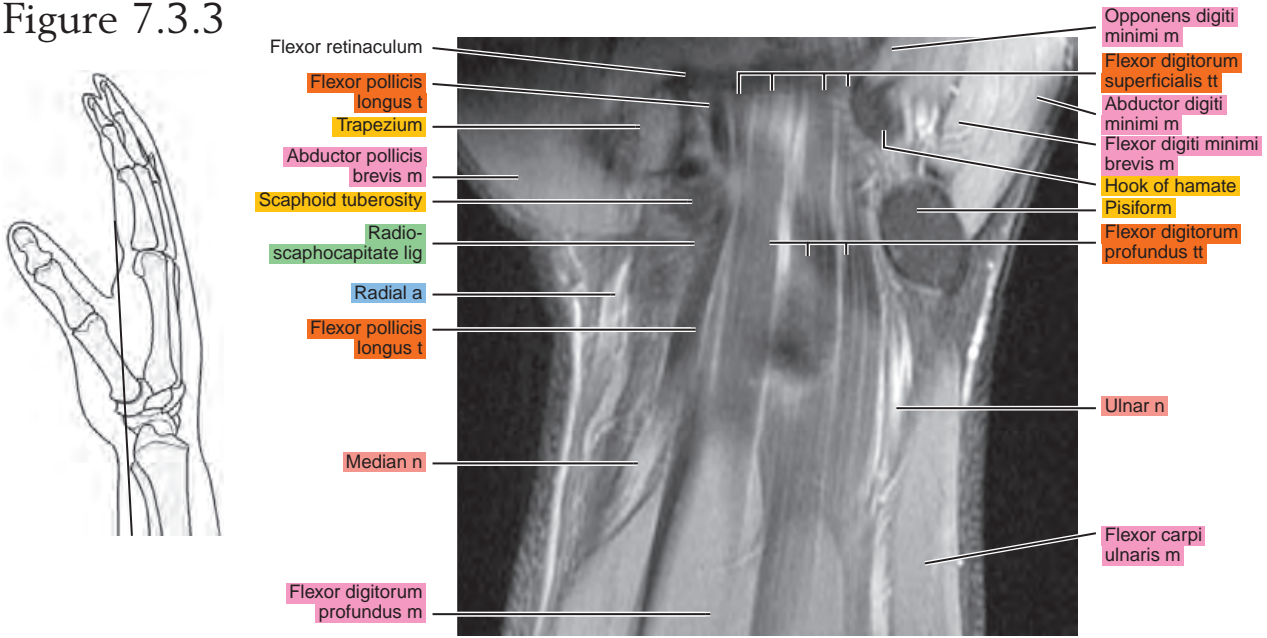


Figure 7.3.4

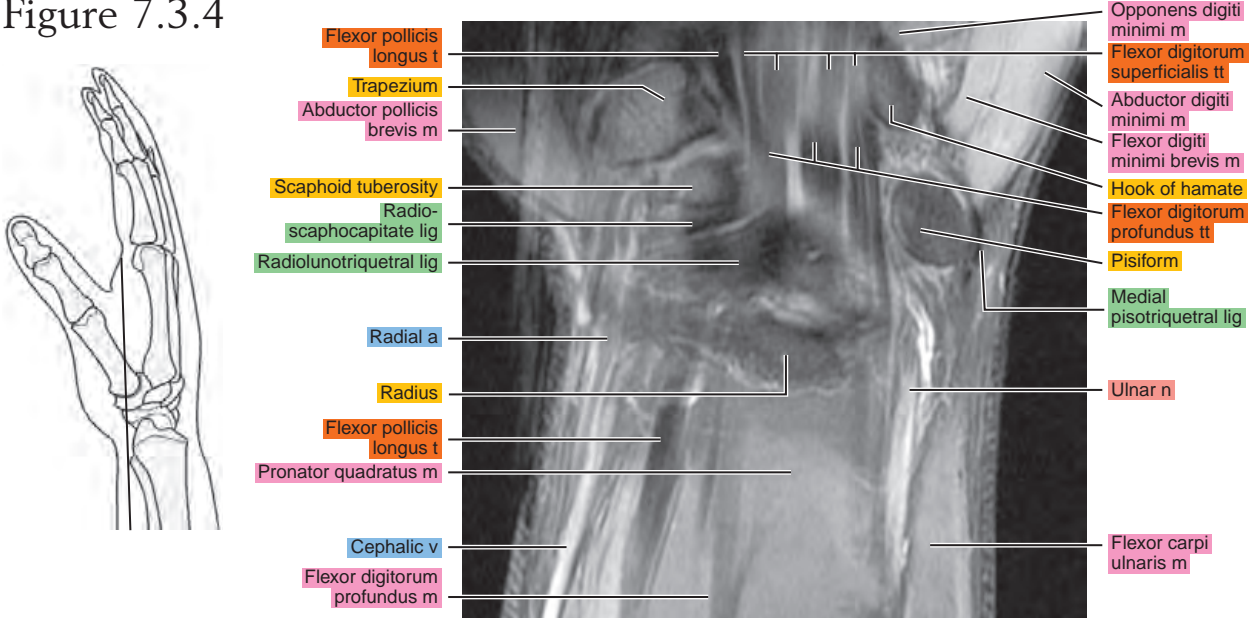


Figure 7.3.5

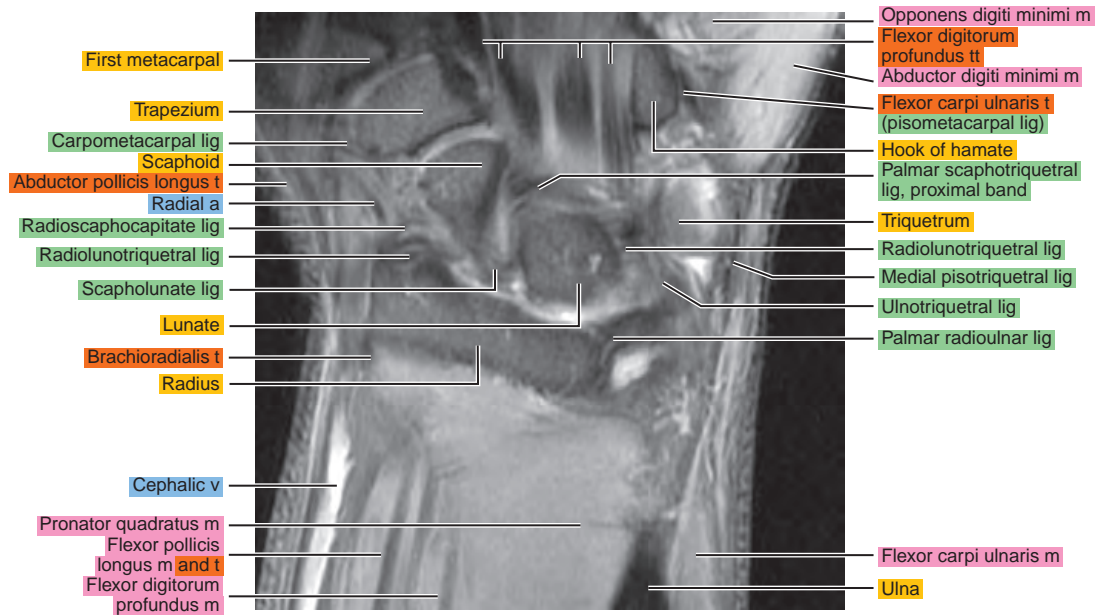
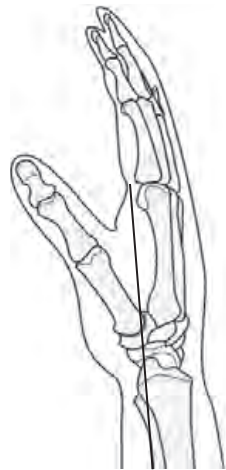

Figure 7.3.6

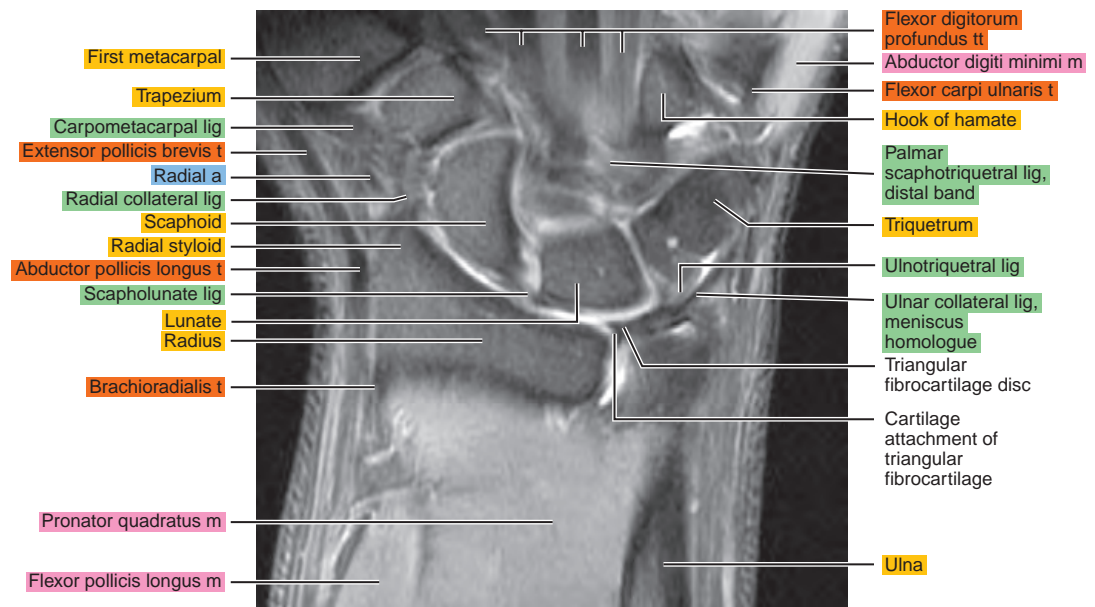
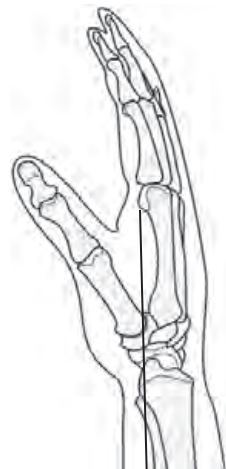

Figure 7.3.7

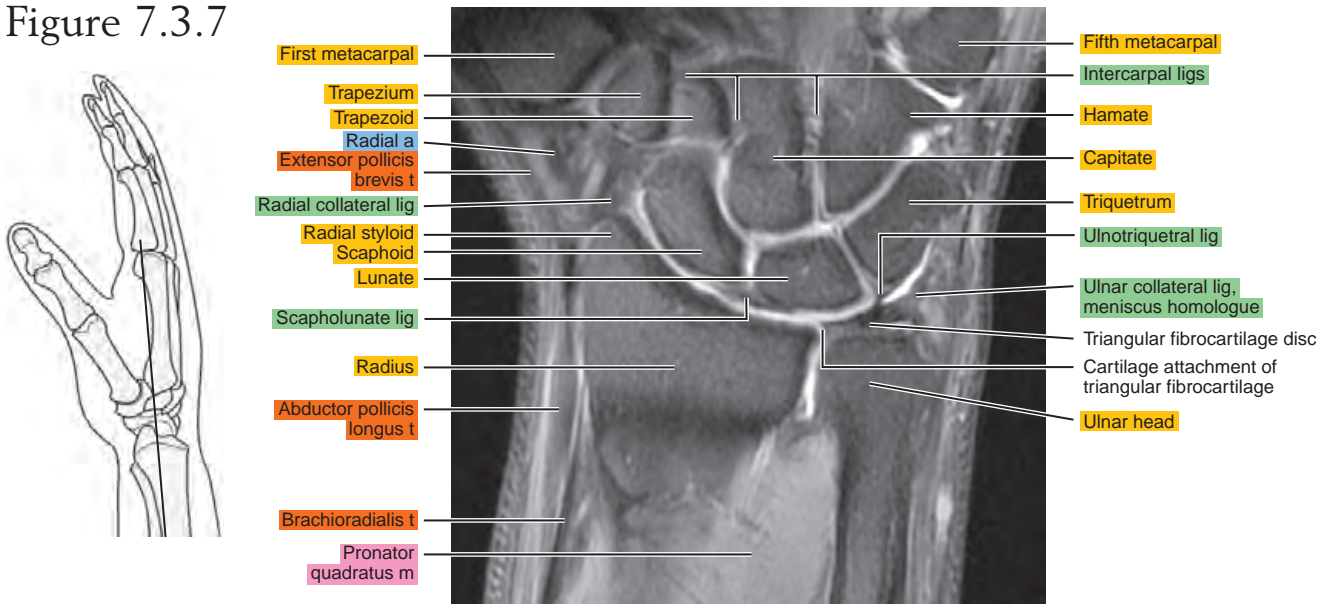


Figure 7.3.8

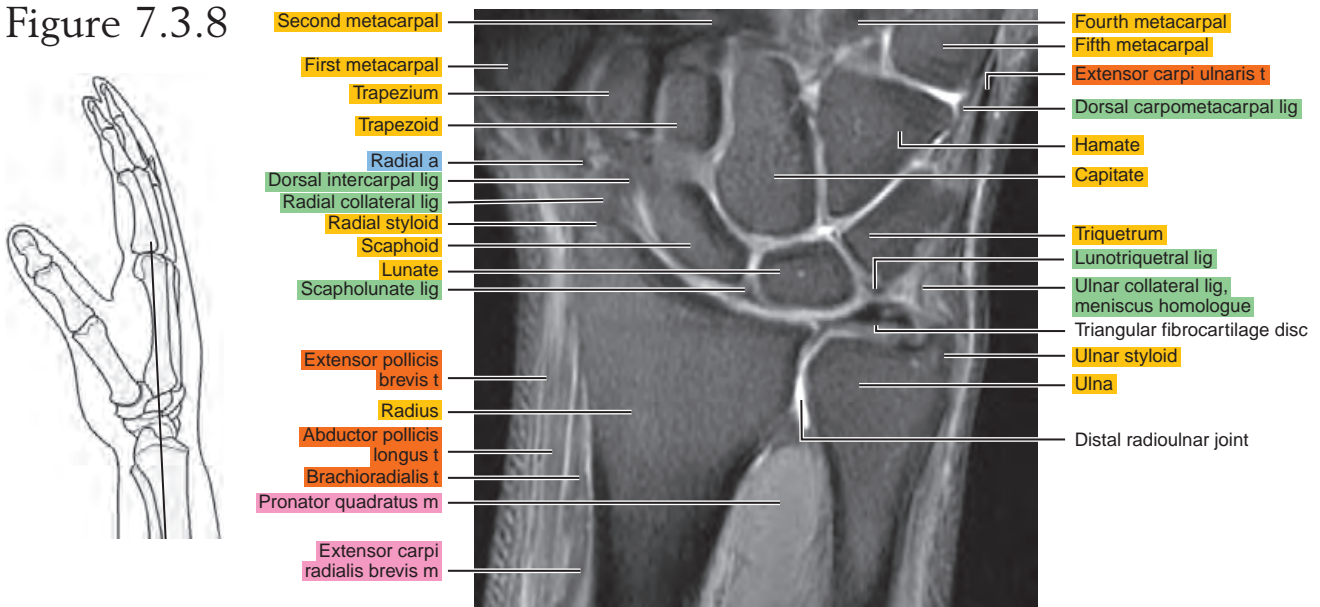


Figure 7.3.9

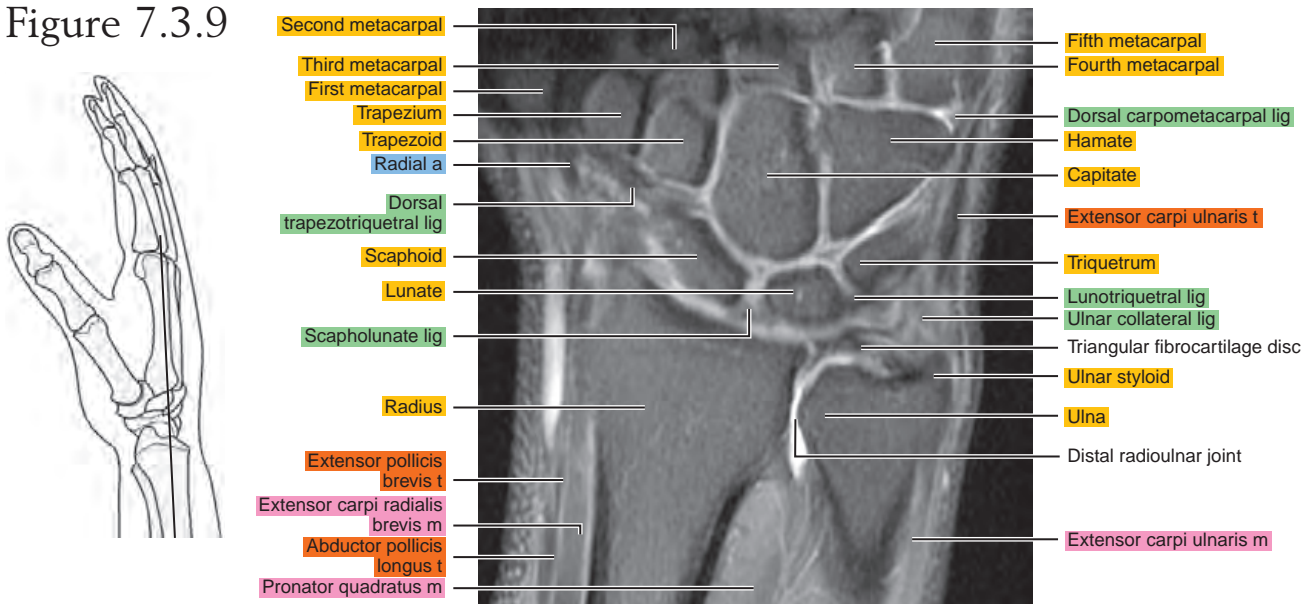


Figure 7.3.10

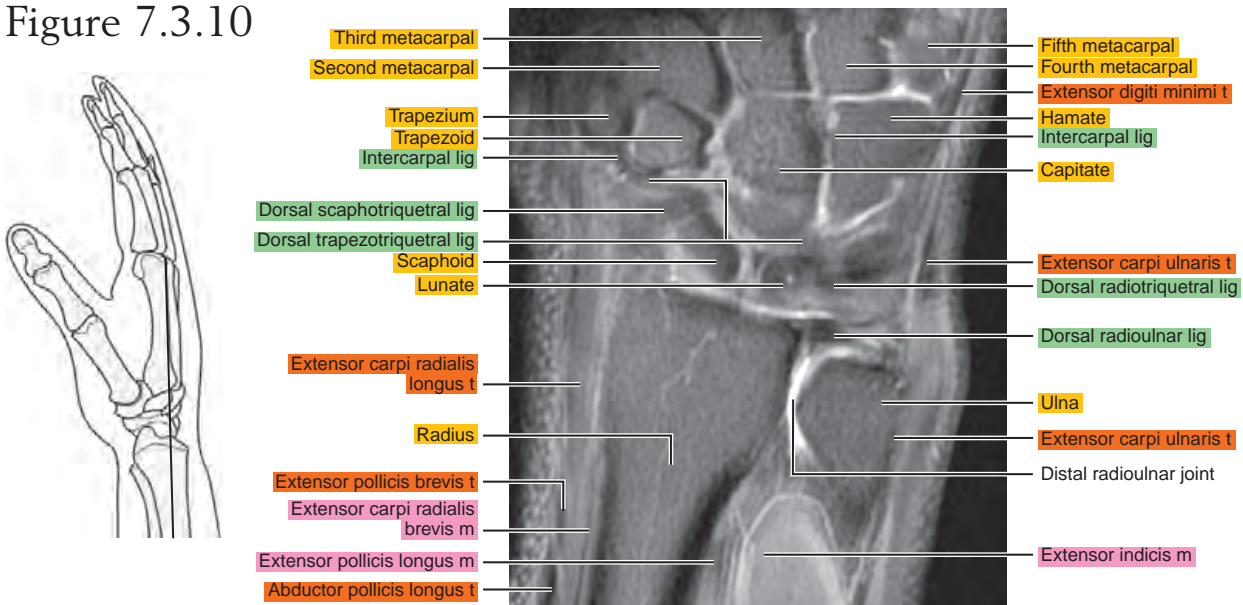


Figure 7.3.11

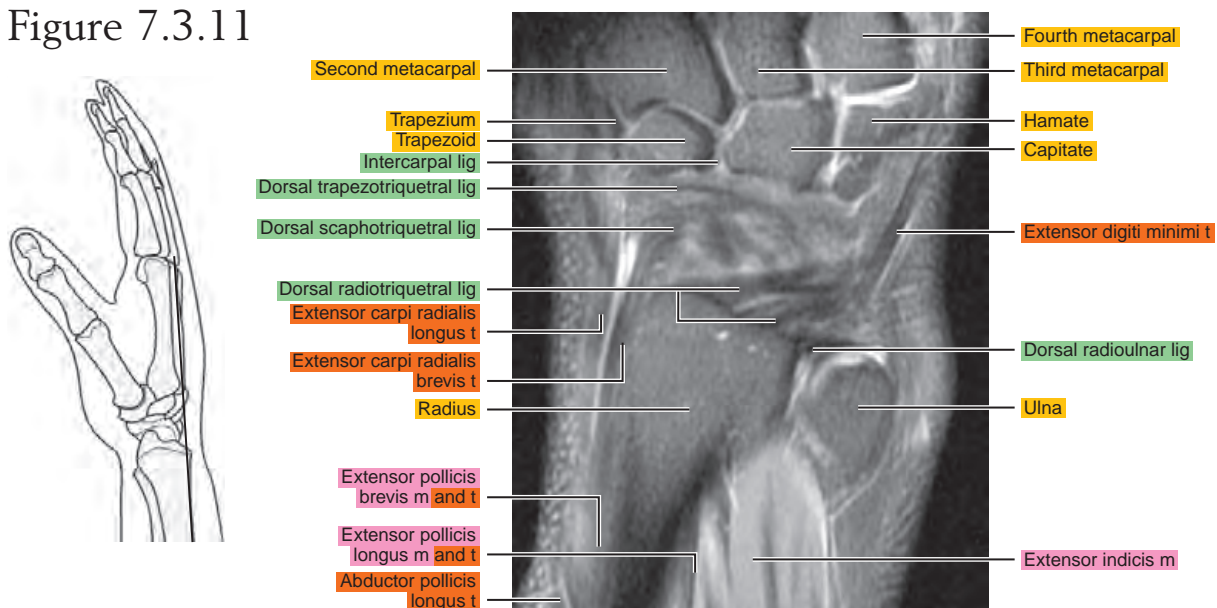


Figure 7.3.12

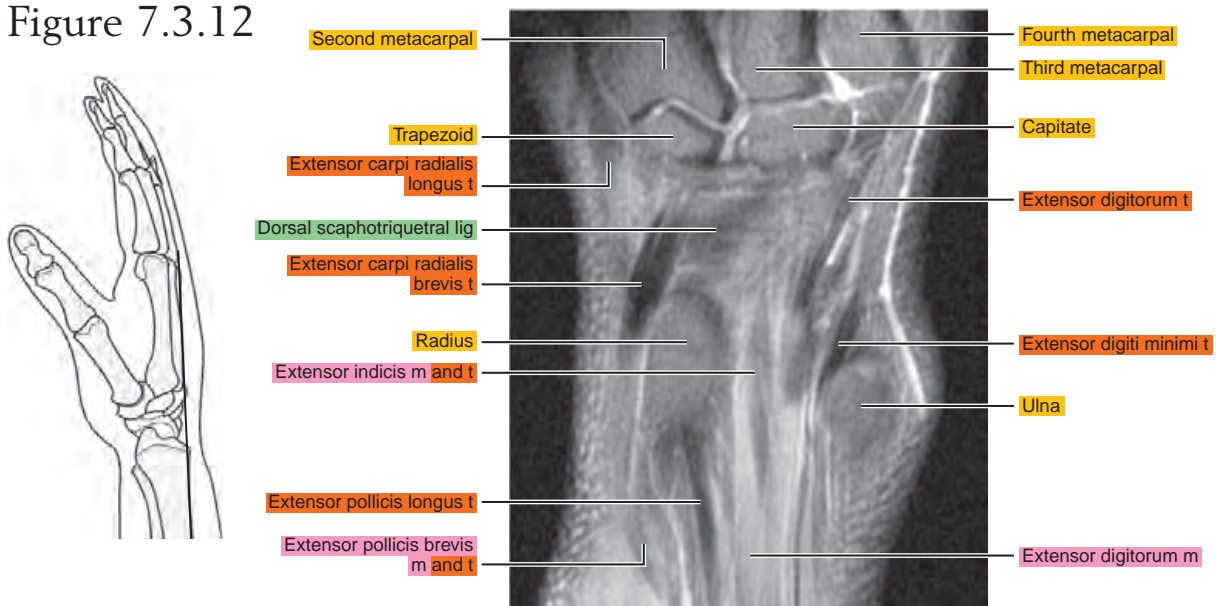
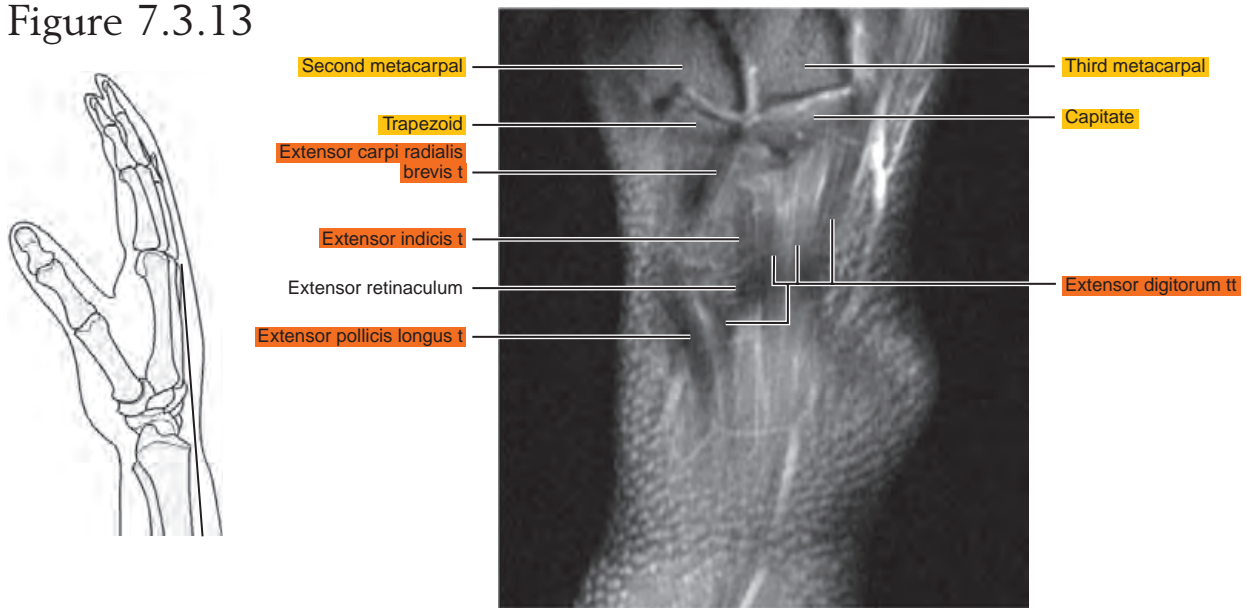


Figure 7.3.13



Chapter
8

MRI of the Hand

Table 8-1. Muscles of the Hand

MUSCLE	ORIGIN	INSERTION	NERVE SUPPLY
Palmaris brevis	Ulnar border of the palmar aponeurosis	Deep surface of the skin along the ulnar border of the palm	Superficial branch of ulnar (C8, T1)
Abductor pollicis brevis	Palmar surface of the flexor retinaculum, trapezium, and, occasionally, scaphoid	Radial side of the base of the proximal phalanx of the thumb	Recurrent branch of median (C8, T1)
Opponens pollicis	Palmar surface of the flexor retinaculum and tubercle of the trapezium	Lateral part of the palmar surface of the shaft of the first metacarpal	Recurrent branch of median (C8, T1)
Flexor pollicis brevis	Superficial head: trapezium, adjacent part of the flexor retinaculum, and tendon sheath of the flexor carpi radialis; deep head: trapezoid and capitate	Superficial head: lateral side of the palmar aspect of the base of the proximal phalanx; deep head: into a tendon of the superficial head	Recurrent branch of median and deep branch of ulnar (C8, T1)
Adductor pollicis brevis	Carpal head: flexor retinaculum, capitate, bases of the second and third metacarpals; metacarpal head: palmar ridges of the third metacarpal and capsules of the second, third, and fourth metacarpophalangeal articulations	Ulnar side of the palmar aspect of the base of the proximal phalanx of the thumb	Recurrent branch of median (C8, T1)
Abductor digiti minimi	Distal half of the pisiform, pisiformate ligament, tendon of the flexor carpi ulnaris, and, frequently, the flexor retinaculum	Two tendons: (1) the ulnar side of the base of the proximal phalanx of the little finger, and (2) the aponeurosis of the extensor tendon of the little finger	Deep palmar division of ulnar (C8, T1)
Flexor digiti minimi brevis	Hook of the hamate and adjacent parts of the flexor retinaculum	Ulnar side of the base of the proximal phalanx of the little finger	Superficial or deep palmar branch of ulnar (C8, T1)
Opponens digiti minimi	Distal border of the hook of the hamate and adjacent flexor retinaculum	Medial surface of the body and particularly onto the head of the fifth metacarpal	Deep palmar branch of ulnar (C8, T1)
Lumbrical	Two lateral lumbricals: radial and palmar sides of the first and second tendons of the flexor digitorum profundus; two medial lumbricals: adjacent side of the second and third tendons, and the third and fourth tendons of the flexor digitorum profundus	Into the radial border of the tendon of the extensor digitorum on the dorsal aspect of the proximal phalanx	Median, lateral two or three lumbricals; ulnar, deep palmar branch, medial one or two lumbricals (C8, T1)
Interosseous	Palmar interosseous: anterior border of the shaft of the first, second, fourth, and fifth metacarpals. The first arises near the base and the others arise from three fourths of the shaft of the bone. Dorsal interosseous: adjacent sides of the metacarpal bones in each metacarpal interspace	Into the expansion on the axial side of the corresponding digit. The first palmar interosseous is described frequently as a division of the flexor brevis or adductor pollicis. The first dorsal interosseous usually inserts onto the proximal phalanx. The other three insert into the extensor expansion and proximal phalanx	Deep palmar branch of ulnar (C8, T1)

AXIAL

Figure 8.1.1

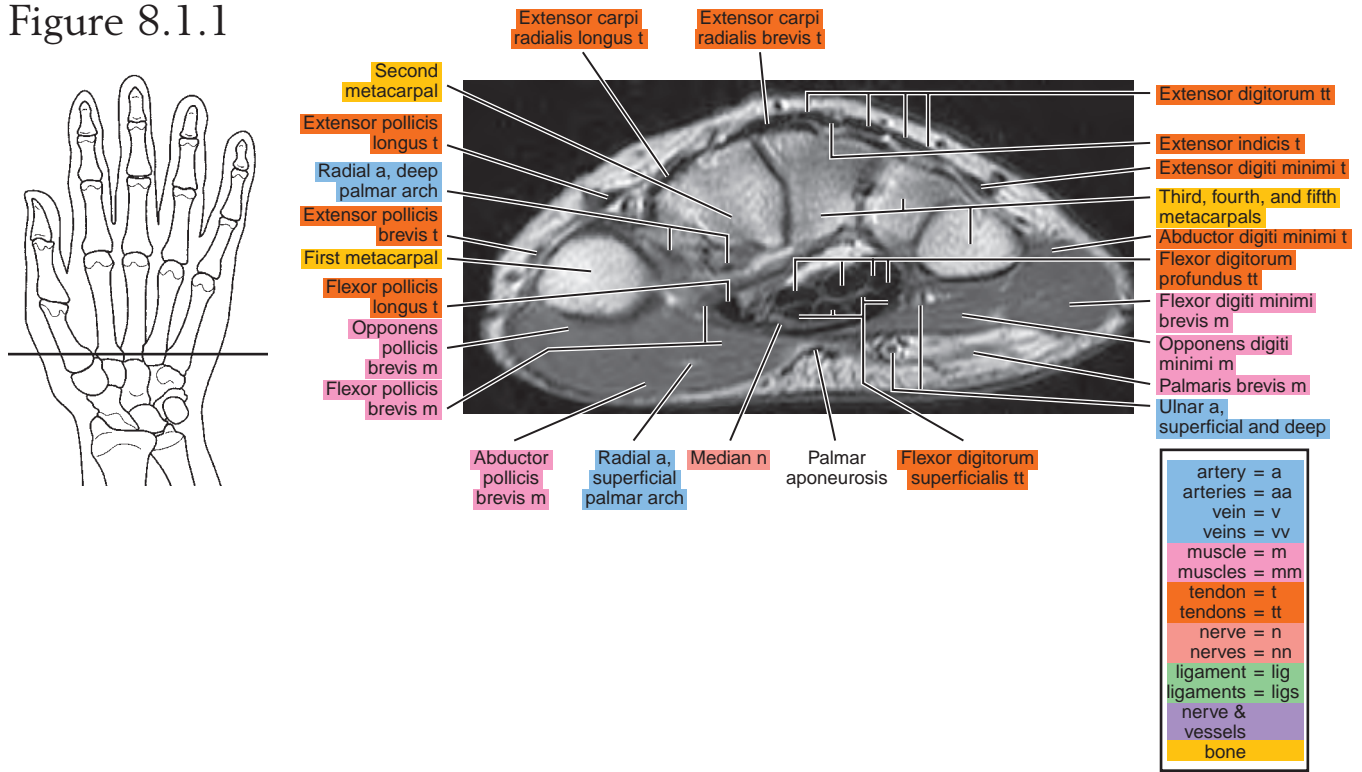


Figure 8.1.2

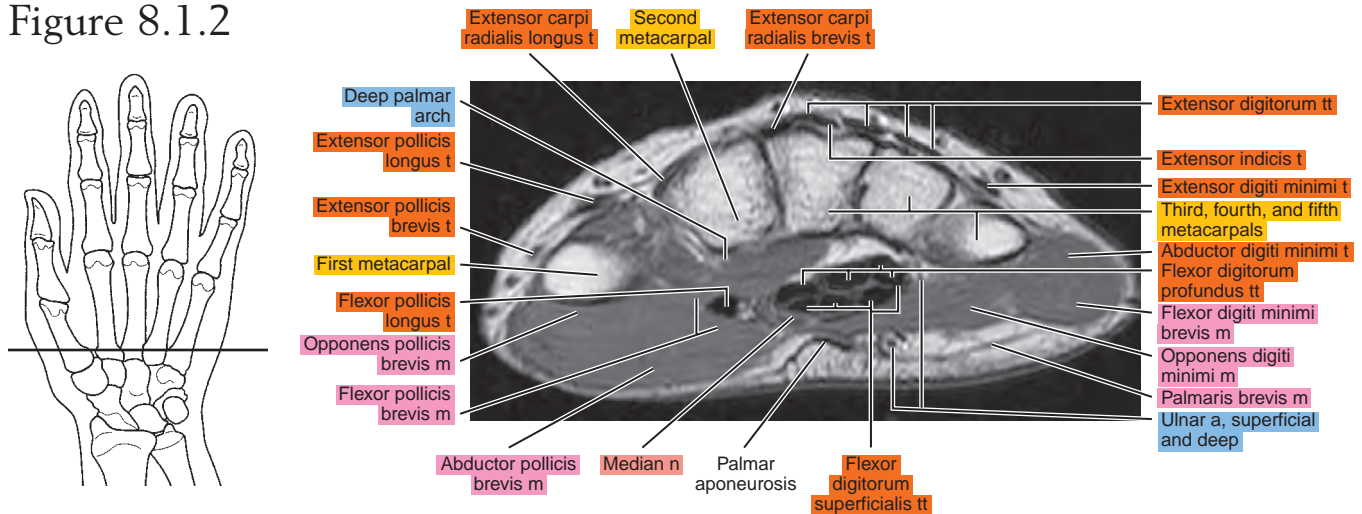


Figure 8.1.3

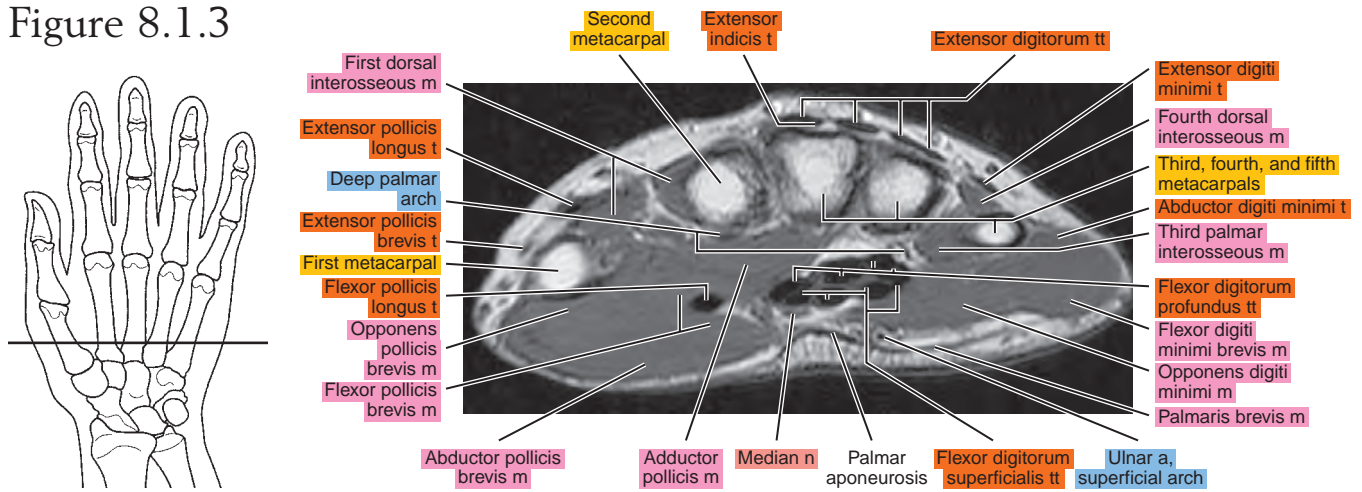


Figure 8.1.4

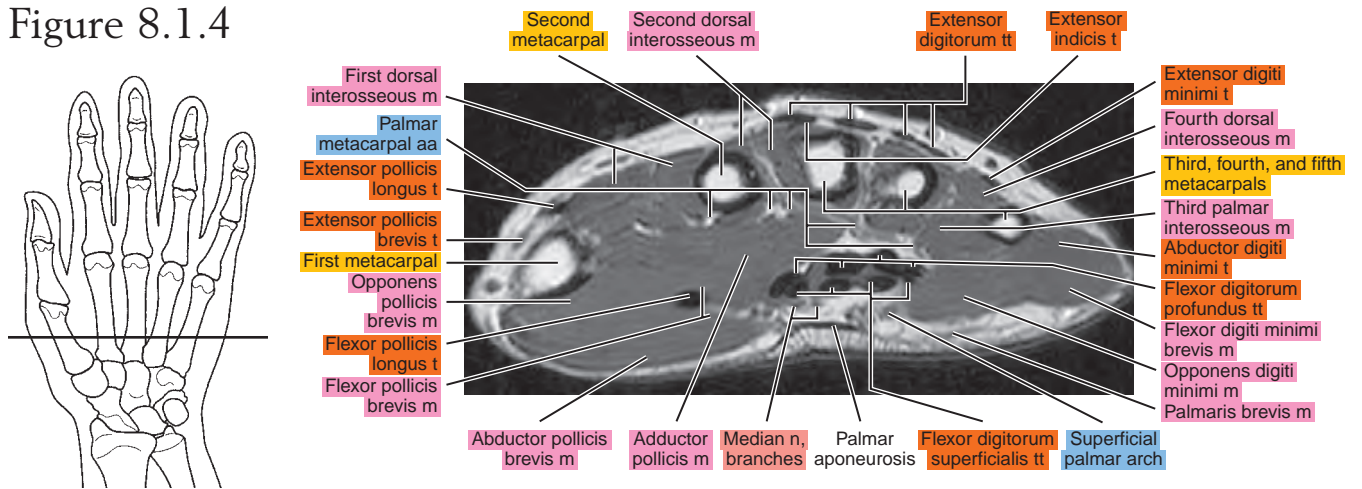


Figure 8.1.5

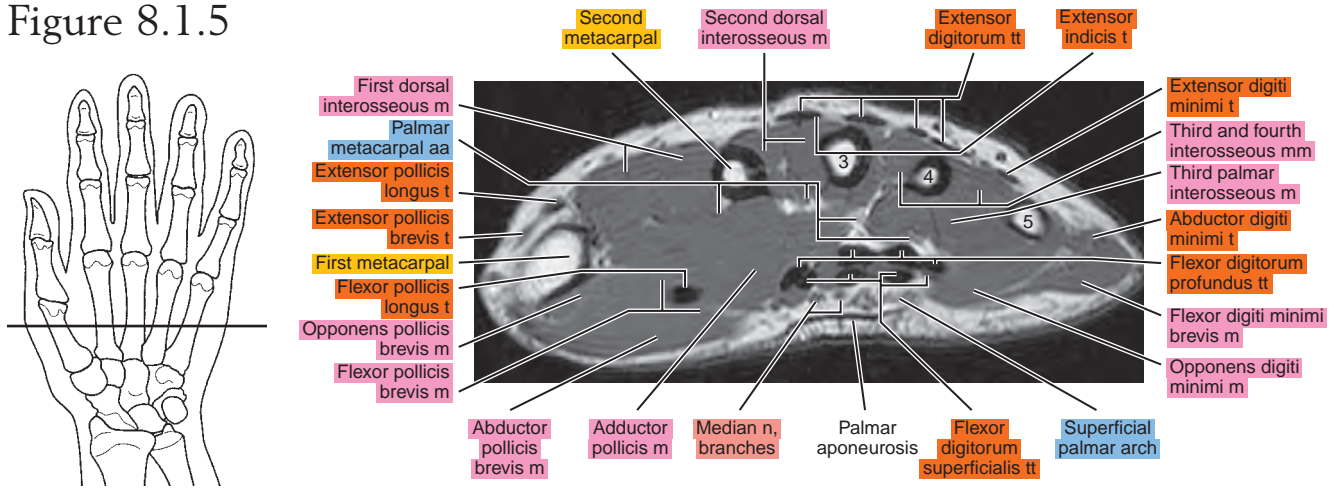


Figure 8.1.6

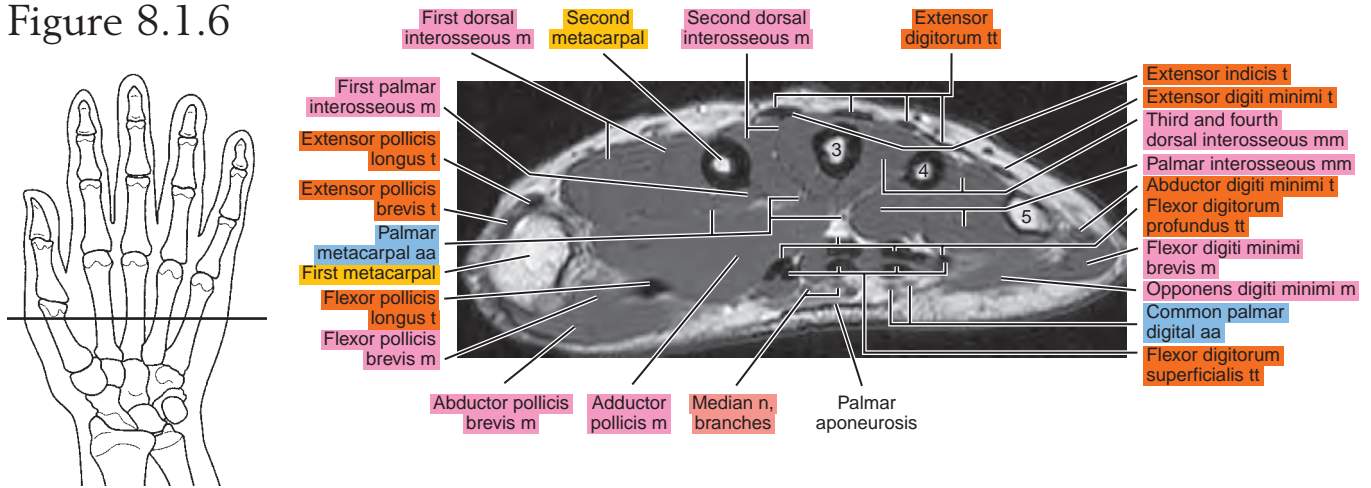


Figure 8.1.7

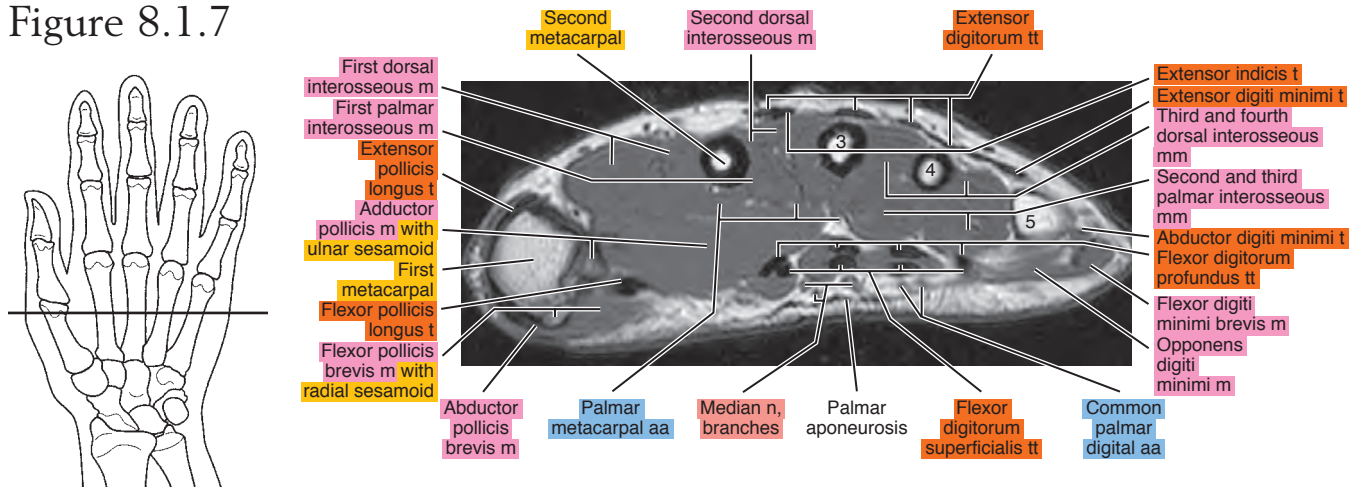


Figure 8.1.8

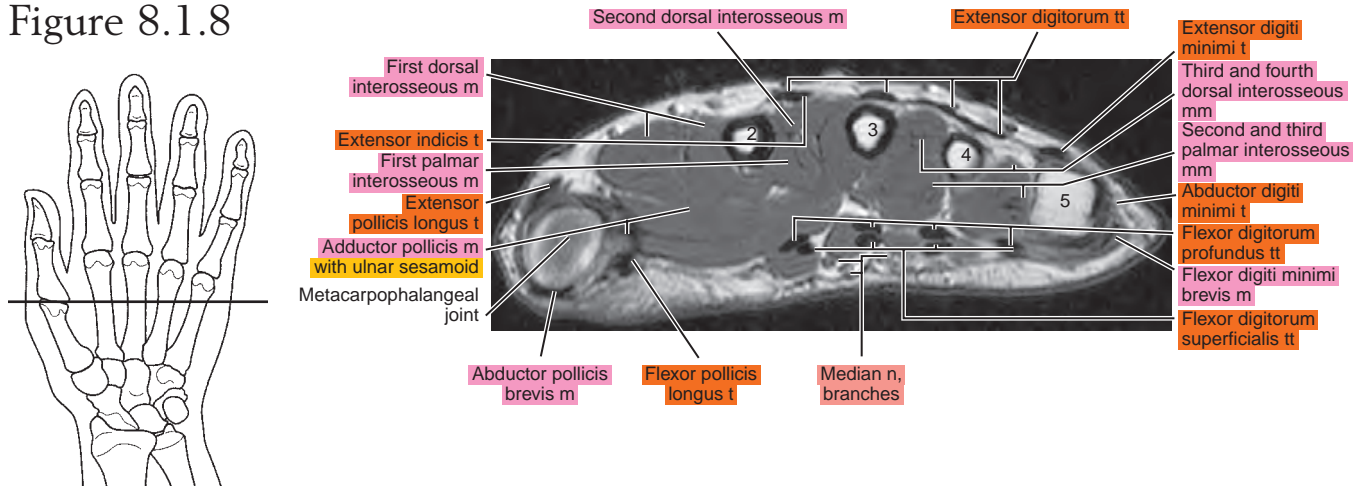


Figure 8.1.9

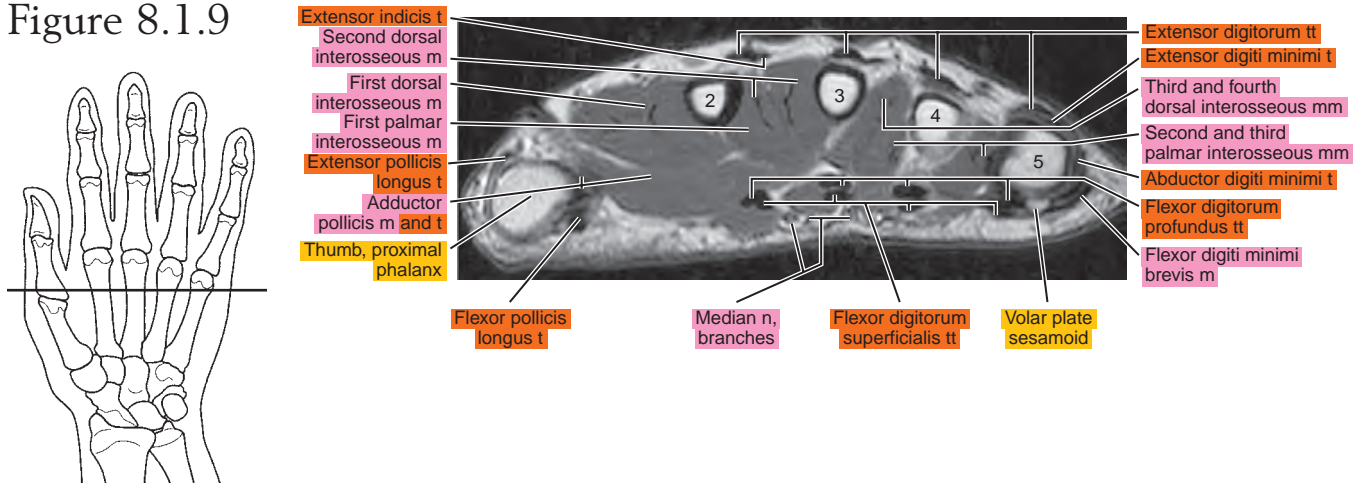


Figure 8.1.10

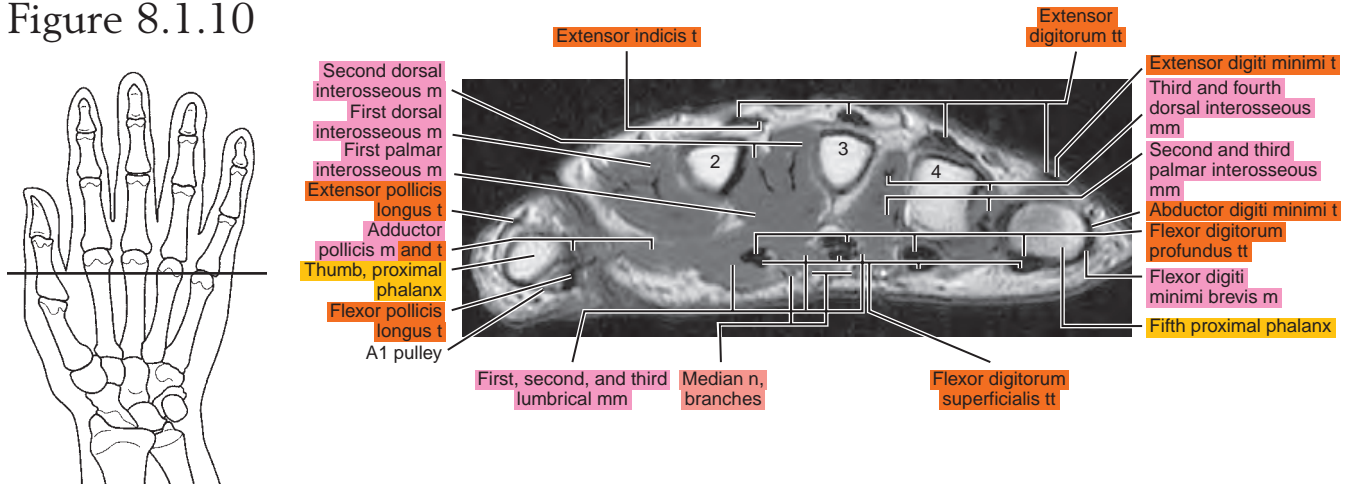


Figure 8.1.11

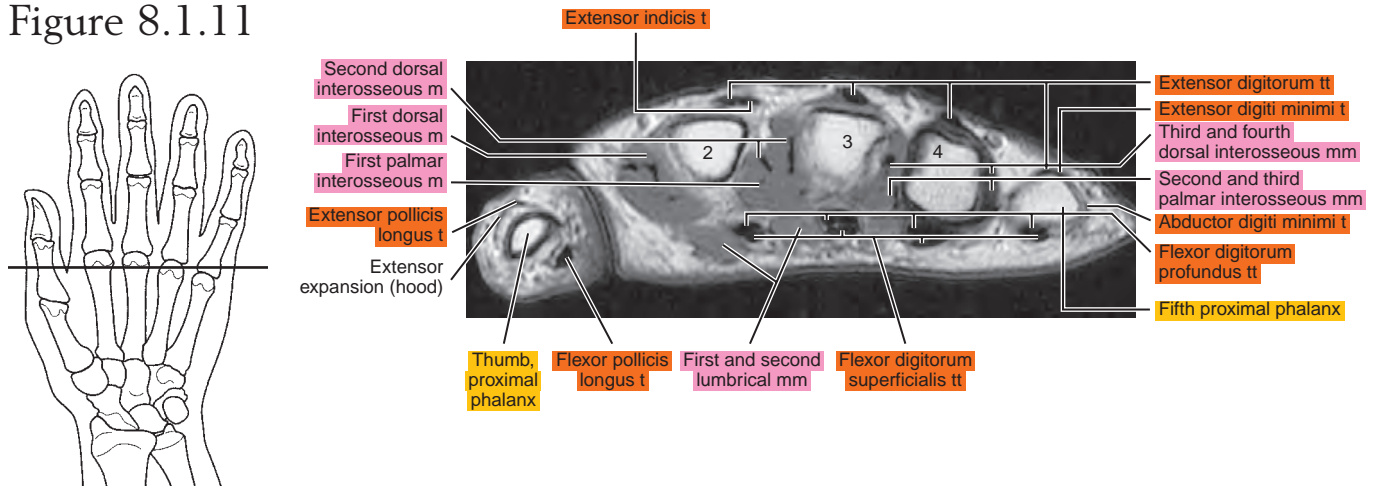


Figure 8.1.12

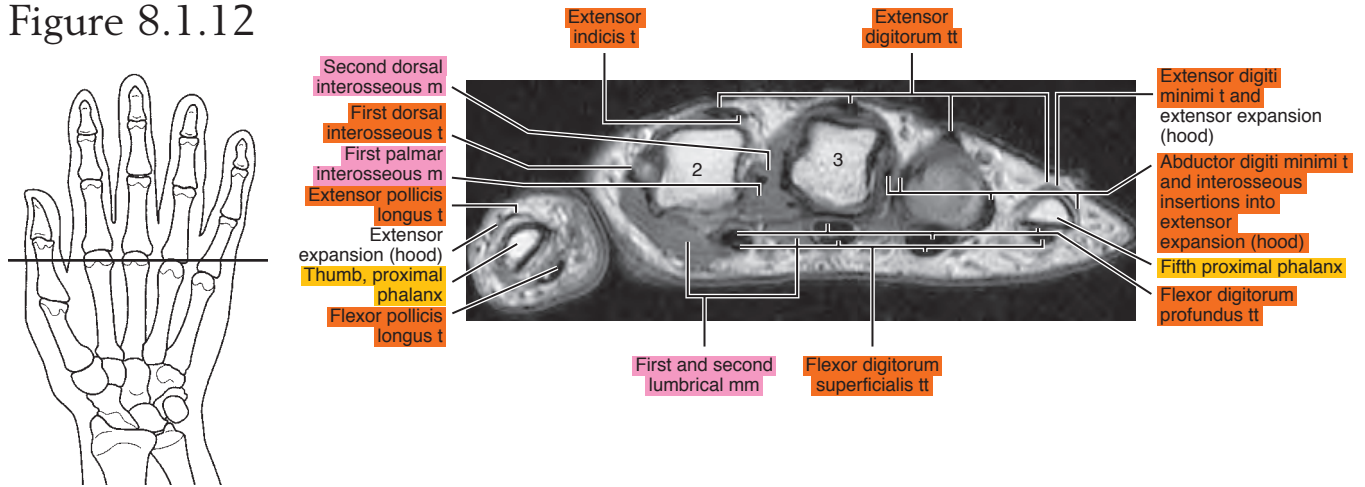


Figure 8.1.13

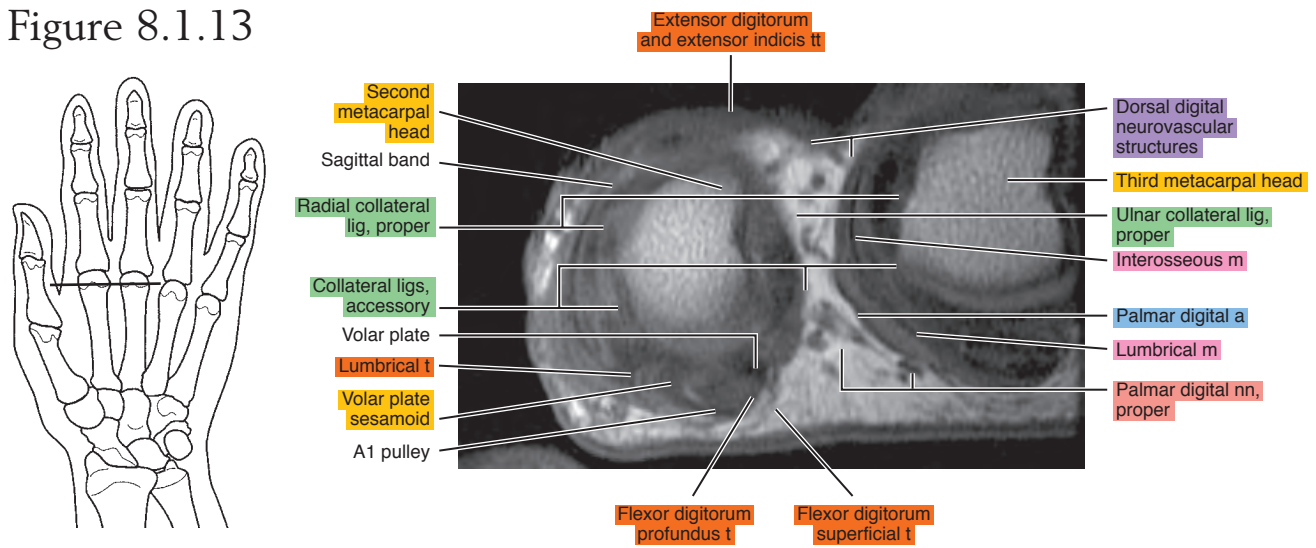
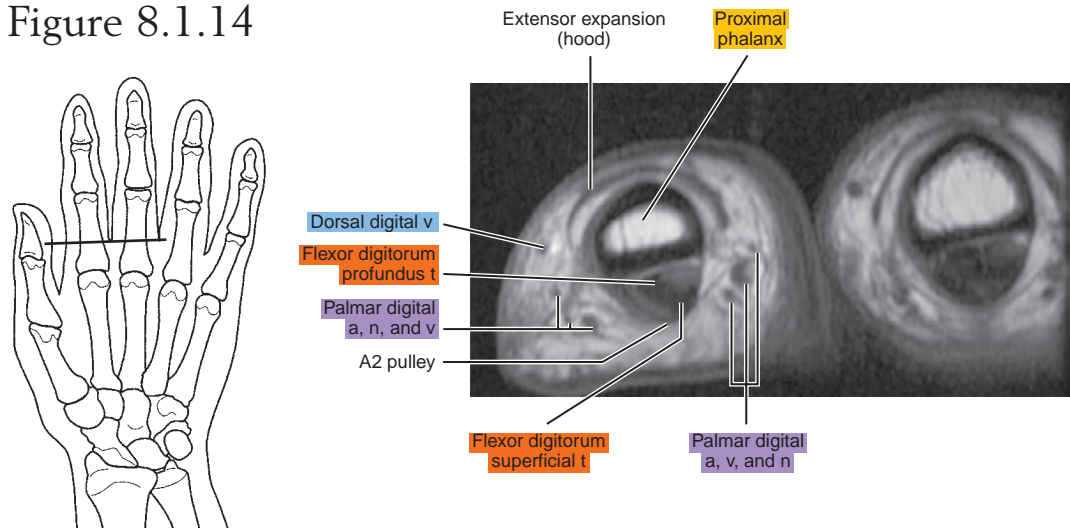


Figure 8.1.14



SAGITTAL

Figure 8.2.1

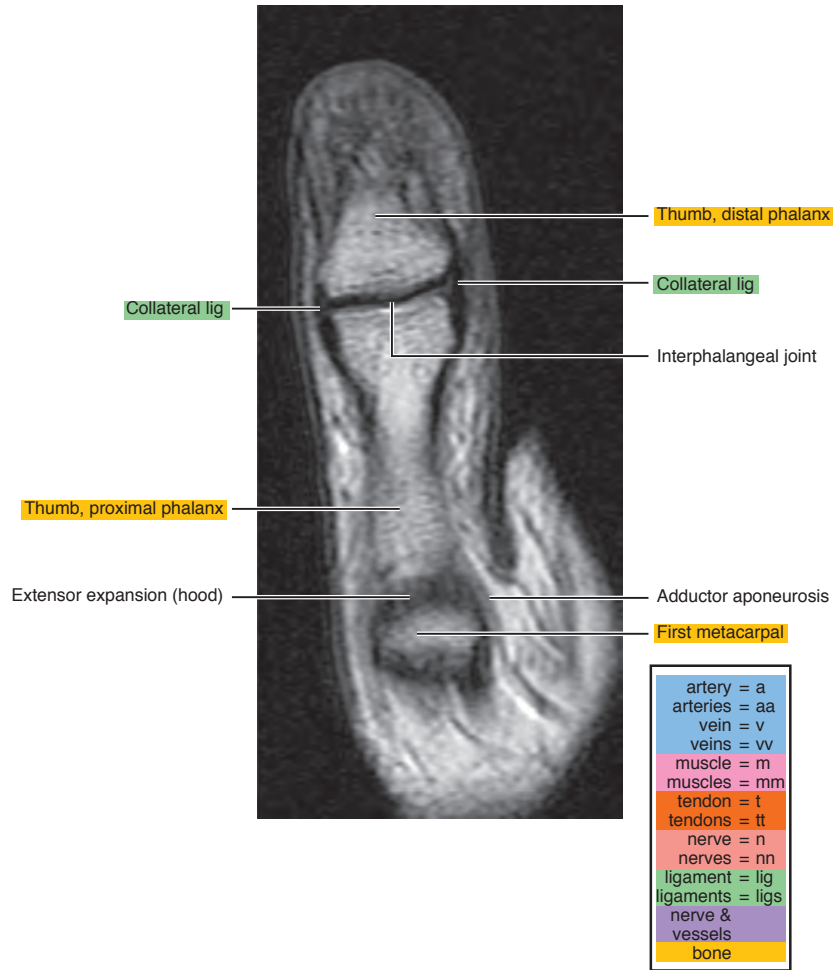
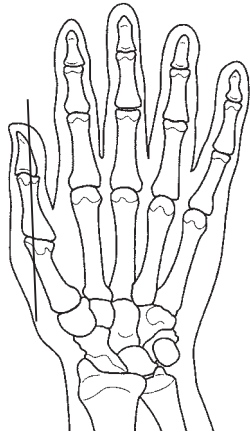


Figure 8.2.2

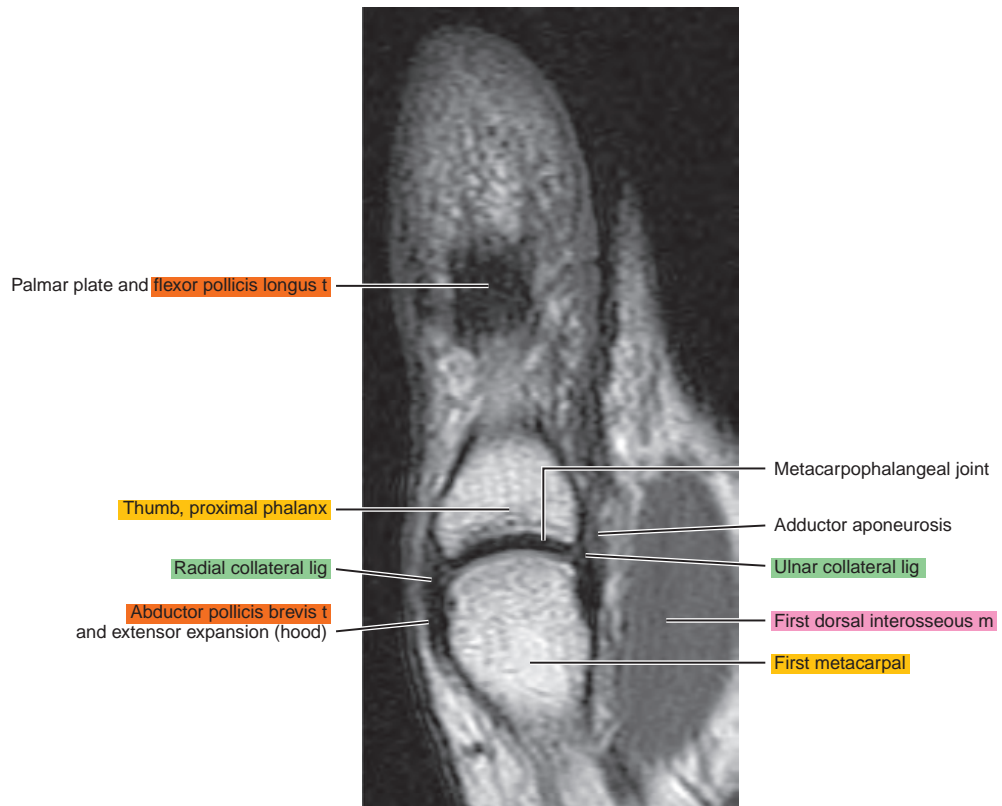
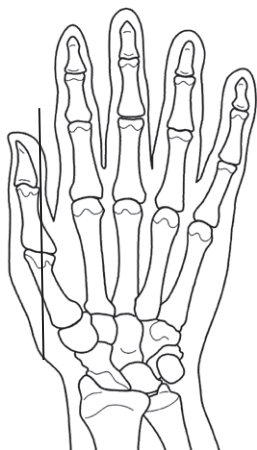


Figure 8.2.3

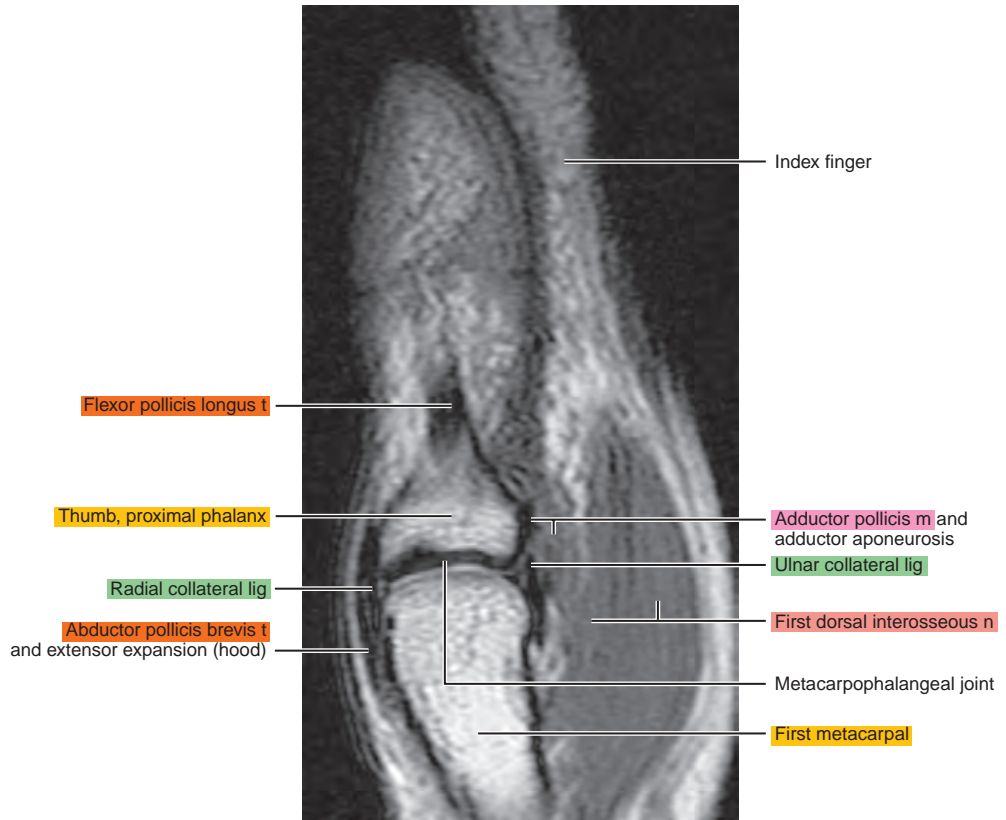
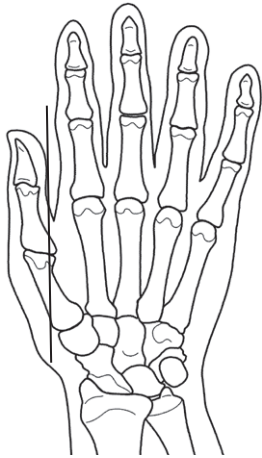


Figure 8.2.4

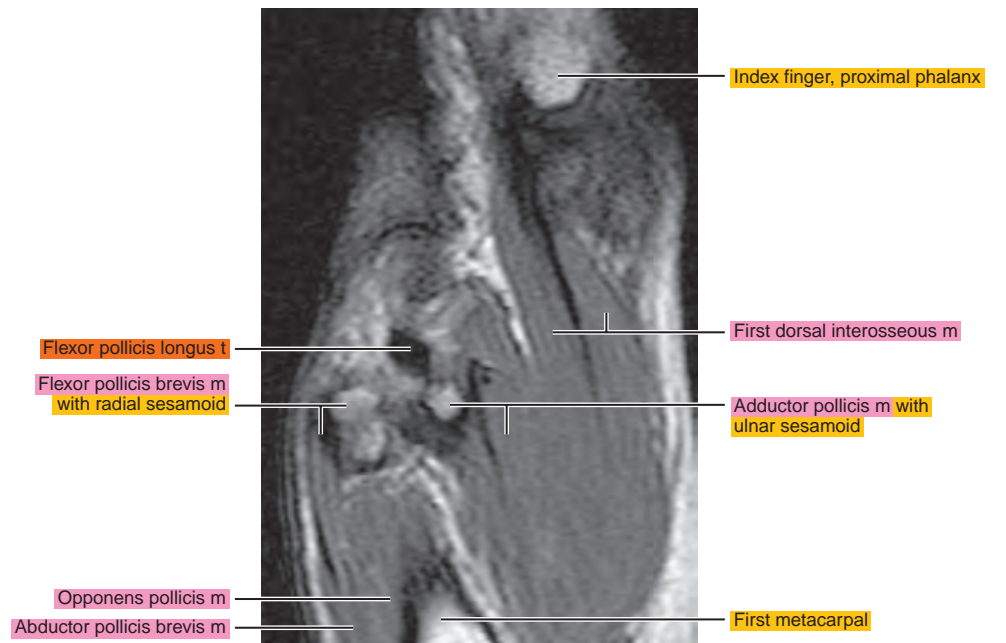
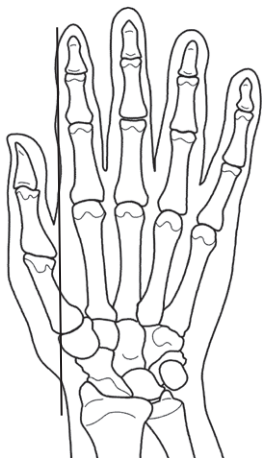


Figure 8.2.5

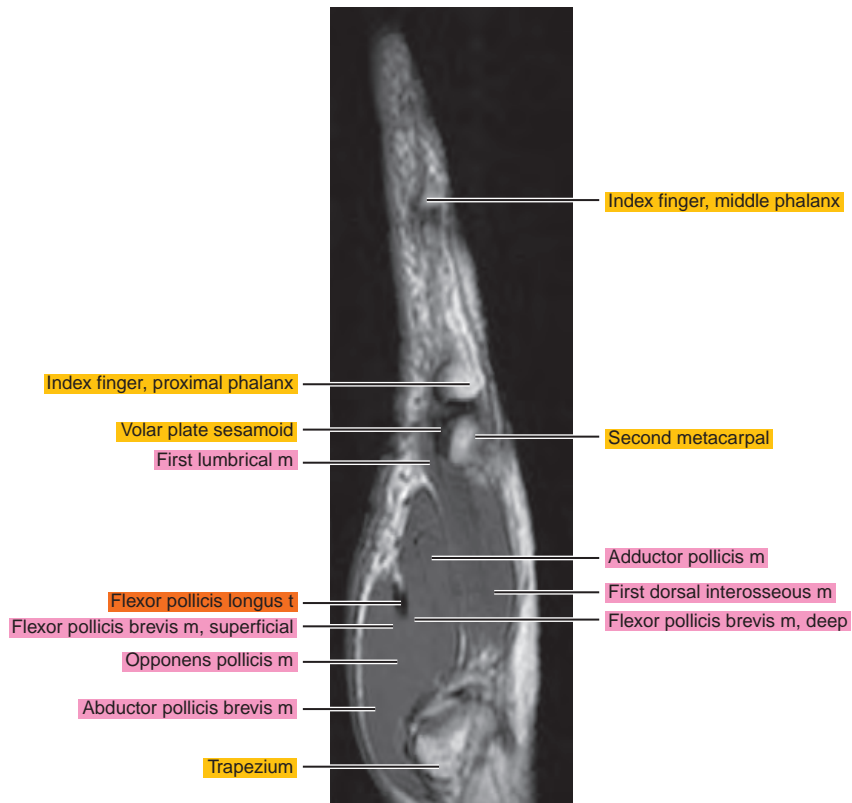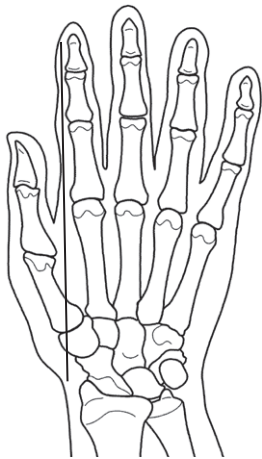


Figure 8.2.6

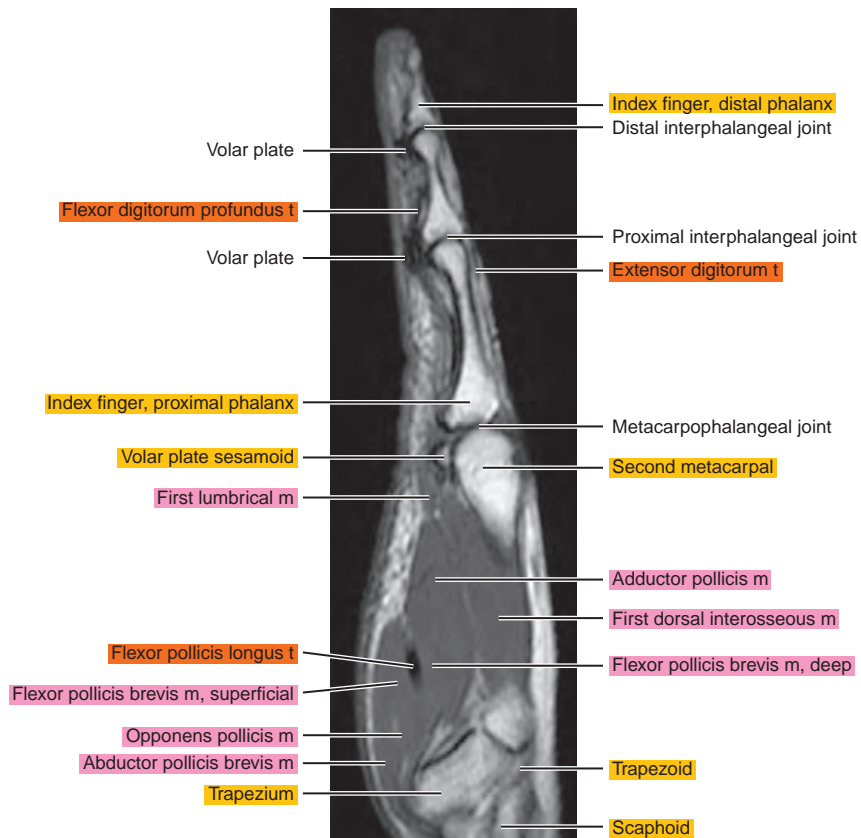
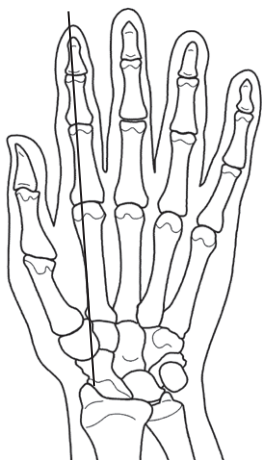


Figure 8.2.7

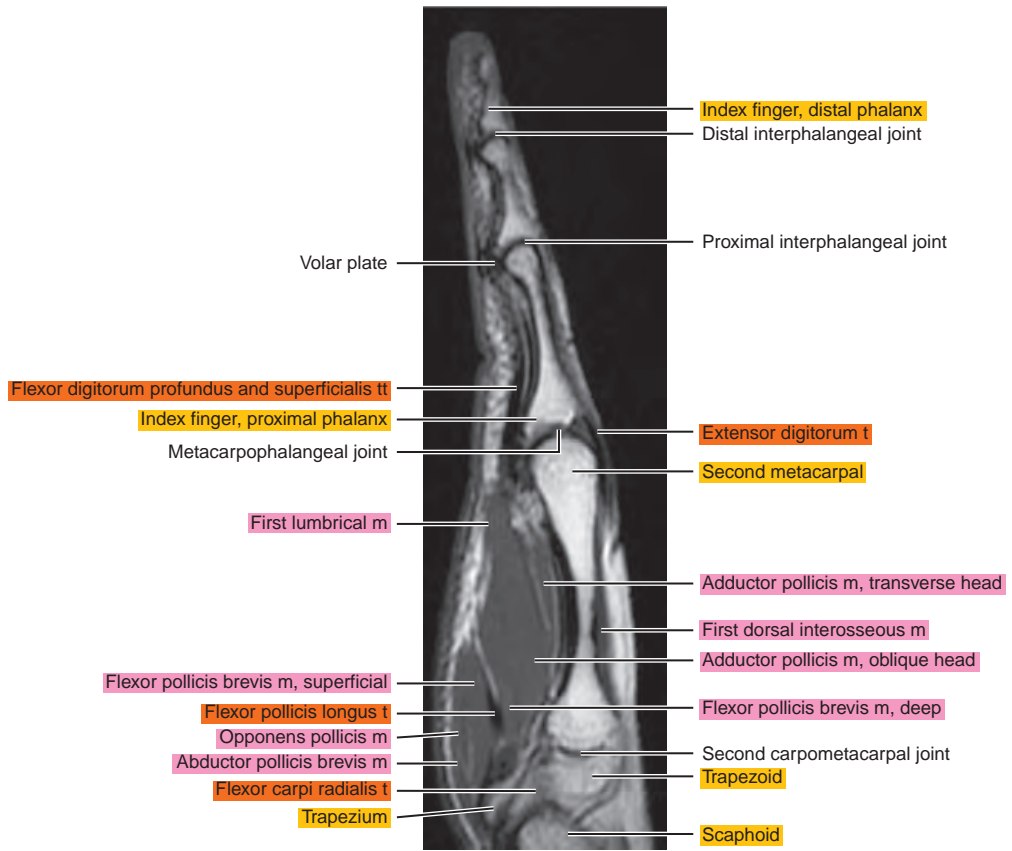
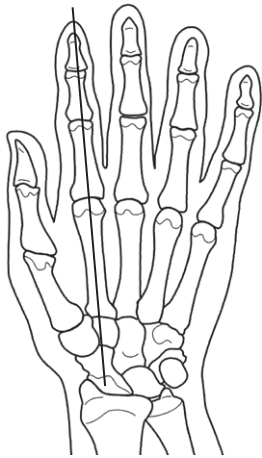


Figure 8.2.8

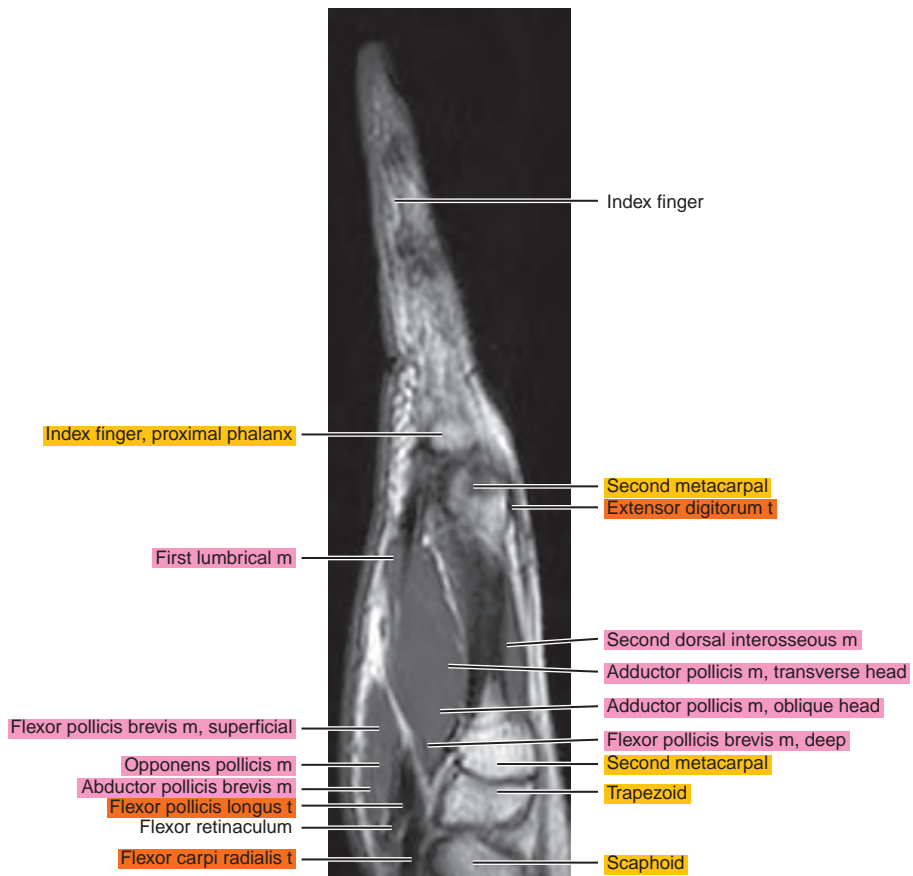
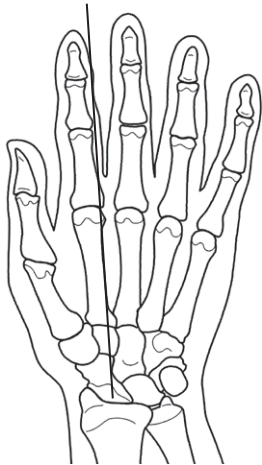


Figure 8.2.9

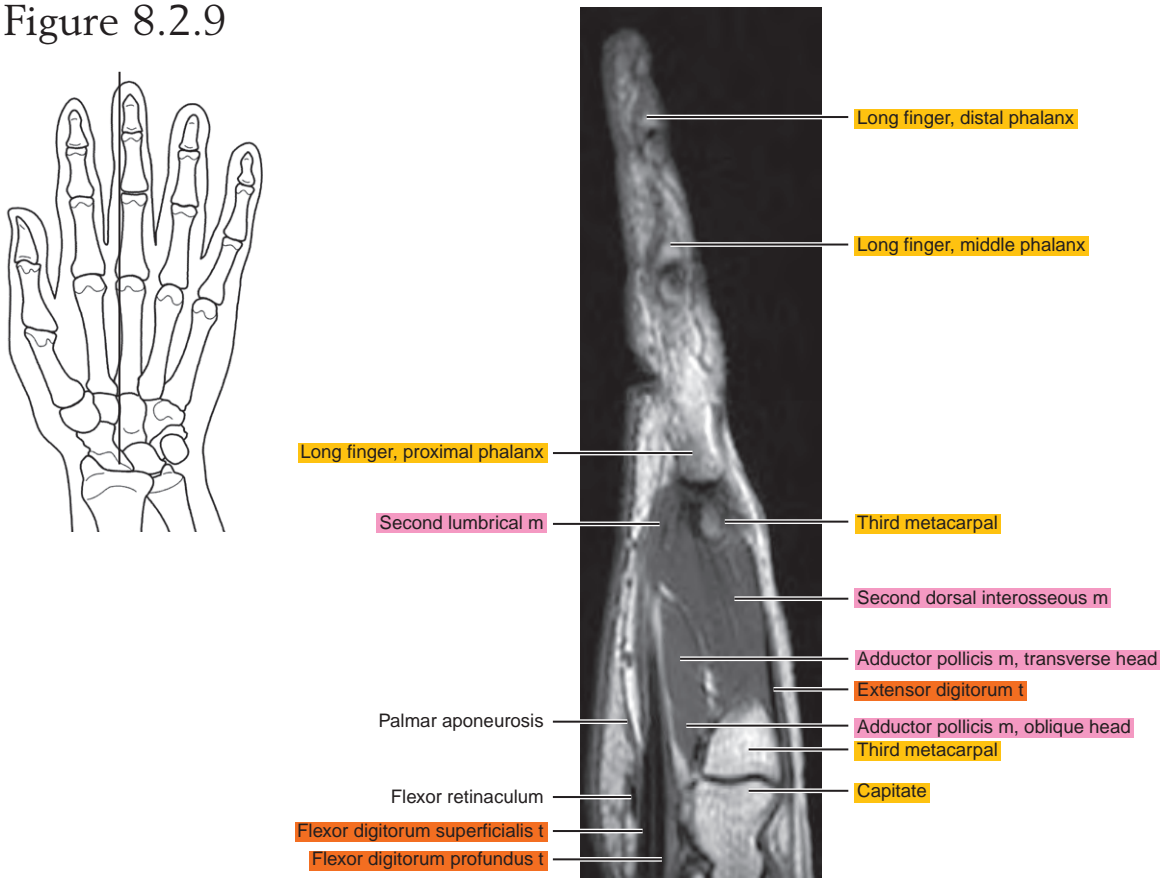


Figure 8.2.10

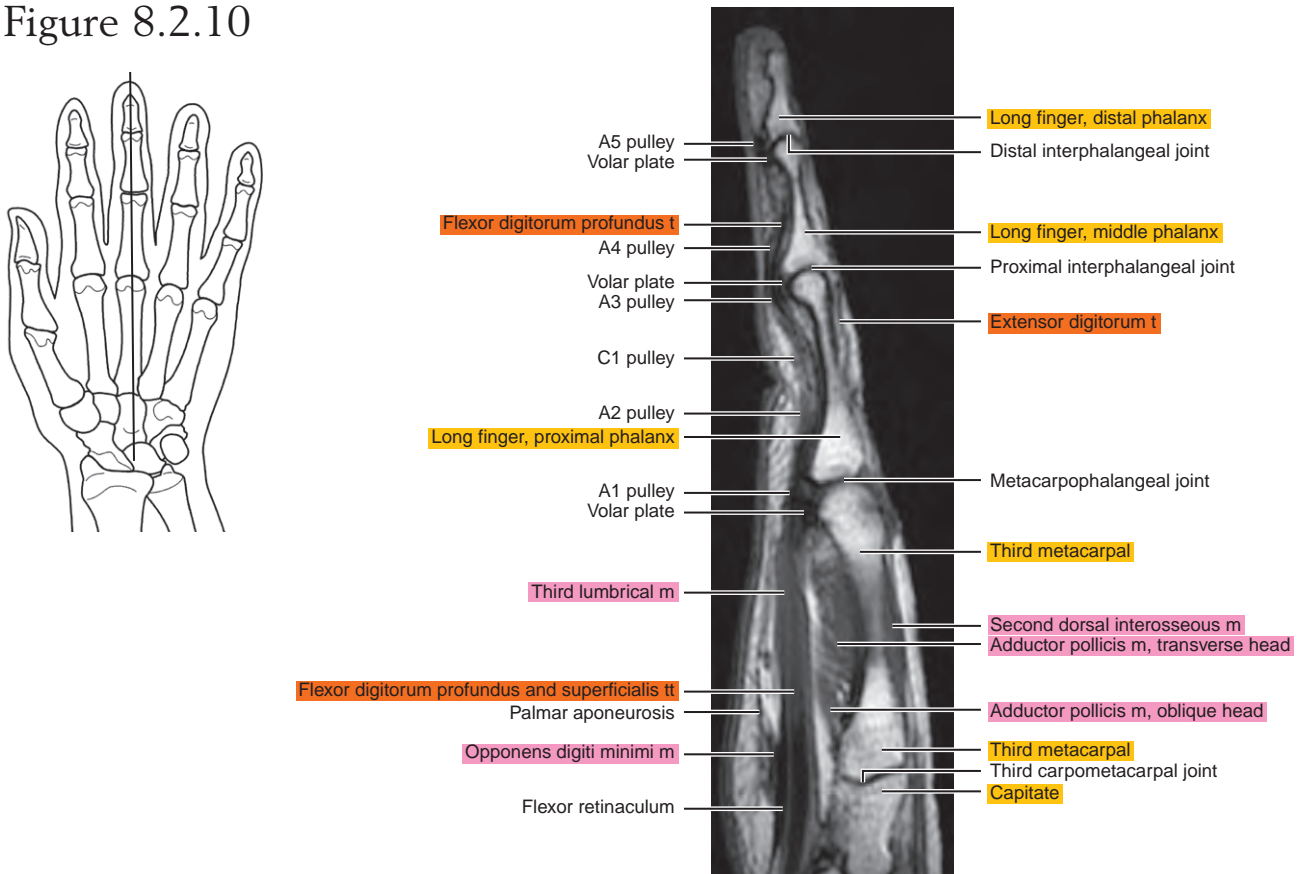


Figure 8.2.11

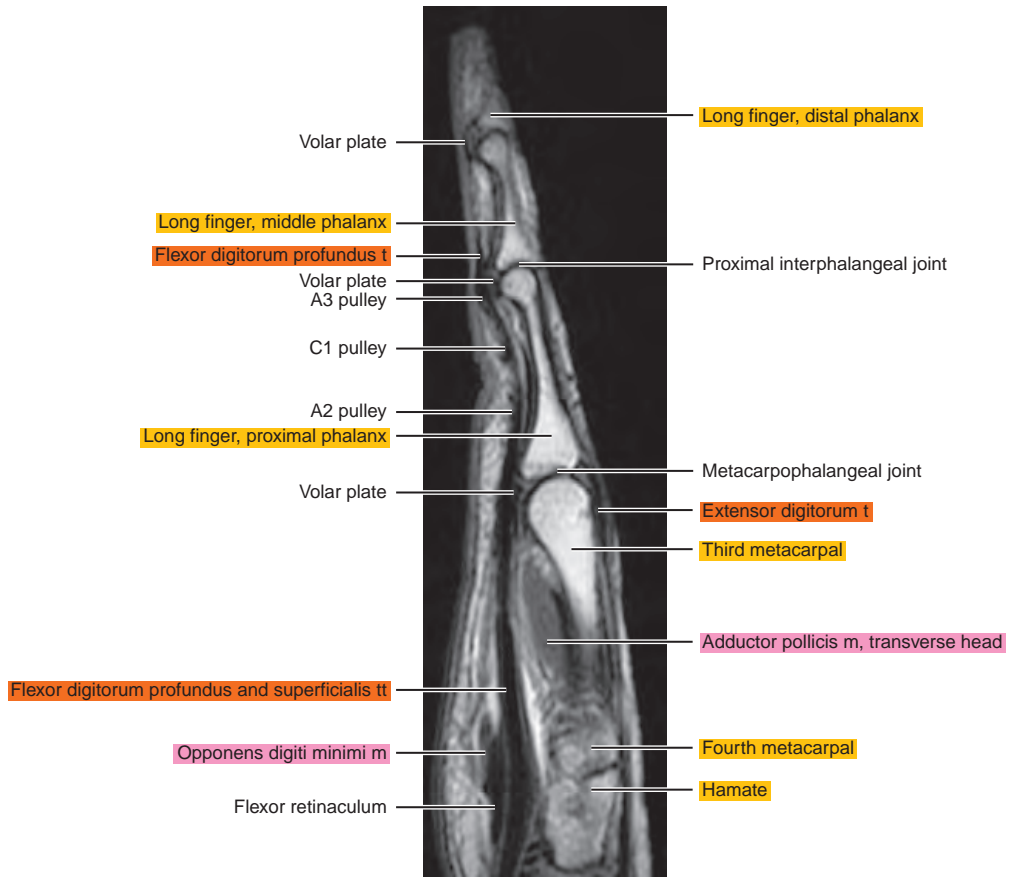
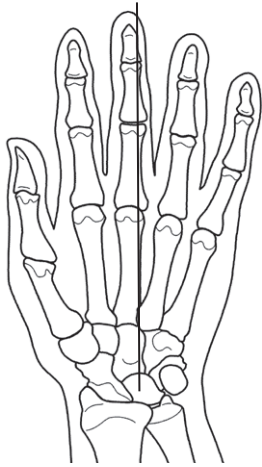


Figure 8.2.12

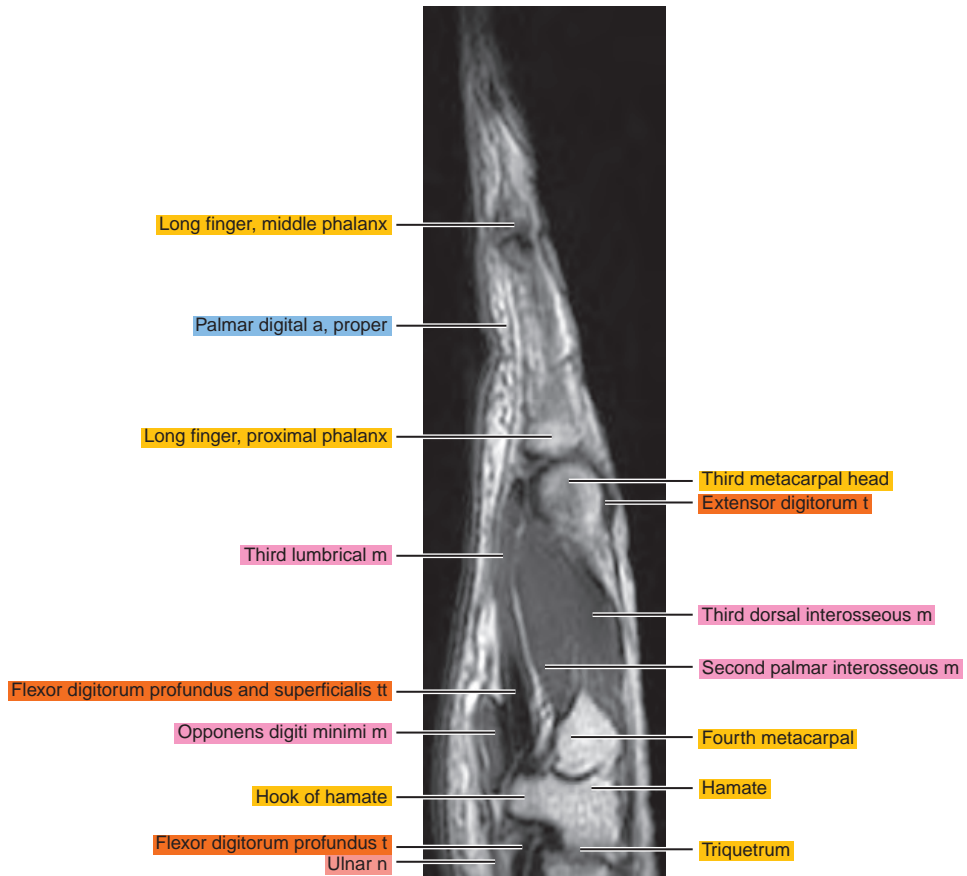
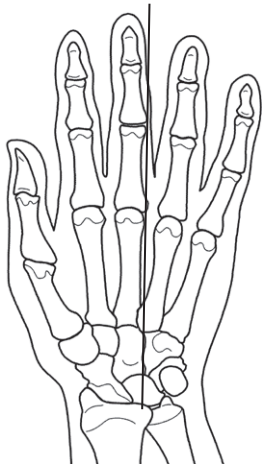


Figure 8.2.13

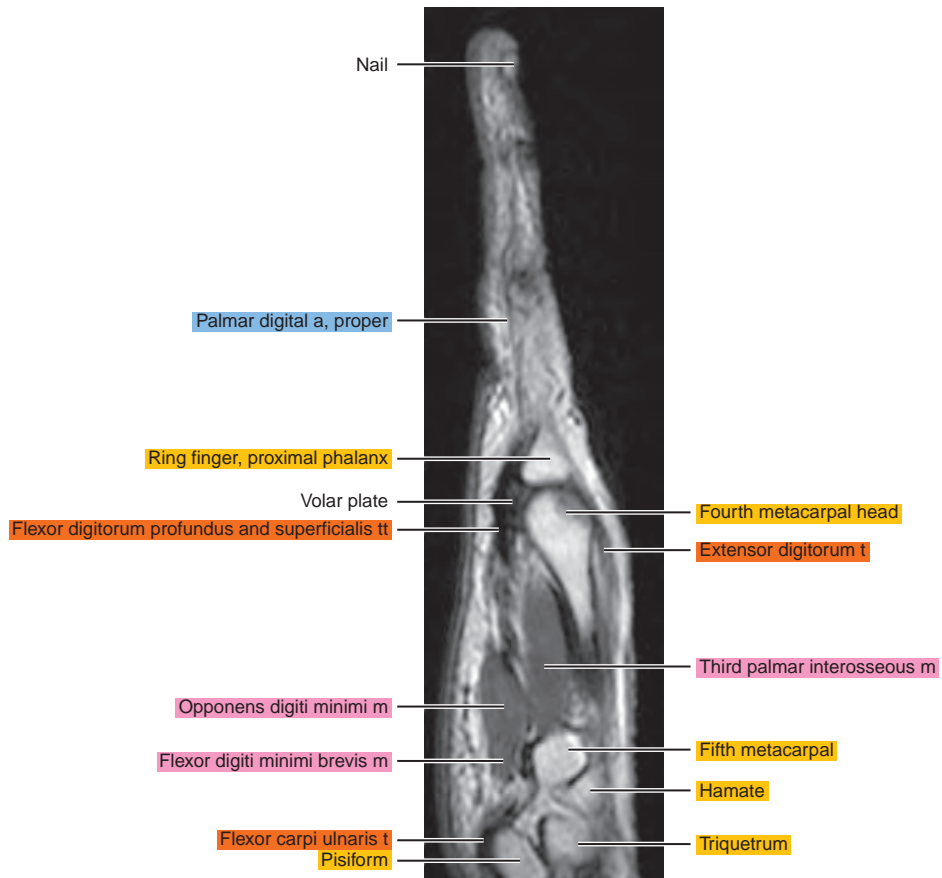
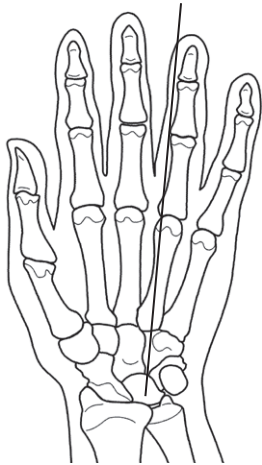


Figure 8.2.14

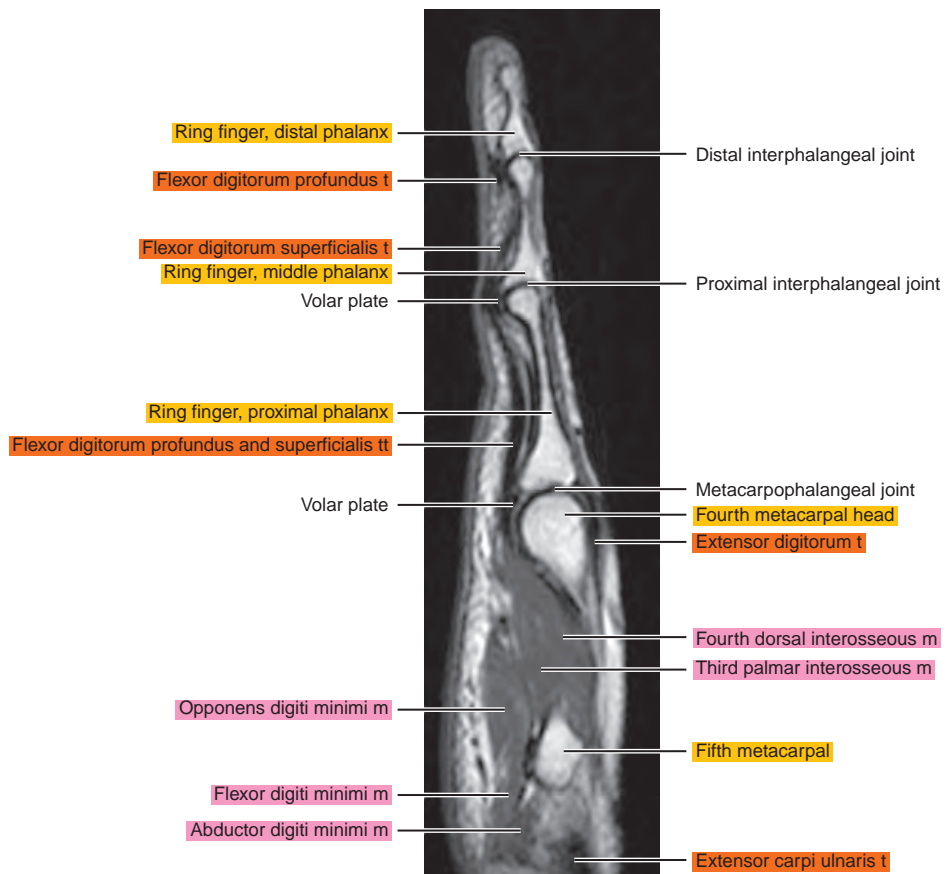
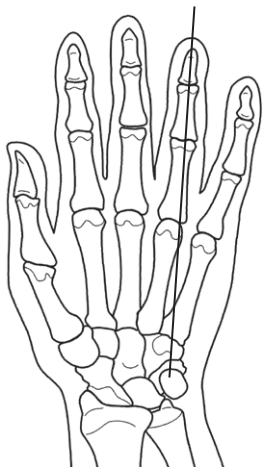


Figure 8.2.15

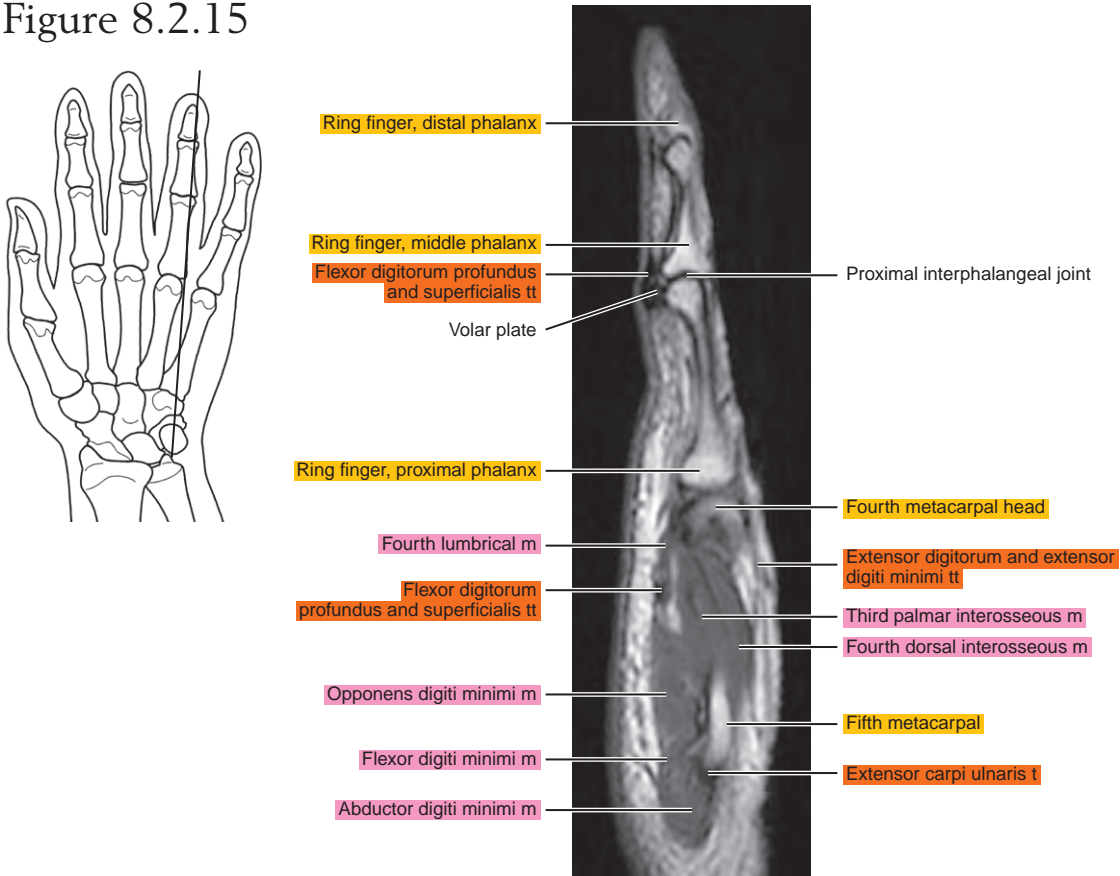


Figure 8.2.16

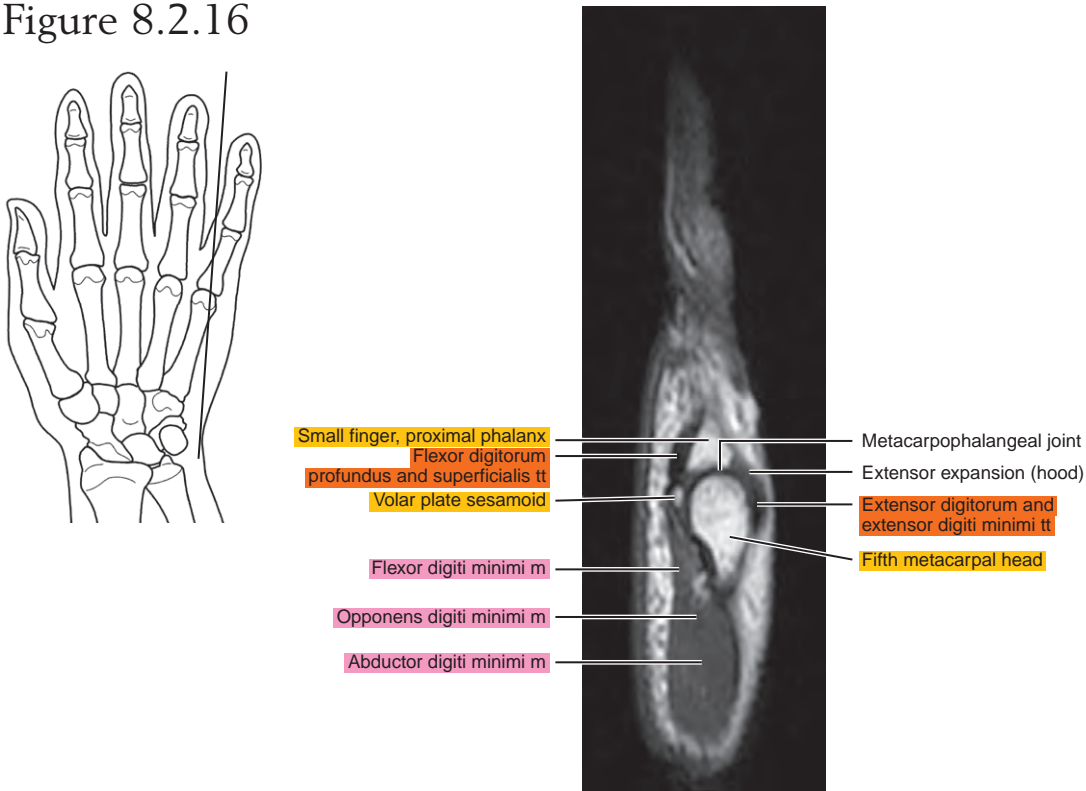


Figure 8.2.17

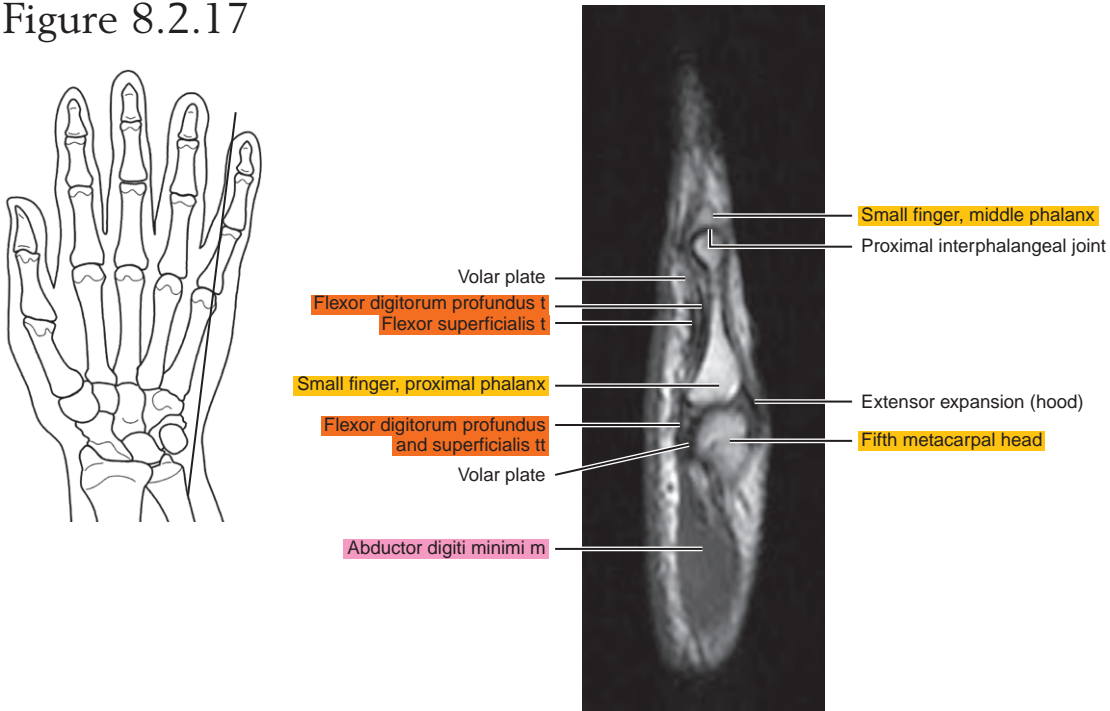
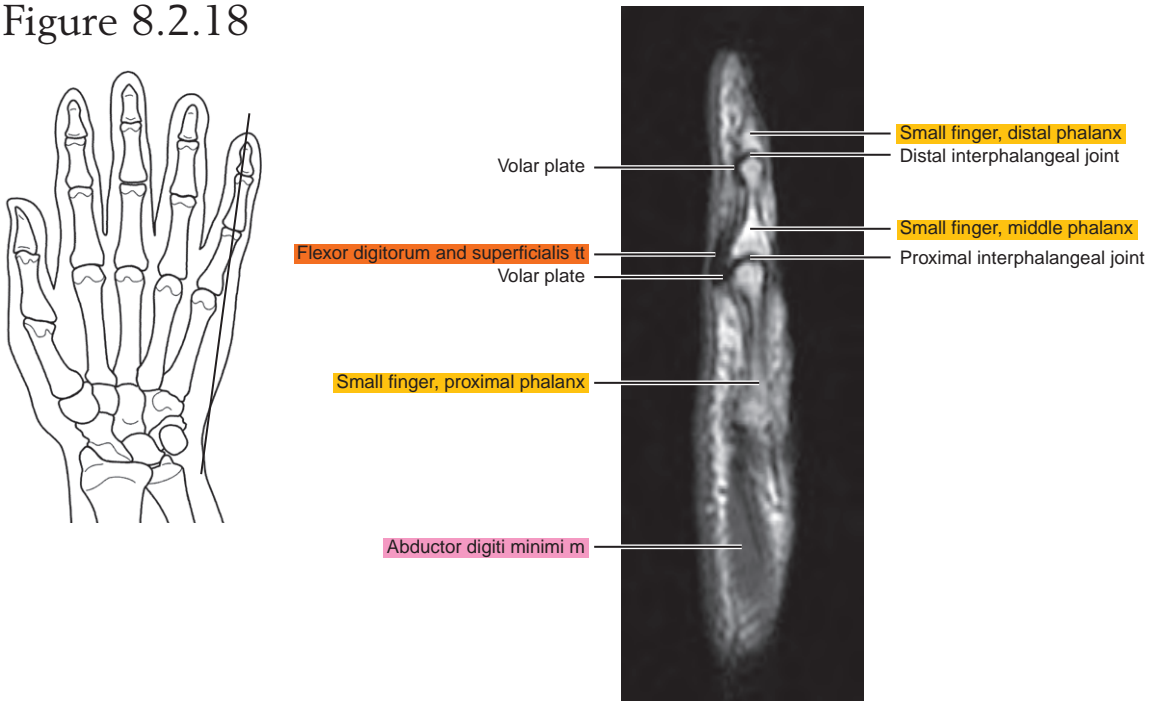


Figure 8.2.18



CORONAL

Figure 8.3.1

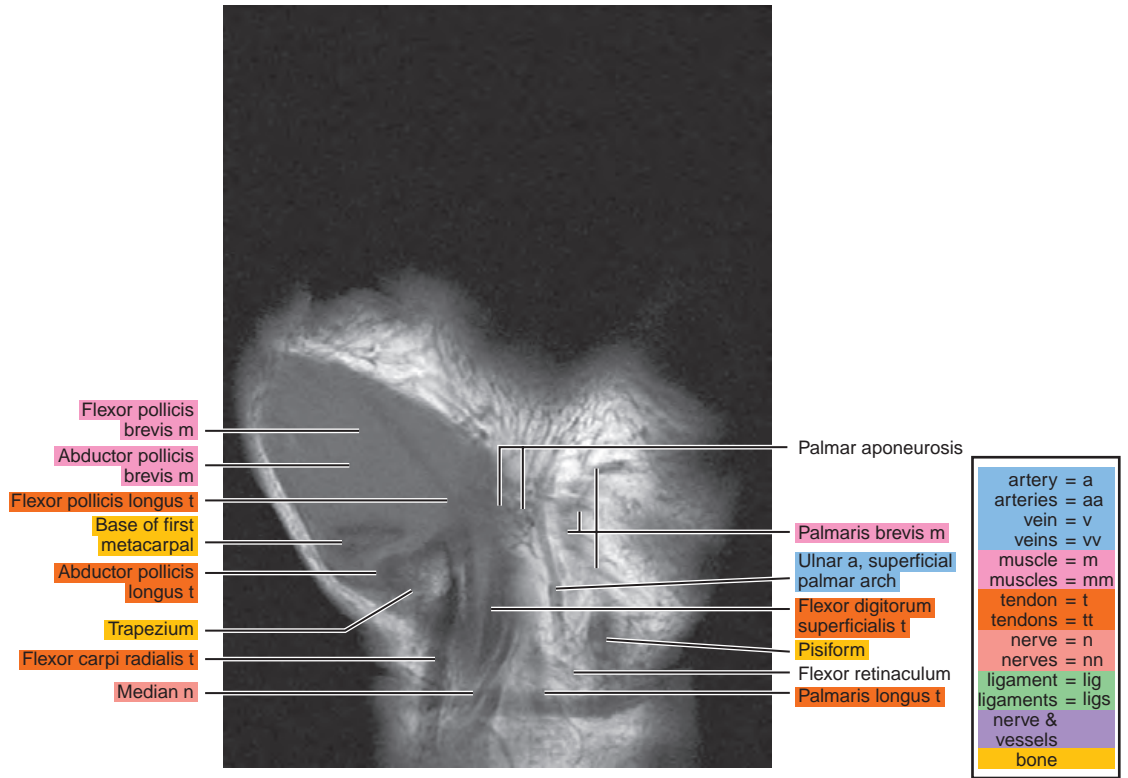
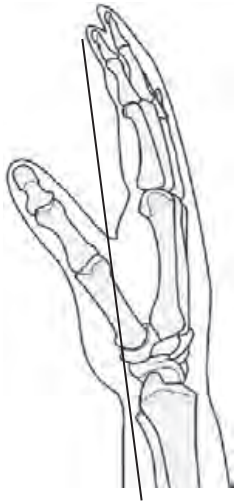


Figure 8.3.2

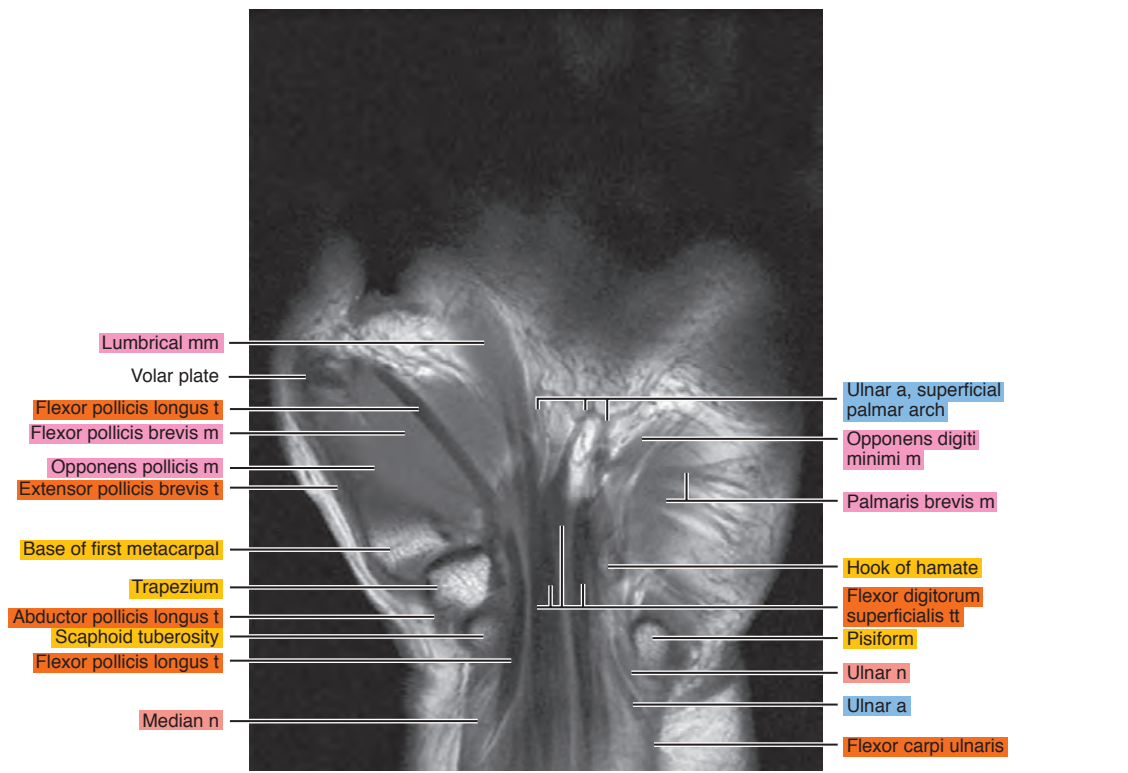
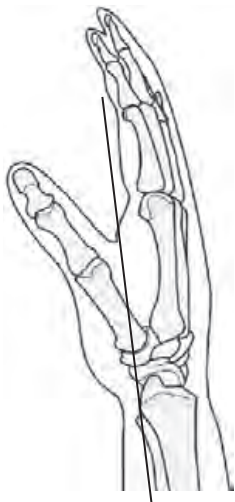

Figure 8.3.3

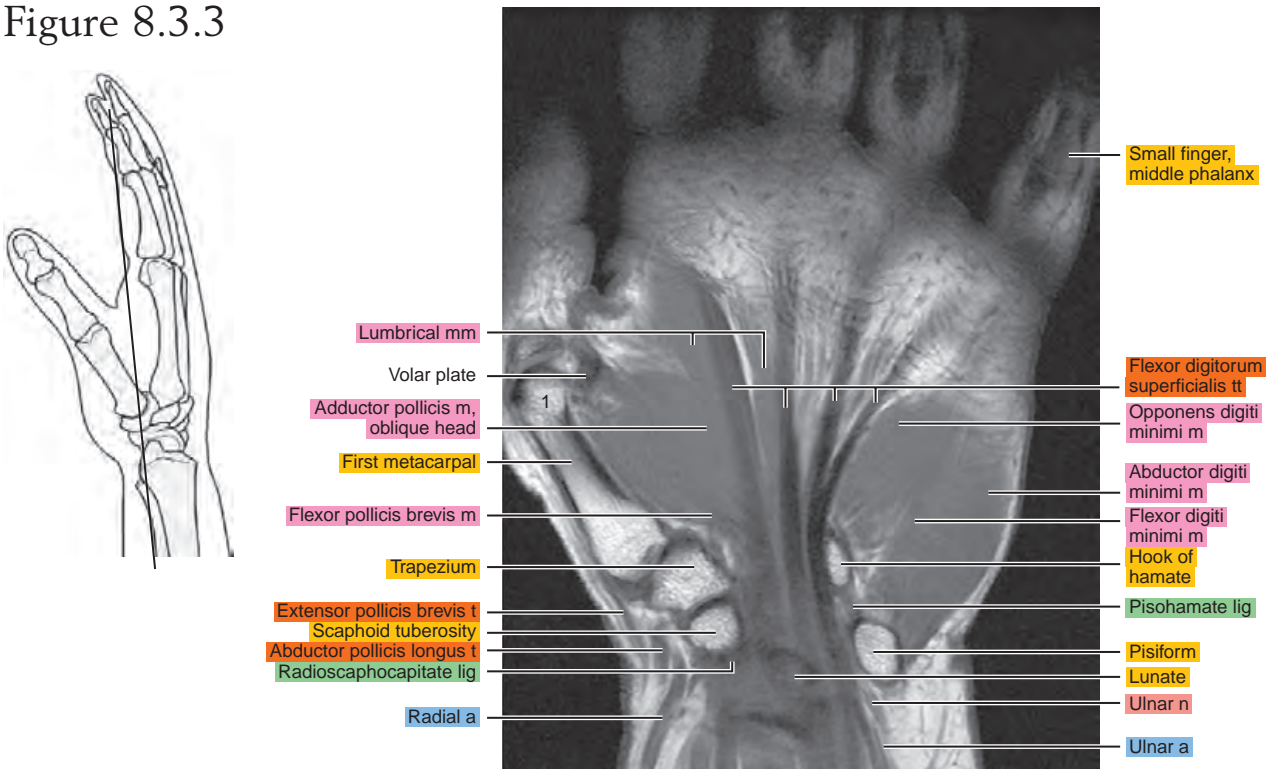


Figure 8.3.4

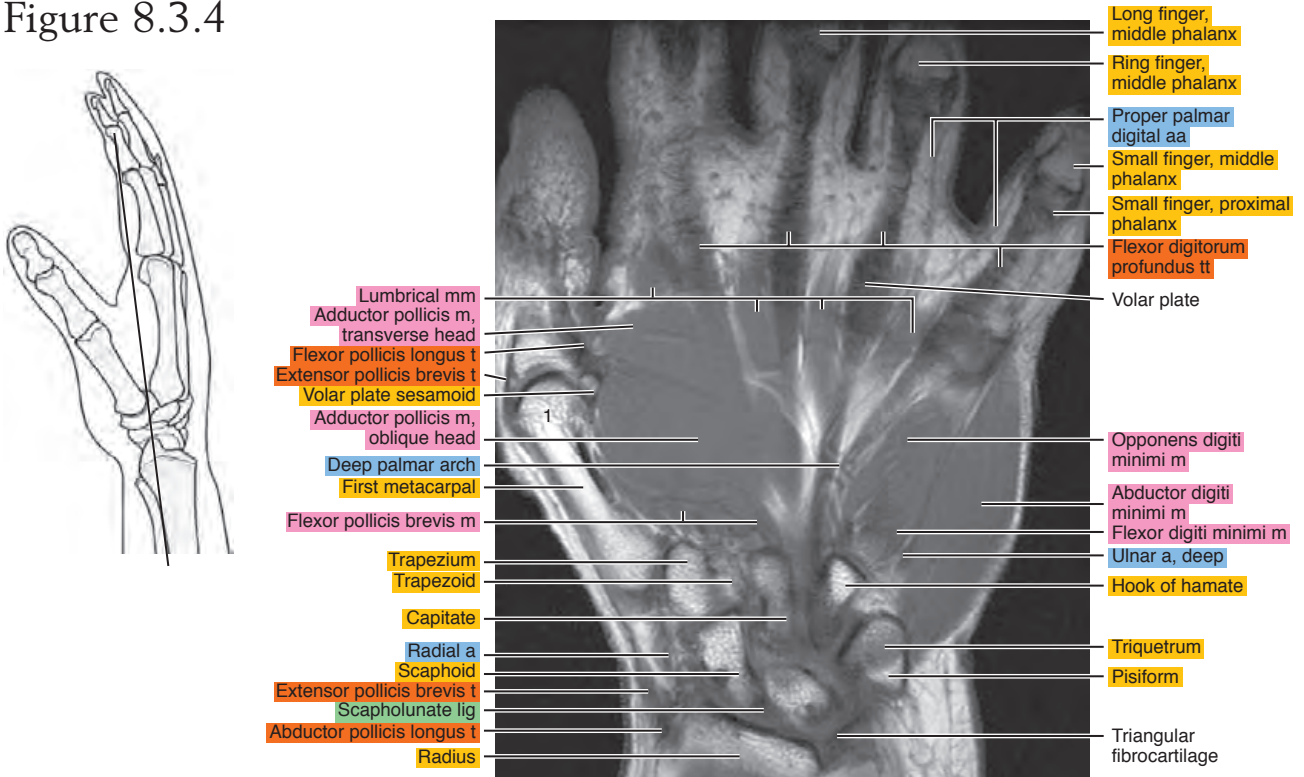


Figure 8.3.5

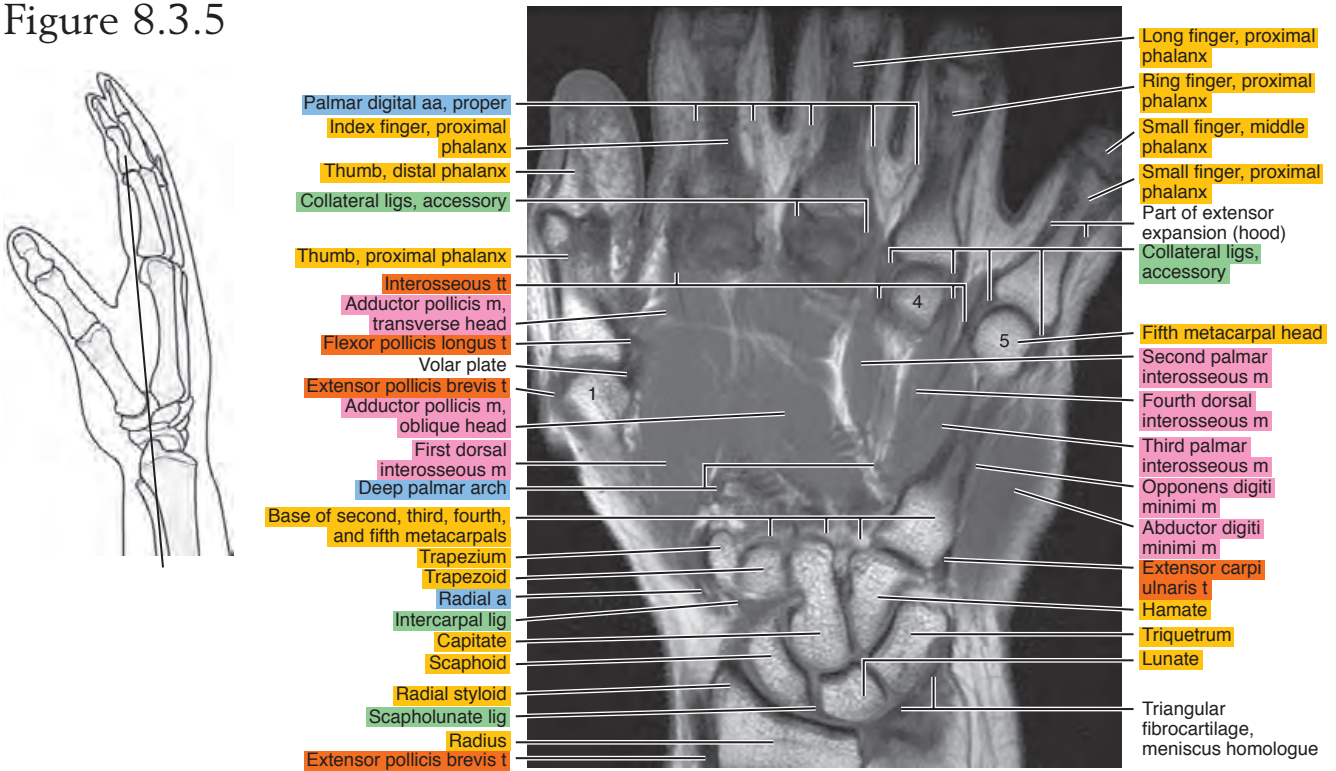


Figure 8.3.6

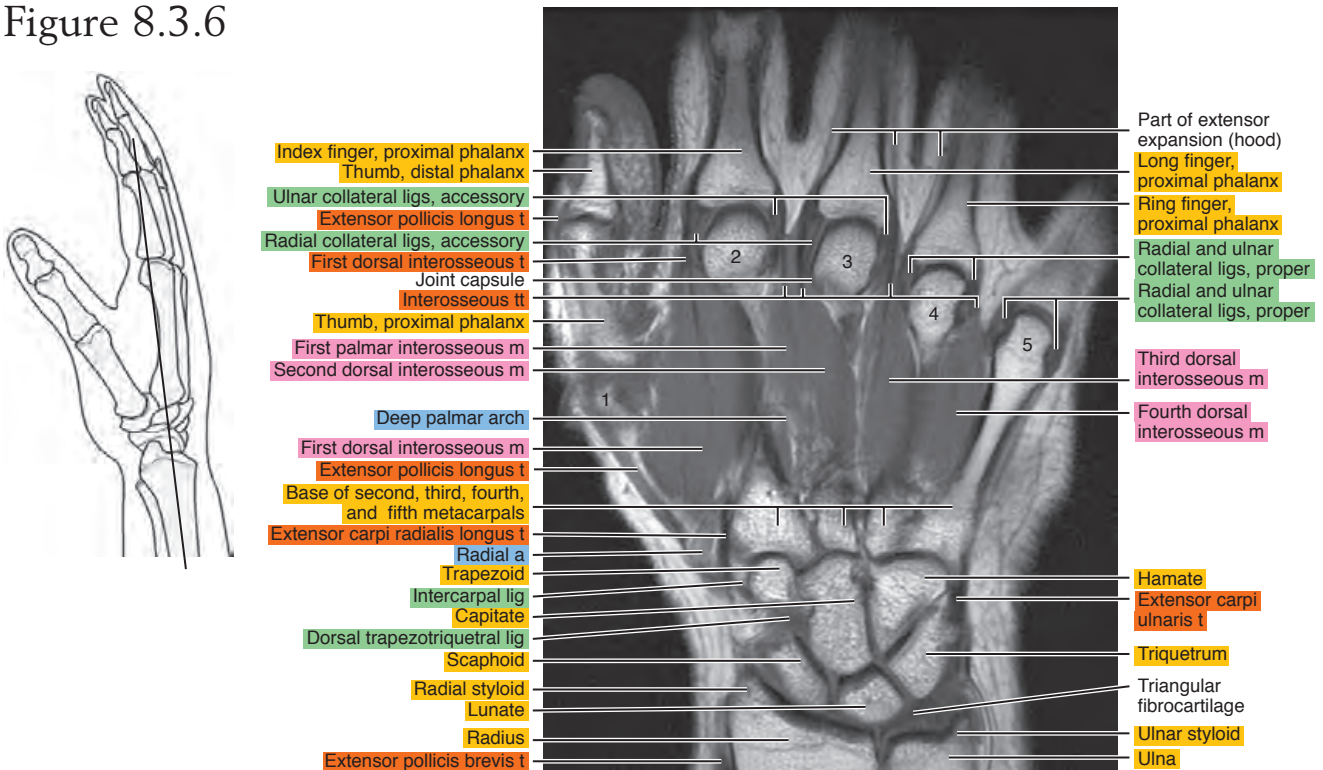


Figure 8.3.7

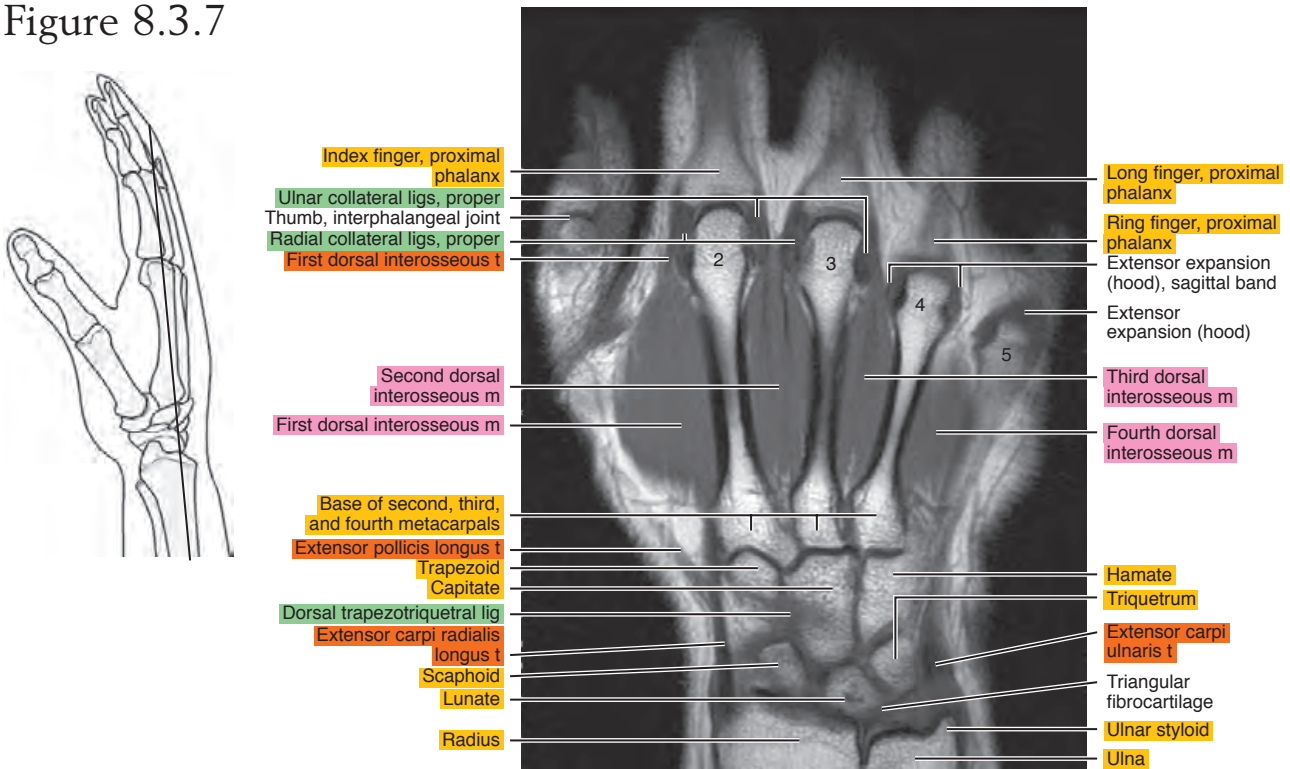


Figure 8.3.8

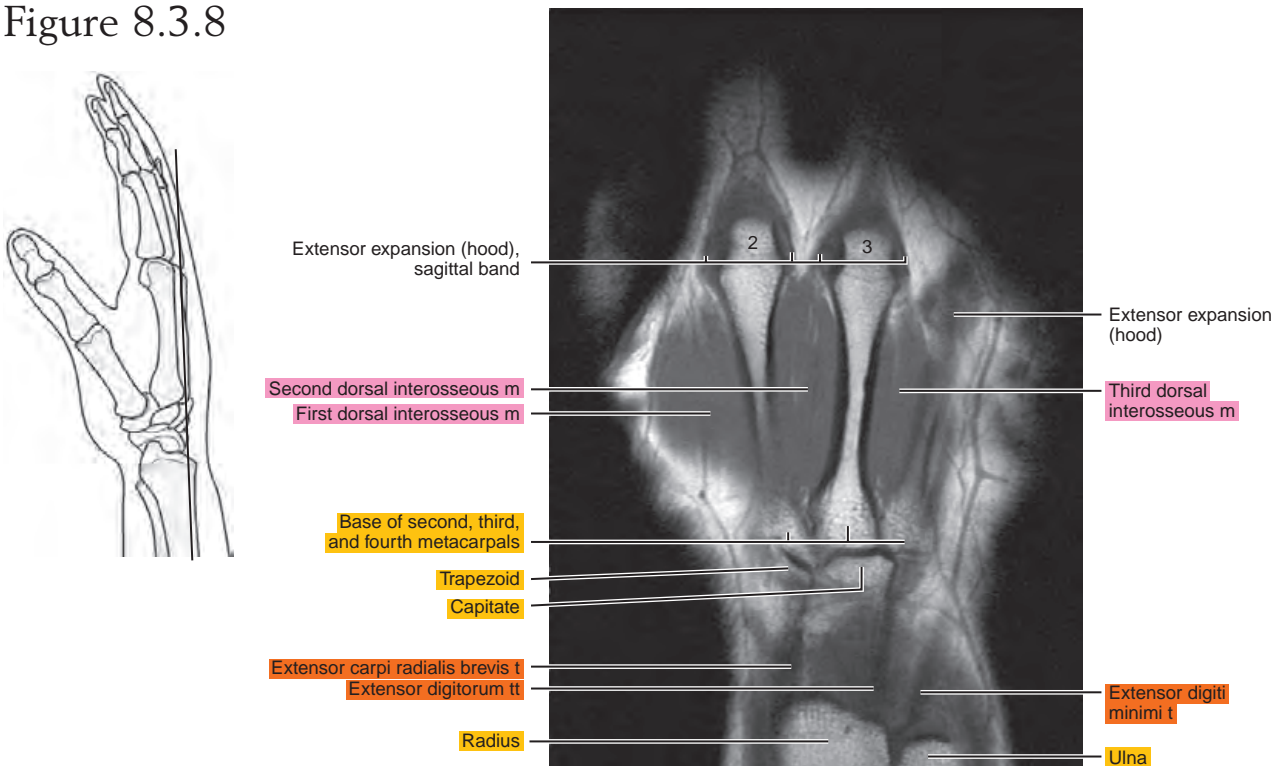
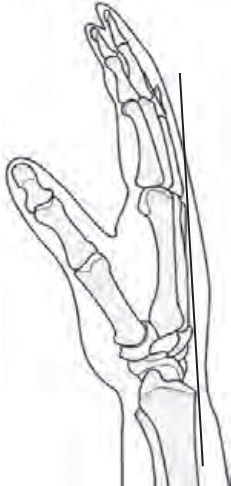


Figure 8.3.9



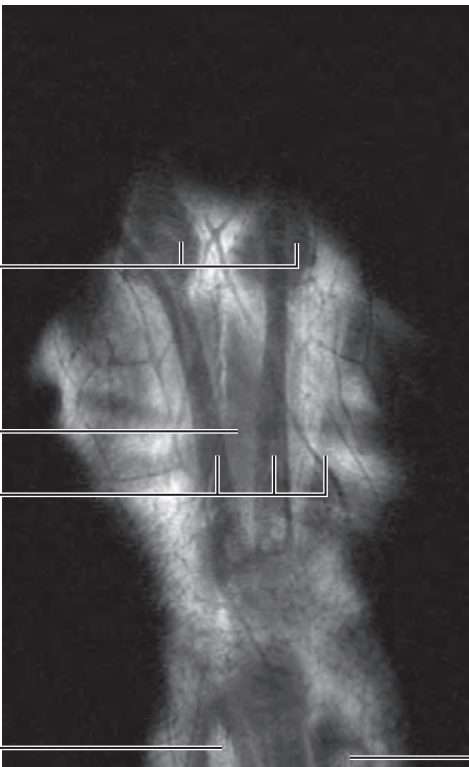
Extensor expansions (hoods)

Second dorsal interosseous m

Extensor digitorum ti

Radius

Ulna



The background of the page is a complex, repeating geometric pattern of green triangles and hexagons, creating a textured, crystalline effect. The colors range from light green to a darker, forest green.

II
Section

Lower Extremity

This page intentionally left blank

Chapter
9

MRI of the Hip

Table 9-1. Muscles of the Hip

MUSCLE	ORIGIN	INSERTION	NERVE SUPPLY
Obturator internus	Pelvic surface of the pubic rami near the obturator foramen, pelvic surface of the ischium between the foramen and the greater sciatic notch, deep surface of the obturator internus fascia, fibrous arch that surrounds the foramen for obturator vessels and nerve, most of the pelvic surface of the obturator membrane except the lower part	Medial side of the greater trochanter in front of the trochanteric fossa of the femur	Nerve to the obturator internus, from the lumbosacral trunk, and first and second sacral
Obturator externus	Lateral surface of the pubic and ischial rami, where they surround the obturator membrane, lateral surface of the obturator membrane	Trochanteric fossa	Obturator
Gemellus superior	Outer surface of the ischial spine and edge of the lesser sciatic notch	After union with the tendon of the obturator internus, inserts into the medial side of the greater trochanter in front of the trochanteric fossa	By a small nerve, branch of the nerve to obturator internus or branch of the nerve to the quadratus femoris
Gemellus inferior	Upper part of the inner border of the tuberosity of the ischium, sacrotuberous ligament, and edge of the lesser sciatic notch	By union with the tendon of the obturator internus or with the tendon onto the greater trochanter below the obturator internus muscle	By a small branch of the nerve to the quadratus femoris
Quadratus femoris	Upper part of the outer border of the tuberosity of the ischium	The inferior dorsal angle of the greater trochanter	Lumbosacral trunk and first sacral
Psoas major	By a series of thick fasciculi from the intervertebral discs and bodies between T12 and L5, from the bodies of L1 to L4, and from slender fascicles from the ventral surfaces of the transverse processes of the lumbar vertebrae	The lesser trochanter of the femur	Branches from L1 (often), L2, L3, and L4
Iliacus	Iliac crest, iliolumbar ligament, iliac fossa, anterior sacroiliac ligaments, often from the ala of the sacrum, and from the ventral border of the ilium between the two anterior spines	Lateral surface of the psoas tendon (above the inguinal ligament) onto the femur immediately distal to the lesser trochanter; the lateral portion arises from the ventral border of the ilium and is attached to the tendon of the rectus femoris and the capsule of the hip joint	Femoral and L1 to L4
Tensor fasciae latae	Anterior superior iliac spine and anterior part of the external lip of the iliac crest	Muscle fibers pass distally in parallel array, unite with the tendon, and join the iliotibial tract about one third of the way down the thigh	Superior gluteal
Gluteus medius	Ventral three fourths of the iliac crest, outer surface of the ilium between the anterior and posterior gluteal lines, and from the investing fascia	Onto the posterosuperior angle and the external surface of the greater trochanter	Superior gluteal (L4, L5, S1)

Table 9-1. Muscles of the Hip—cont’d

MUSCLE	ORIGIN	INSERTION	NERVE SUPPLY
Piriformis	Lateral part of the ventral surface of S2, S3, and S4, posterior border of the greater sciatic notch, from the sacrotuberous ligament near the sacrum	Onto the anterior and inner parts of the upper border of the greater trochanter	S1 or S2 or from a loop between S1 and S2
Gluteus maximus	Dorsal fifth of the outer lip of the iliac crest, ilium dorsal to the posterior gluteal line, thoracolumbar fascia between the posterior superior spine of the ilium and the side of the sacrum, lateral parts of S4, S5, and coccygeal vertebrae, and from the back of the sacrotuberous ligament	Into the iliotibial tract, gluteal tuberosity of the femur, adjacent part of the tendinous origin of the vastus lateralis	Inferior gluteal by two branches from the sacral plexus (separately or as a united nerve)
Gluteus minimus	Outer surface of the ilium between the anterior and inferior gluteal lines, from the septum between the gluteus minimus and the gluteus medius near the anterior superior, iliac spine and the capsule of the hip joint	Onto the anterior border of the greater trochanter of the femur	Superior gluteal from a branch that supplies the tensor fasciae latae
Biceps femoris, long head	Medial facet on the posterior surface of the ischial tuberosity and sacrotuberous ligament	By a tendon that extends to the head of the fibula	Tibial part of the sciatic
Semitendinosus	Distal margin of the ischial tuberosity and from the tendon common to it and the long head of the biceps femoris	By a triangular tendinous expansion into the proximal part of the medial surface of the tibia behind and distal to the insertion of the gracilis	Sciatic or directly from the lumbosacral plexus by two nerves: from S1 and S2 and from L5 and S1
Semimembranosus	Lateral facet on the posterior surface of the ischial tuberosity	Posterior aspect of the medial tibial condyle	Sciatic branch (also supplies the adductor magnus)

AXIAL

Figure 9.1.1

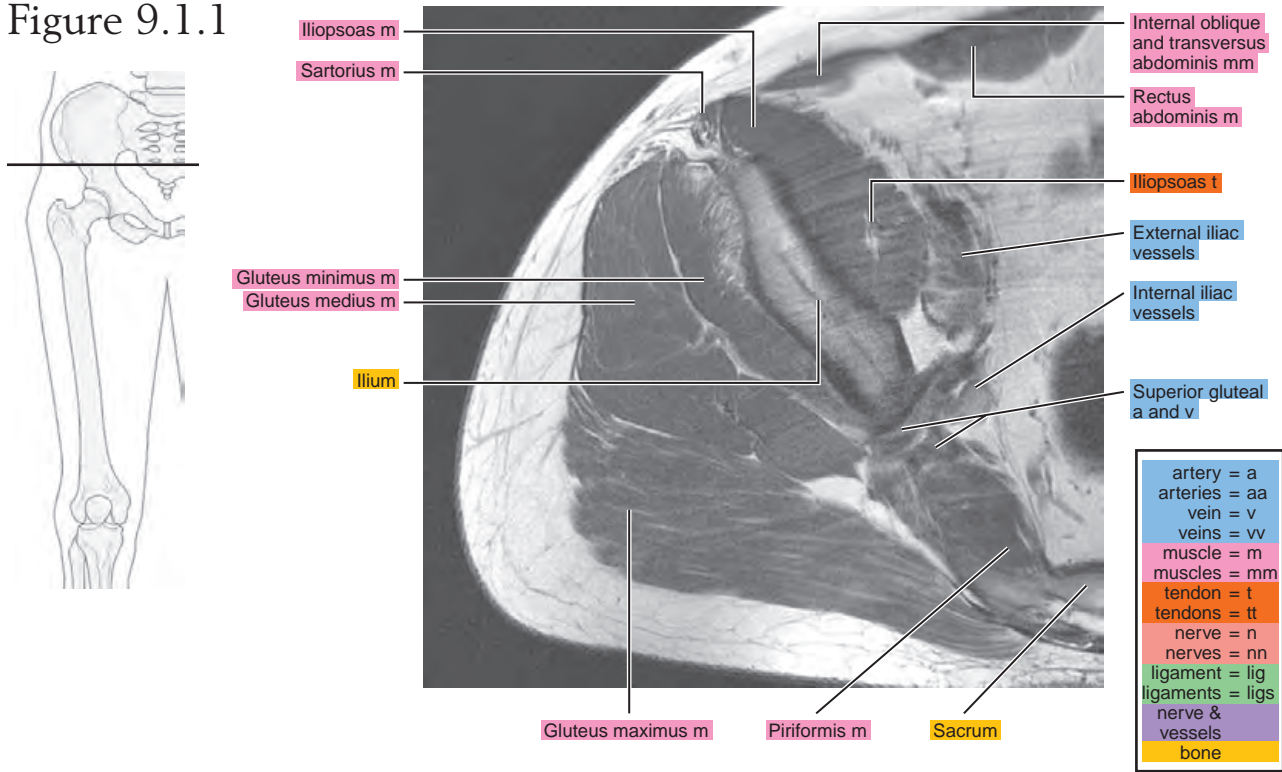


Figure 9.1.2

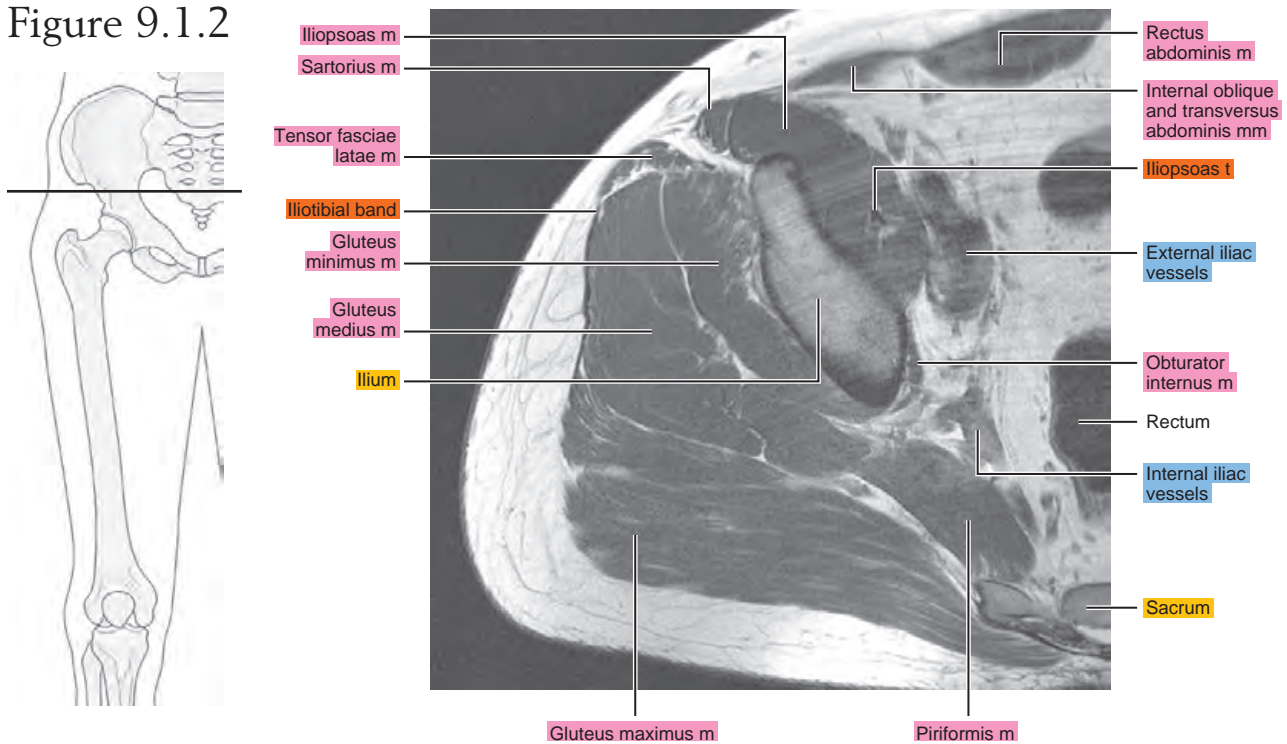


Figure 9.1.3

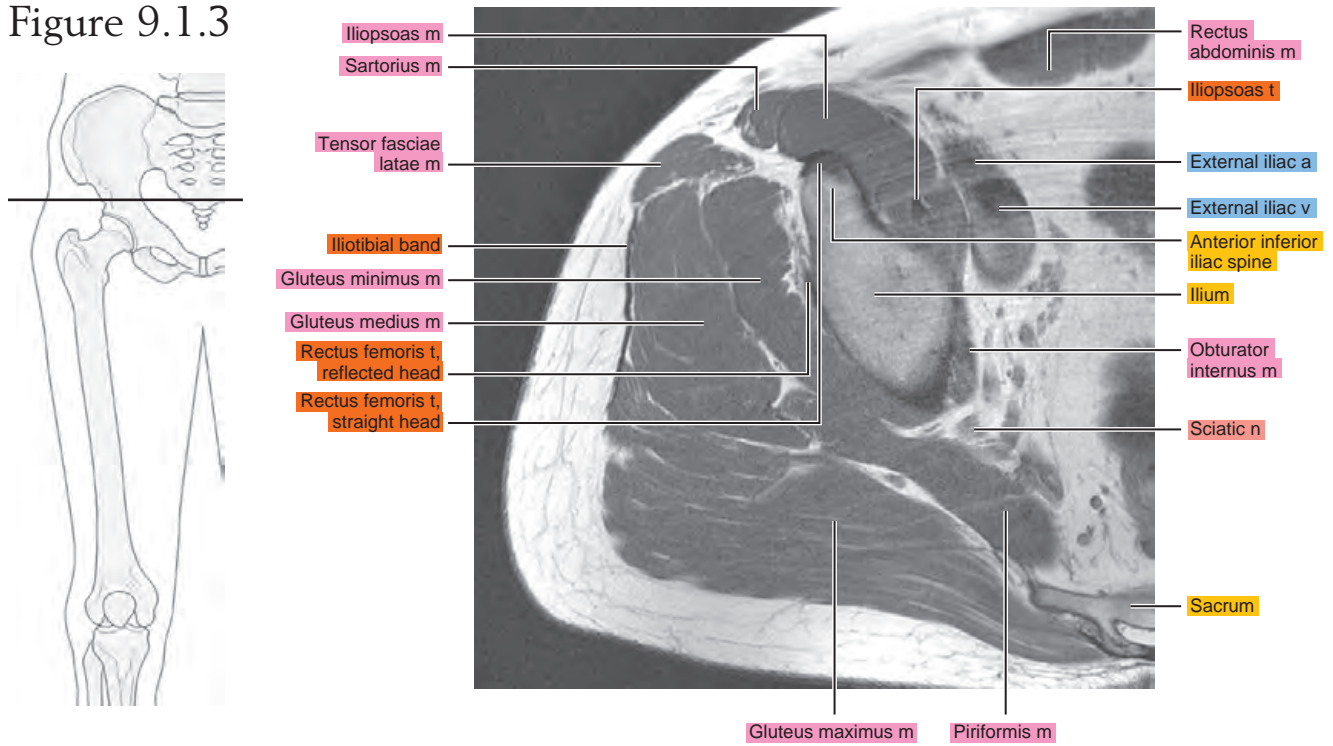


Figure 9.1.4

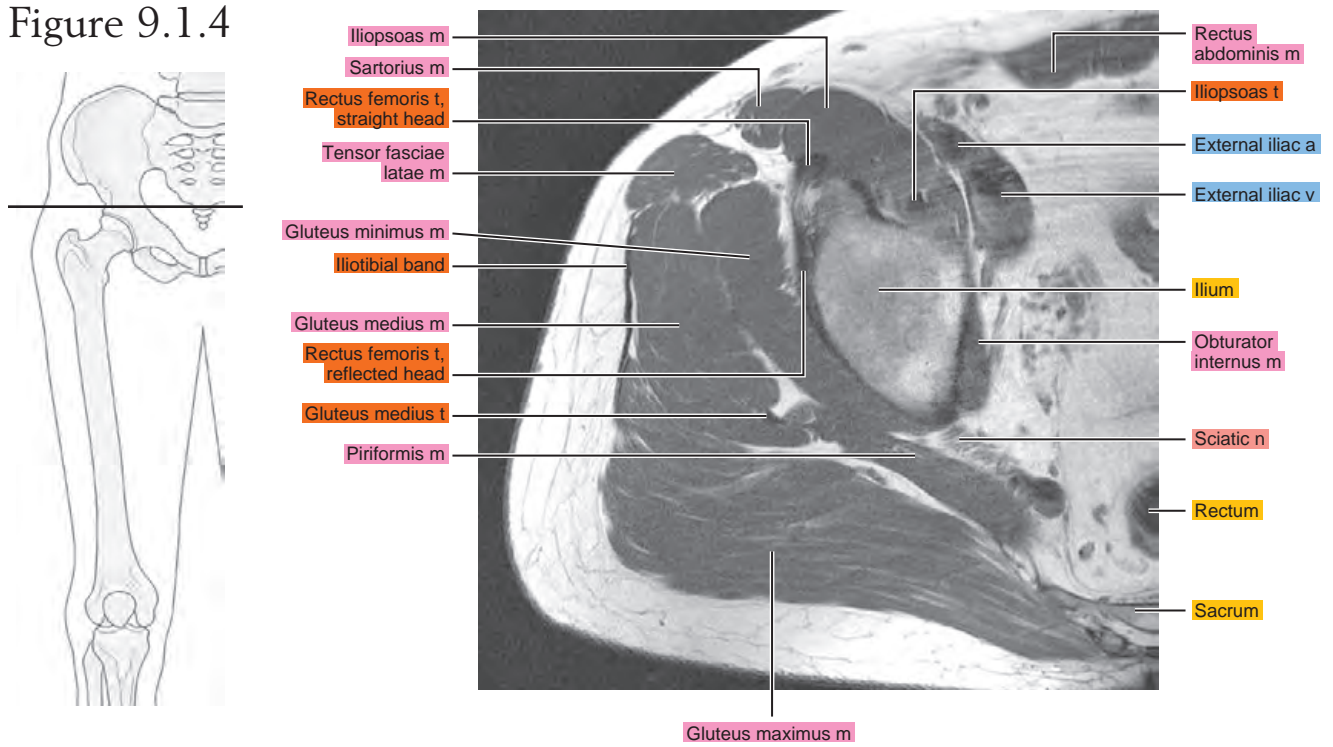


Figure 9.1.5

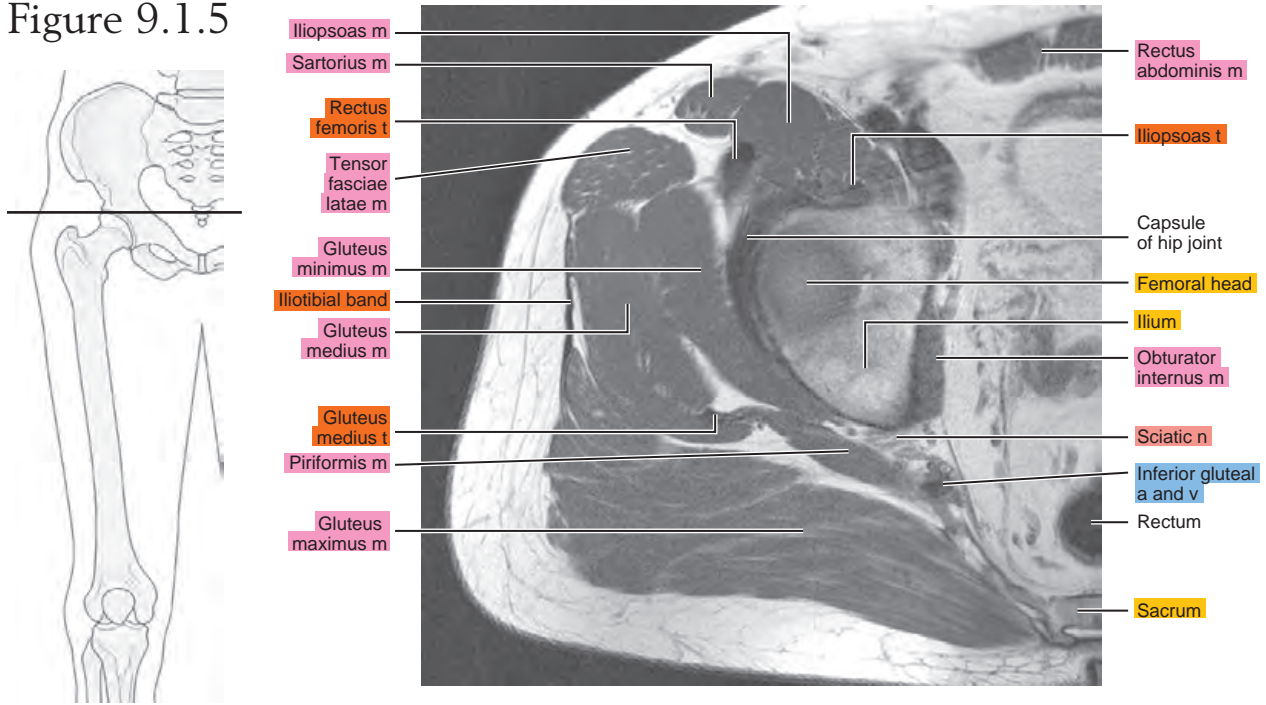


Figure 9.1.6

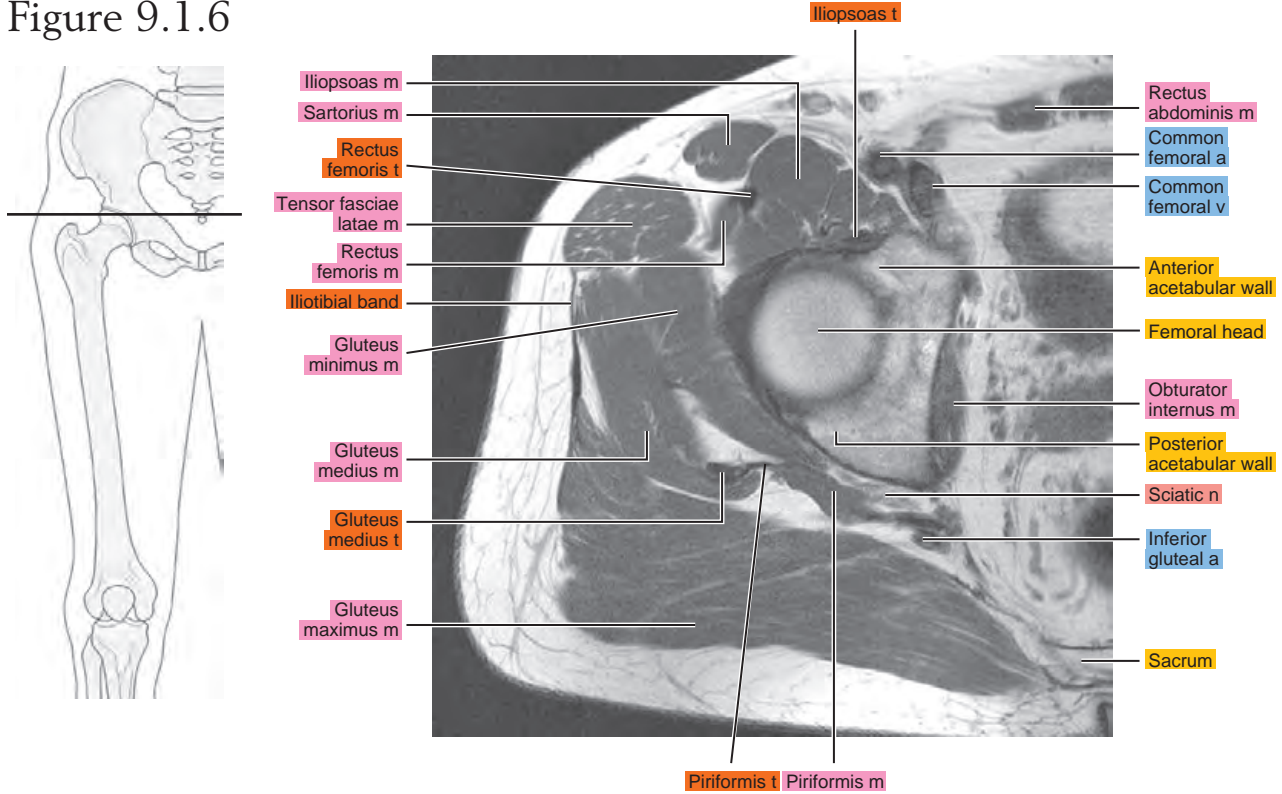


Figure 9.1.7

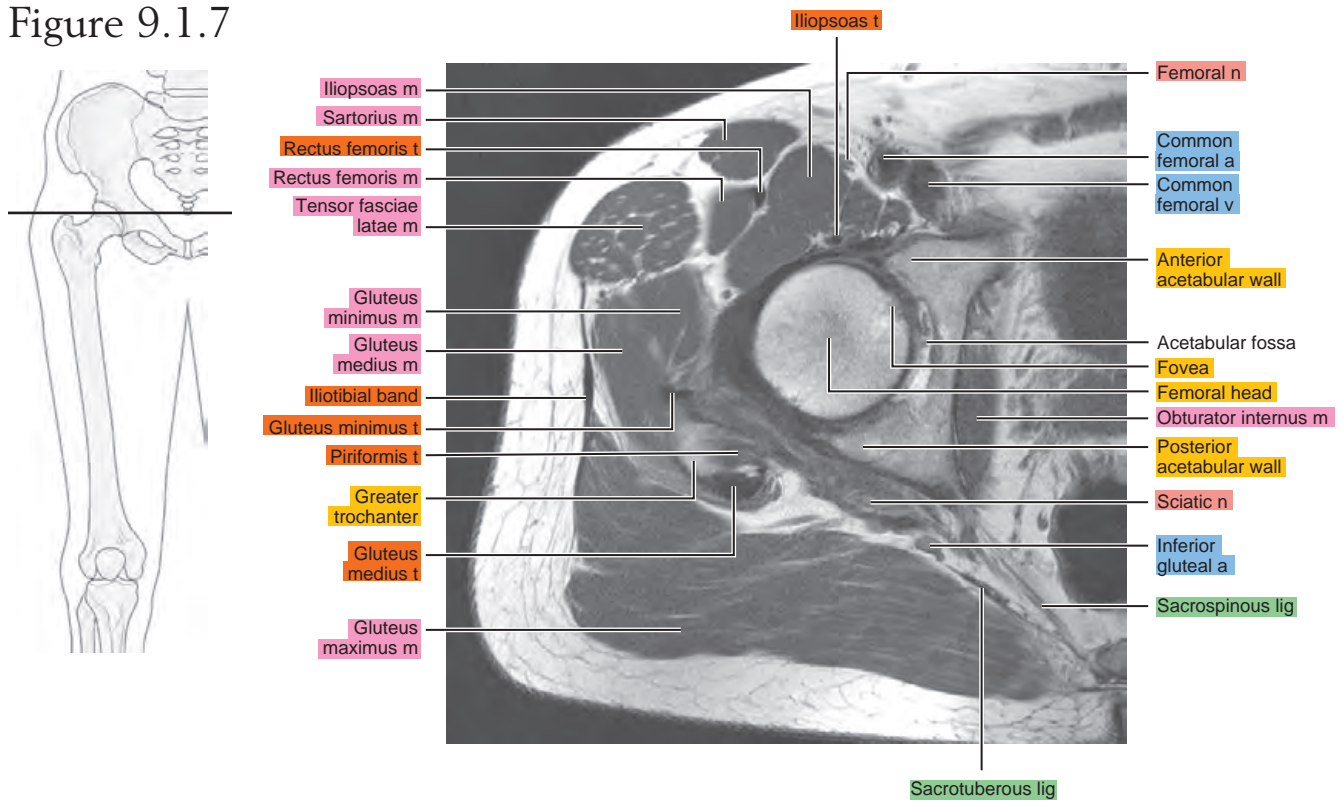


Figure 9.1.8

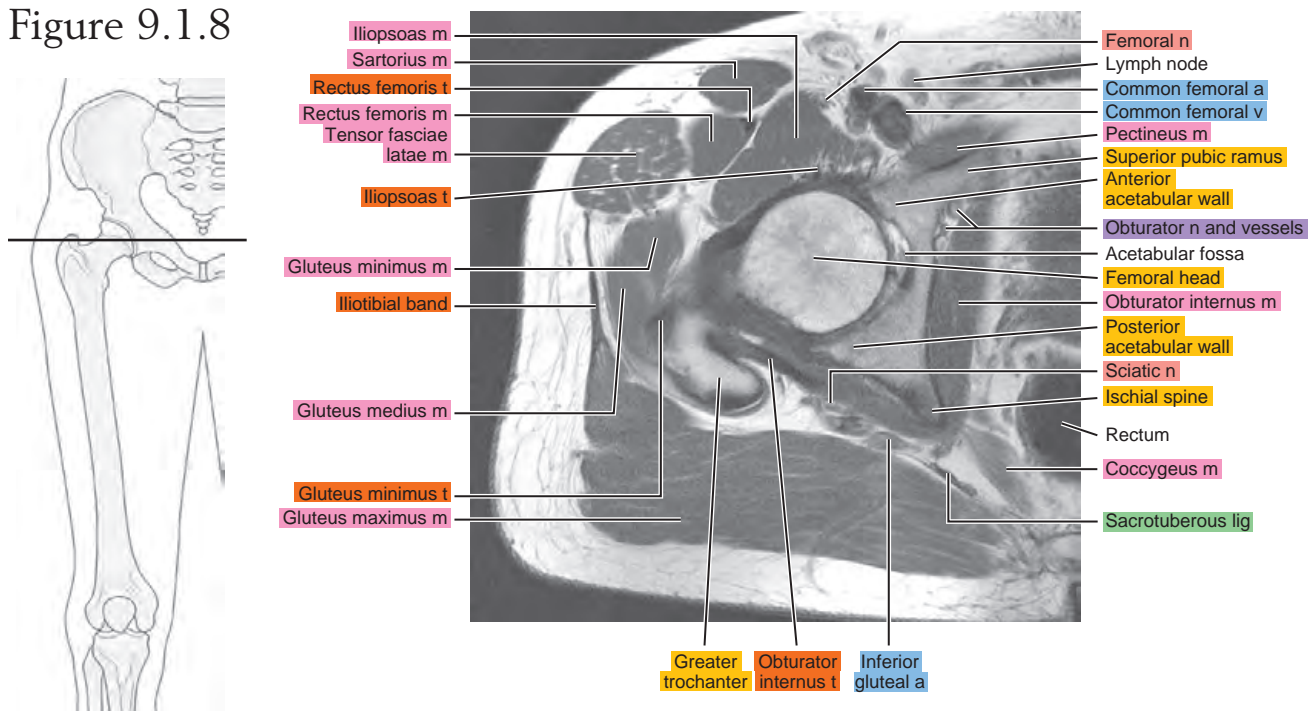


Figure 9.1.9

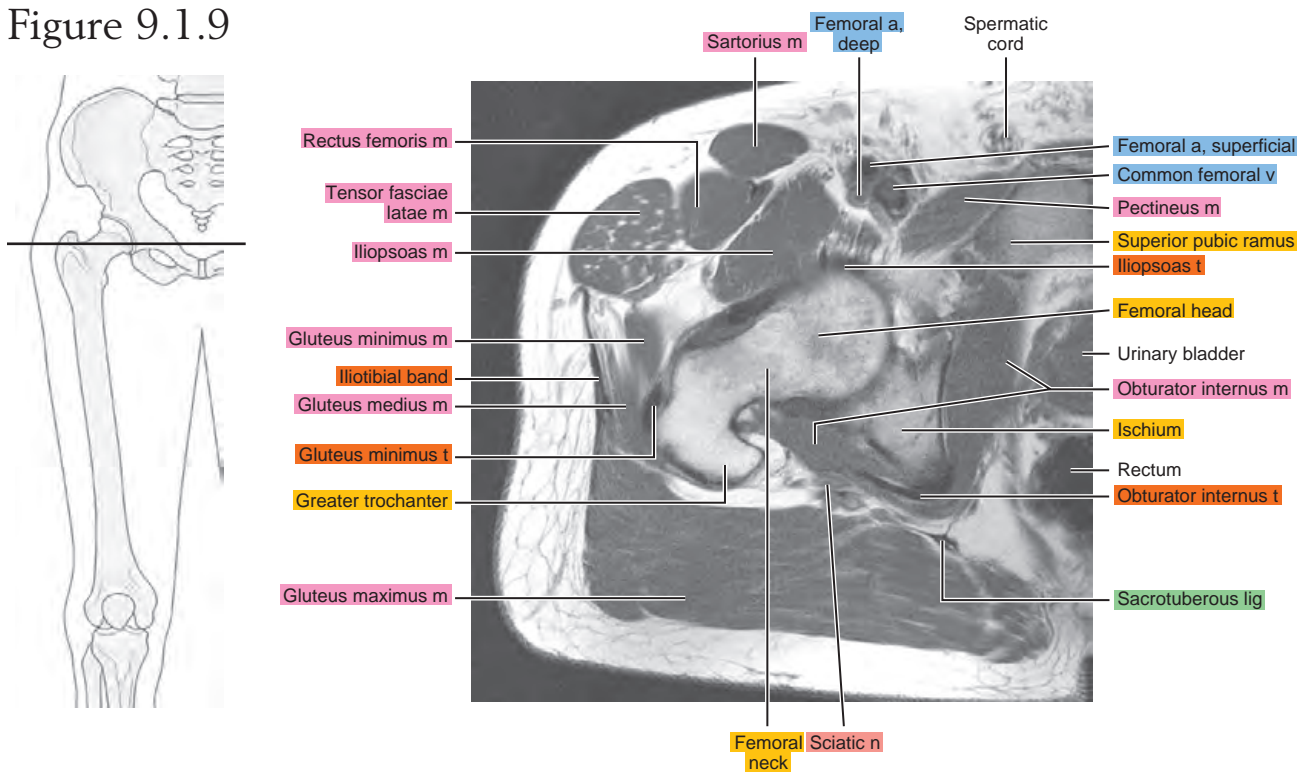


Figure 9.1.10

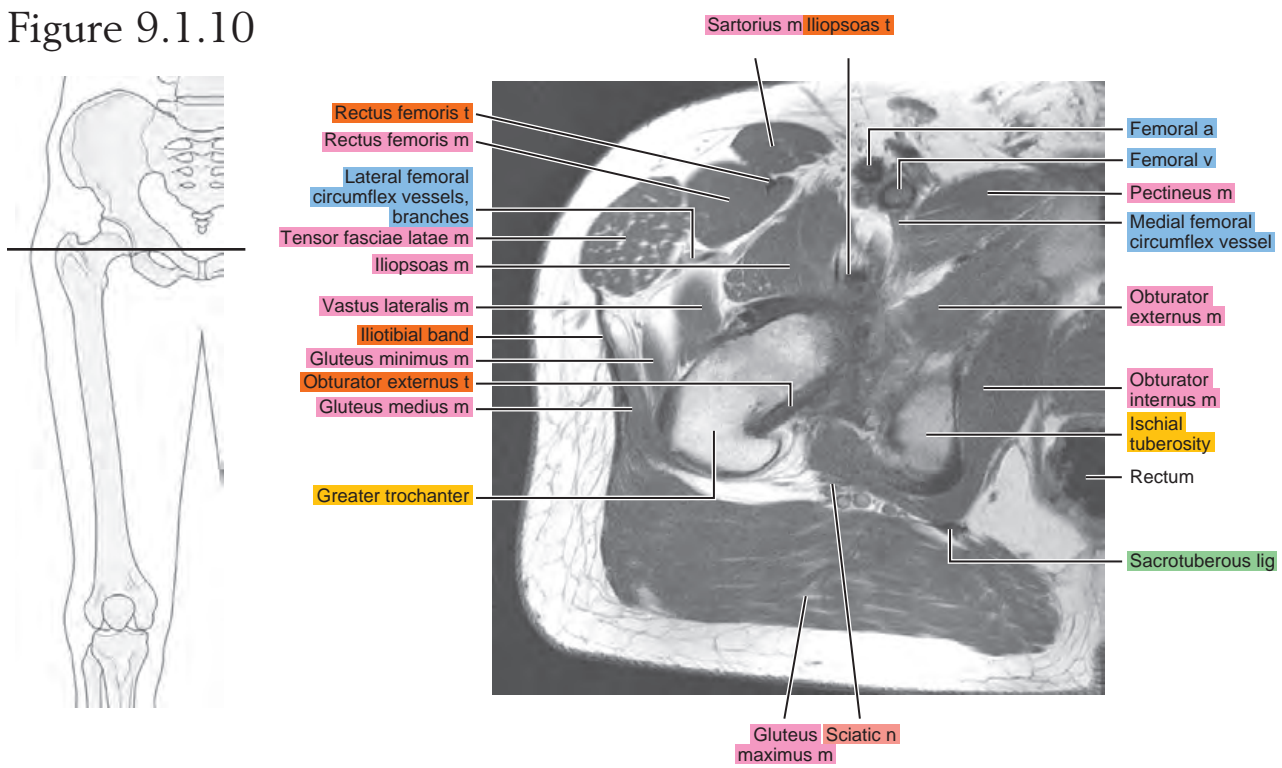


Figure 9.1.11

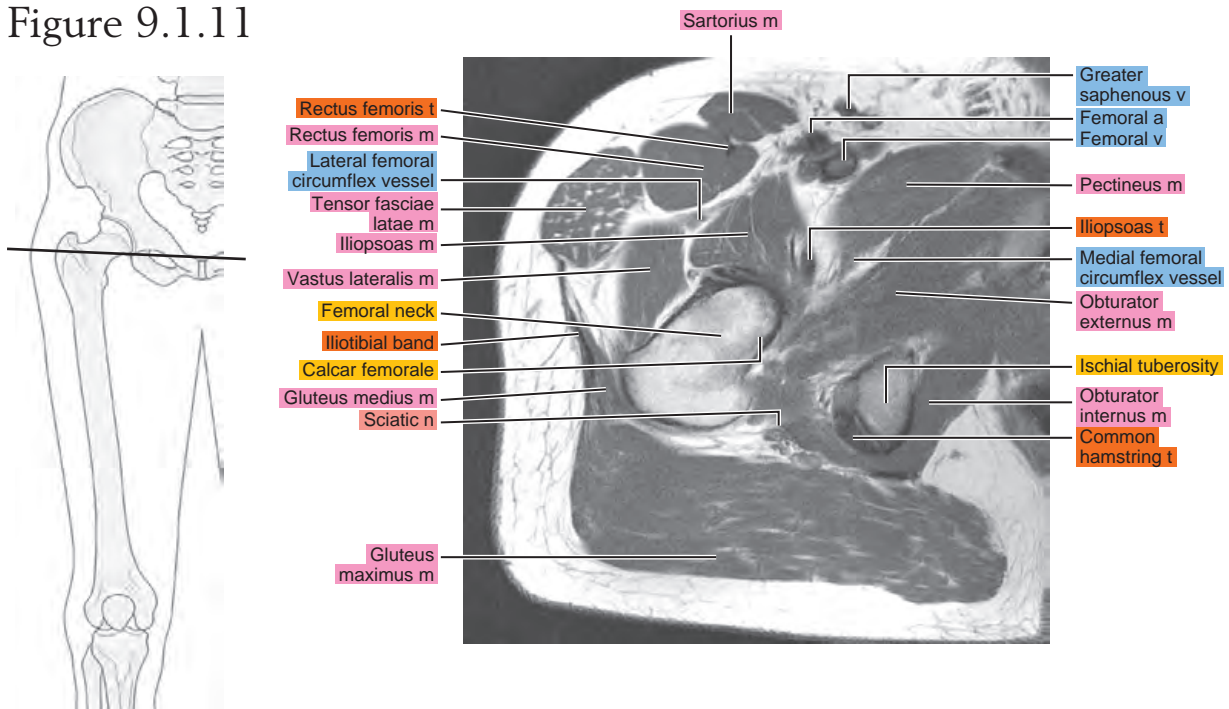


Figure 9.1.12

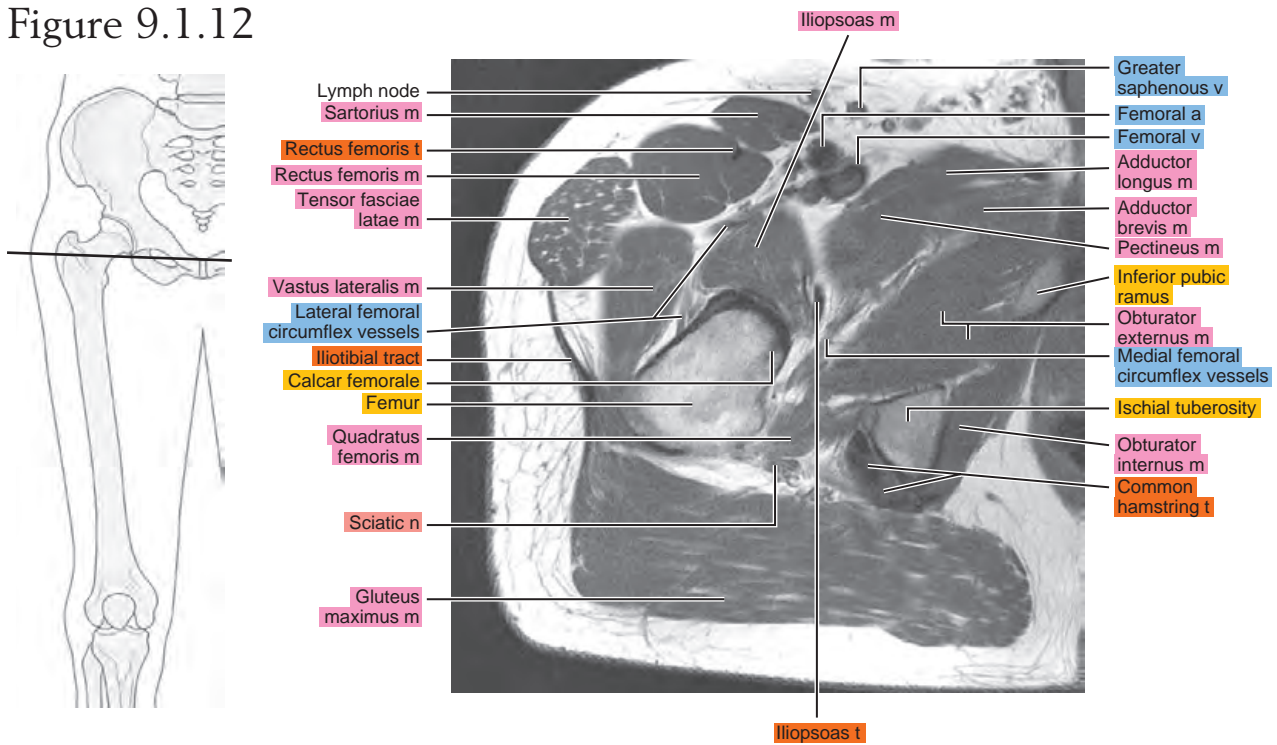


Figure 9.1.13

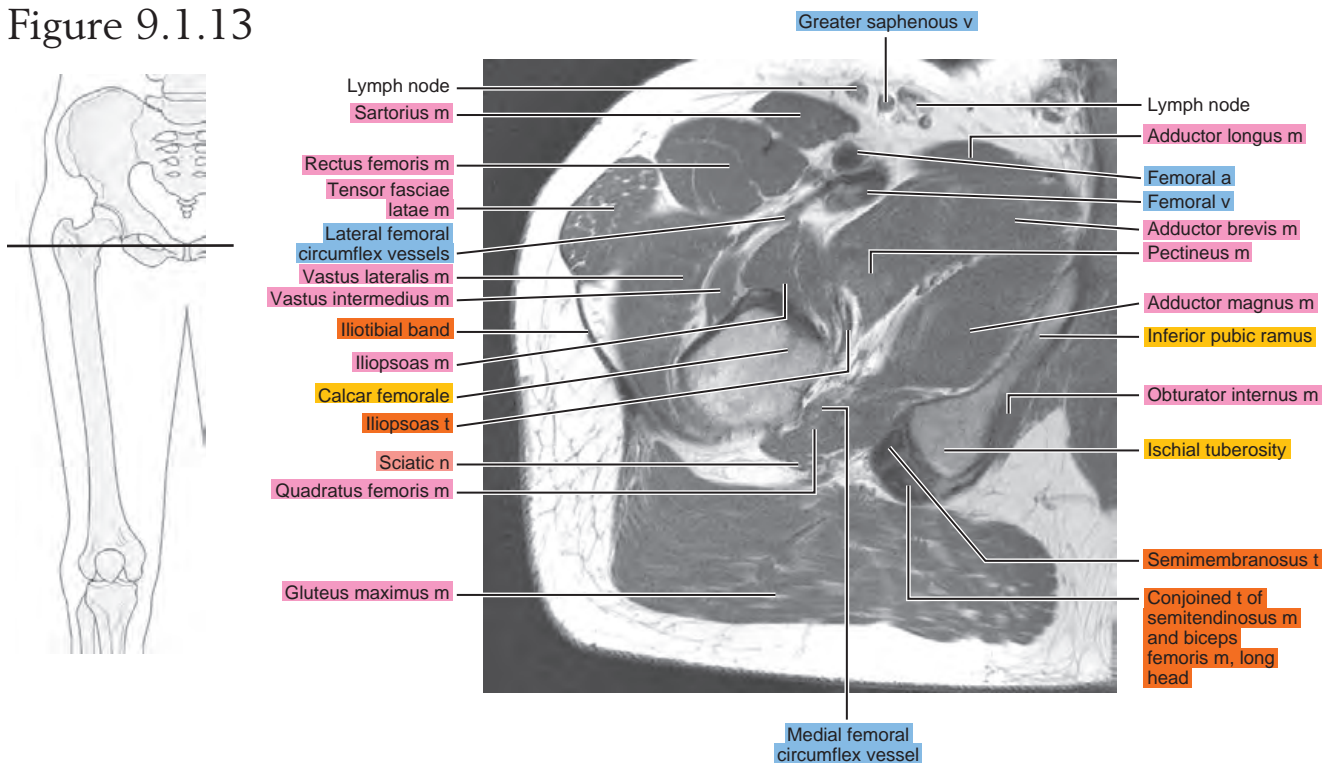


Figure 9.1.14

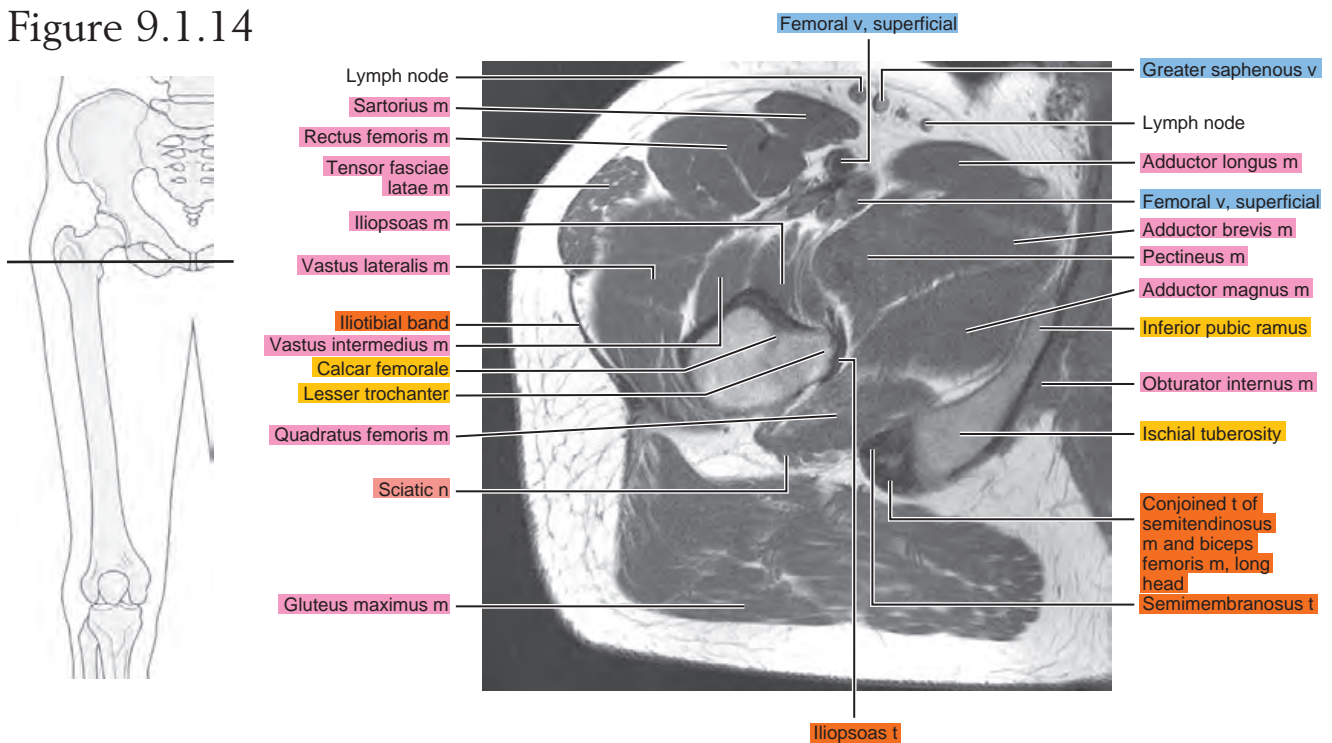


Figure 9.1.15

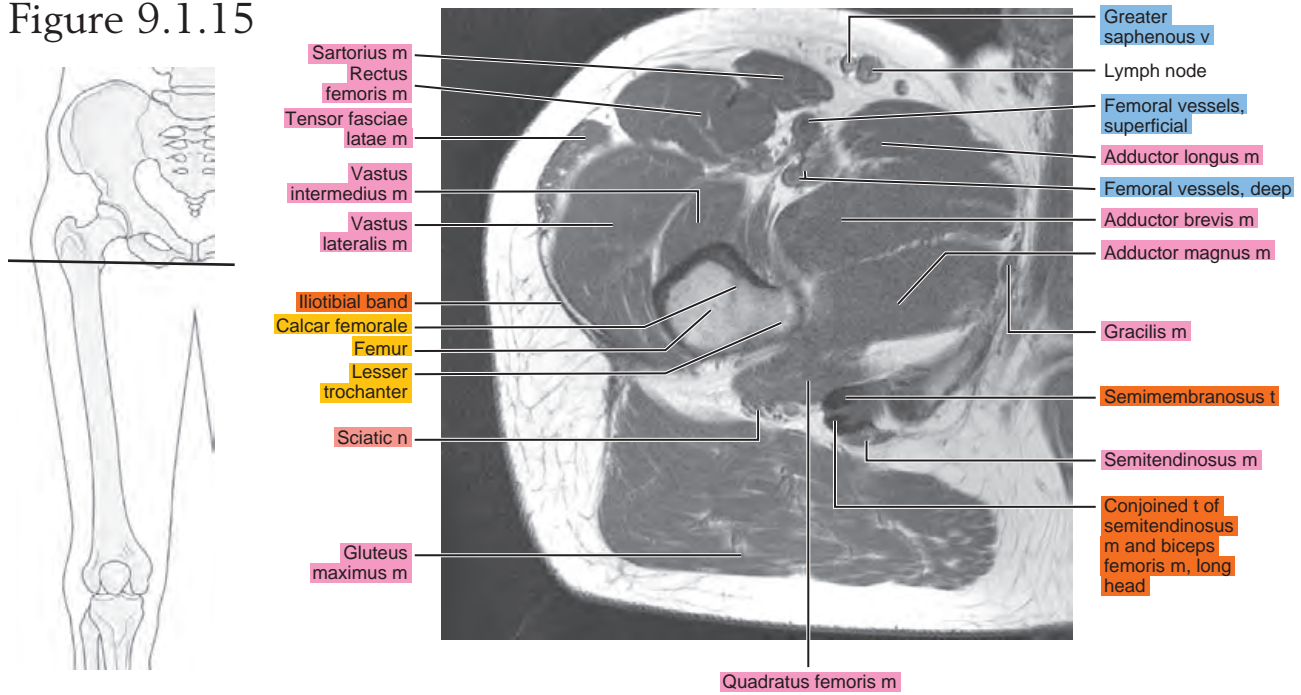


Figure 9.1.16

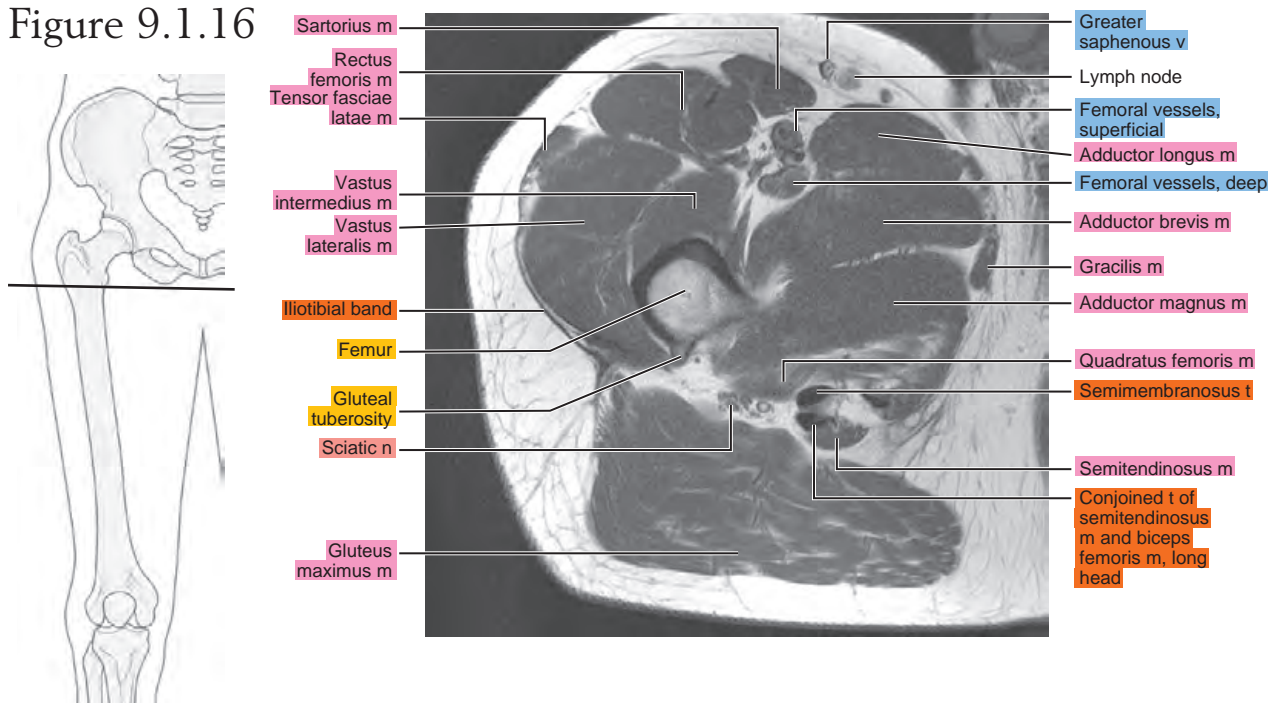


Figure 9.1.17

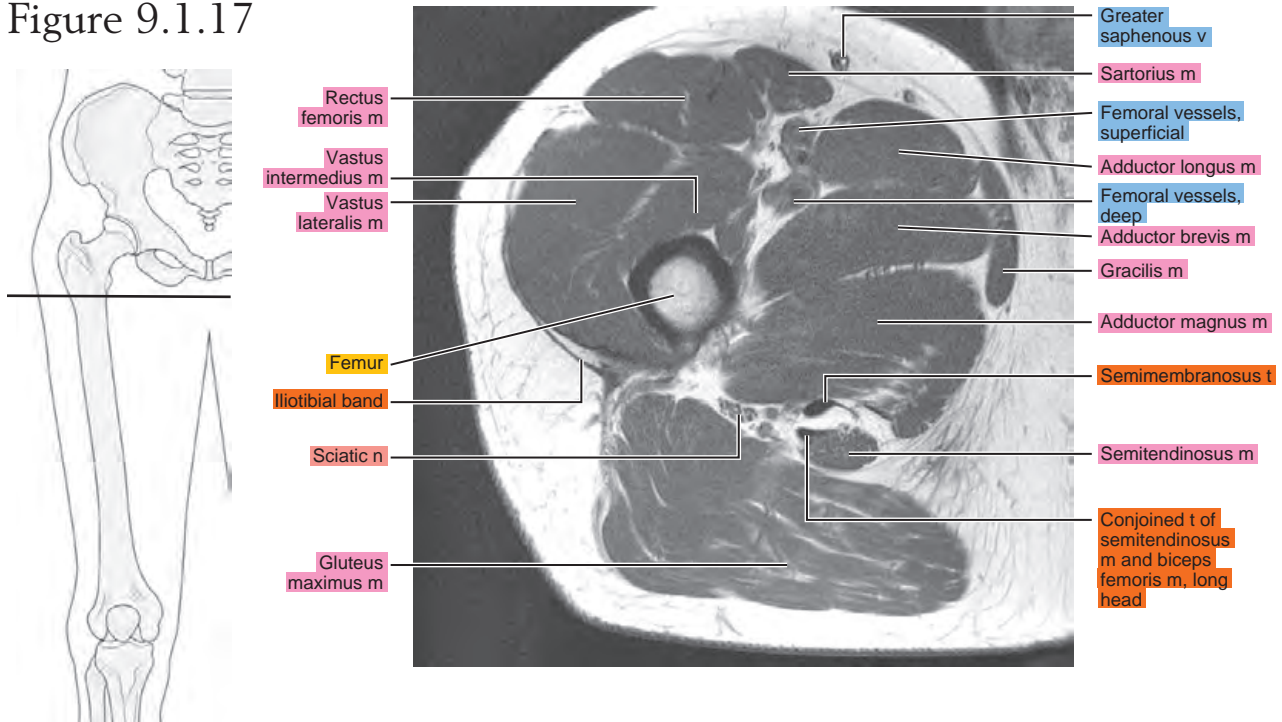
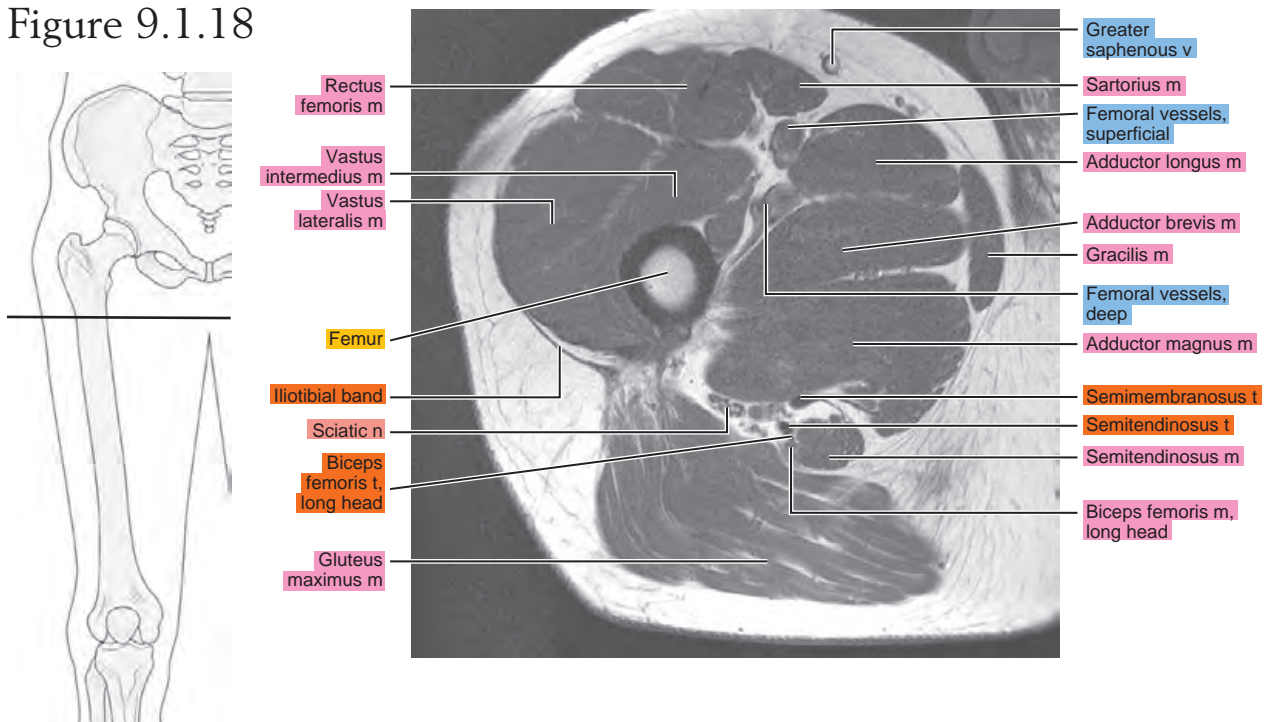


Figure 9.1.18



SAGITTAL

Figure 9.2.1

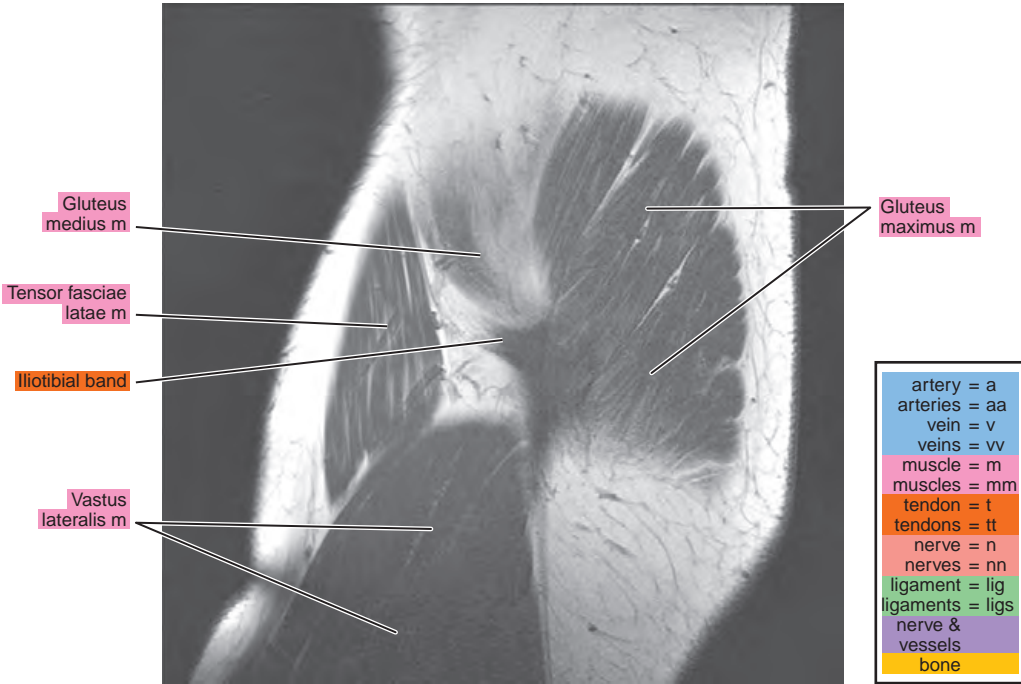


Figure 9.2.2

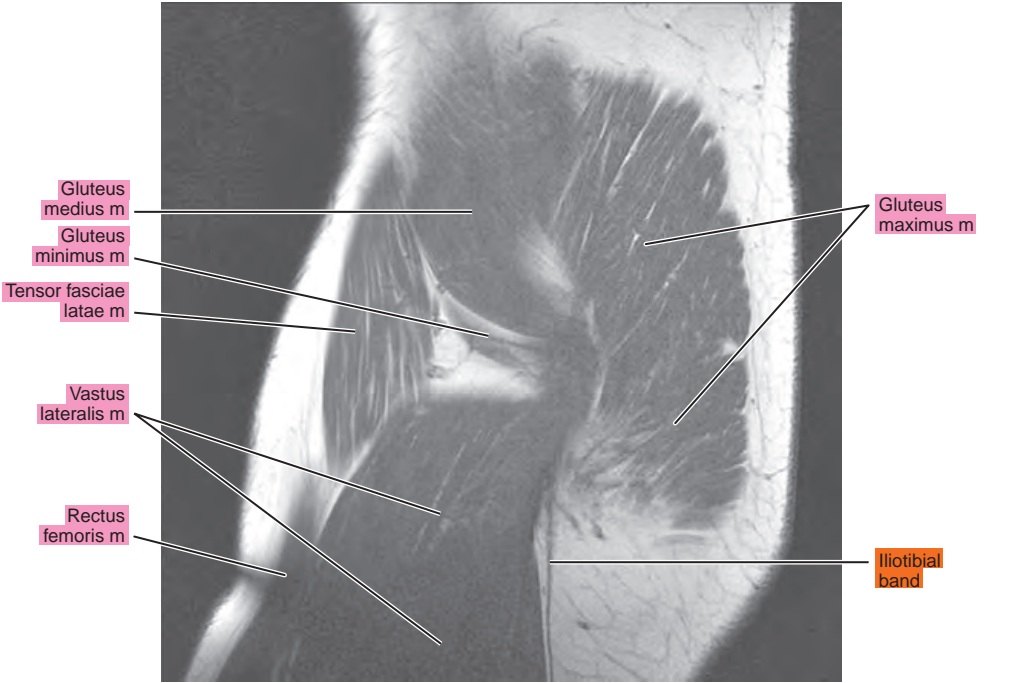


Figure 9.2.3

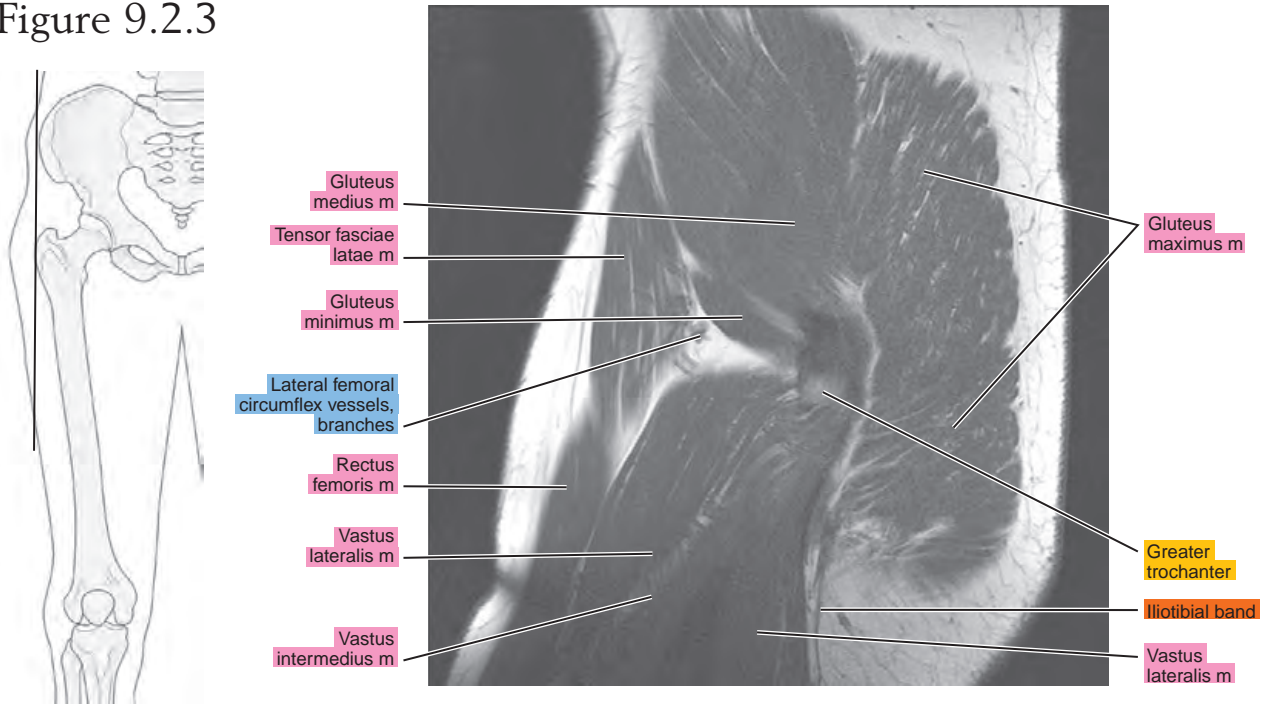


Figure 9.2.4

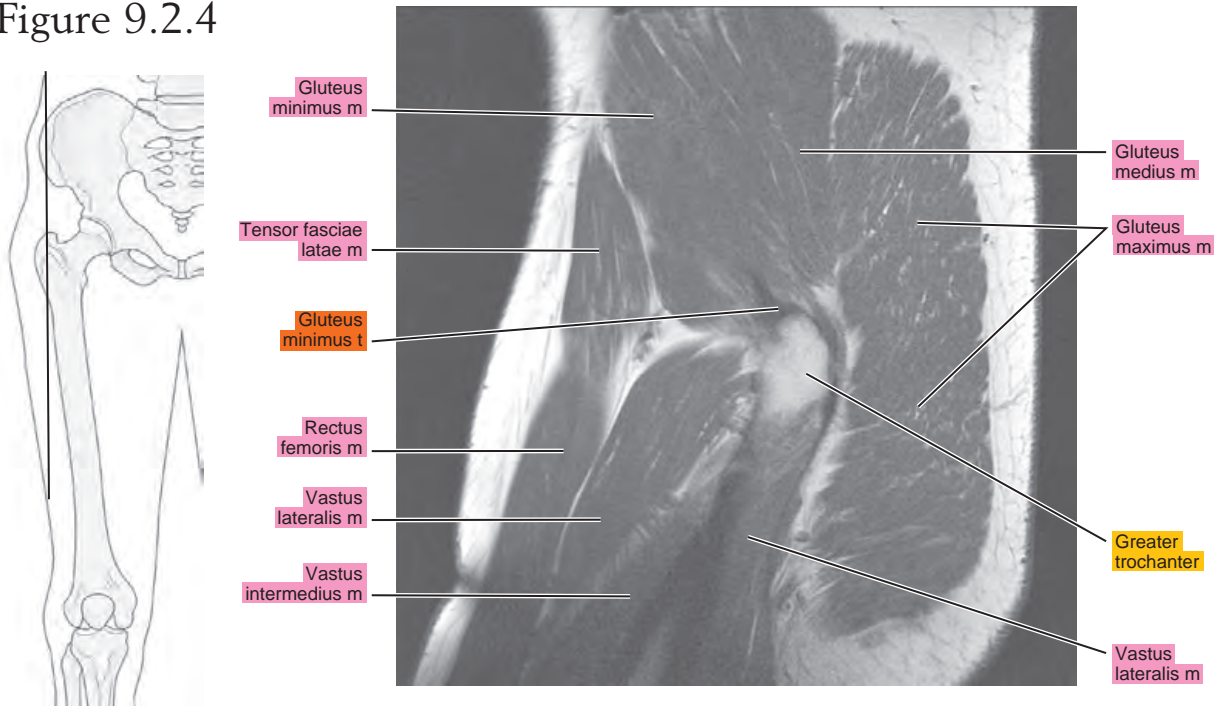


Figure 9.2.5

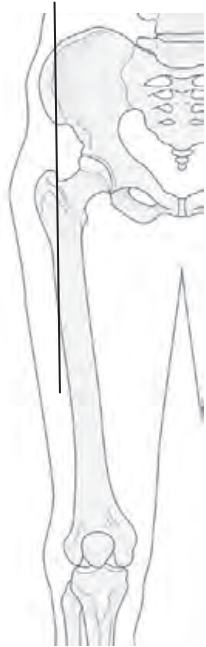


Figure 9.2.6

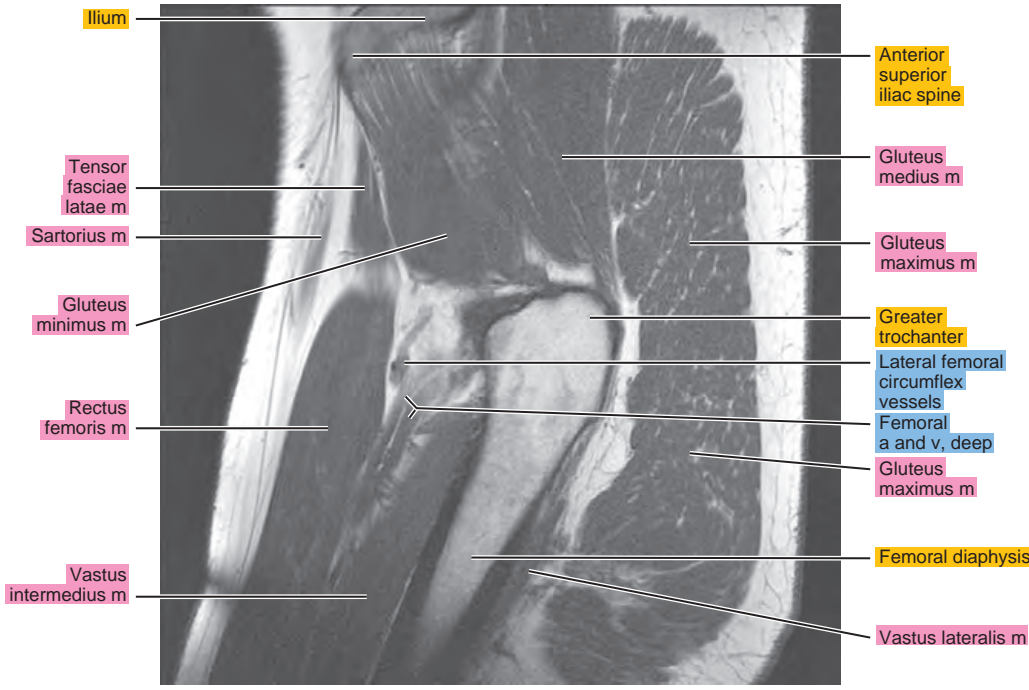


Figure 9.2.7

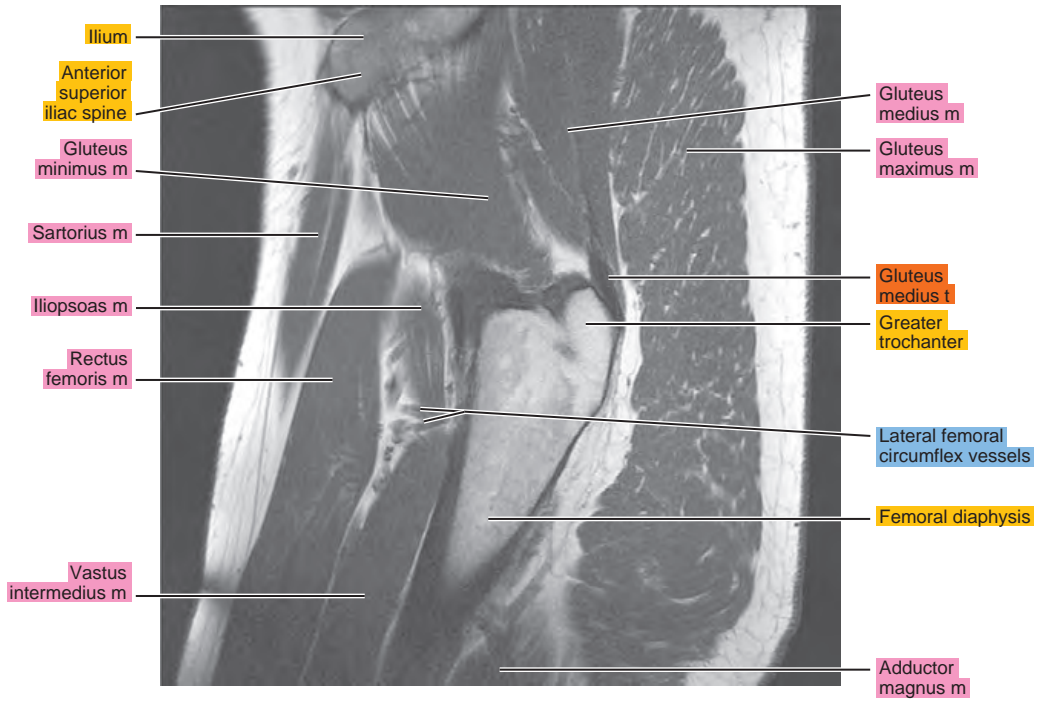


Figure 9.2.8




Figure 9.2.9

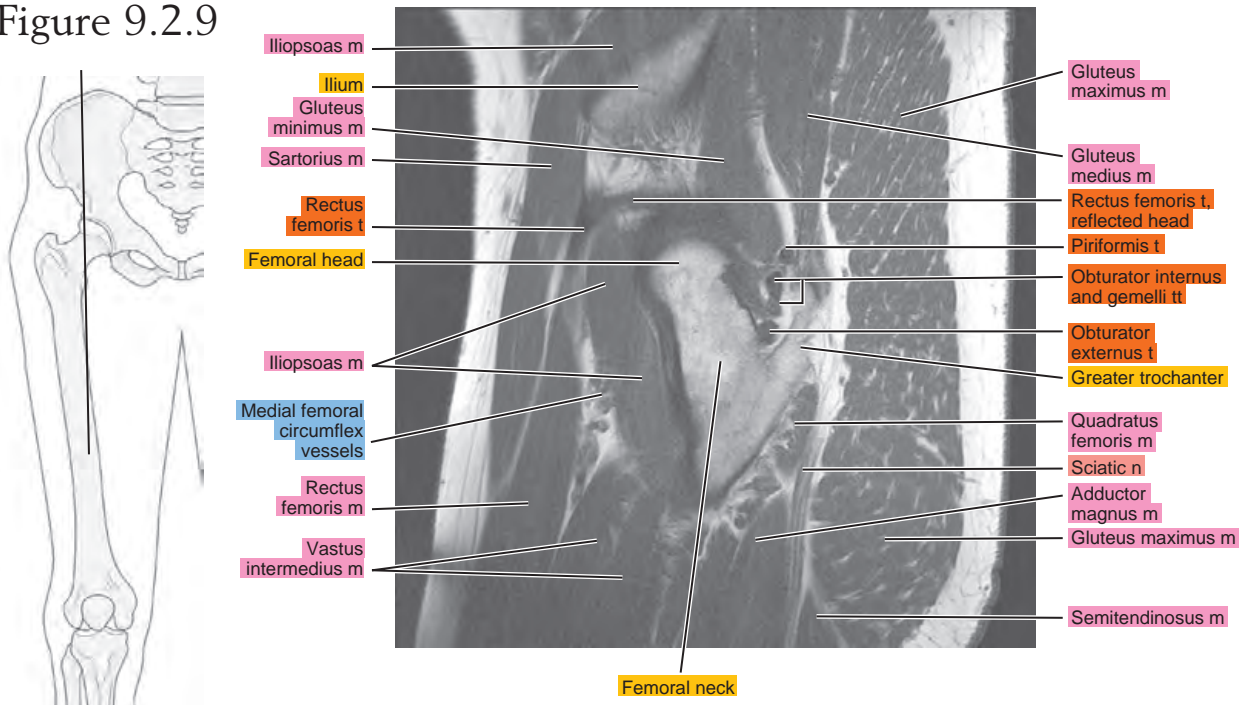


Figure 9.2.10

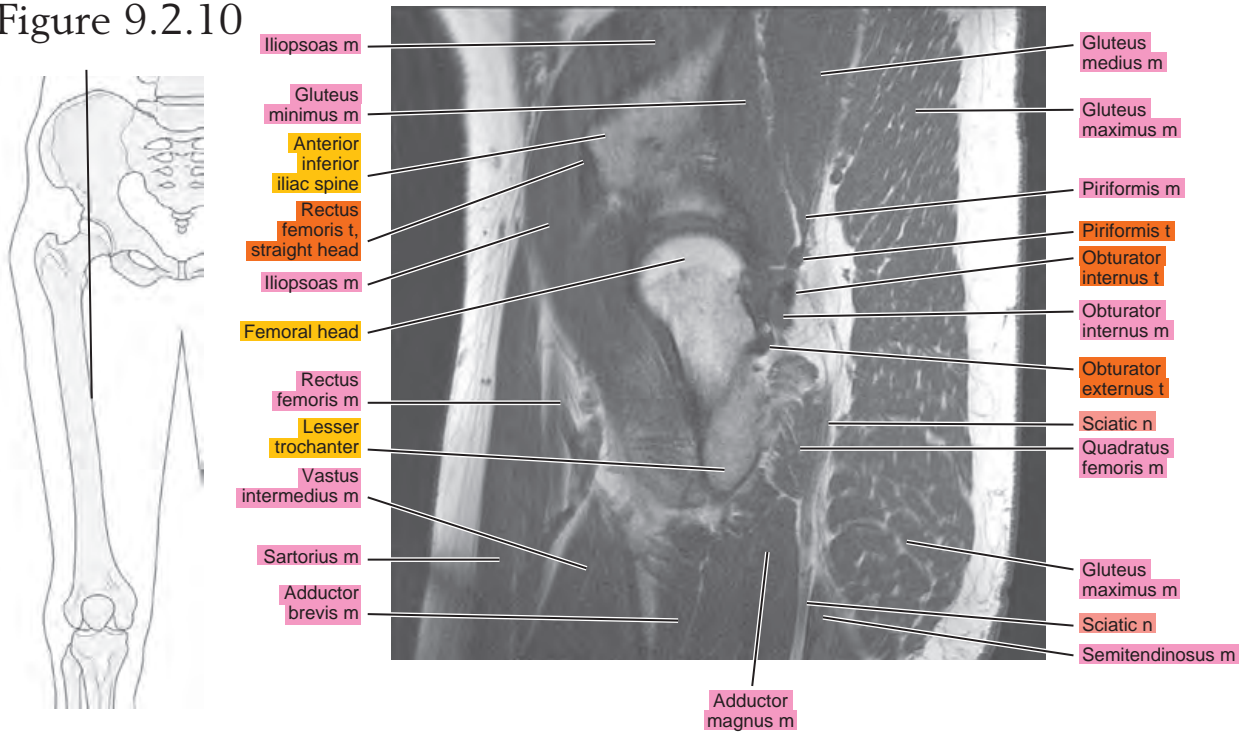


Figure 9.2.11

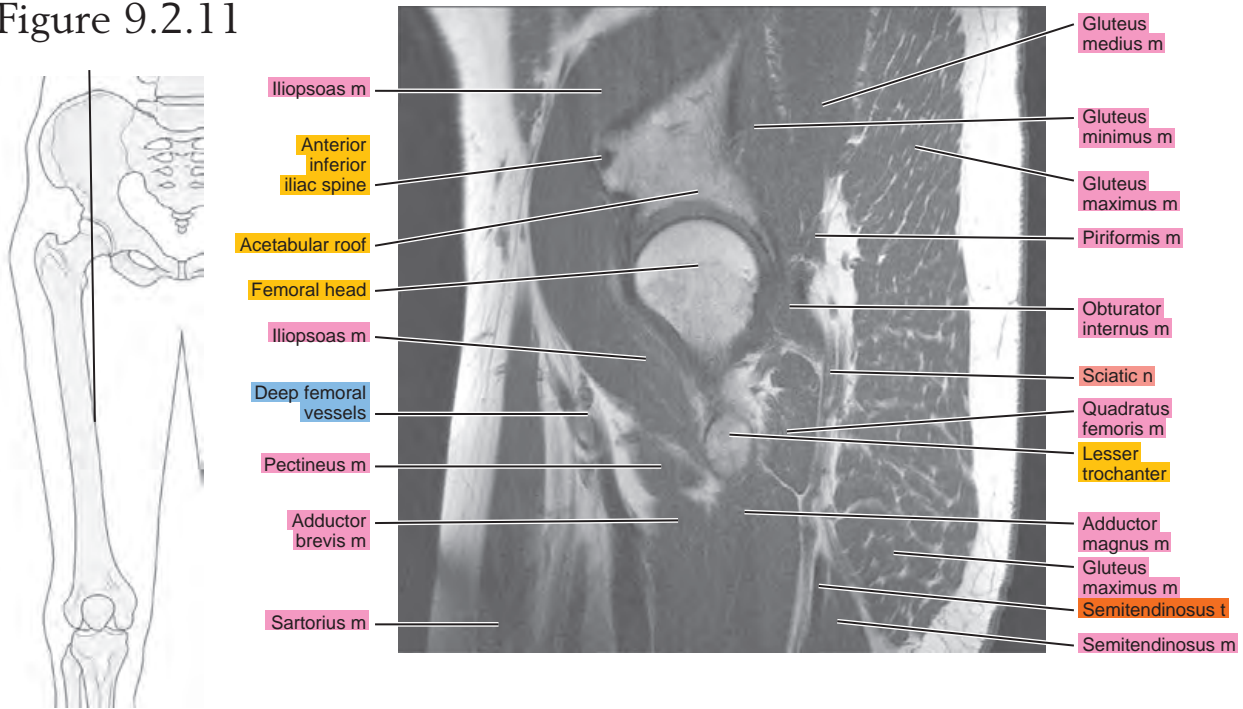

Figure 9.2.12

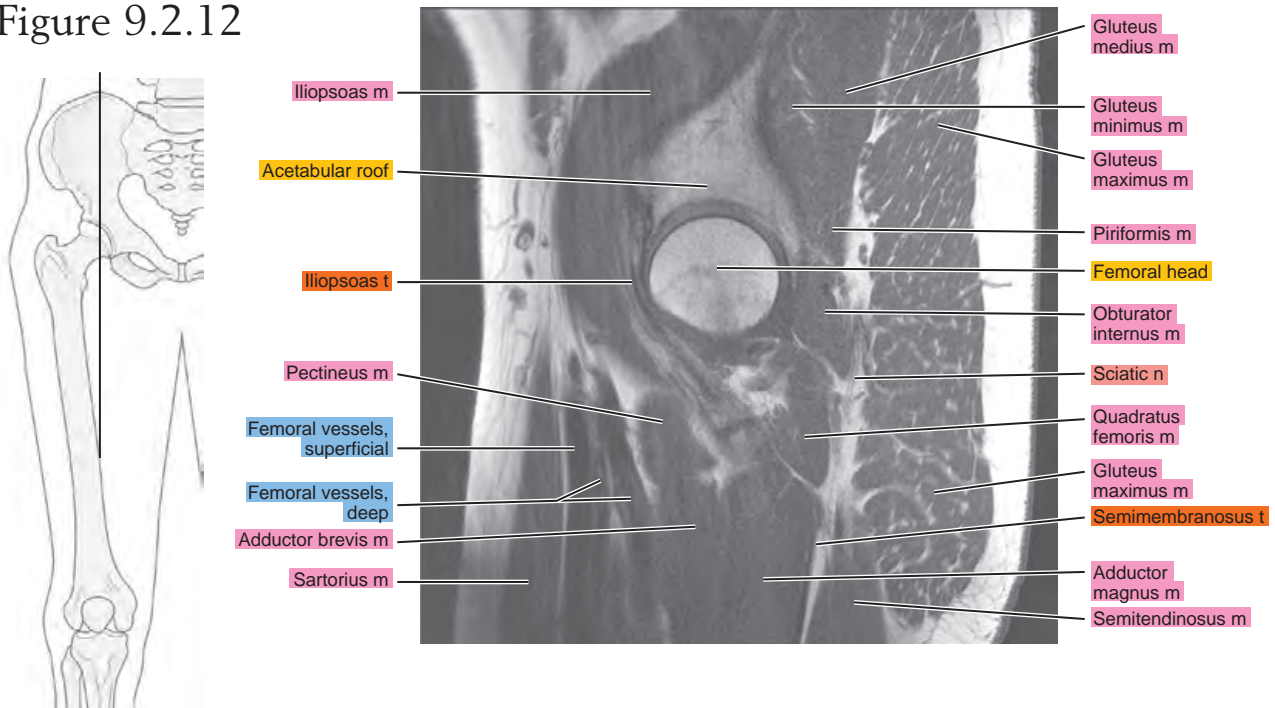


Figure 9.2.13

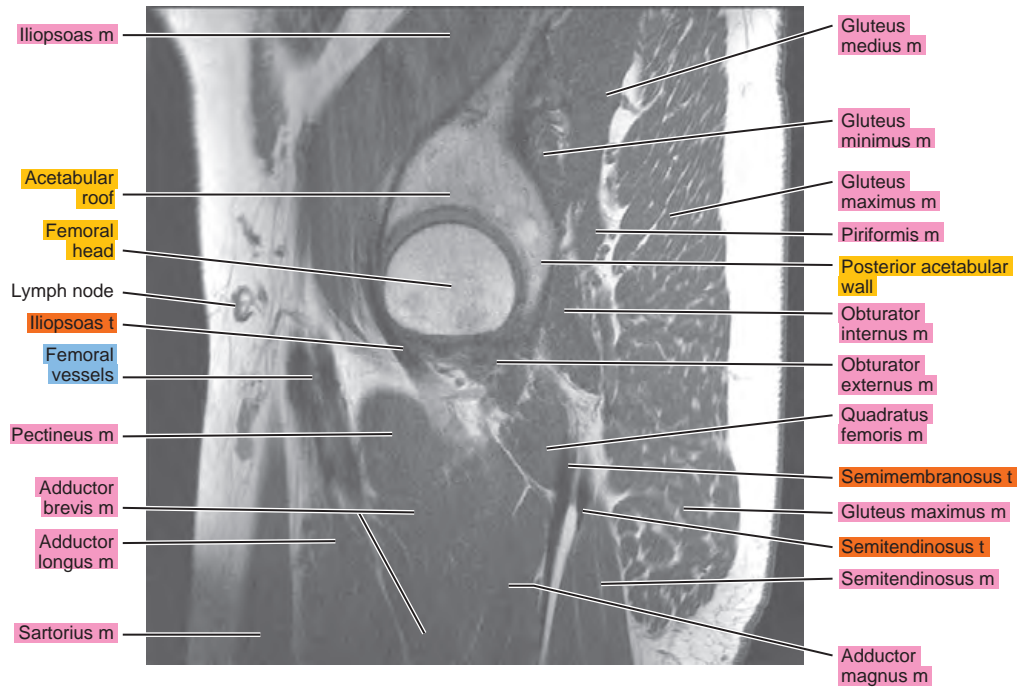
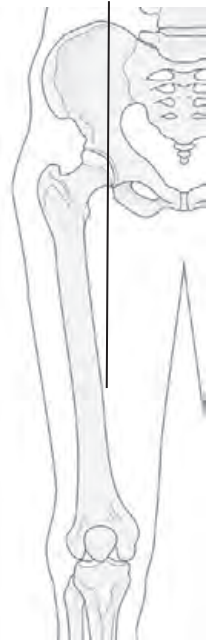

Figure 9.2.14

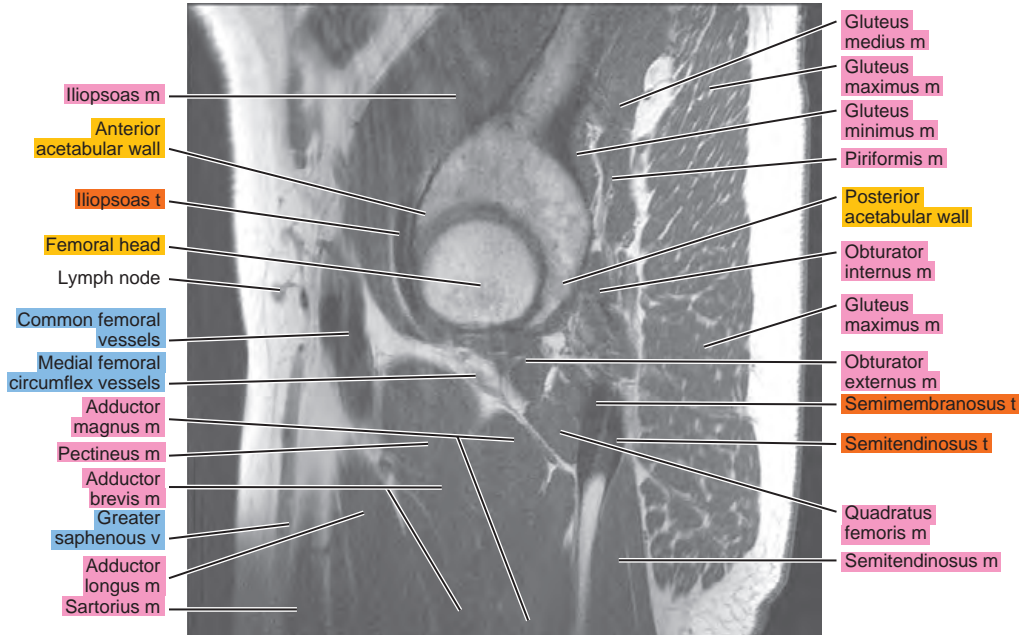
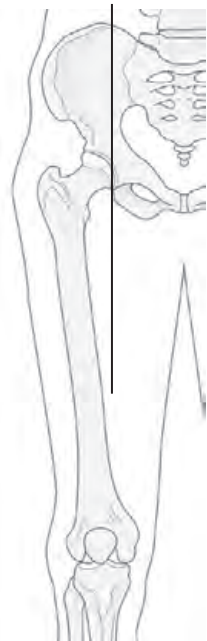

Figure 9.2.15

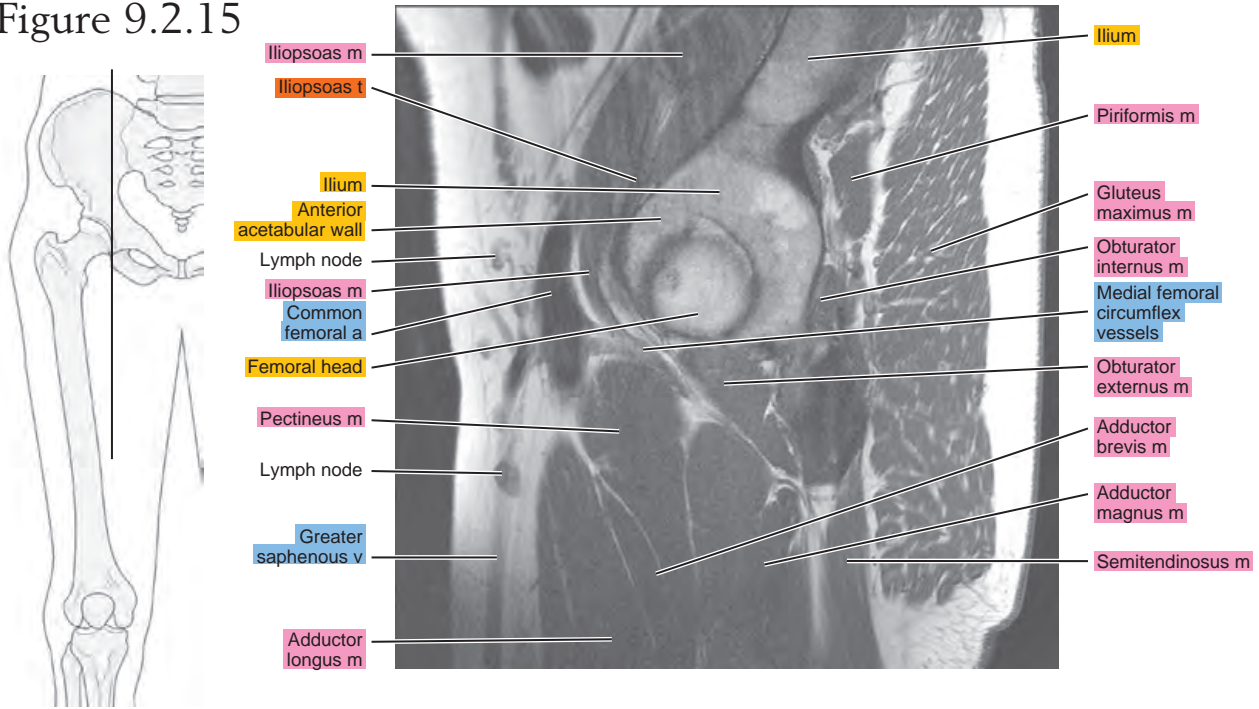


Figure 9.2.16

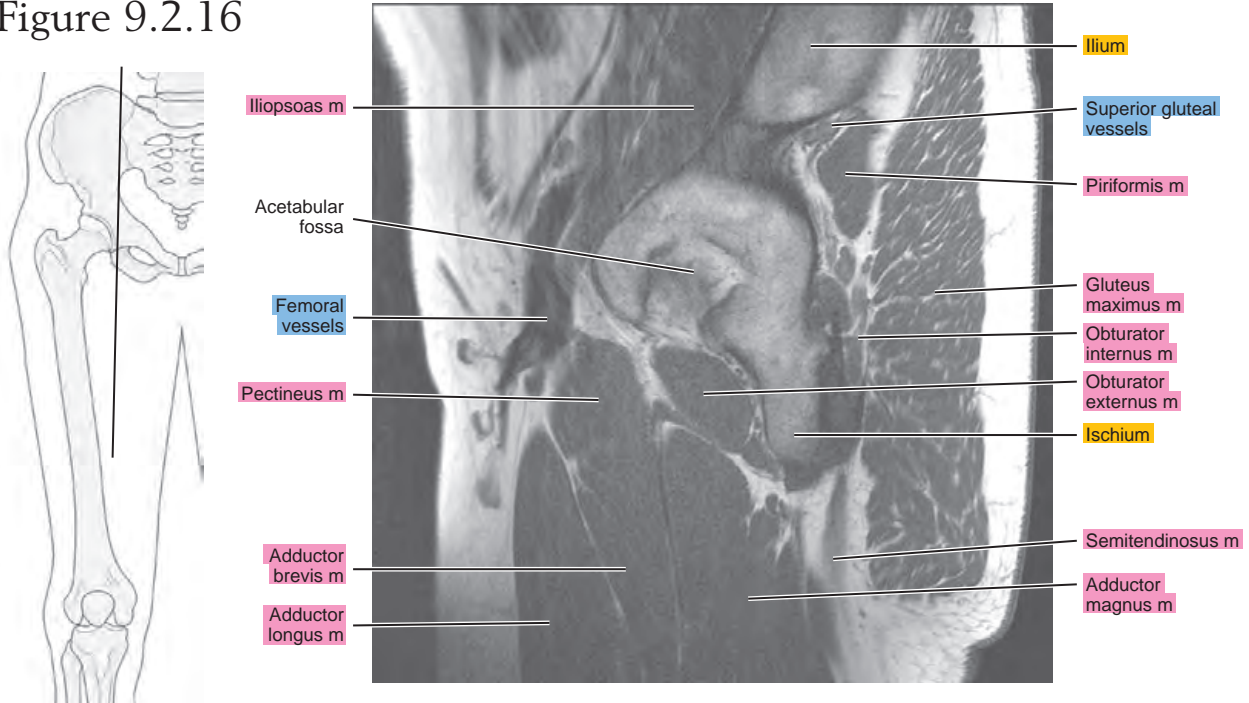


Figure 9.2.17

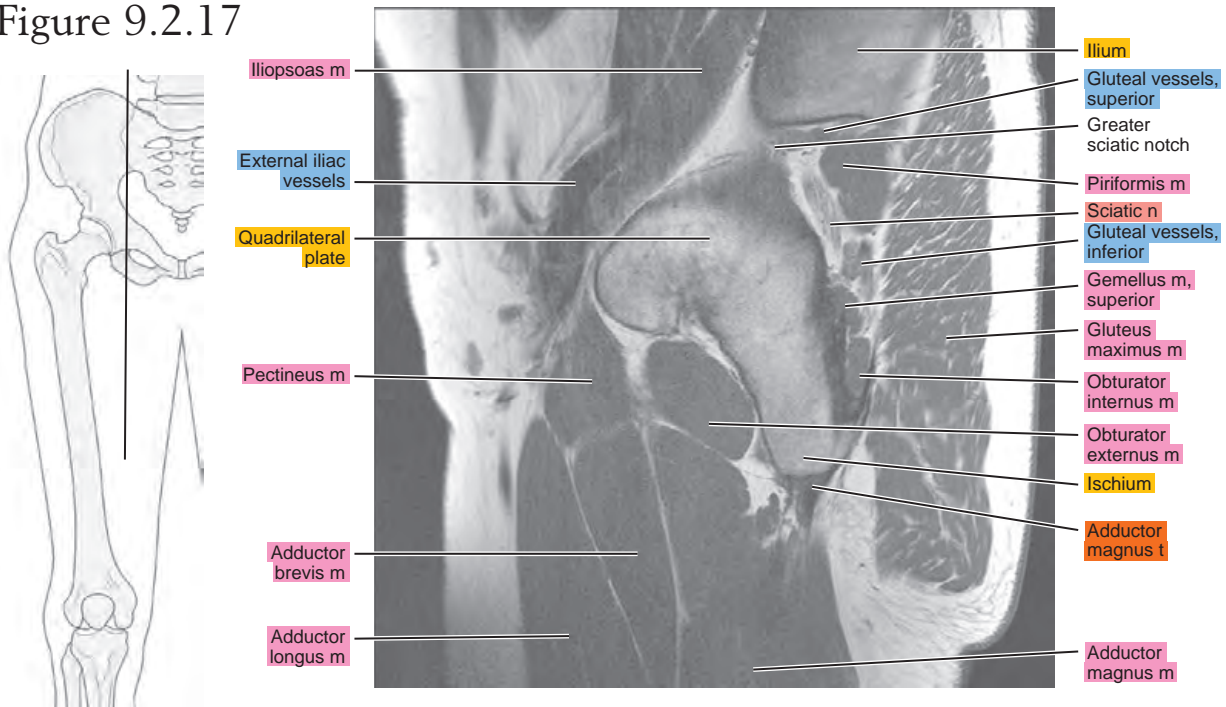


Figure 9.2.18

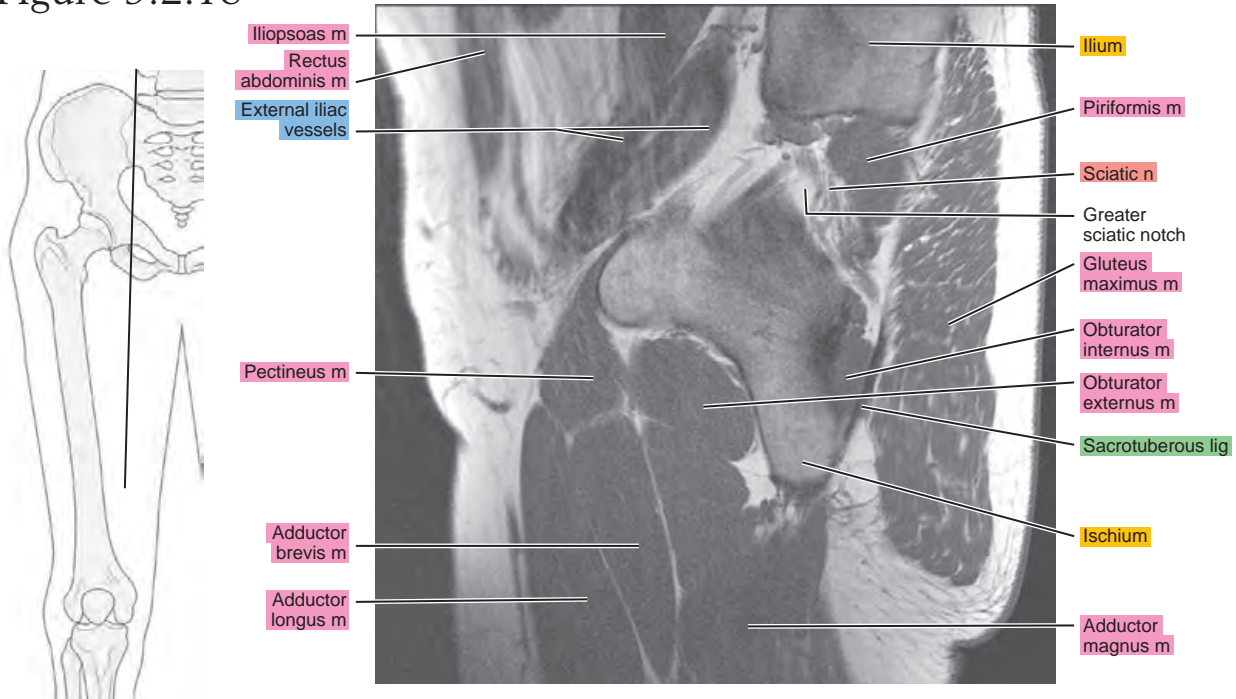
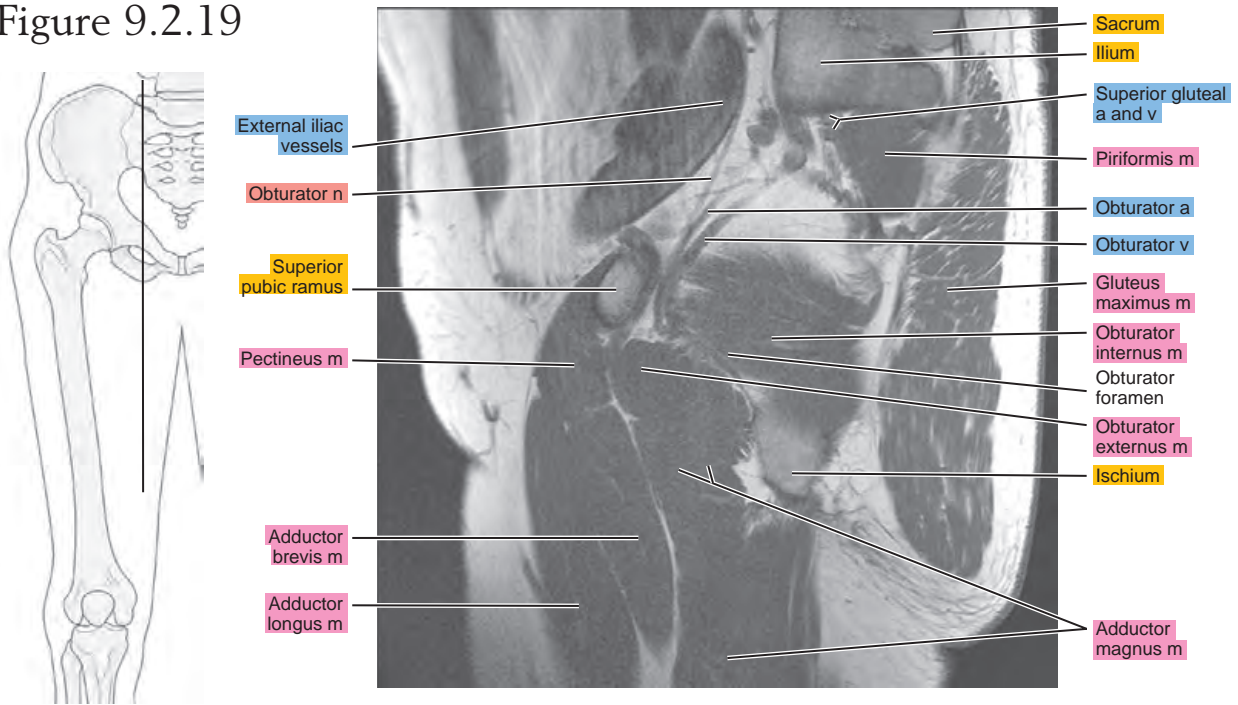


Figure 9.2.19



CORONAL

Figure 9.3.1

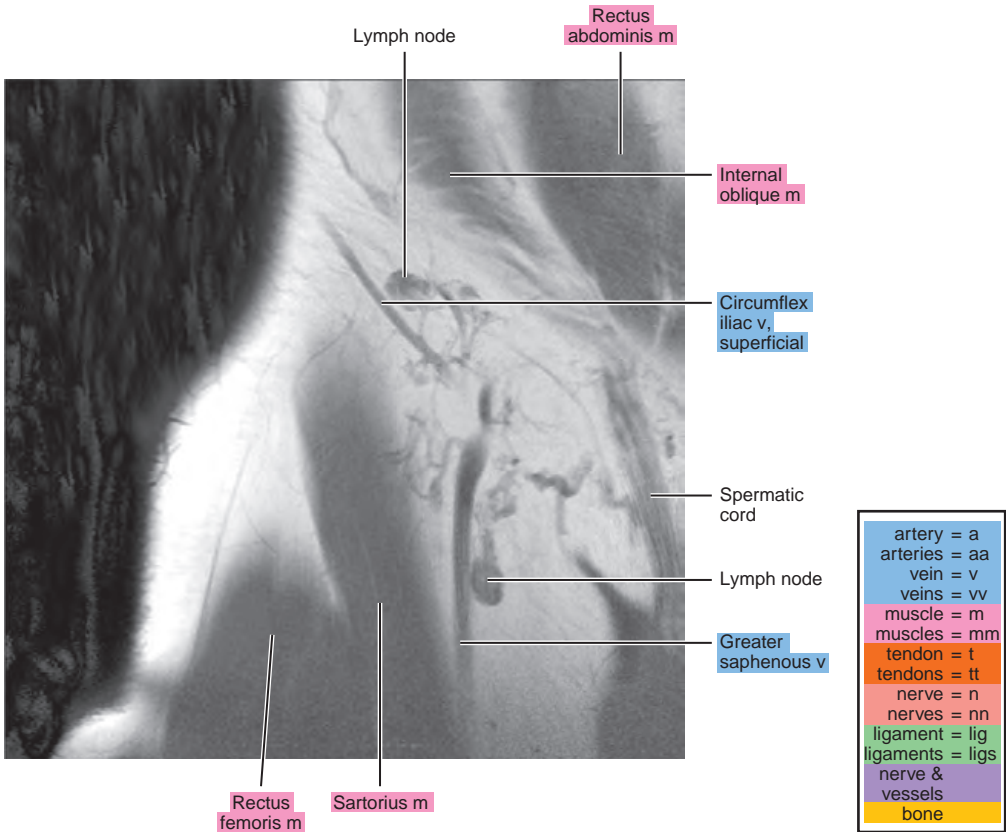
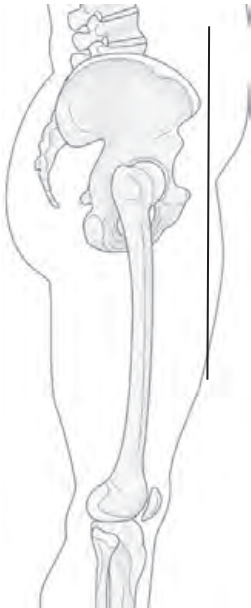

Figure 9.3.2

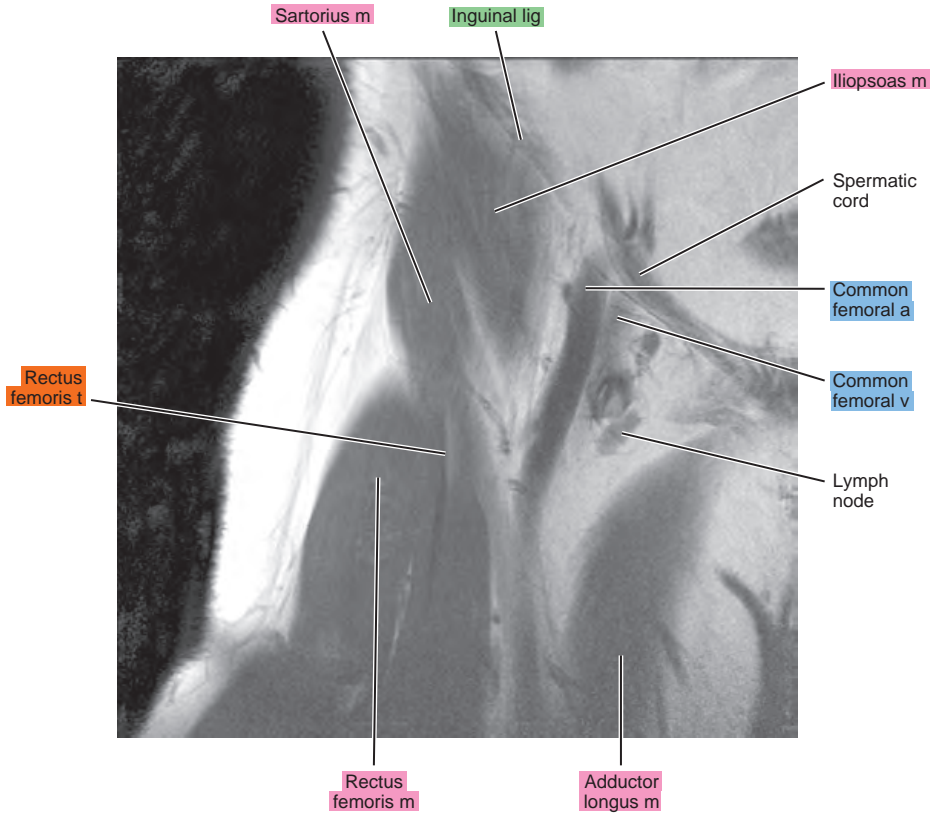
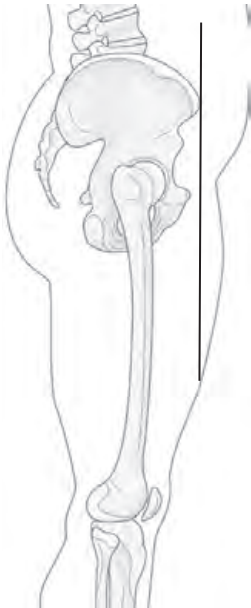


Figure 9.3.3

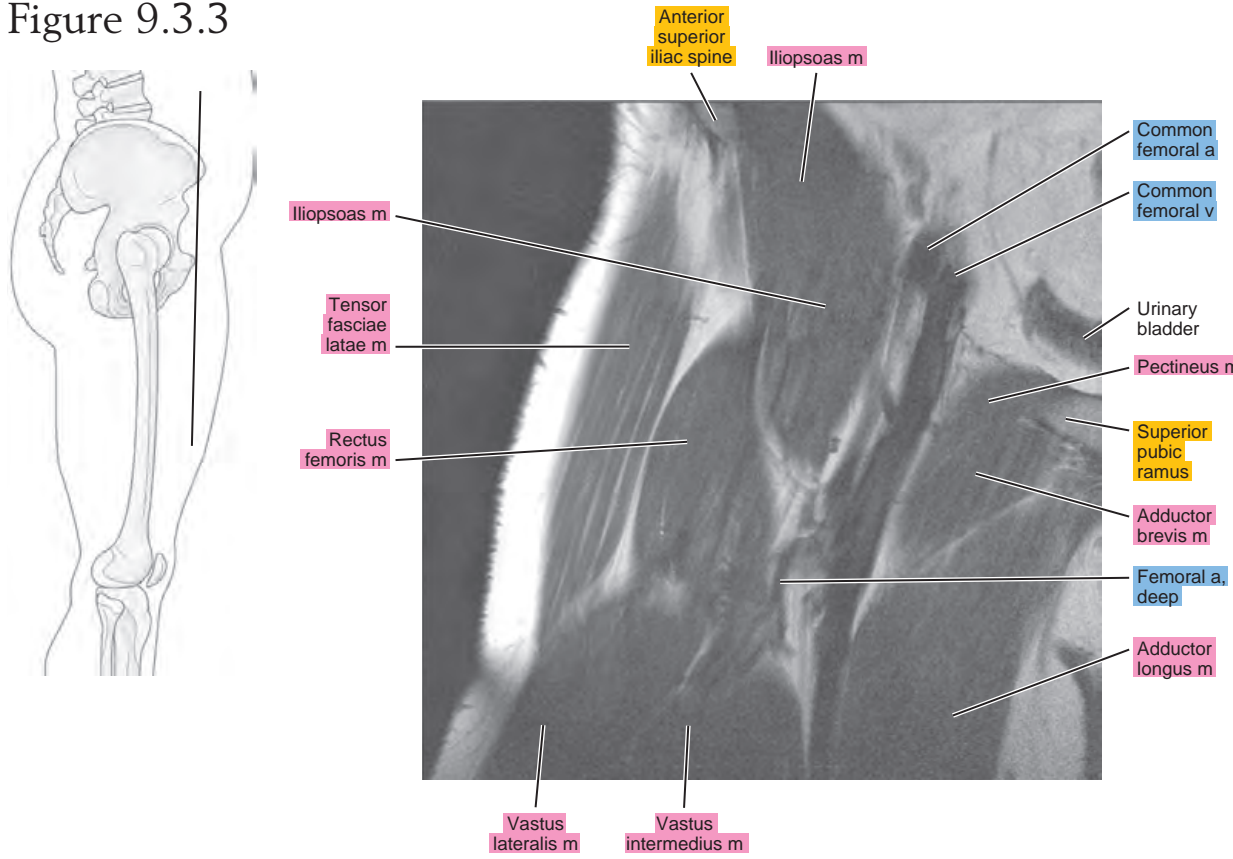


Figure 9.3.4

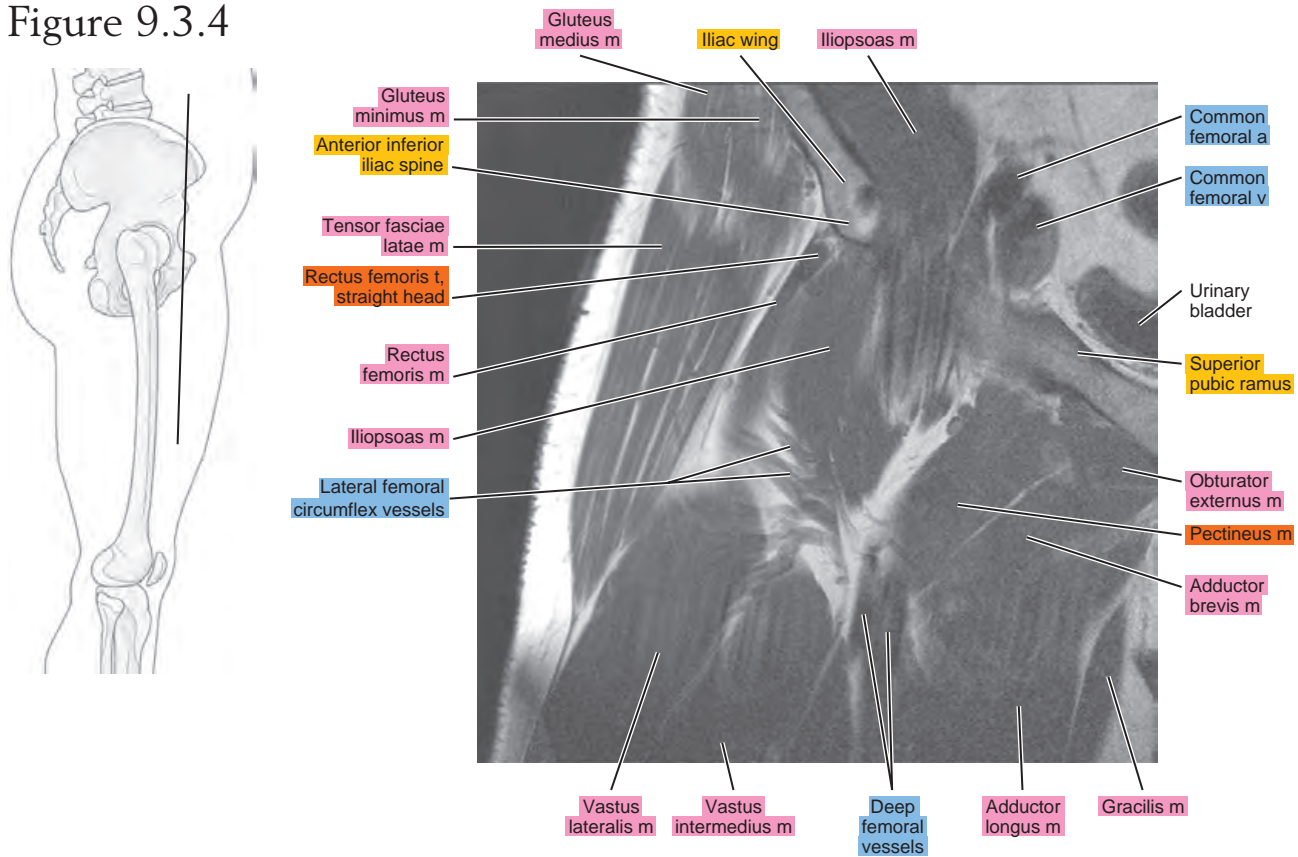


Figure 9.3.5

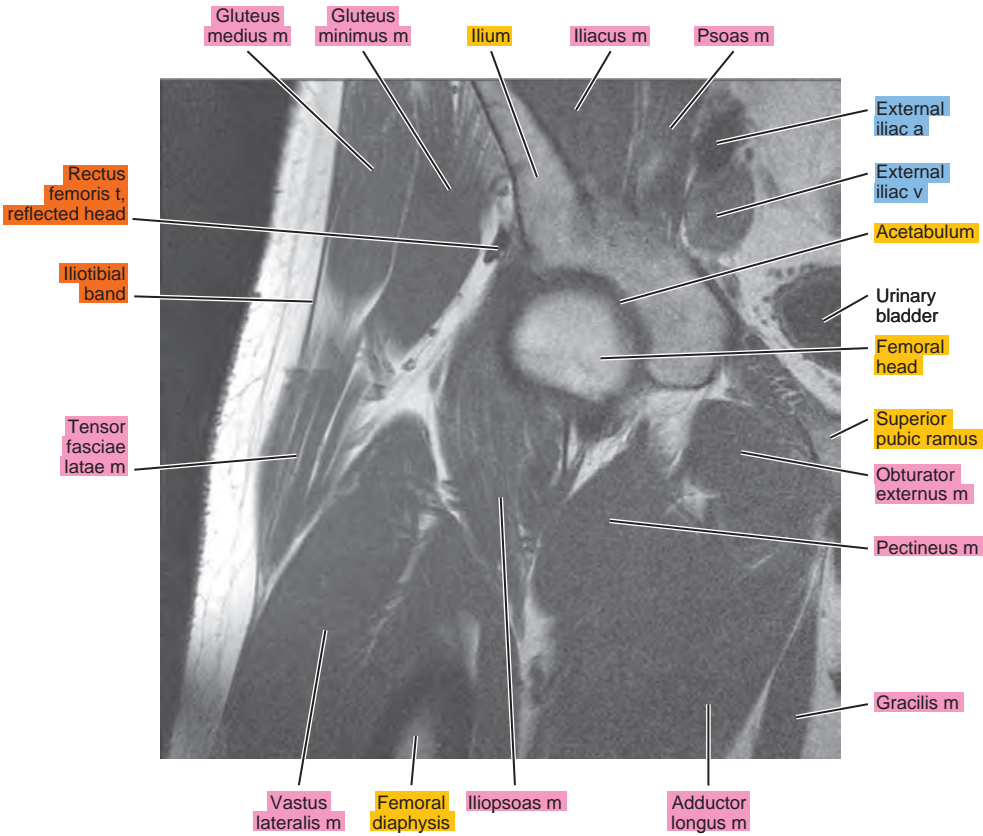
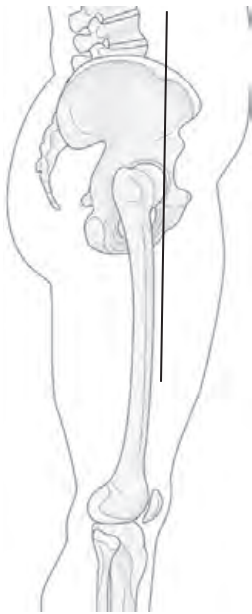


Figure 9.3.6

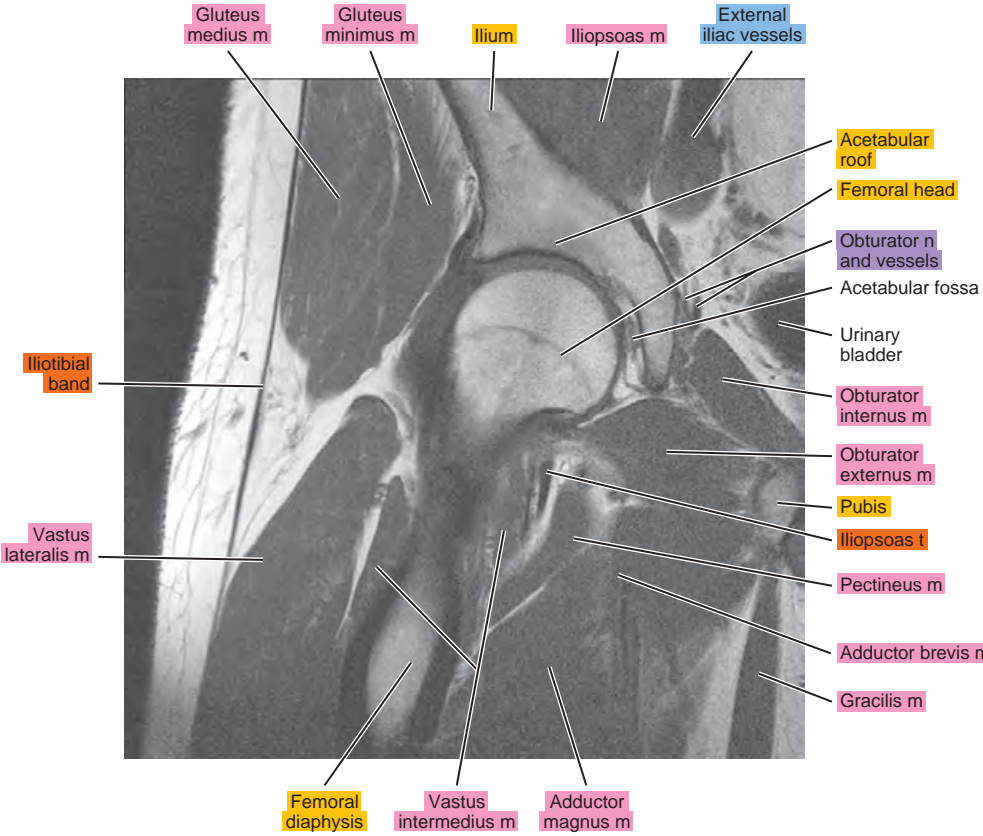
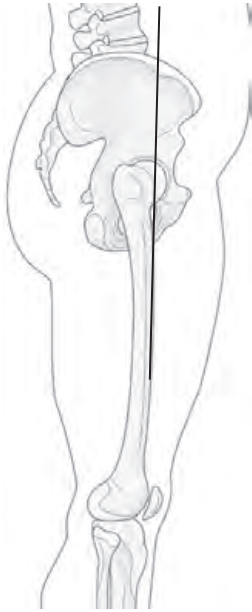


Figure 9.3.7

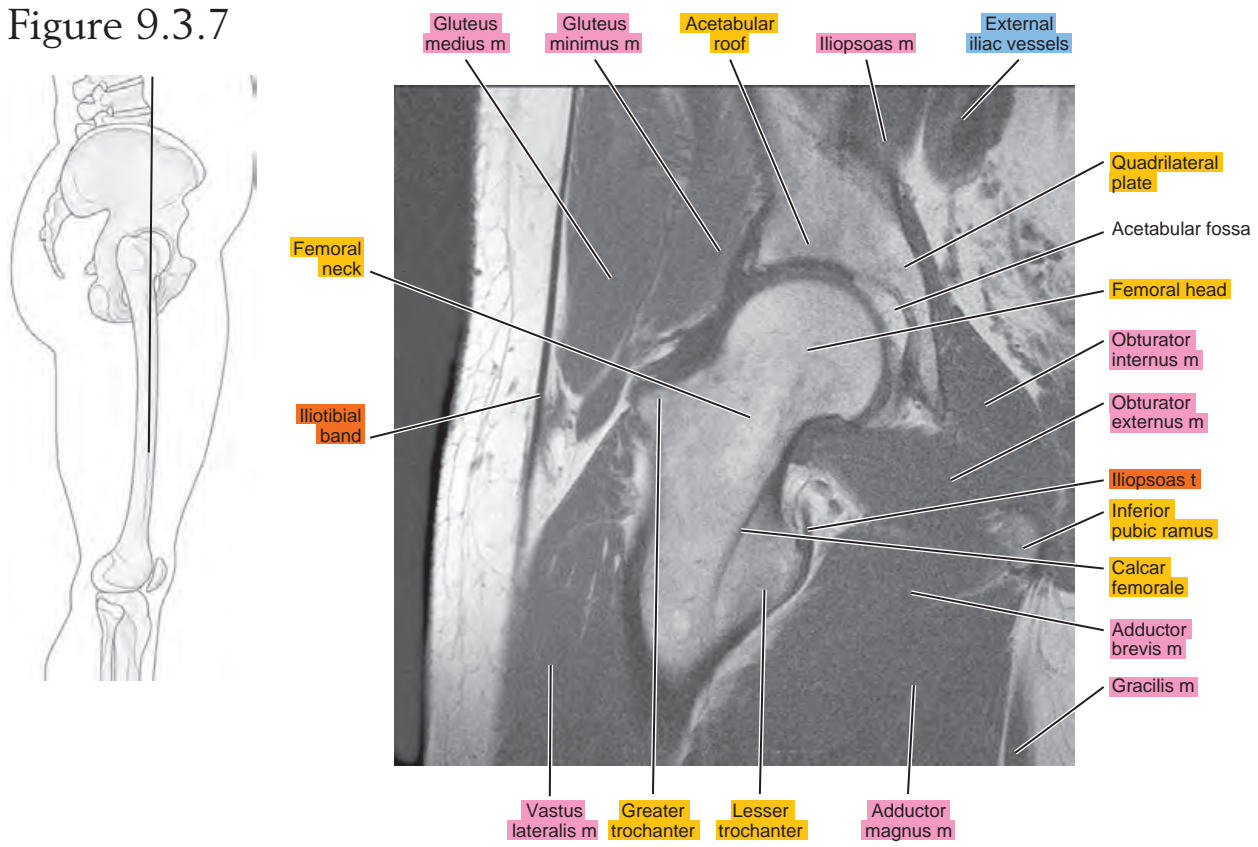


Figure 9.3.8

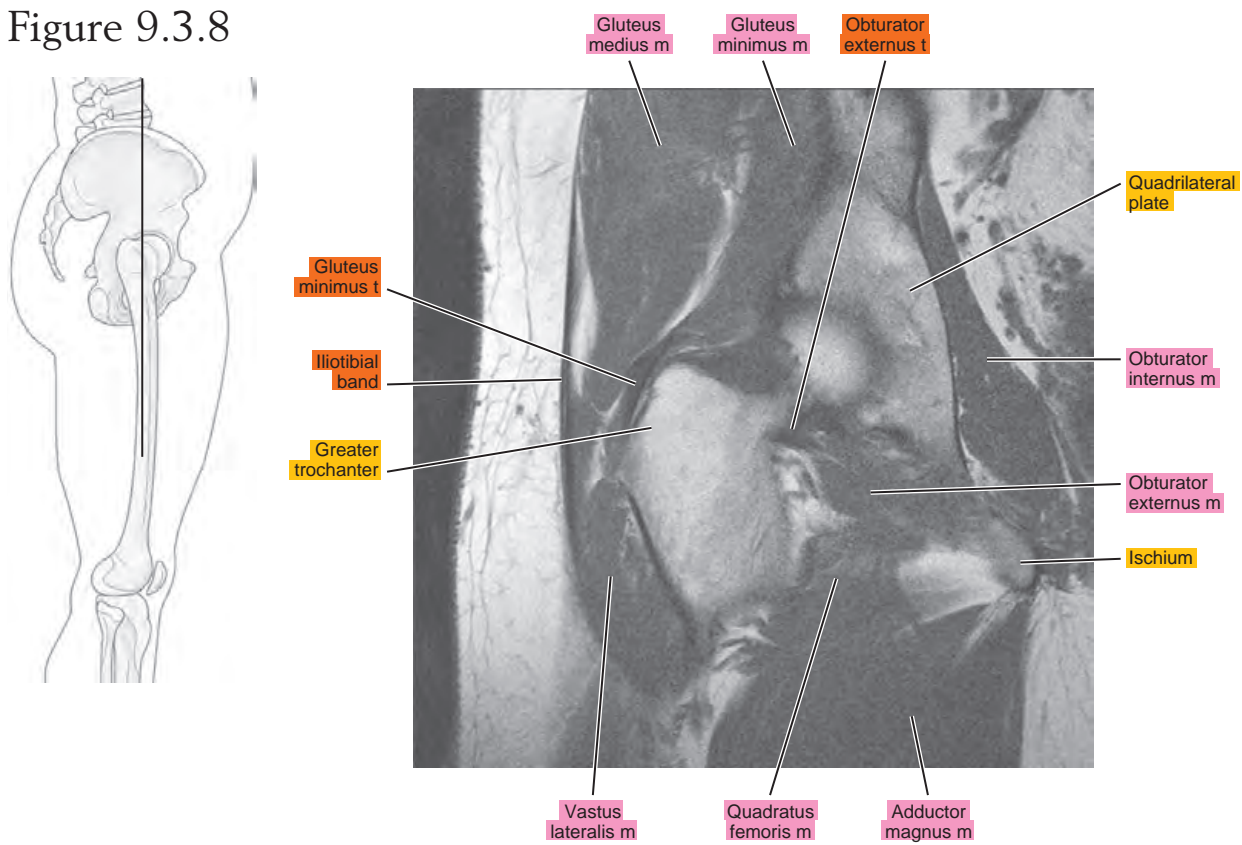


Figure 9.3.9

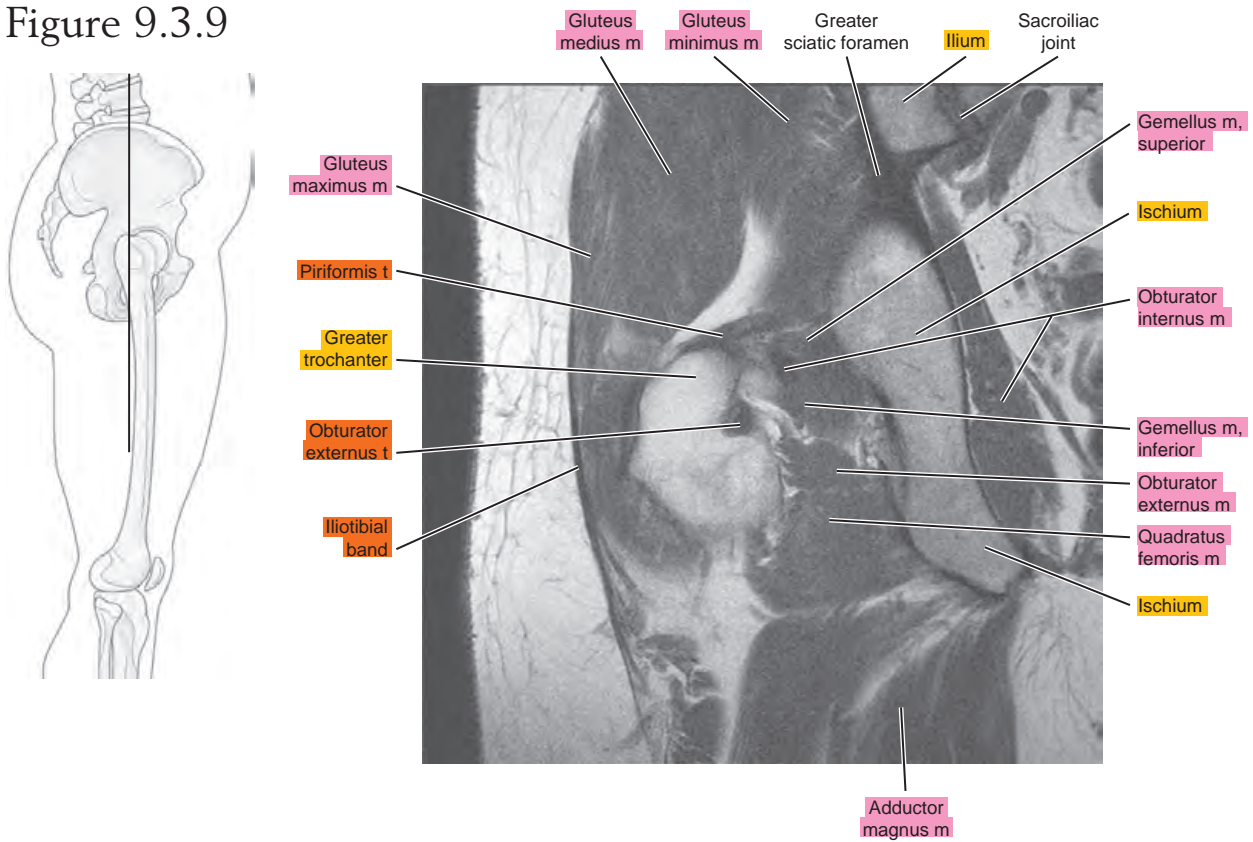


Figure 9.3.10




Figure 9.3.11

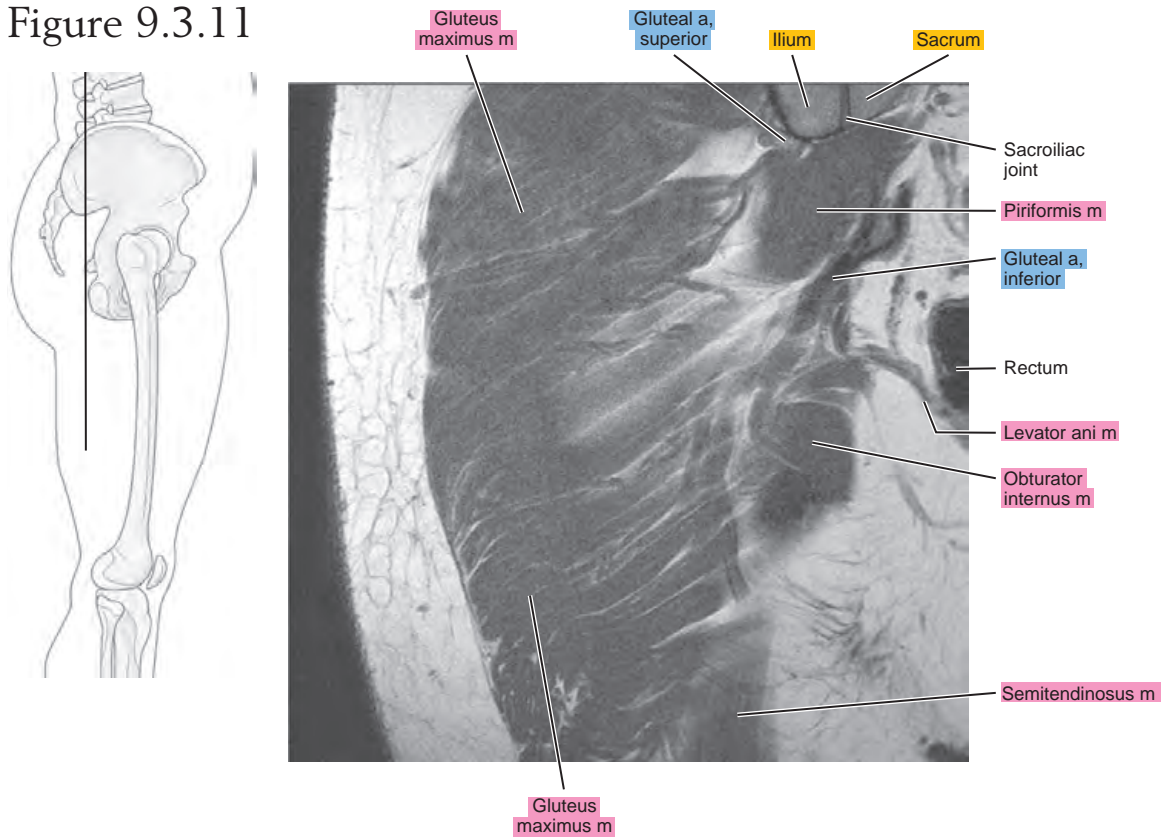


Figure 9.3.12

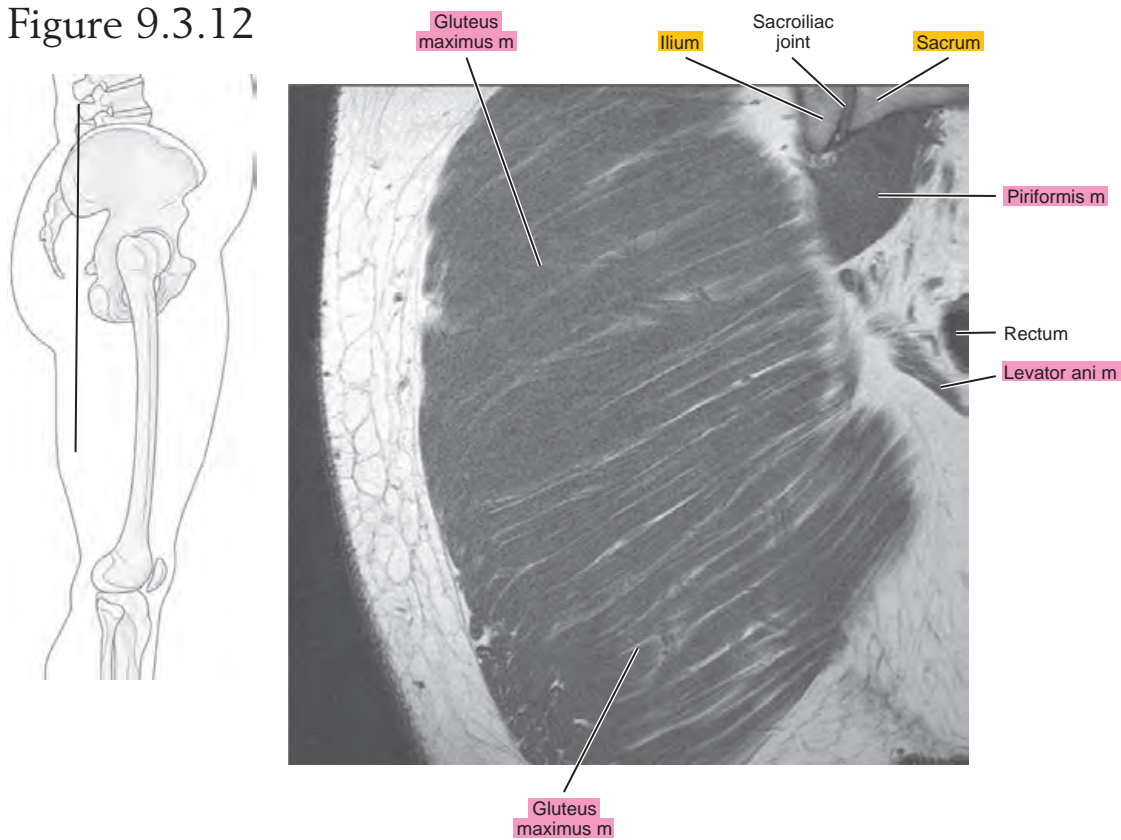
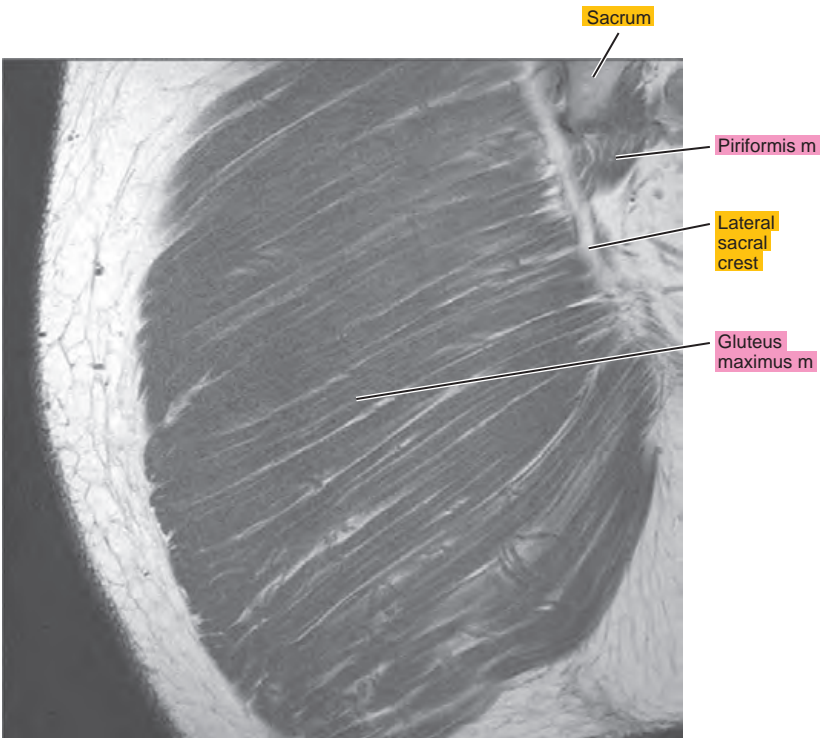
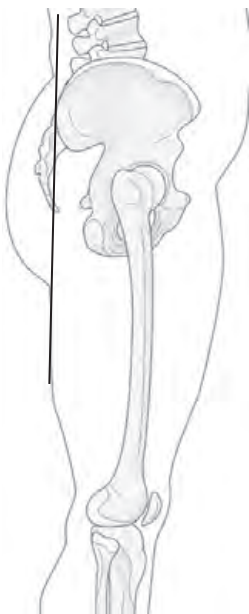


Figure 9.3.13



Chapter
10

MR Arthrography of the Hip

AXIAL

Figure 10.1.1

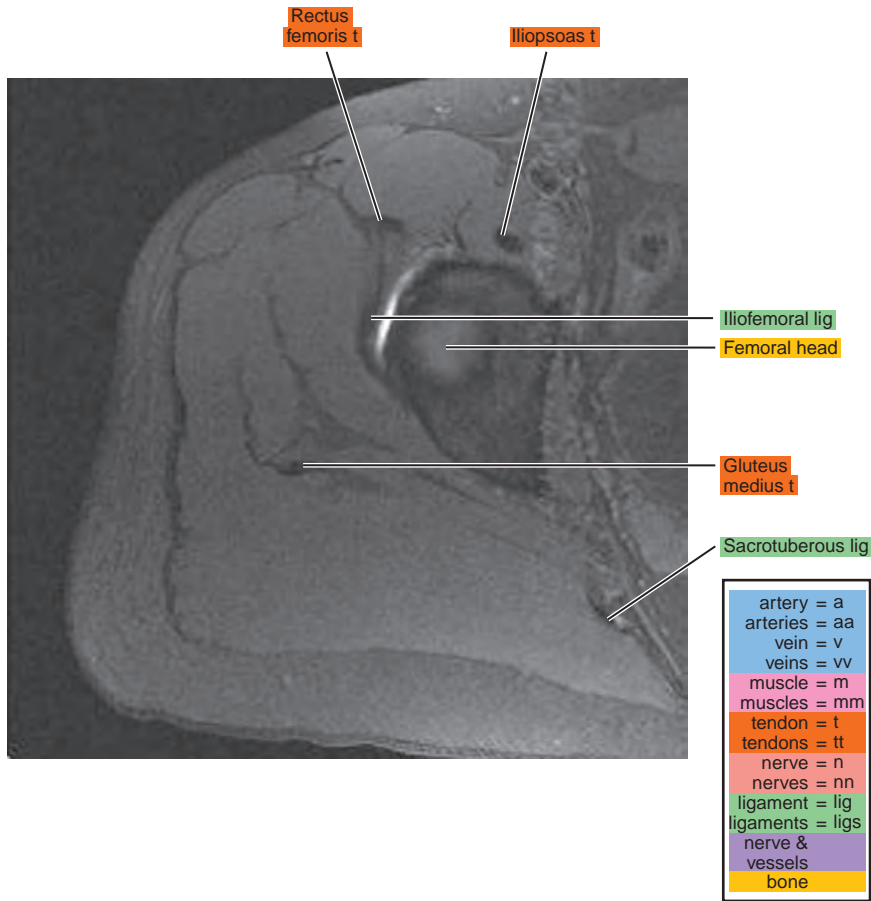
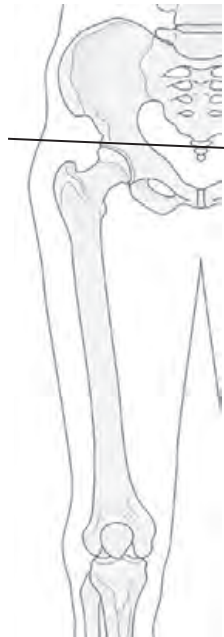

Figure 10.1.2

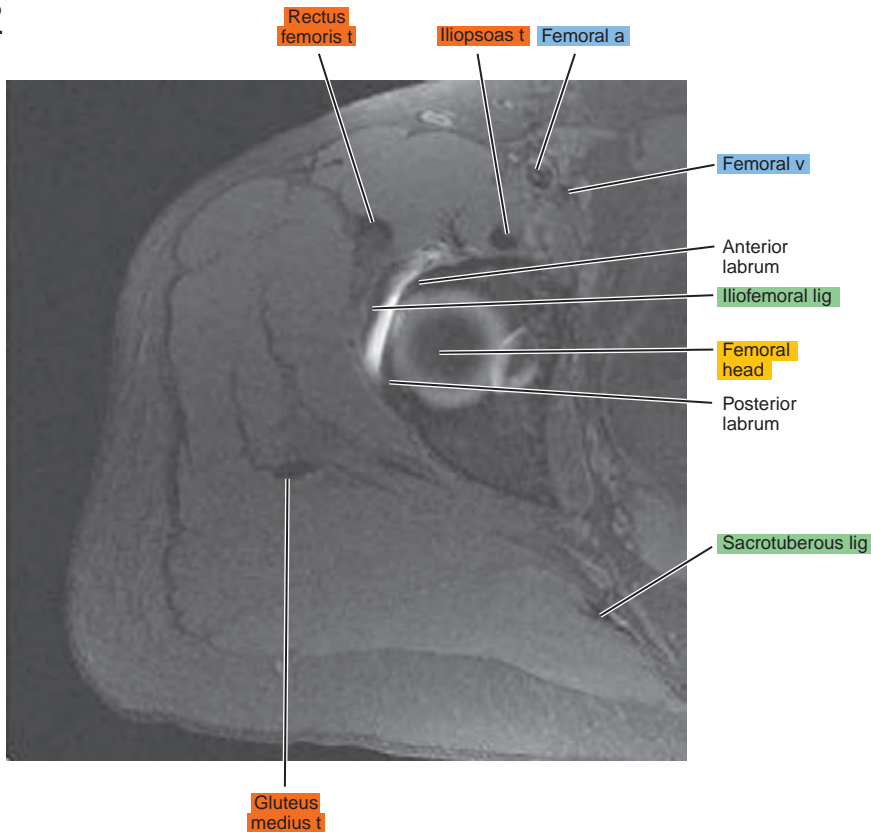
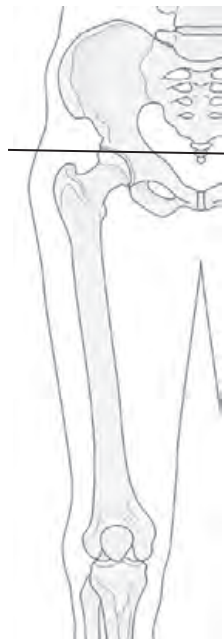

Figure 10.1.3

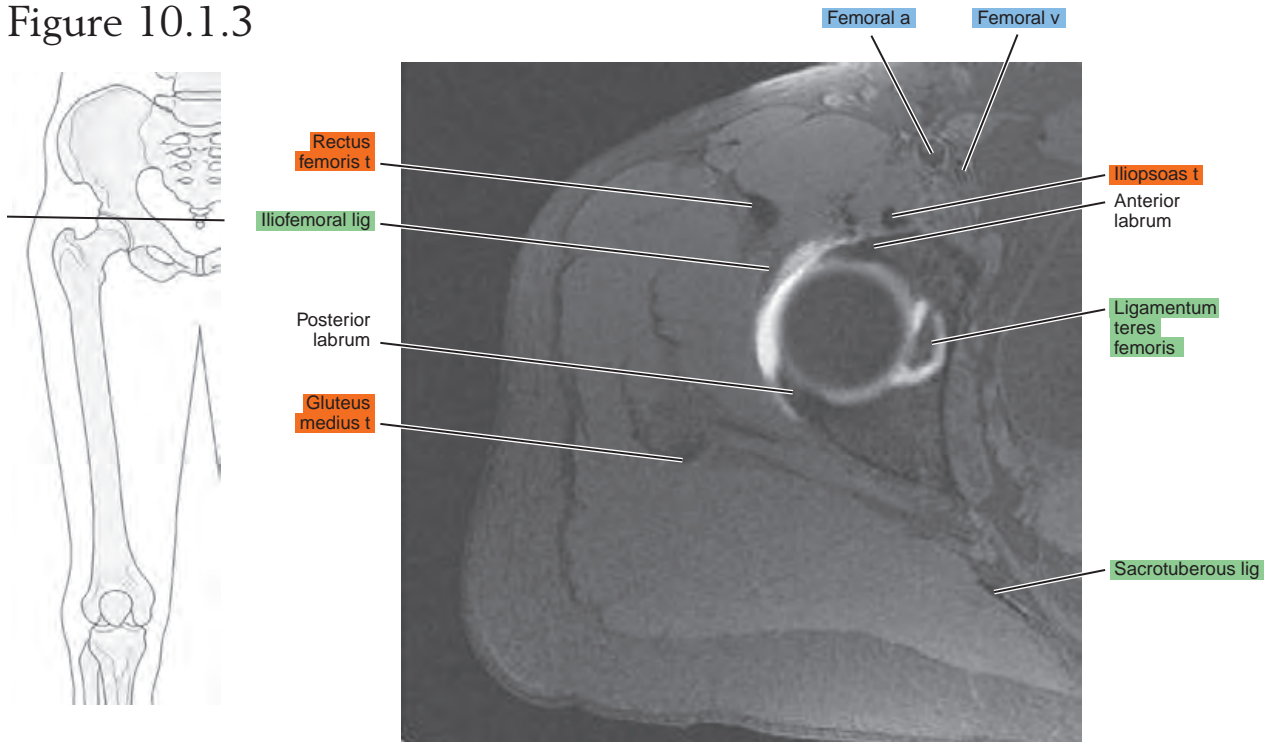


Figure 10.1.4

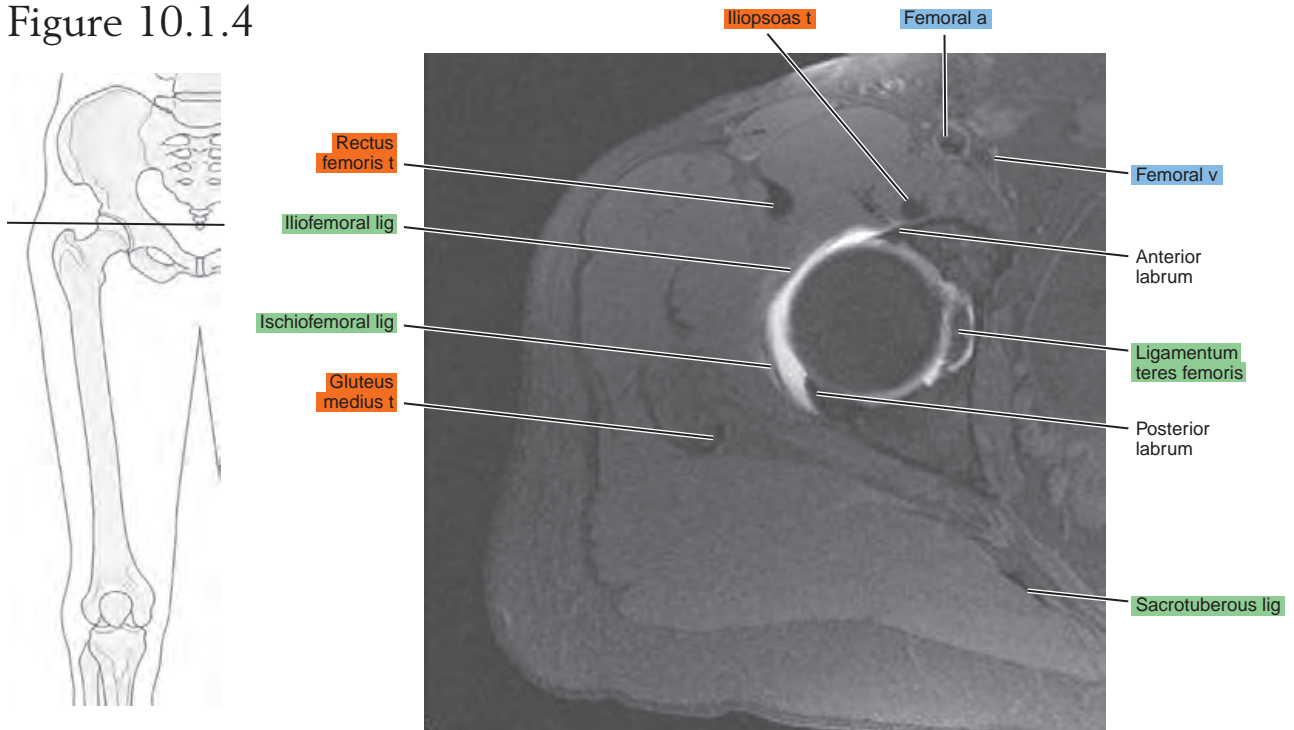


Figure 10.1.5

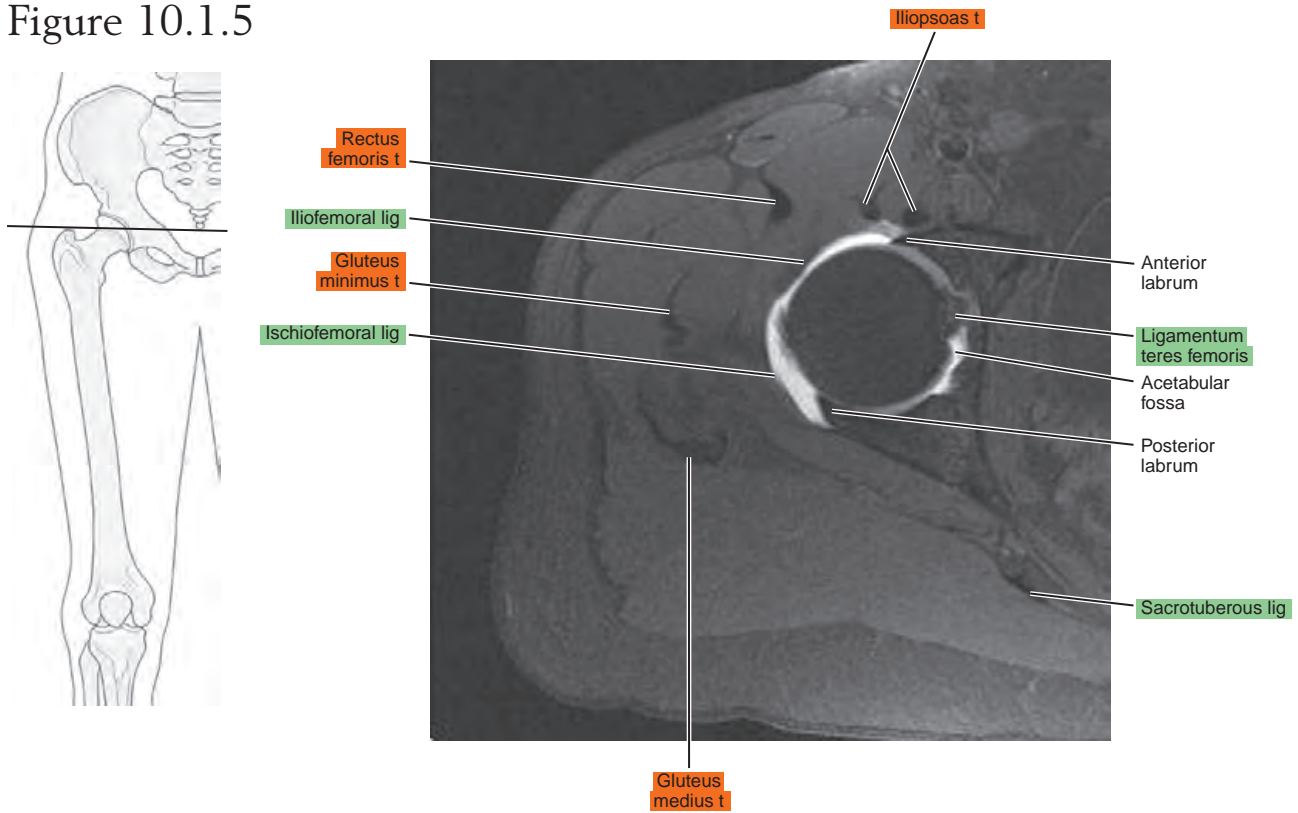


Figure 10.1.6

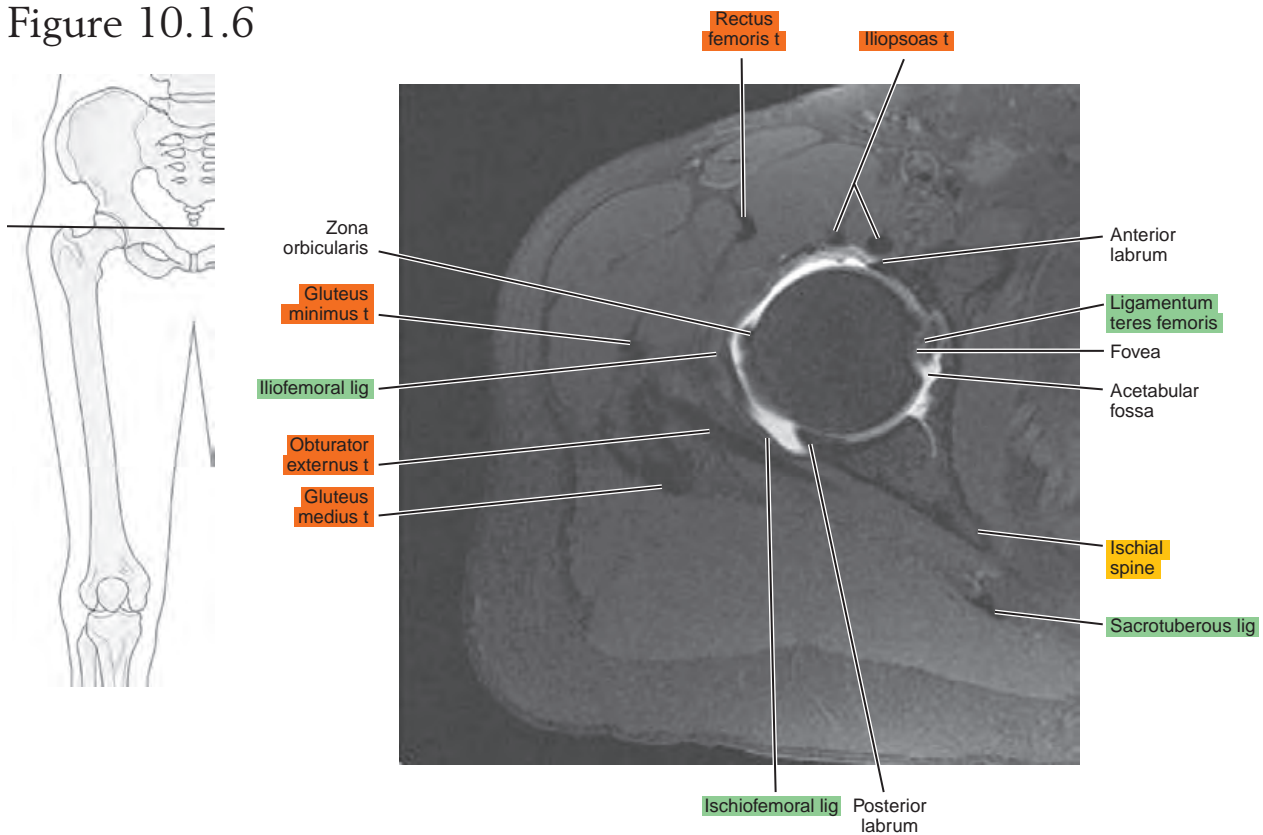


Figure 10.1.7

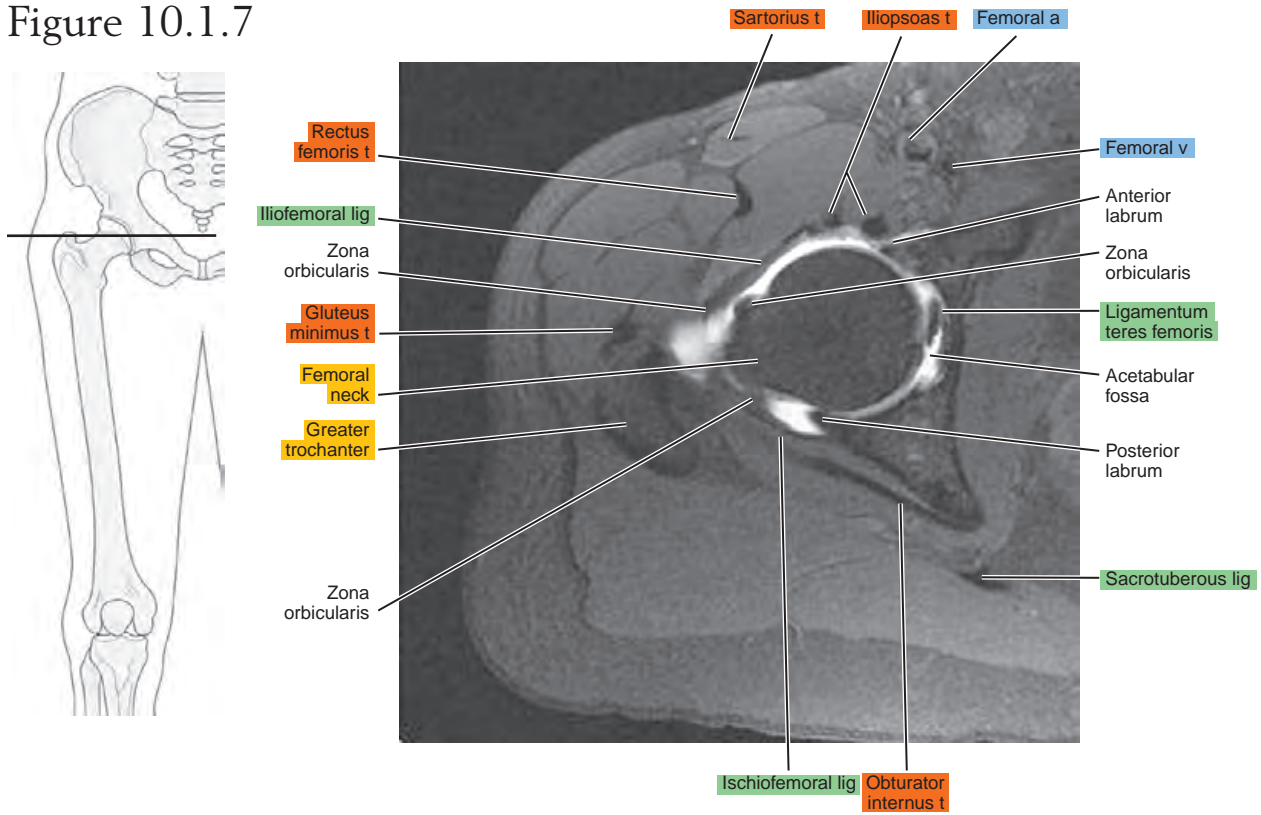


Figure 10.1.8

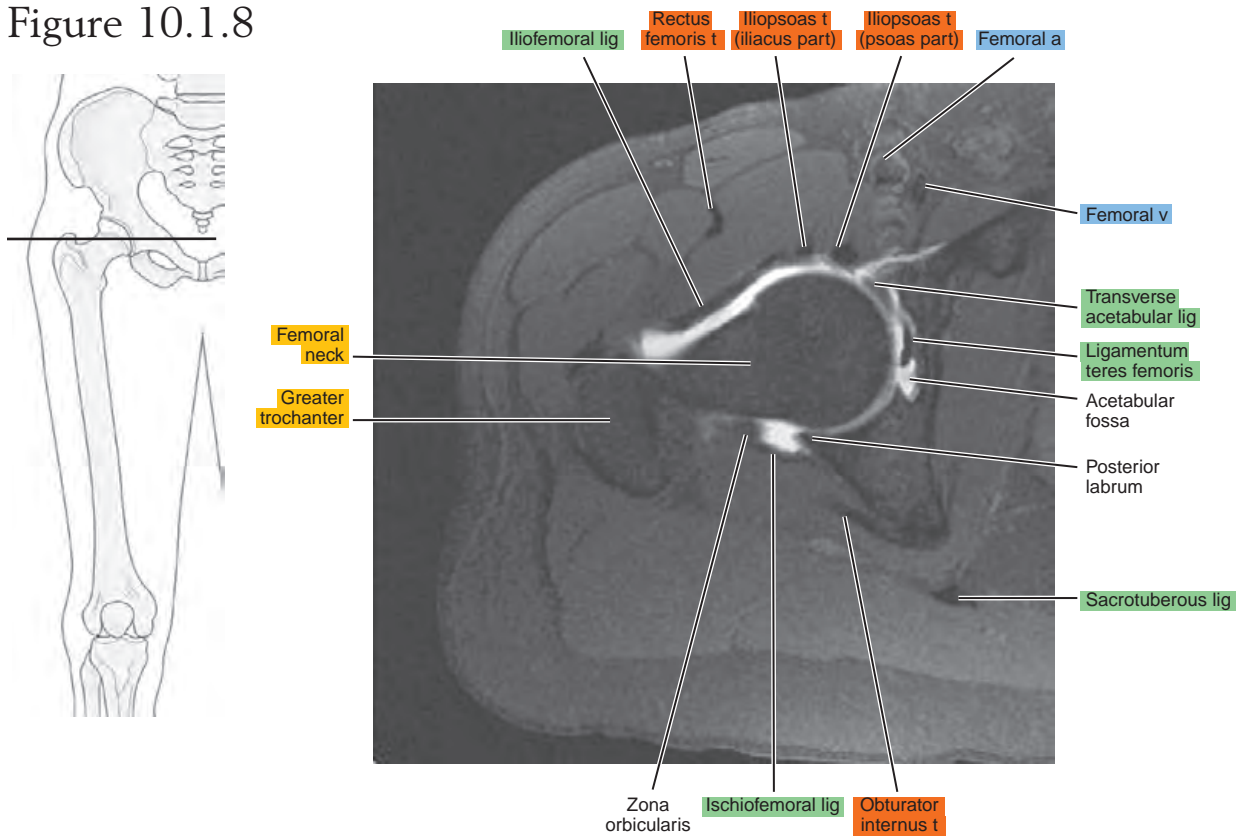


Figure 10.1.9

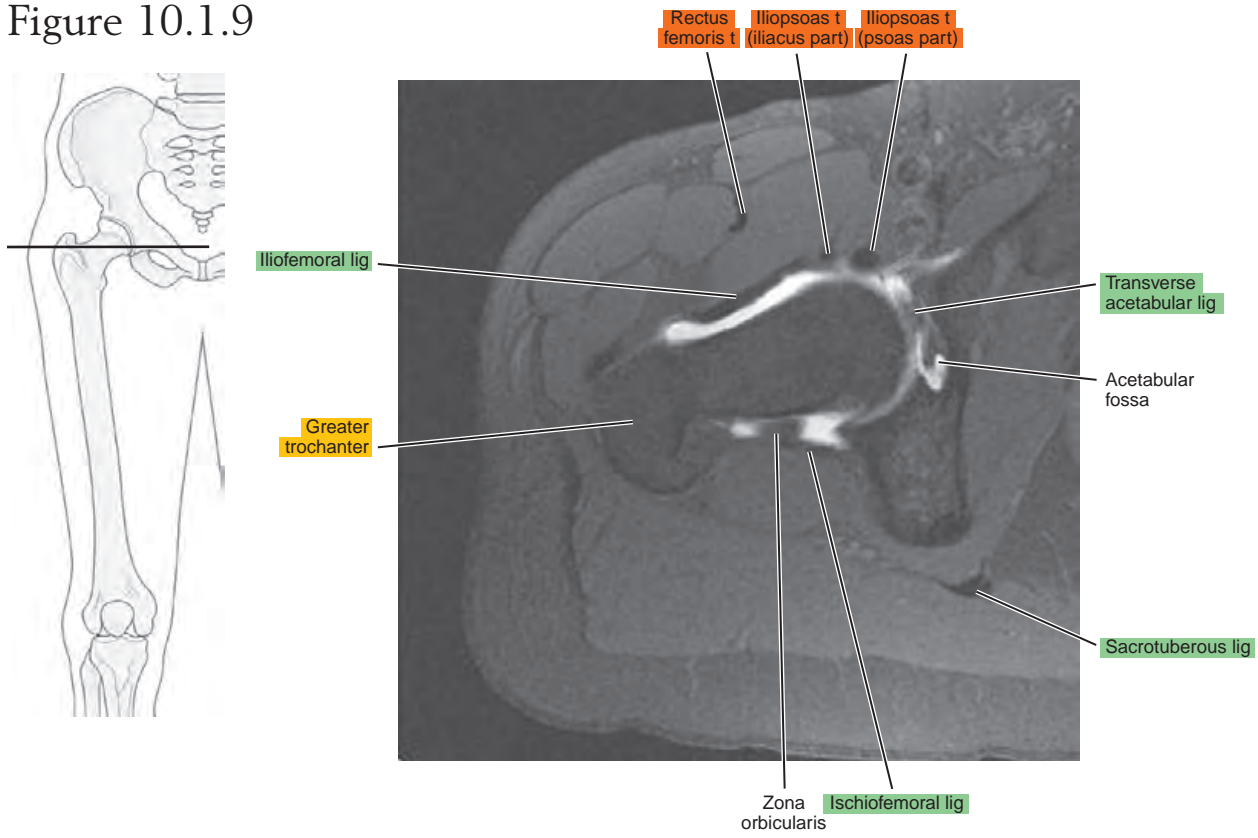


Figure 10.1.10

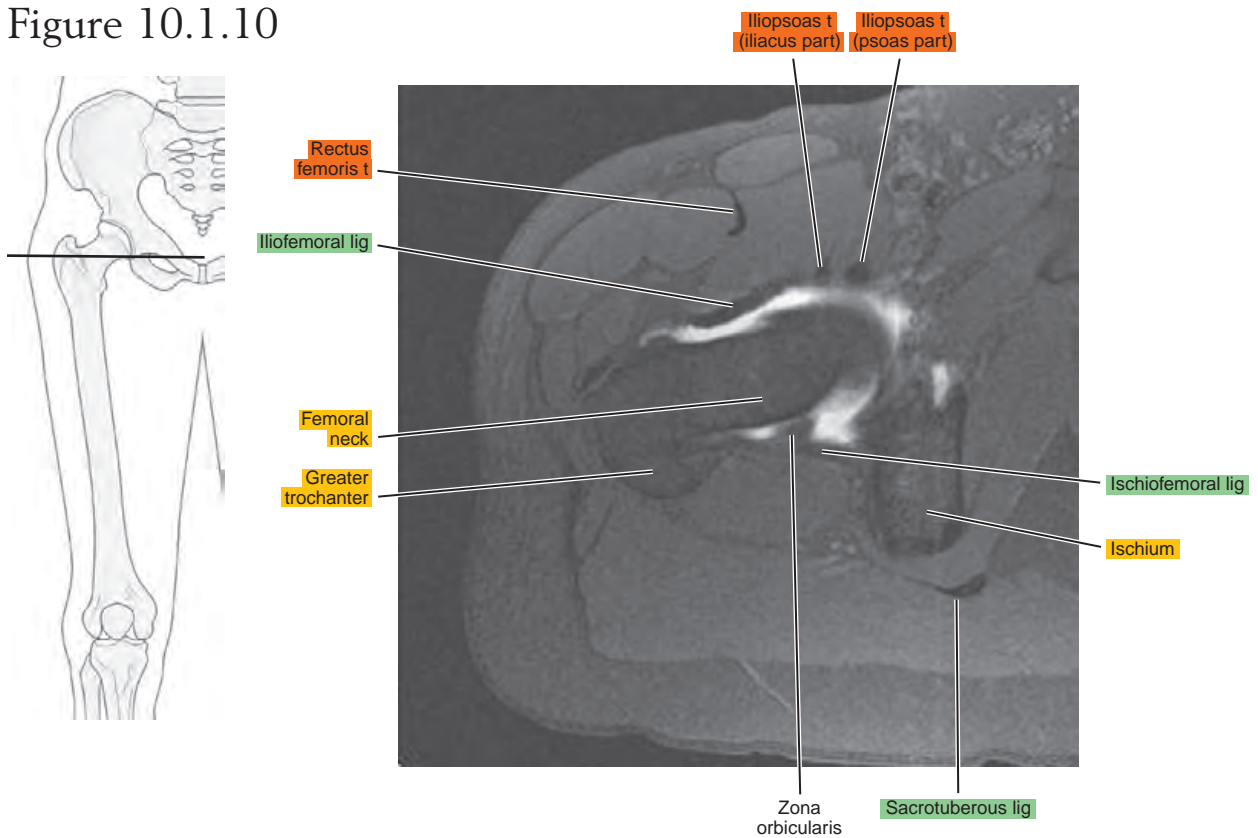


Figure 10.1.11

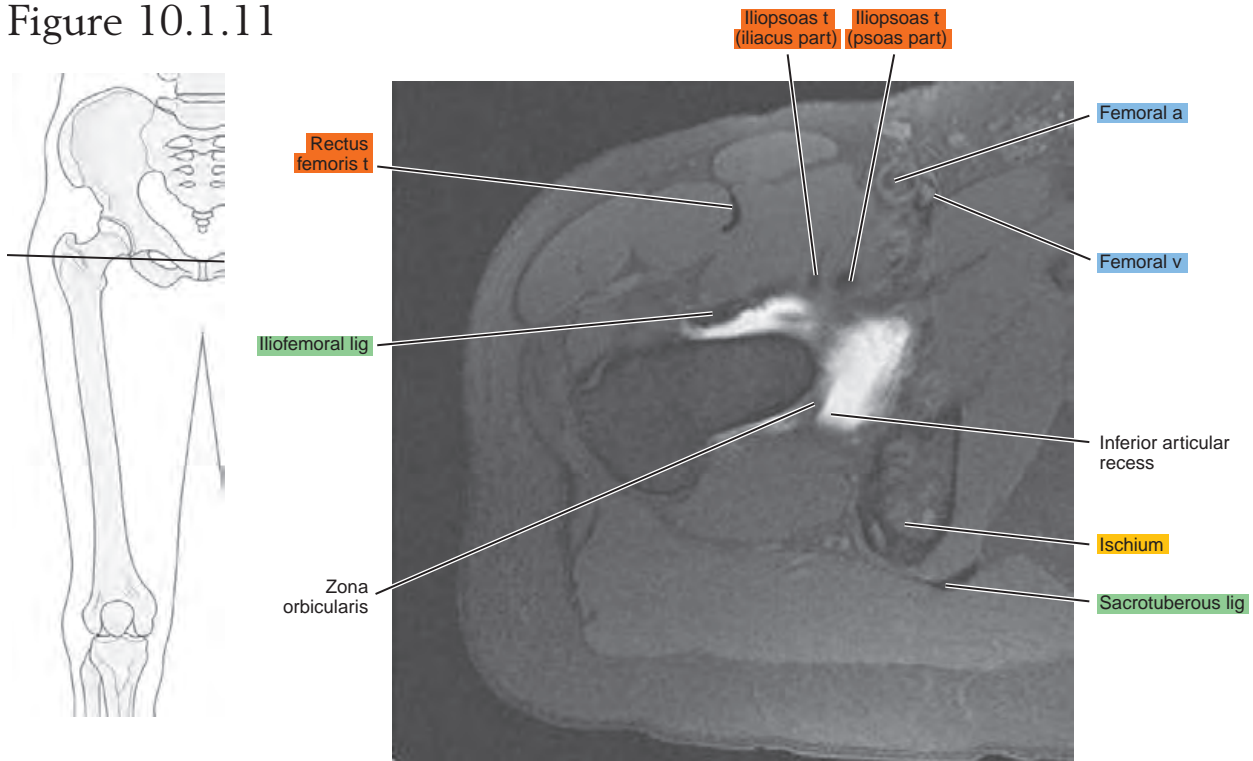
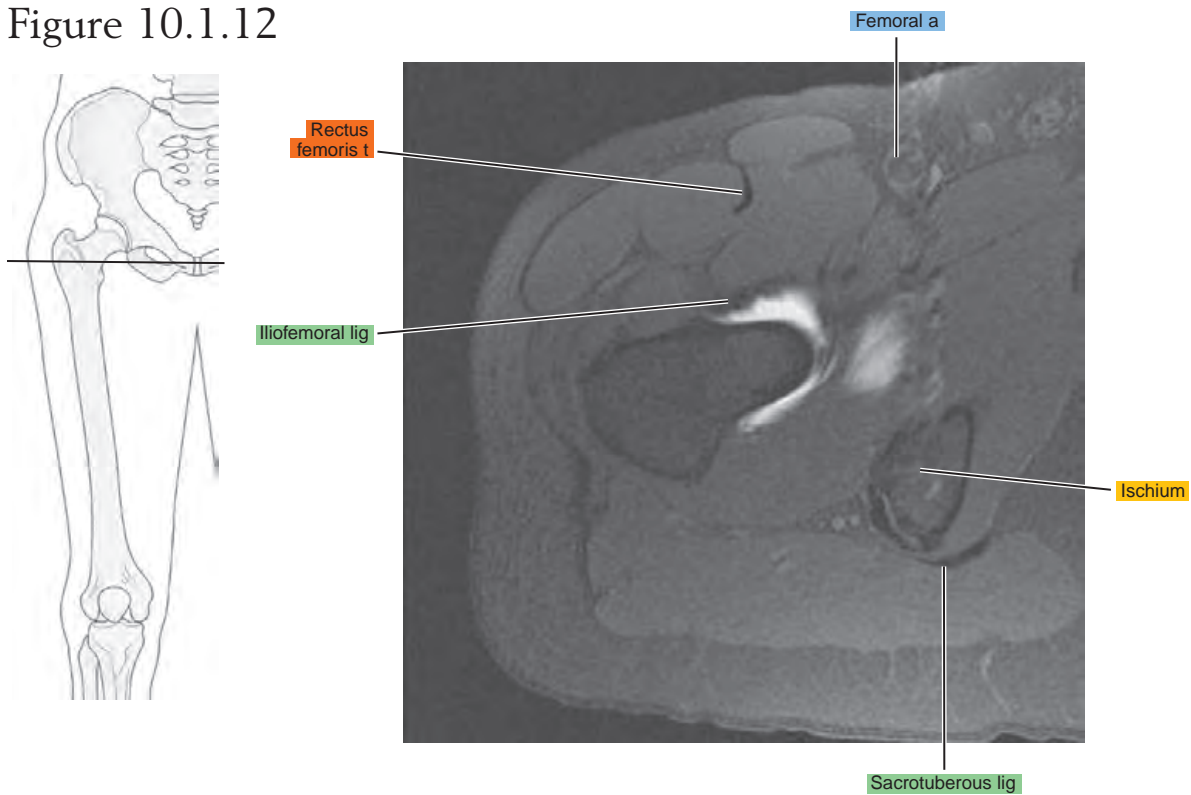


Figure 10.1.12



SAGITTAL

Figure 10.2.1

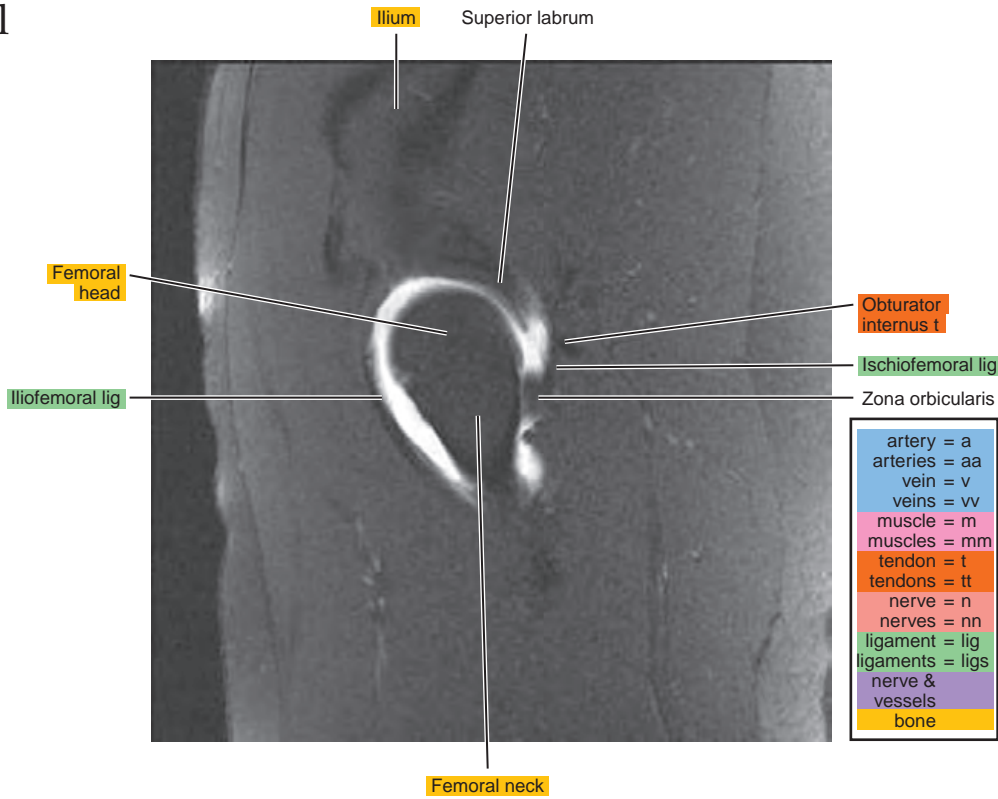
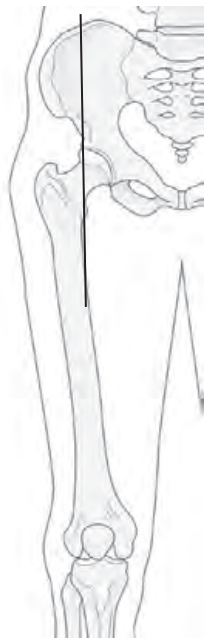

Figure 10.2.2

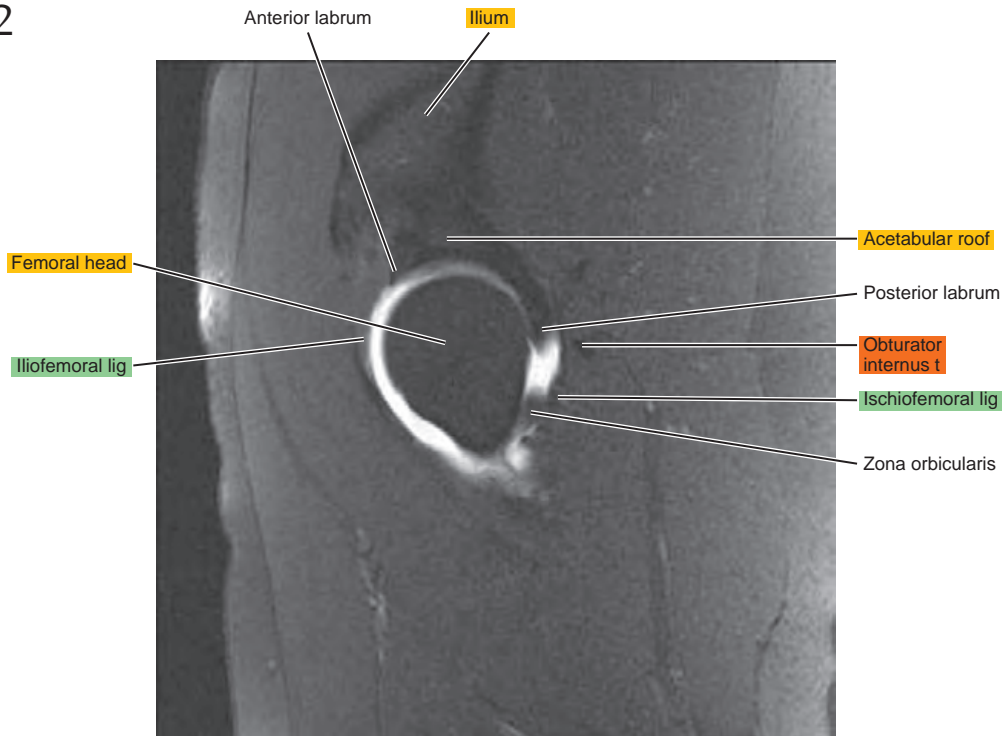
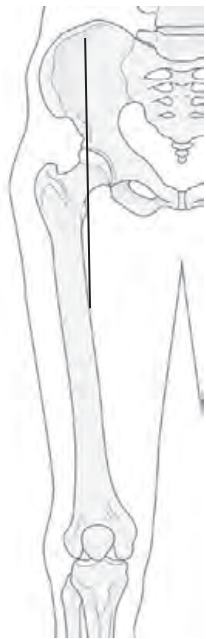

Figure 10.2.3

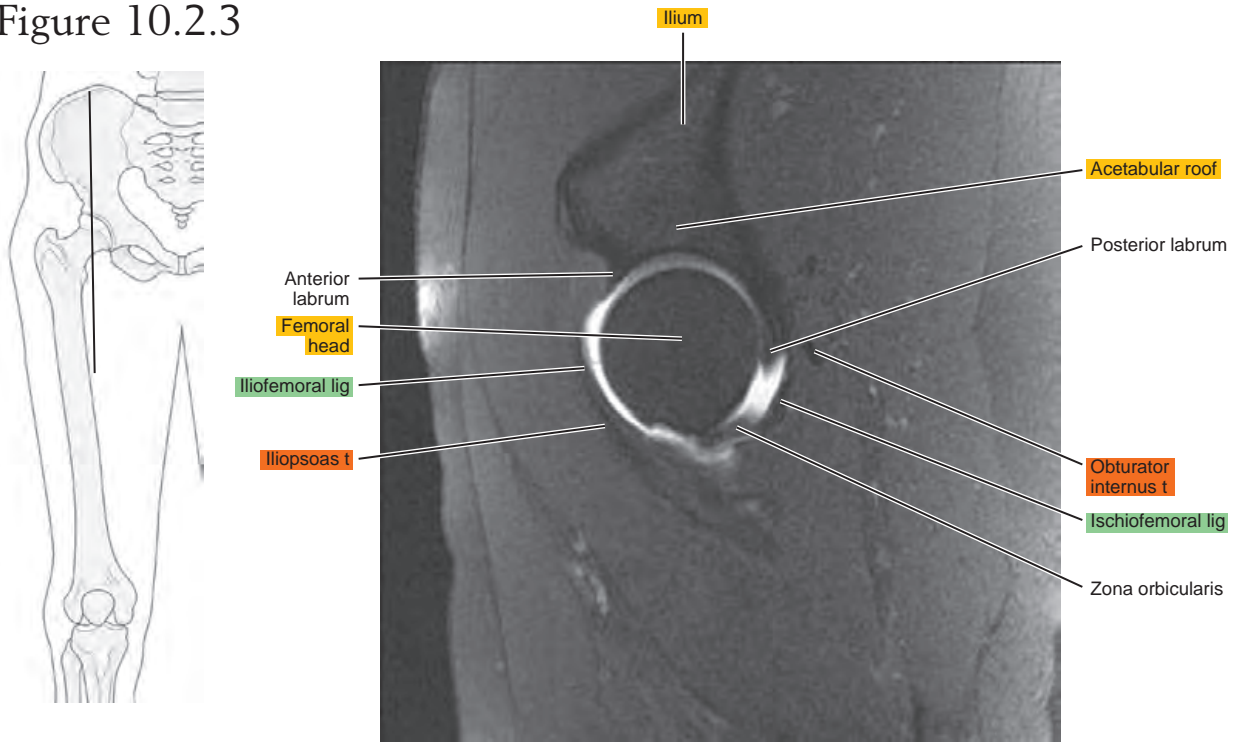


Figure 10.2.4

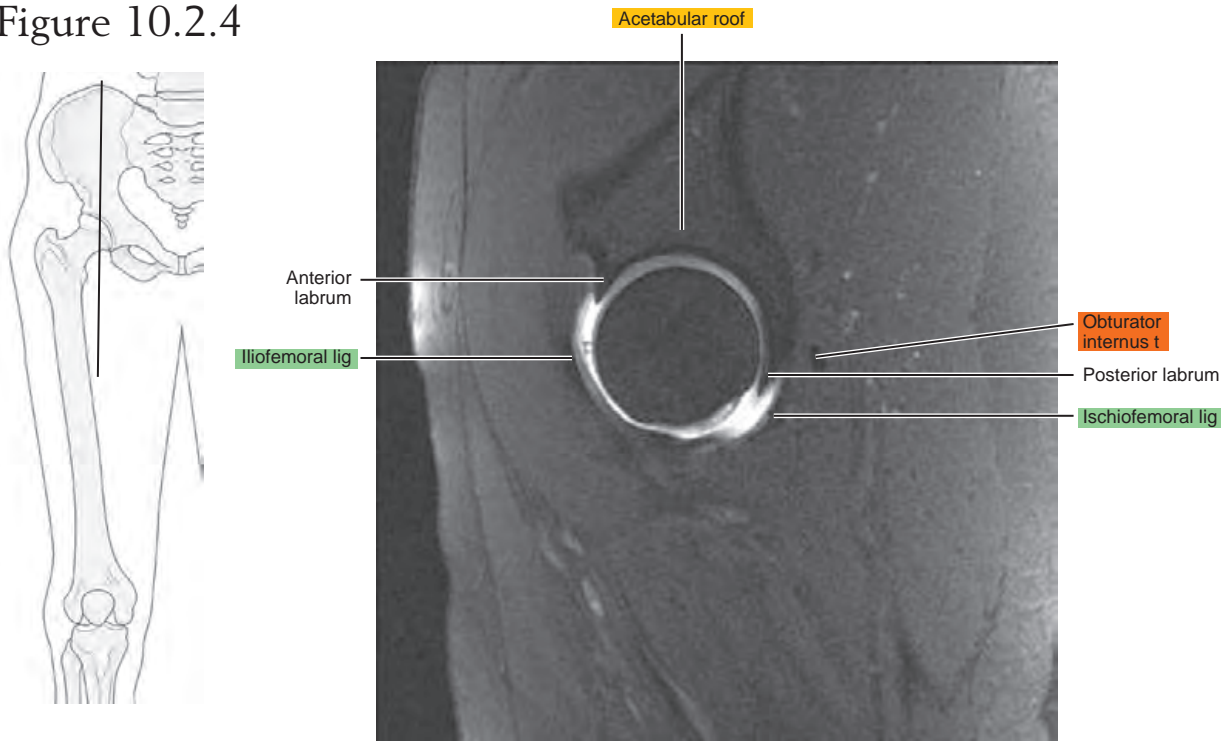


Figure 10.2.5

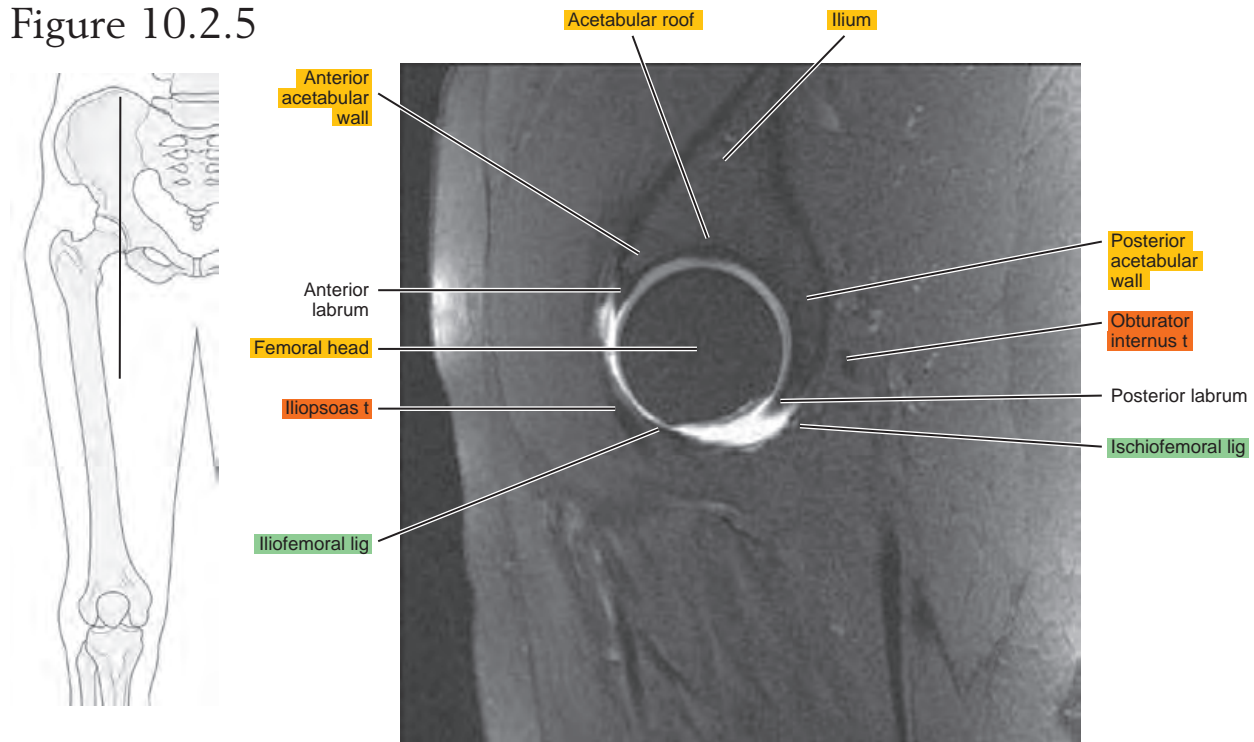


Figure 10.2.6

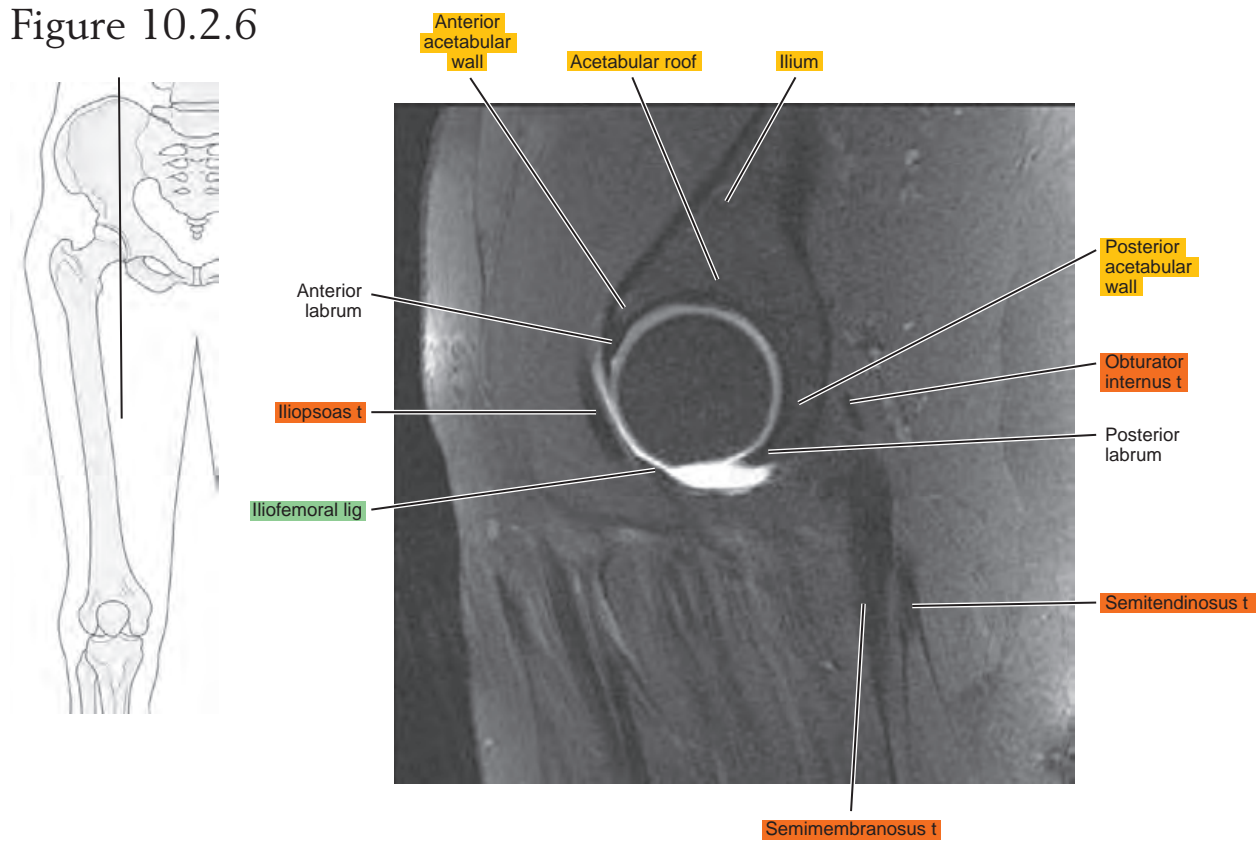


Figure 10.2.7

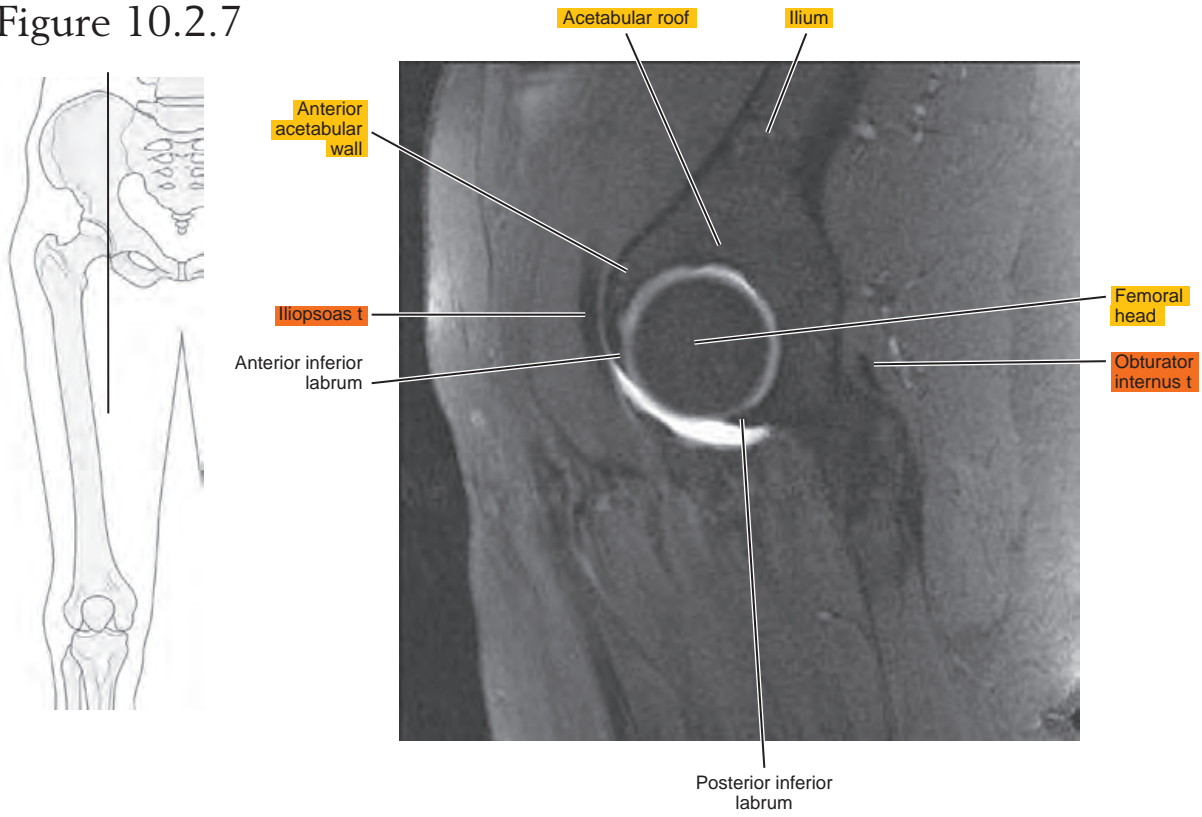


Figure 10.2.8

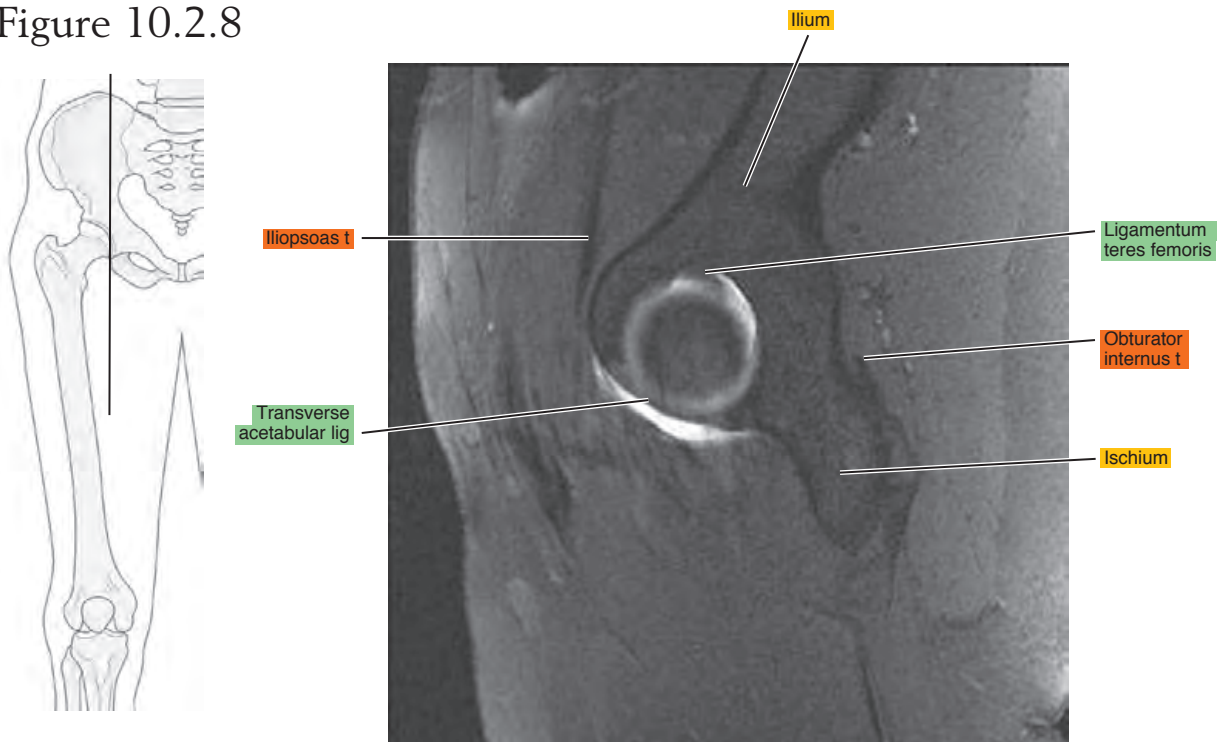


Figure 10.2.9

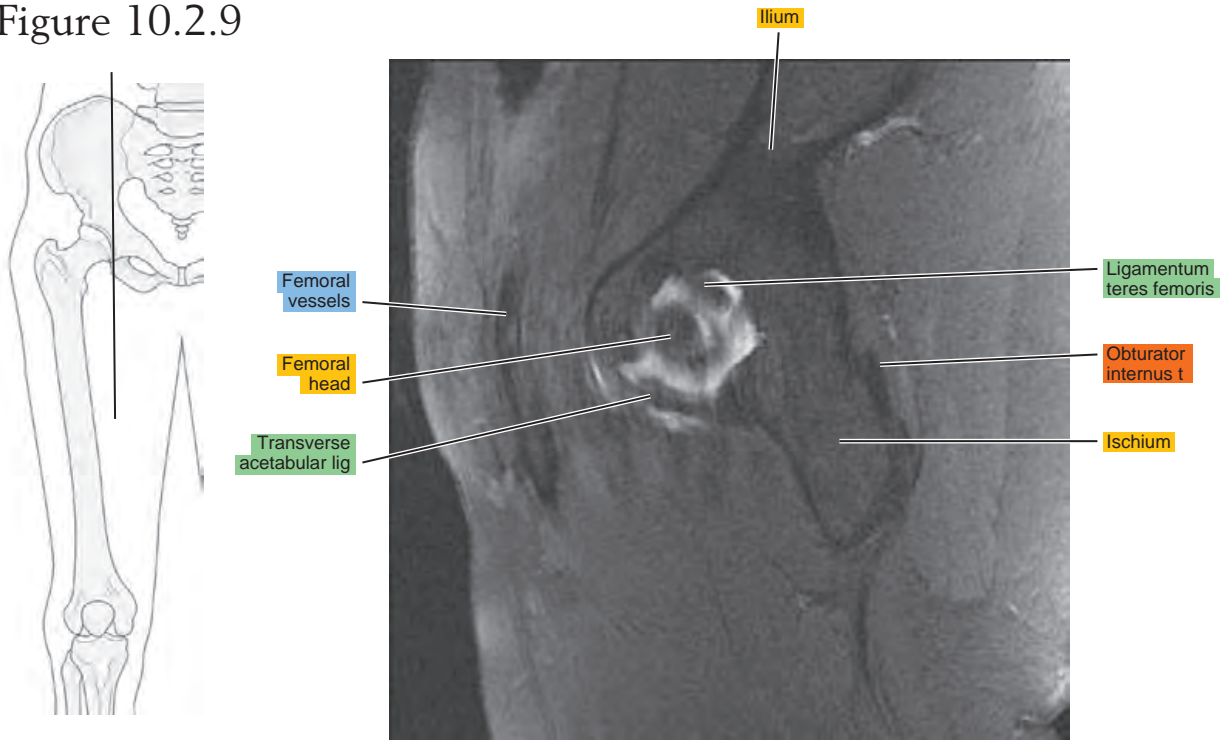
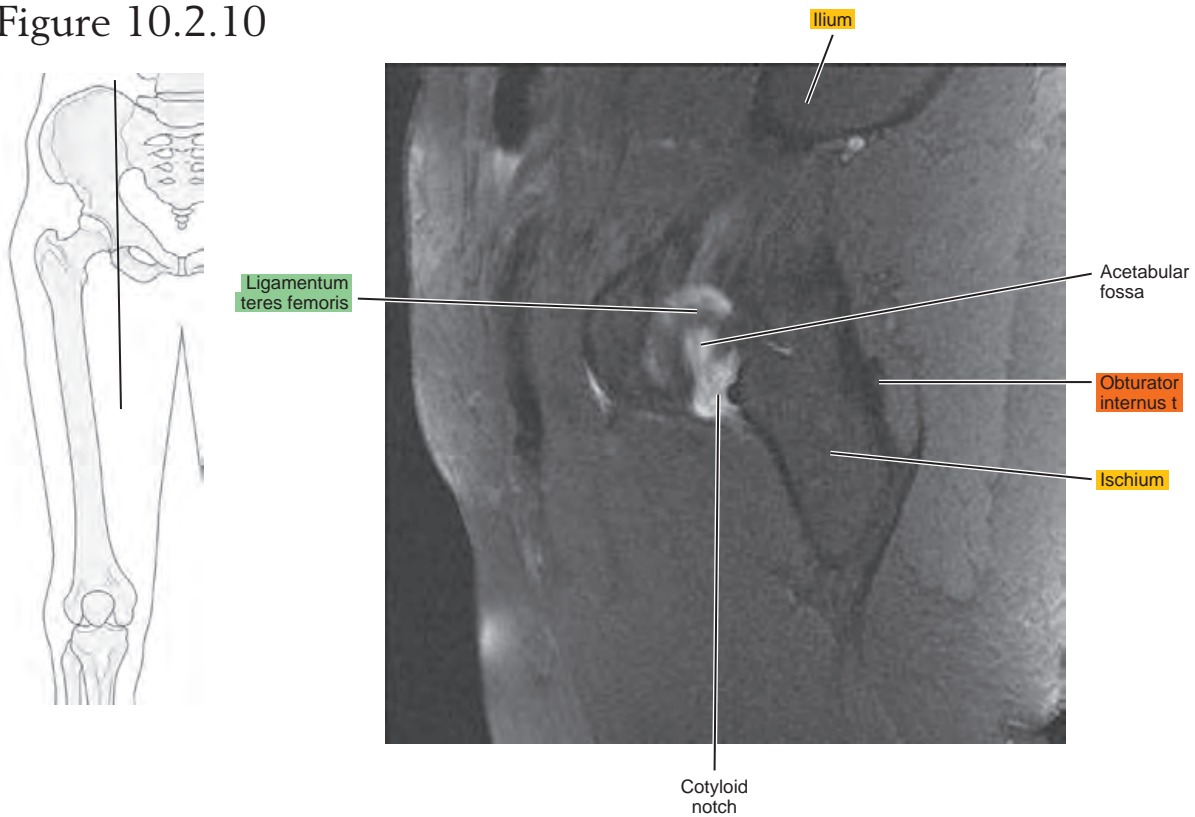


Figure 10.2.10



CORONAL

Figure 10.3.1

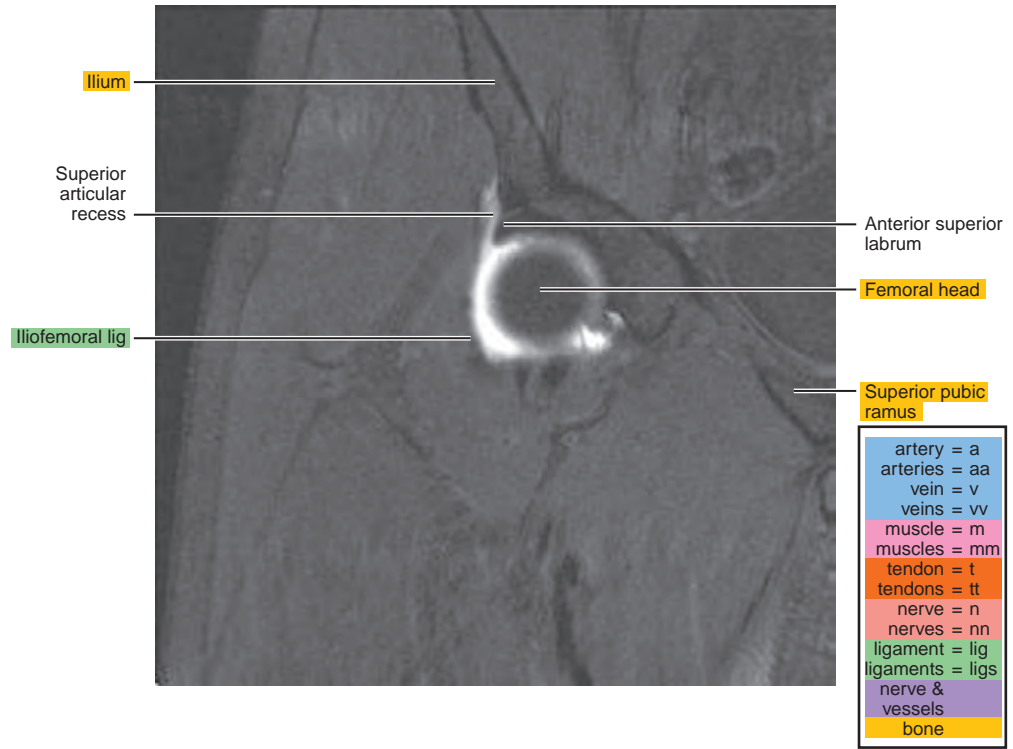
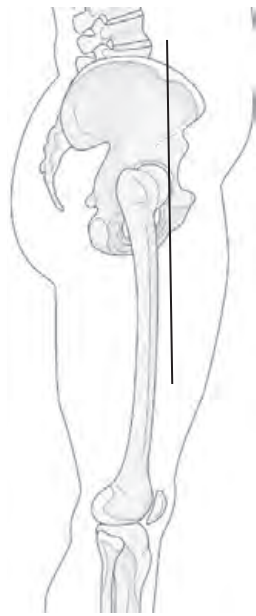


Figure 10.3.2

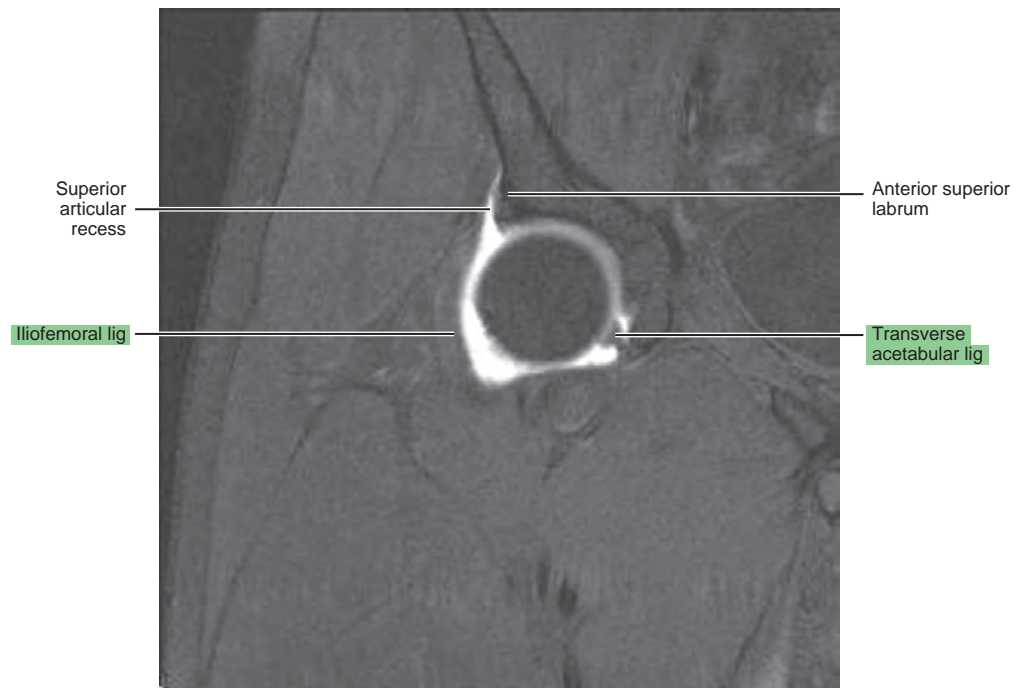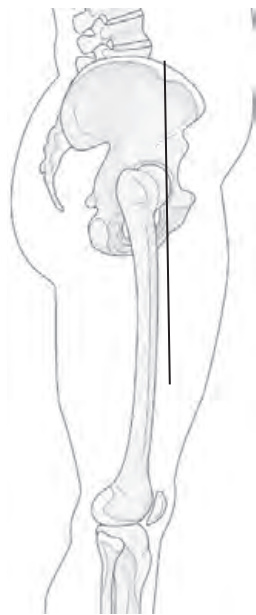


Figure 10.3.3

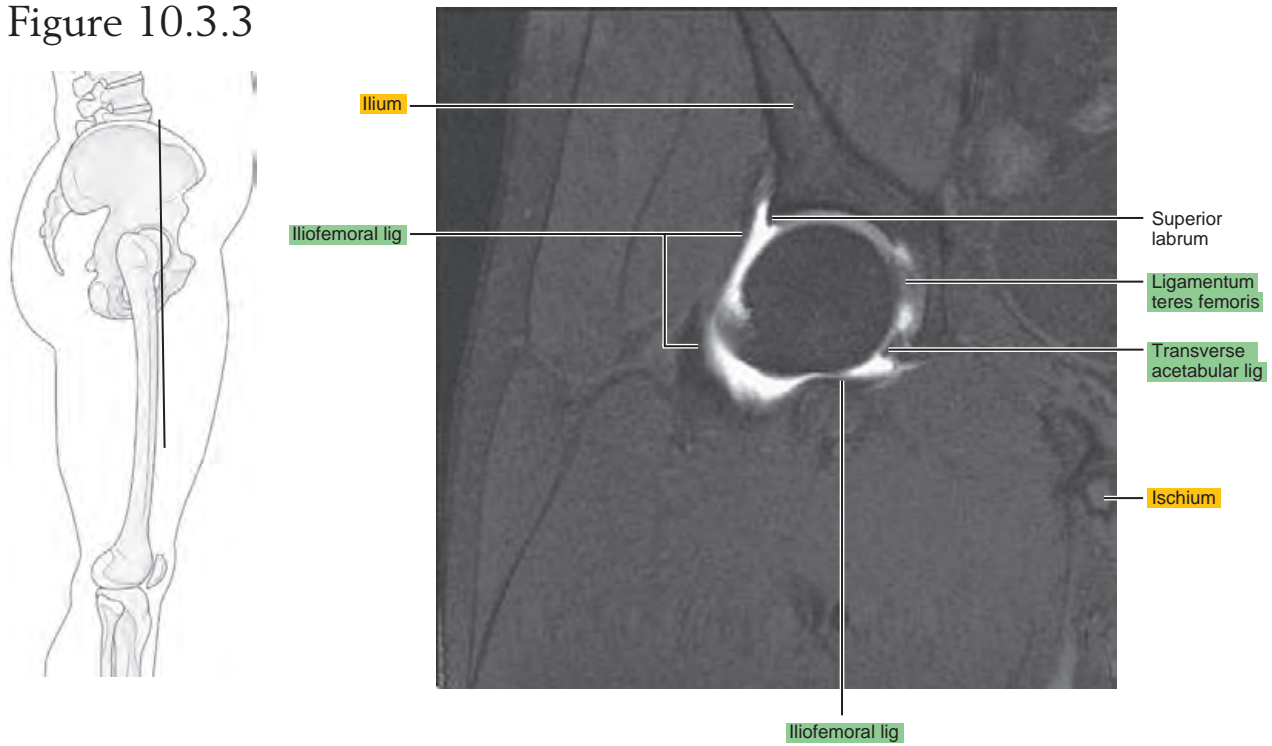


Figure 10.3.4

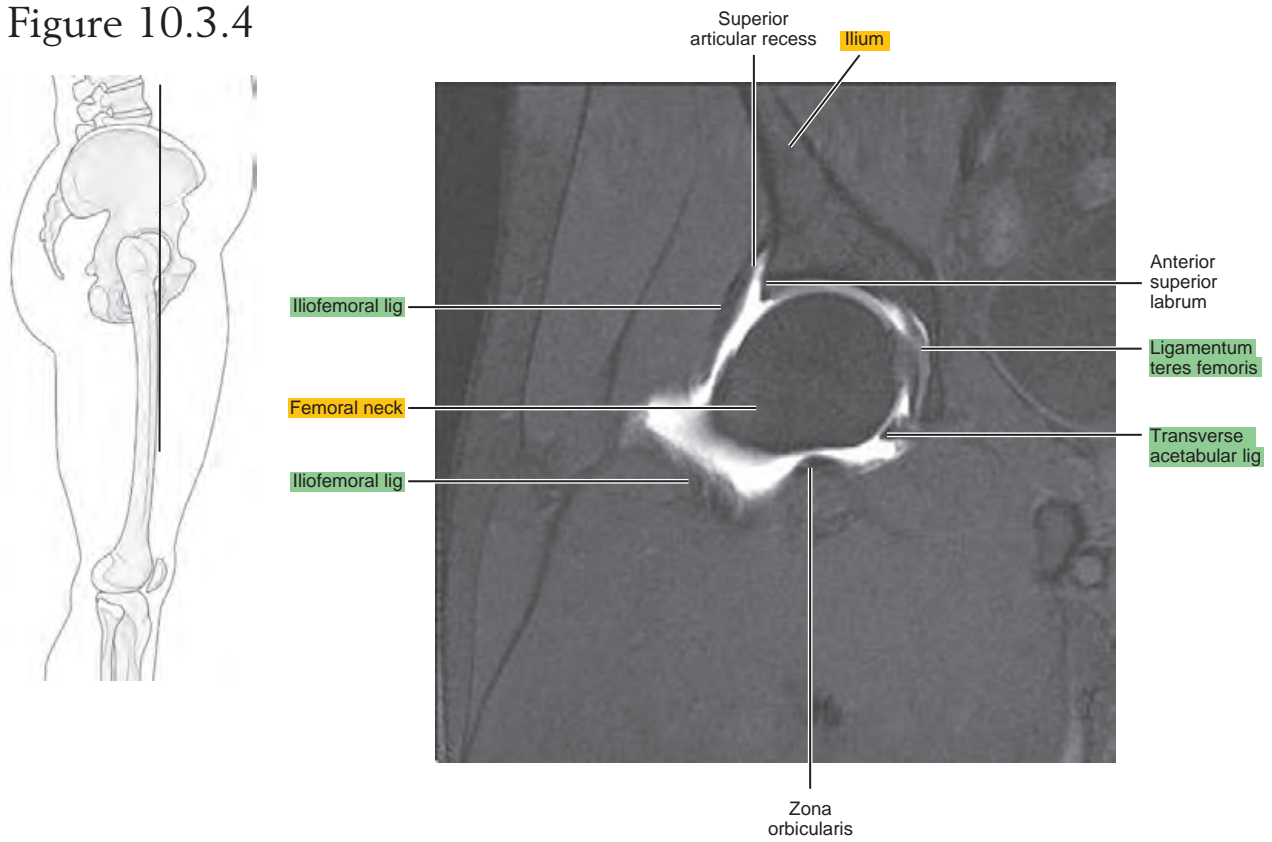


Figure 10.3.5

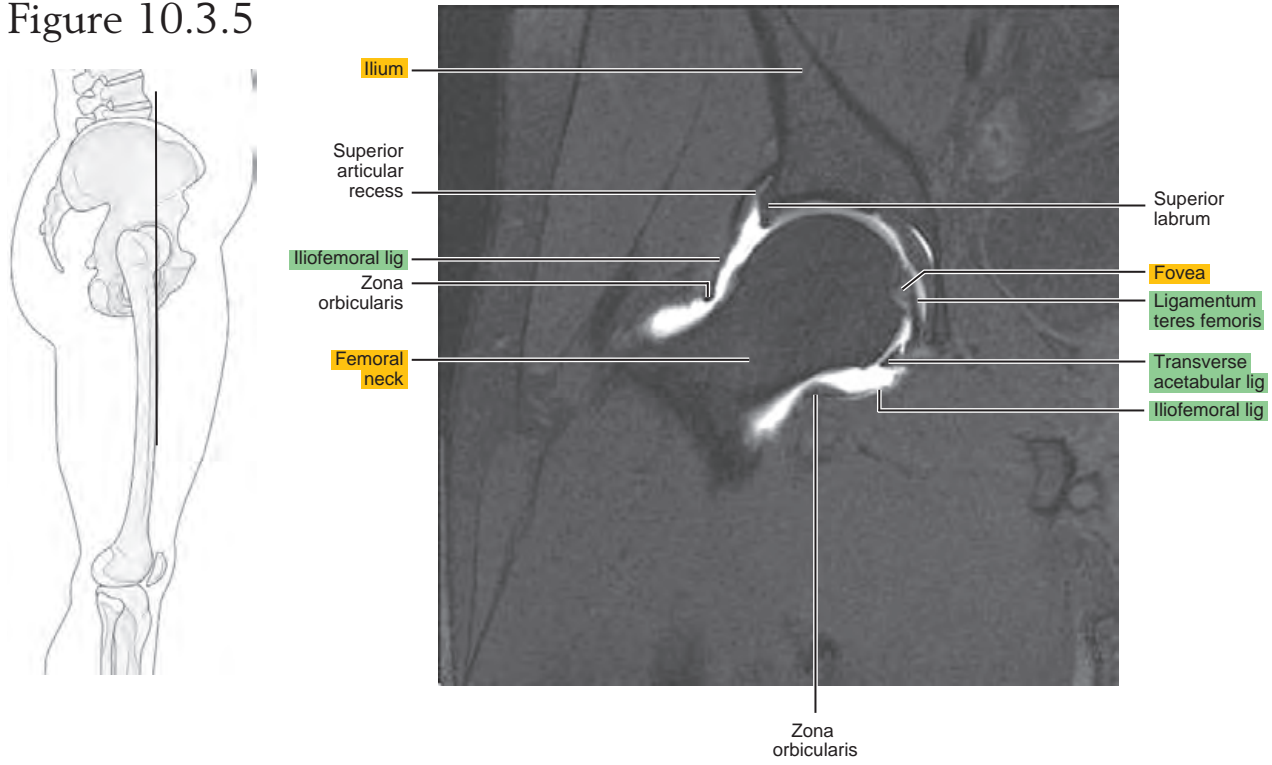


Figure 10.3.6

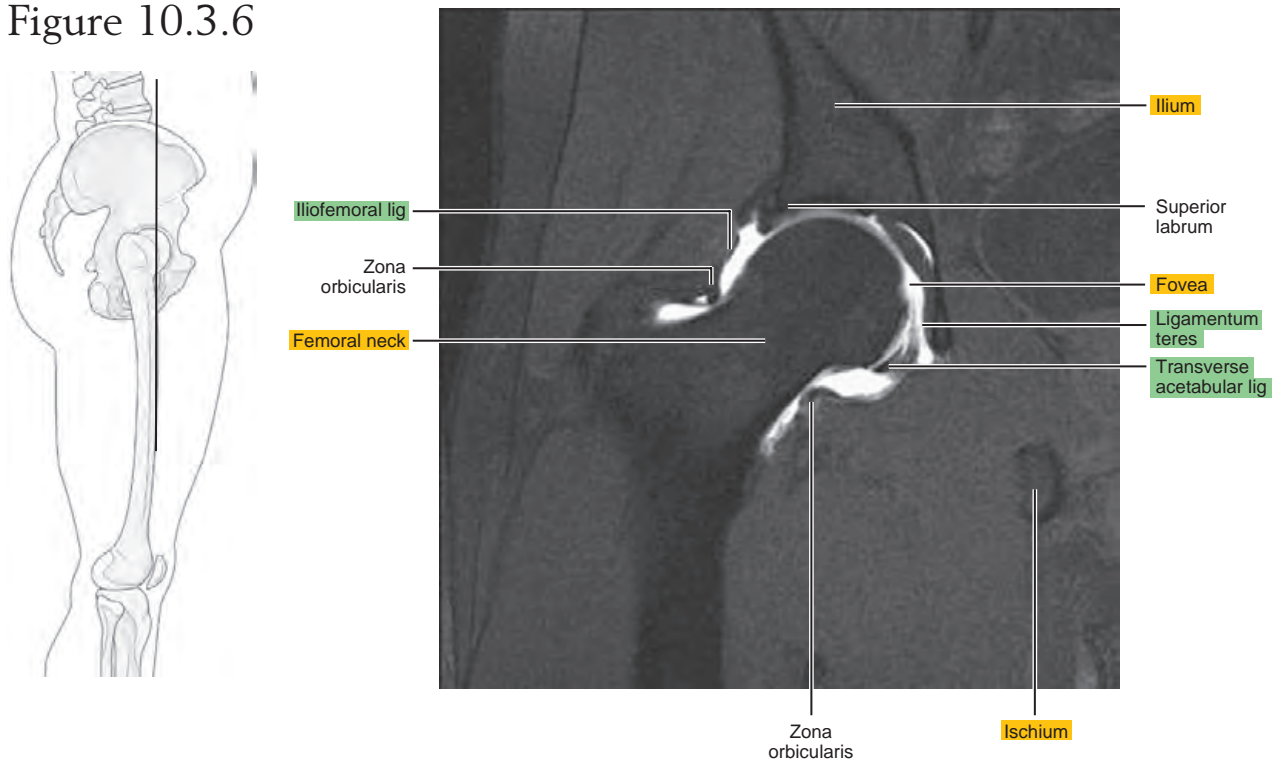


Figure 10.3.7

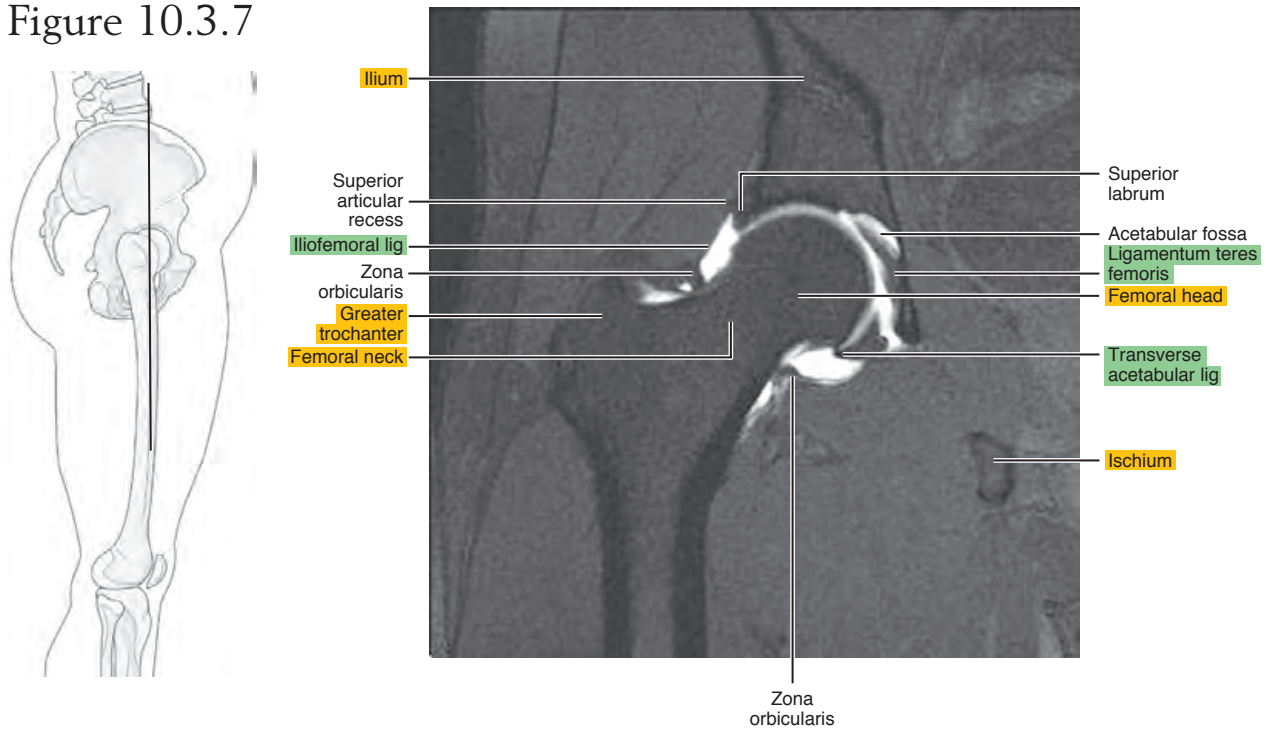


Figure 10.3.8

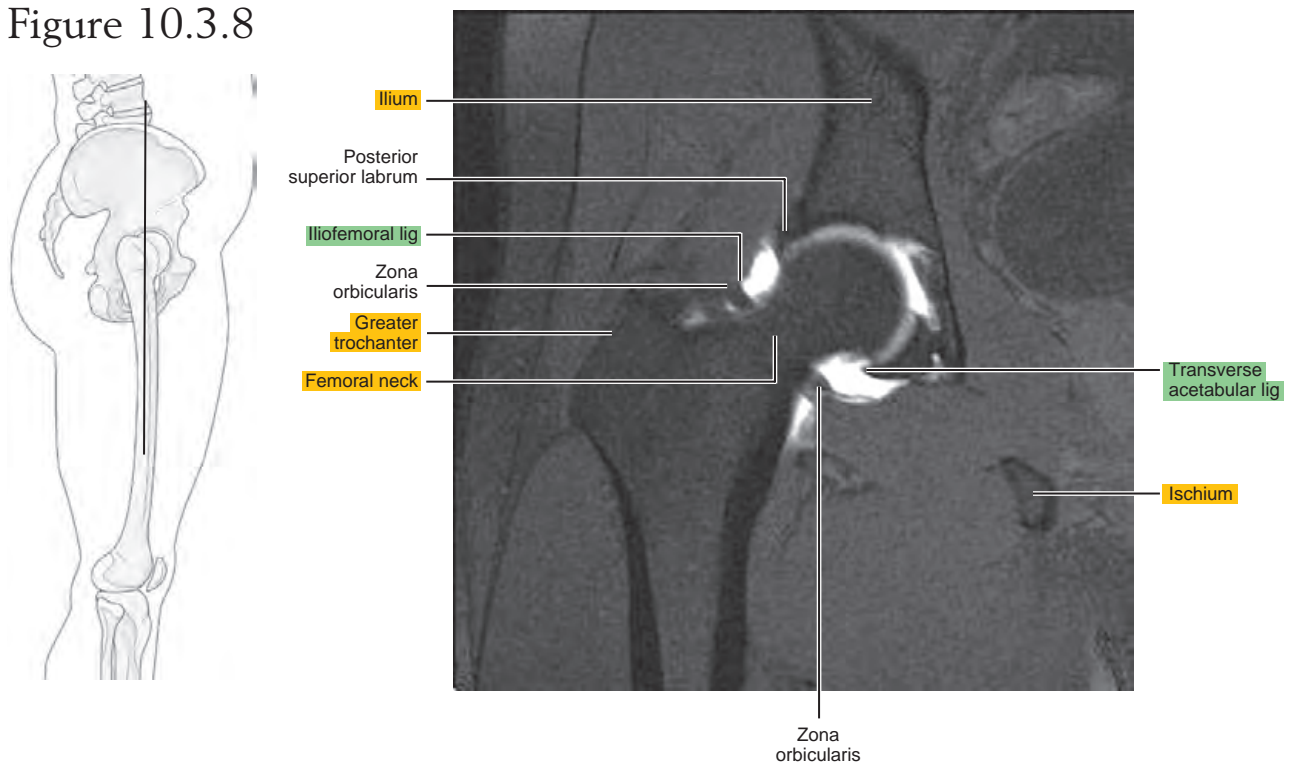


Figure 10.3.9

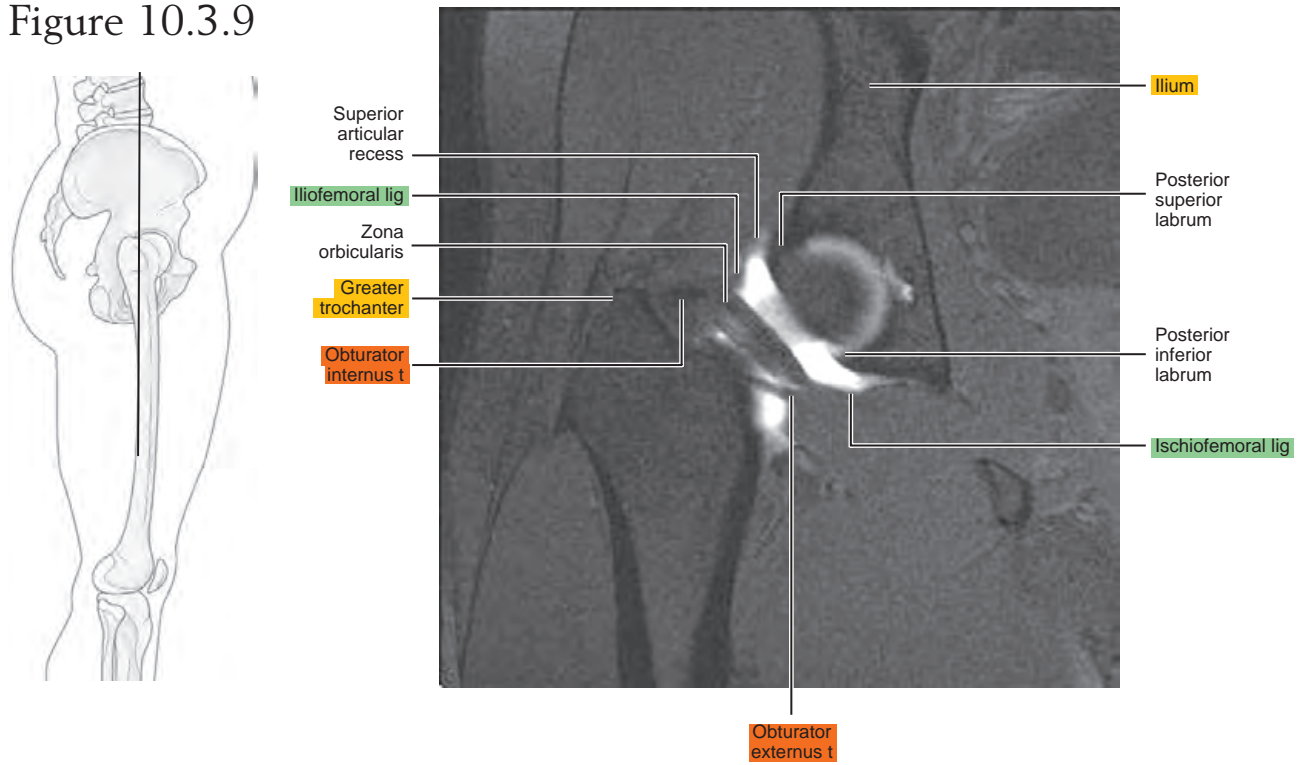
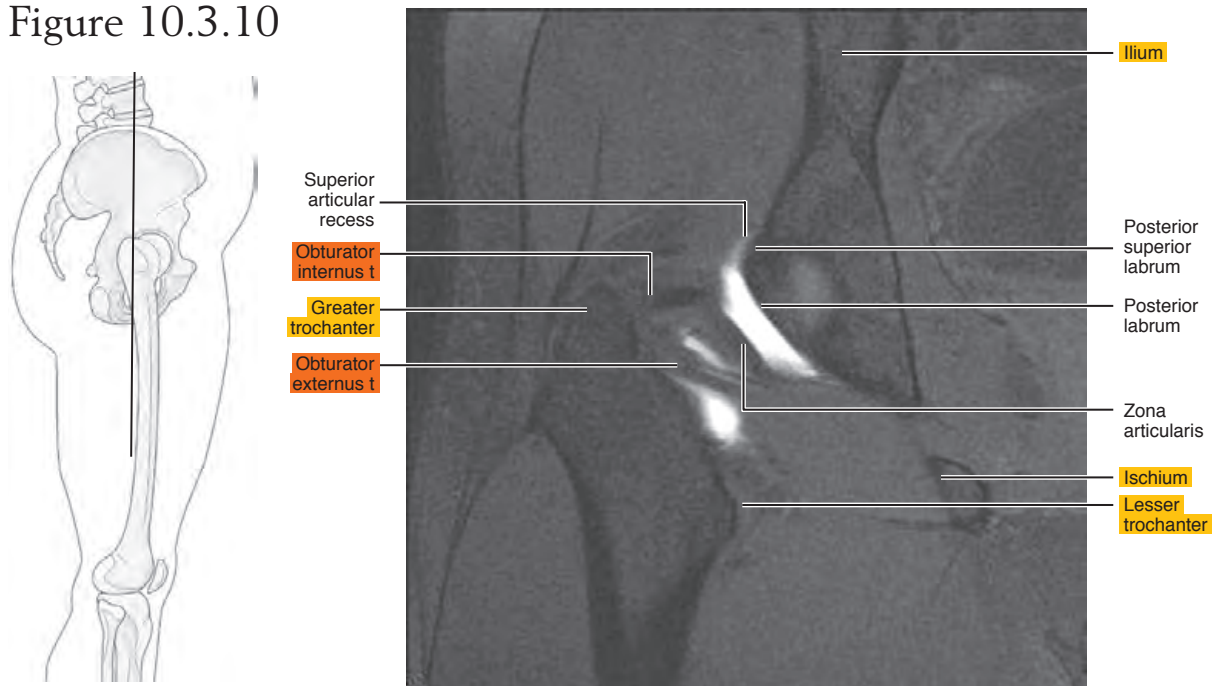


Figure 10.3.10



Chapter
11

MRI of the Thigh

Table 11-1. Muscles of the Thigh

MUSCLE	ORIGIN	INSERTION	NERVE SUPPLY
Sartorius	Anterior superior iliac spine and adjacent area below	Medial surface of the tibia; near the tuberosity and neighboring fascia	Femoral
Rectus femoris	Straight head: anterior inferior iliac spine; reflected head: posterosuperior surface of the rim of the acetabulum	Through the patellar ligament to the tibial tuberosity	Femoral
Vastus lateralis	Shaft of the femur along the anteroinferior margin of the greater trochanter, above the gluteal tuberosity, and the upper half of the linea aspera	Proximal border of the patella, front of the lateral condyle of the tibia and fascia of the leg	Femoral
Vastus medialis	Medial lip of the linea aspera and the distal half of the intertrochanteric line, and the aponeurosis of the tendons of insertion of the adductor muscles	Upper two thirds of the medial margin and proximal margin of the patella, medial condyle of the tibia, and investing deep fascia of the leg with the tendons of vastus intermedius, lateralis, and rectus, and through the patellar ligament onto the front of the tibial tuberosity	Femoral
Vastus intermedius	Distal half of the lateral margin of the linea aspera and its lateral bifurcation and from the anterolateral part of the shaft of the femur	Proximal margin and deep surface of the patella, aponeurosis of the vastus lateralis, medially and laterally to the tendons of vastus medialis and lateralis, to the patellar ligament and onto the tibial tuberosity	Femoral
Gracilis	Medial margin of inferior ramus of the pubis and the pubic end of the inferior ramus of the ischium	By an expanded tendinous process onto the tibia below the medial condyle	Anterior division of the obturator
Pectineus	Pectineal line, pectineal fascia, and anterior margin of the obturator sulcus, and from the pubofemoral ligament	Upper half of the pectineal line behind lesser trochanter	Femoral, also from the accessory obturator and/or obturator
Adductor longus	Pubic tubercle to symphysis pubis	Middle third of the linea aspera	Anterior division of the obturator; also, occasionally, branch from the femoral
Adductor brevis	Medial part of the outer surface of the inferior ramus of the pubis	Distal two thirds of the pectineal line and the upper one third of the linea aspera	Anterior (or posterior) branch of the obturator
Adductor magnus	Inferior ramus of the pubis	Medial side of the gluteal ridge and the superior part of the linea aspera by a tendon from the distal three fourths of the linea aspera and the adductor tubercle at the distal end of the medial supracondylar ridge	Posterior branch of the obturator and a branch from the sciatic
Biceps femoris	From the lateral lip of the linea aspera of the femur, from the middle of the shaft to the bifurcation of the linea aspera proximal two thirds of the supracondylar ridge, and lateral intermuscular septum	Head of the fibula in front of the apex, partially onto the lateral condyle of the tibia, and into the fascia of the leg	Peroneal part of the sciatic

AXIAL

Figure 11.1.1

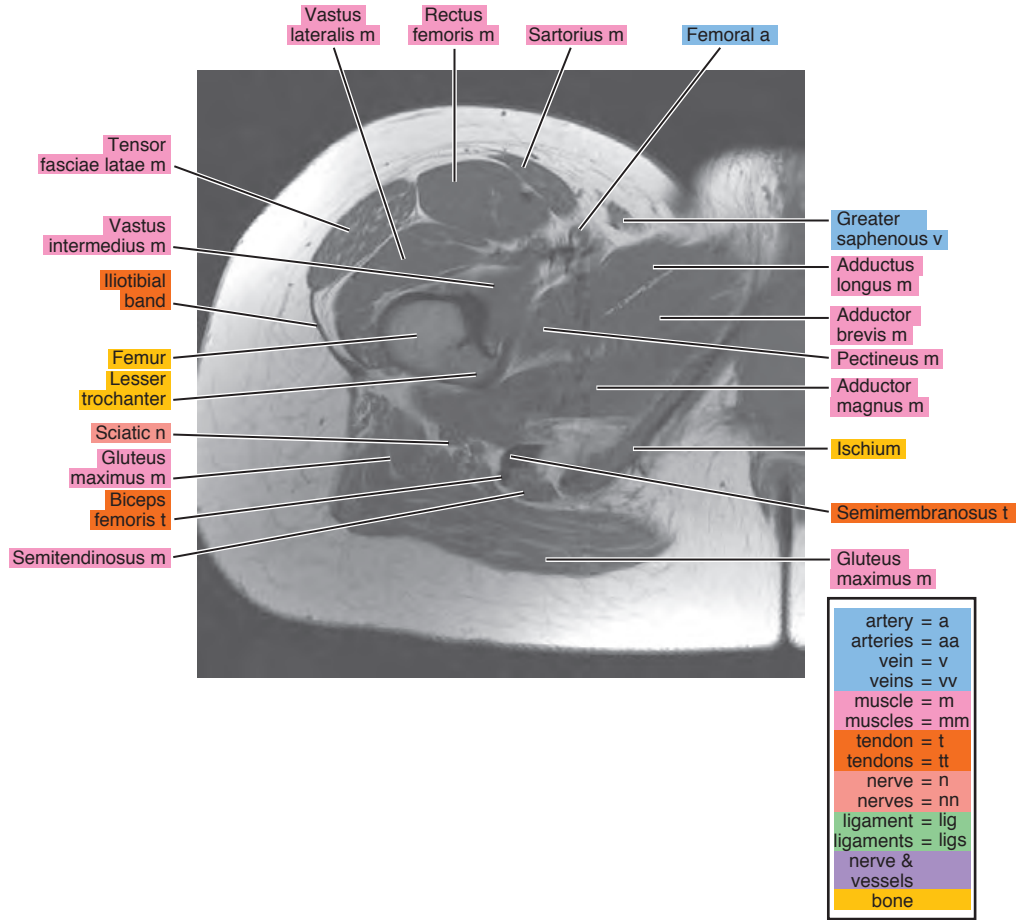


Figure 11.1.2

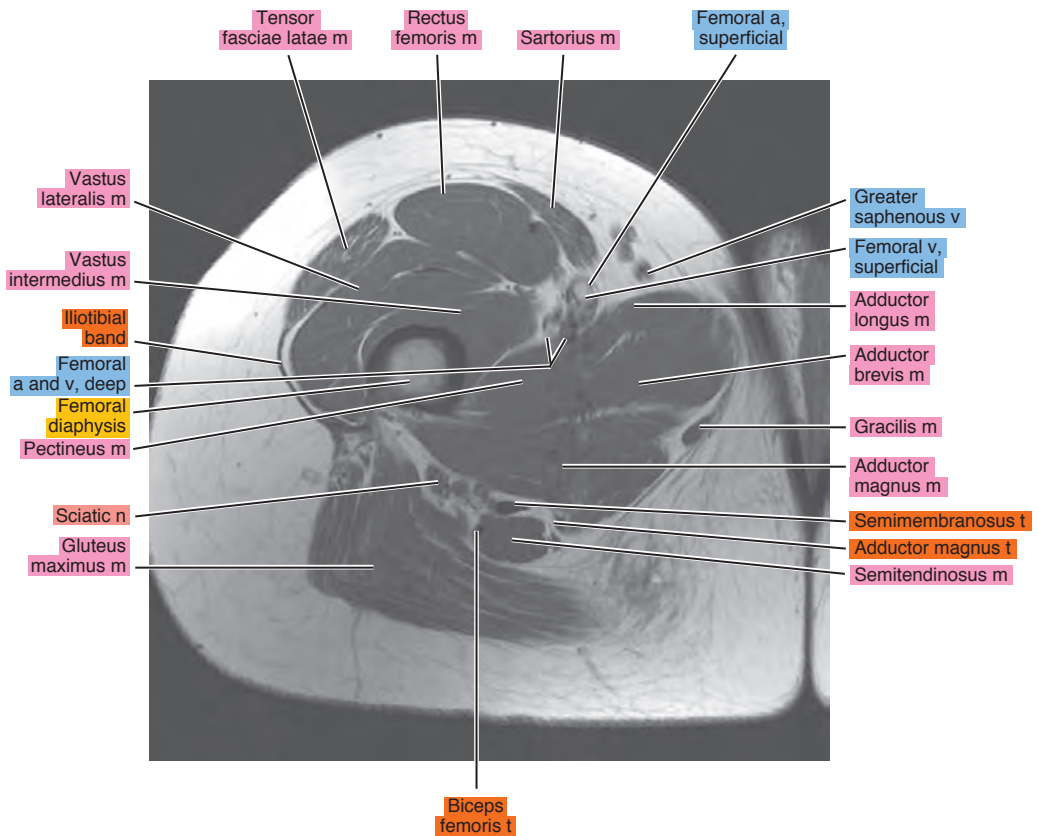
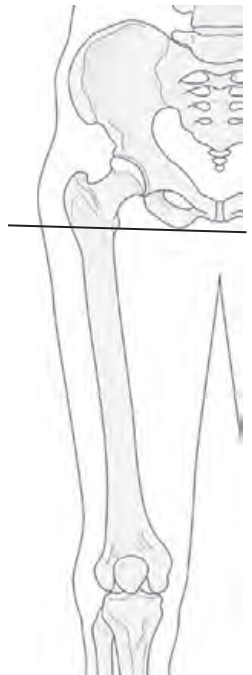

Figure 11.1.3

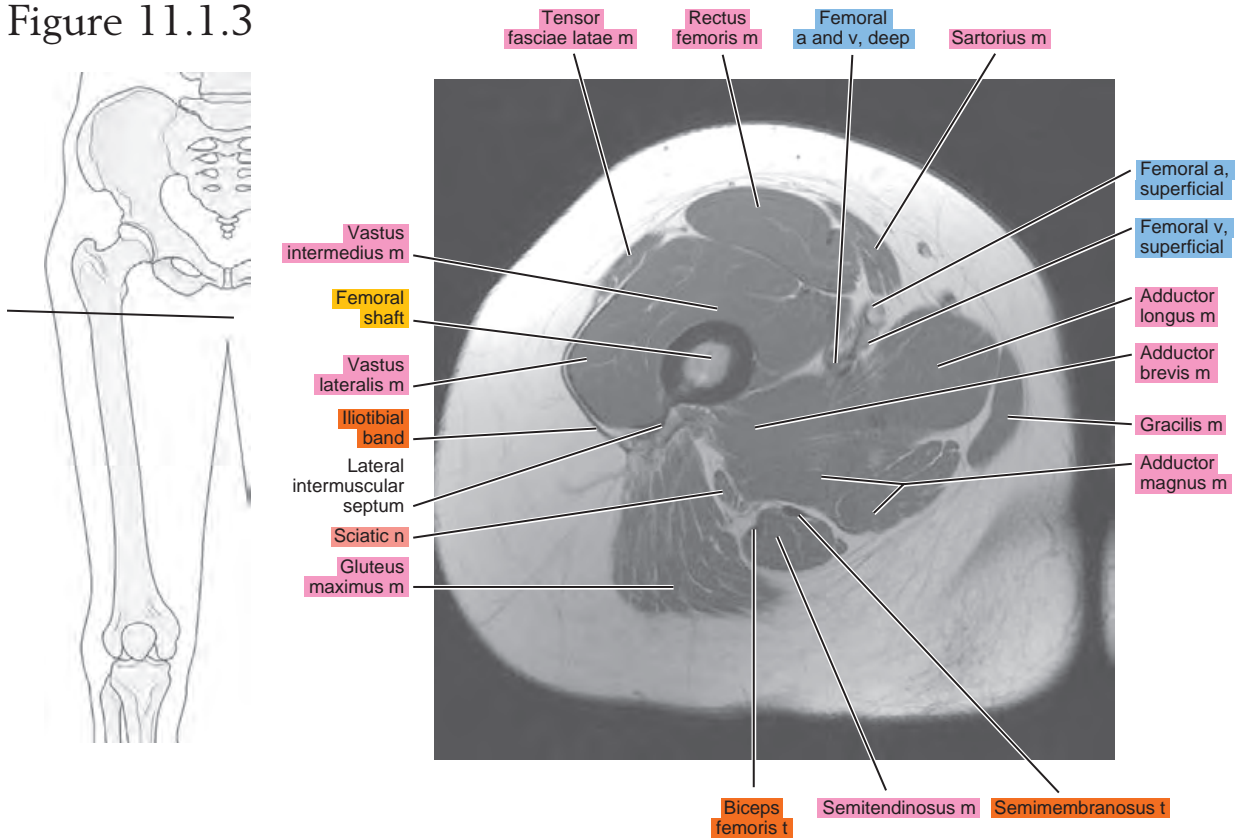


Figure 11.1.4

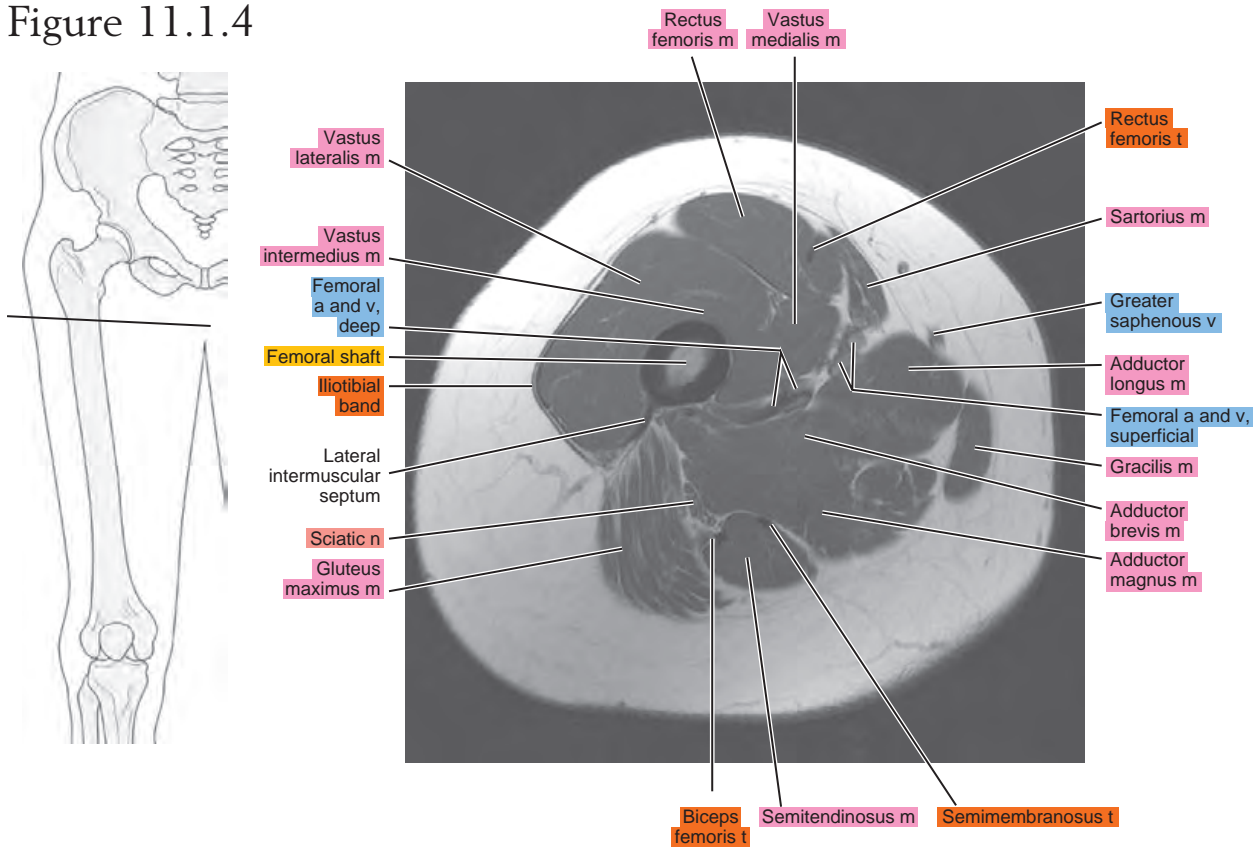


Figure 11.1.5

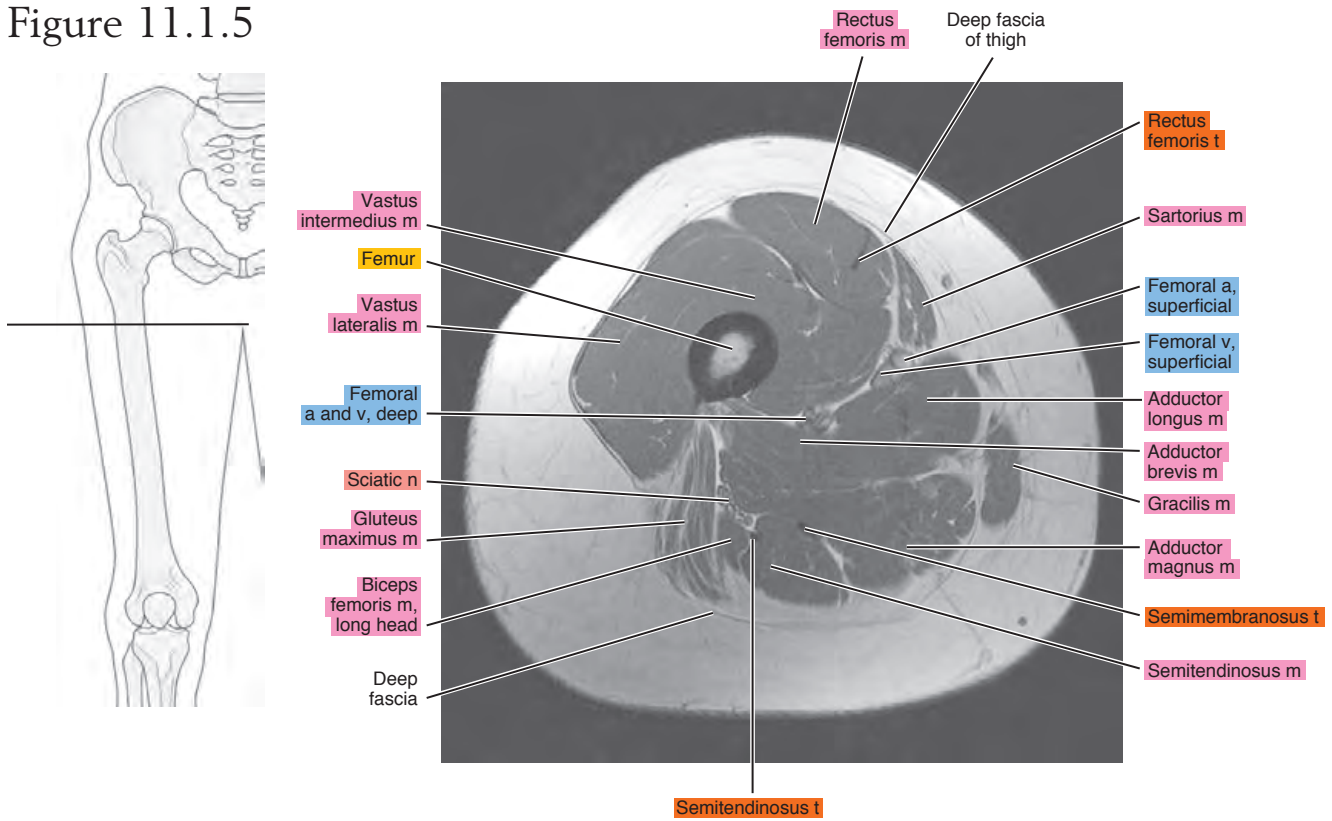


Figure 11.1.6

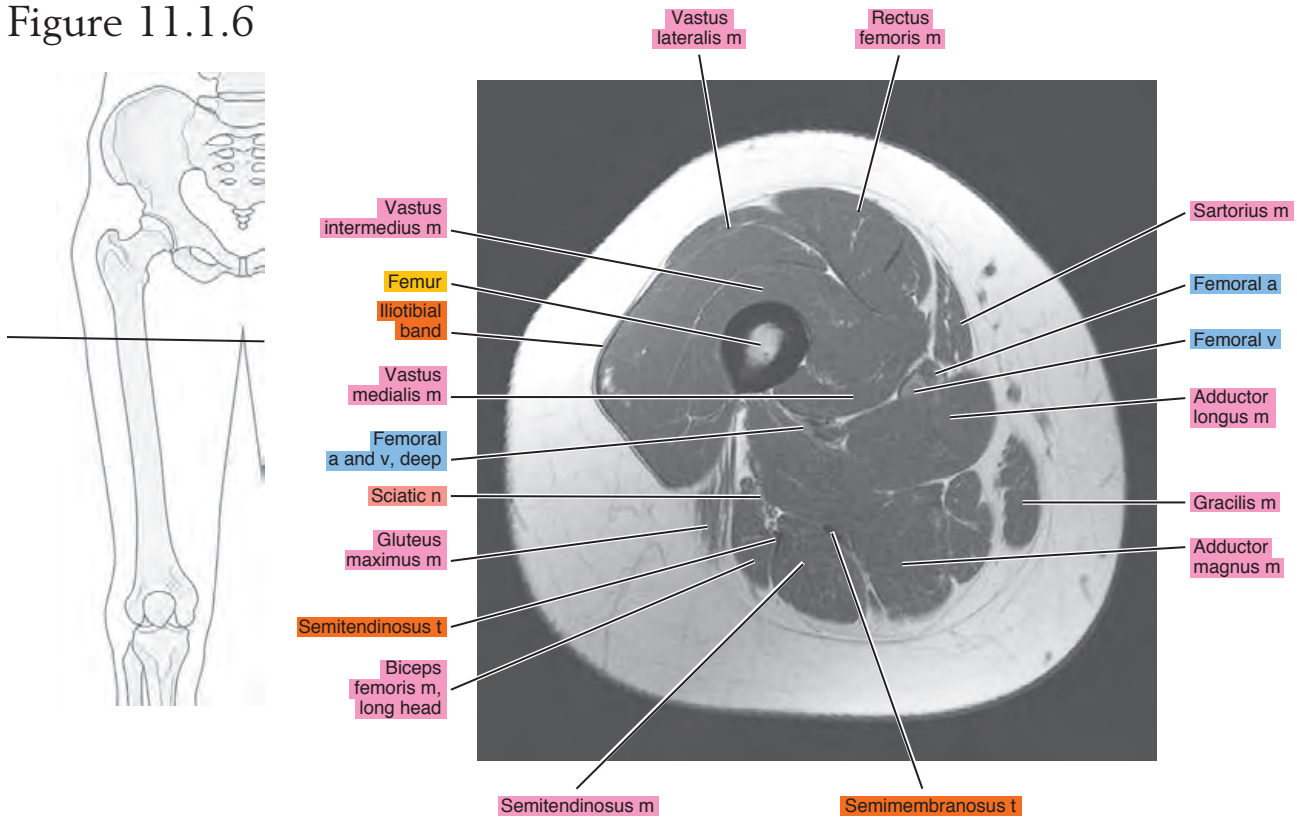


Figure 11.1.7

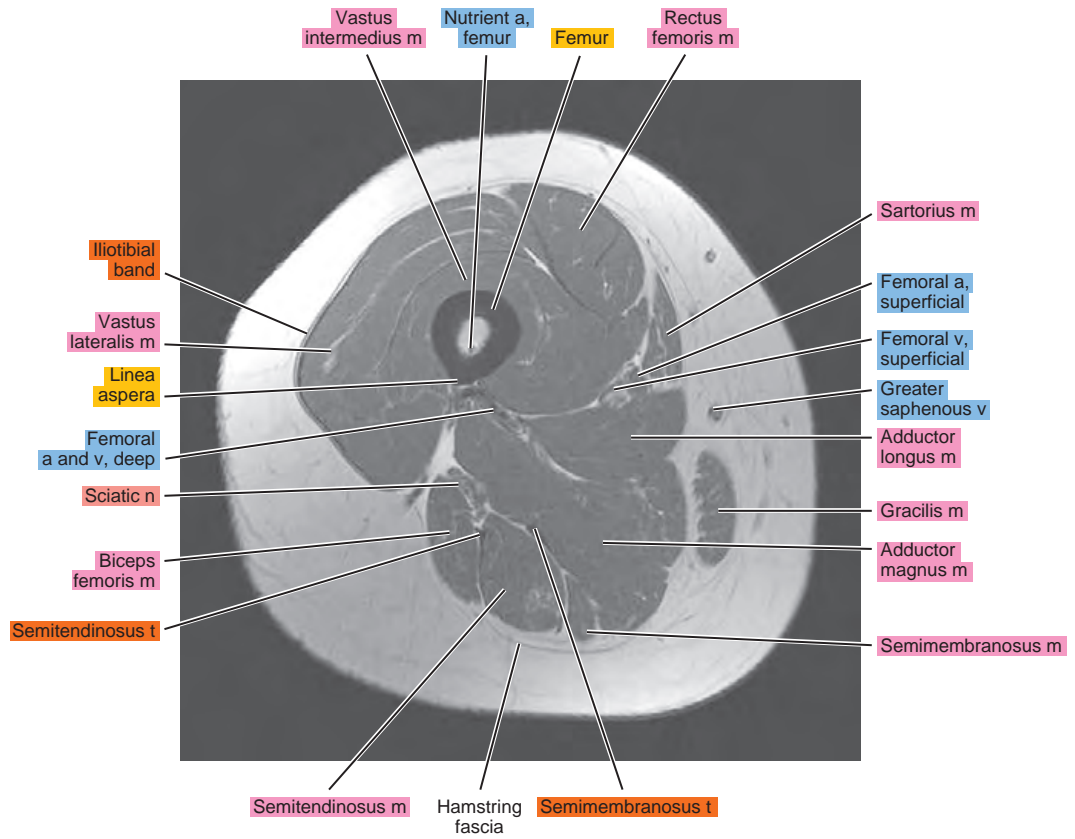
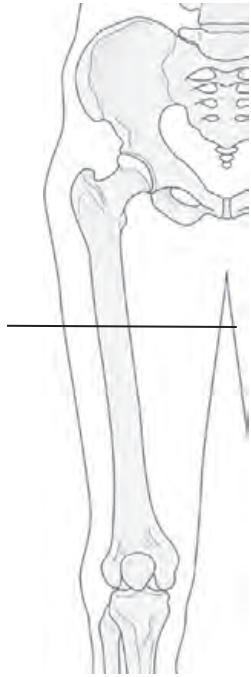


Figure 11.1.8

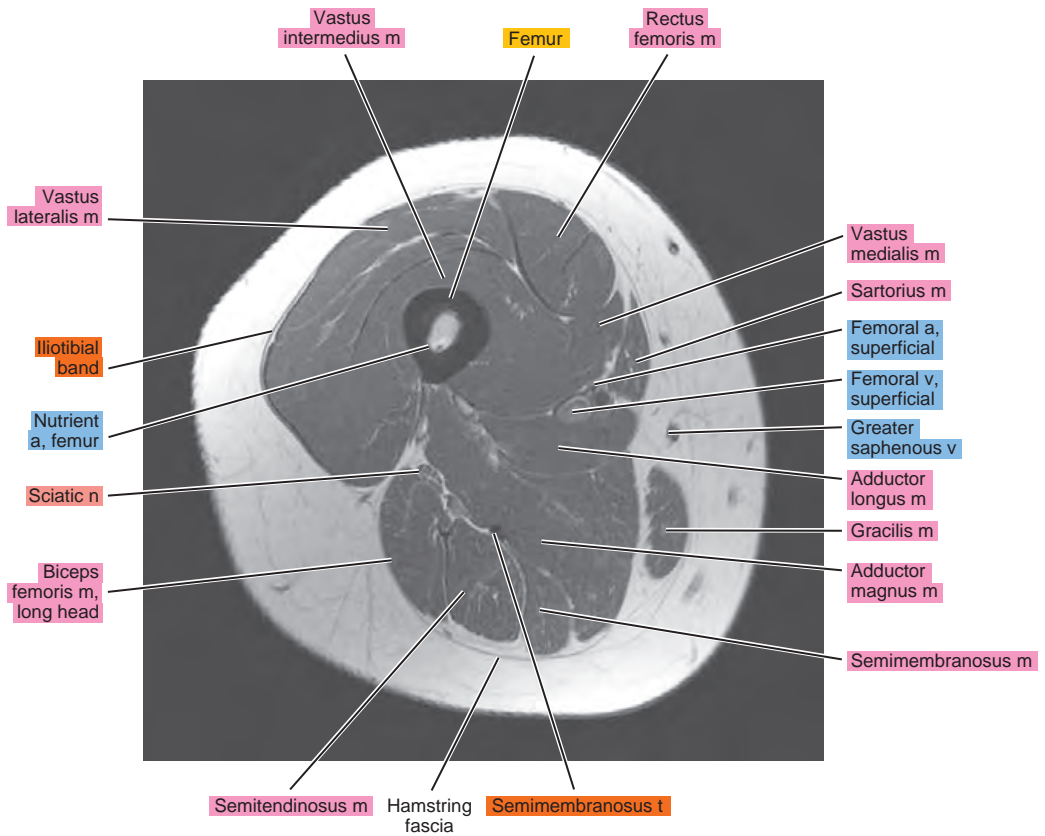
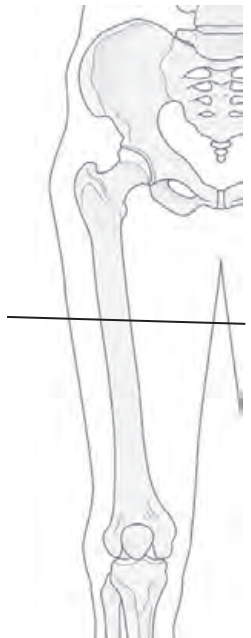


Figure 11.1.9

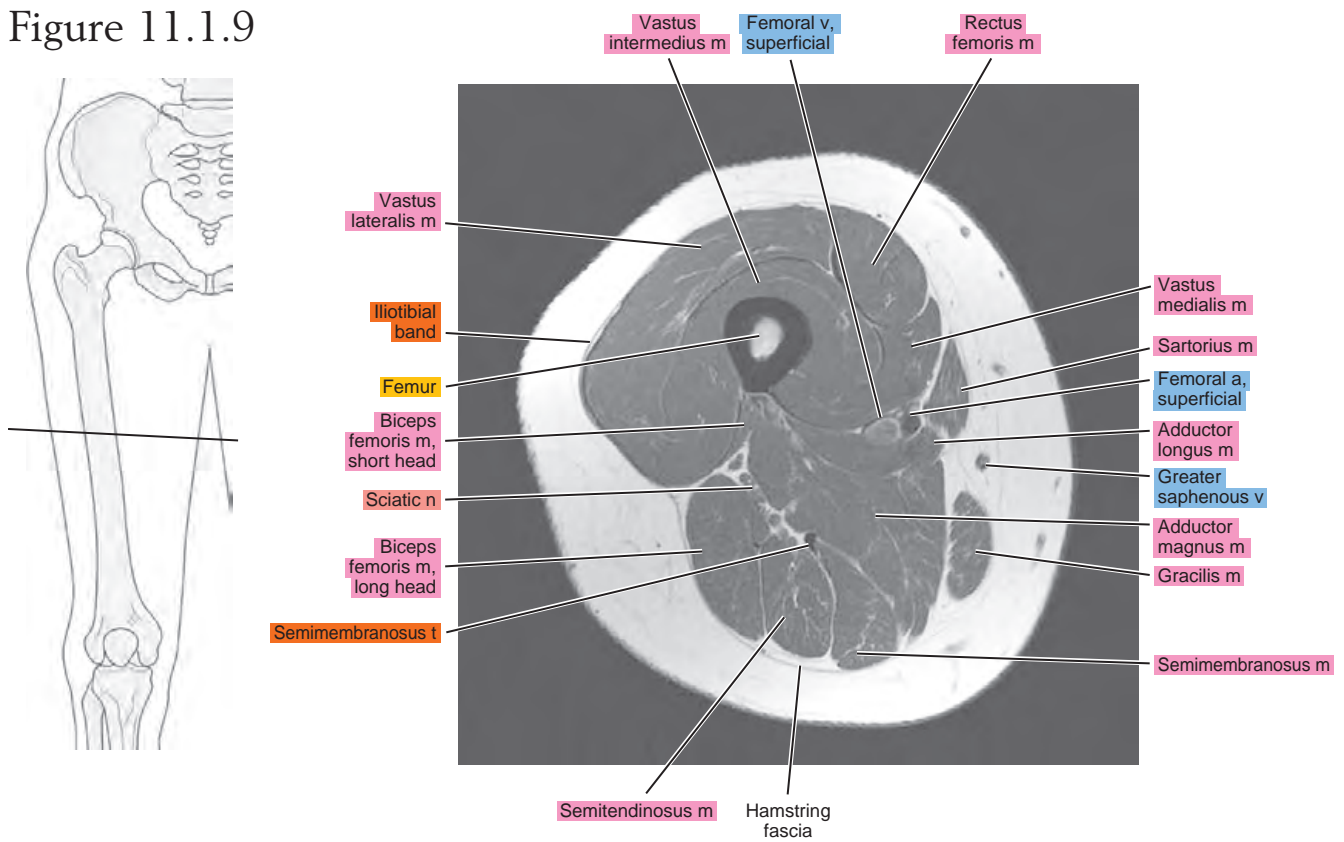


Figure 11.1.10

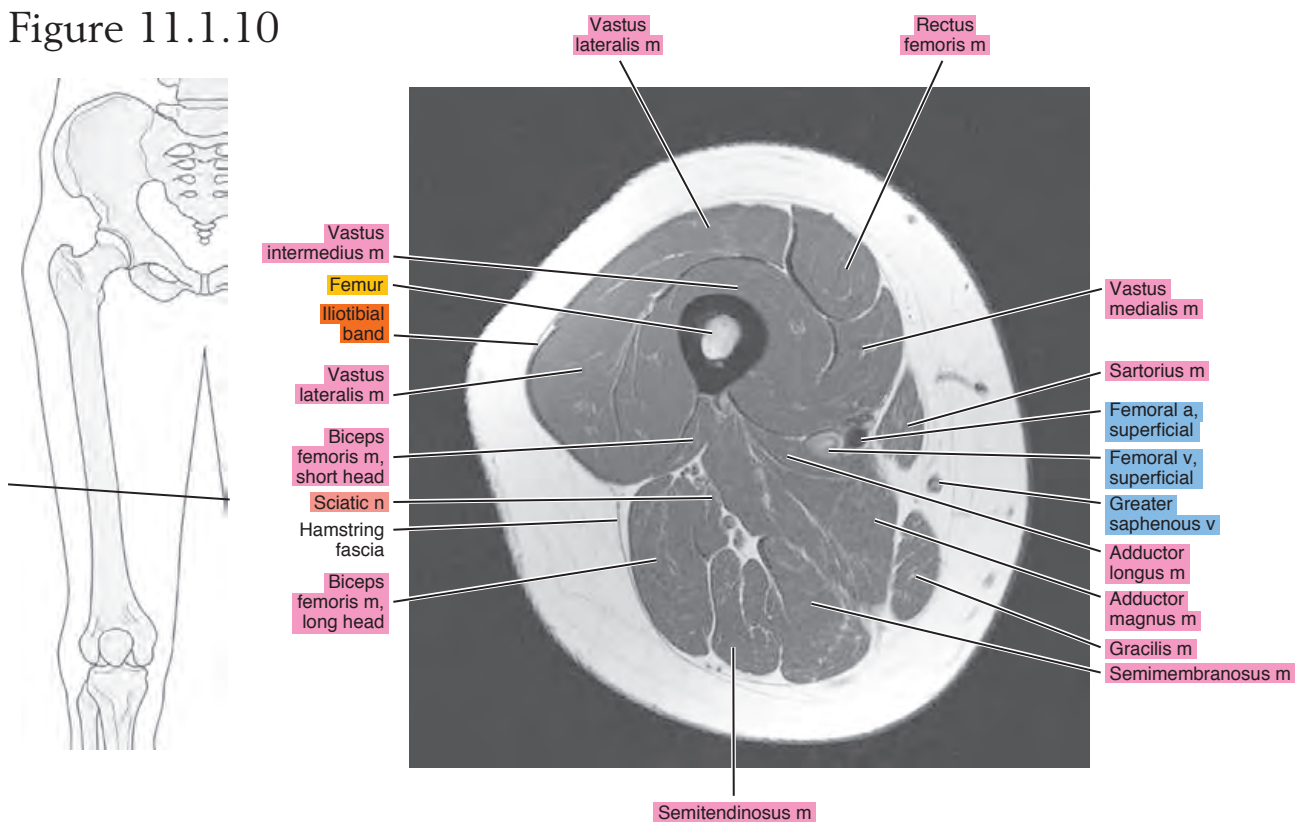


Figure 11.1.11

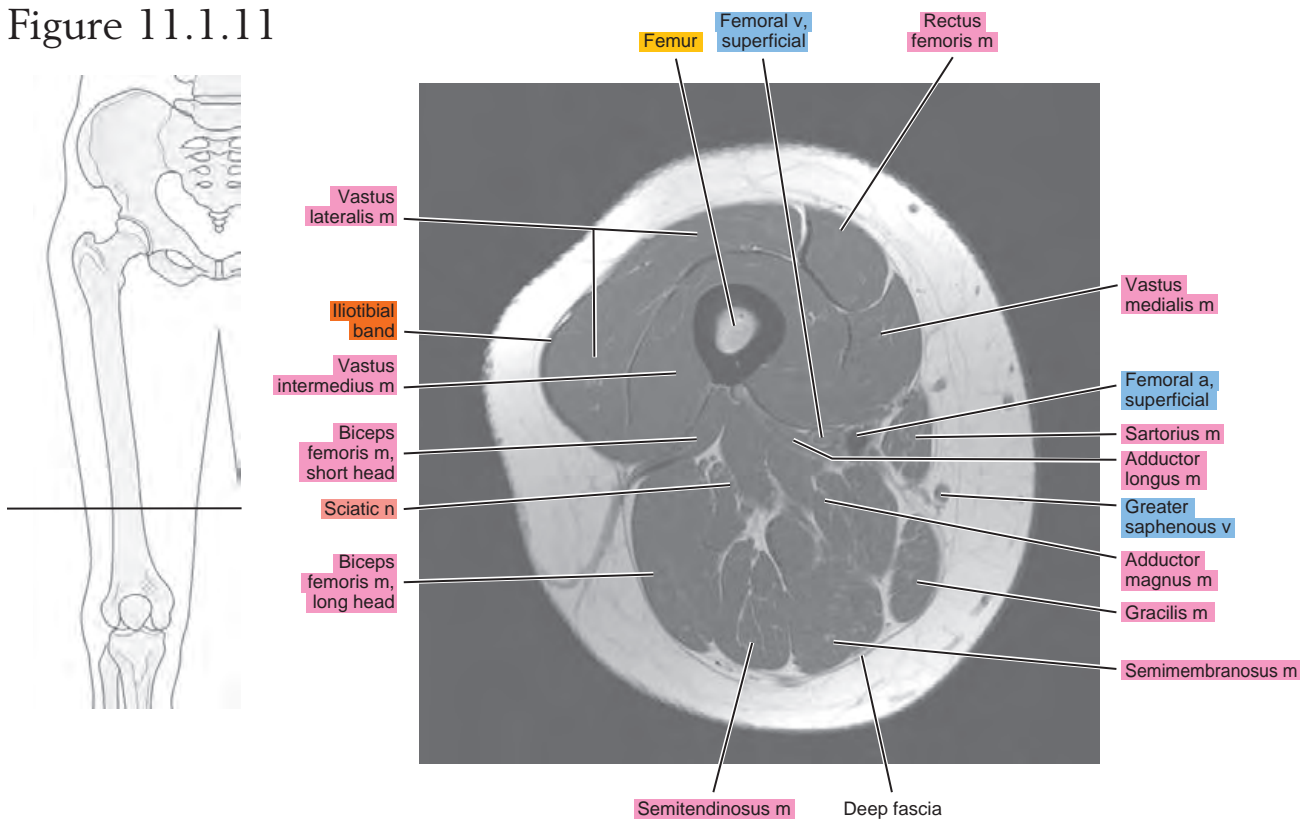


Figure 11.1.12

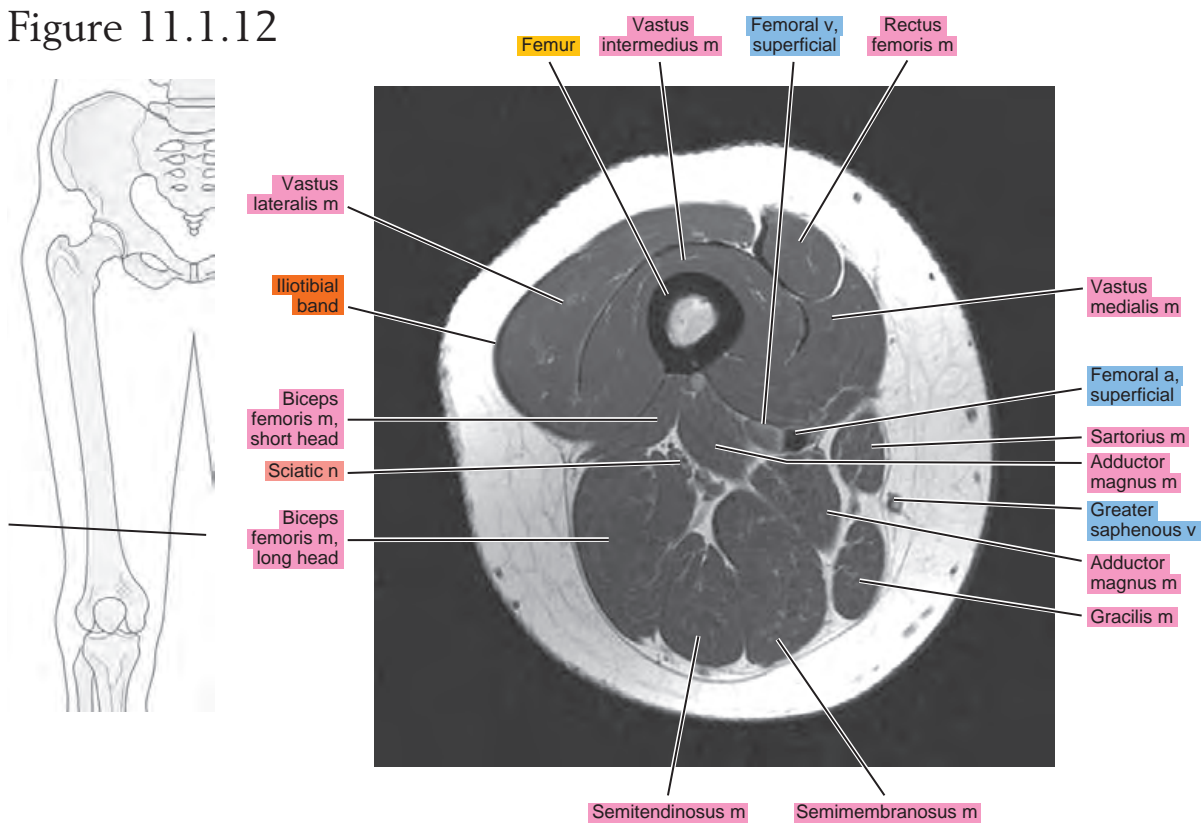


Figure 11.1.13

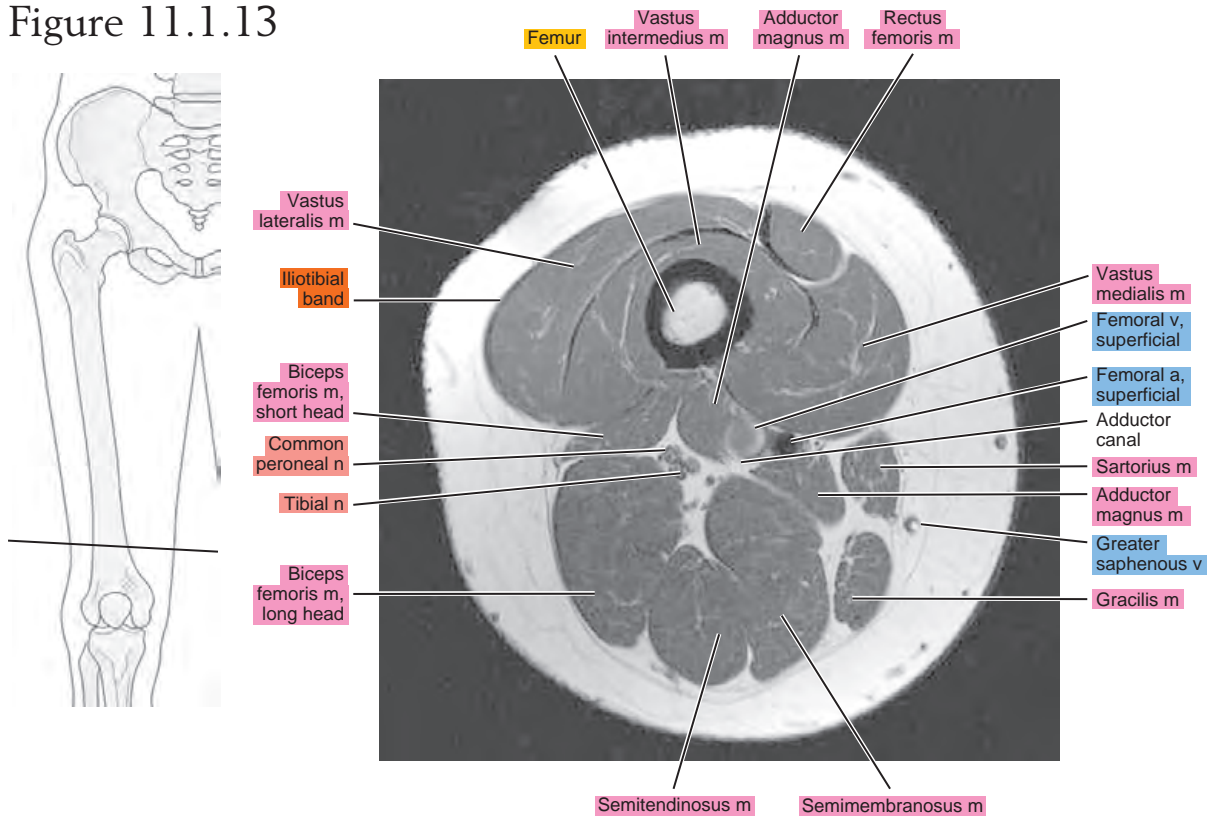


Figure 11.1.14

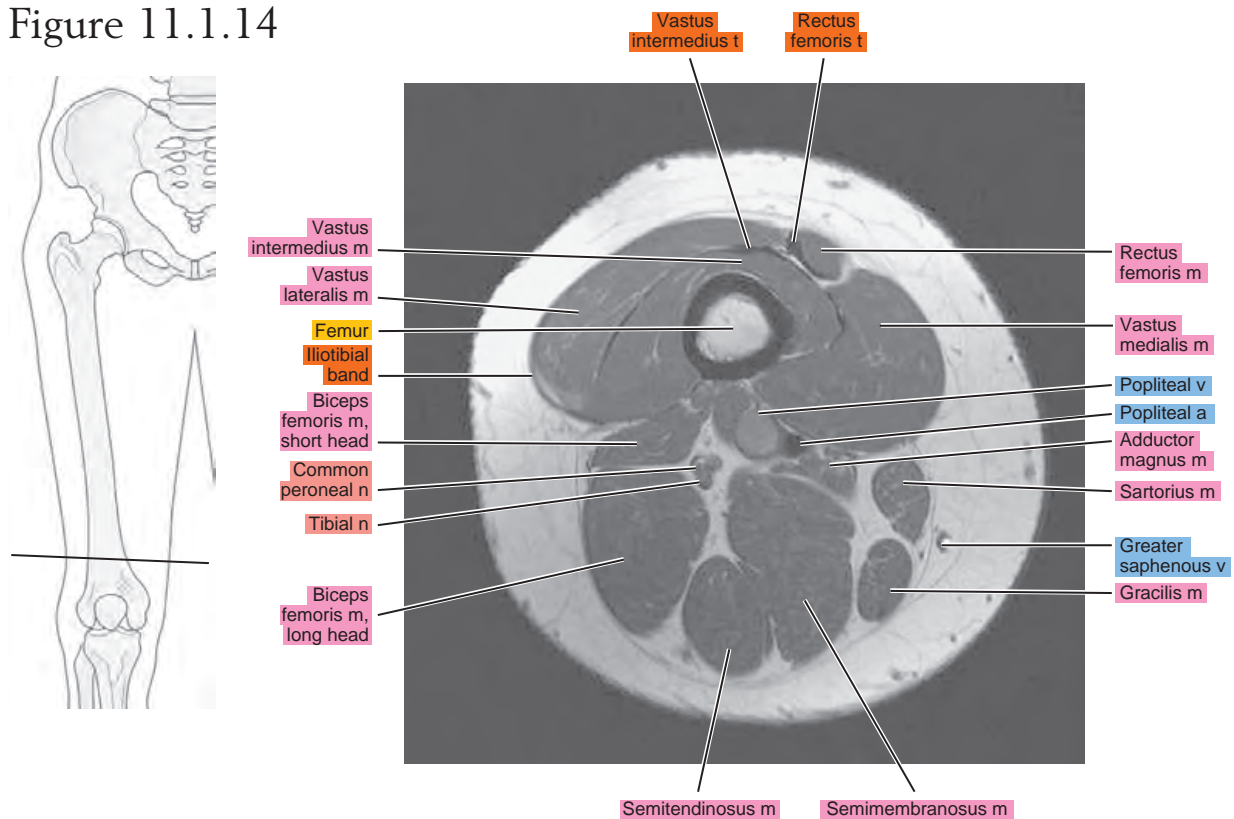


Figure 11.1.15

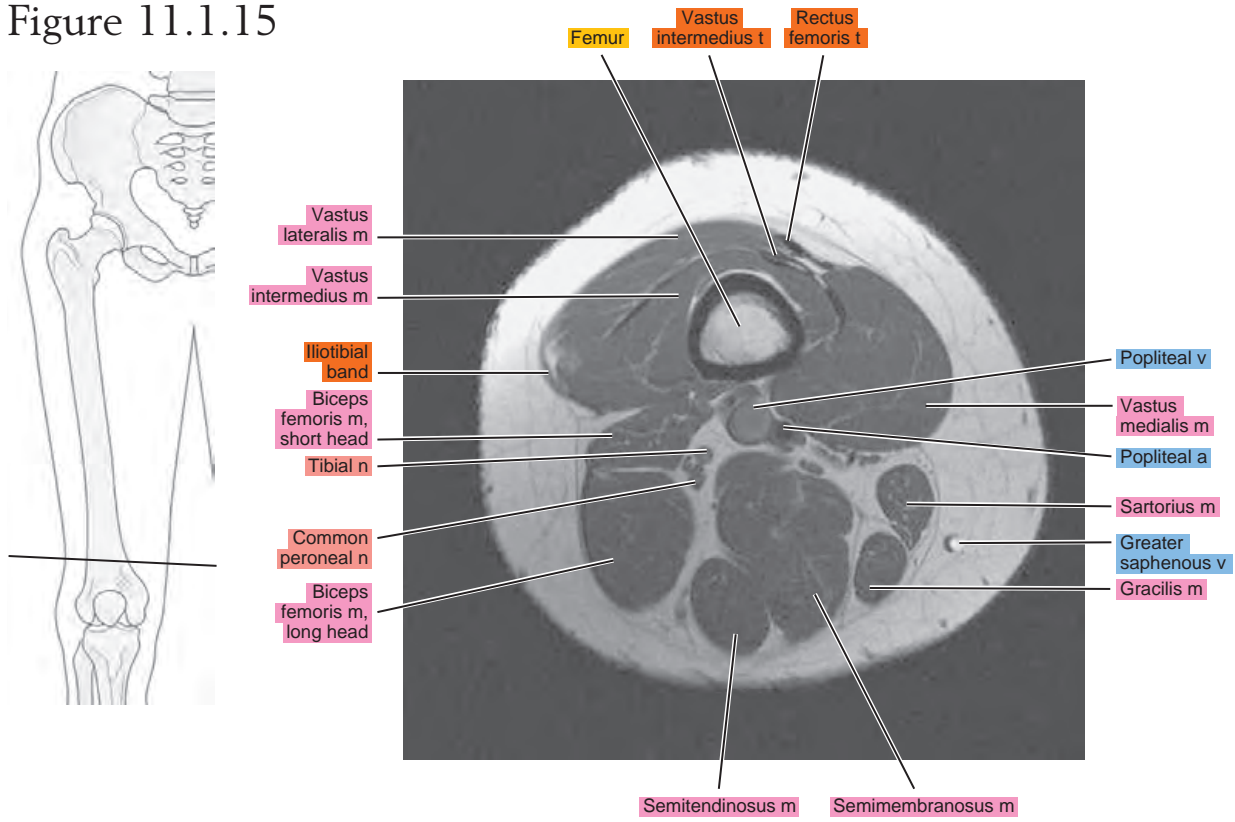
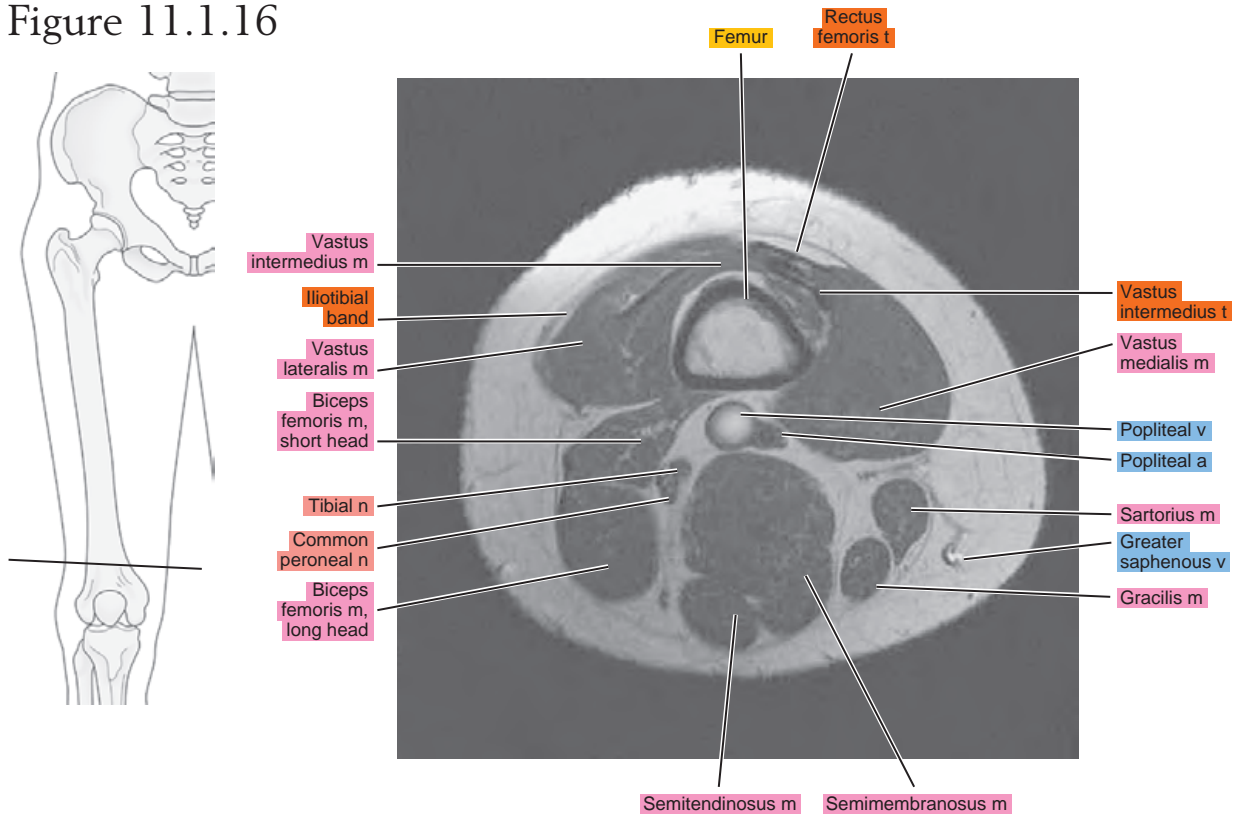


Figure 11.1.16



SAGITTAL

Figure 11.2.1

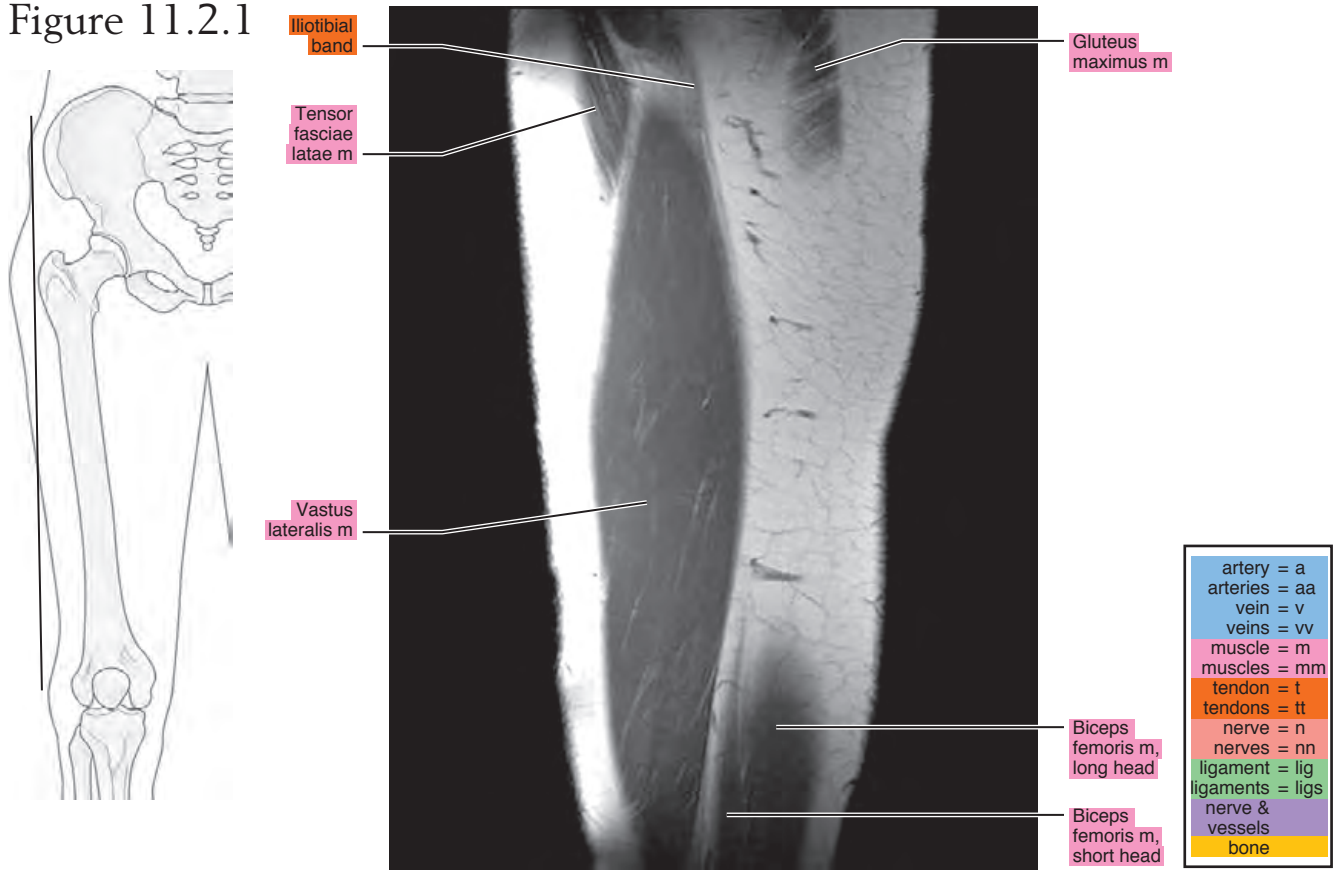


Figure 11.2.2

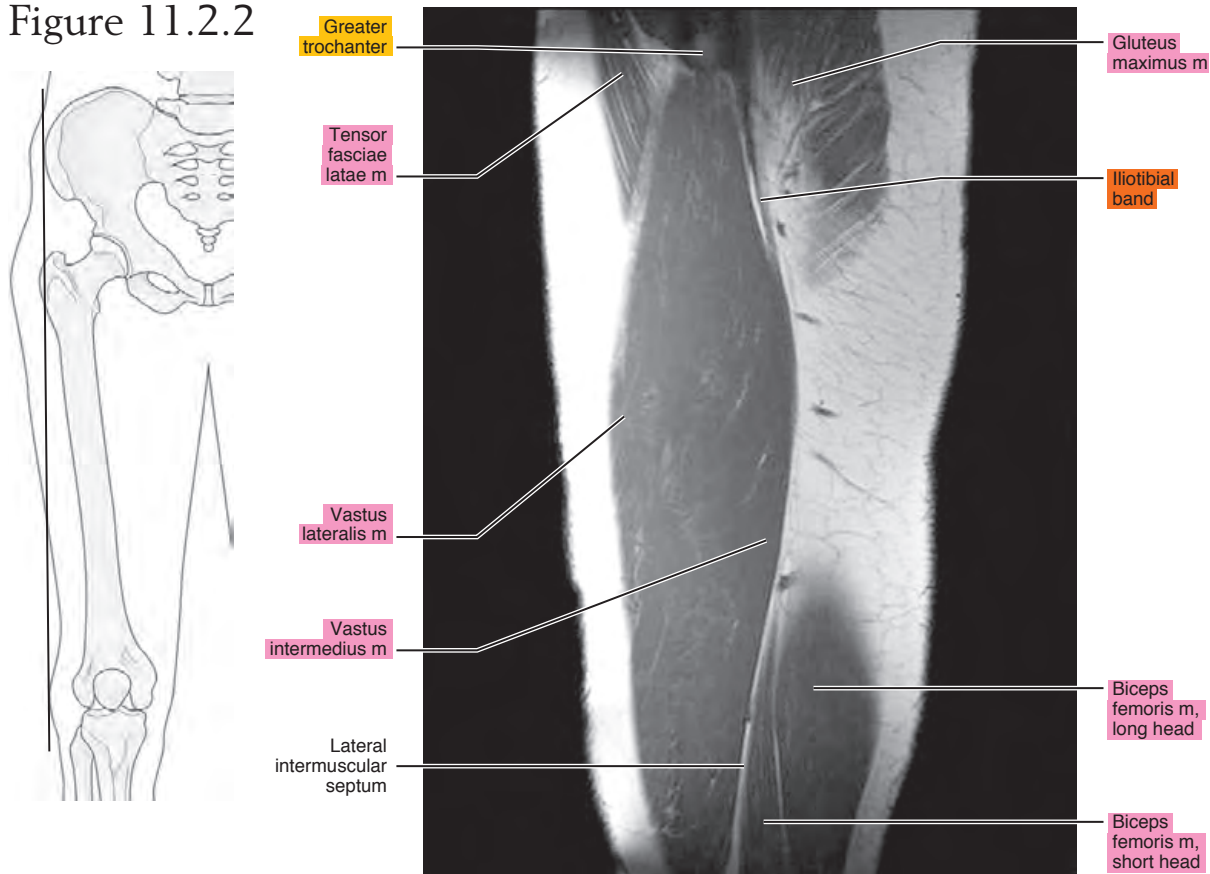


Figure 11.2.3

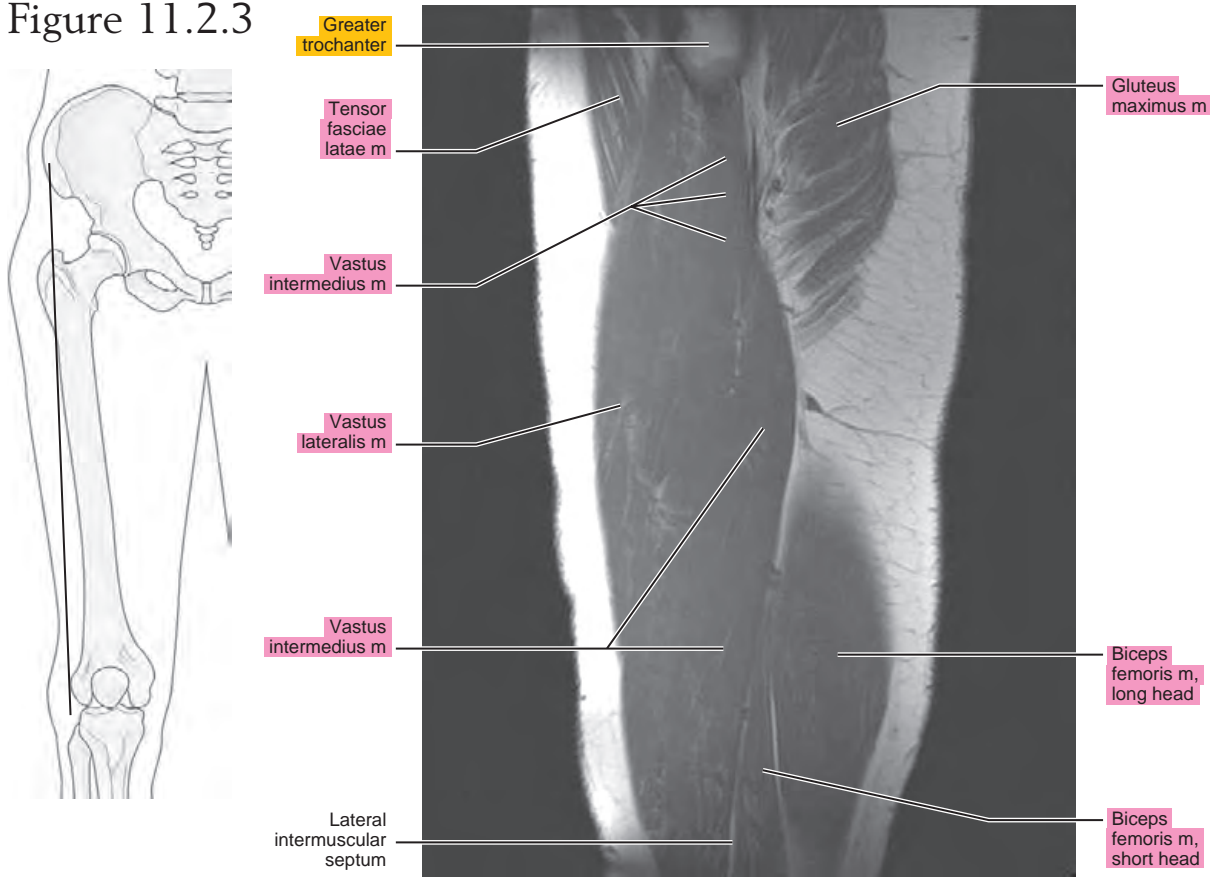


Figure 11.2.4

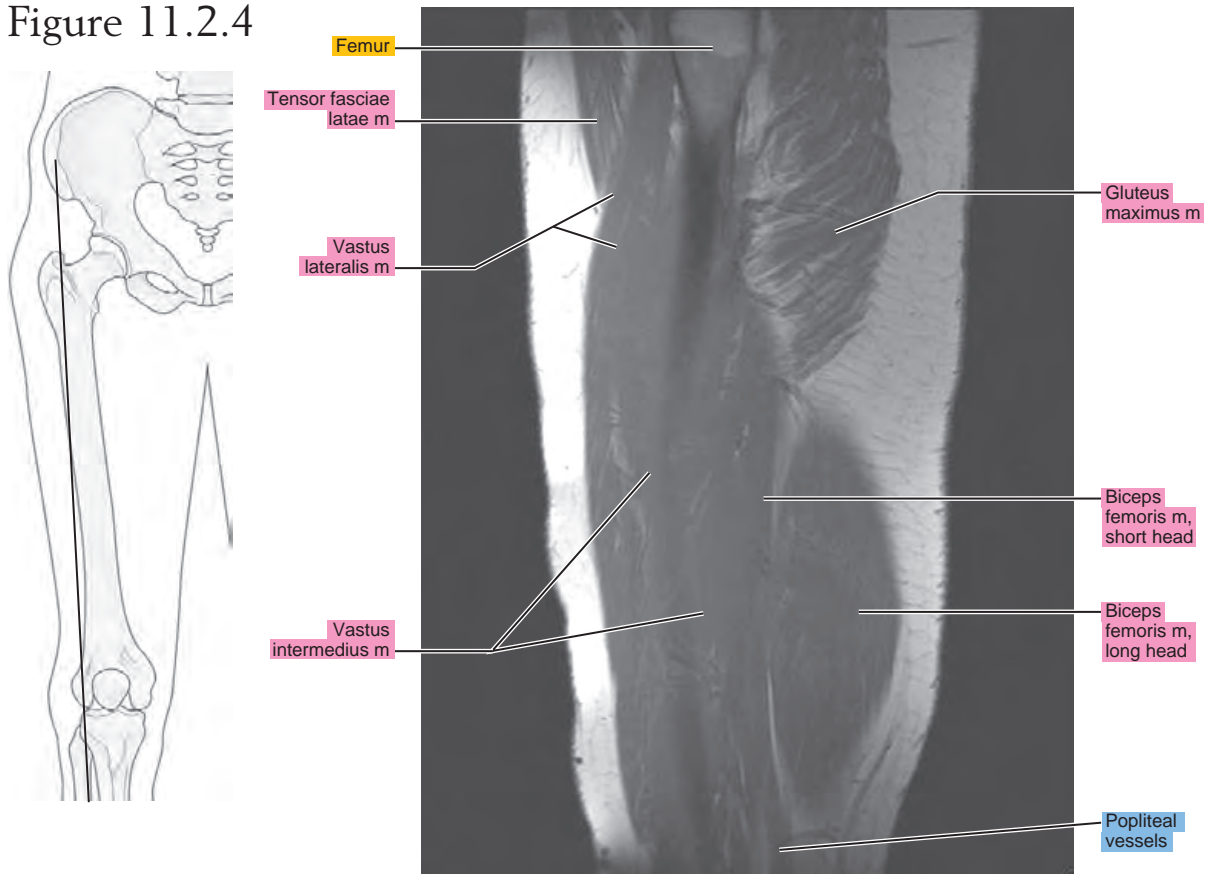


Figure 11.2.5

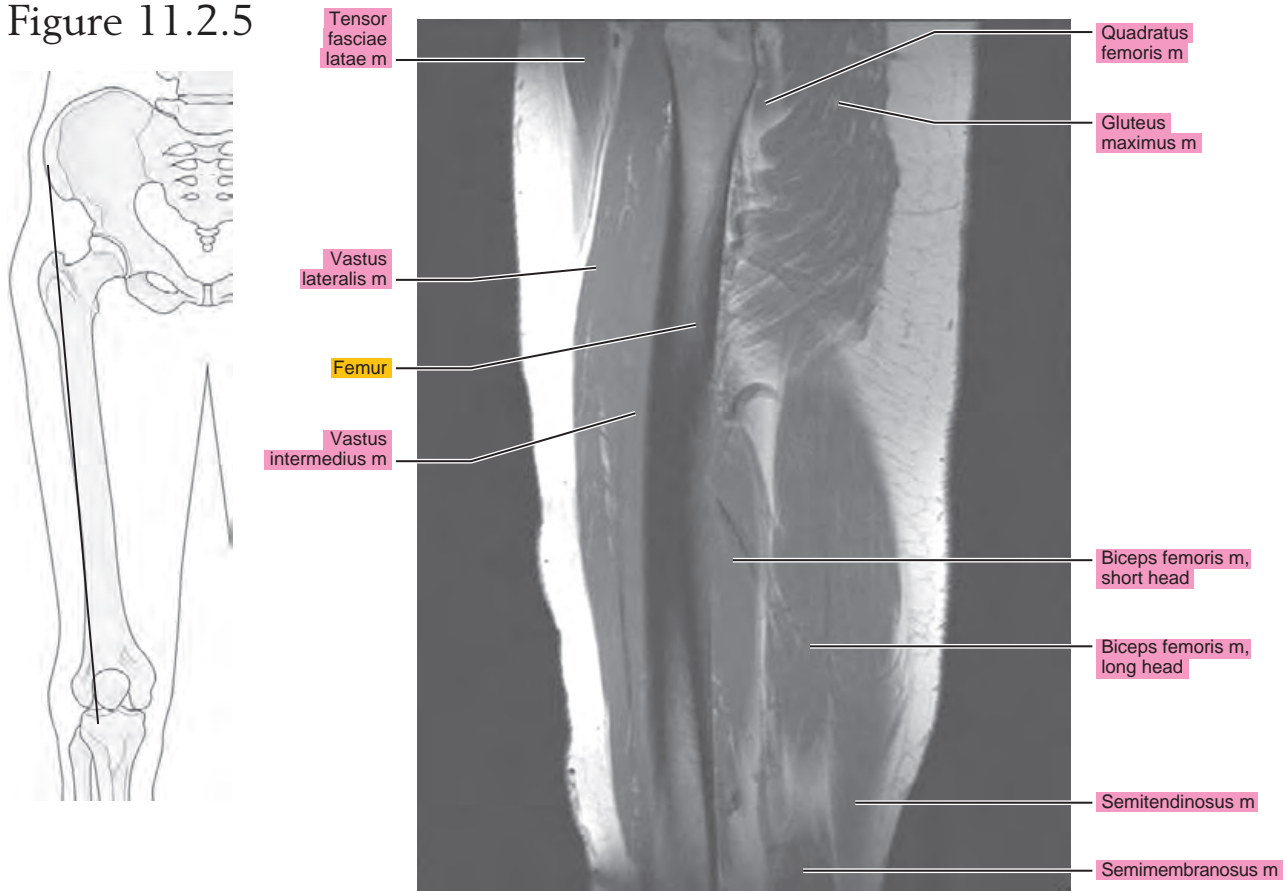


Figure 11.2.6

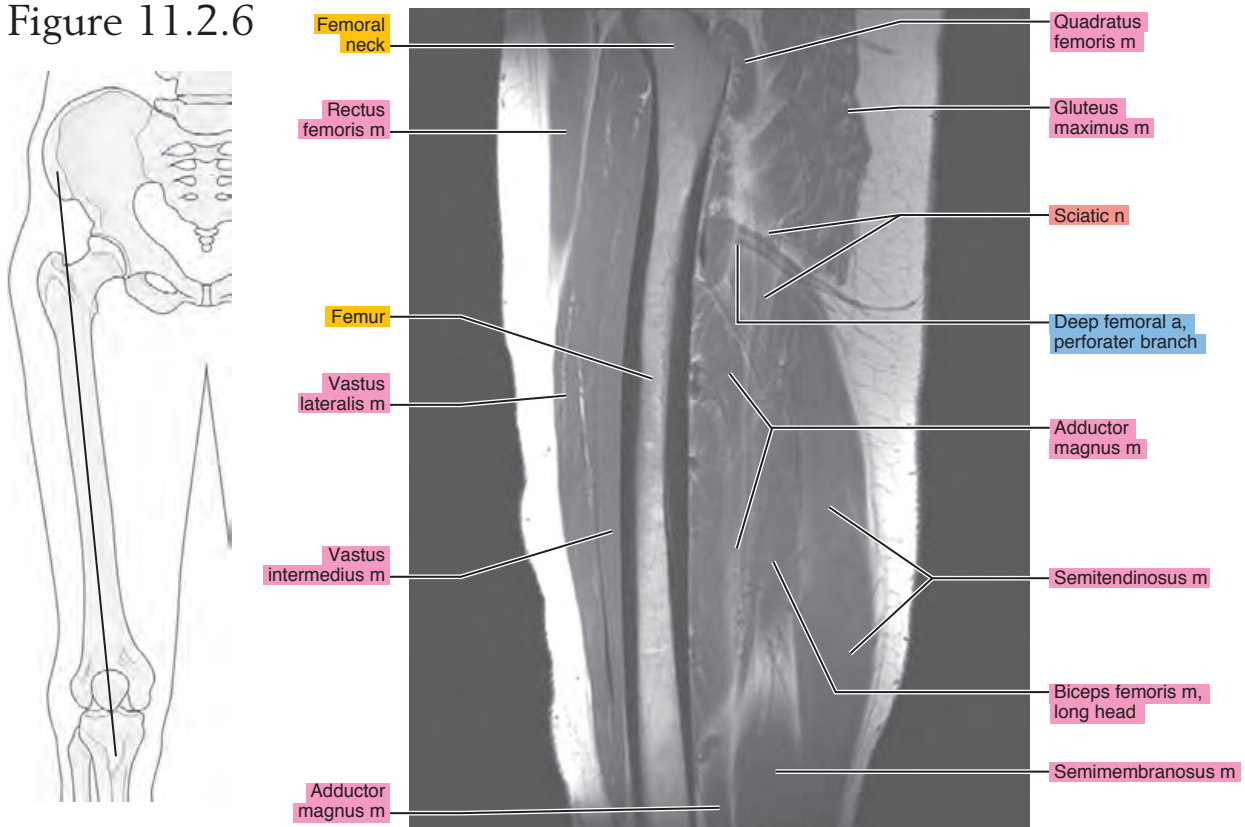


Figure 11.2.7

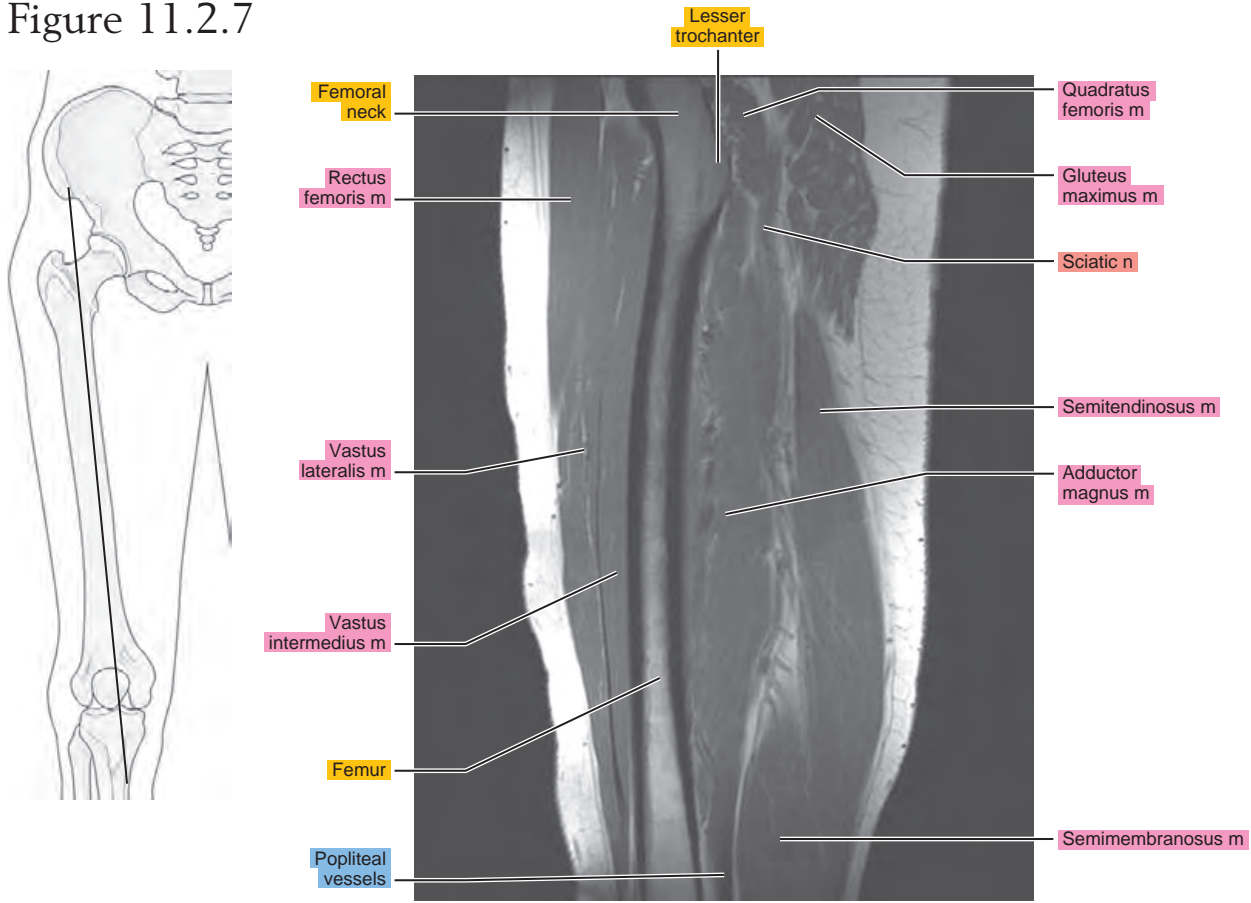


Figure 11.2.8

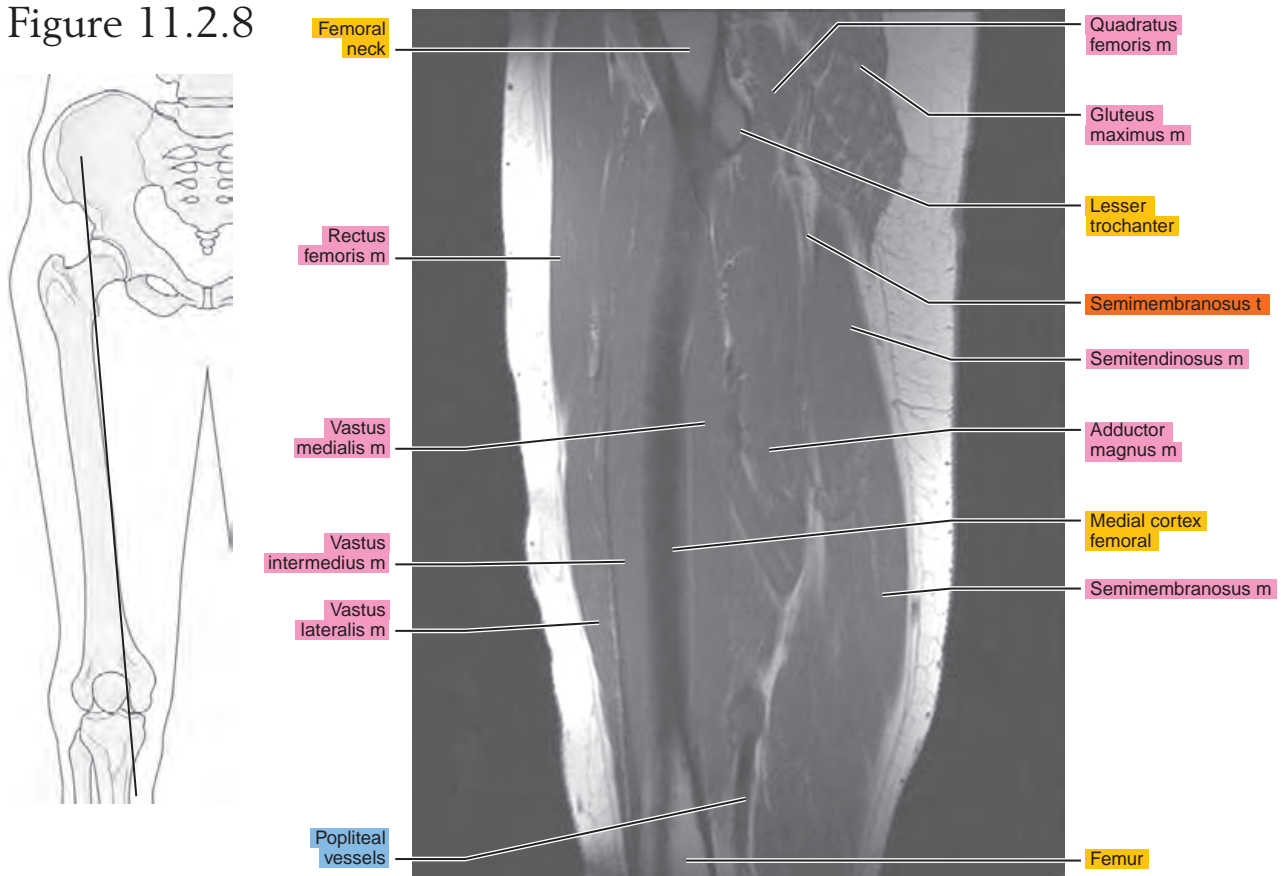


Figure 11.2.9

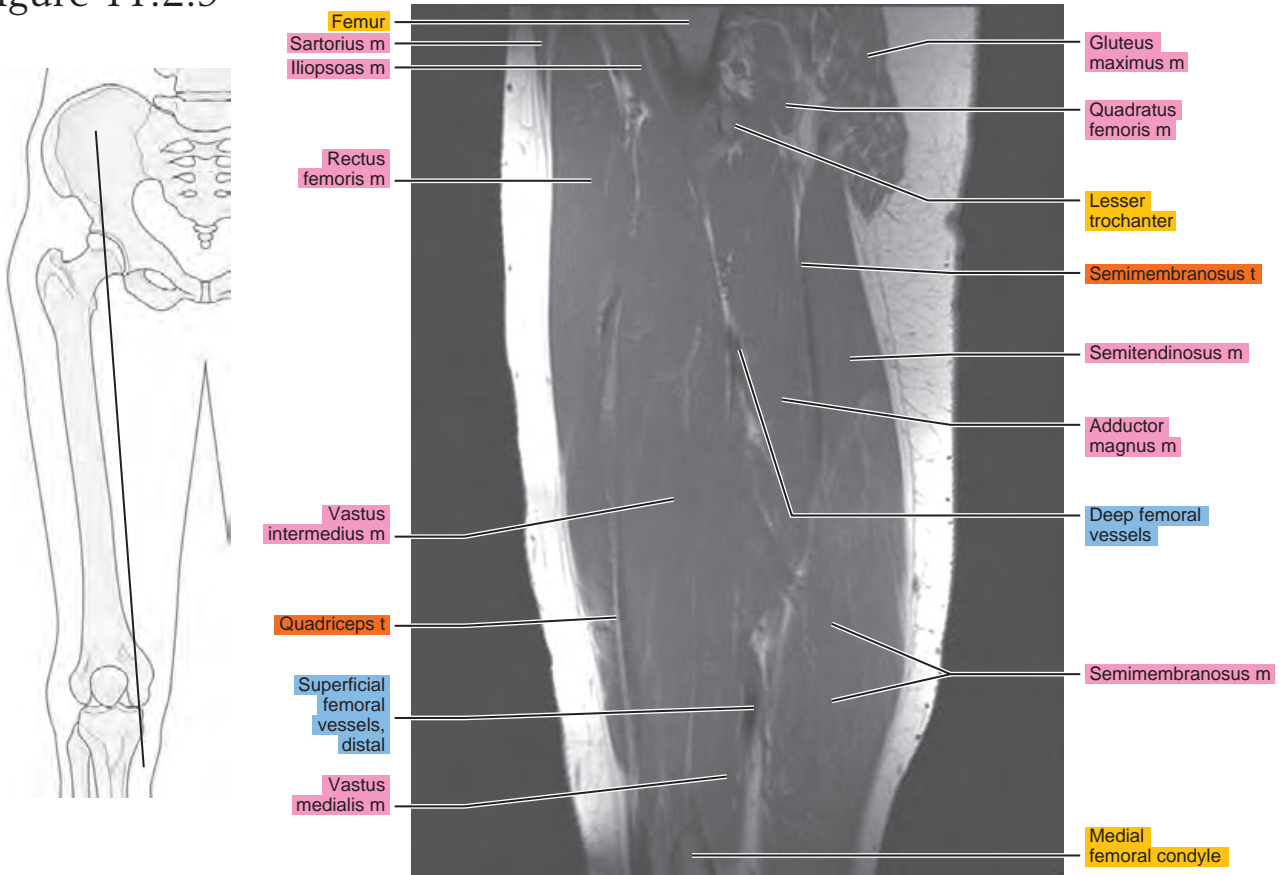


Figure 11.2.10

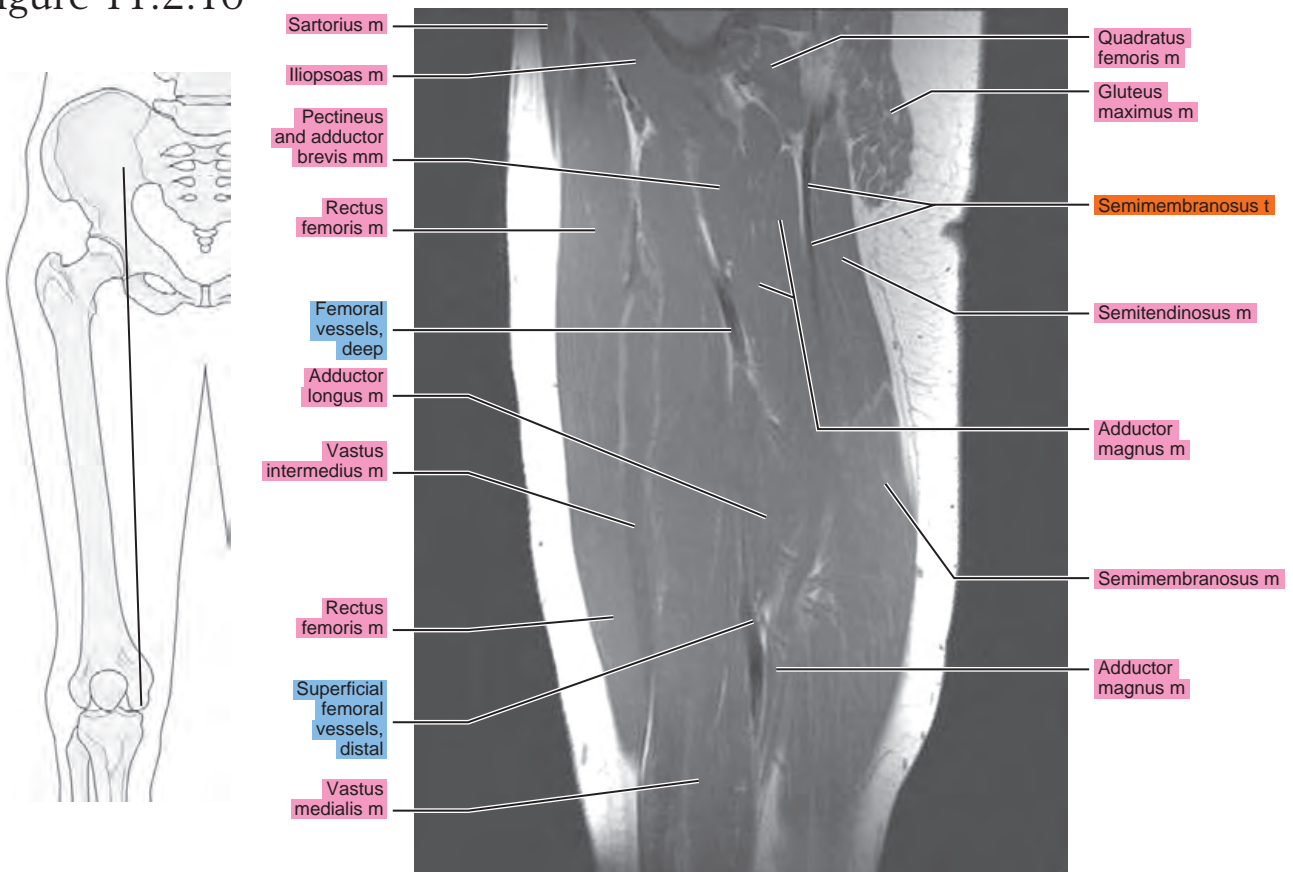


Figure 11.2.11

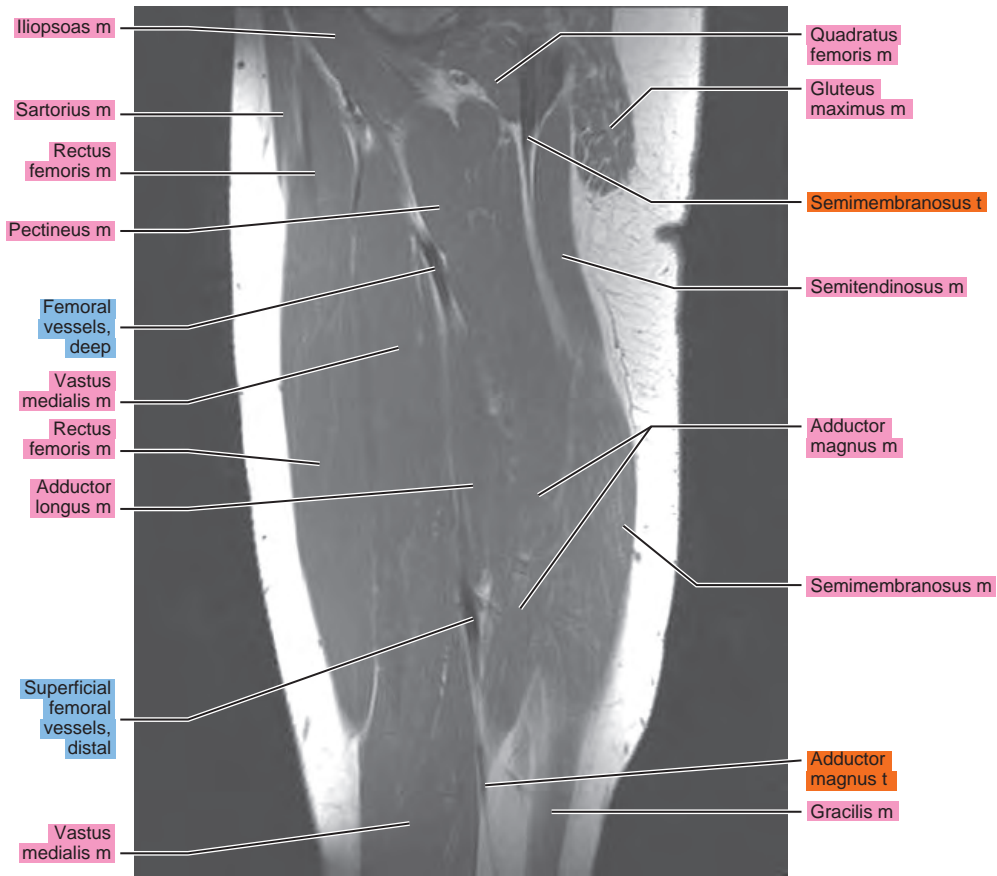
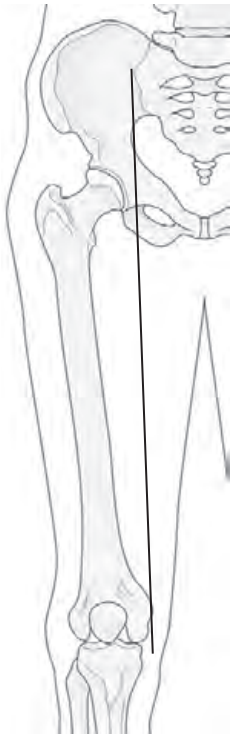


Figure 11.2.12

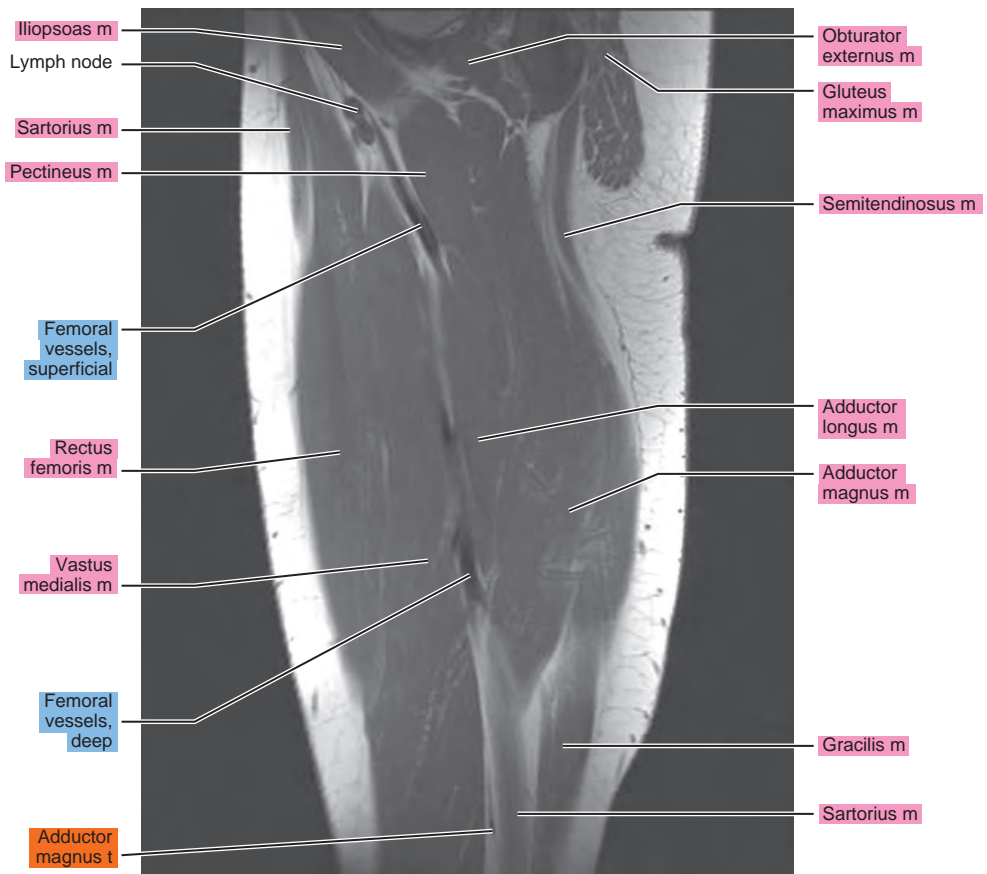
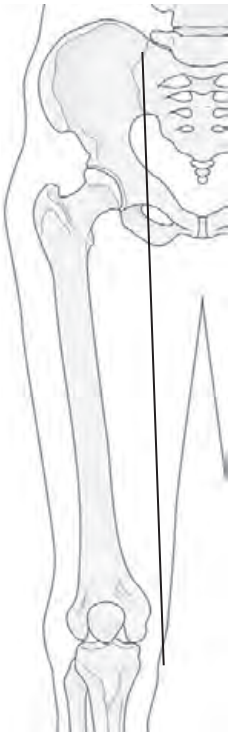


Figure 11.2.13

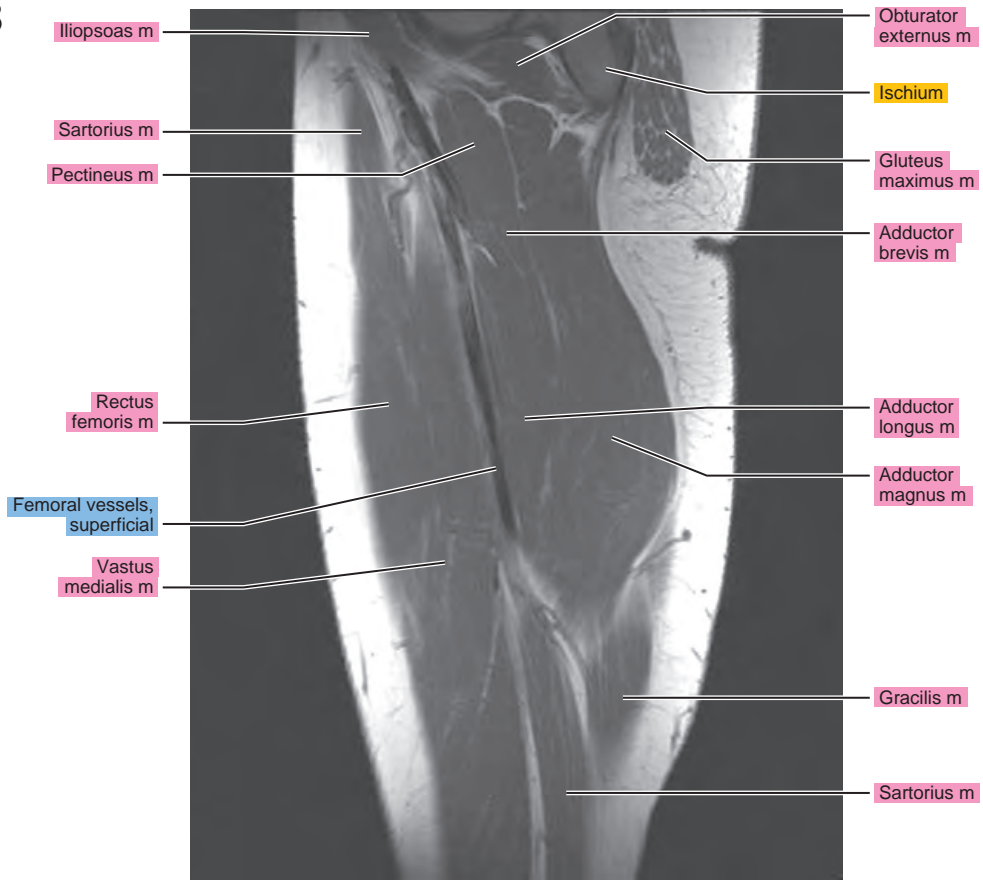
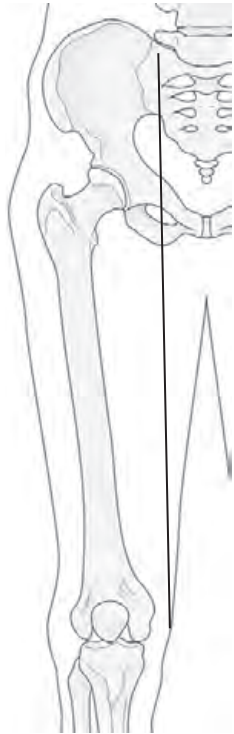


Figure 11.2.14

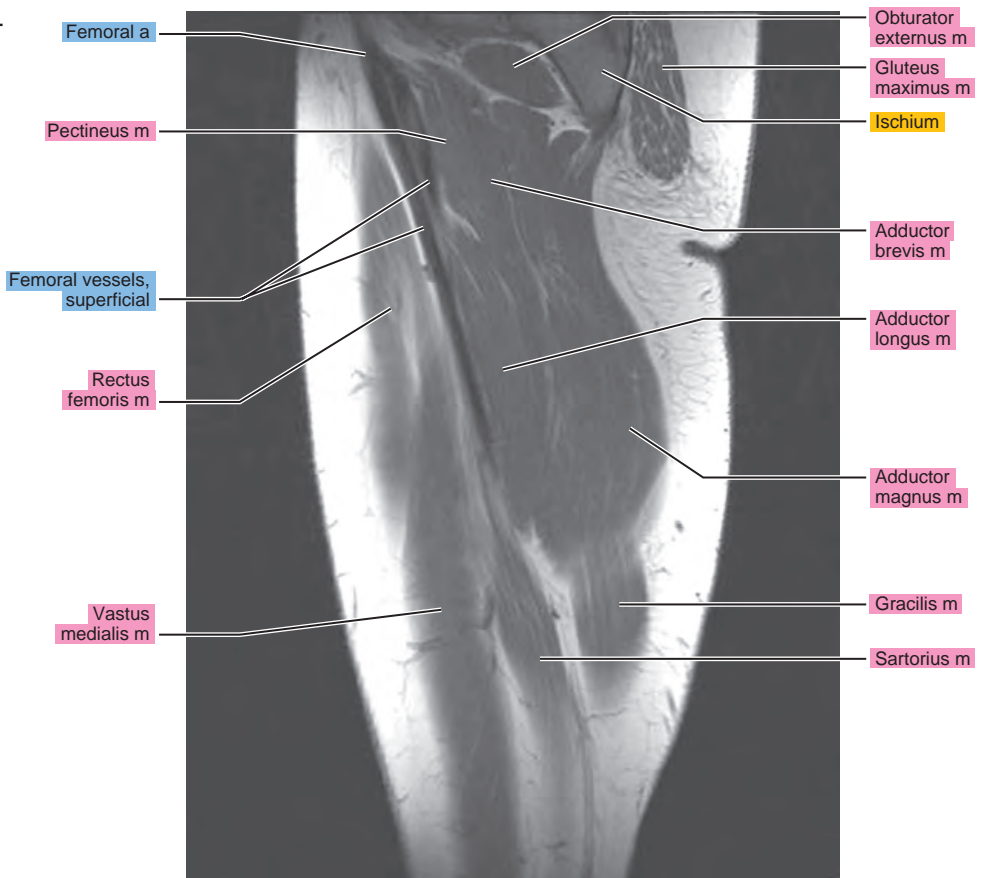
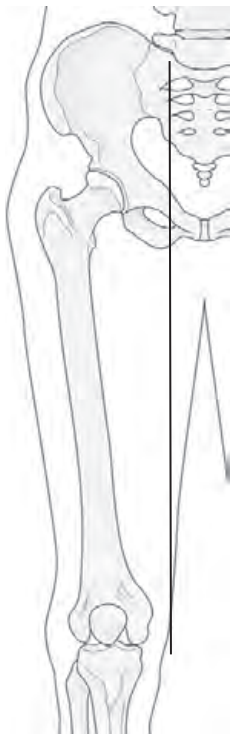


Figure 11.2.15

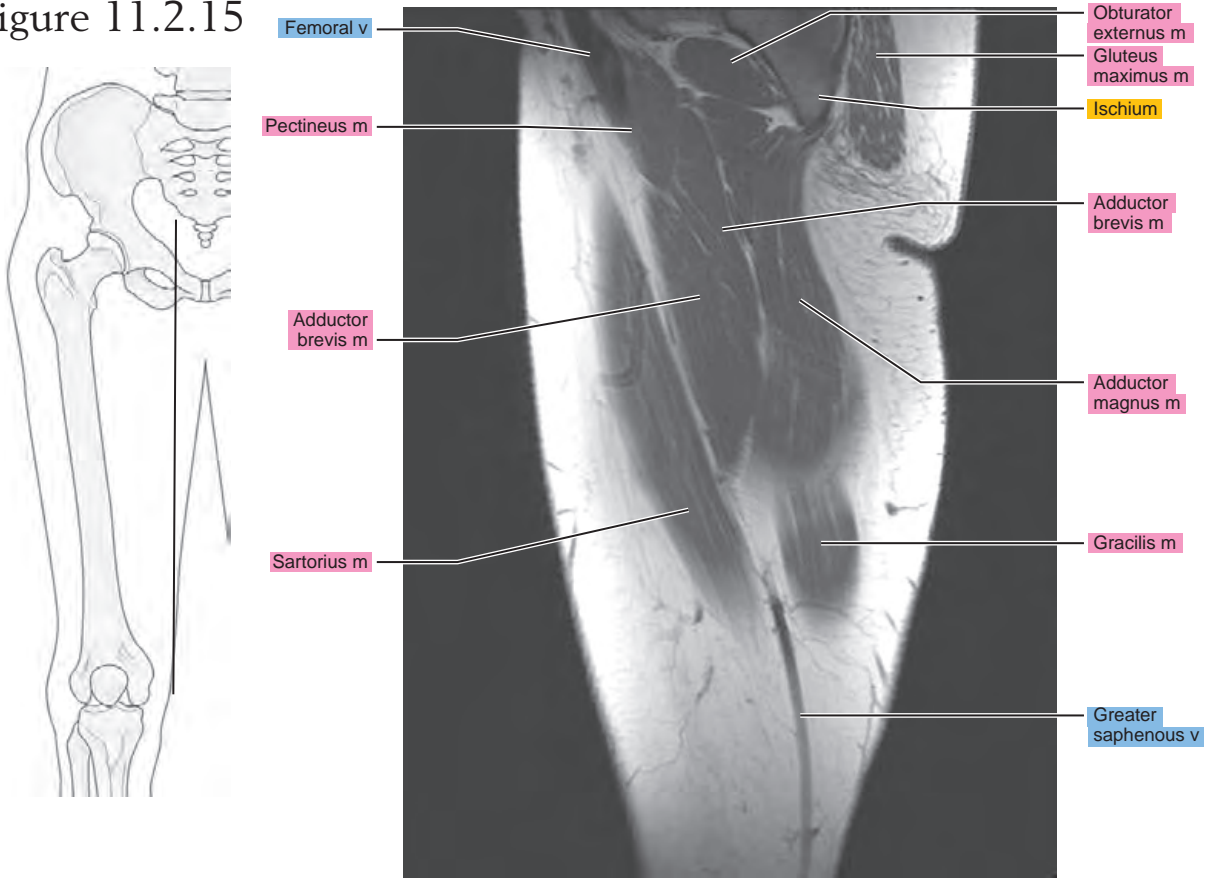


Figure 11.2.16

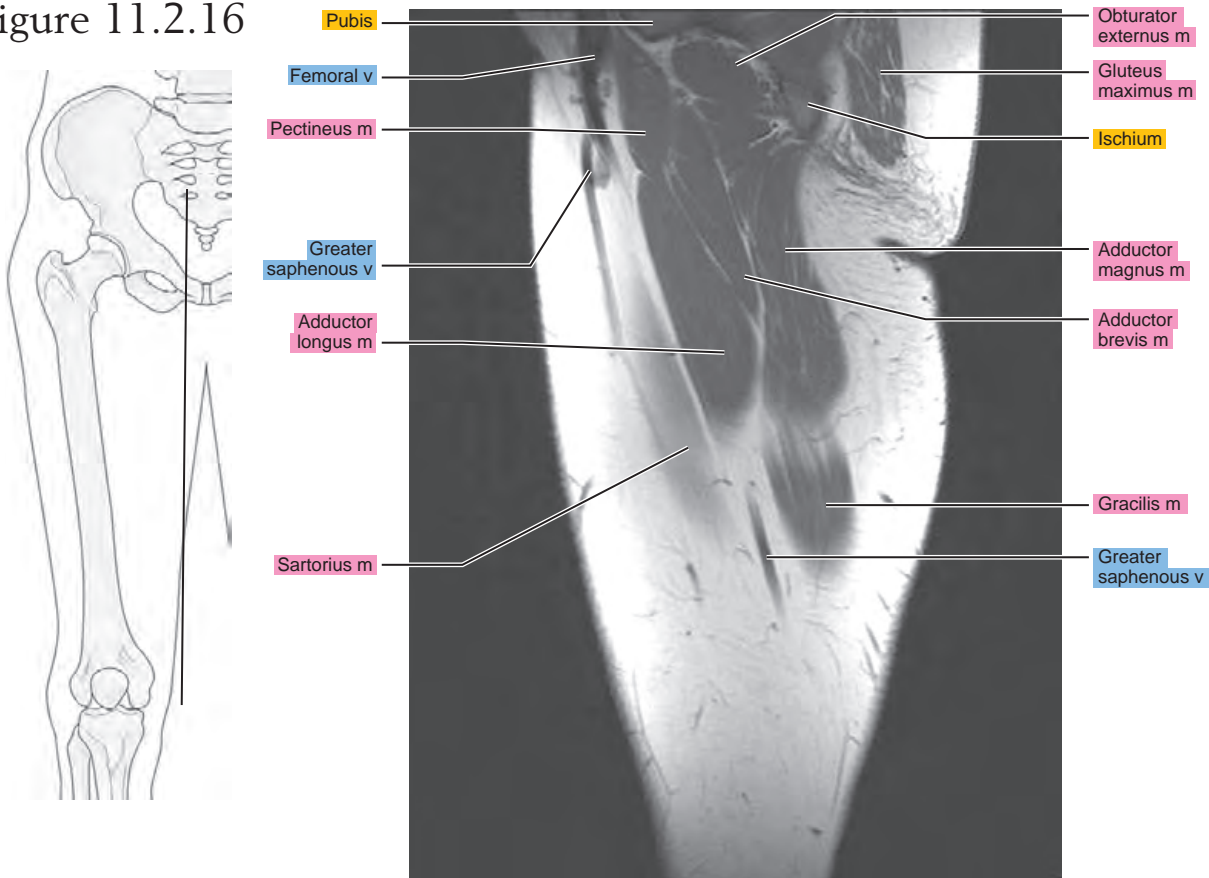
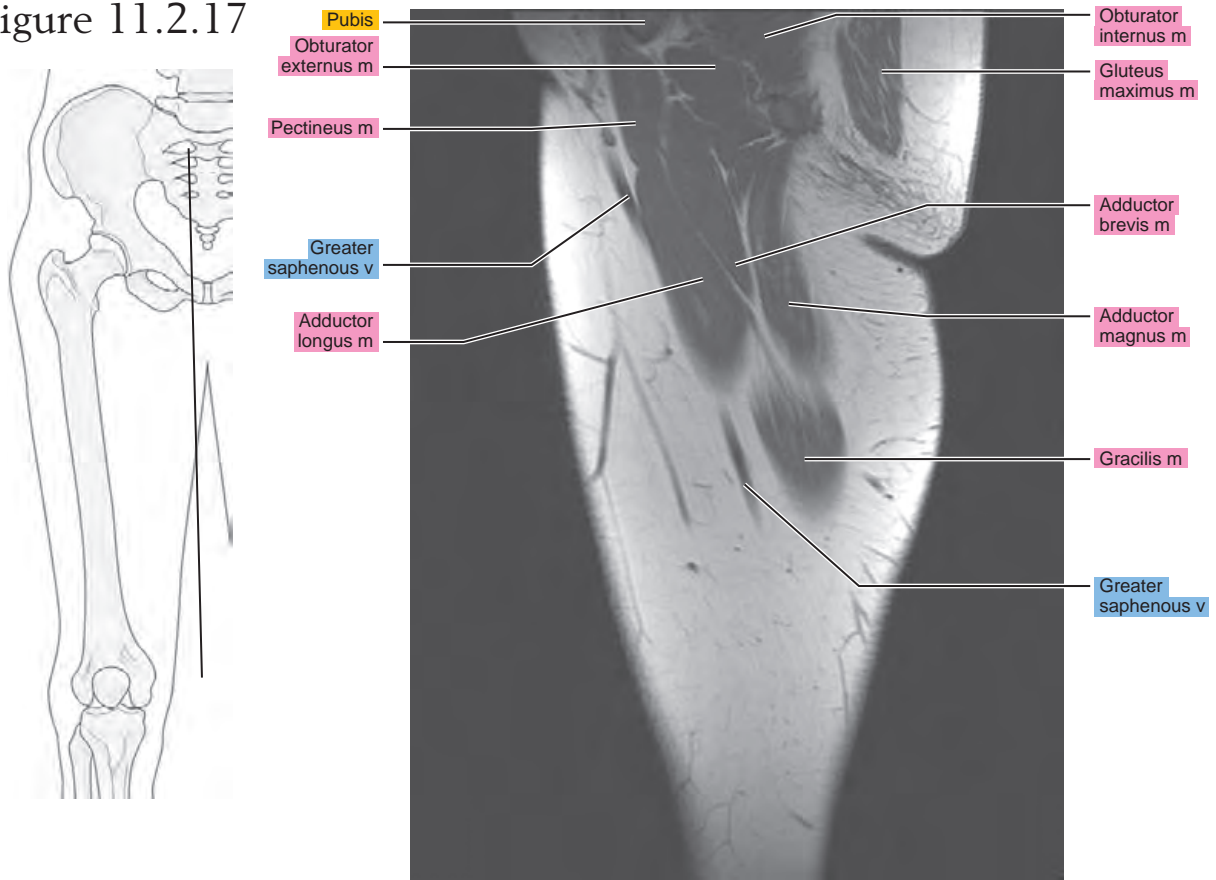
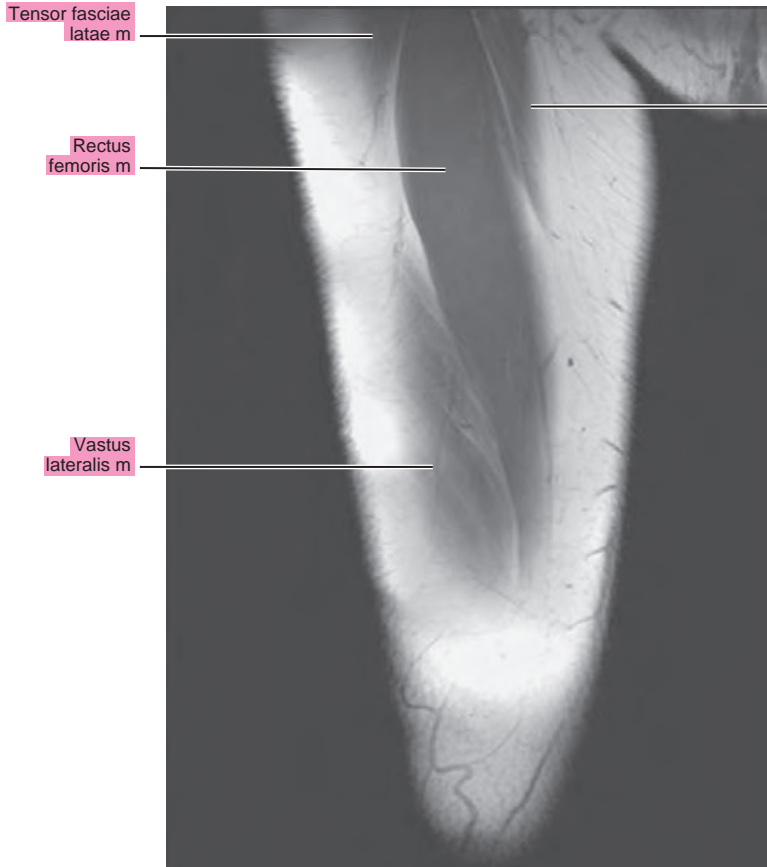
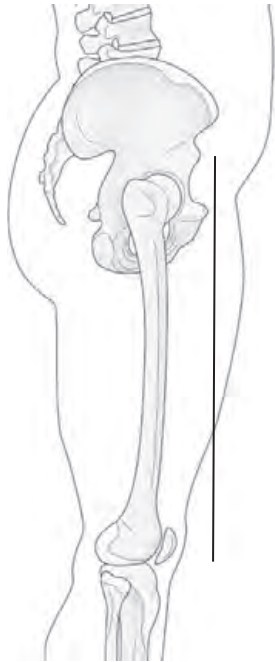


Figure 11.2.17



CORONAL

Figure 11.3.1



artery = a
arteries = aa
vein = v
veins = vv
muscle = m
muscles = mm
tendon = t
tendons = tt
nerve = n
nerves = nn
ligament = lig
ligaments = lig
nerve & vessels
bone

Figure 11.3.2

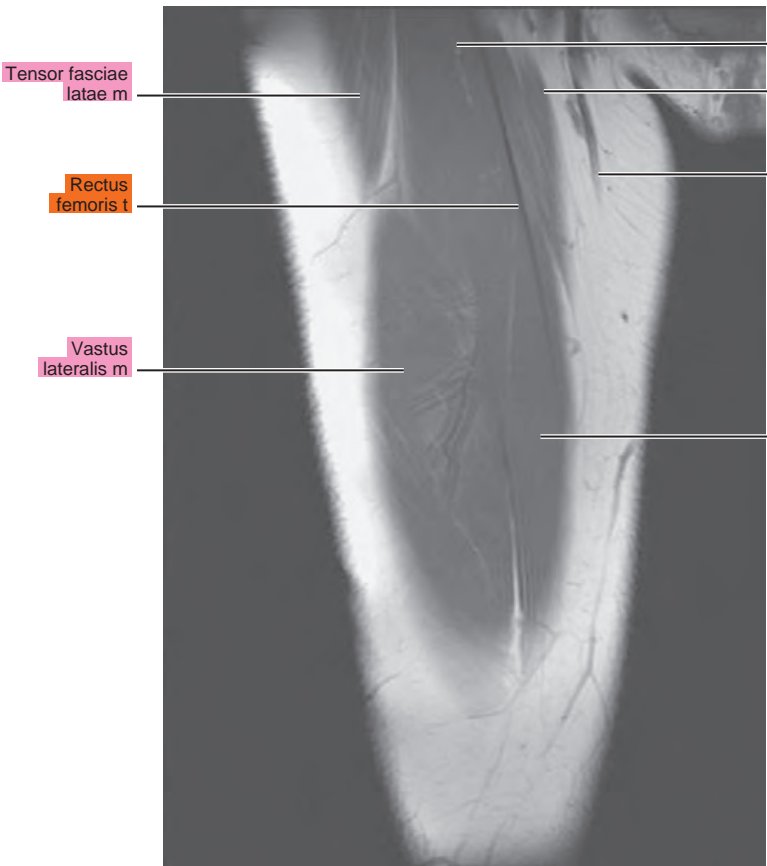
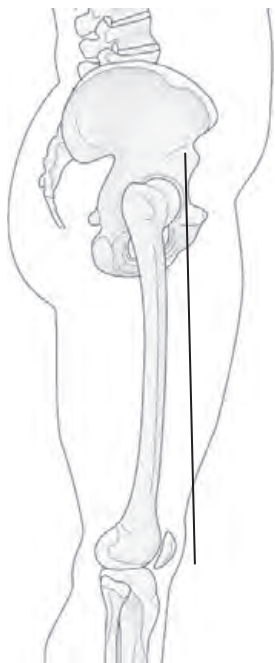


Figure 11.3.3

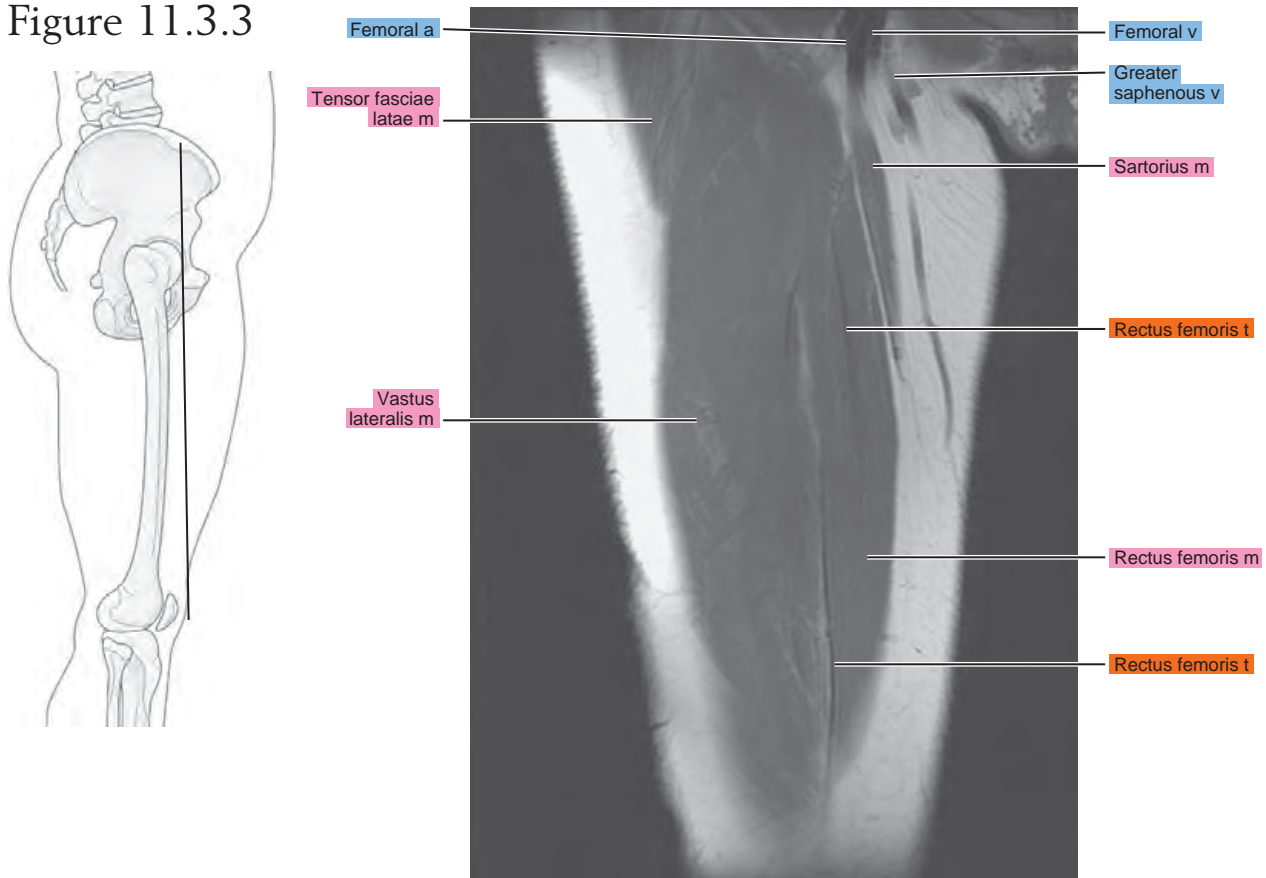


Figure 11.3.4

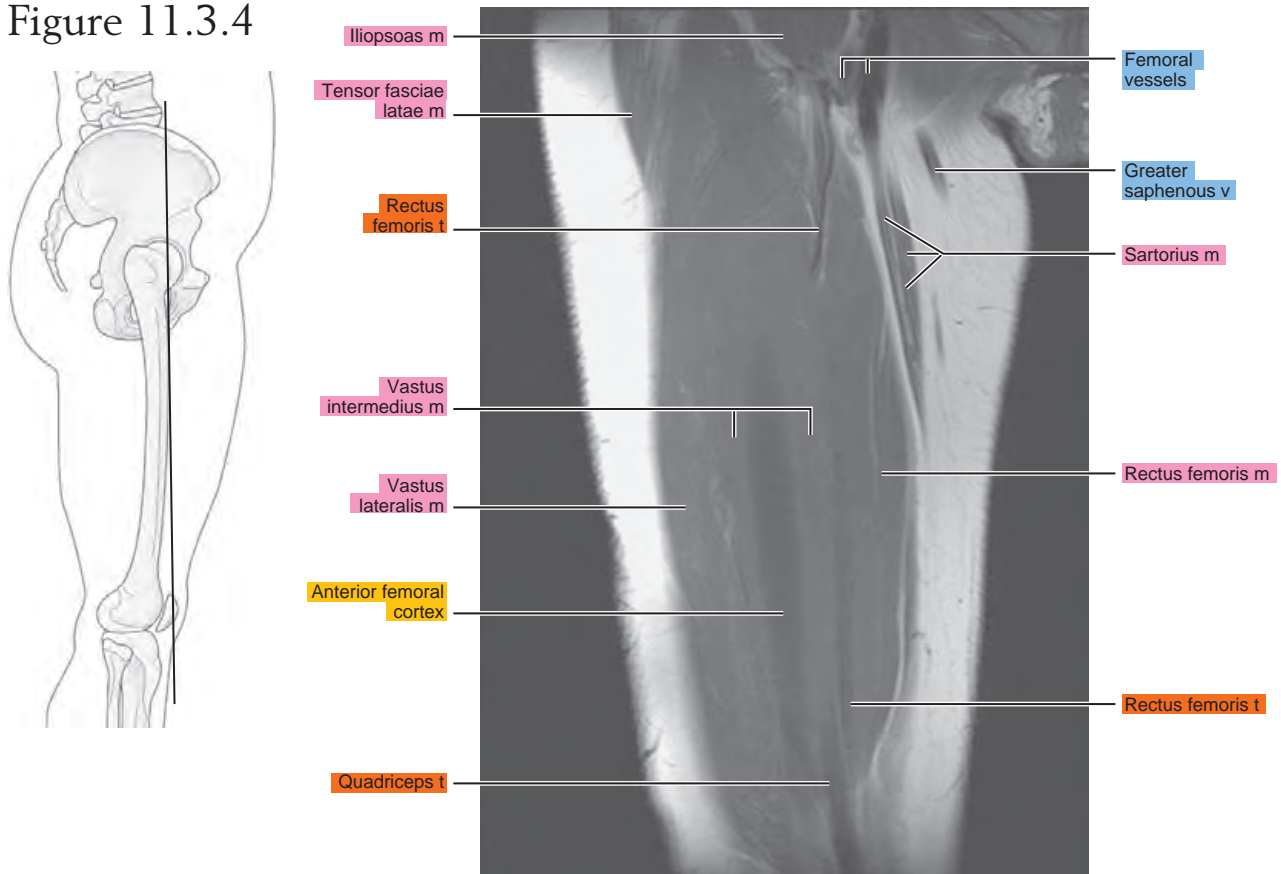


Figure 11.3.5

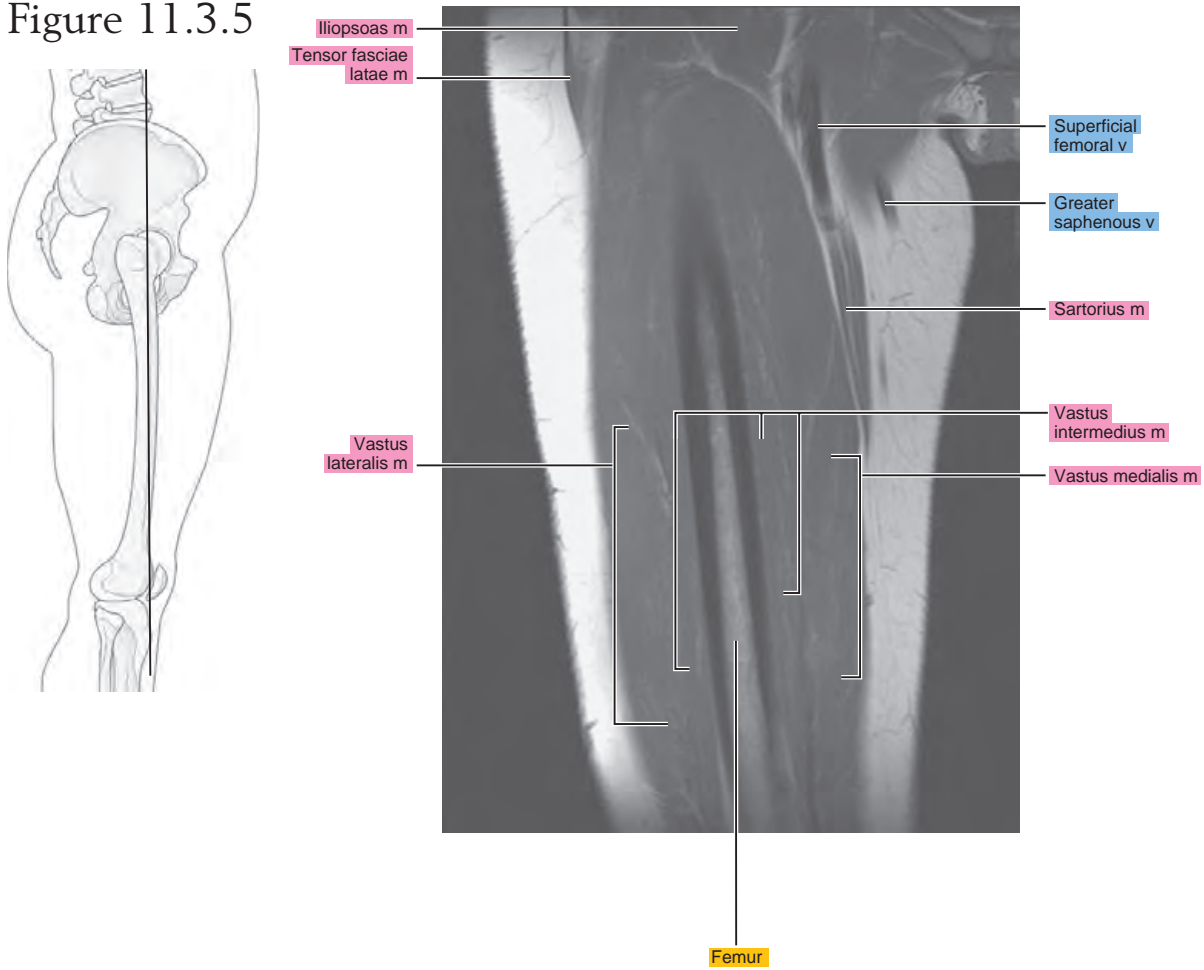


Figure 11.3.6

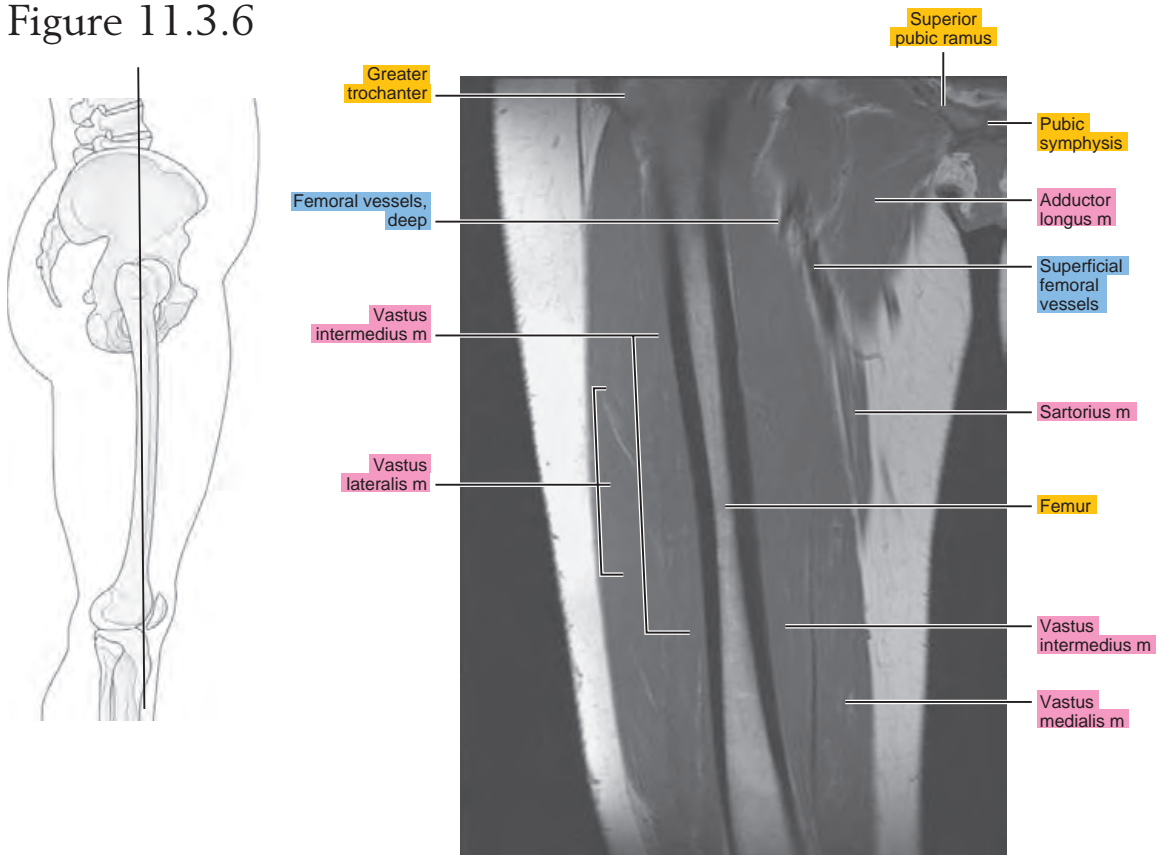


Figure 11.3.7

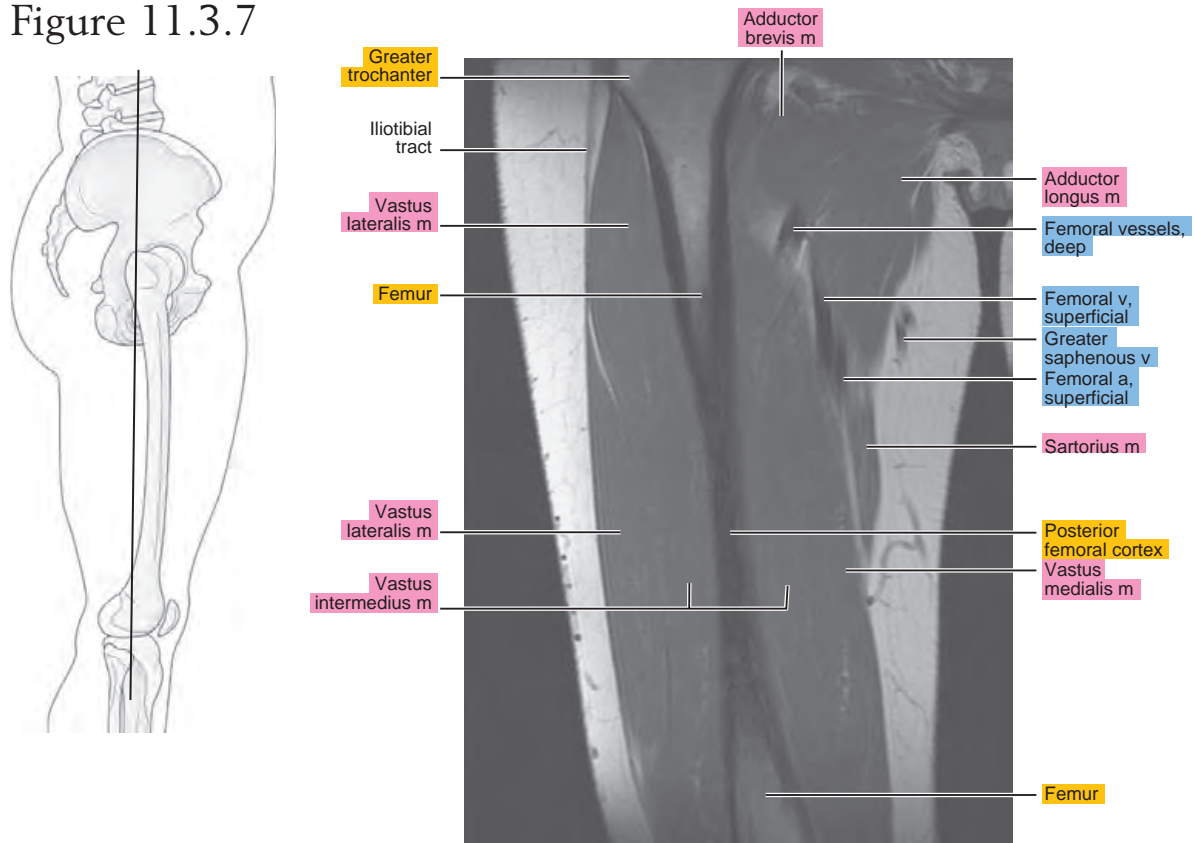


Figure 11.3.8

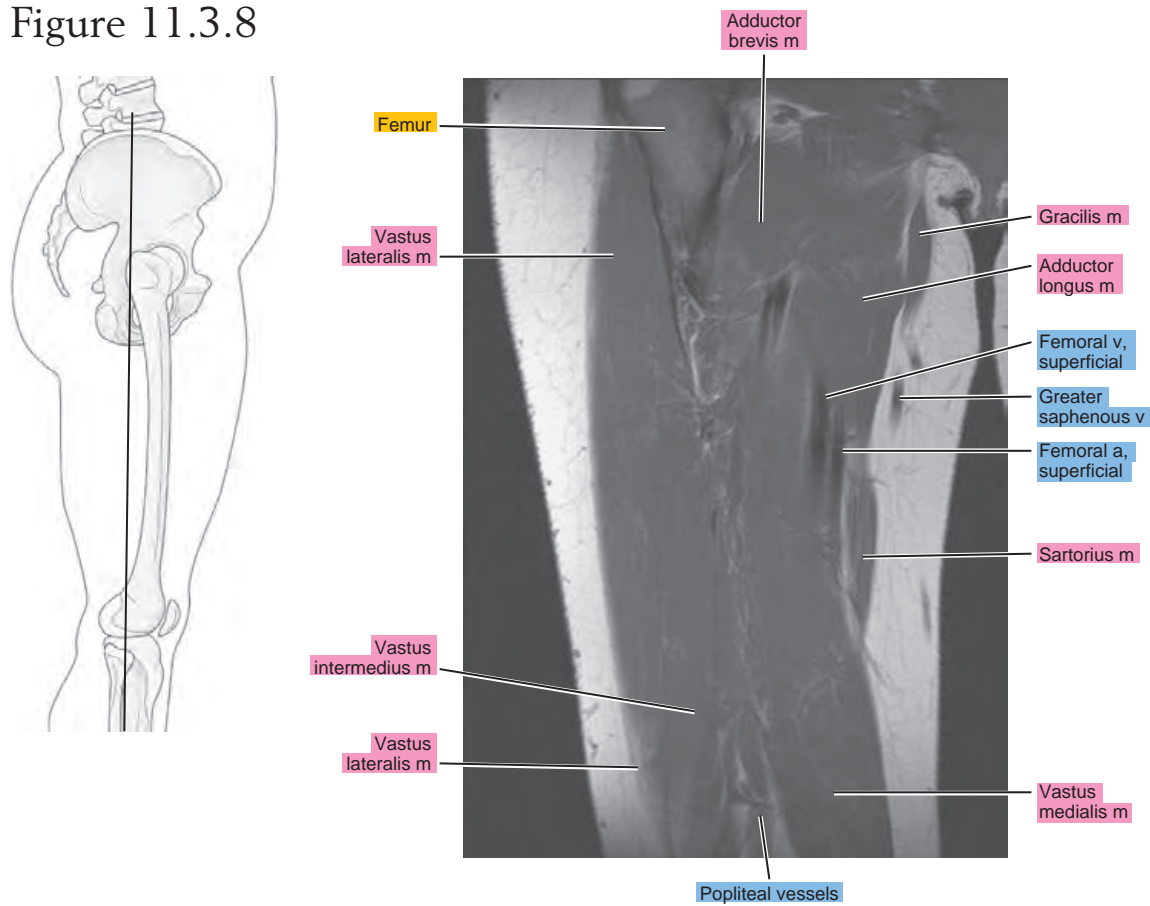


Figure 11.3.9

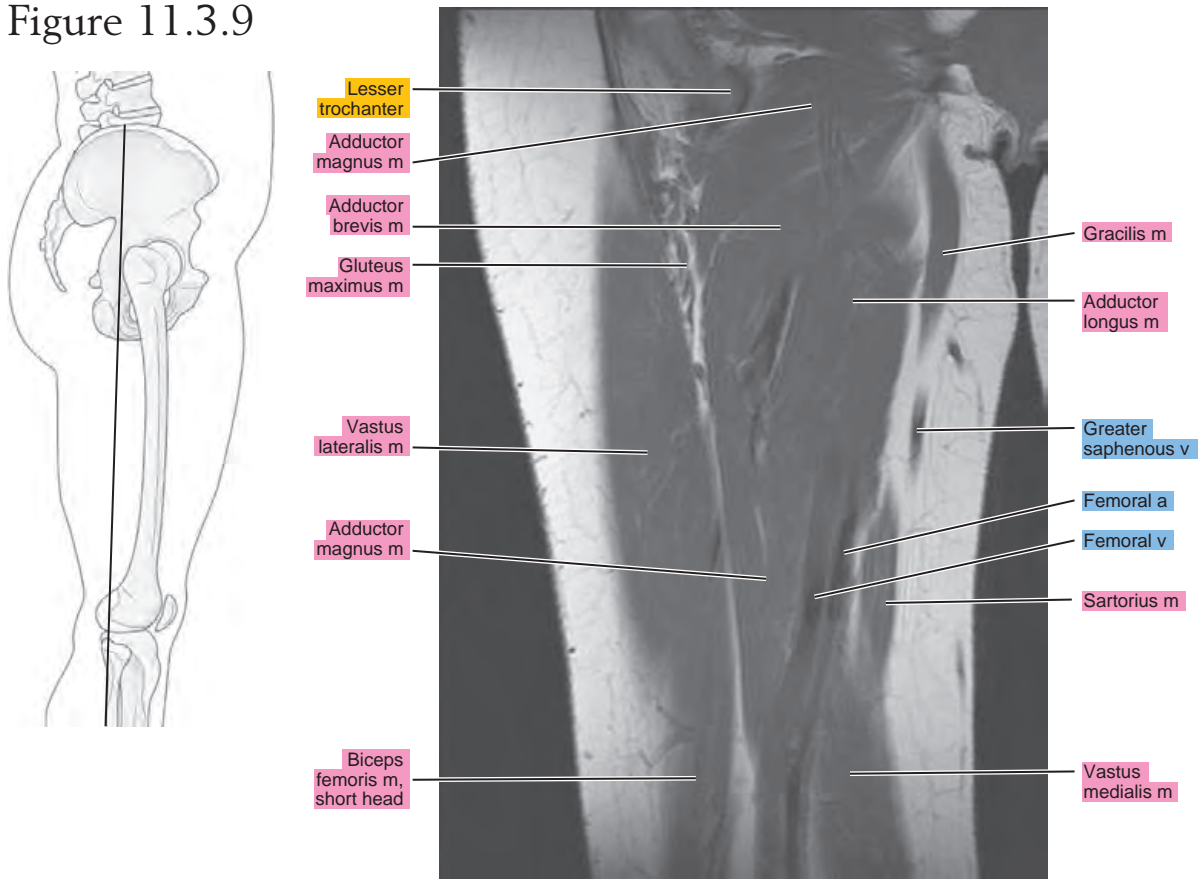


Figure 11.3.10

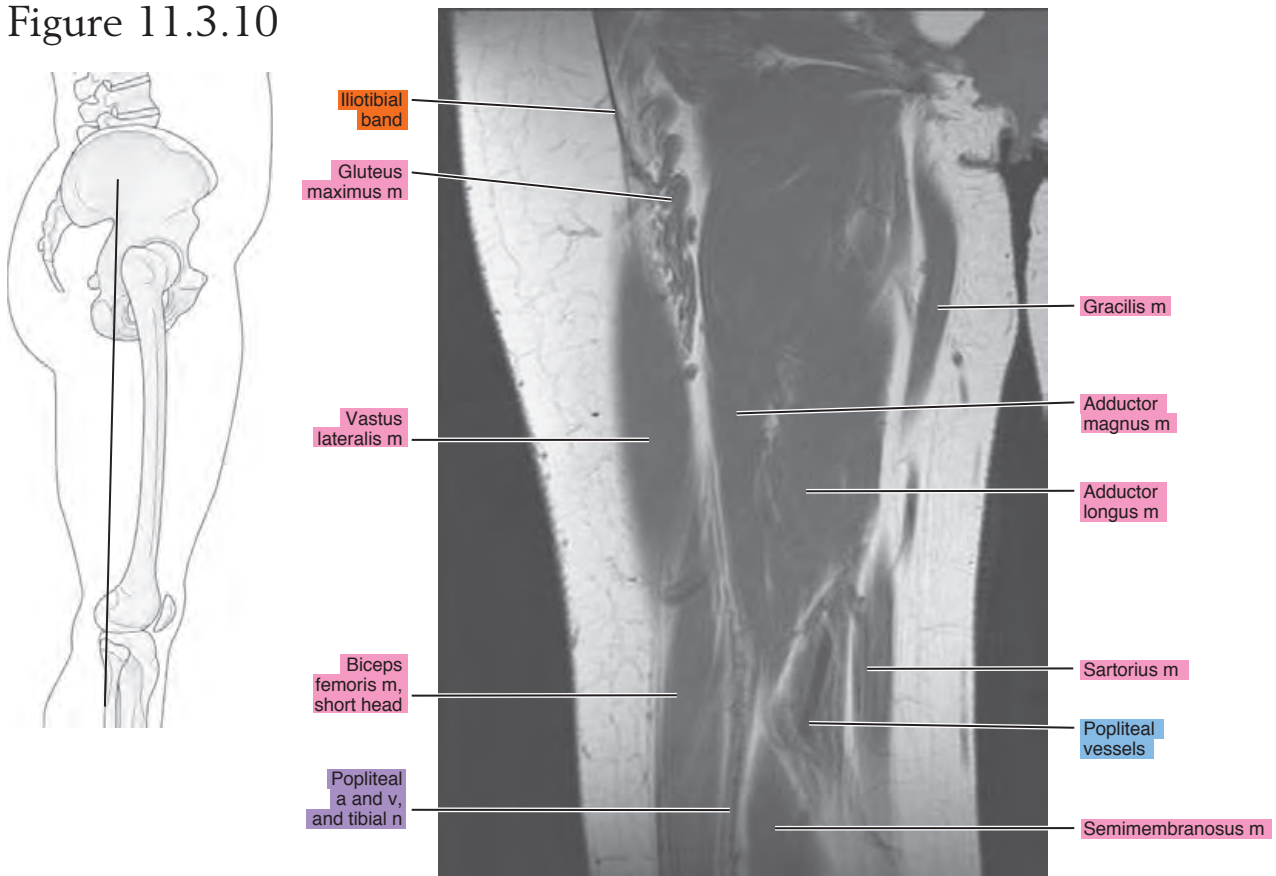


Figure 11.3.11

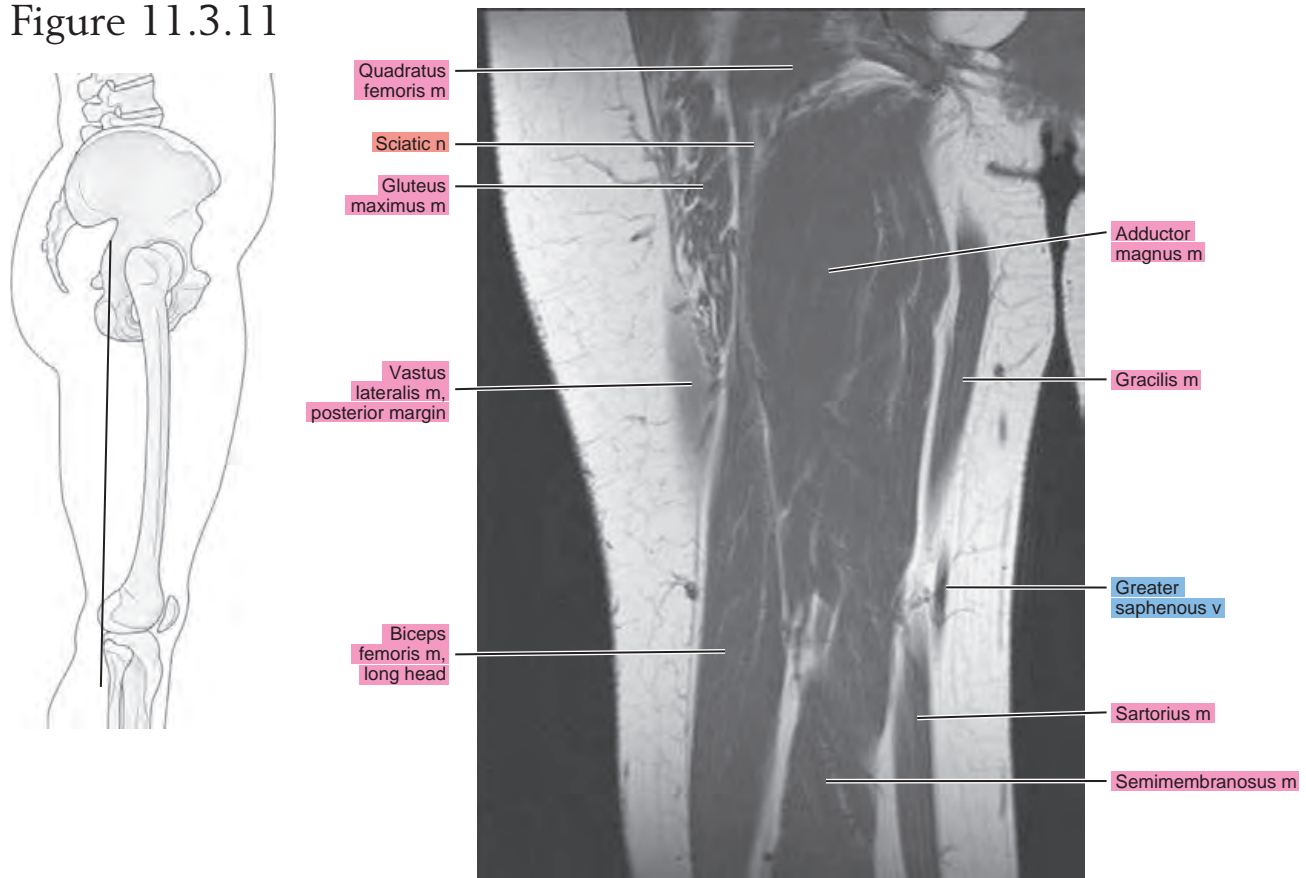


Figure 11.3.12

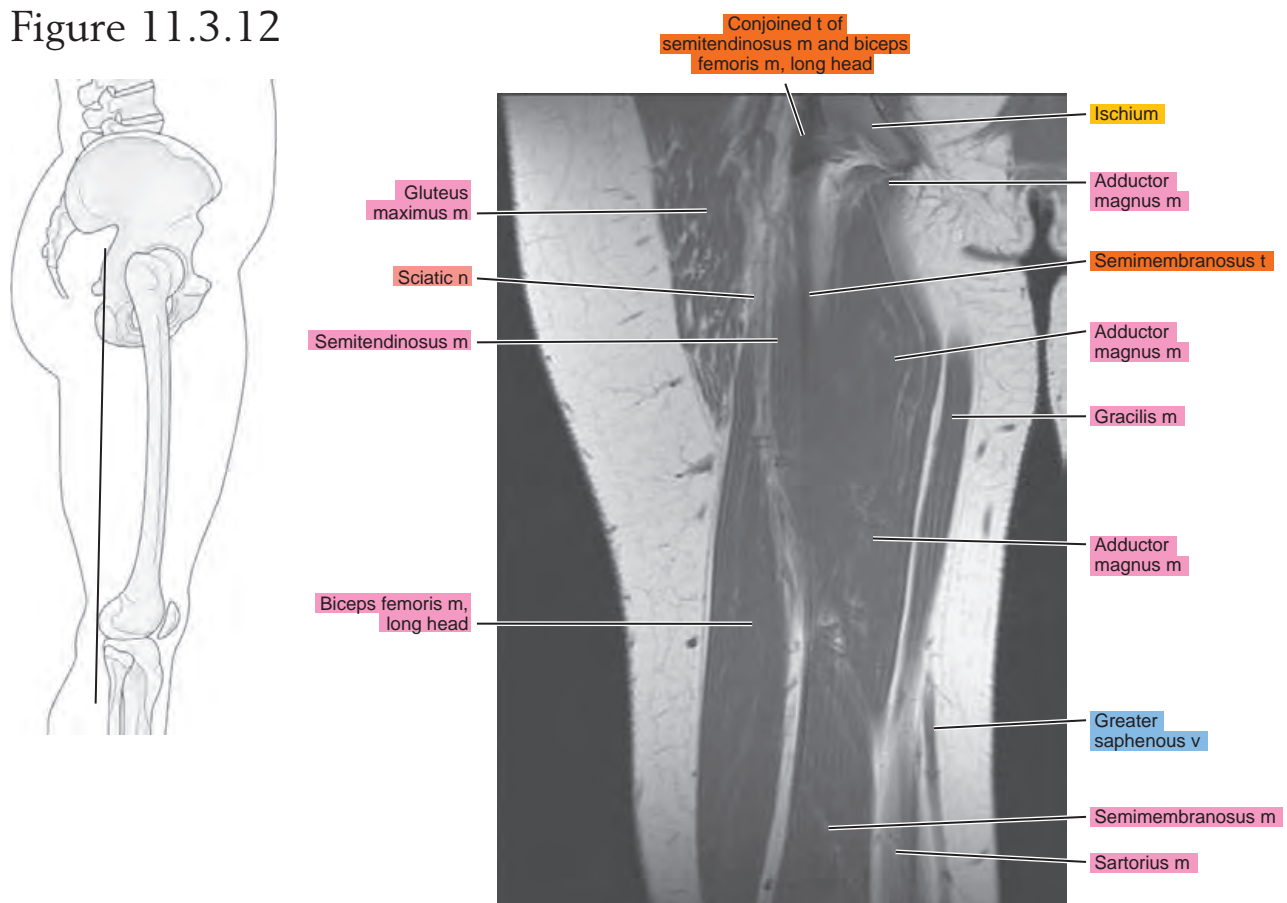


Figure 11.3.13

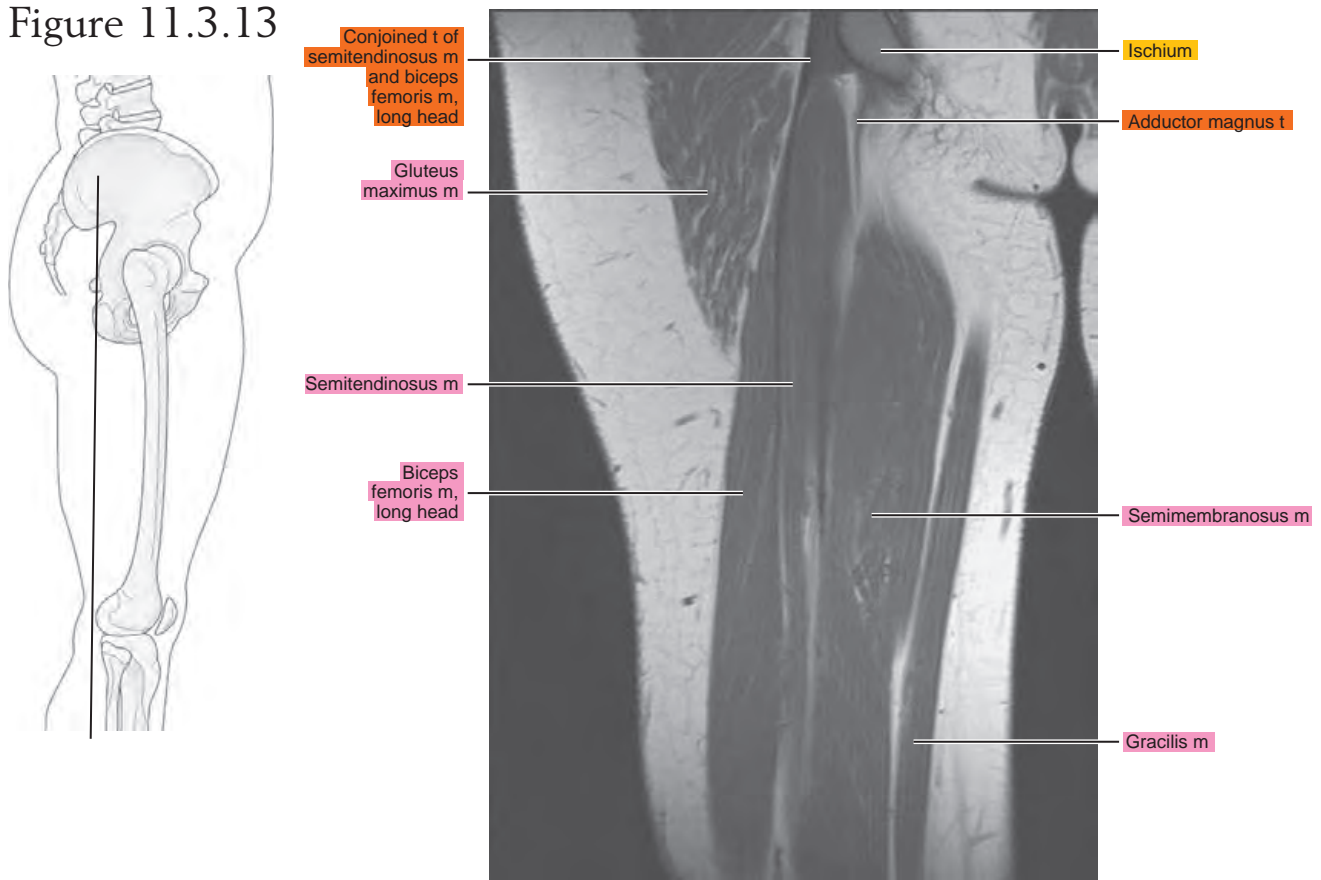


Figure 11.3.14

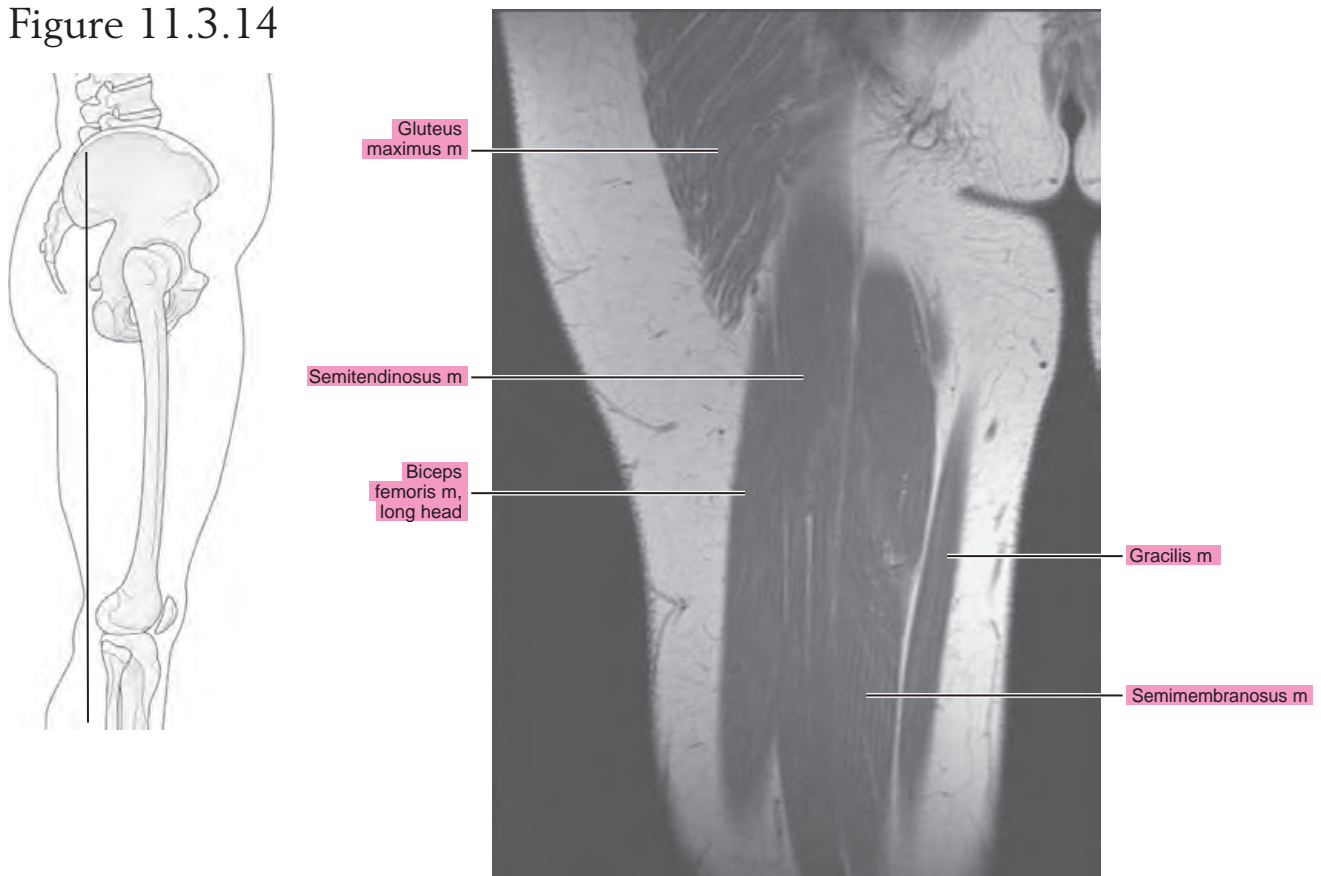
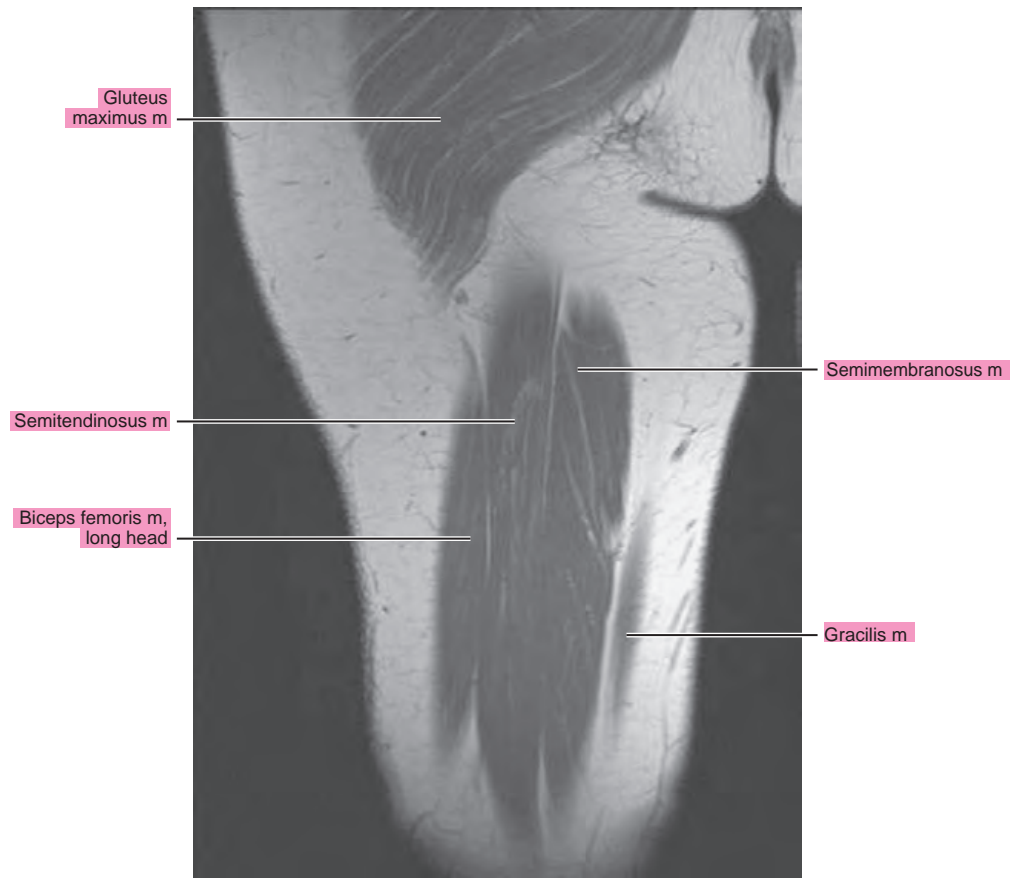
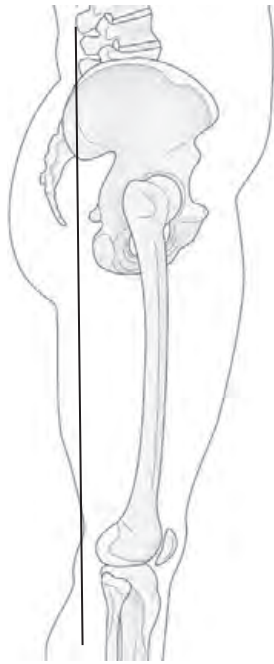


Figure 11.3.15



Chapter
12

MRI of the Knee

AXIAL

Figure 12.1.1

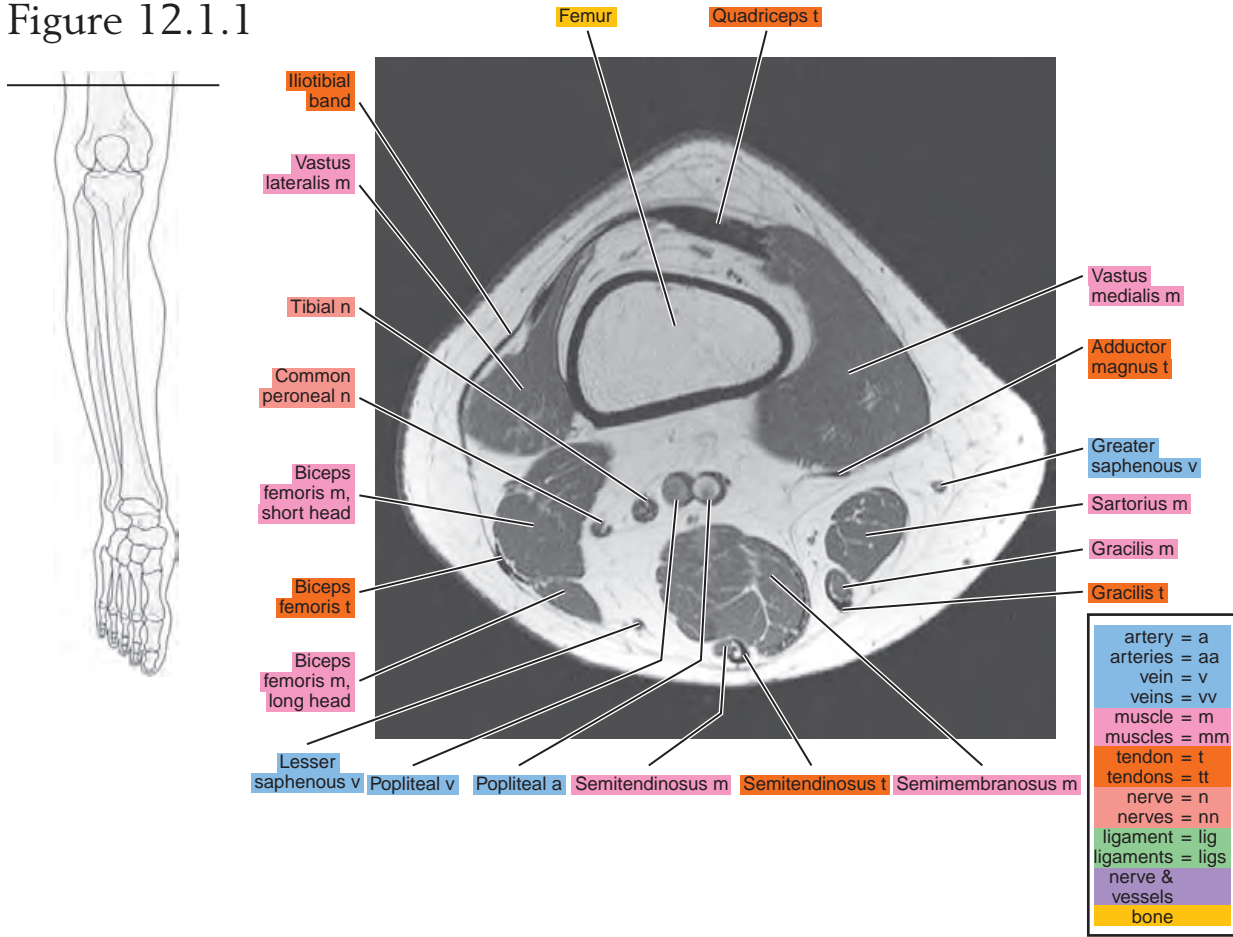


Figure 12.1.2

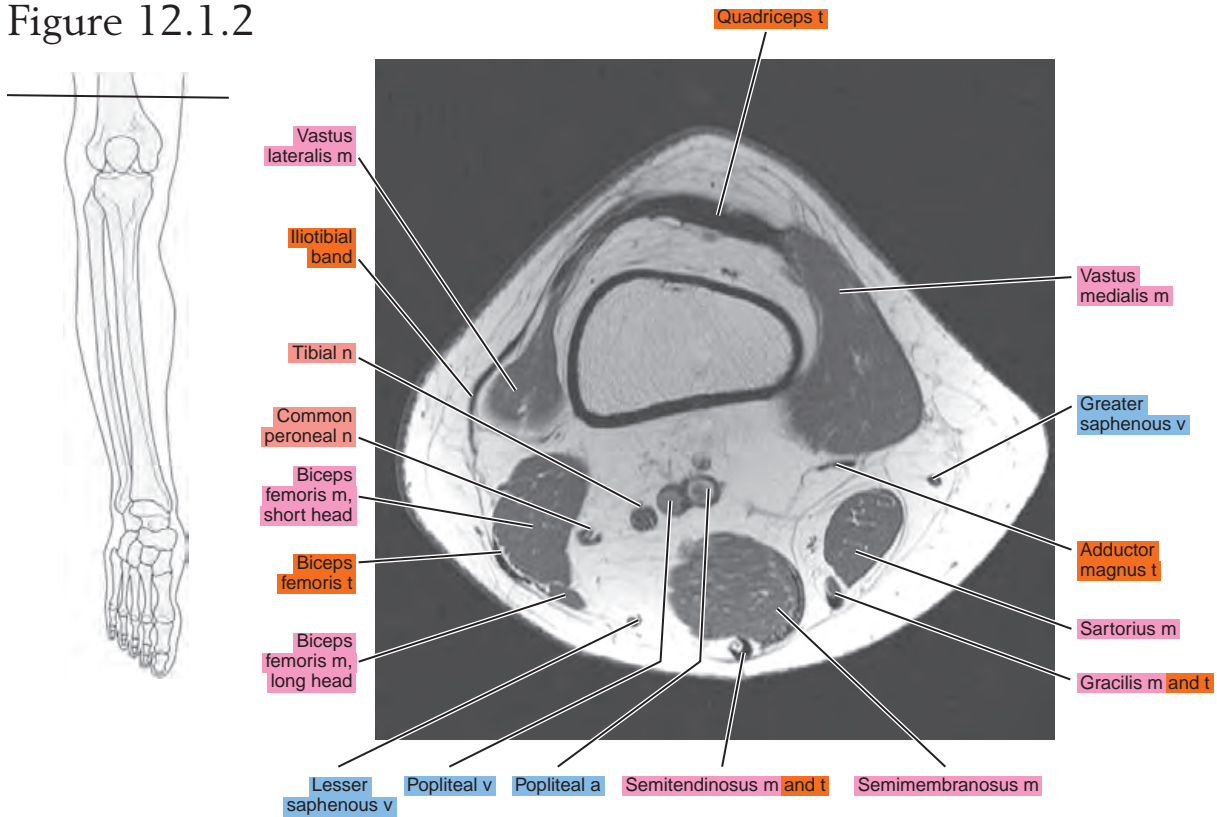


Figure 12.1.3

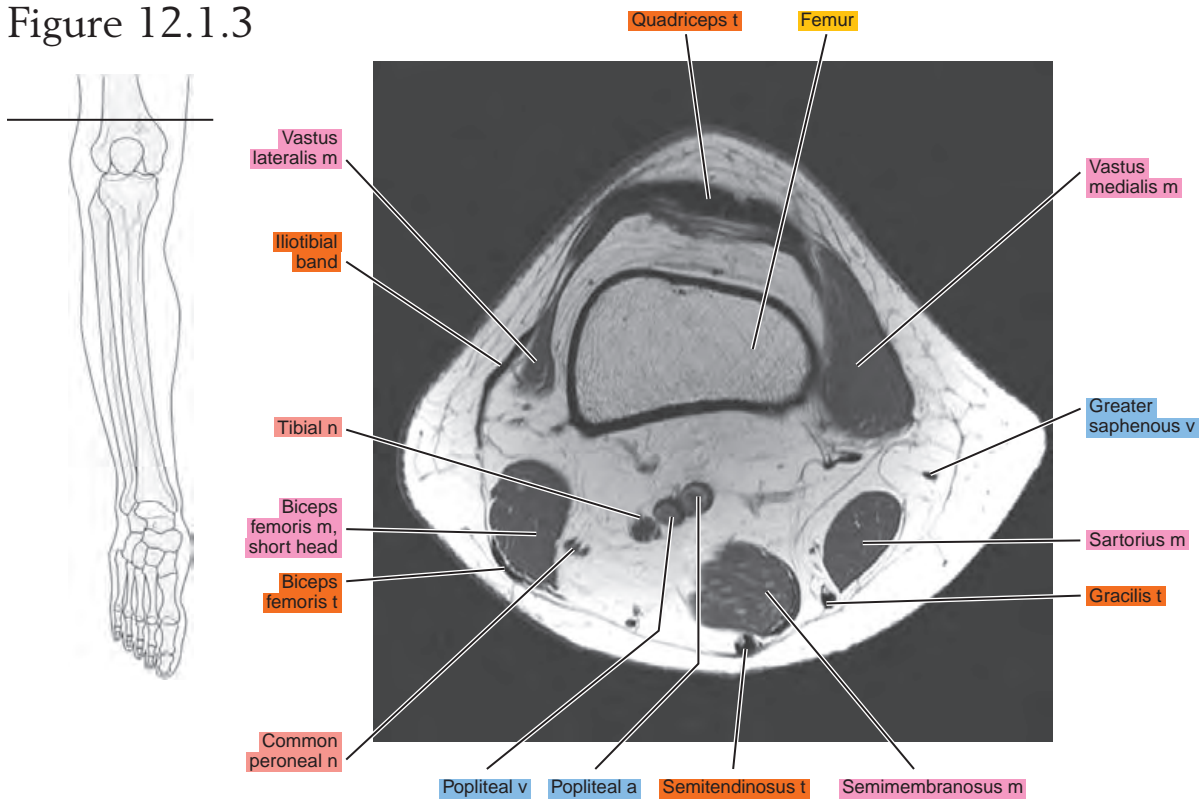


Figure 12.1.4

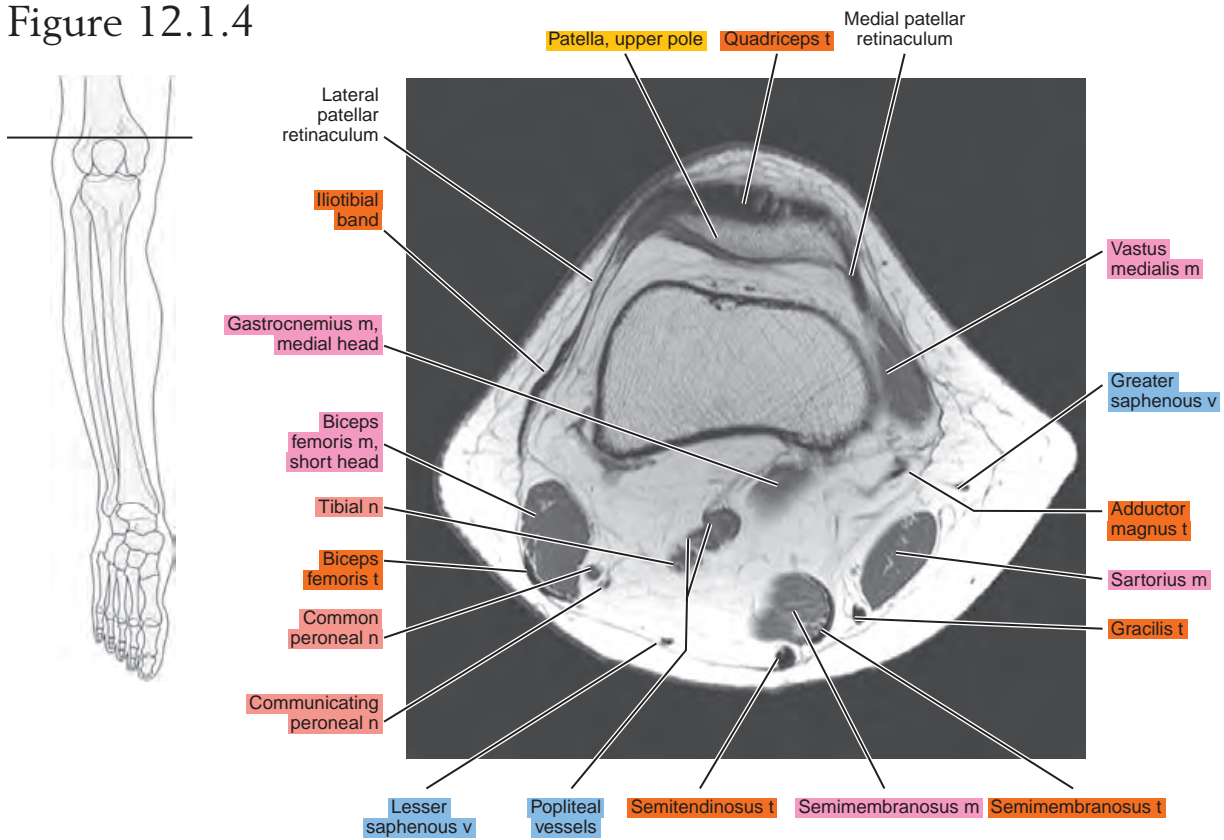


Figure 12.1.5

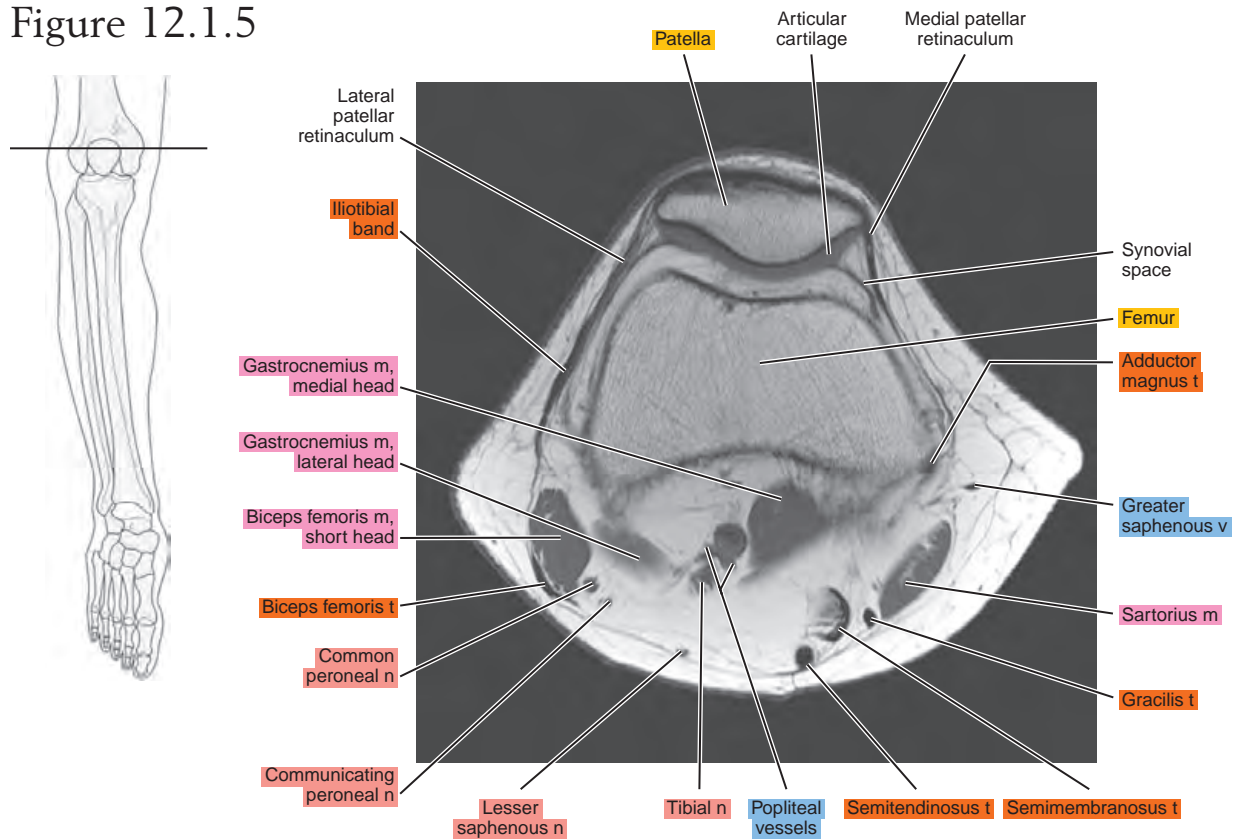


Figure 12.1.6

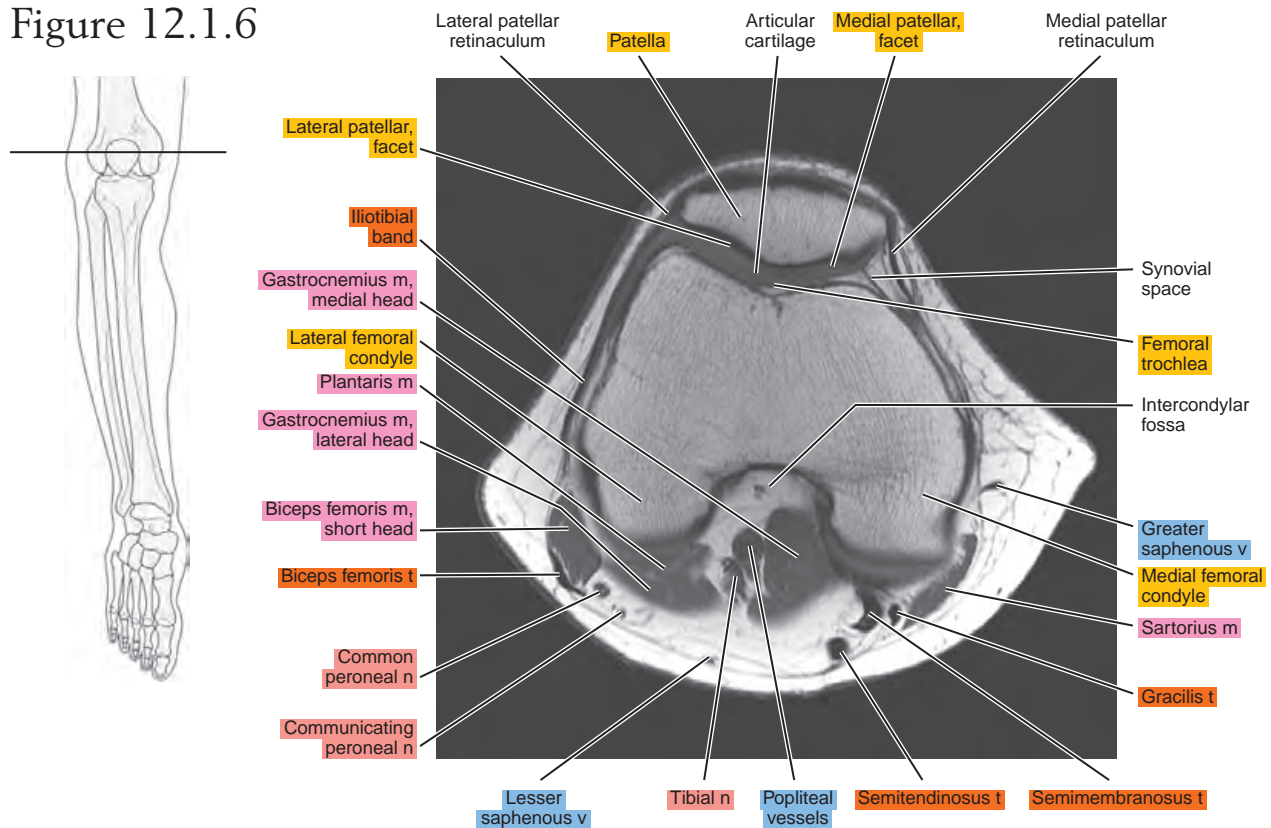


Figure 12.1.7

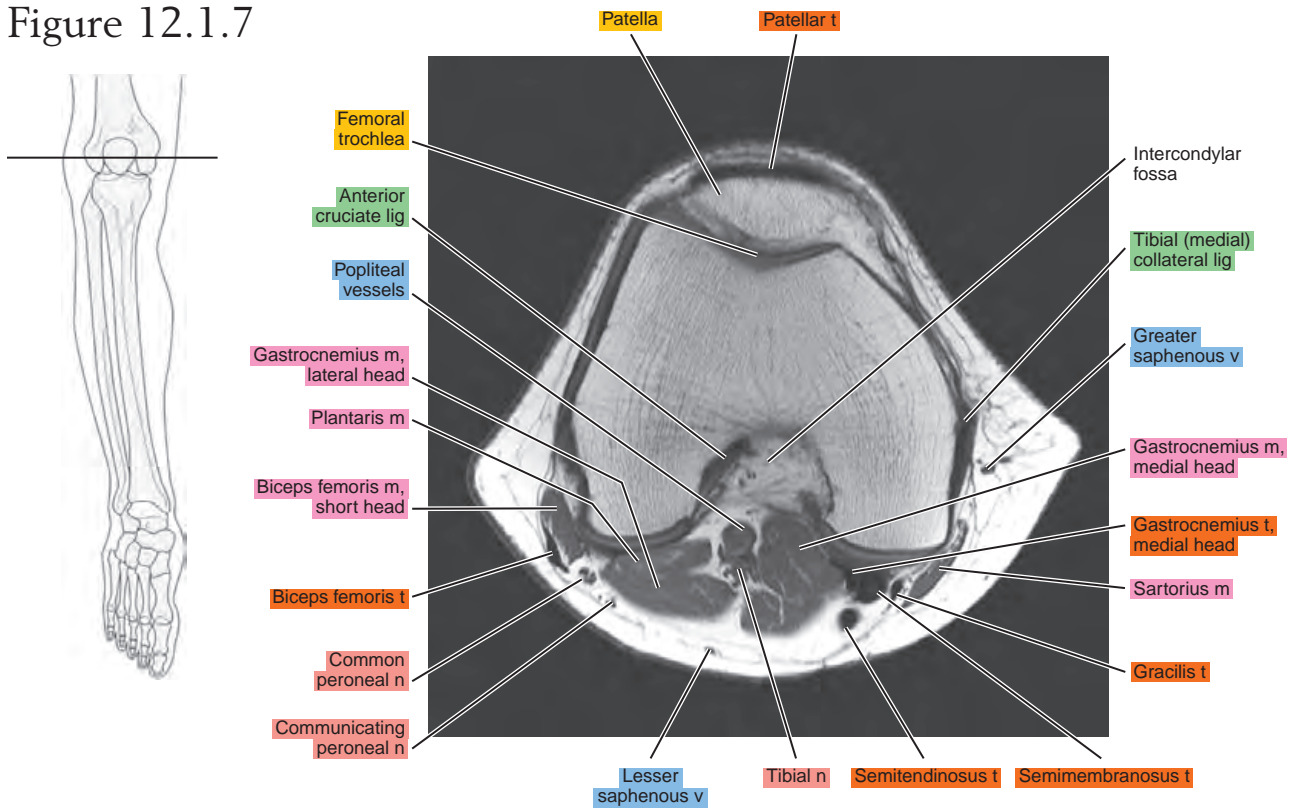


Figure 12.1.8

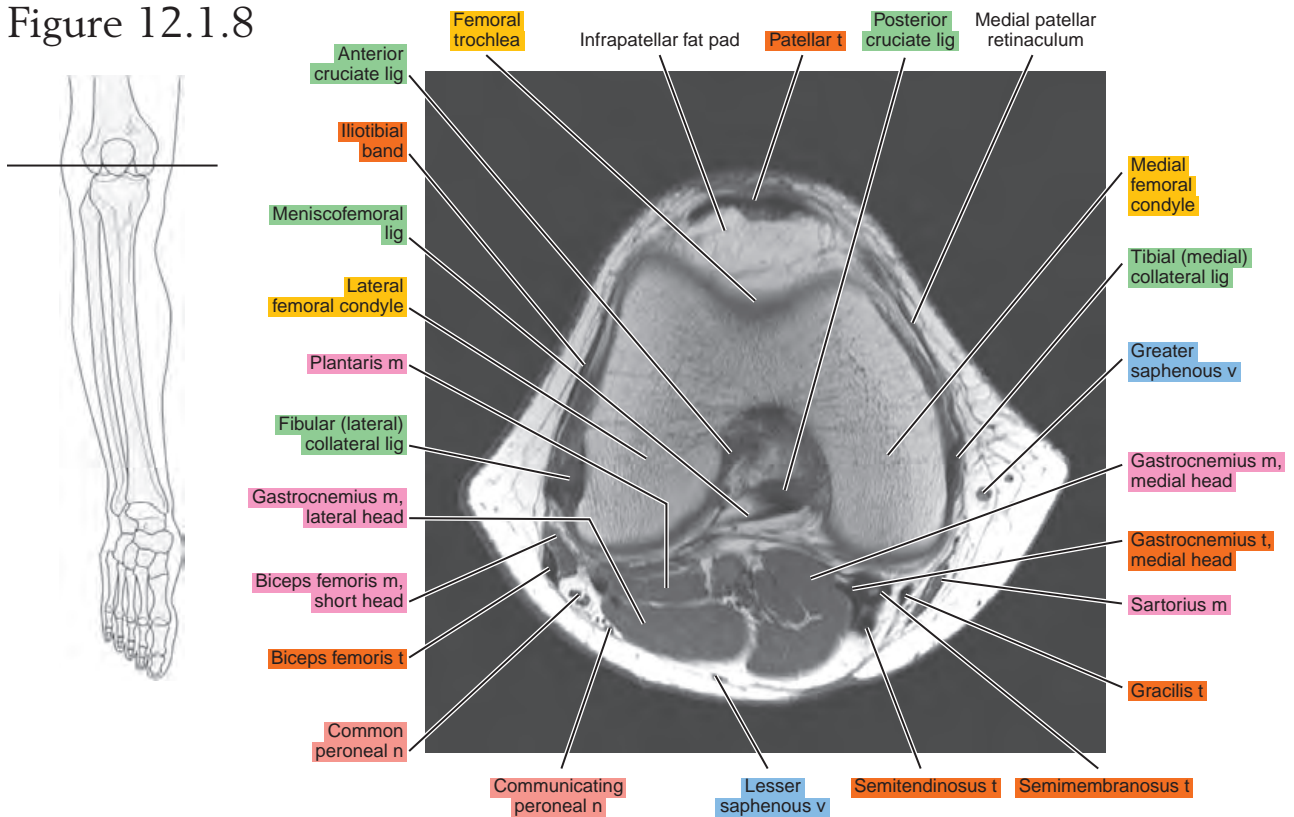


Figure 12.1.9

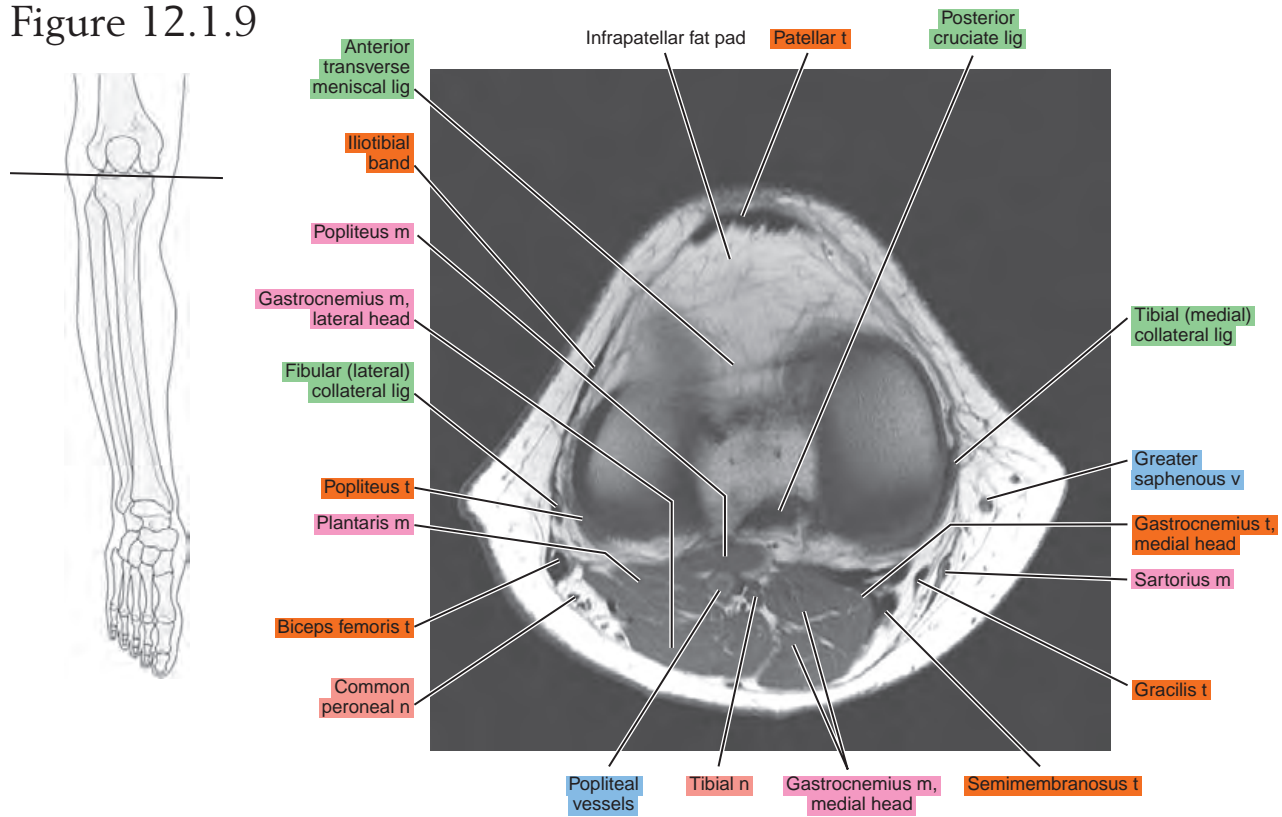


Figure 12.1.10

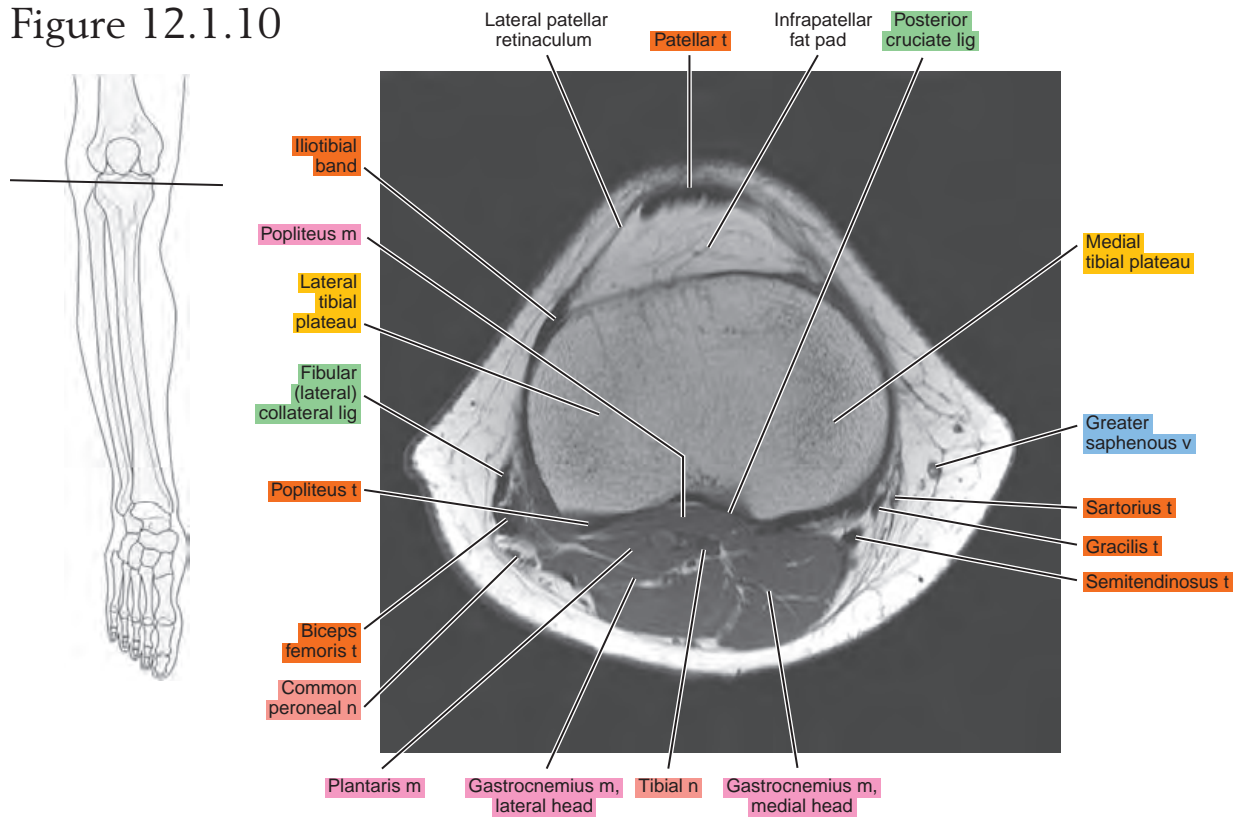


Figure 12.1.11

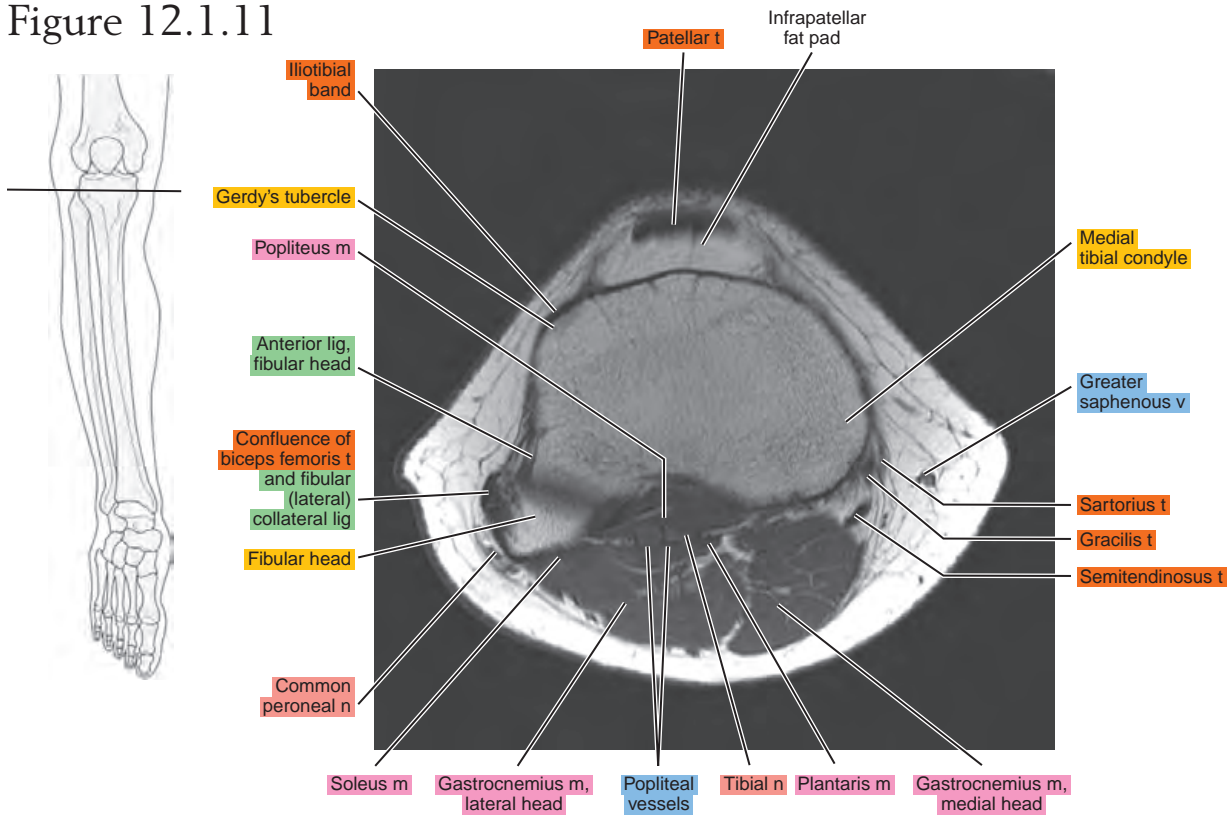


Figure 12.1.12

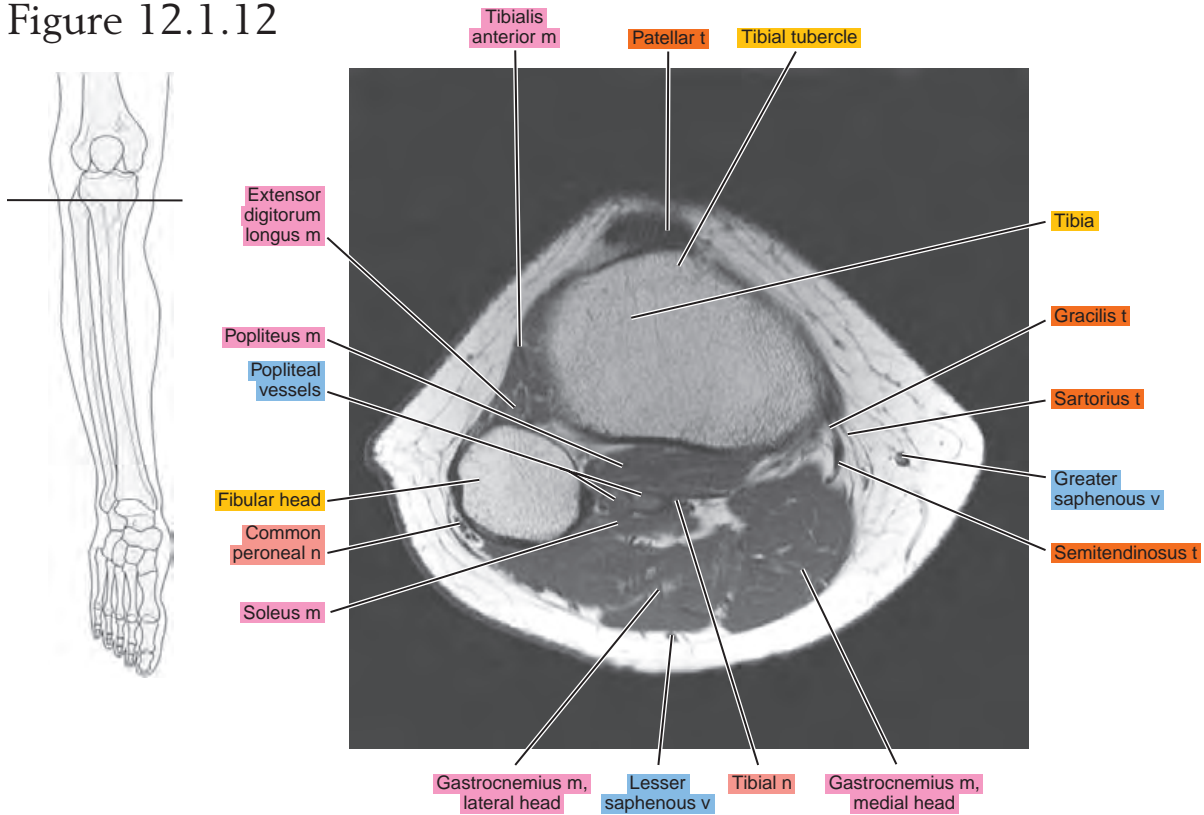


Figure 12.1.13

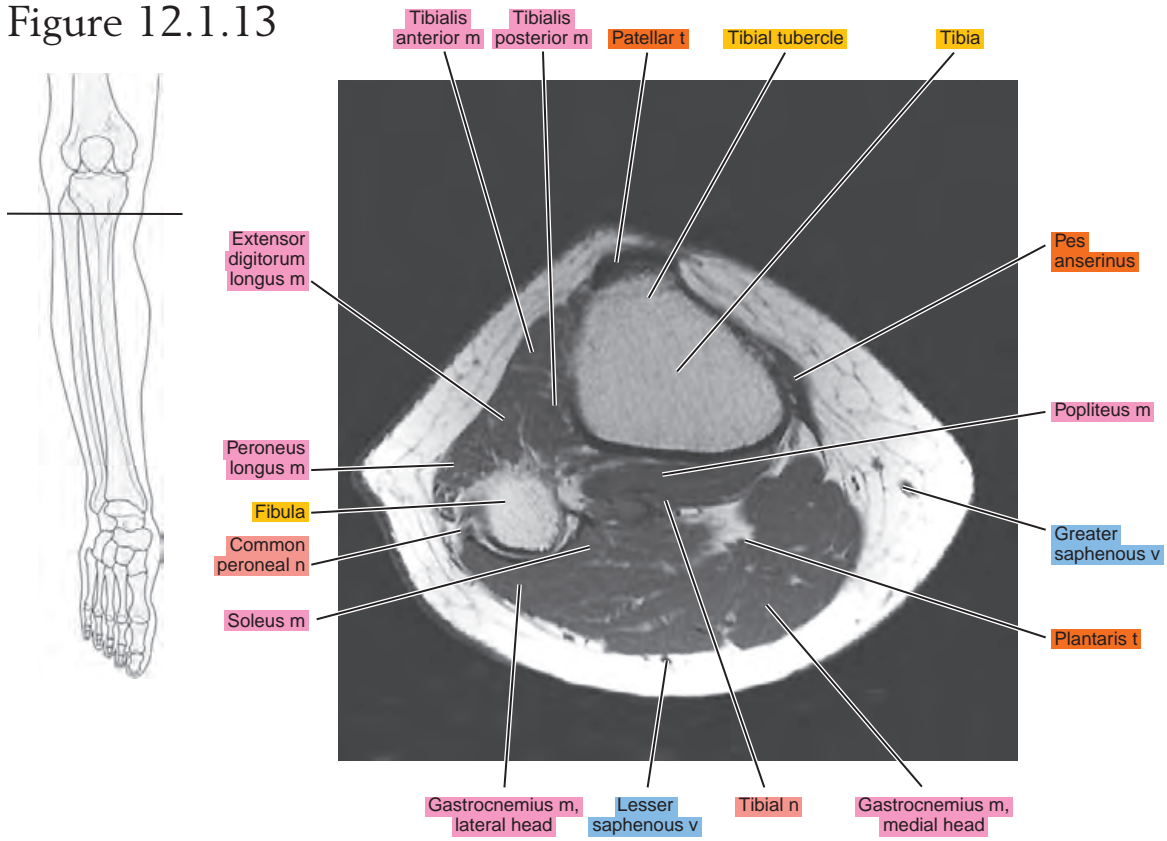
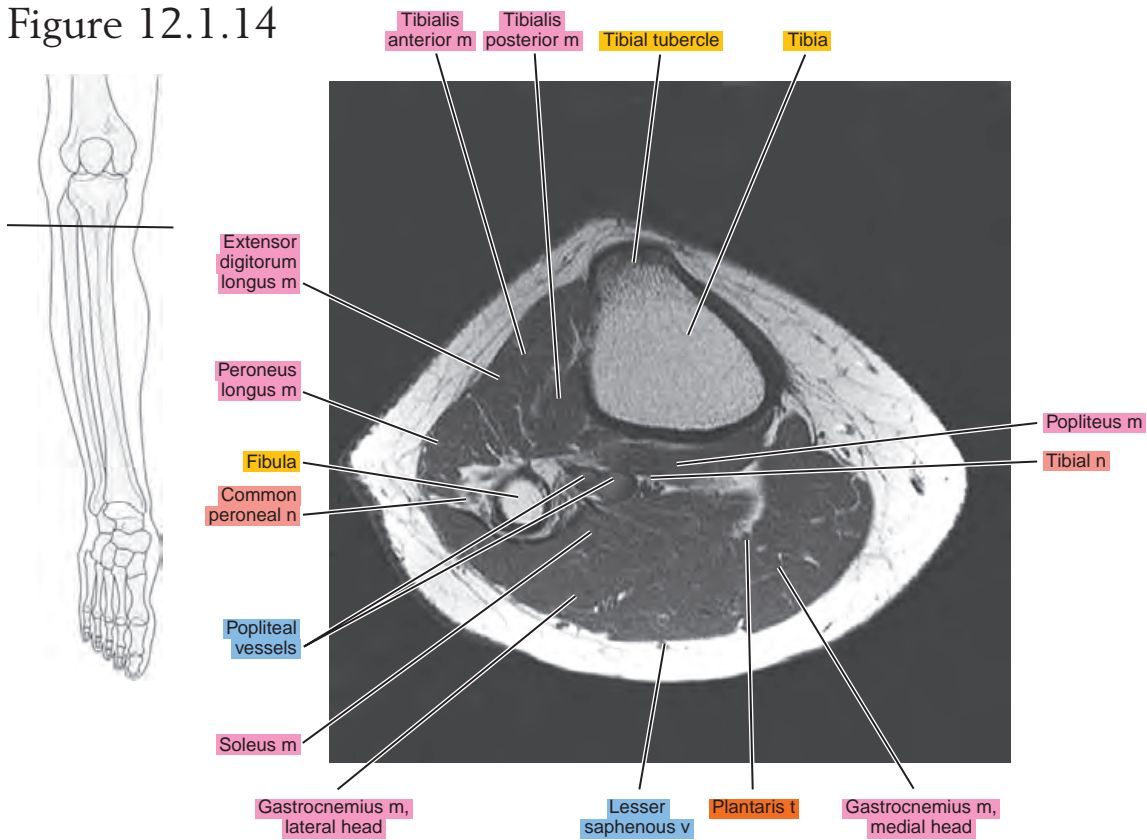


Figure 12.1.14



SAGITTAL

Figure 12.2.1

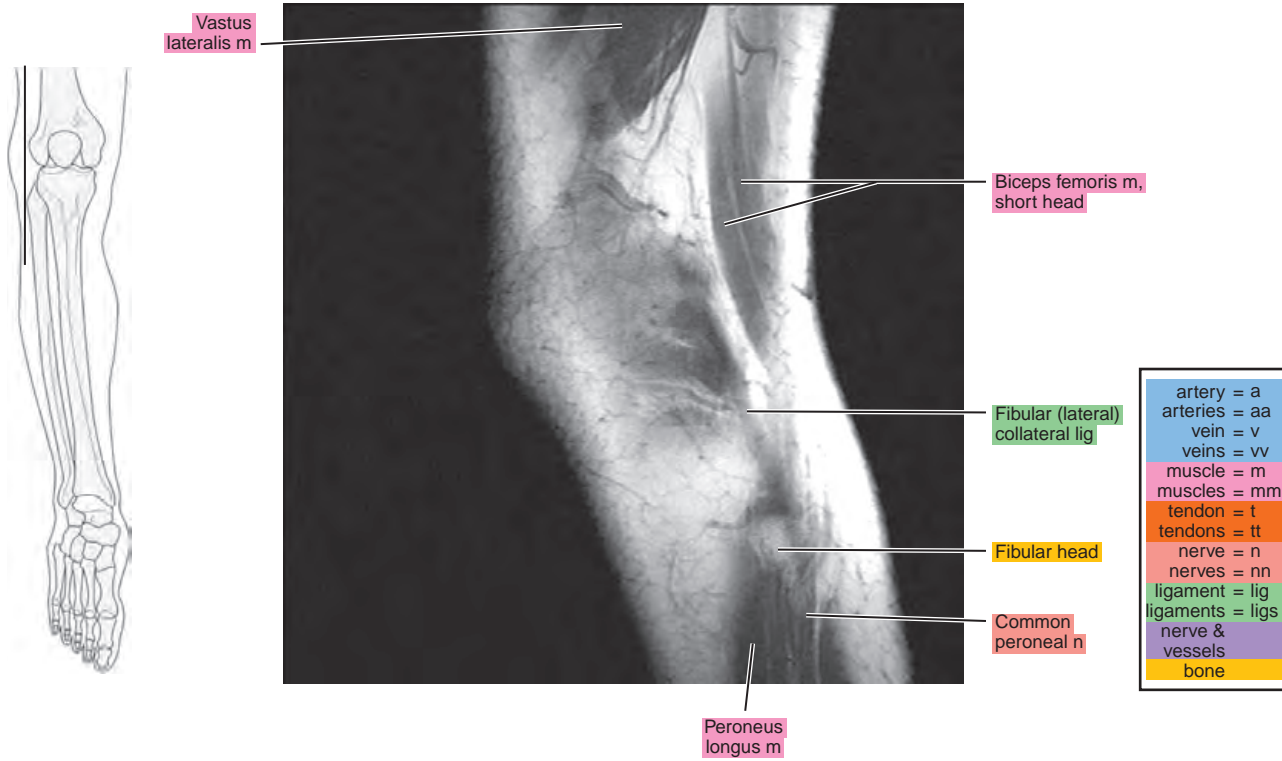


Figure 12.2.2

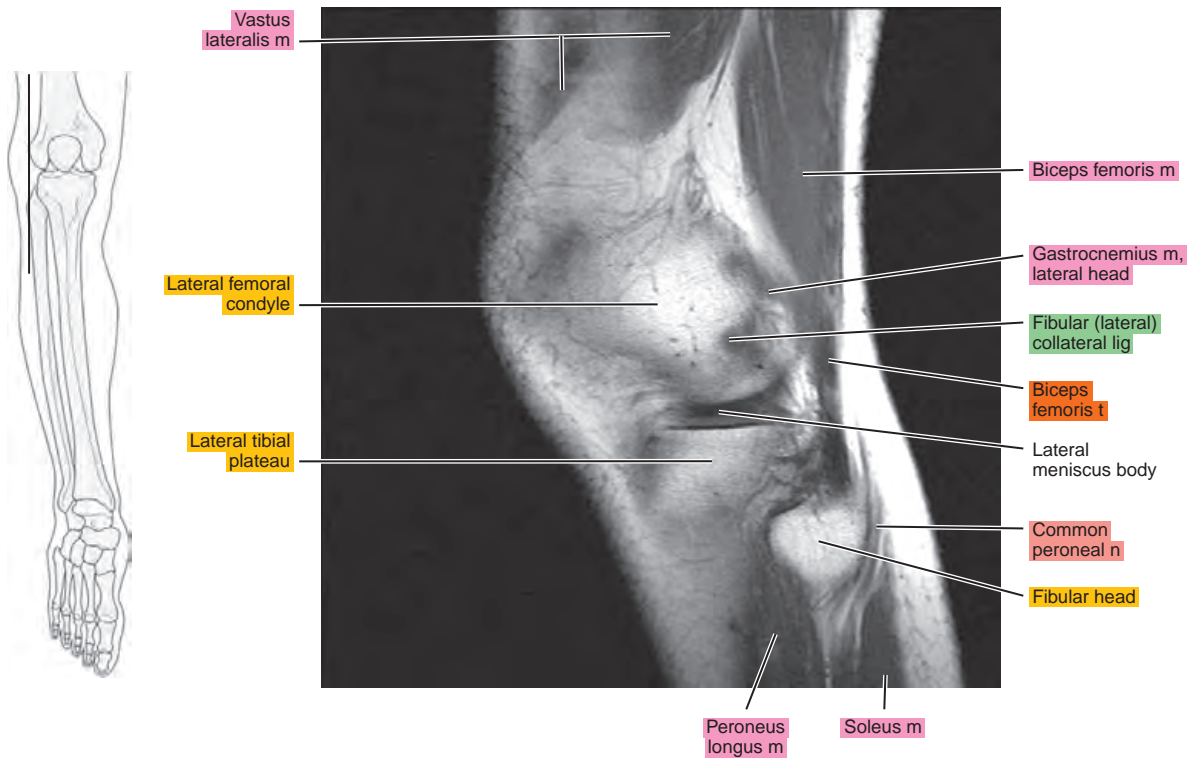


Figure 12.2.3

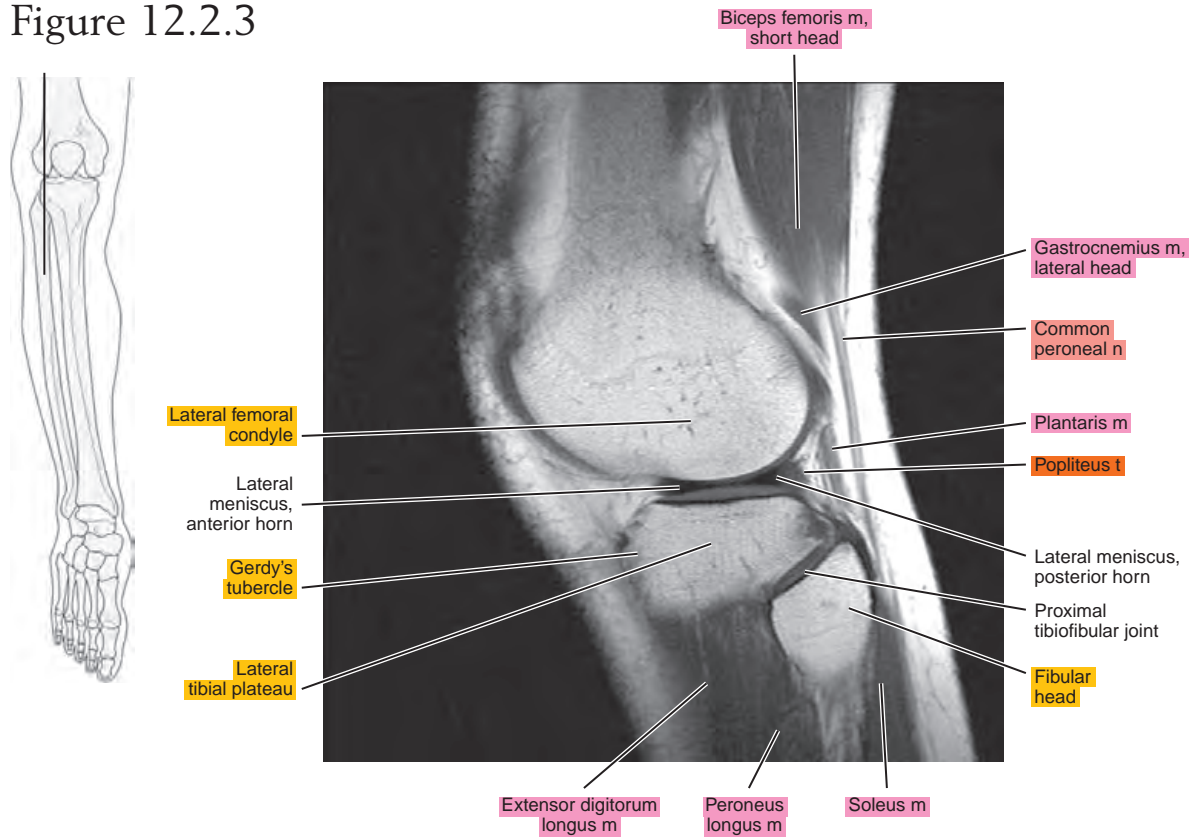


Figure 12.2.4

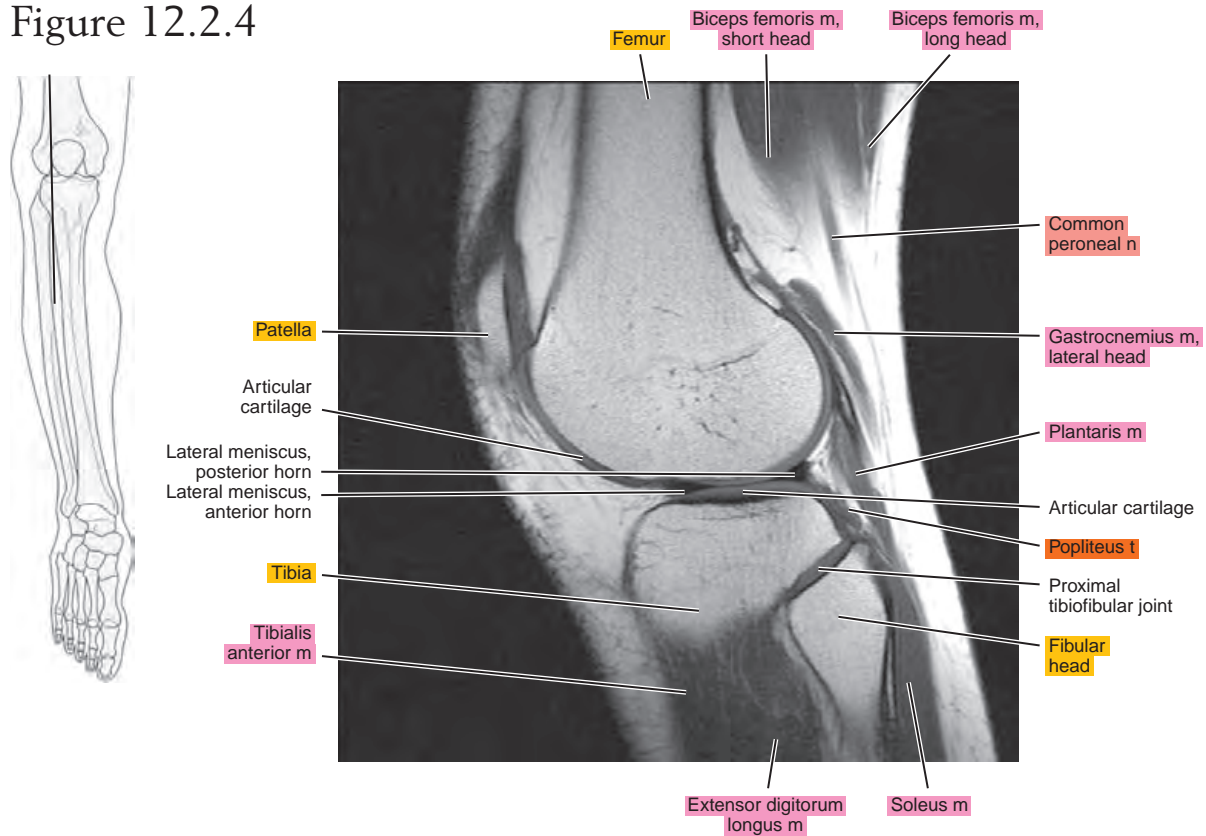


Figure 12.2.5

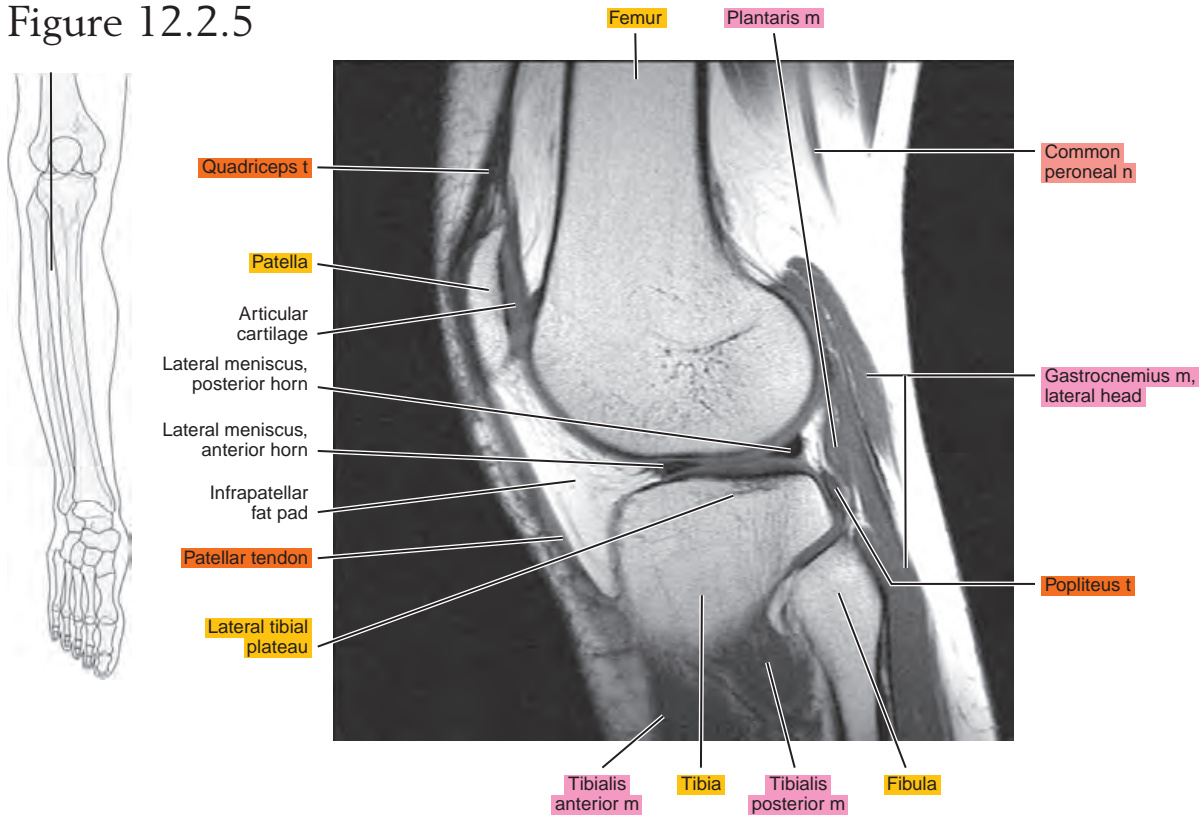


Figure 12.2.6

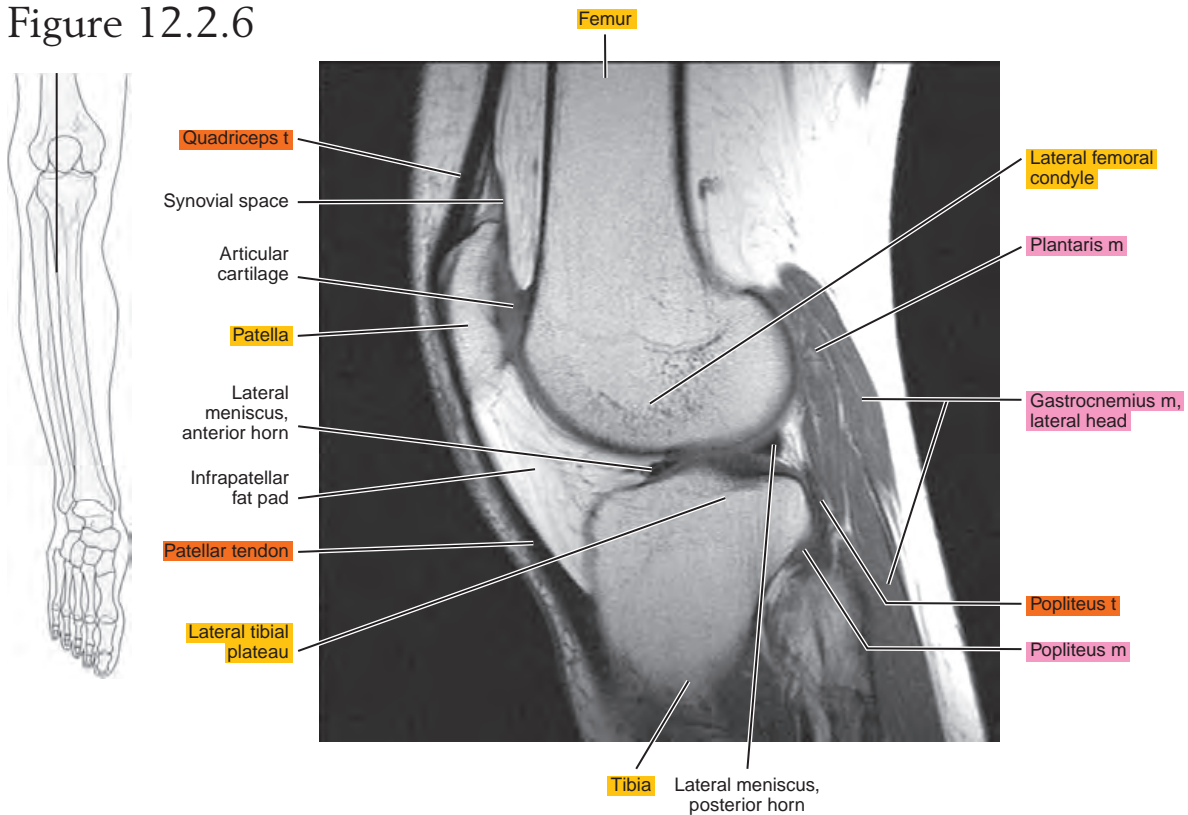


Figure 12.2.7

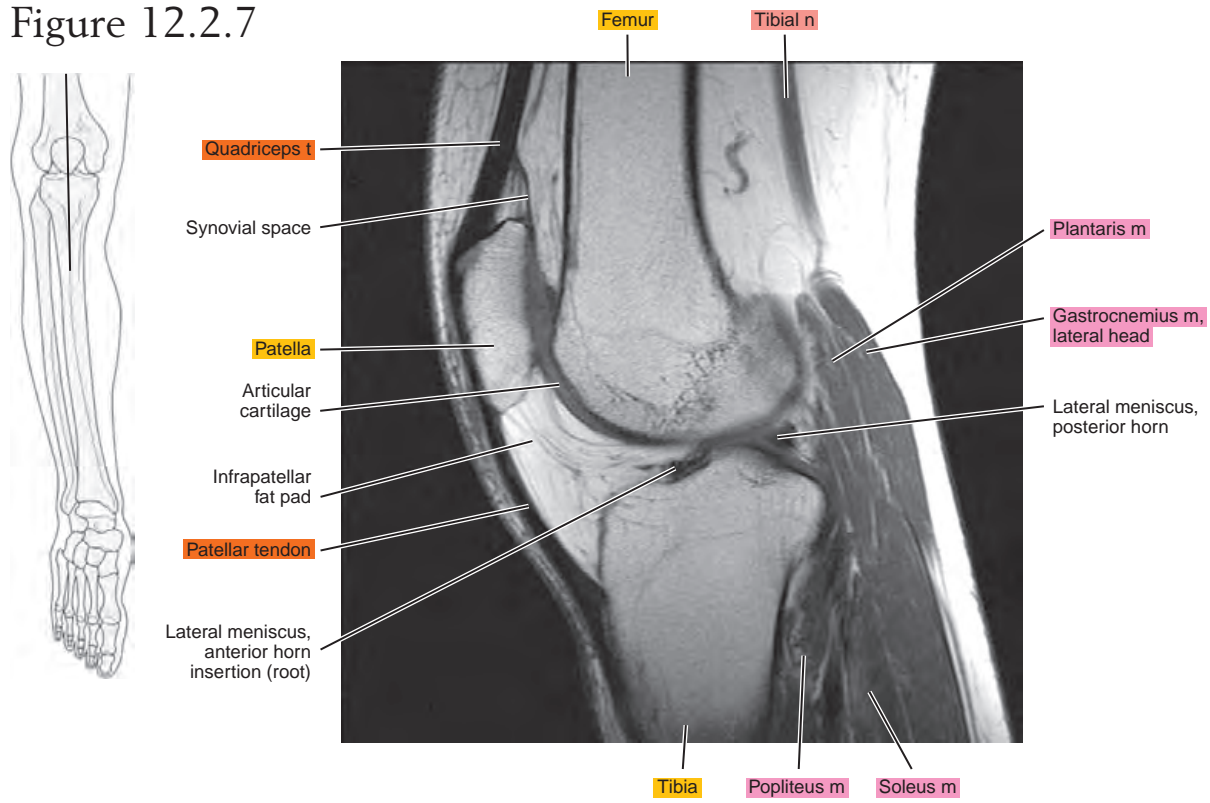


Figure 12.2.8

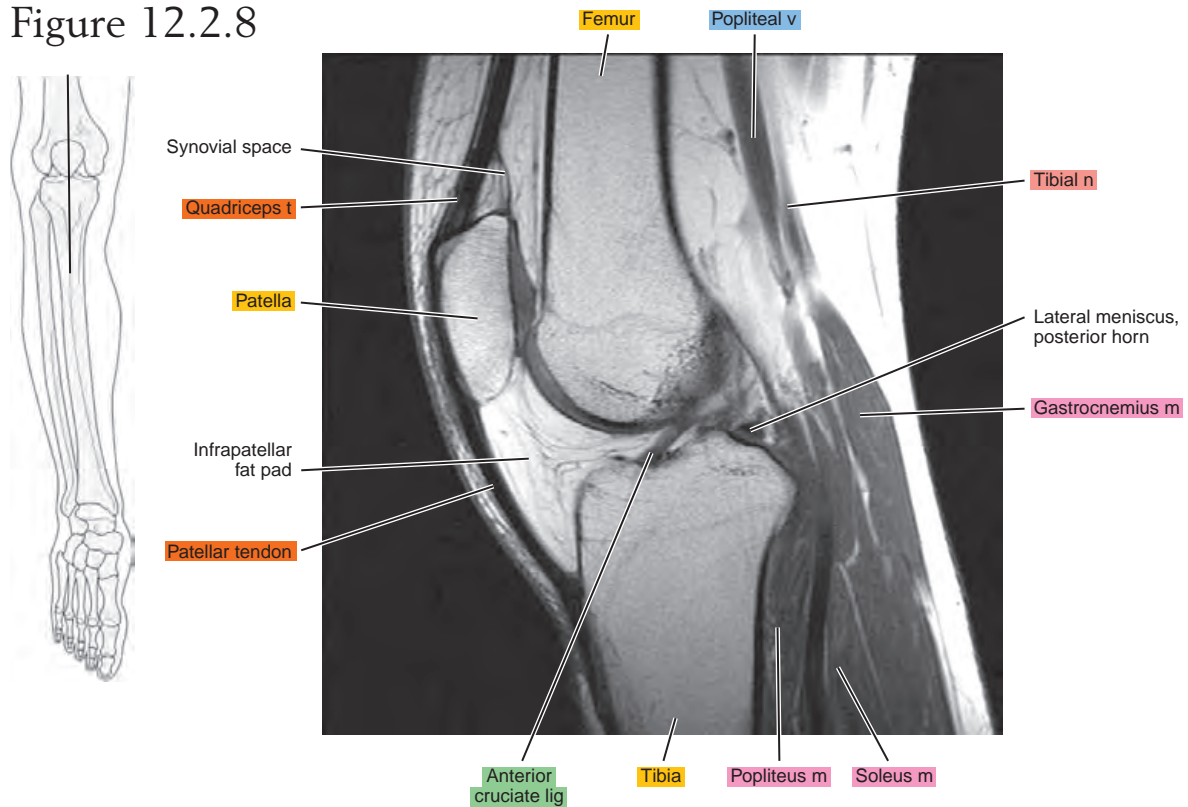


Figure 12.2.9

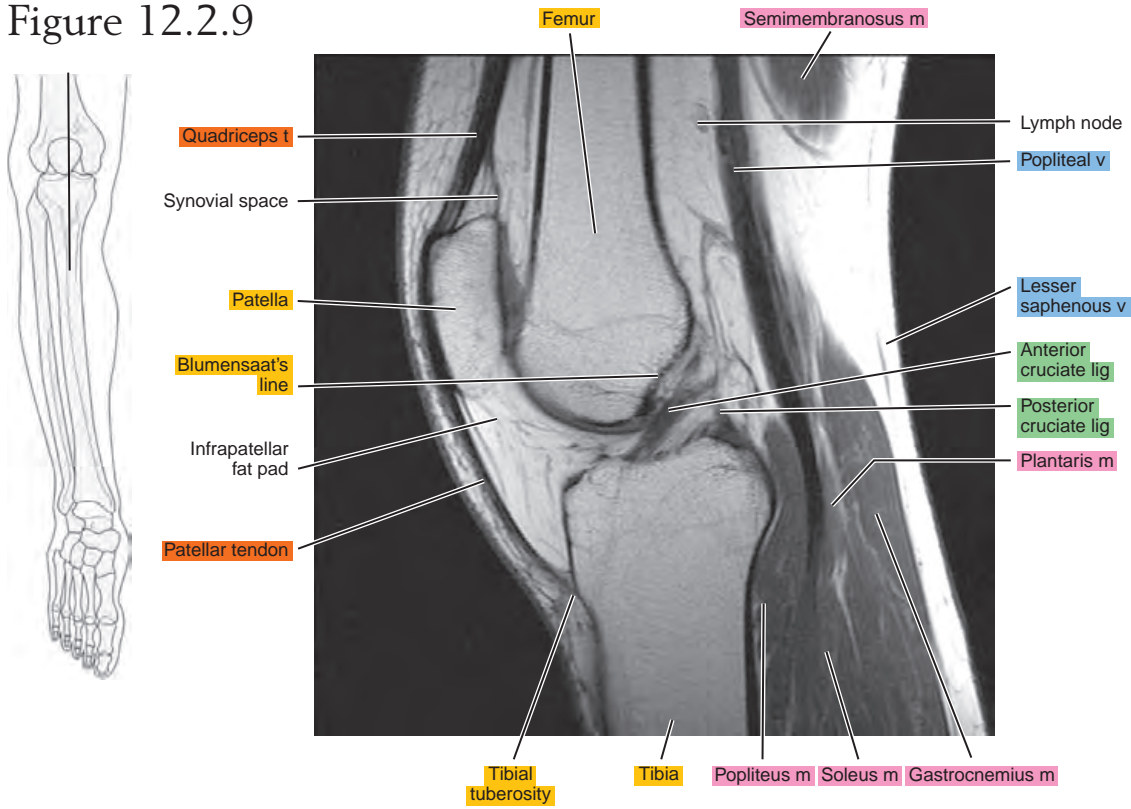


Figure 12.2.10

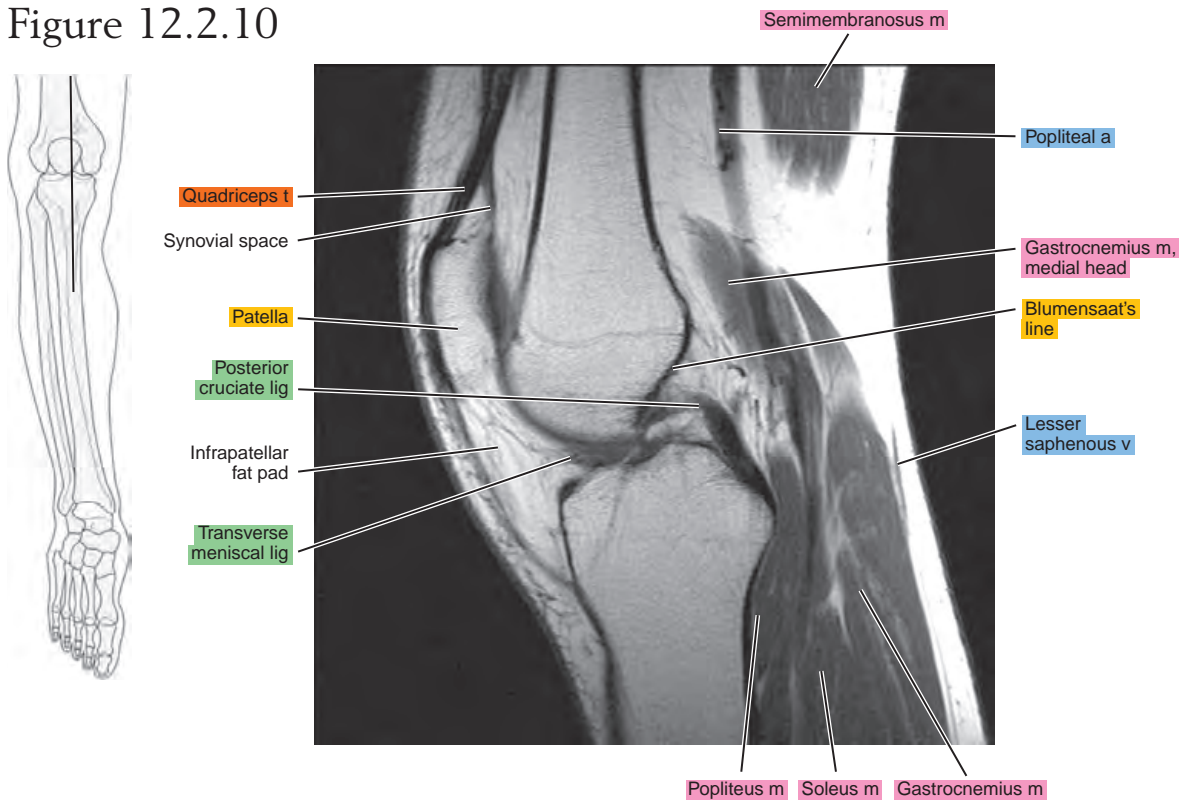


Figure 12.2.11

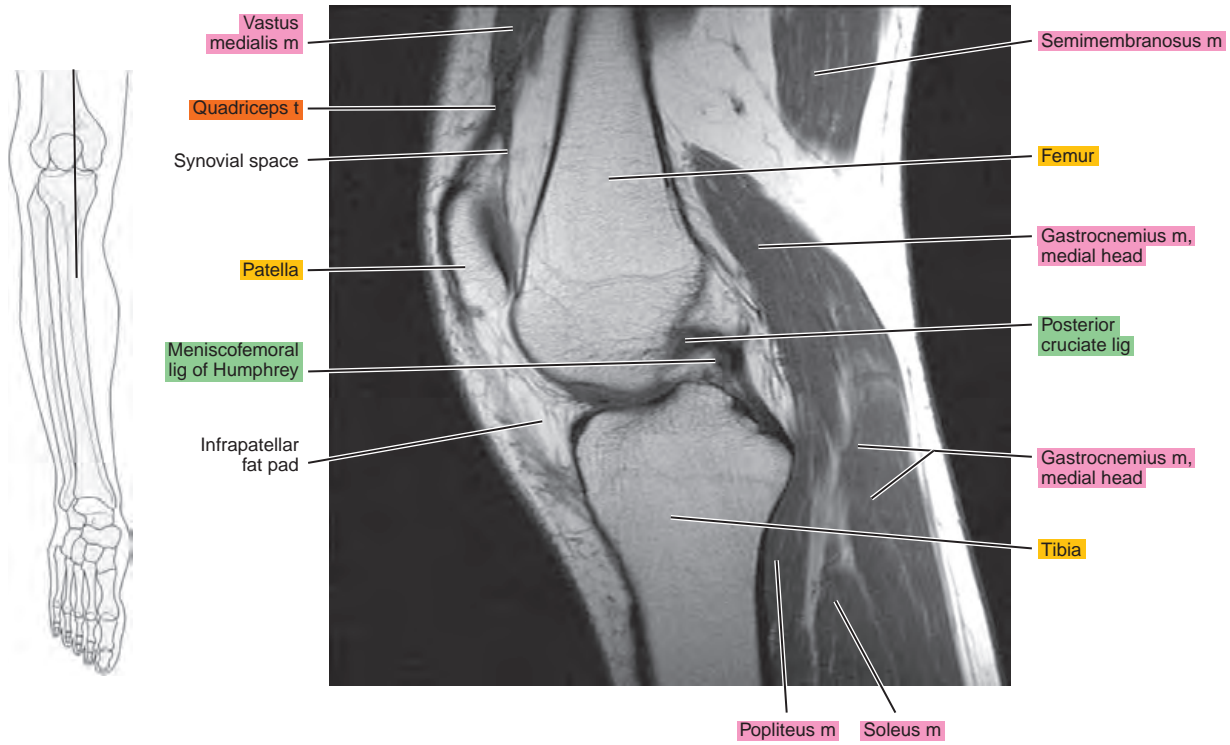


Figure 12.2.12

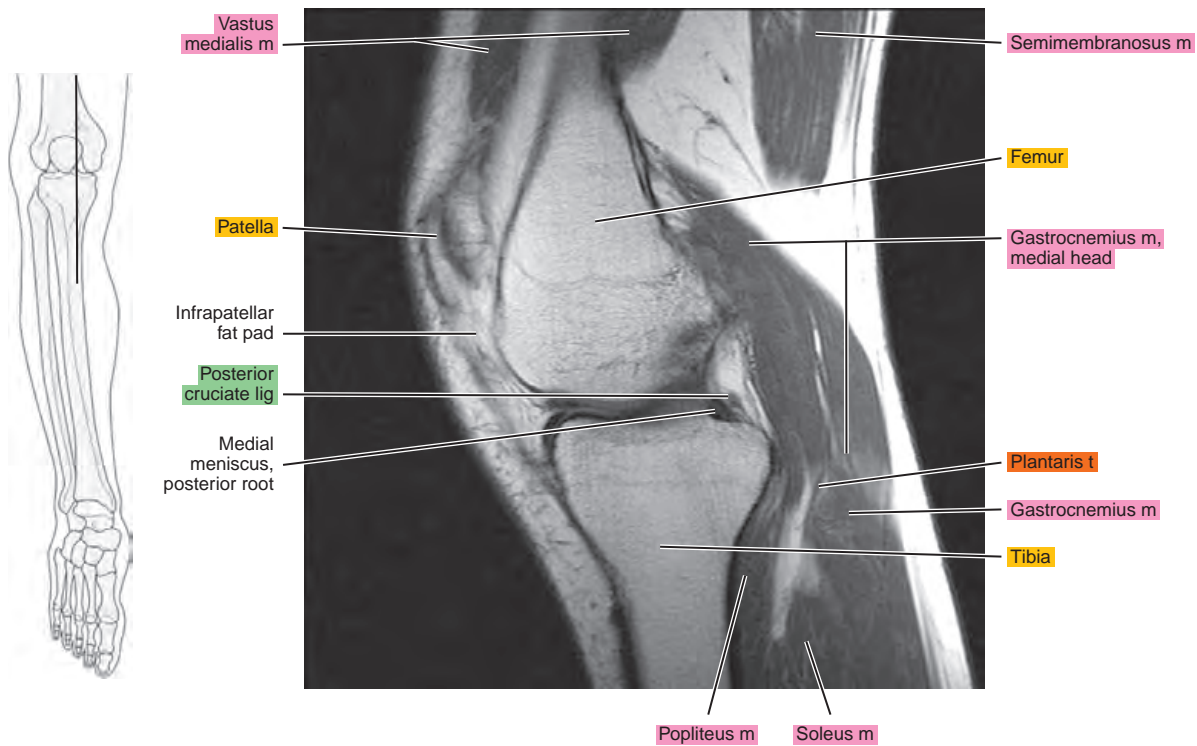


Figure 12.2.13

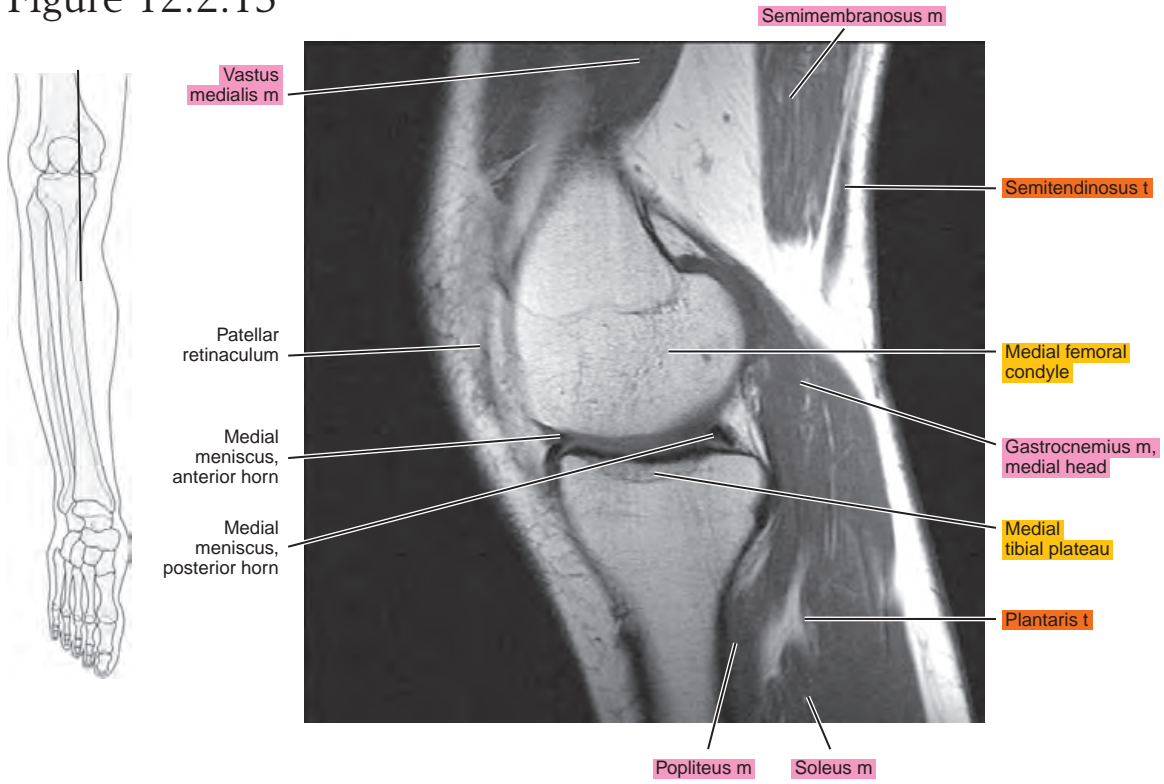


Figure 12.2.14

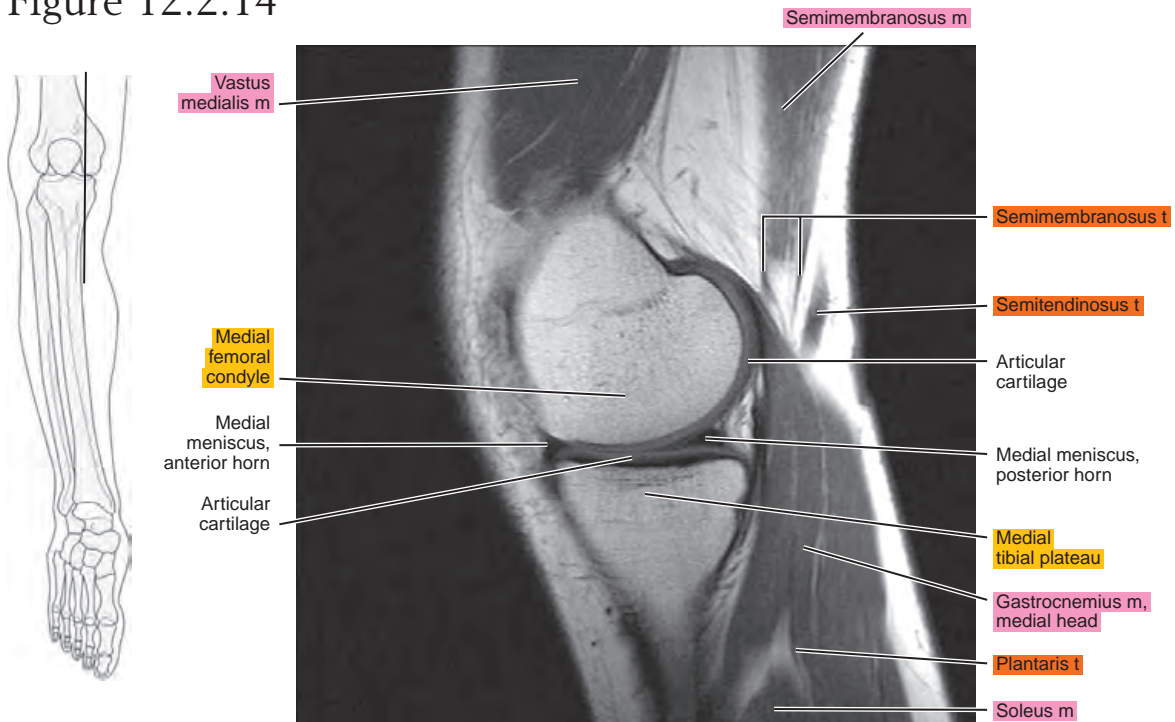


Figure 12.2.15

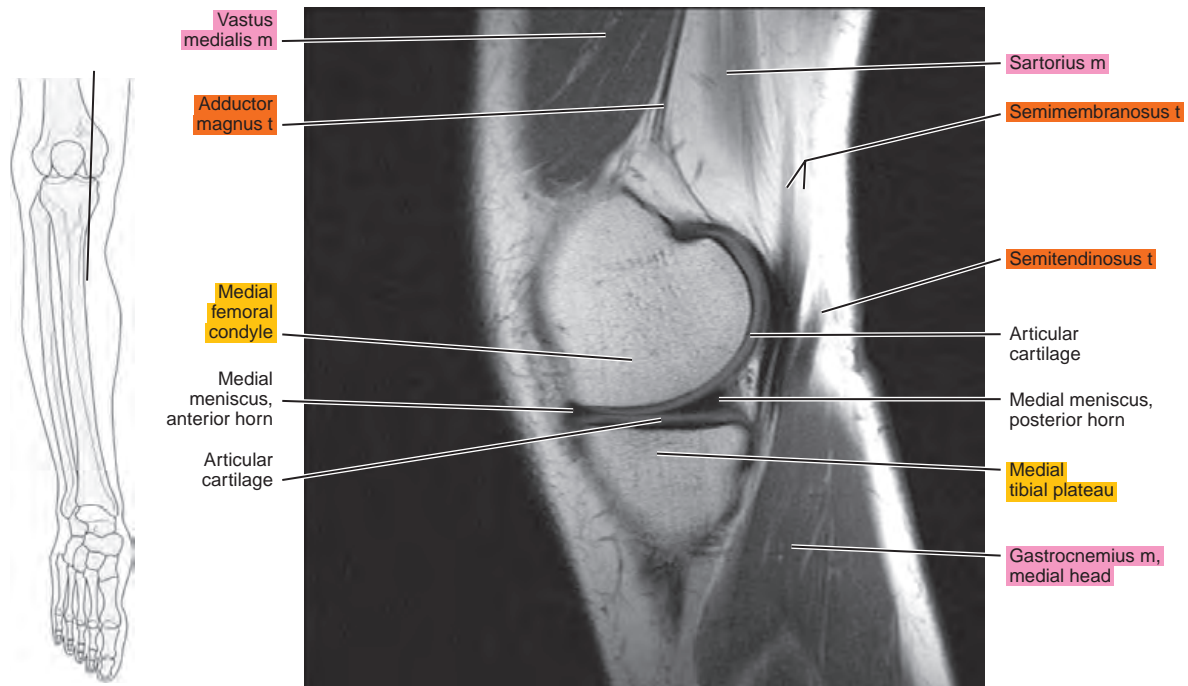


Figure 12.2.16

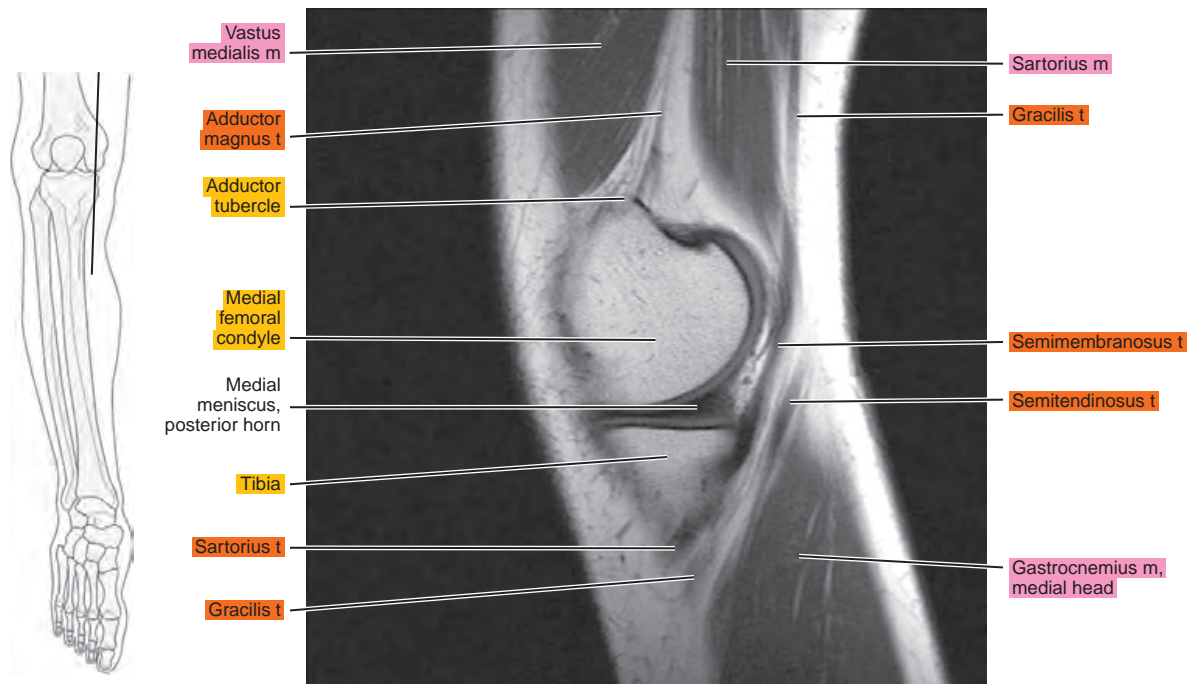
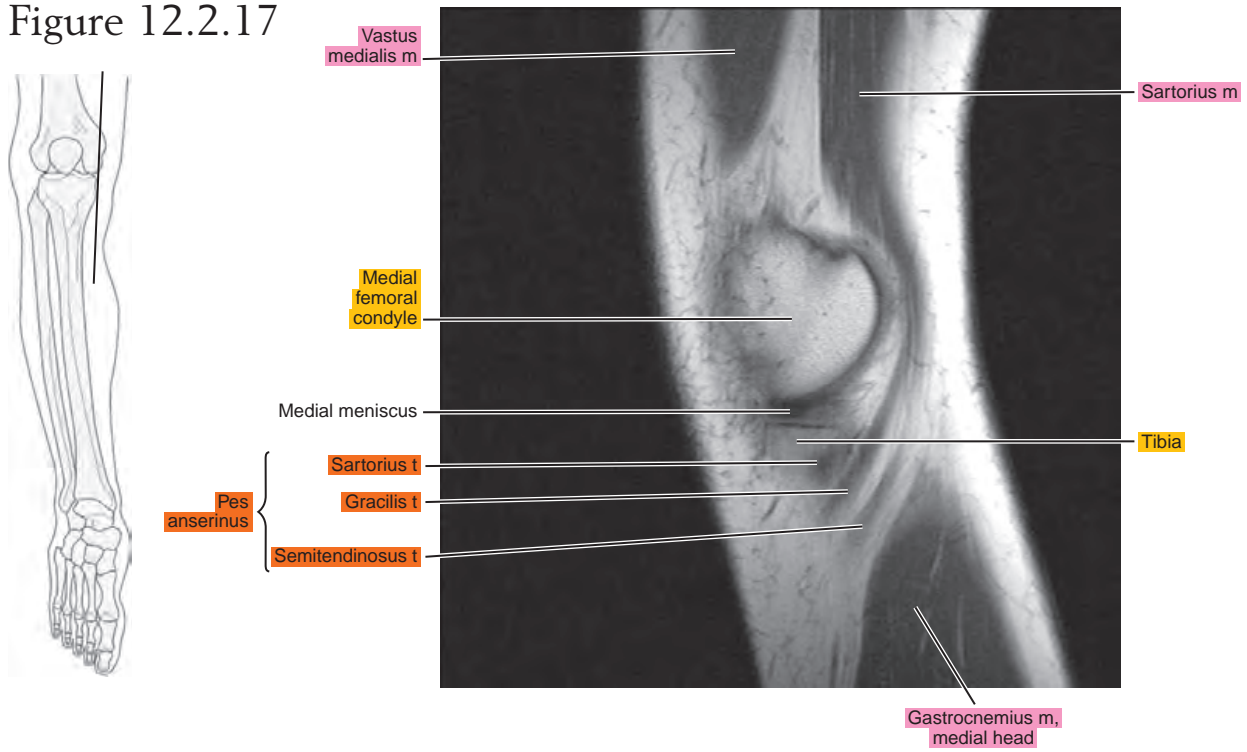


Figure 12.2.17



CORONAL

Figure 12.3.1

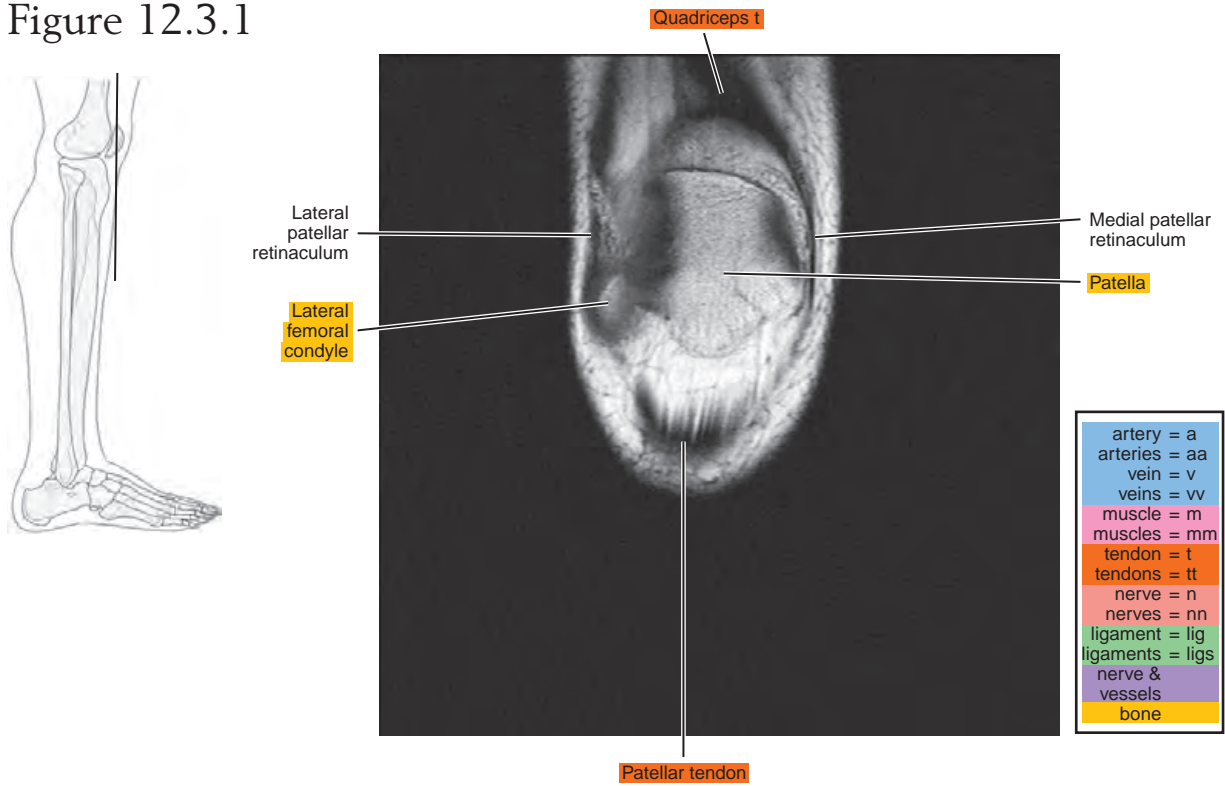


Figure 12.3.2

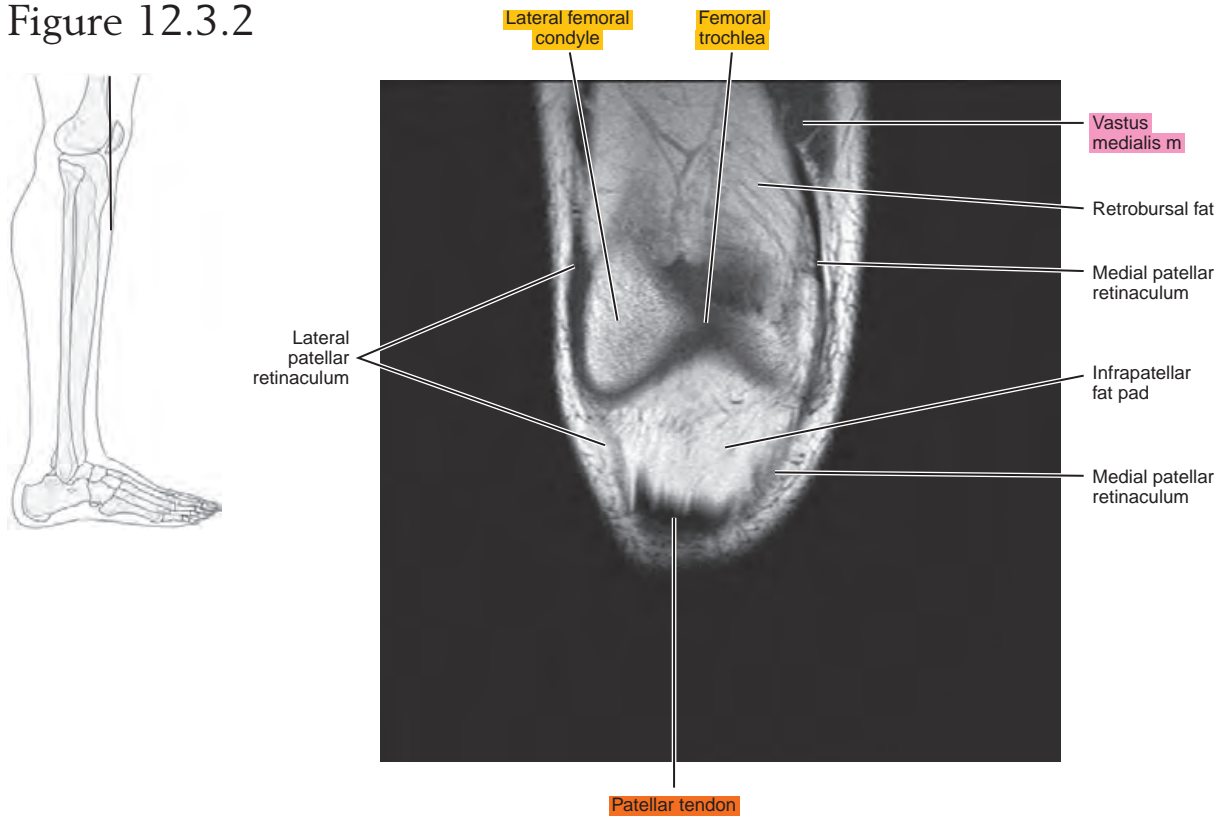


Figure 12.3.3

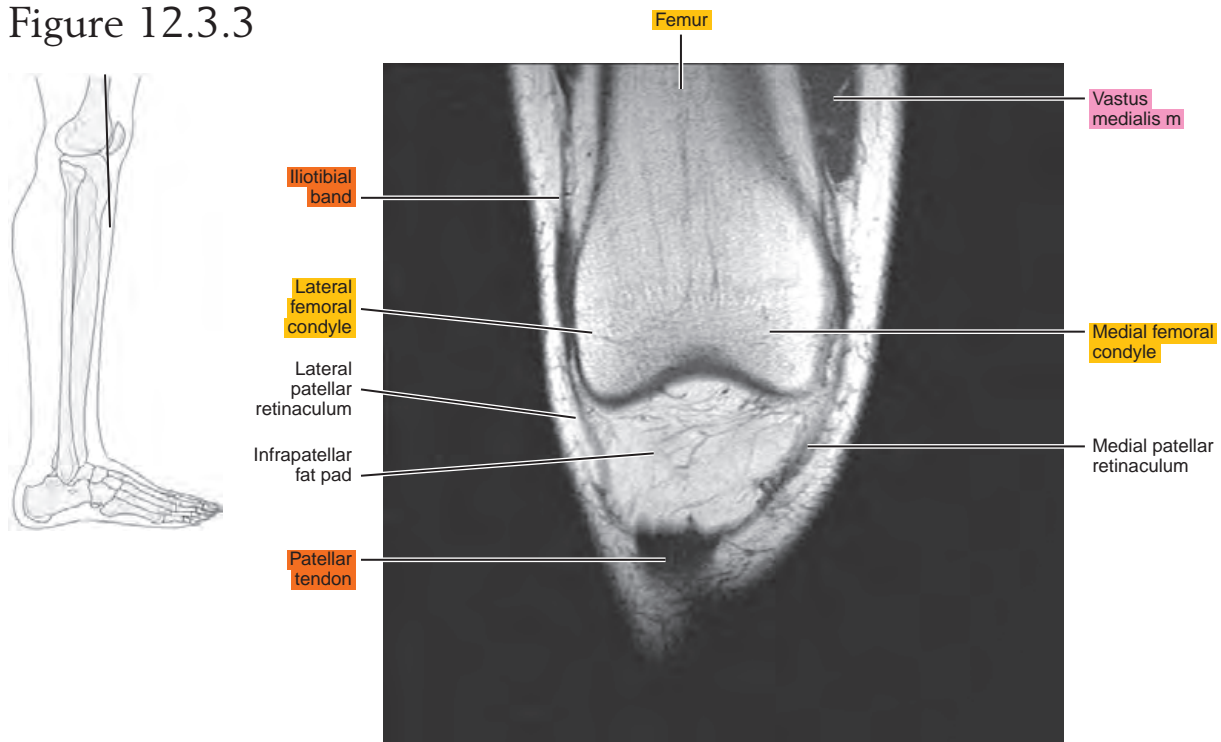


Figure 12.3.4

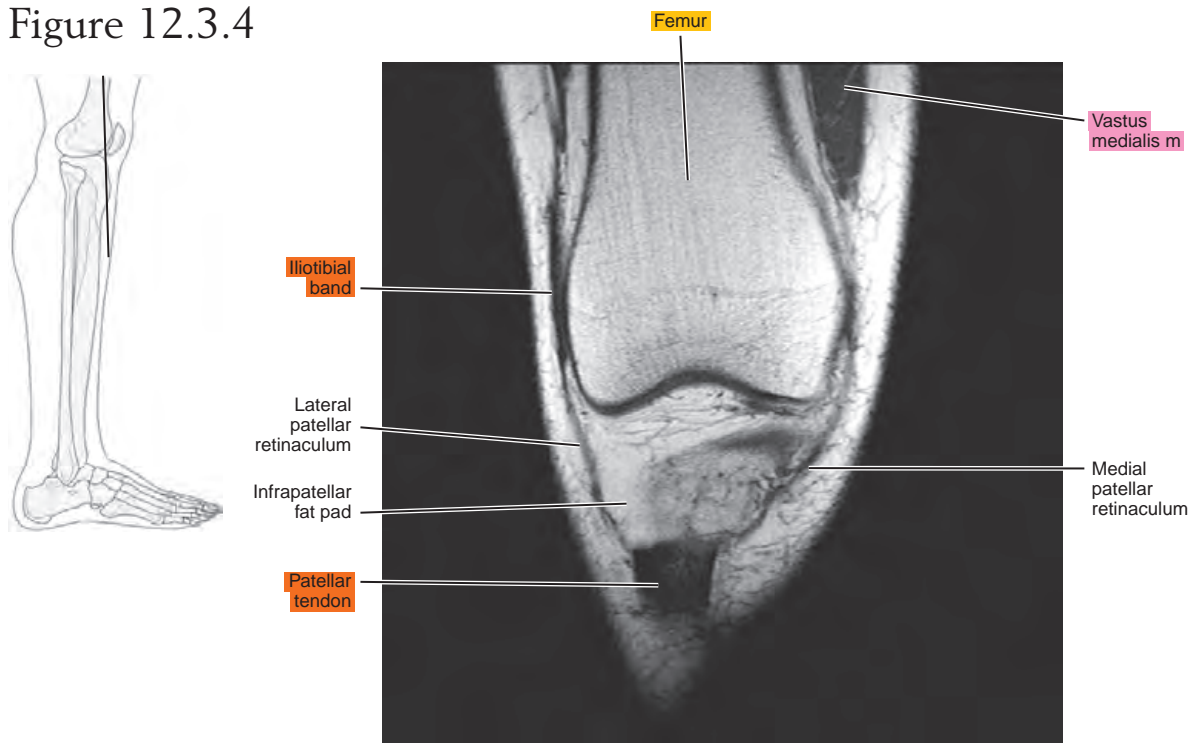


Figure 12.3.5

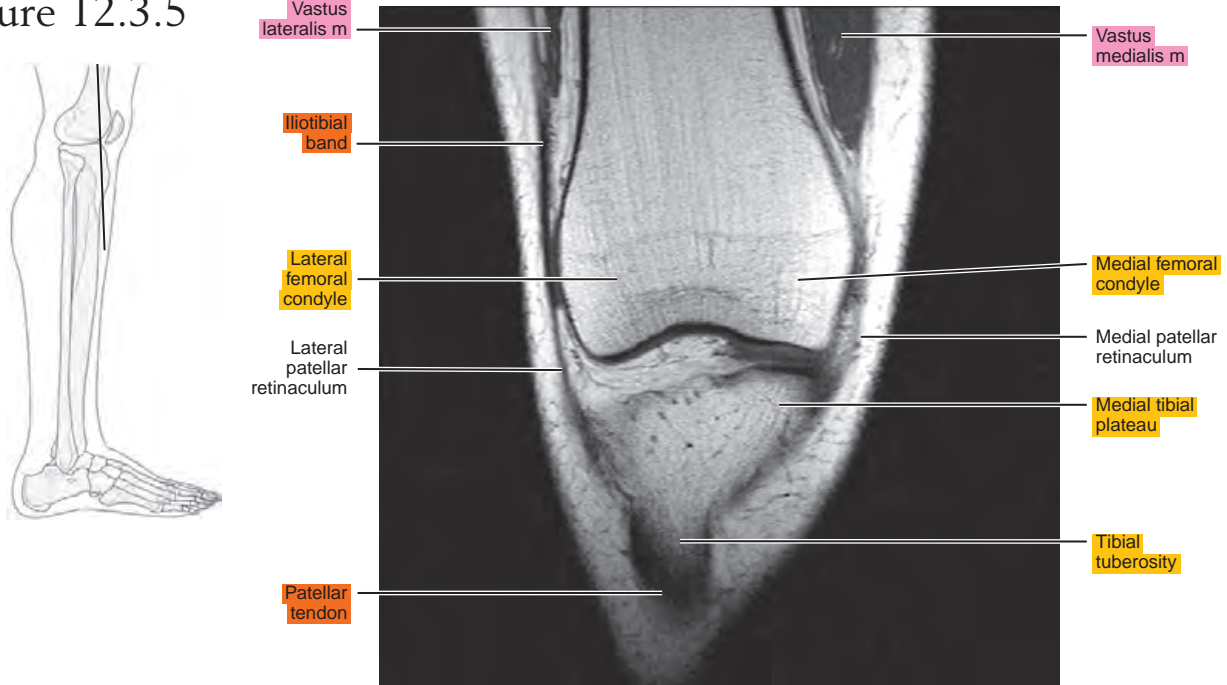


Figure 12.3.6

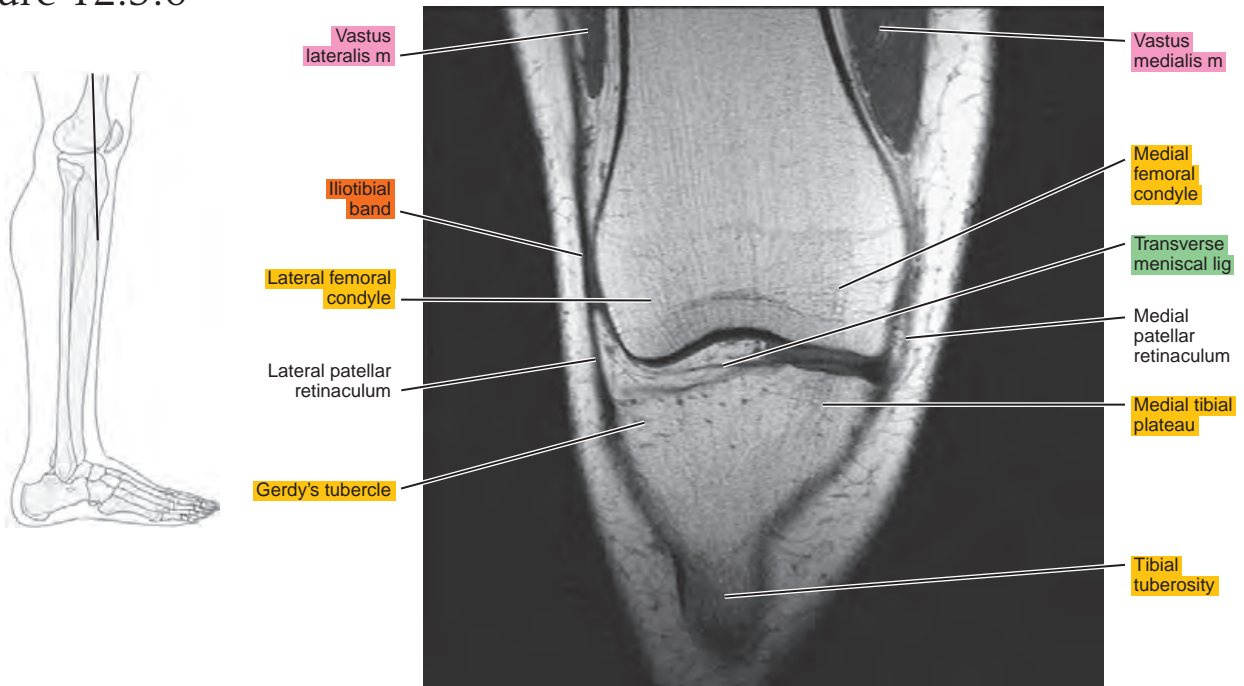


Figure 12.3.7

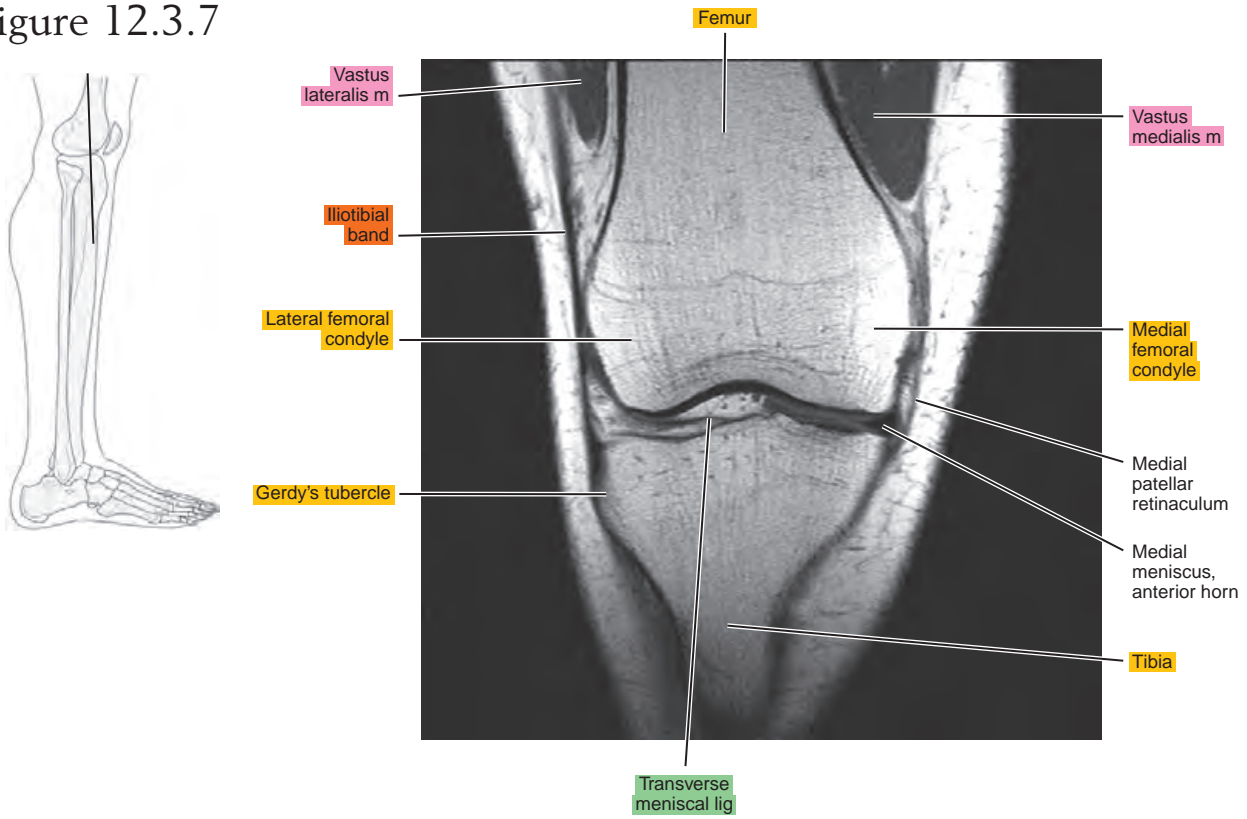


Figure 12.3.8

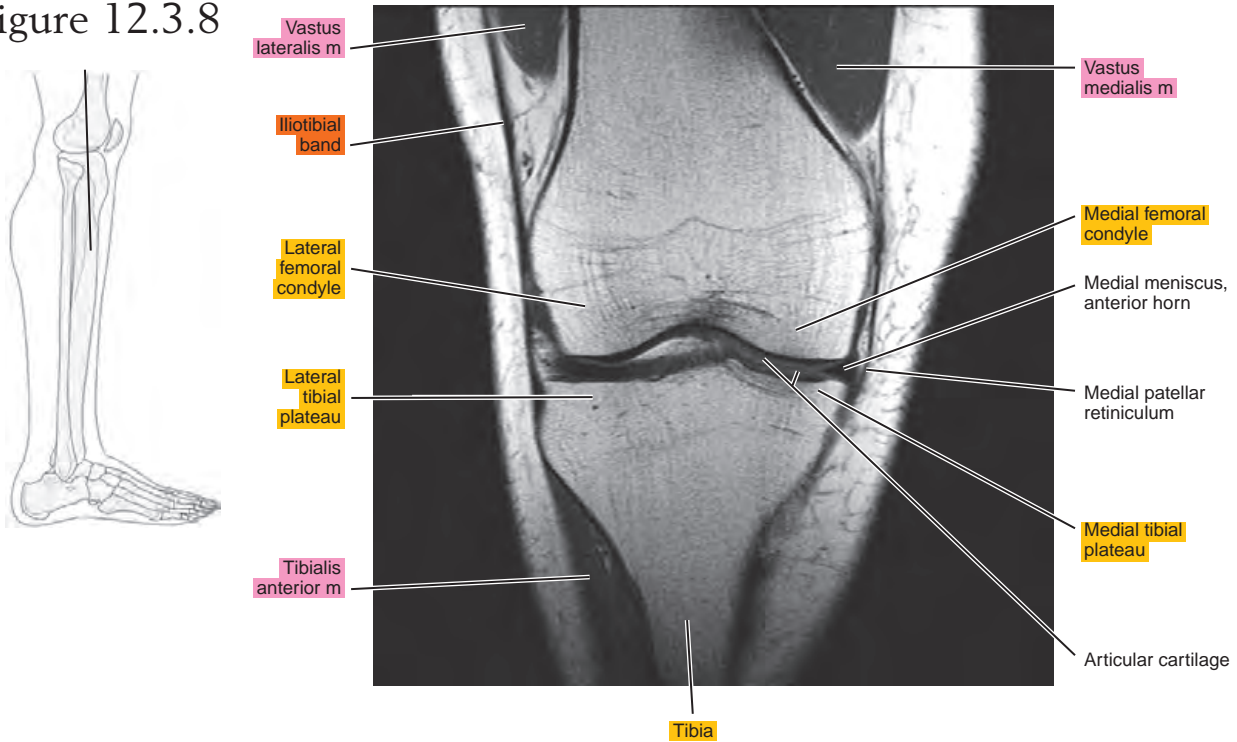


Figure 12.3.9

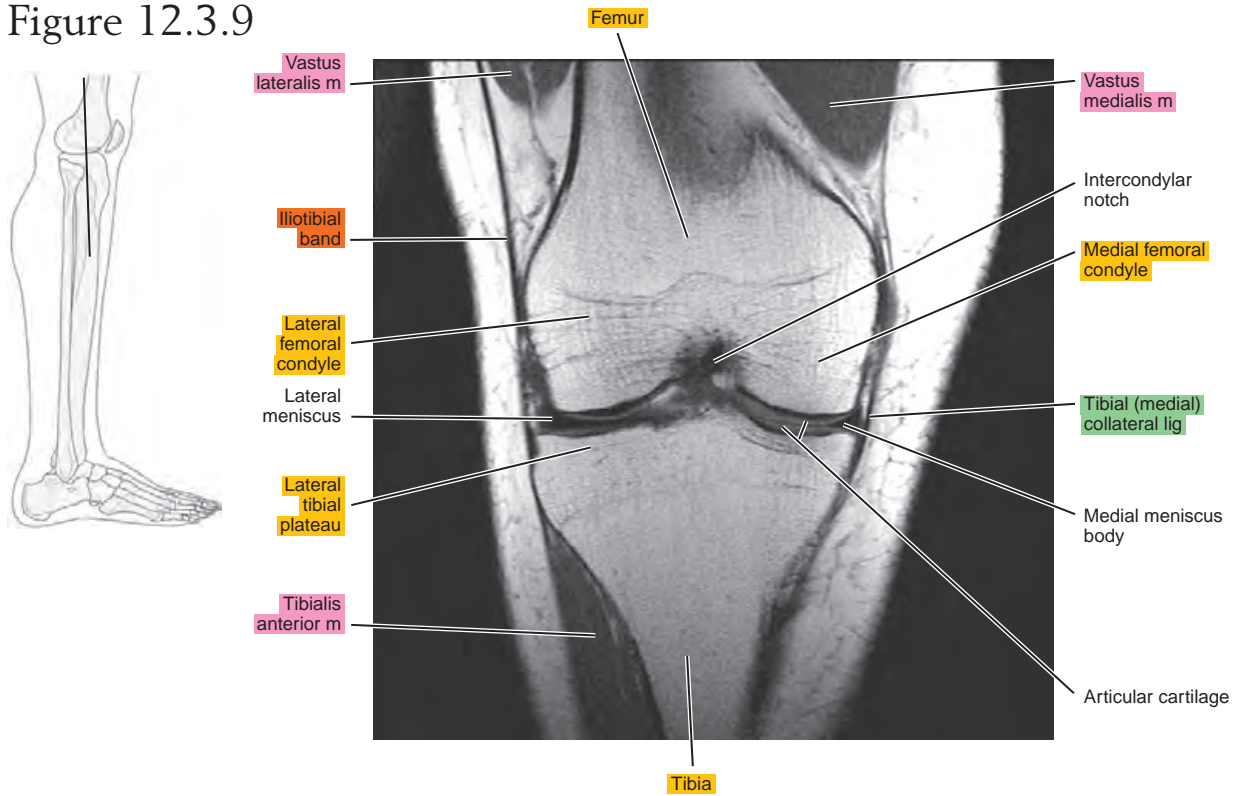


Figure 12.3.10

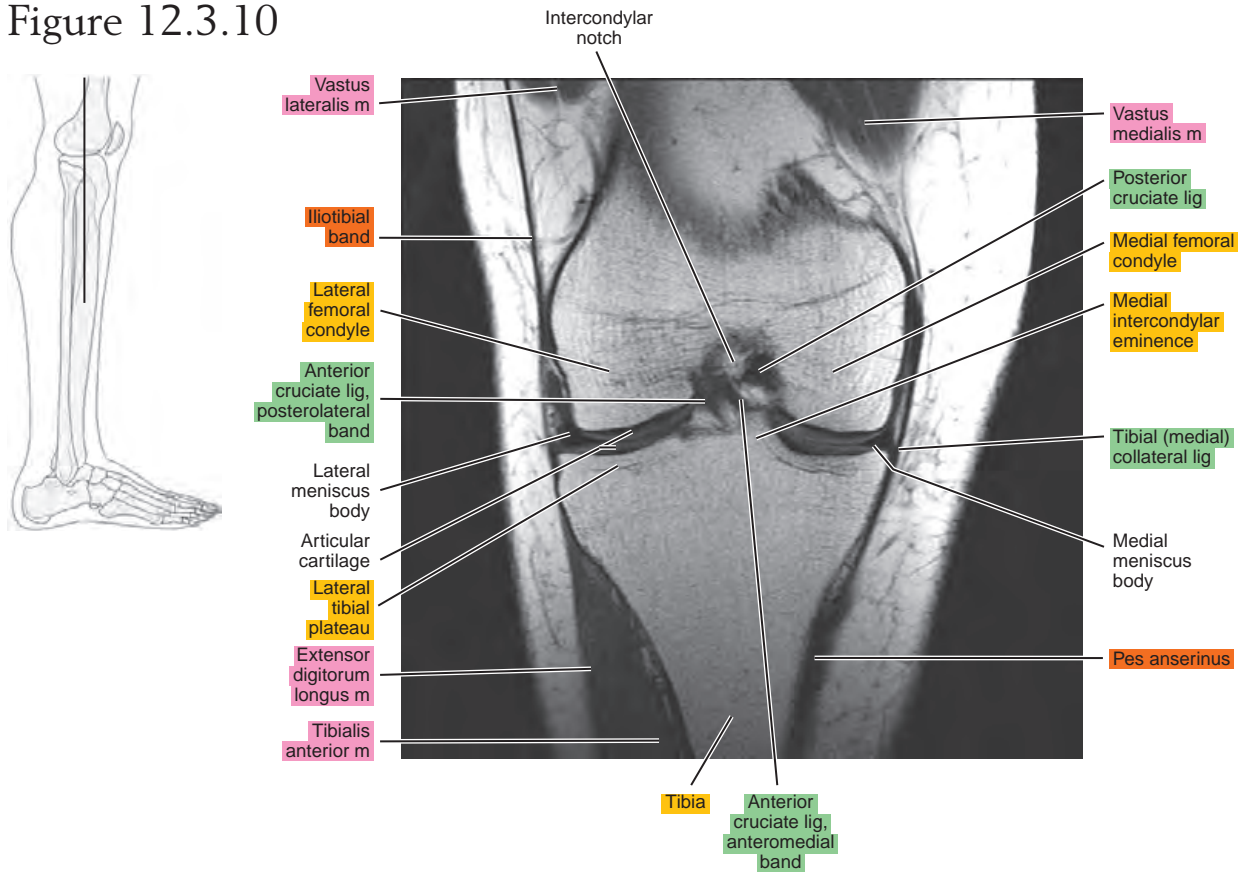


Figure 12.3.11

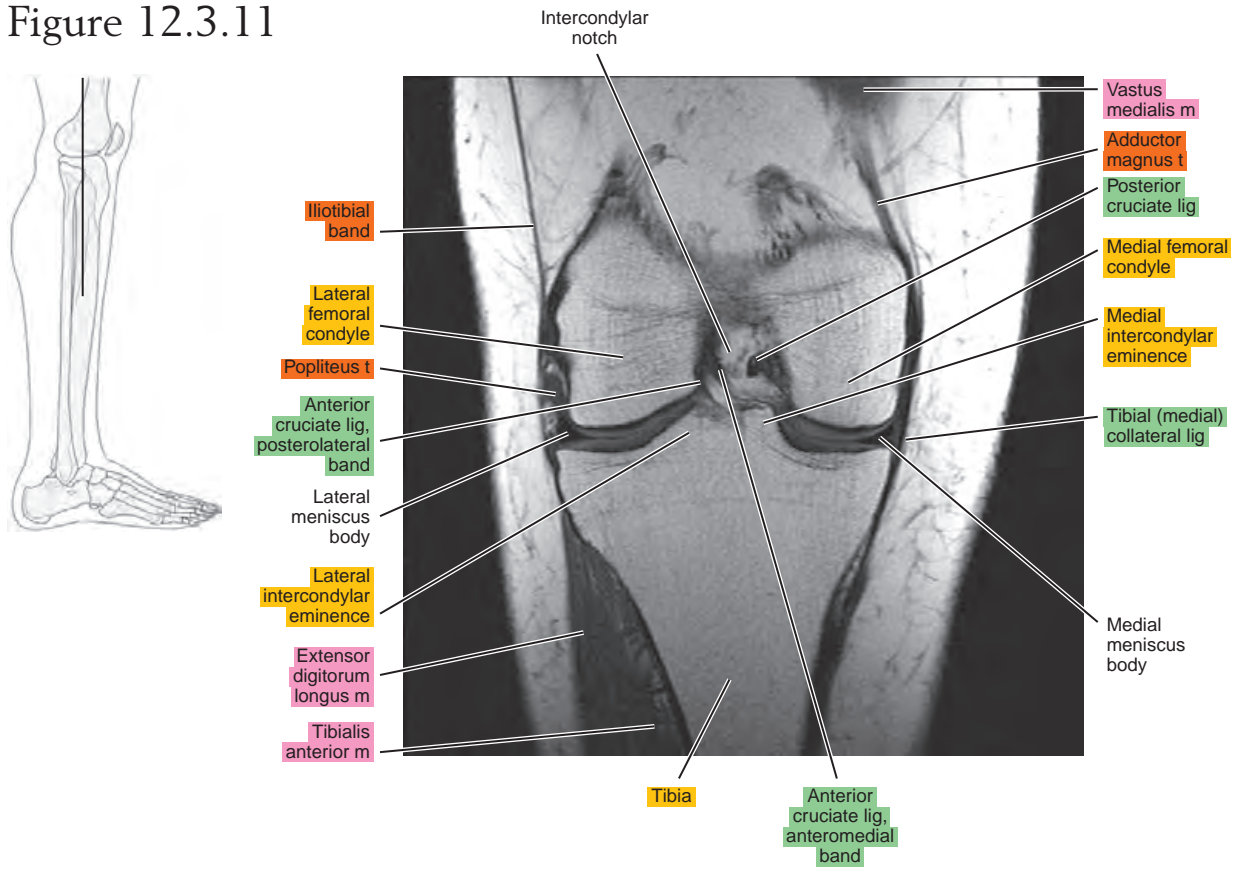


Figure 12.3.12

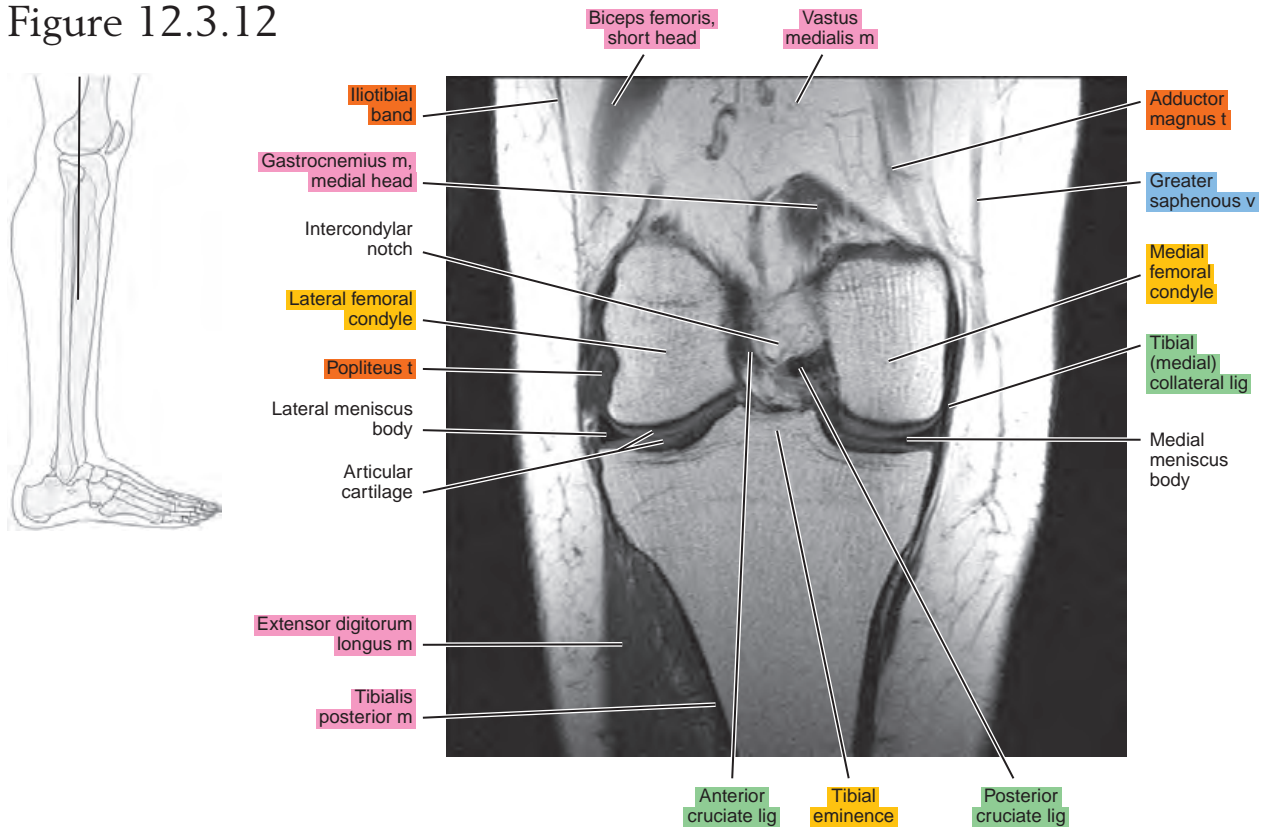


Figure 12.3.13

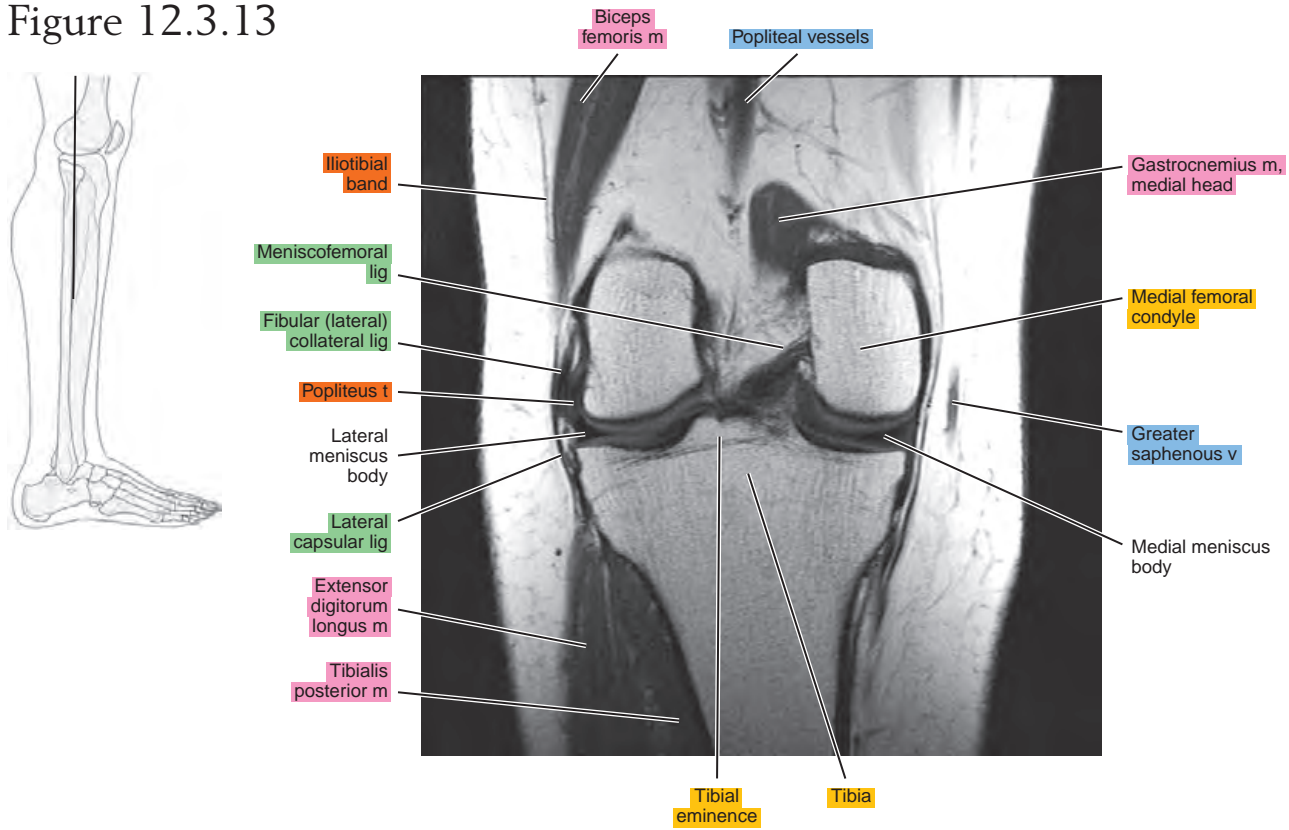


Figure 12.3.14

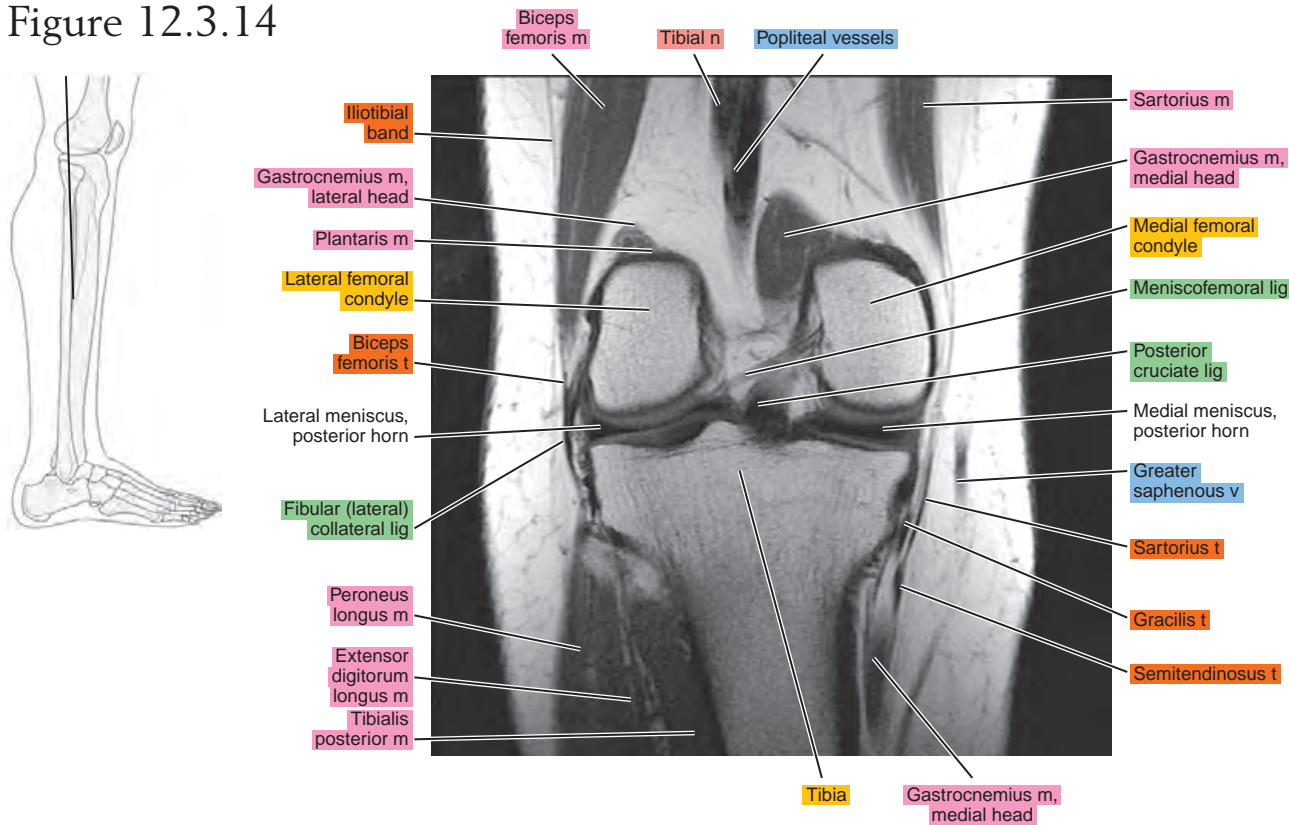


Figure 12.3.15

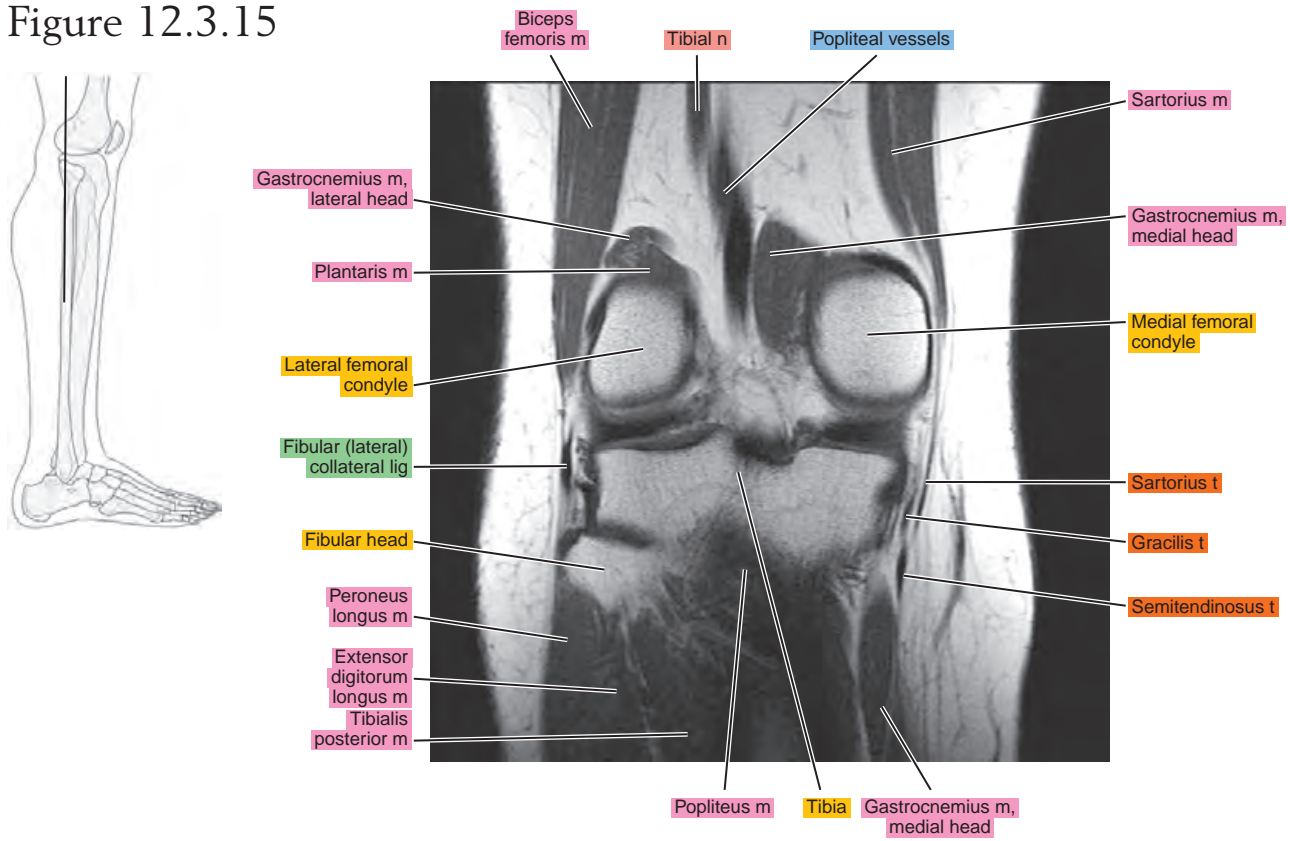


Figure 12.3.16

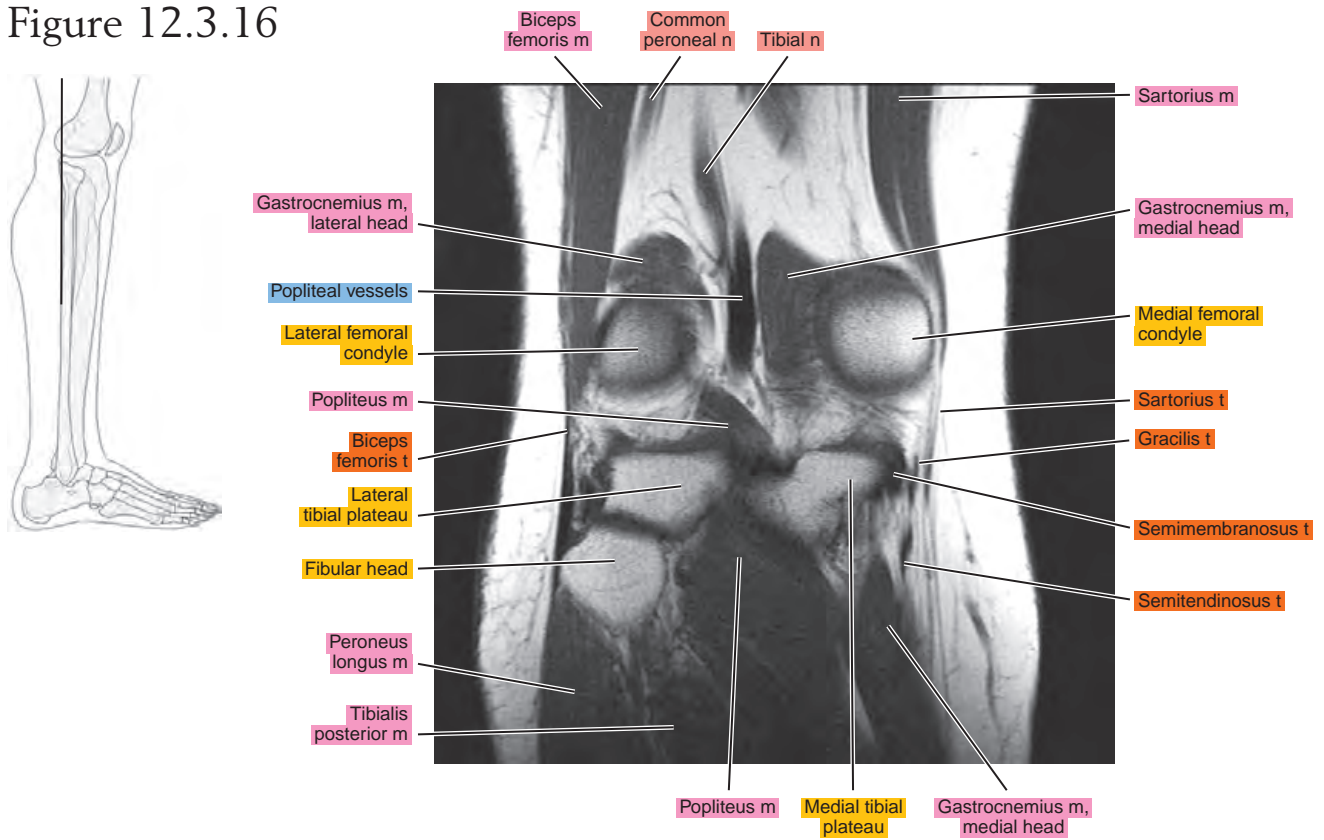


Figure 12.3.17

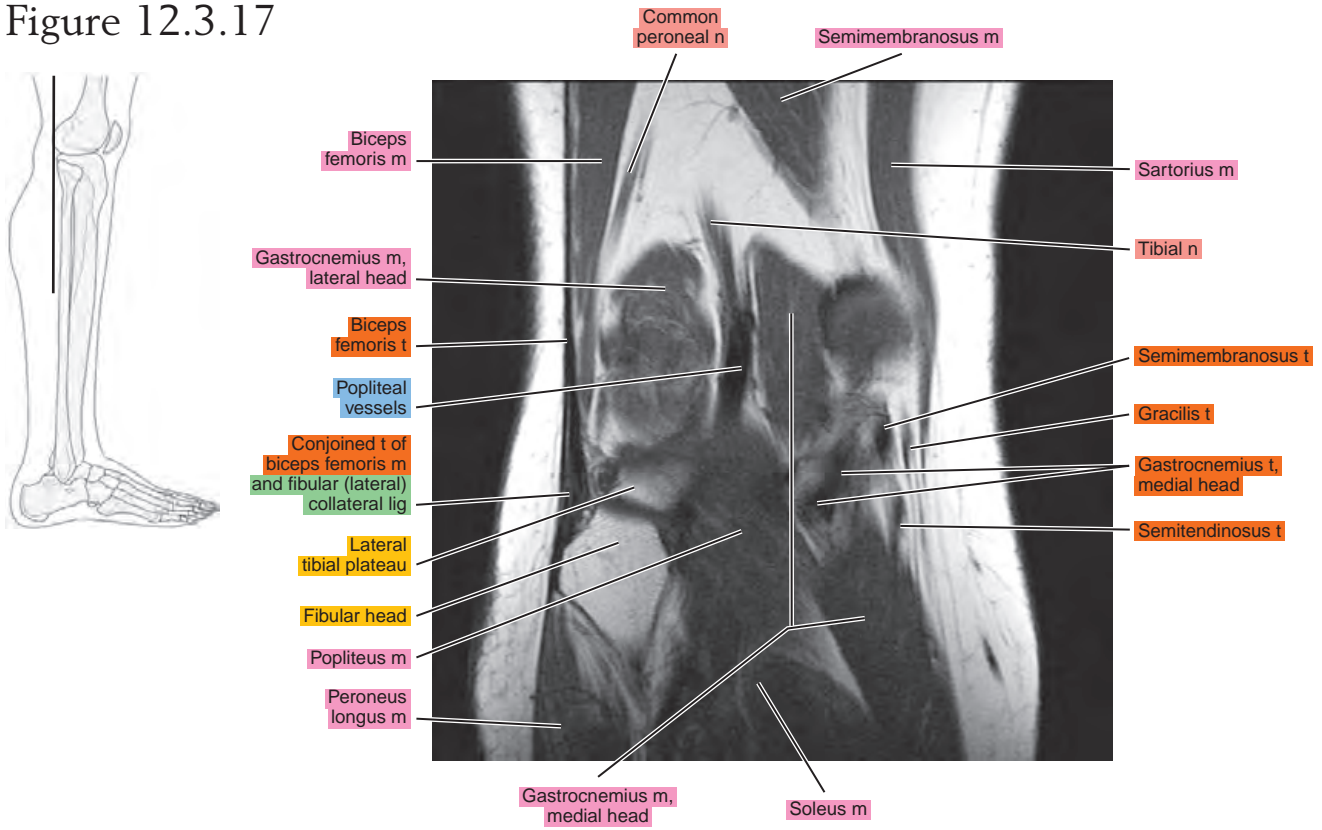


Figure 12.3.18

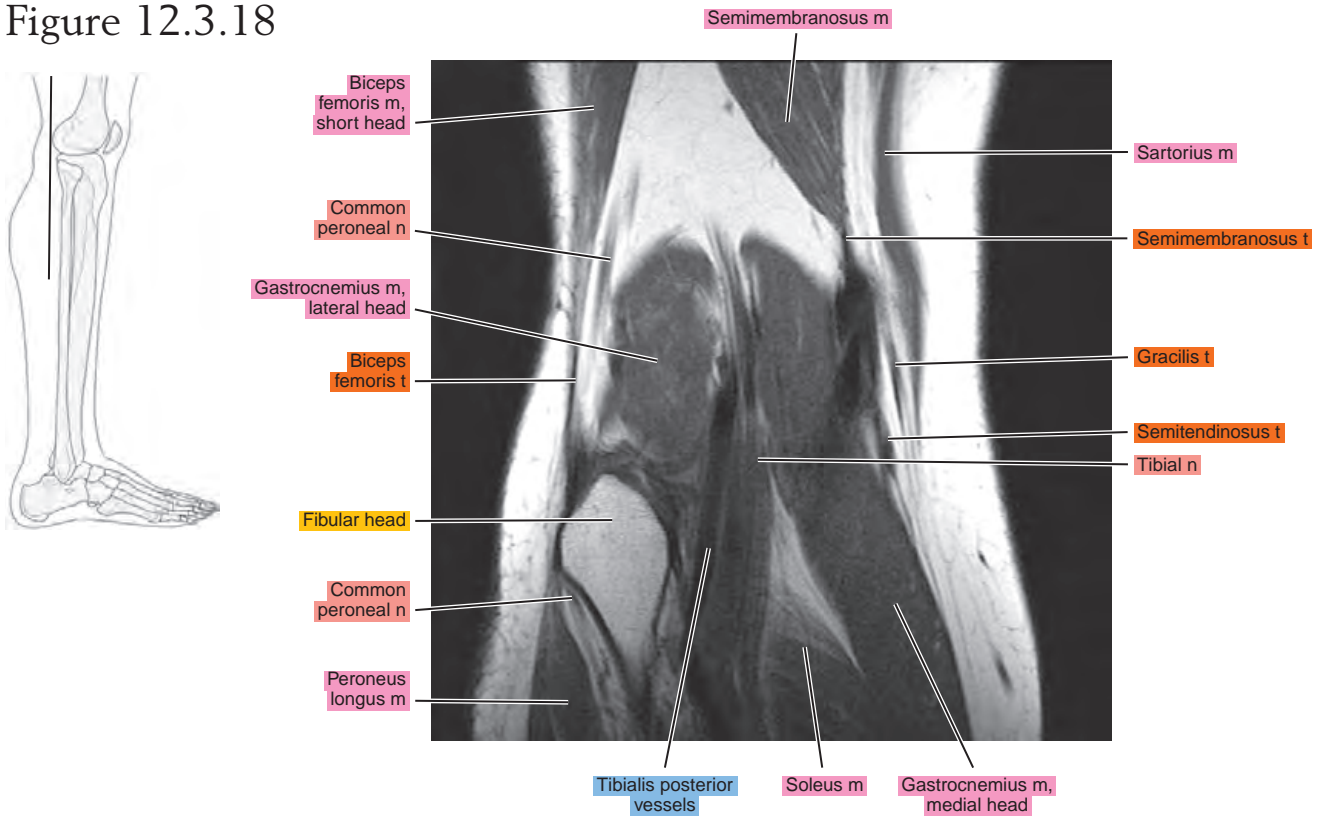
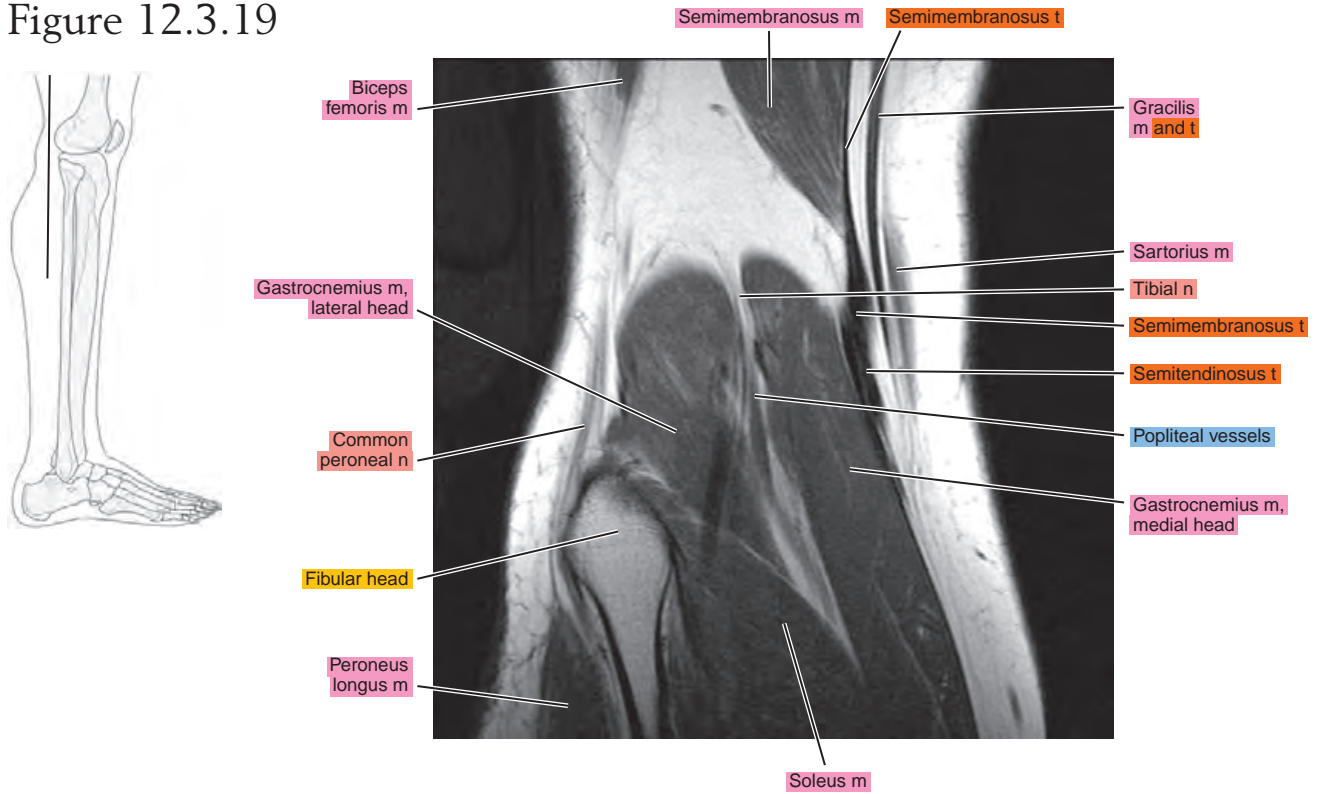


Figure 12.3.19



Chapter
13

MRI of the Leg

Table 13-1. Muscles of the Leg

MUSCLE	ORIGIN	INSERTION	NERVE SUPPLY
Tibialis anterior	Distal part of the lateral condyle of the tibia, lateral surface of the proximal half of the shaft of the tibia, adjacent interosseous membrane, overlying fascia near the condyle of the tibia, and intermuscular septum between it and the extensor digitorum longus	Medial surface of the first cuneiform and the base of the first metatarsal	Branch from the common peroneal and another from the deep peroneal
Extensor digitorum longus	Lateral condyle of the tibia, anterior crest of the fibula intermuscular membrane between it and the tibialis anterior, lateral margin of the interosseous membrane, the septum between it and the peroneus longus, and fascia of the leg near the tibial origin	Each tendon, located on the dorsal surface of the toe to which it goes, divides into three fasciculi: the intermediate, attached to the dorsum of the base of the middle phalanx; and two lateral, which converge to the dorsum of the base on the distal phalanx. The margins of each tendon are bound to the sides of the back of the proximal phalanx	By two branches of the deep peroneal
Peroneus tertius	Distal one third of the anterior surface of the fibula, neighboring interosseous membrane, and anterior intermuscular septum	Onto the base of the fifth metatarsal and often onto the base of the fourth	The more distal nerve to the extensor digitorum supplies this muscle (deep peroneal)
Extensor hallucis longus	Middle half of the anterior surface of the fibula near the interosseous crest and distal half of the interosseous membrane	At the base of the dorsal aspect of the great toe	Deep peroneal
Peroneus longus	Proximal two thirds of the lateral surface of the fibula	Inferior surface of the first cuneiform and on the adjacent part of the inferolateral border and the base of the first metatarsal	Usually, the common peroneal, sometimes partially by superficial peroneal
Peroneus brevis	Middle one third of the lateral surface of the fibula, from the septum that separate it from the anterior and posterior groups of muscles	Dorsal aspect of the tuberosity of the fifth metatarsal	Superficial peroneal or a branch to peroneus longus
Popliteus	Facet at the anterior end of the groove on the lateral aspect of the femoral condyle	Proximal lip of the popliteal line of the tibia and the shaft of the tibia proximal to this line	Tibial: a branch that arises independently, or with the nerve to the posterior tibial muscle
Flexor digitorum longus	Popliteal line, medial side of the second quarter of the dorsal surface of the tibia, fibrous septum between the muscle and the tibialis fascia posterior, and the covering its proximal extremity	Onto the bases of the terminal phalanges of the second to fourth toes	Tibial: in company with nerves to other muscles of this group
Flexor hallucis longus	Distal two thirds of the posterior surface of the fibula, the septa between it and the tibialis posterior, and peroneal muscles	Onto the base of the terminal phalanx of the great toe	Tibial: often in company with the nerve to the flexor digitorum longus or other muscles of this group

Table 13-1. Muscles of the Leg—cont'd

MUSCLE	ORIGIN	INSERTION	NERVE SUPPLY
Tibialis posterior	Lateral half of the popliteal line and lateral half of the middle one third of the posterior surface of the tibia, medial side of the head and part of the body of the fibula next to the interosseous membrane in the proximal two thirds, the entire proximal and lateral portion of the lateral part of the posterior surface of the interosseous membrane, and the septum between its proximal portion and the long flexor muscles	The tendon divides into two parts: the deep part becomes attached primarily to the tubercle of the navicular bone, and usually to the first cuneiform; the superficial part attaches to the third cuneiform and the base of the fourth metatarsal, and also, in part, to the second cuneiform, to the capsule of the naviculocuneiform joint, to the sulcus of the cuboid, and usually also to the origin of the short flexor of the big toe and base of the second metatarsal; slip may extend to other structures	Tibial: in company with nerves to other muscles of this group
Gastrocnemius	Medial head: posterior surface of the medial condyle of the femur above the articular surface; lateral head: a facet on the proximal part of the posterolateral surface of the lateral condyle of the femur	Via the Achilles tendon onto the posterior surface of the calcaneus	Sciatic, tibial part
Soleus	By a fibular head from the back of the head and the proximal one third of the posterior surface of the shaft of the fibula; intermuscular septum between it and the peroneus longus, by a tibial head from the popliteal line and the middle one third of the medial border of the tibia	Via the calcaneal tendon onto the posterior surface of the calcaneus	Sciatic, tibial part
Plantaris	Distal part of the lateral line of the bifurcation of the linea aspera, in close association with the lateral head of the gastrocnemius	Via a flat narrow tendon running along the medial edge of the Achilles tendon to the posterior surface of the calcaneus	Sciatic, tibial part

AXIAL

Figure 13.1.1

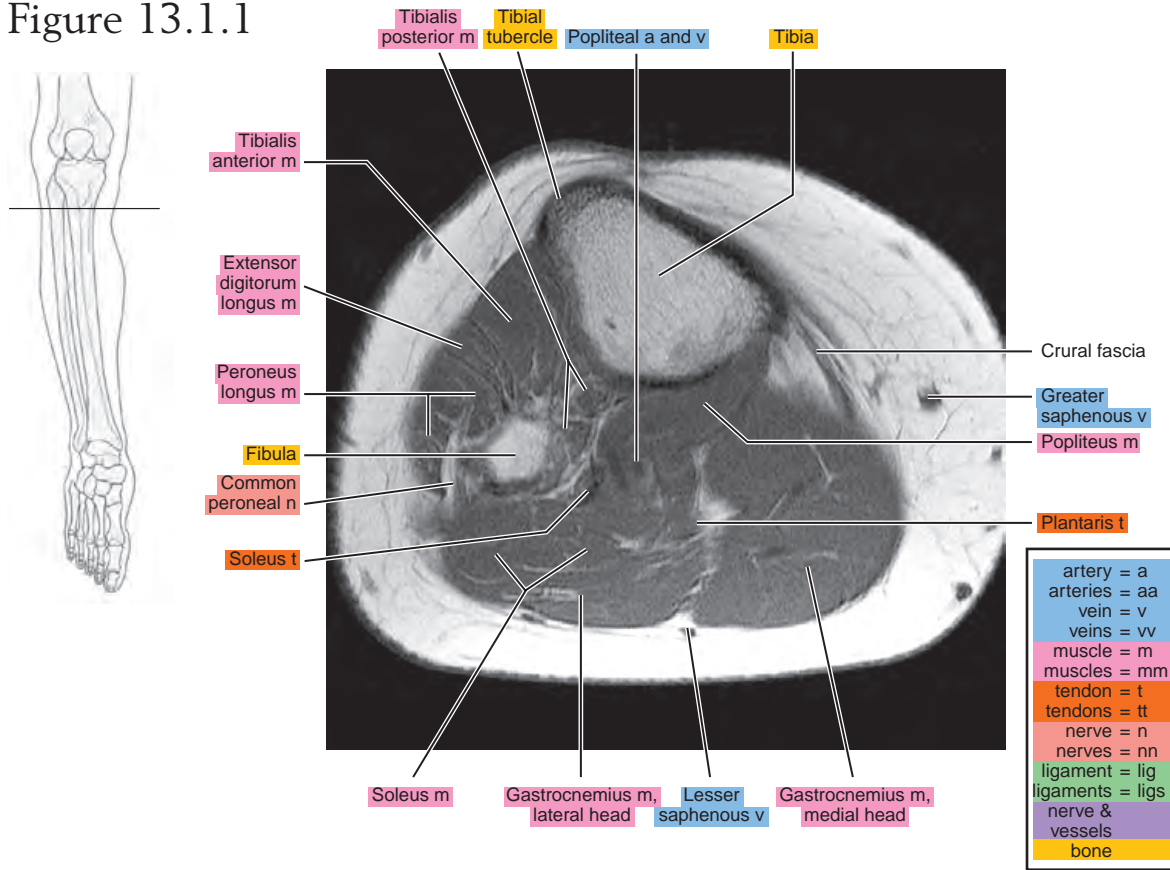


Figure 13.1.2

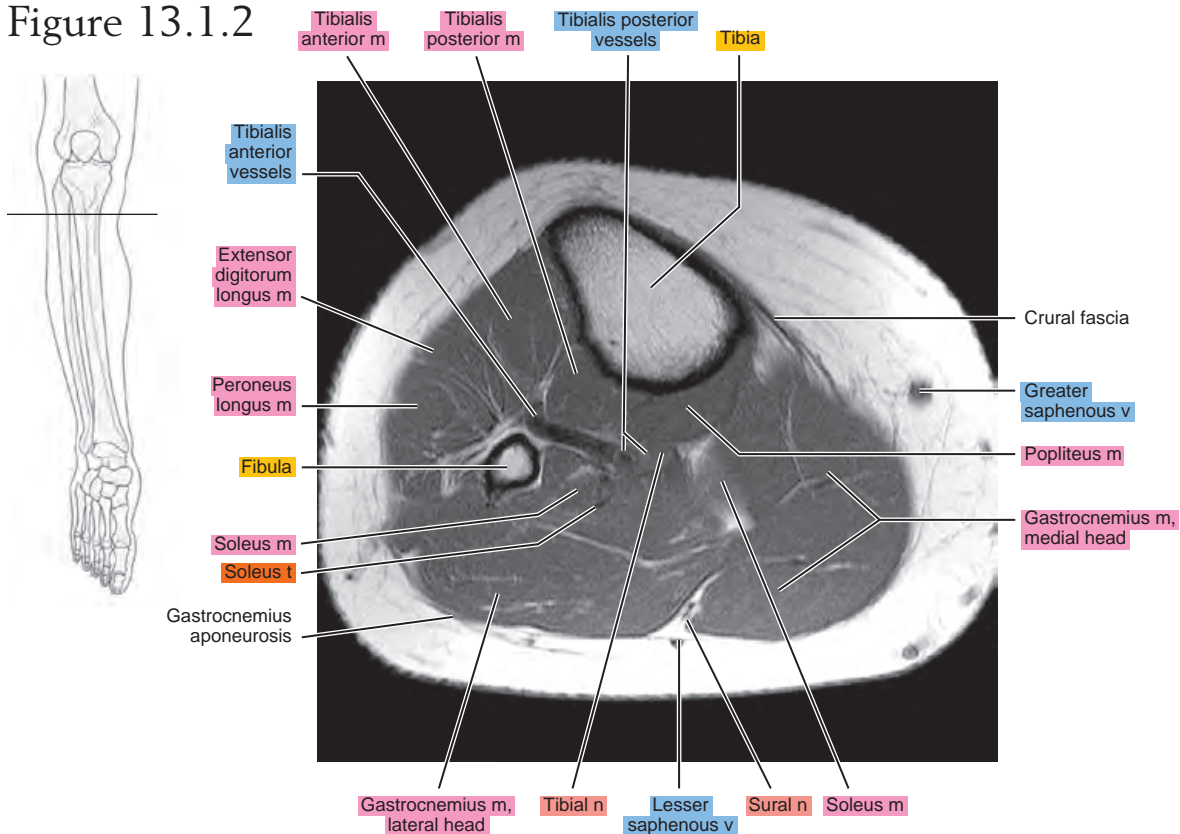


Figure 13.1.3

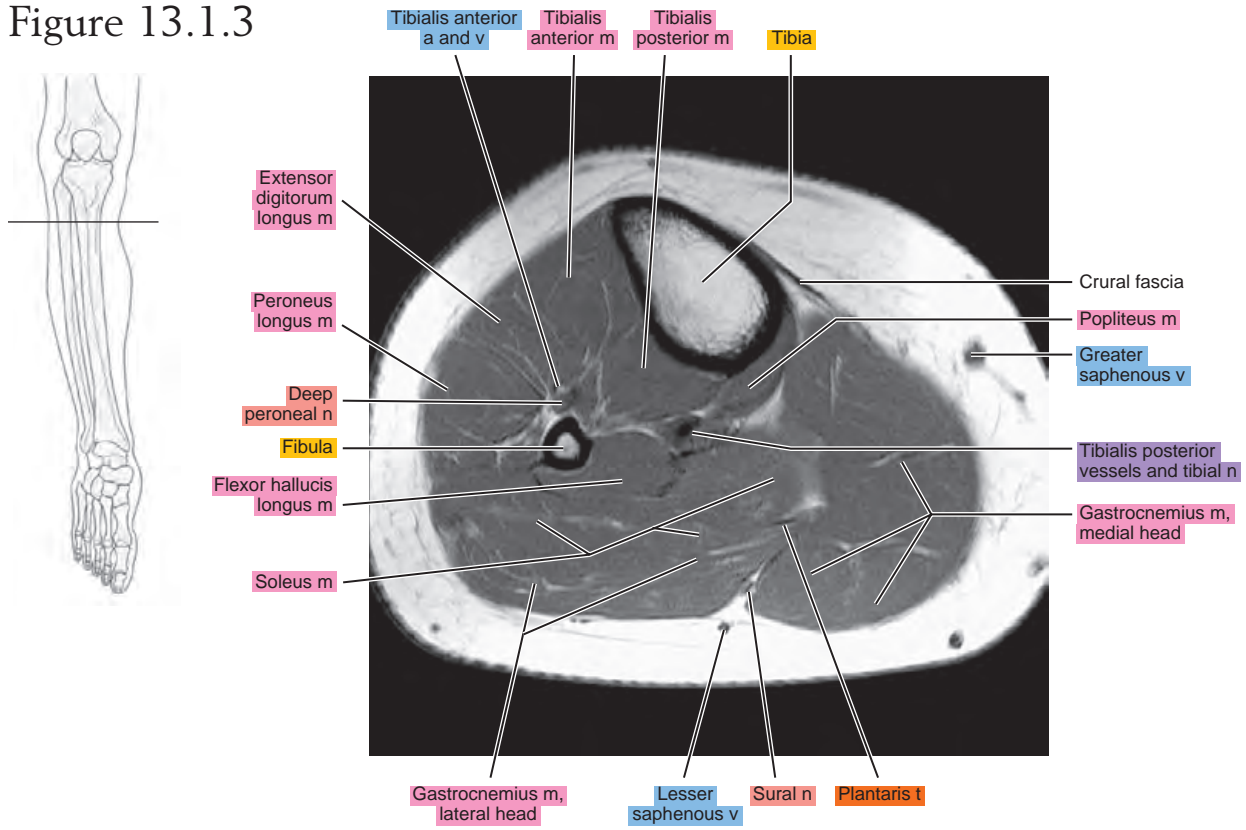


Figure 13.1.4

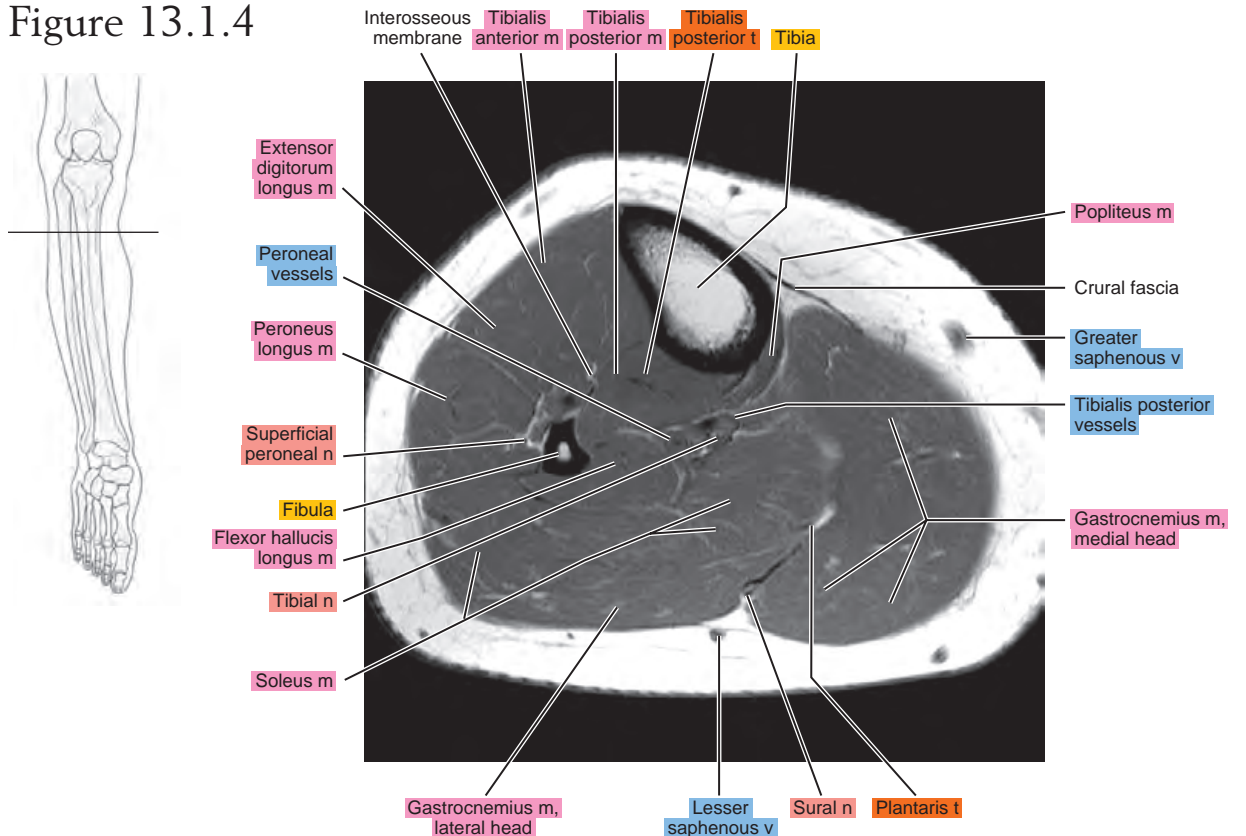


Figure 13.1.5

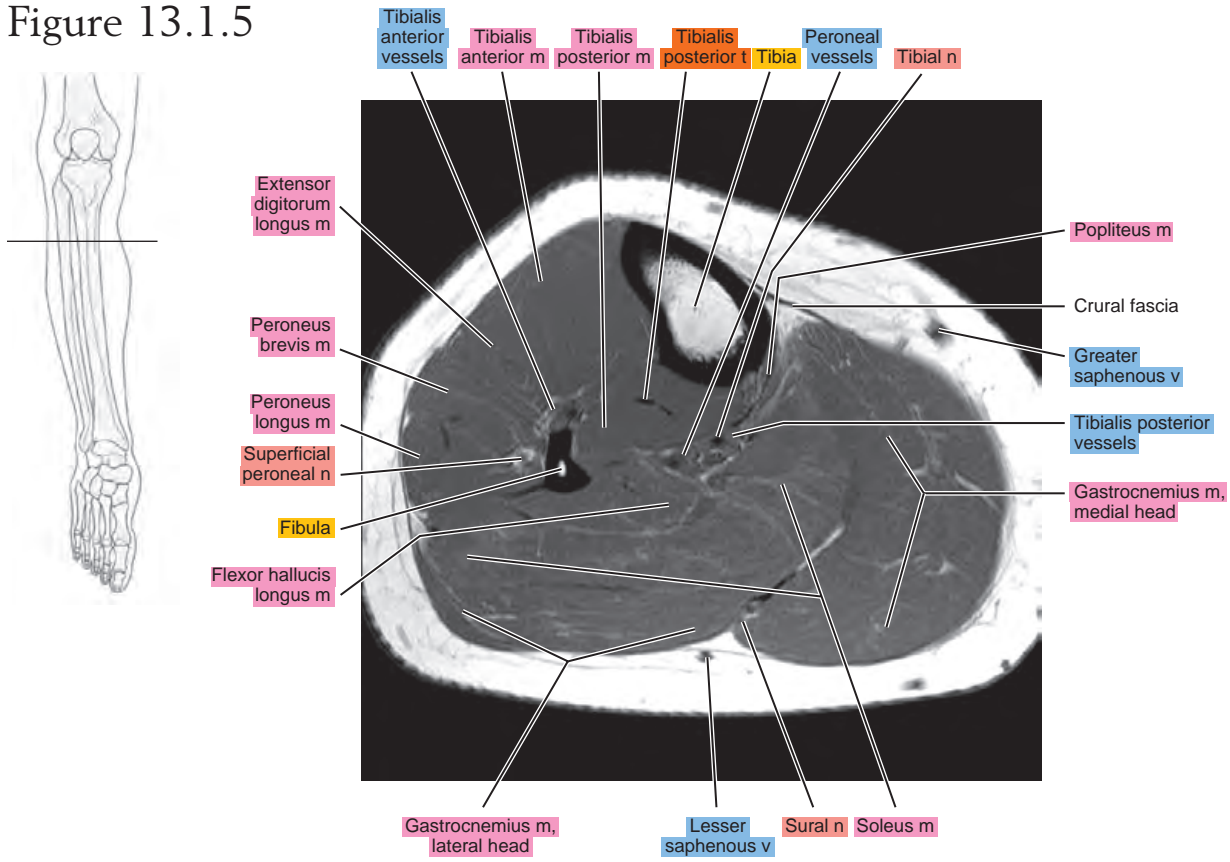


Figure 13.1.6

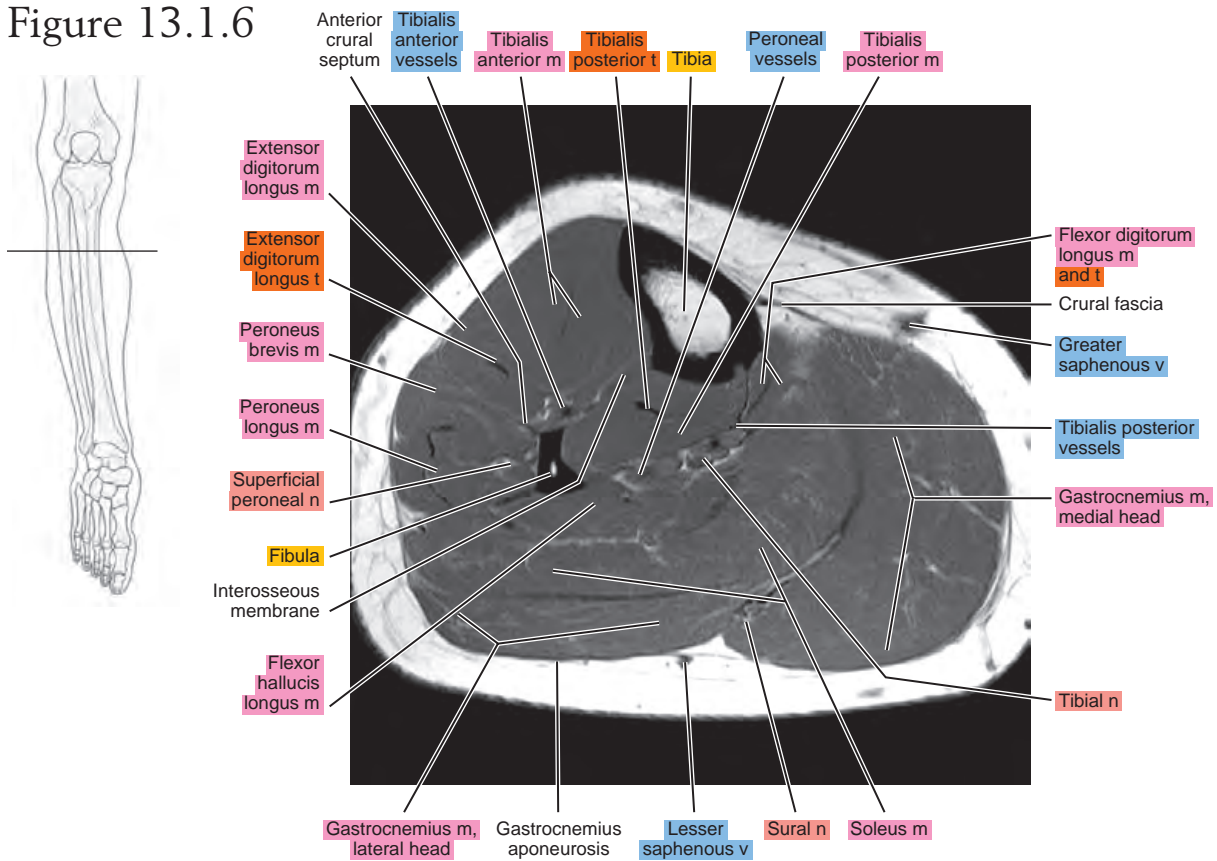


Figure 13.1.7

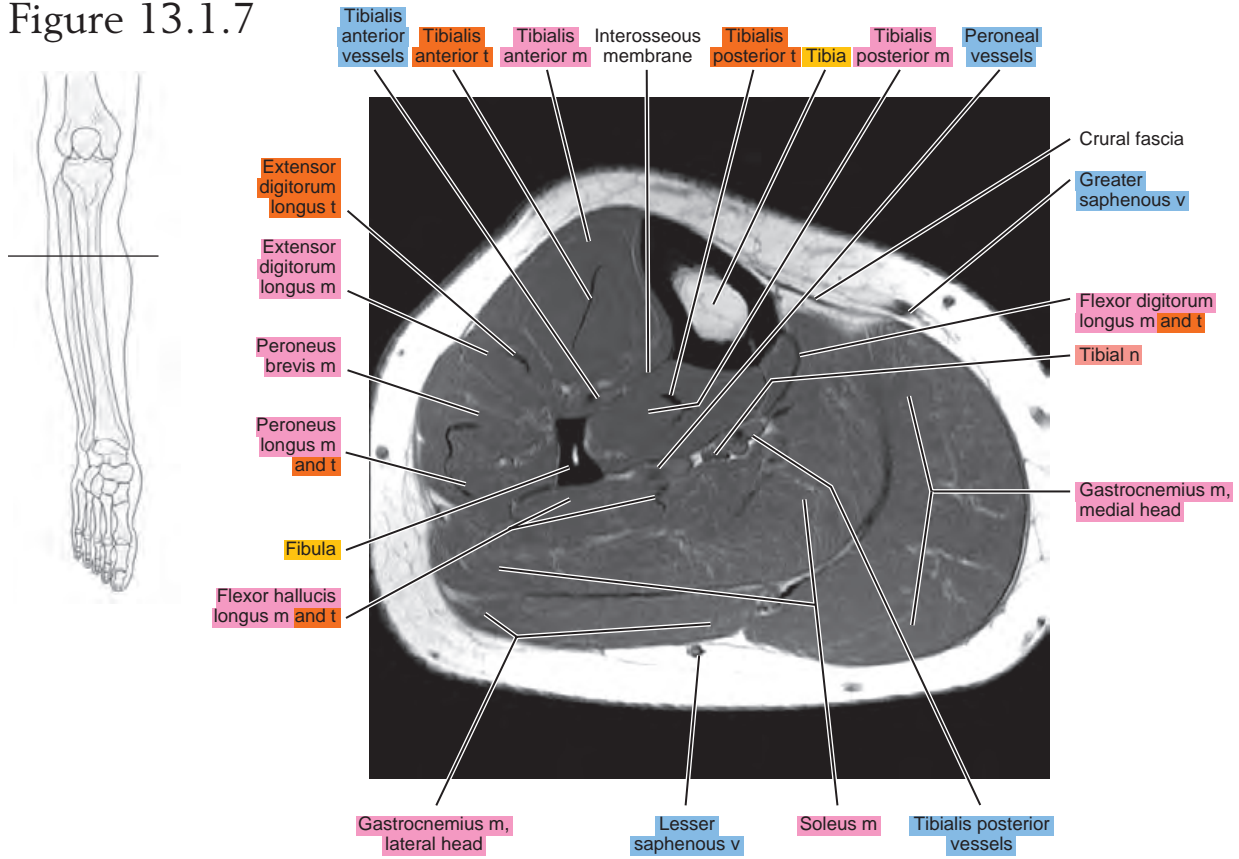


Figure 13.1.8

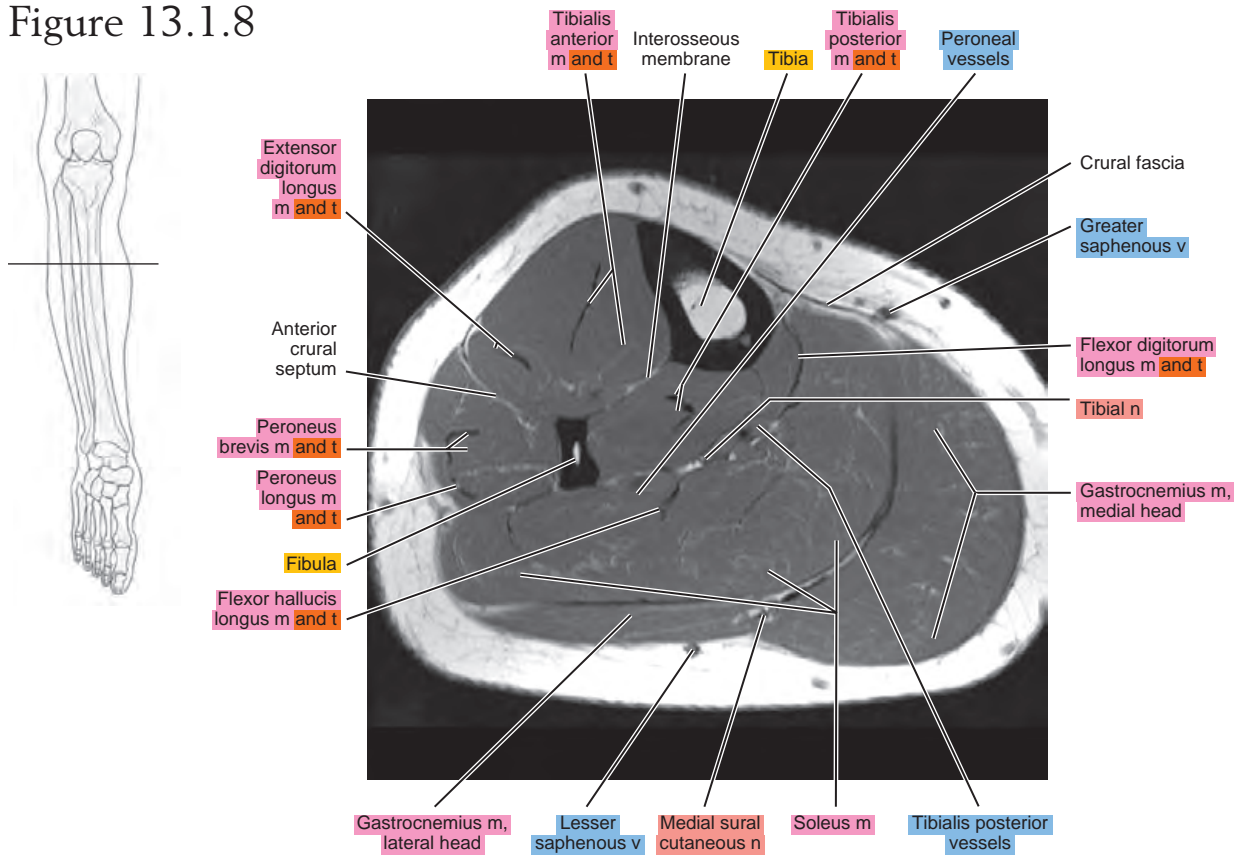


Figure 13.1.9

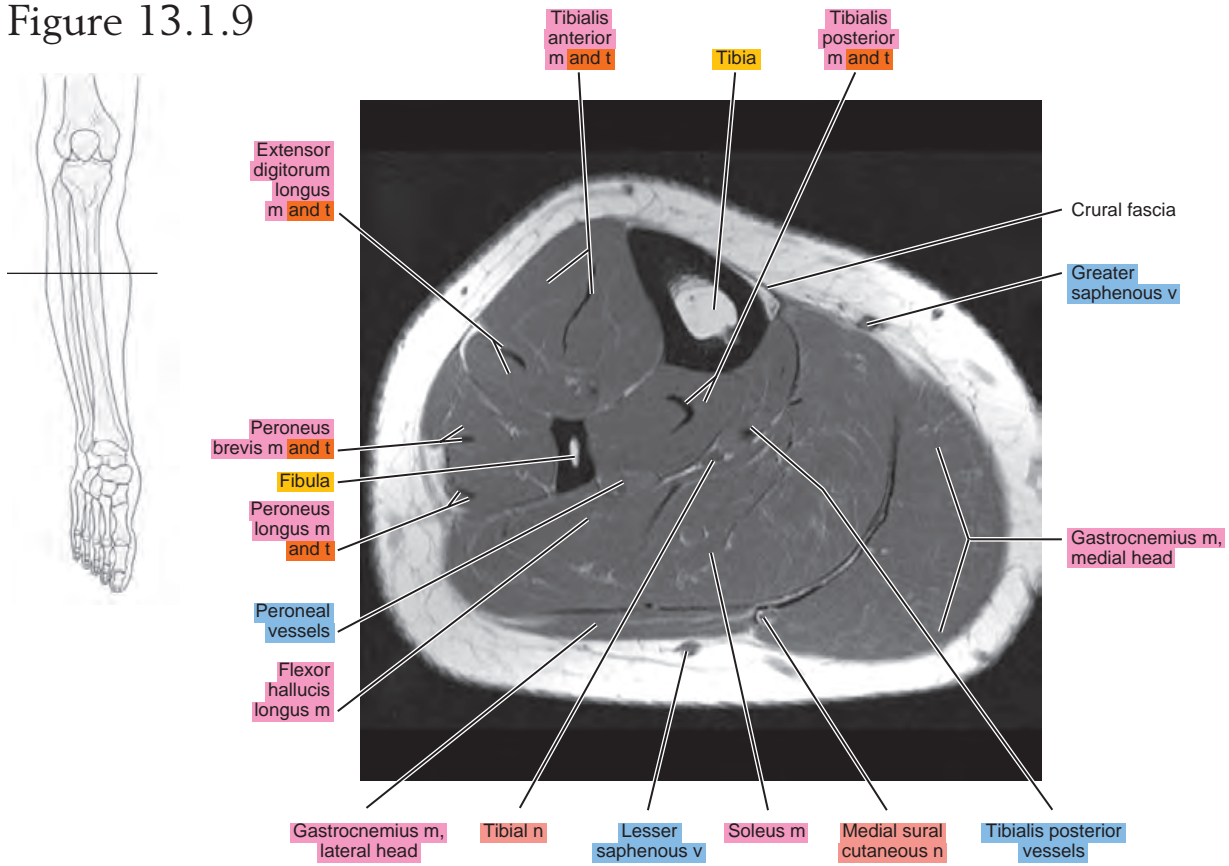


Figure 13.1.10

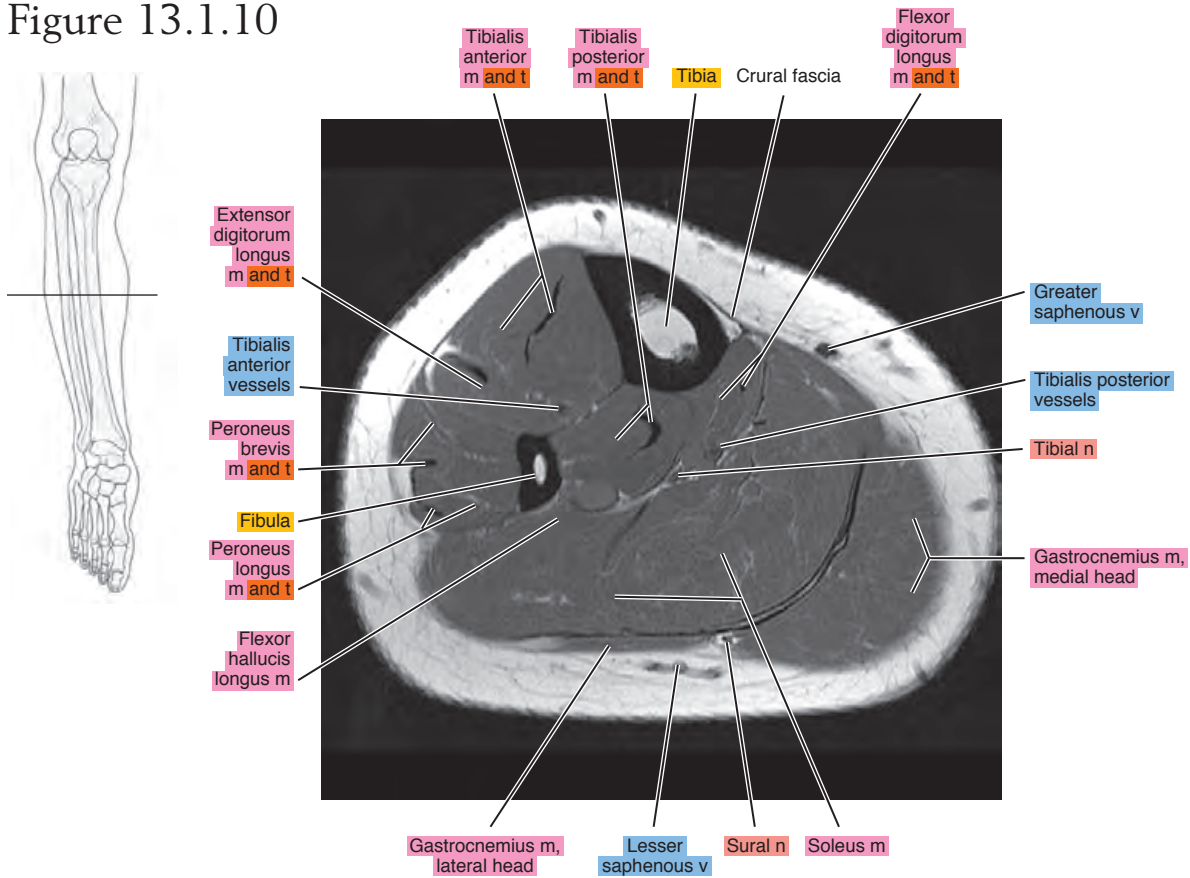


Figure 13.1.11

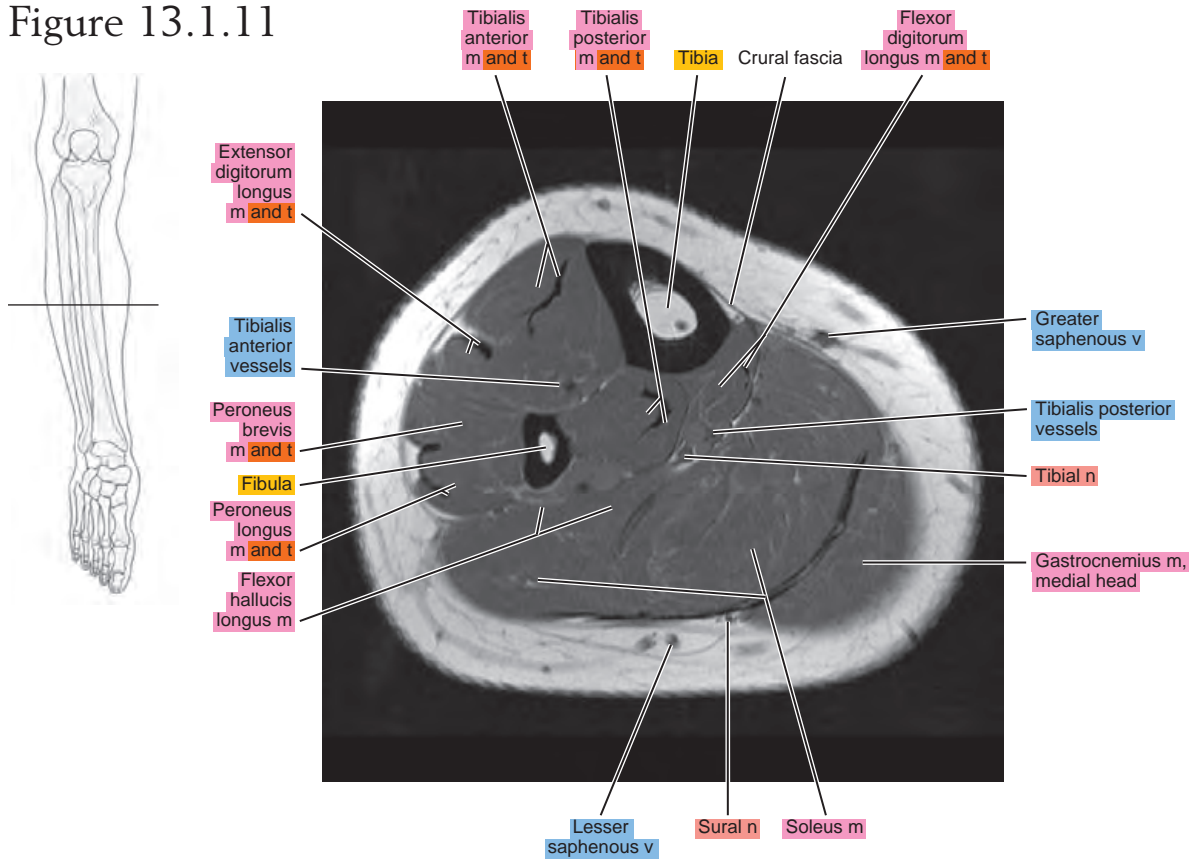


Figure 13.1.12

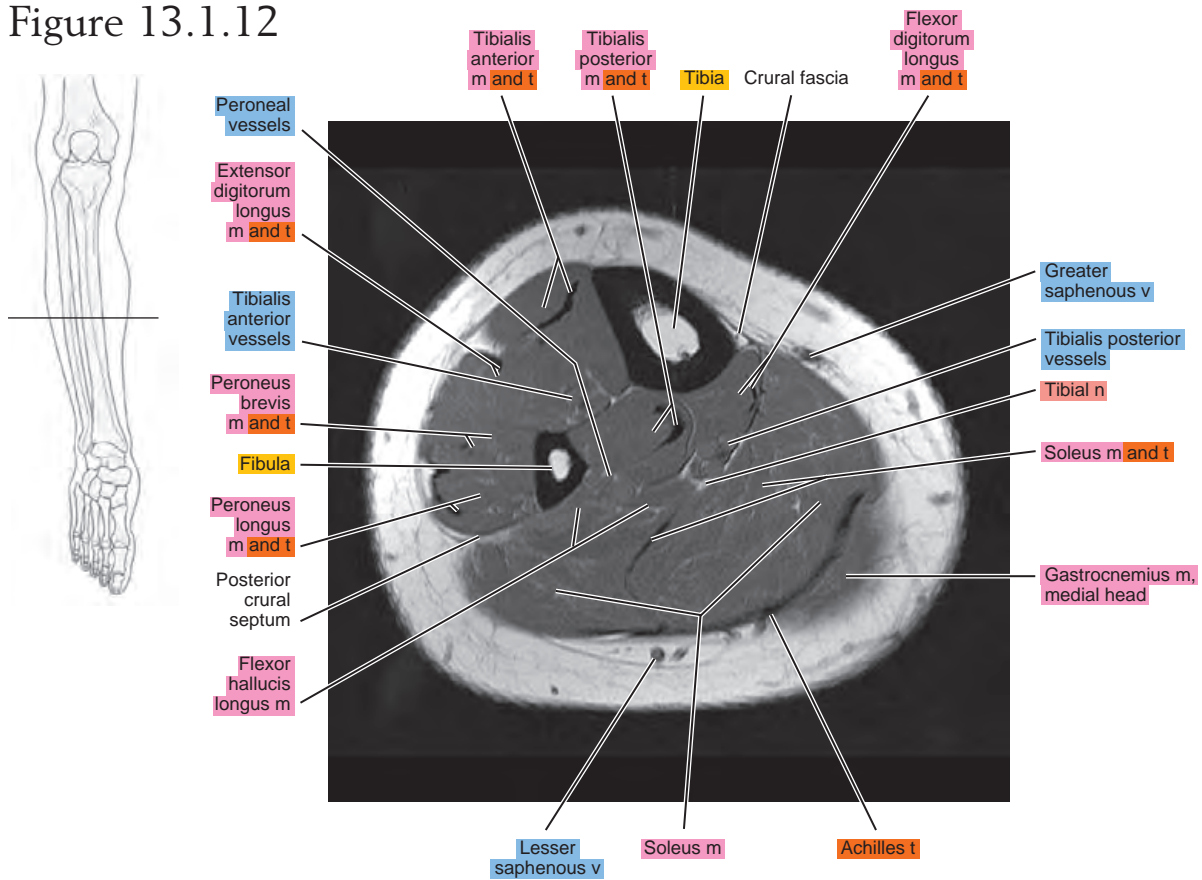


Figure 13.1.13

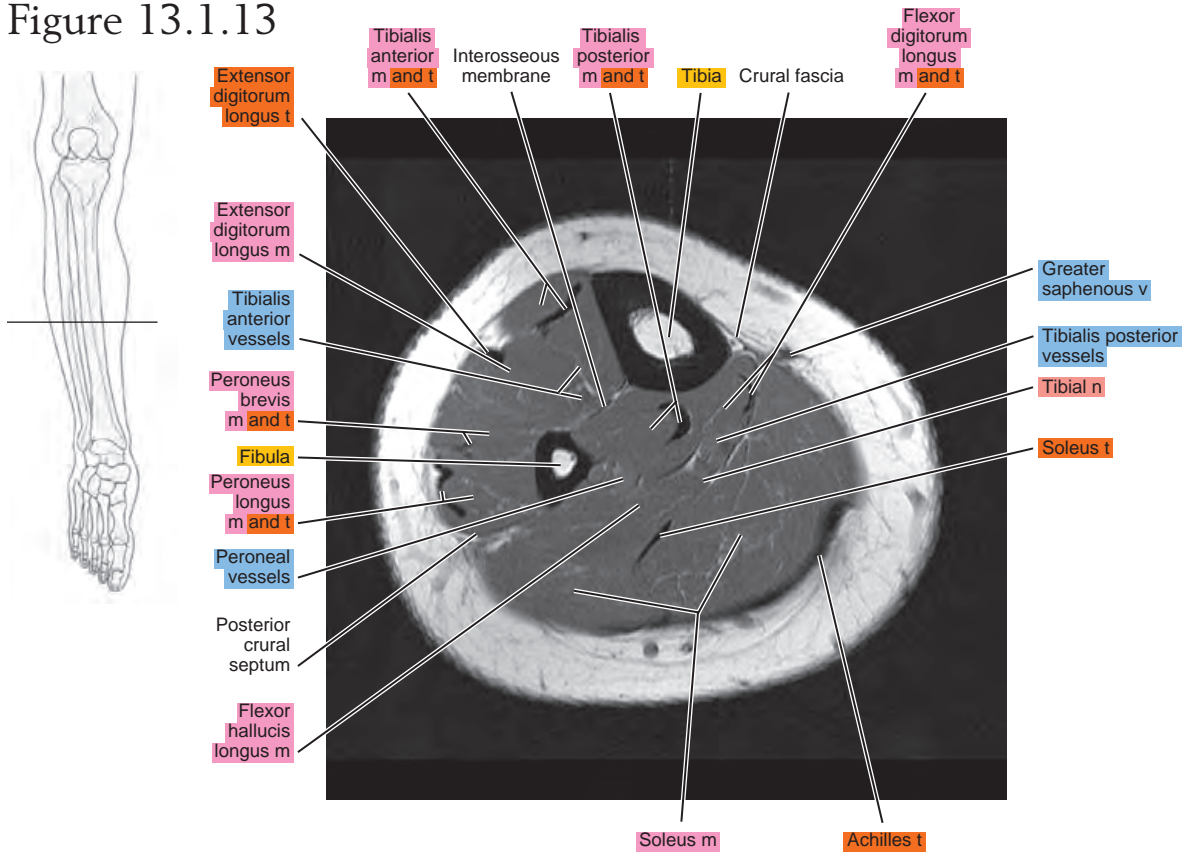


Figure 13.1.14

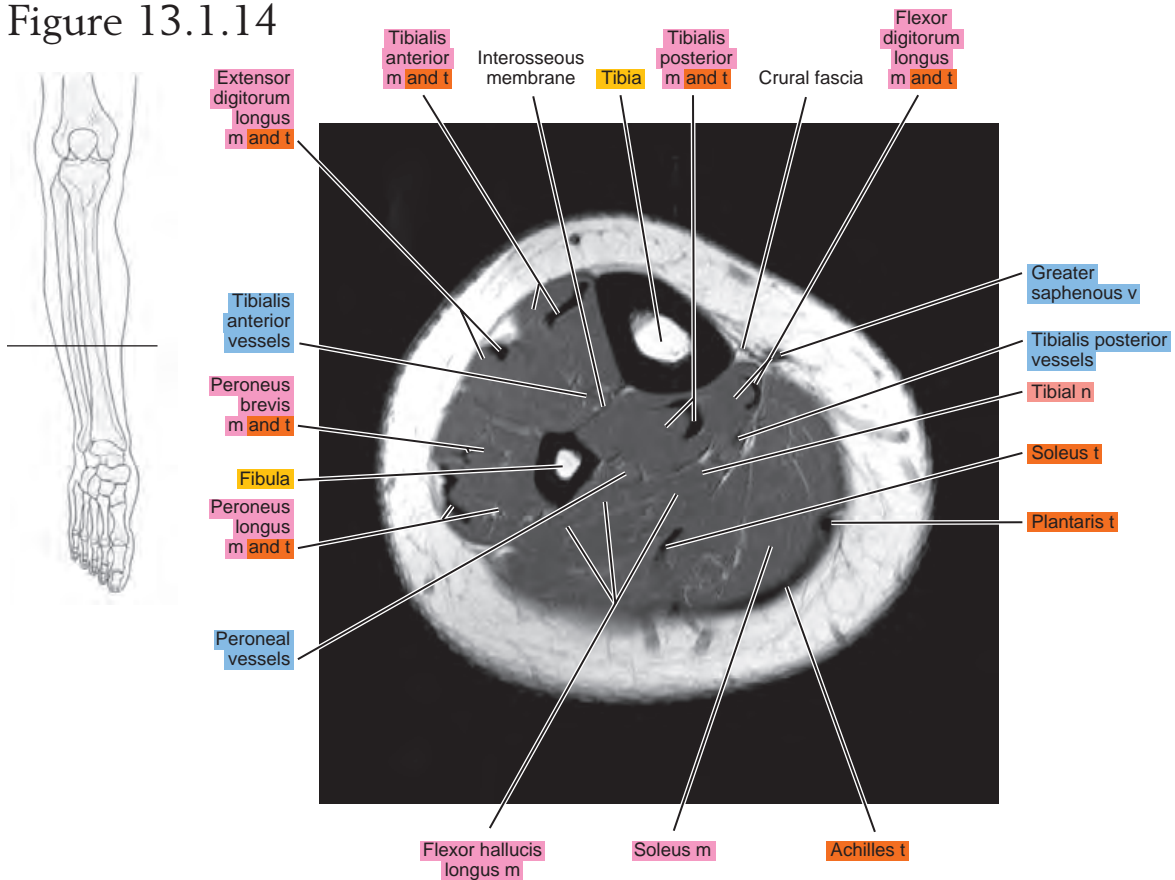


Figure 13.1.15

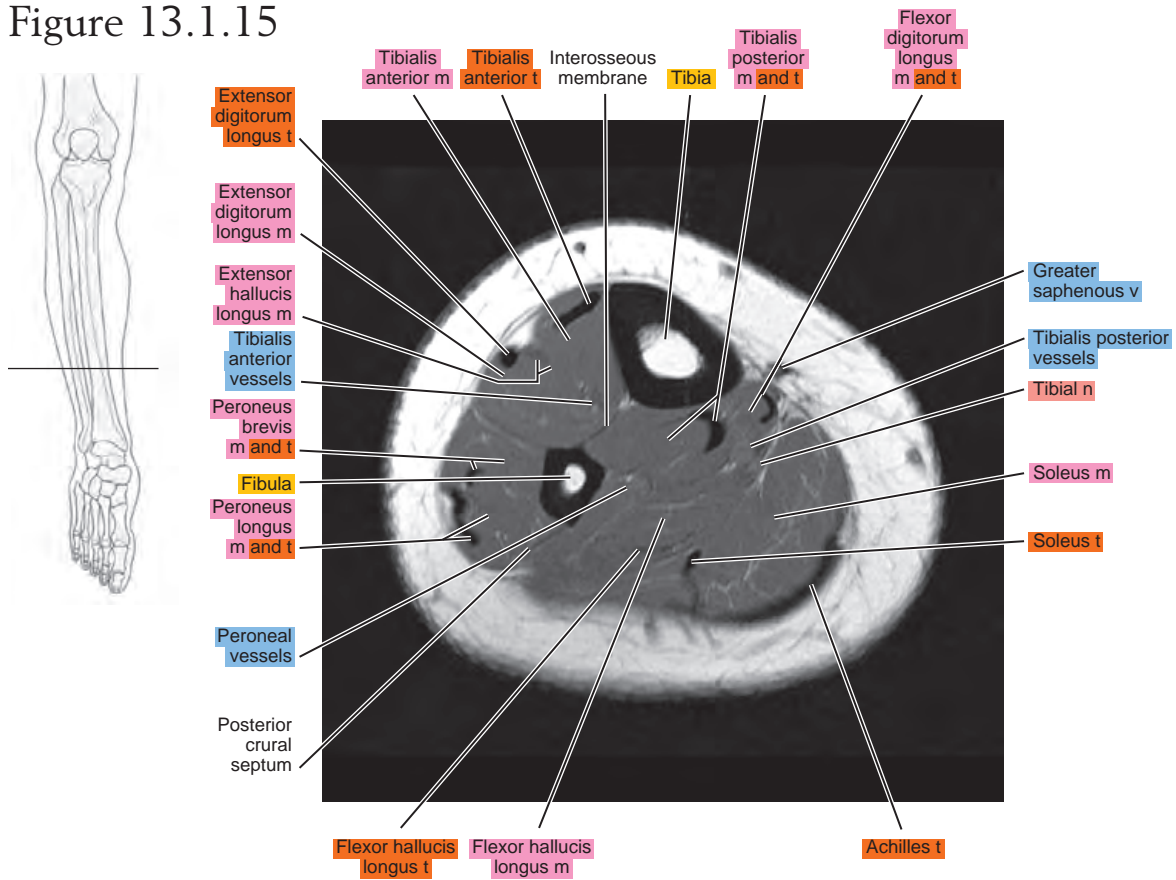


Figure 13.1.16

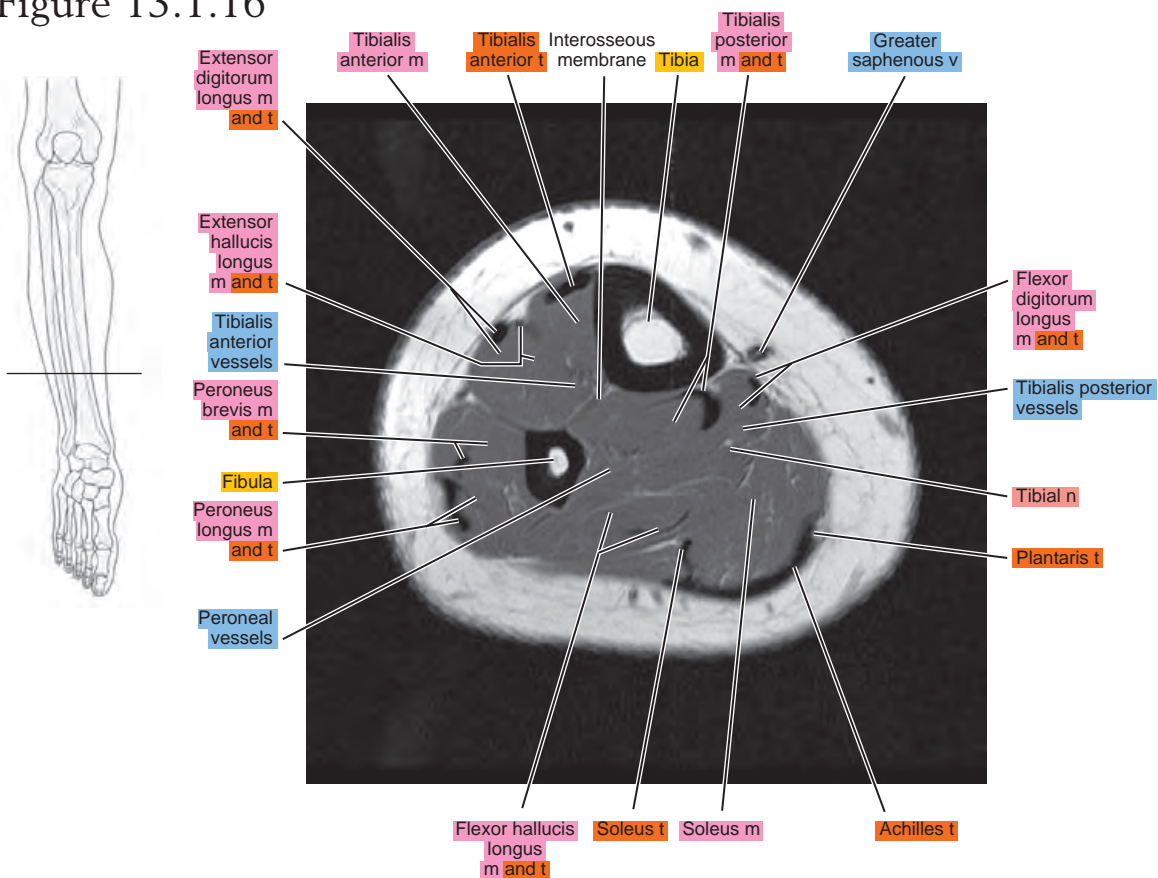


Figure 13.1.17

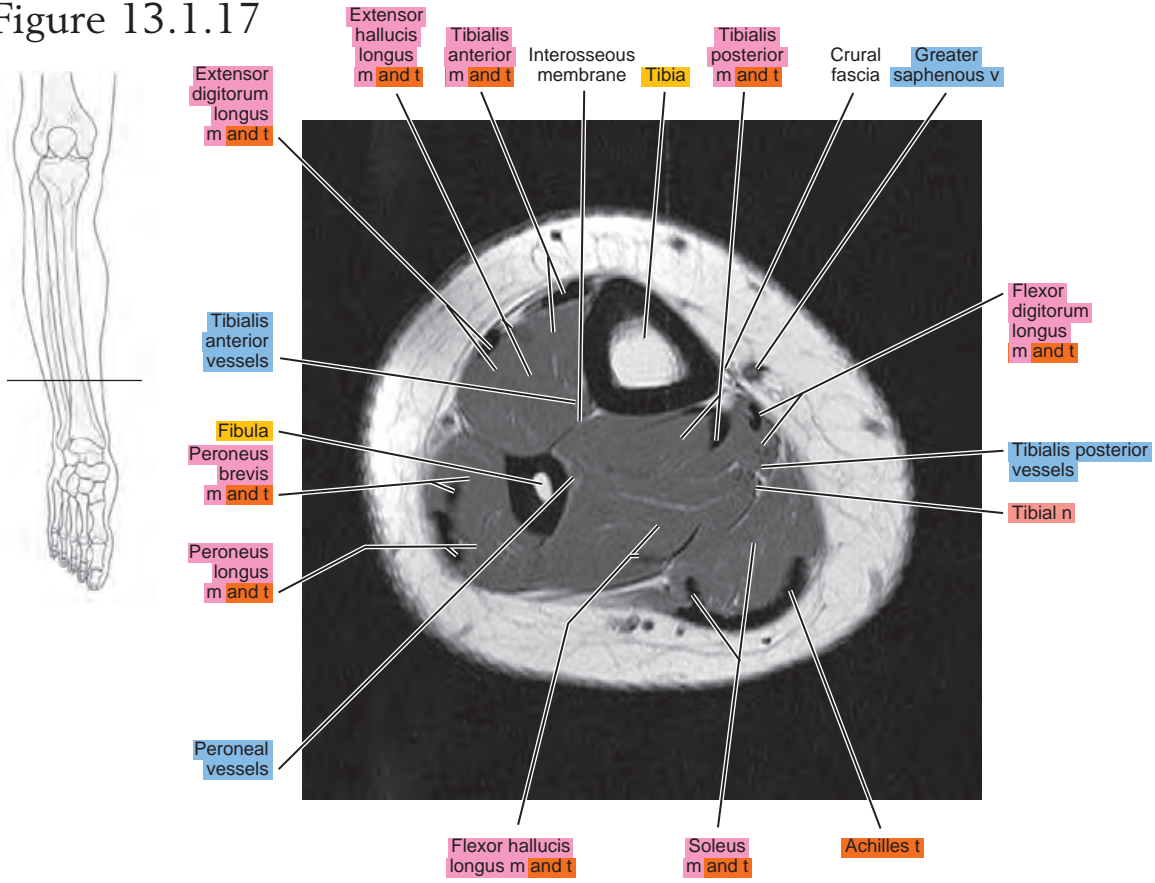


Figure 13.1.18

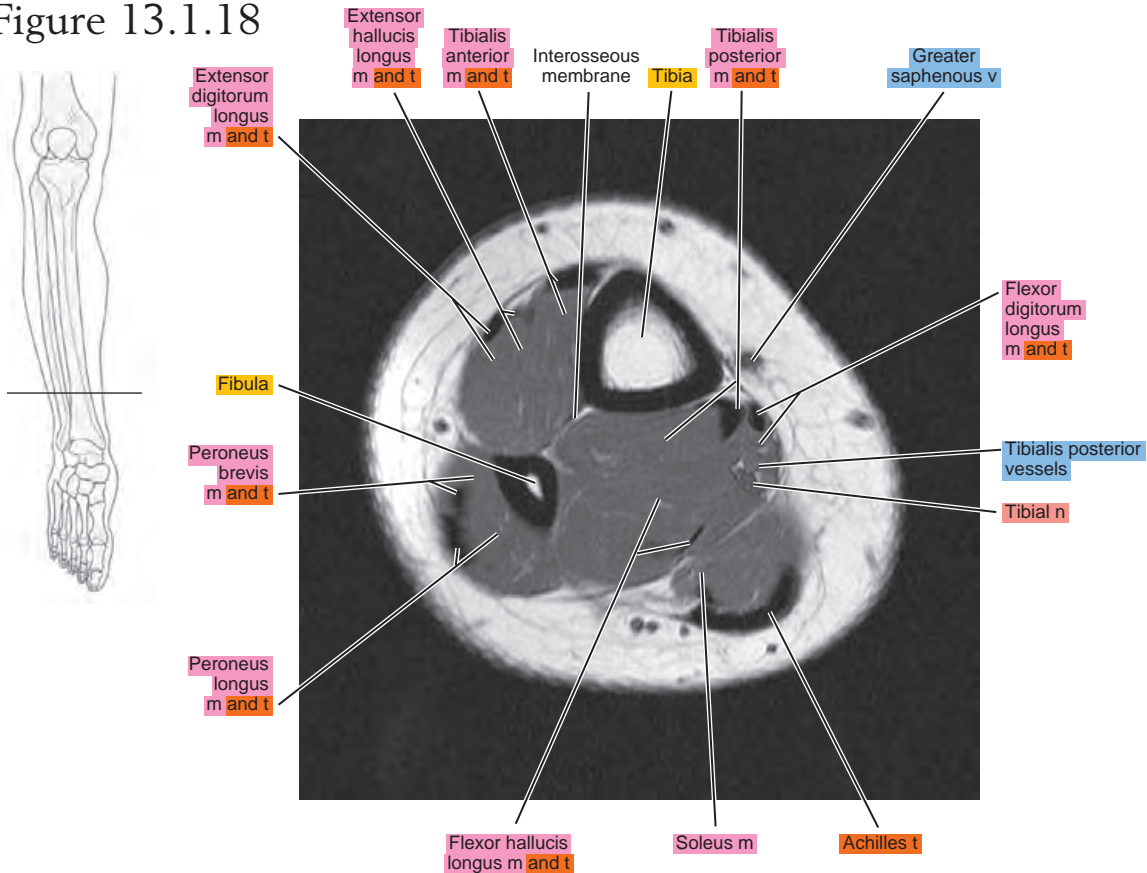


Figure 13.1.19

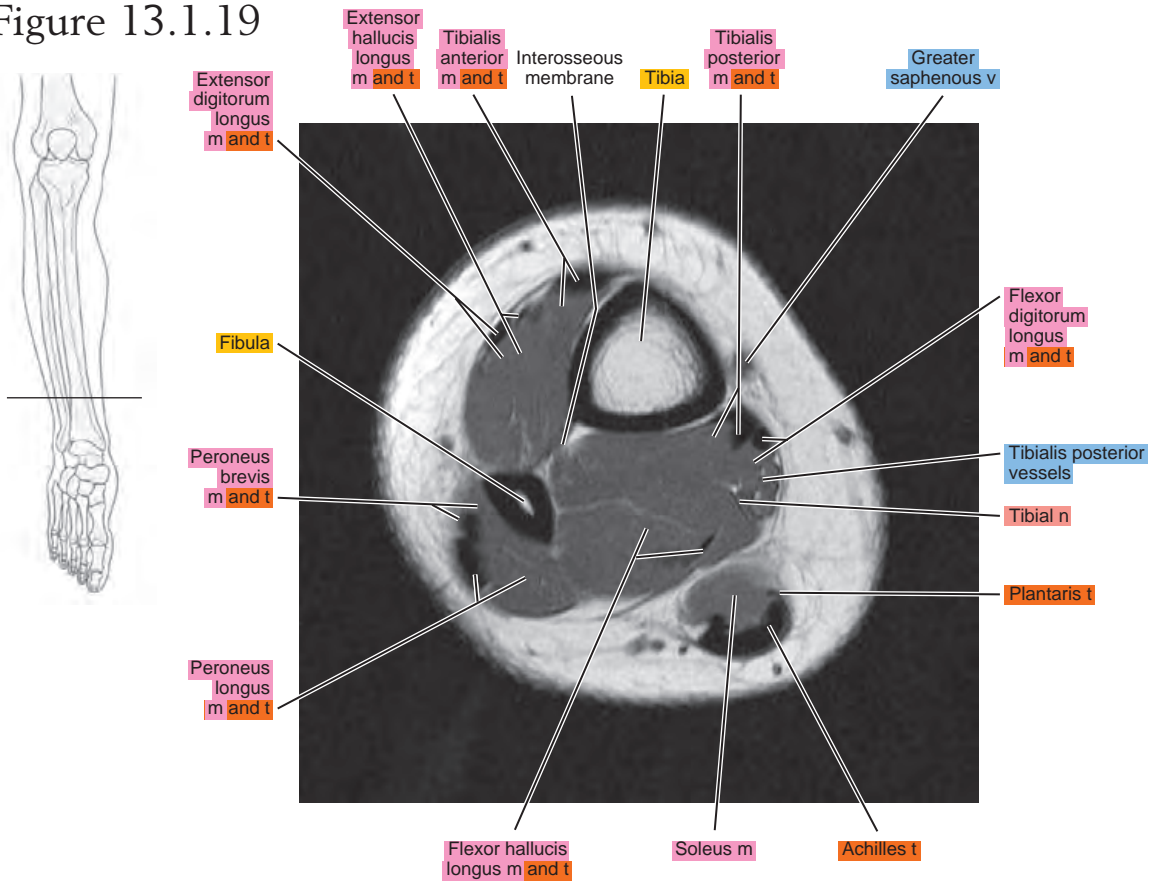
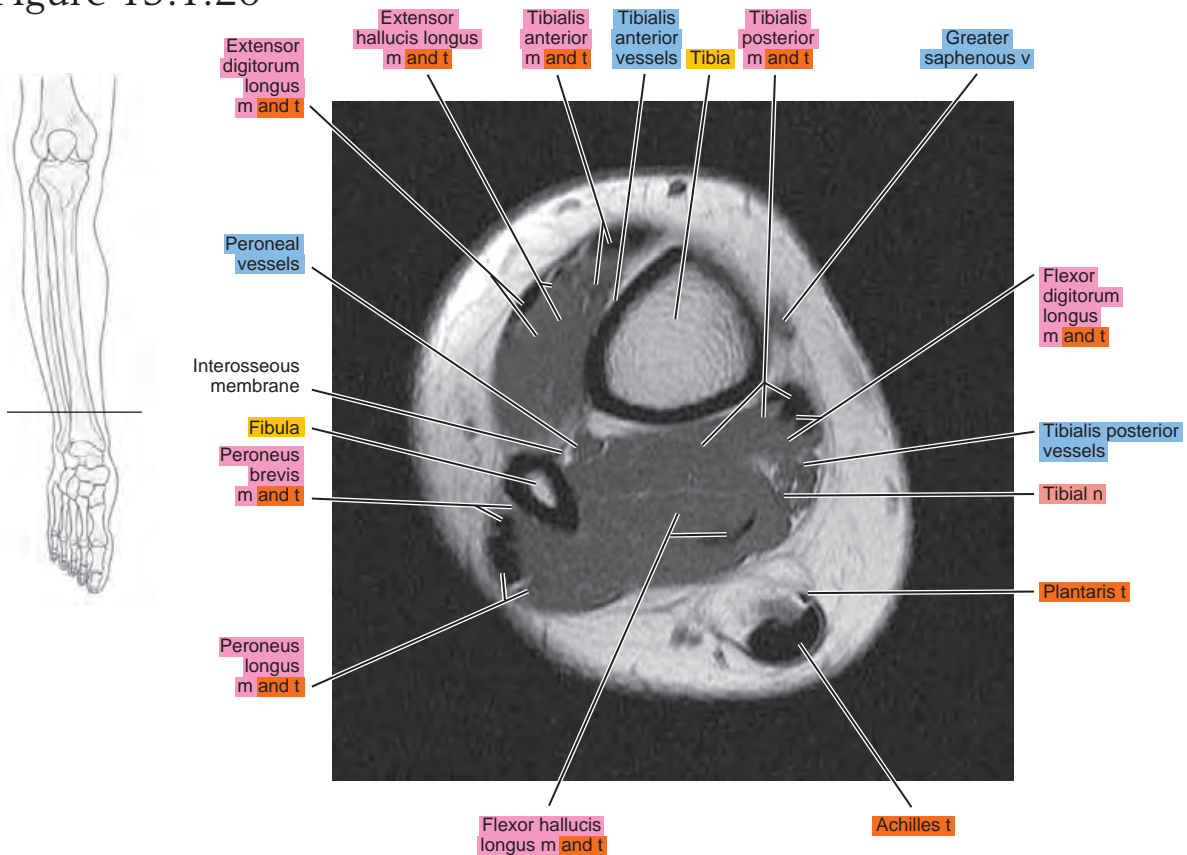


Figure 13.1.20



SAGITTAL

Figure 13.2.1

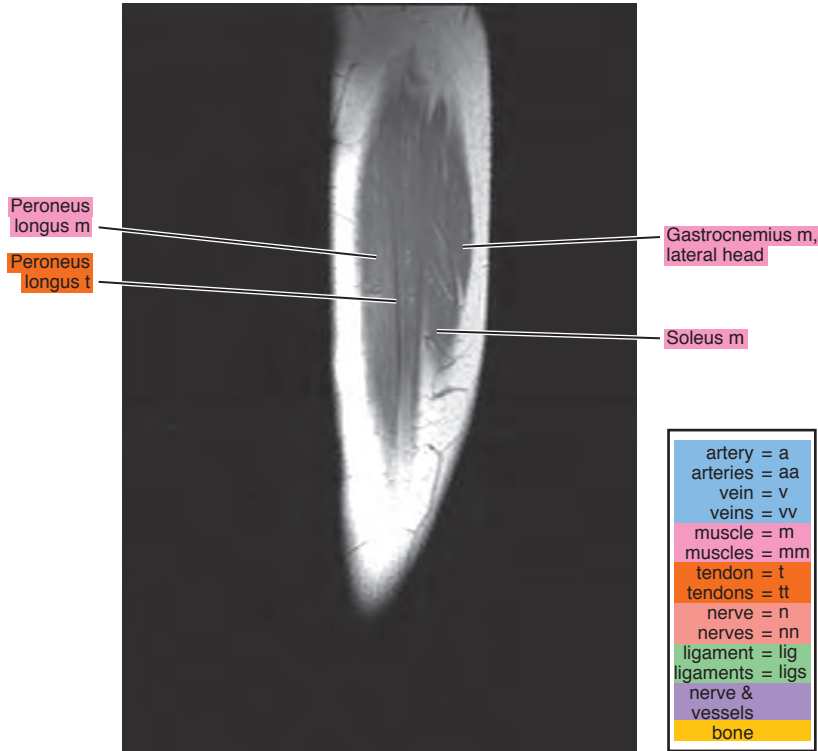


Figure 13.2.2

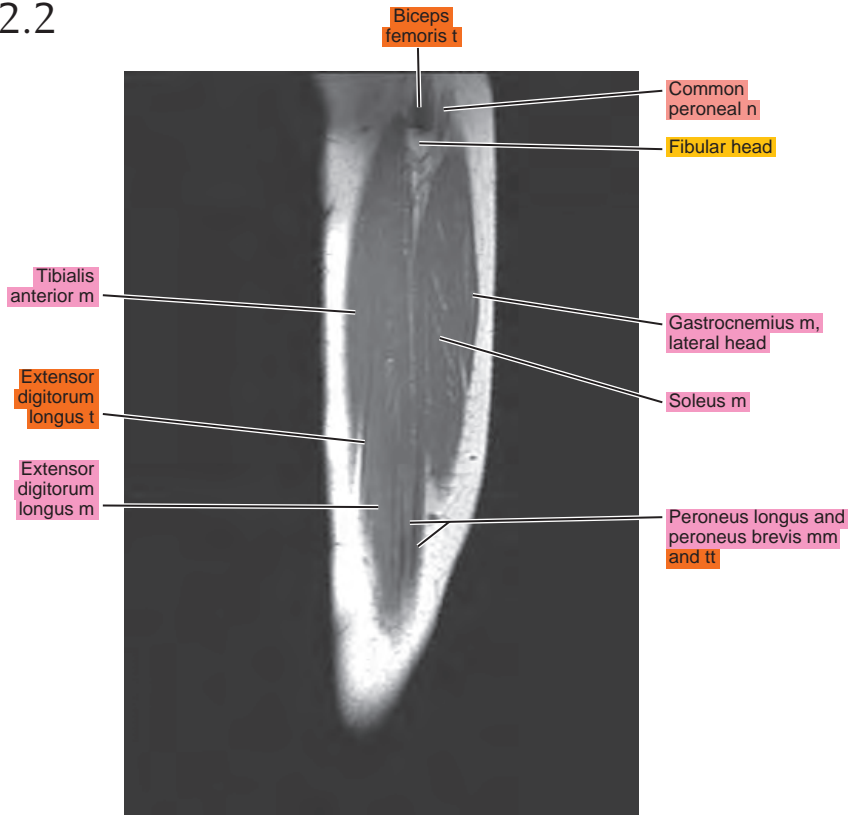


Figure 13.2.3

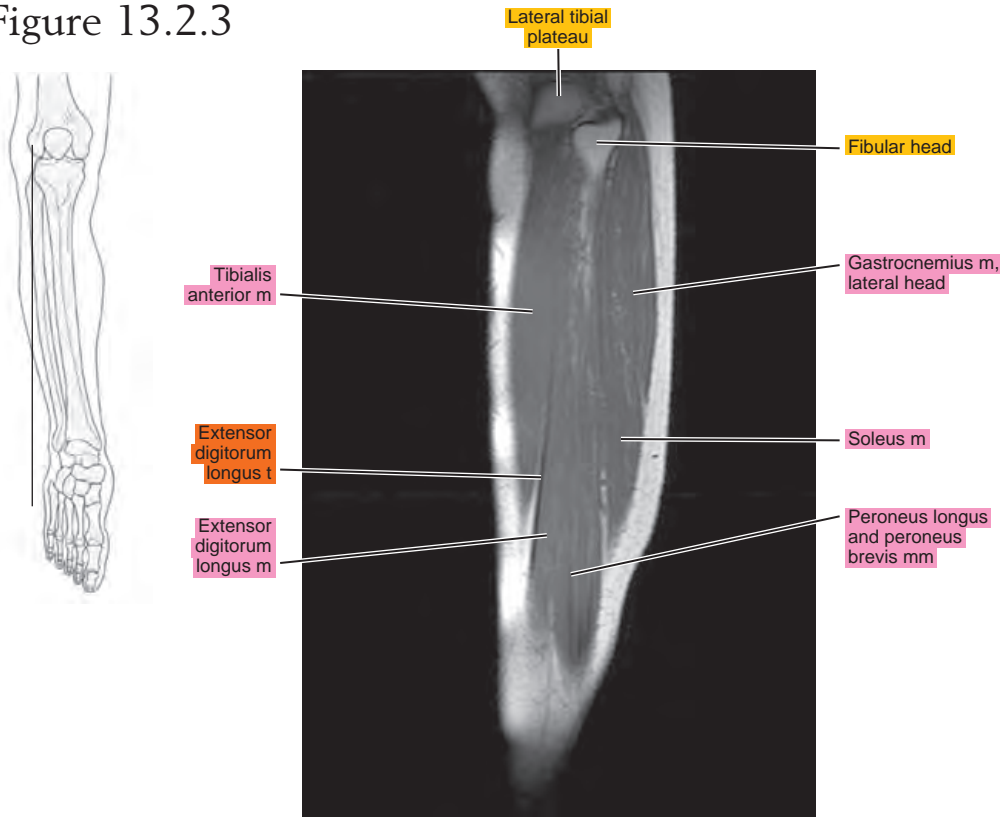


Figure 13.2.4

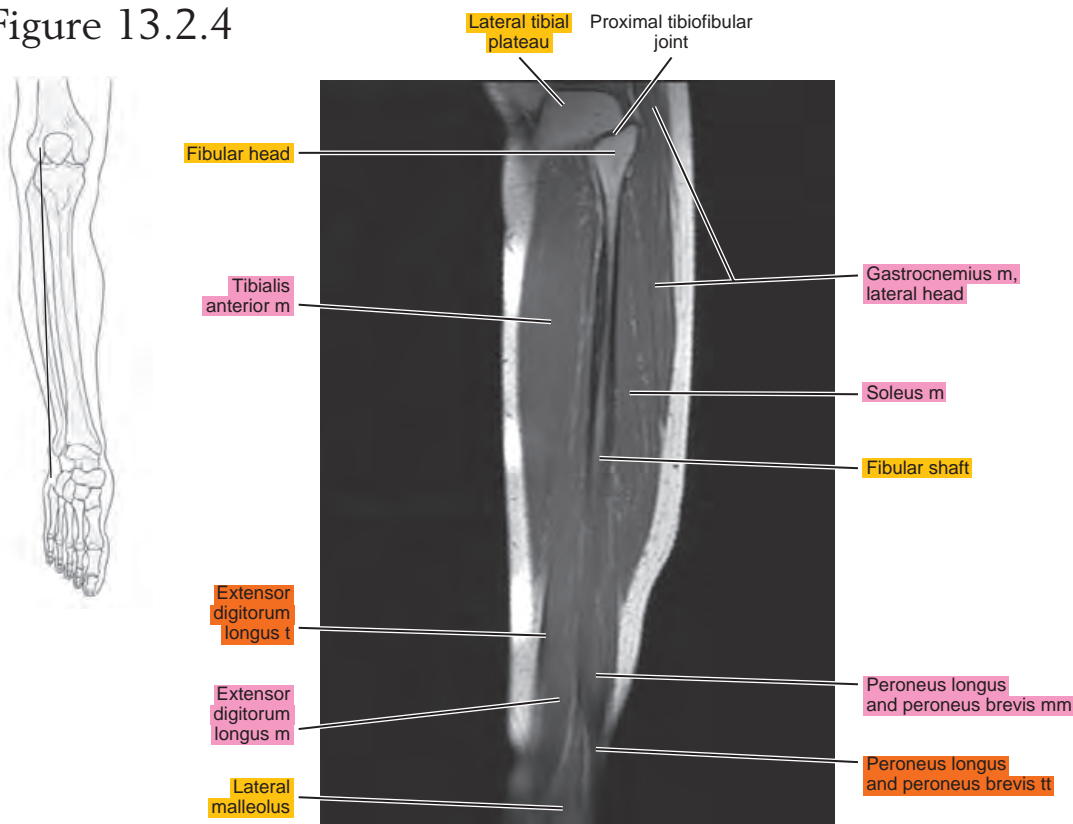


Figure 13.2.5

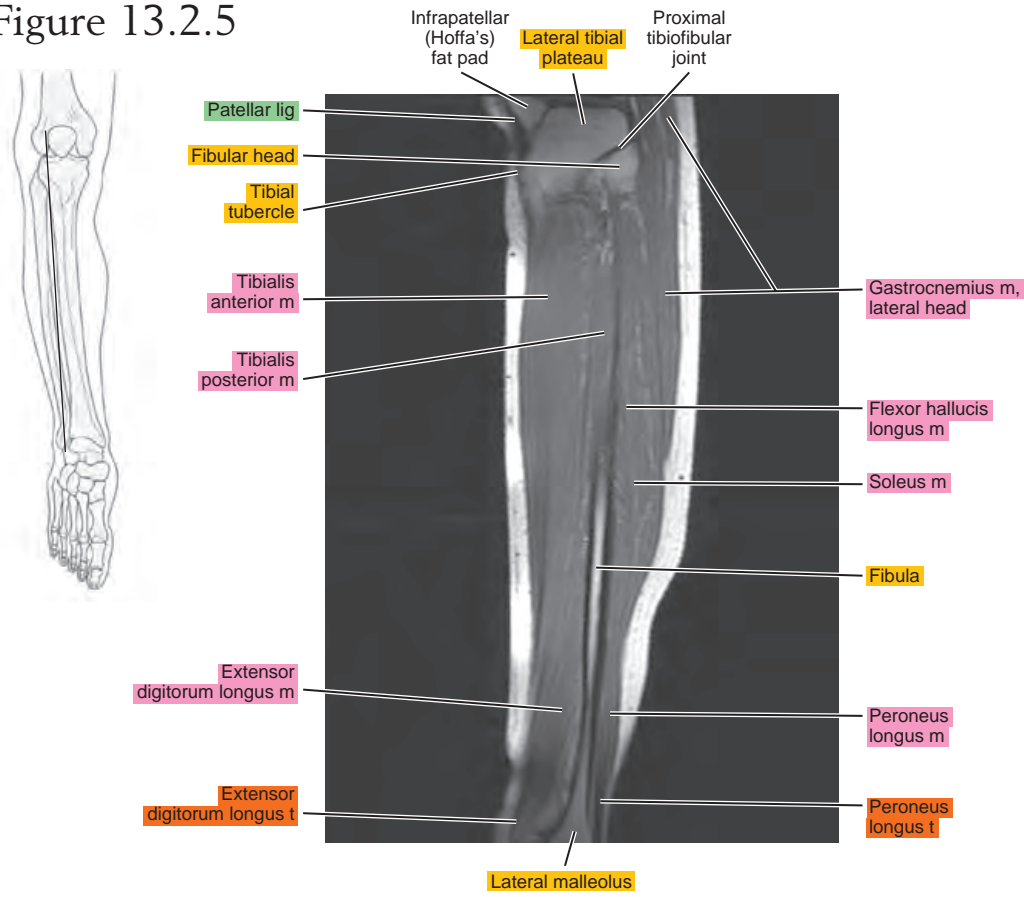


Figure 13.2.6

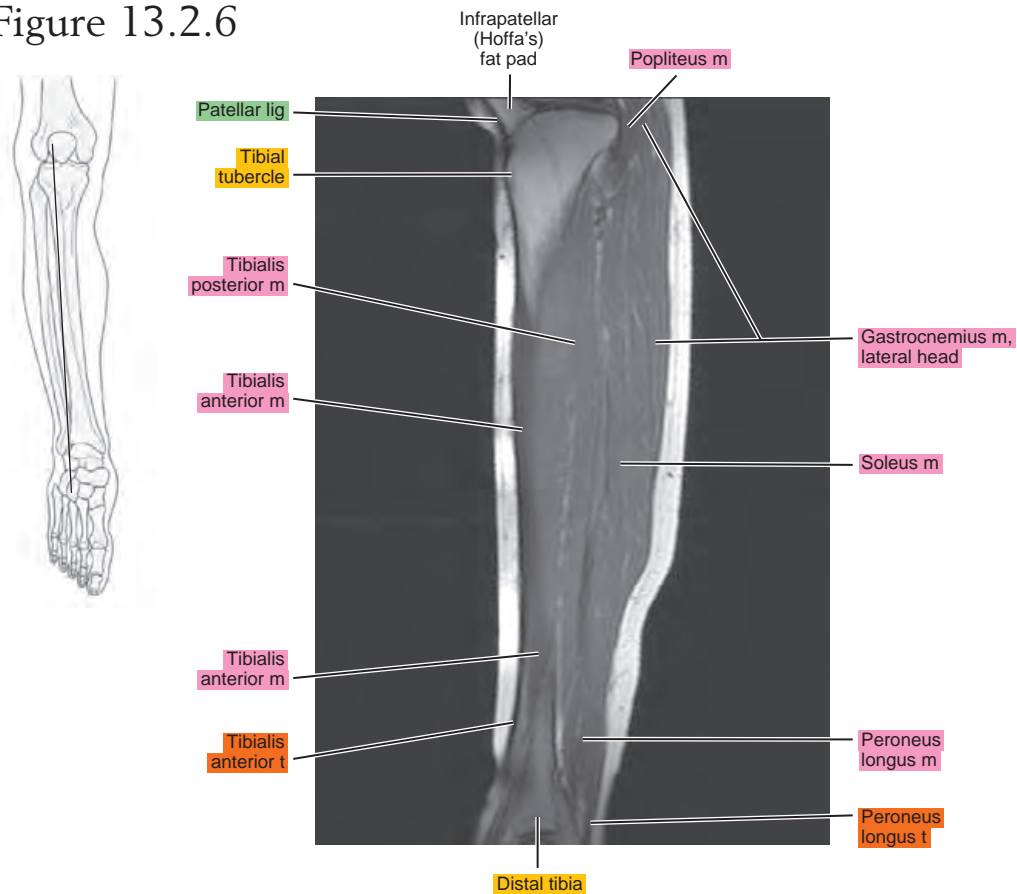


Figure 13.2.7

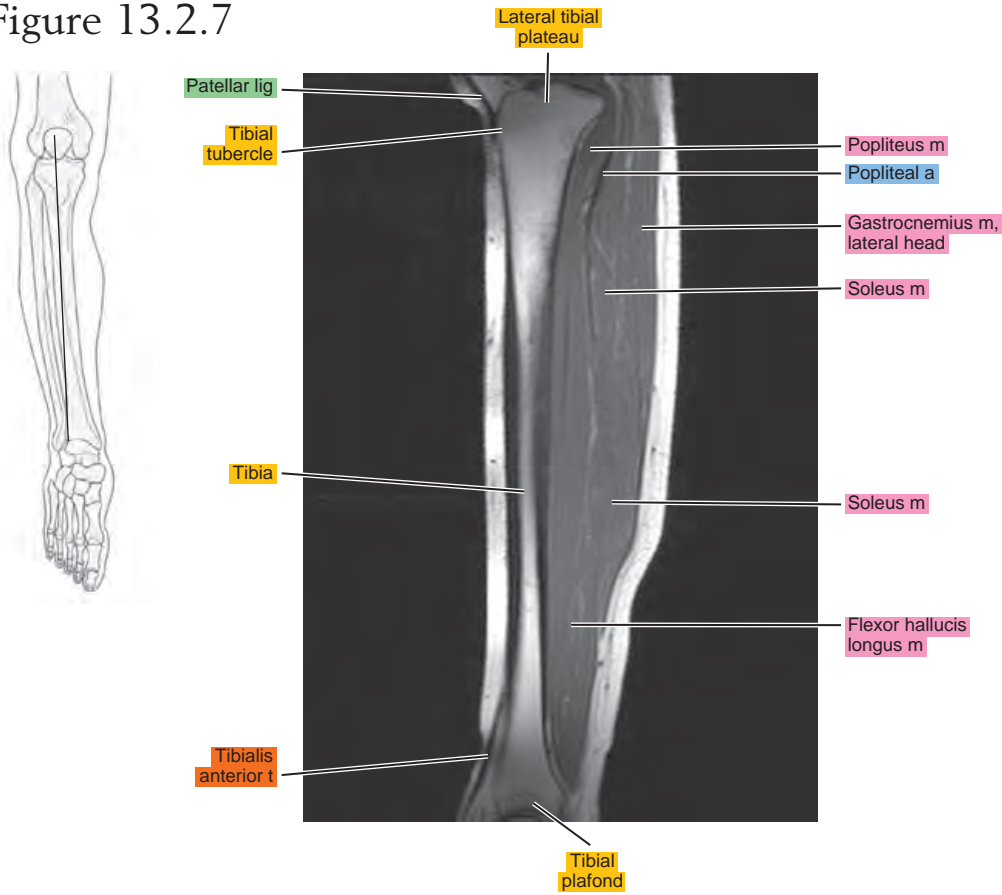


Figure 13.2.8

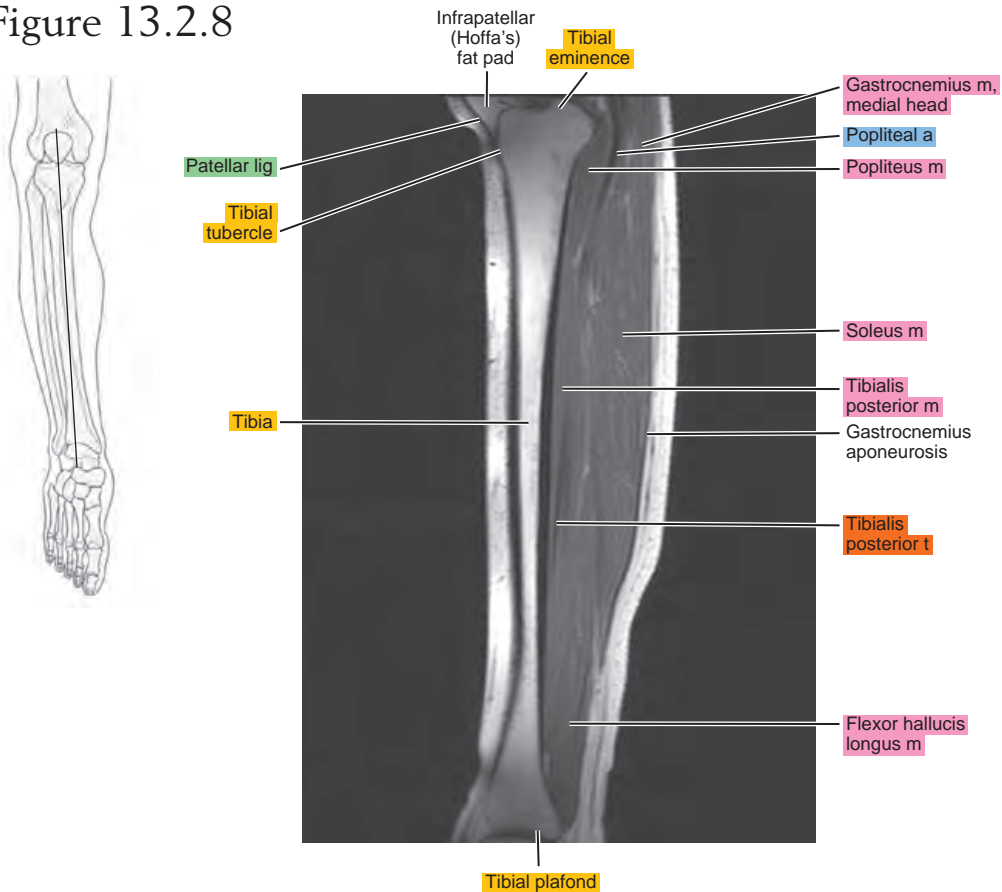


Figure 13.2.9

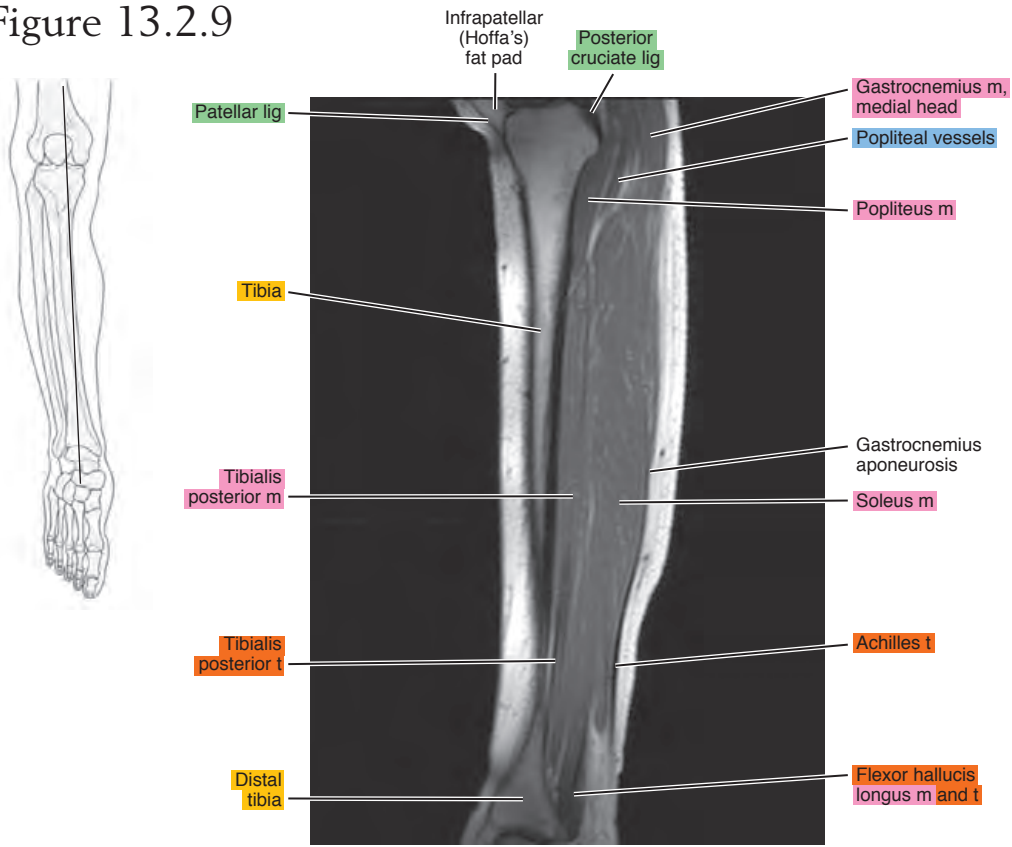


Figure 13.2.10

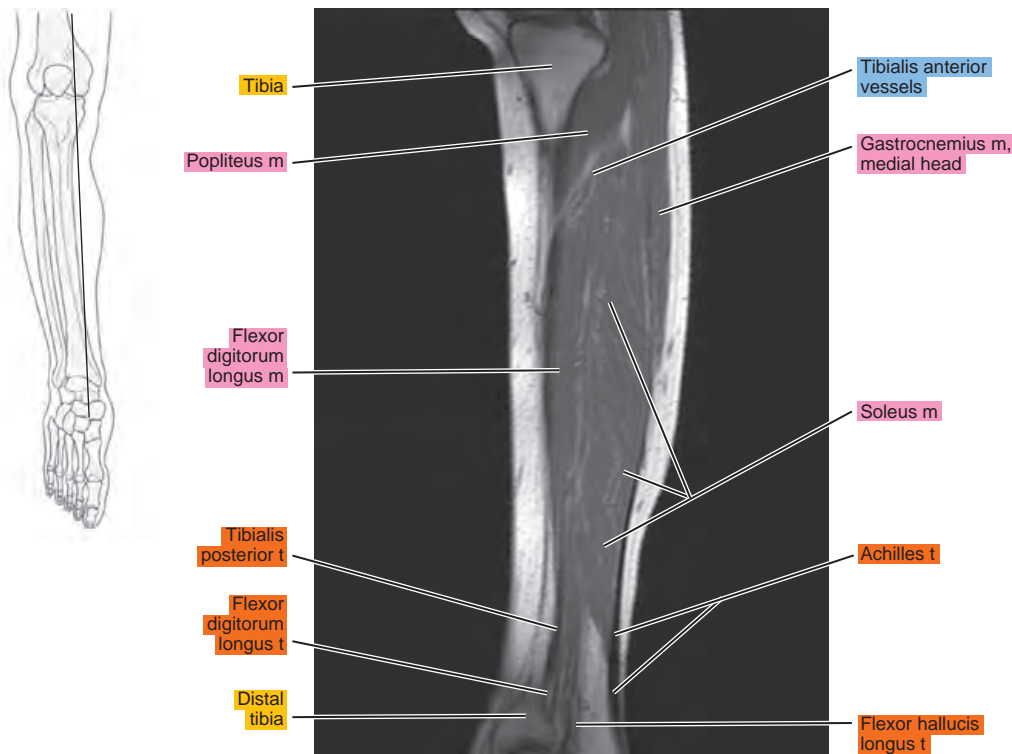


Figure 13.2.11

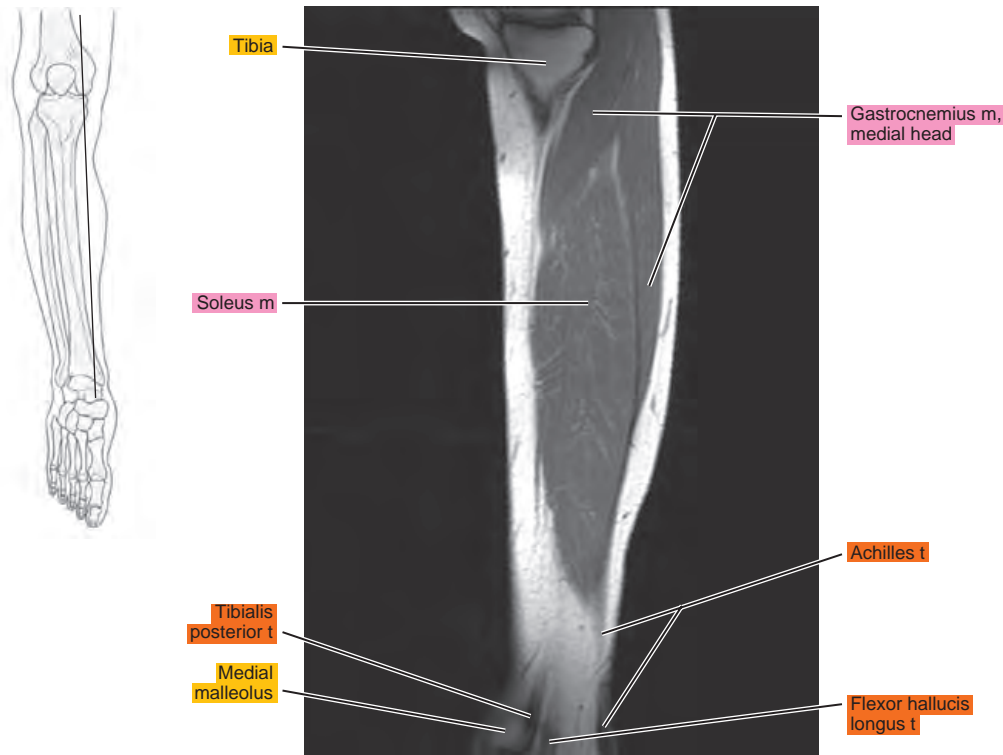


Figure 13.2.12

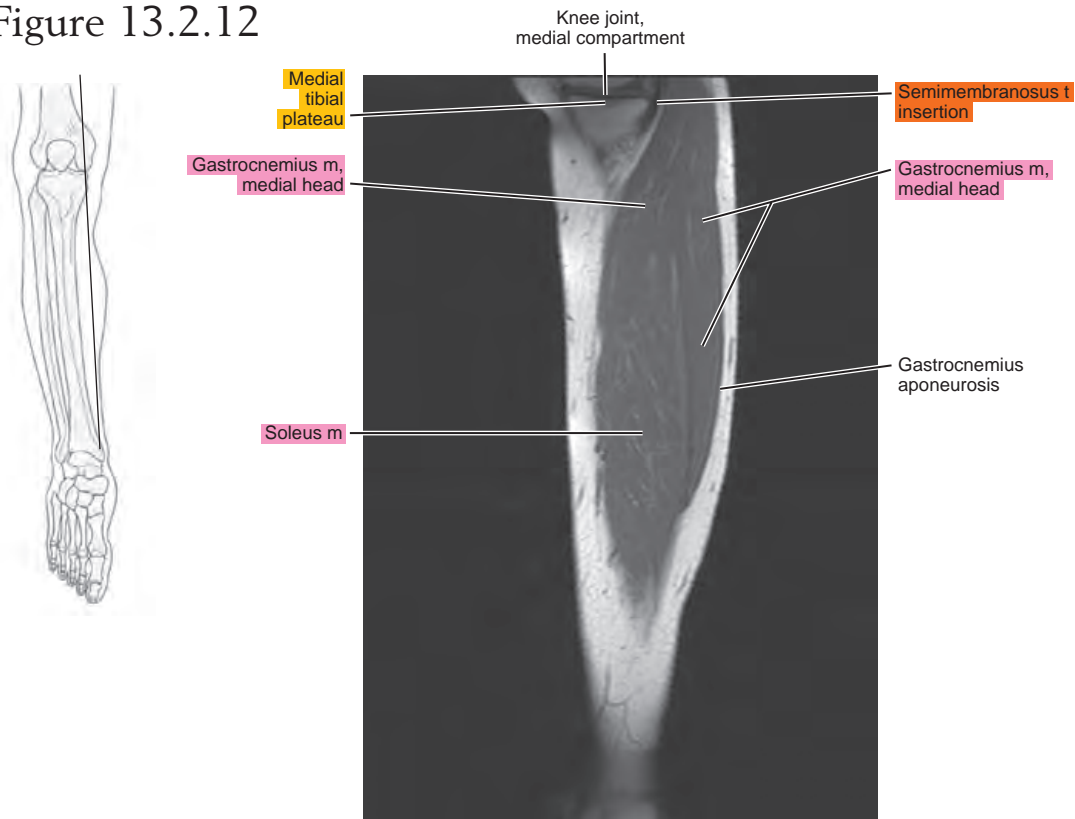


Figure 13.2.13

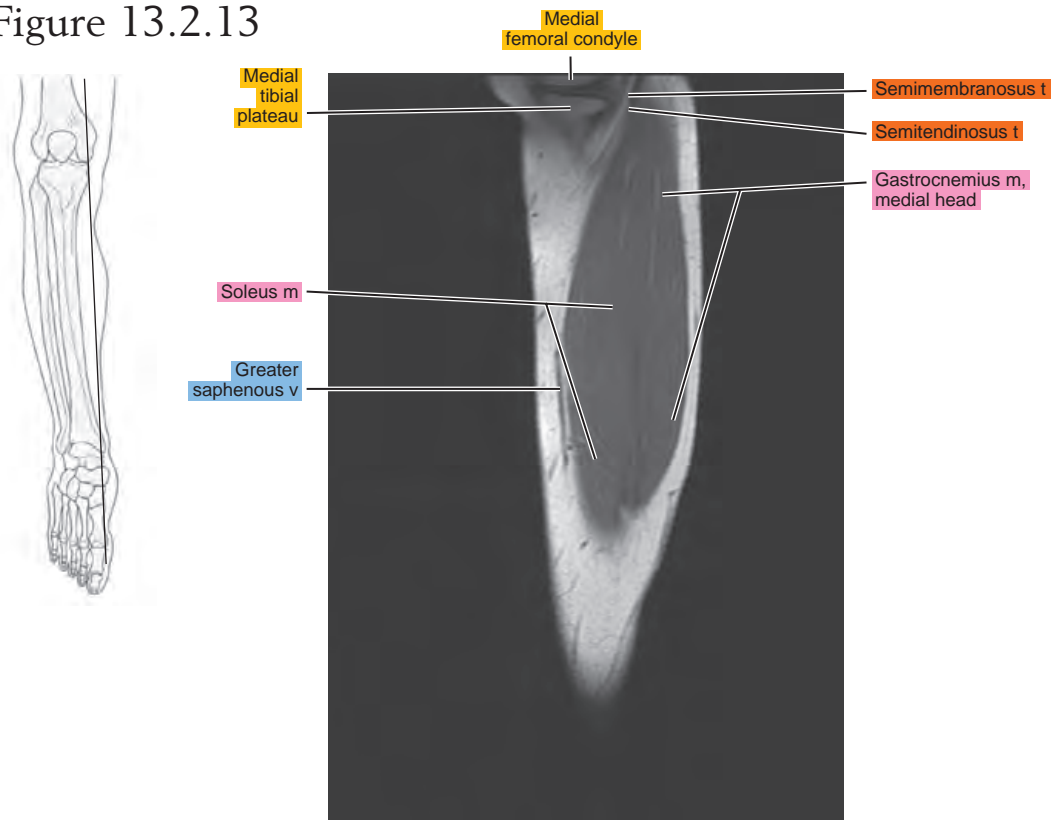


Figure 13.2.14

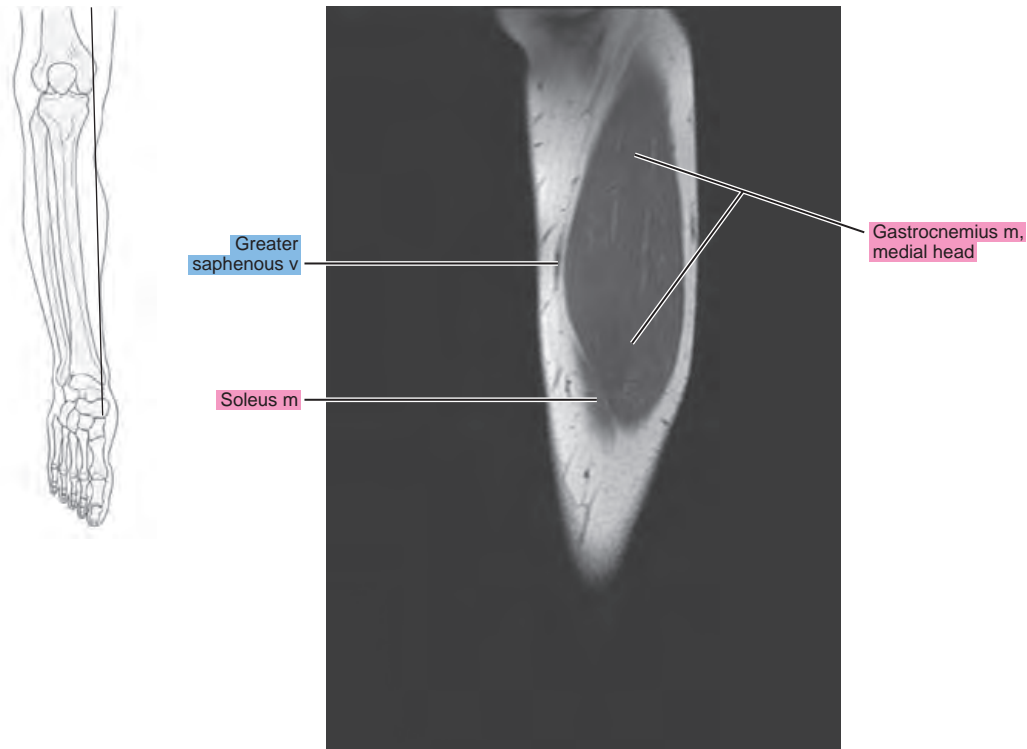
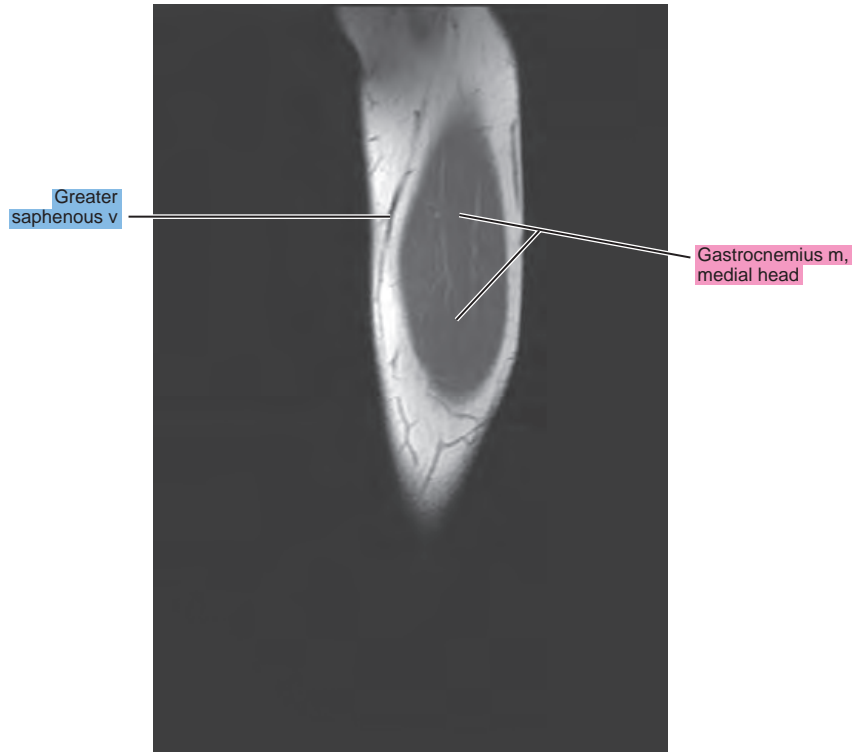


Figure 13.2.15



CORONAL

Figure 13.3.1

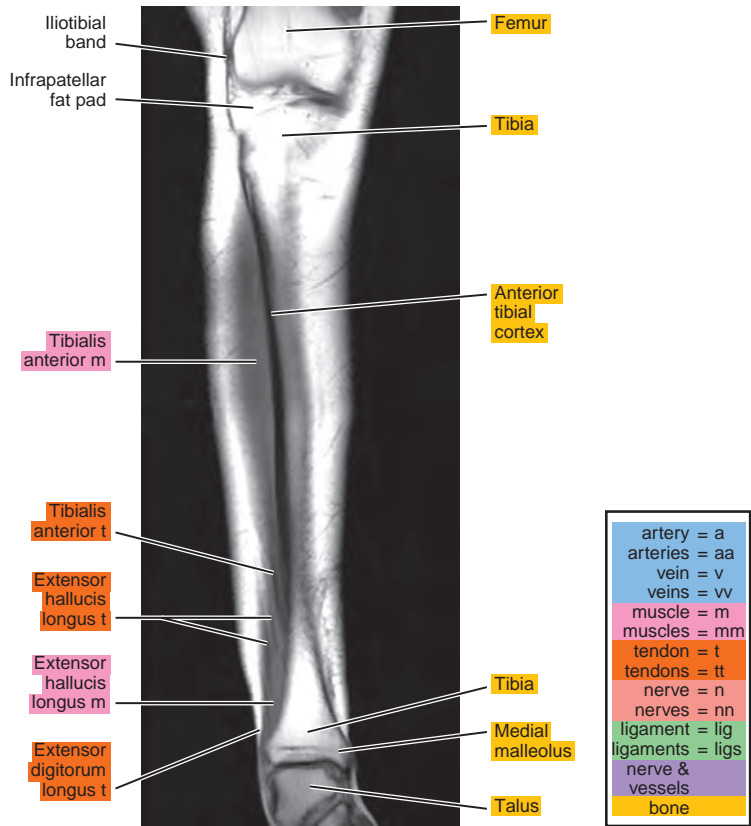
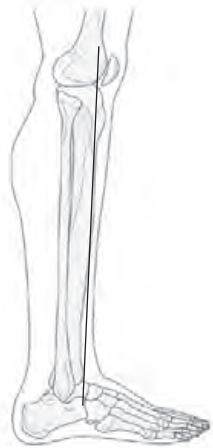

Figure 13.3.2

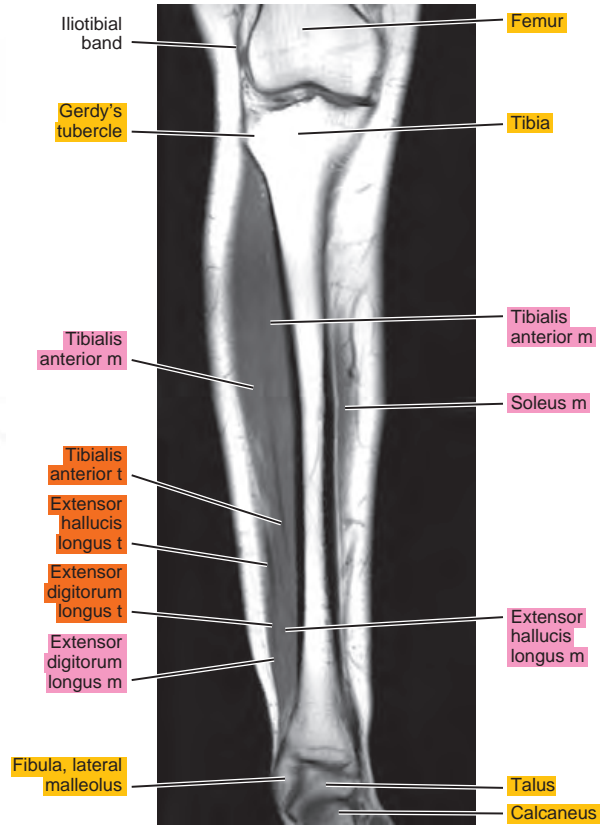



Figure 13.3.3

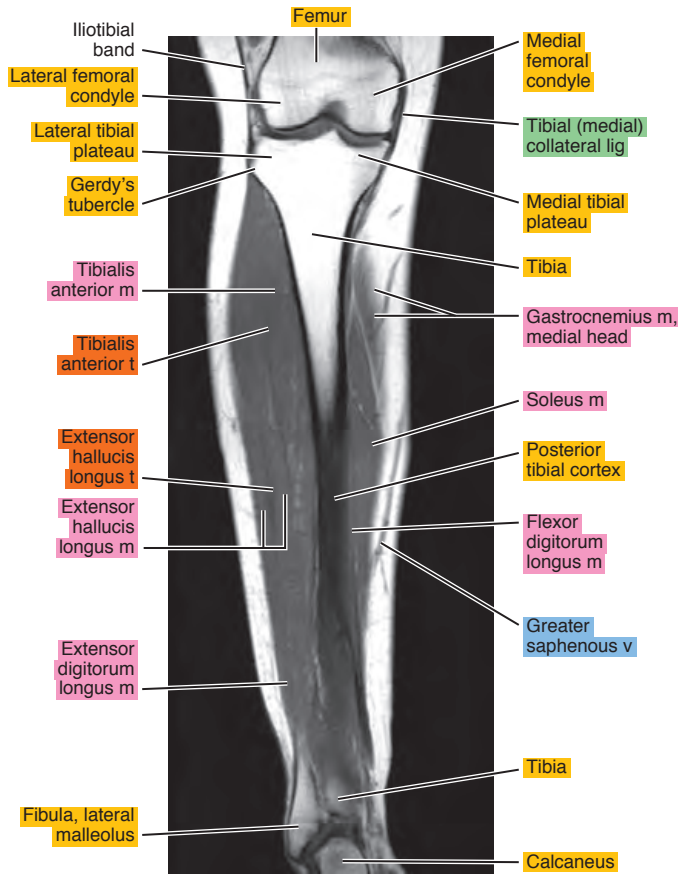


Figure 13.3.4

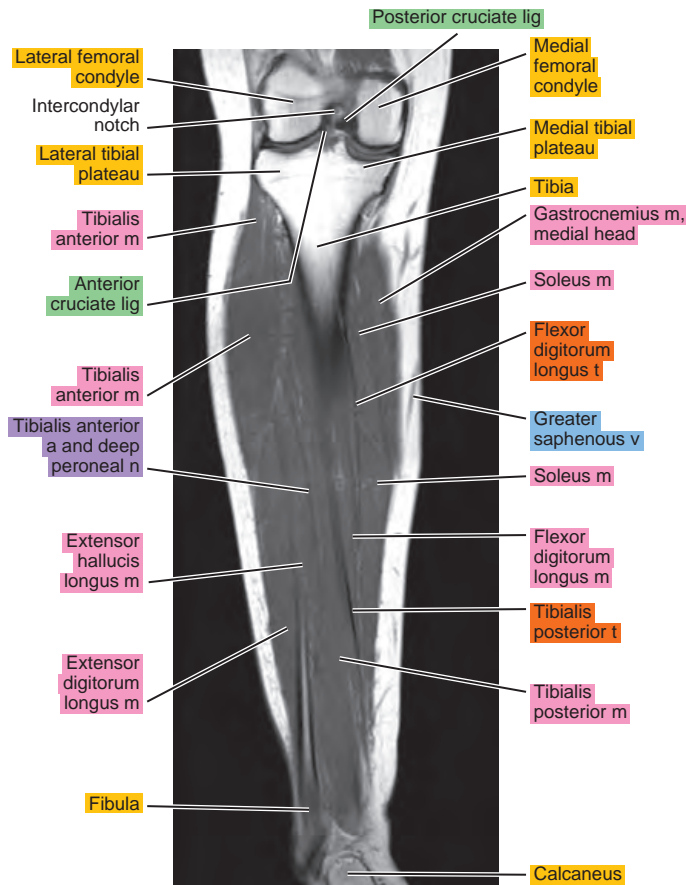


Figure 13.3.5

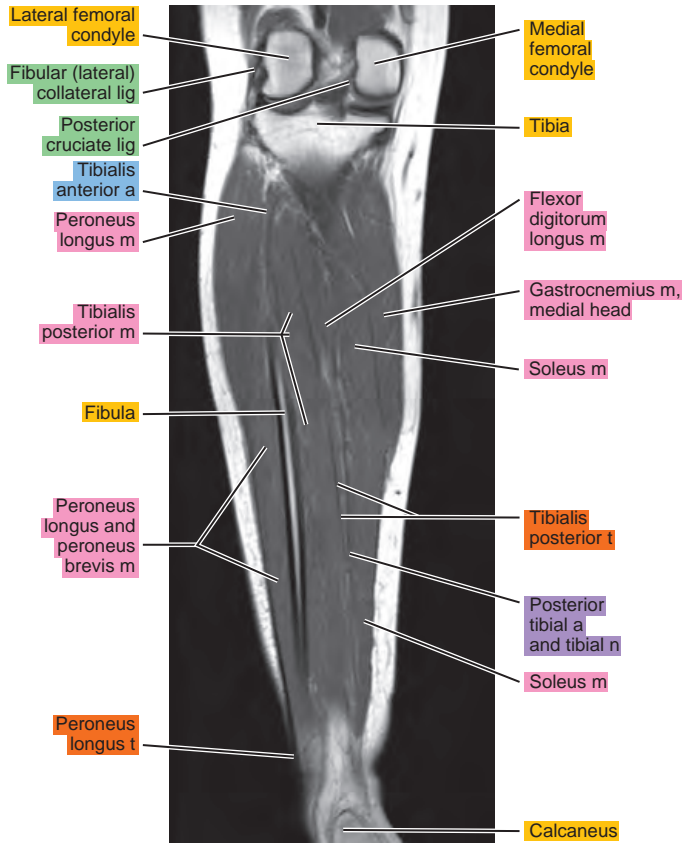
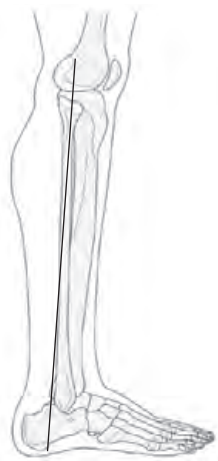

Figure 13.3.6

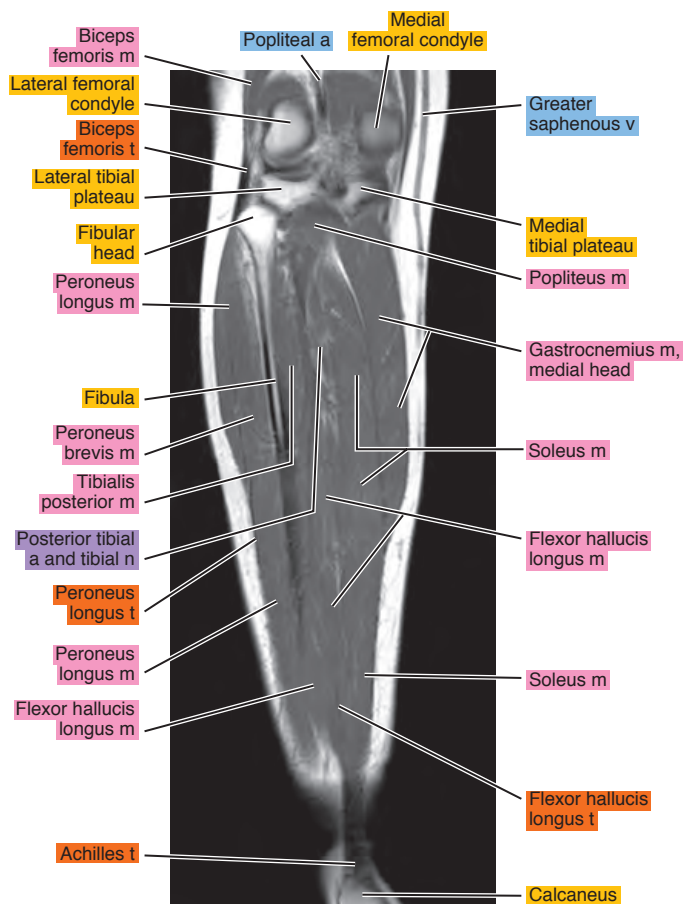
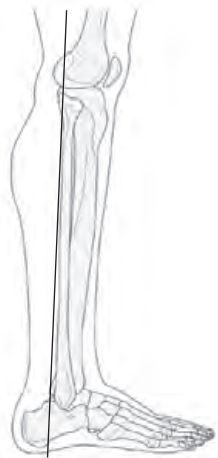

Figure 13.3.7

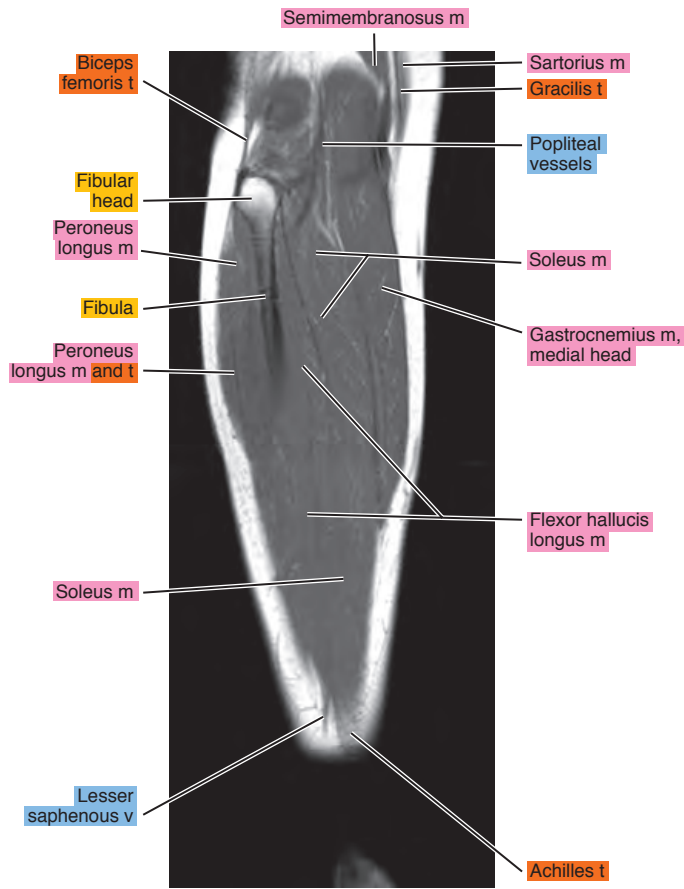



Figure 13.3.8

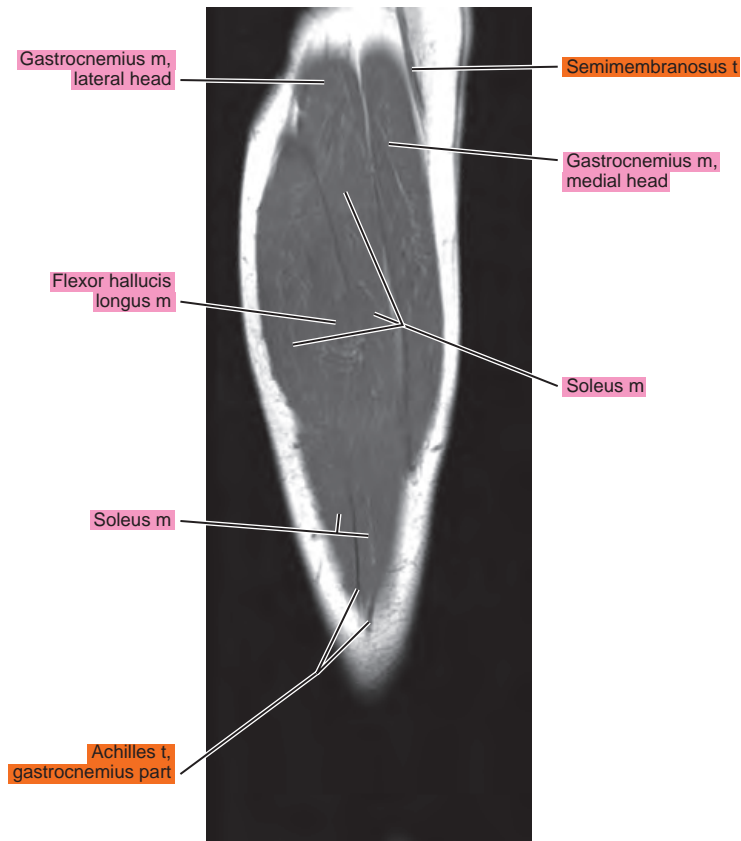
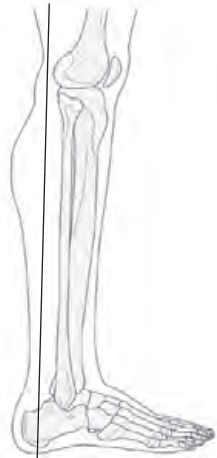


Figure 13.3.9

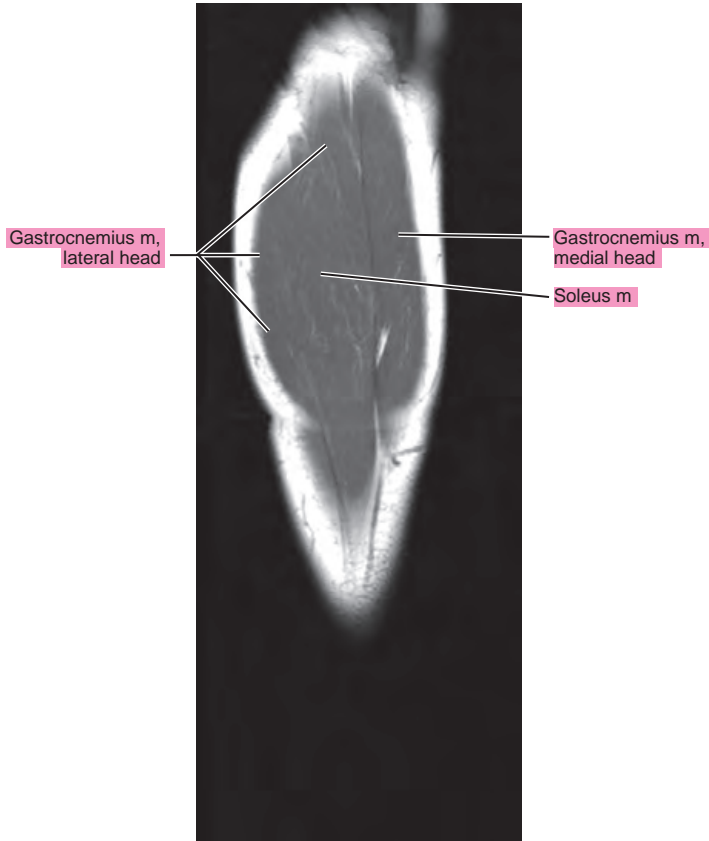
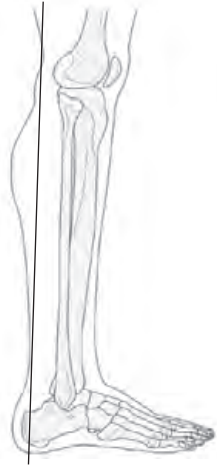


Figure 13.3.10

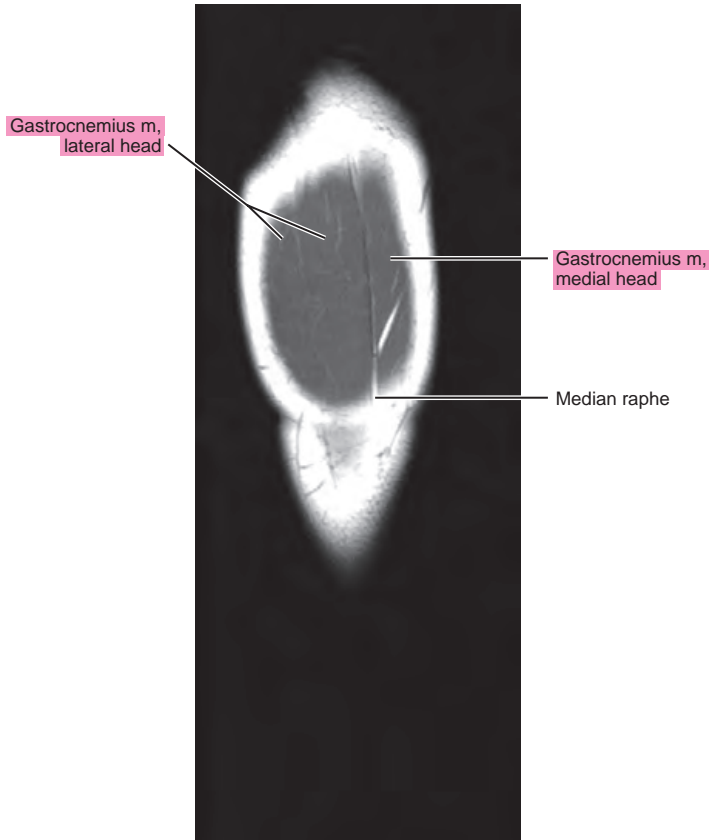
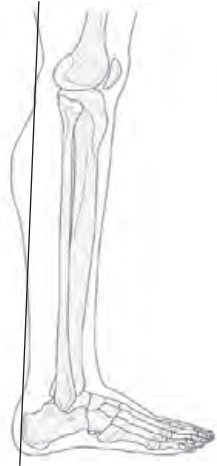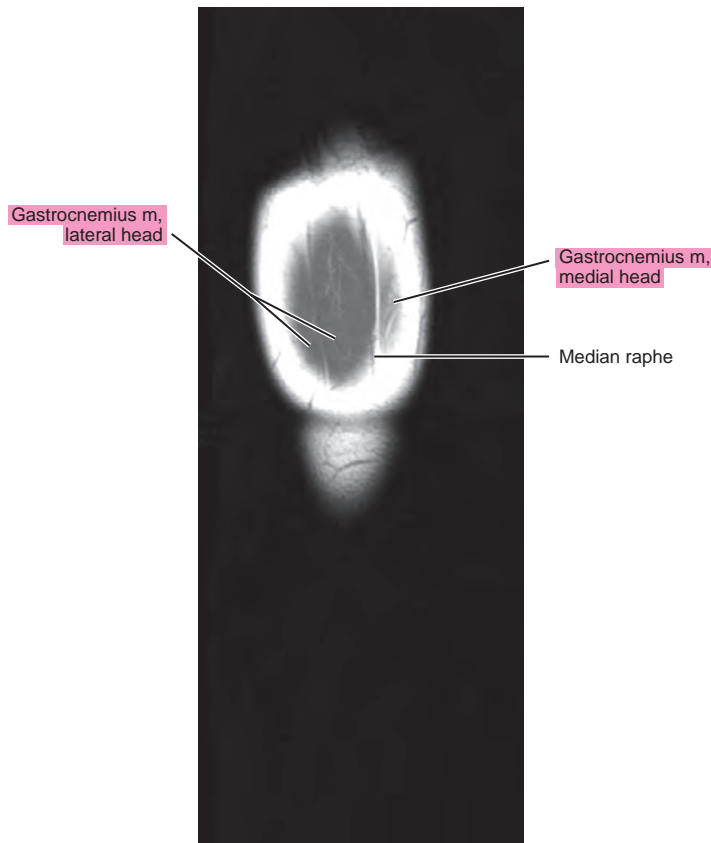

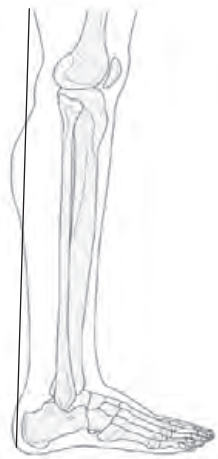
Figure 13.3.11



Chapter
14

MRI of the Ankle

AXIAL

Figure 14.1.1

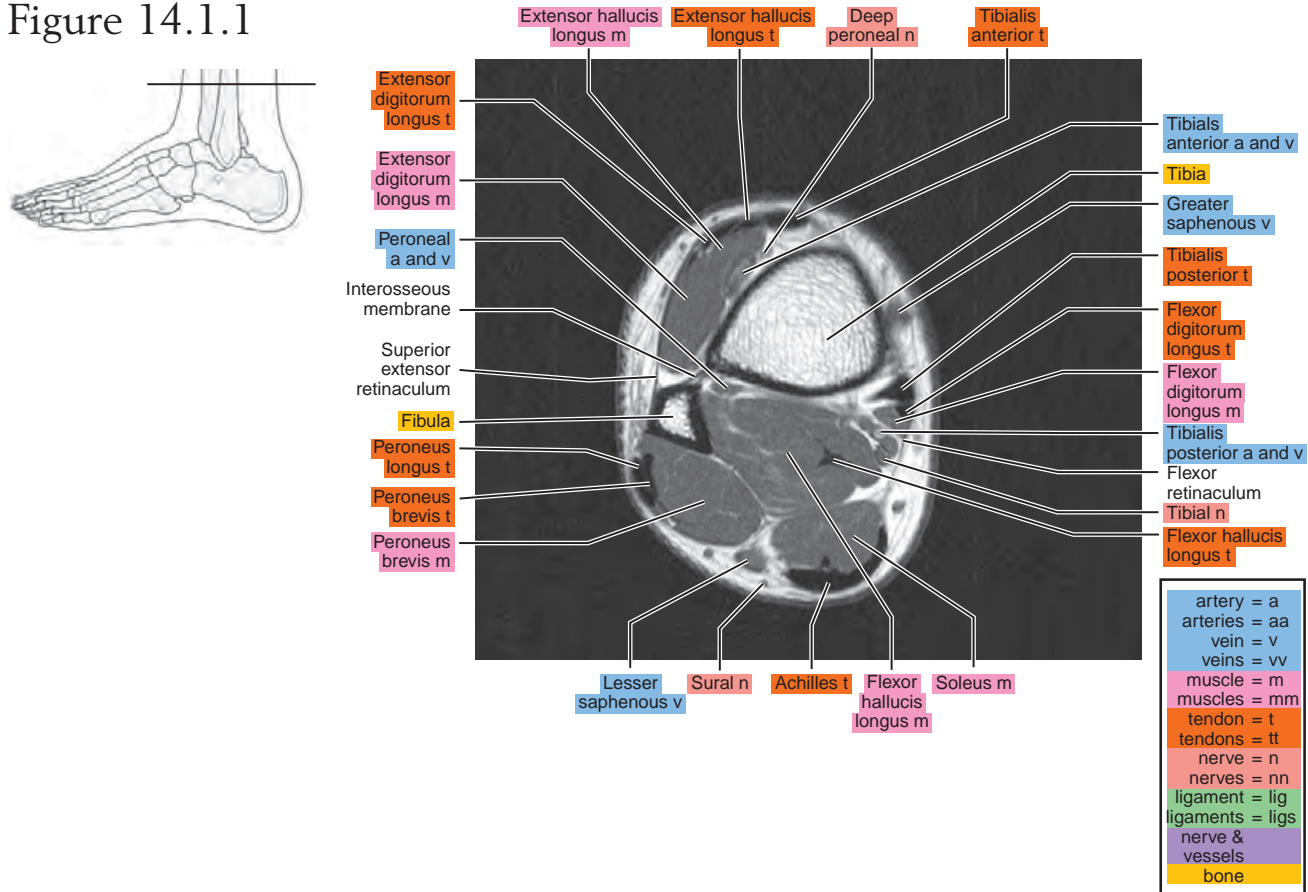


Figure 14.1.2

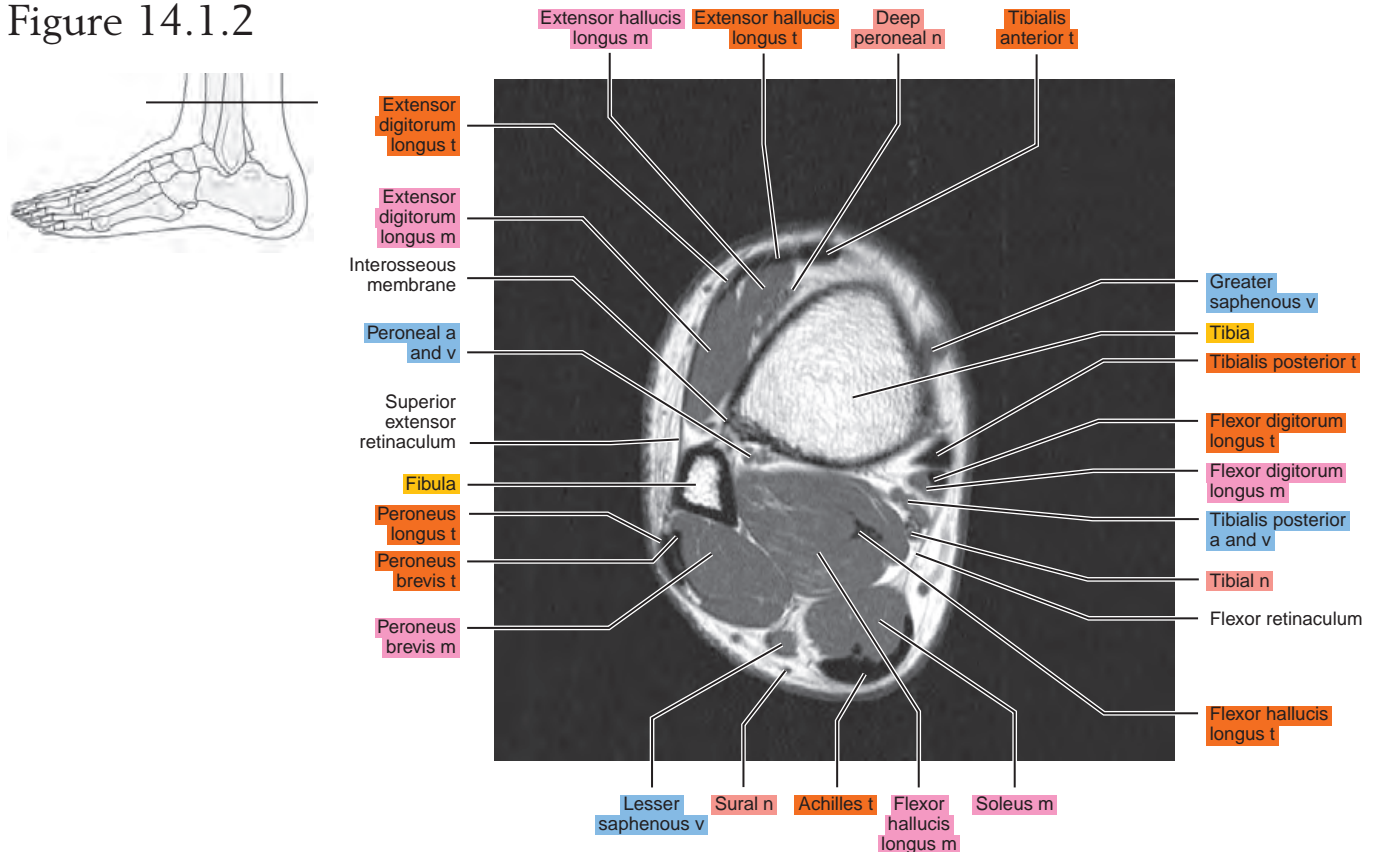


Figure 14.1.3

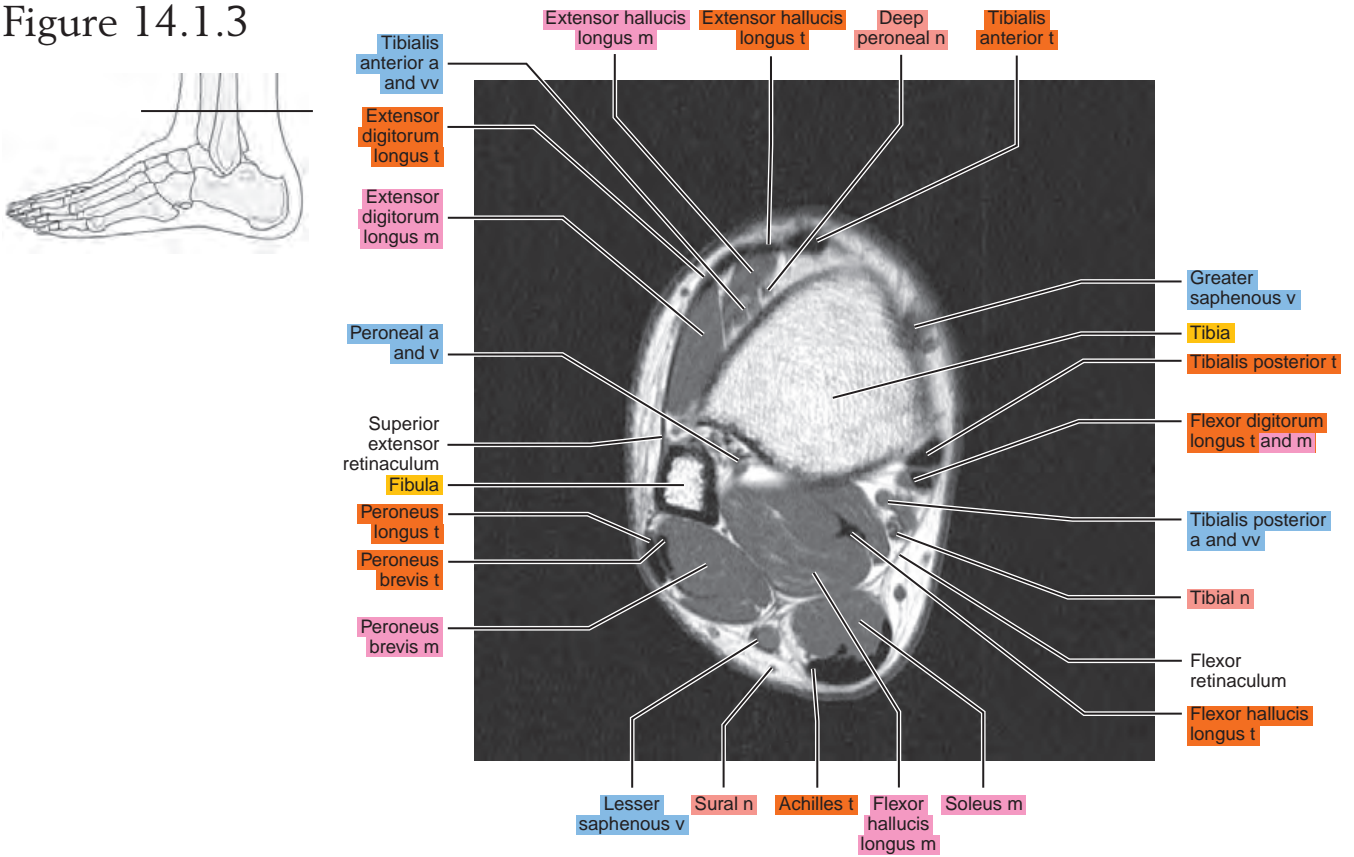


Figure 14.1.4

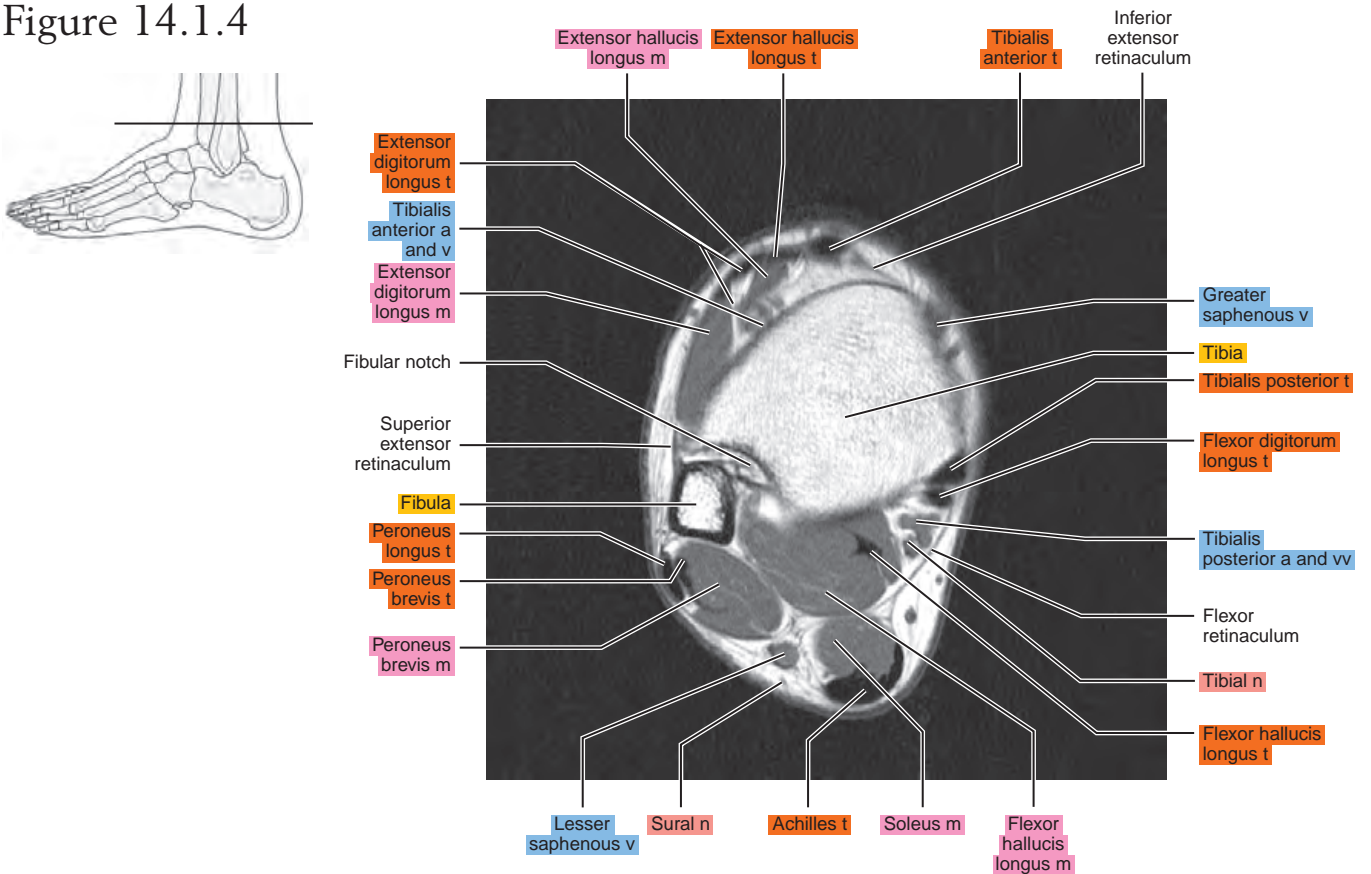


Figure 14.1.5

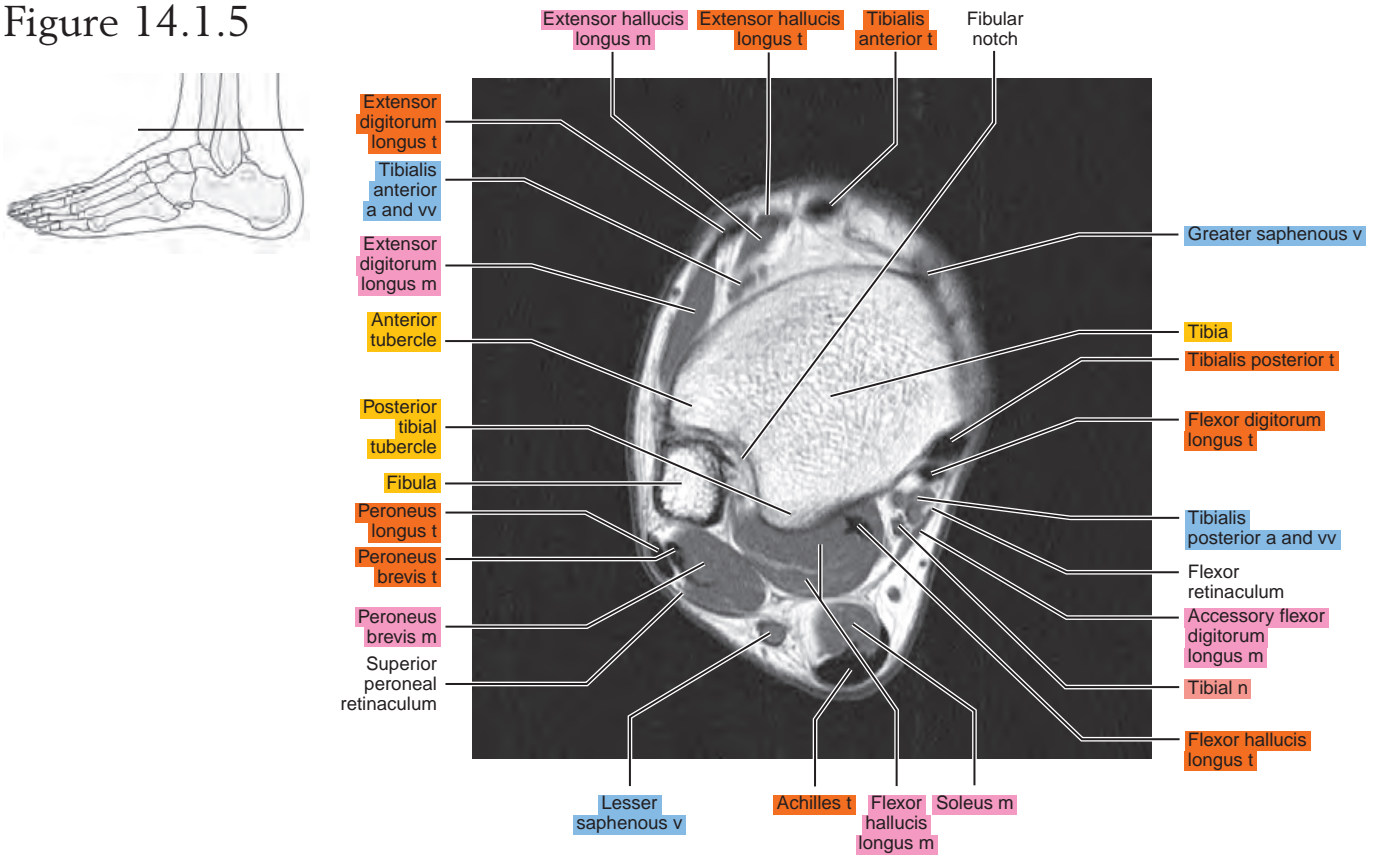


Figure 14.1.6

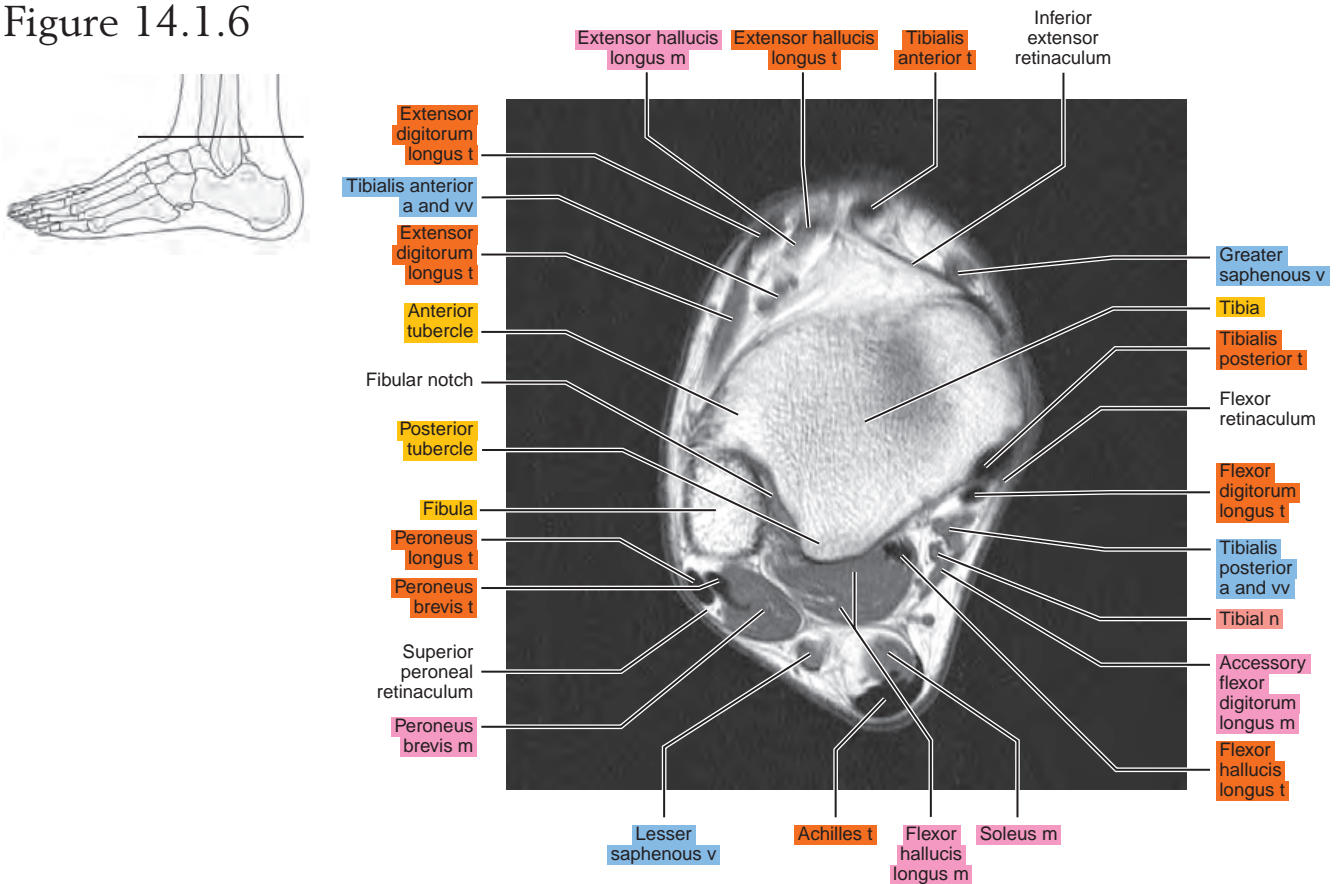


Figure 14.1.7

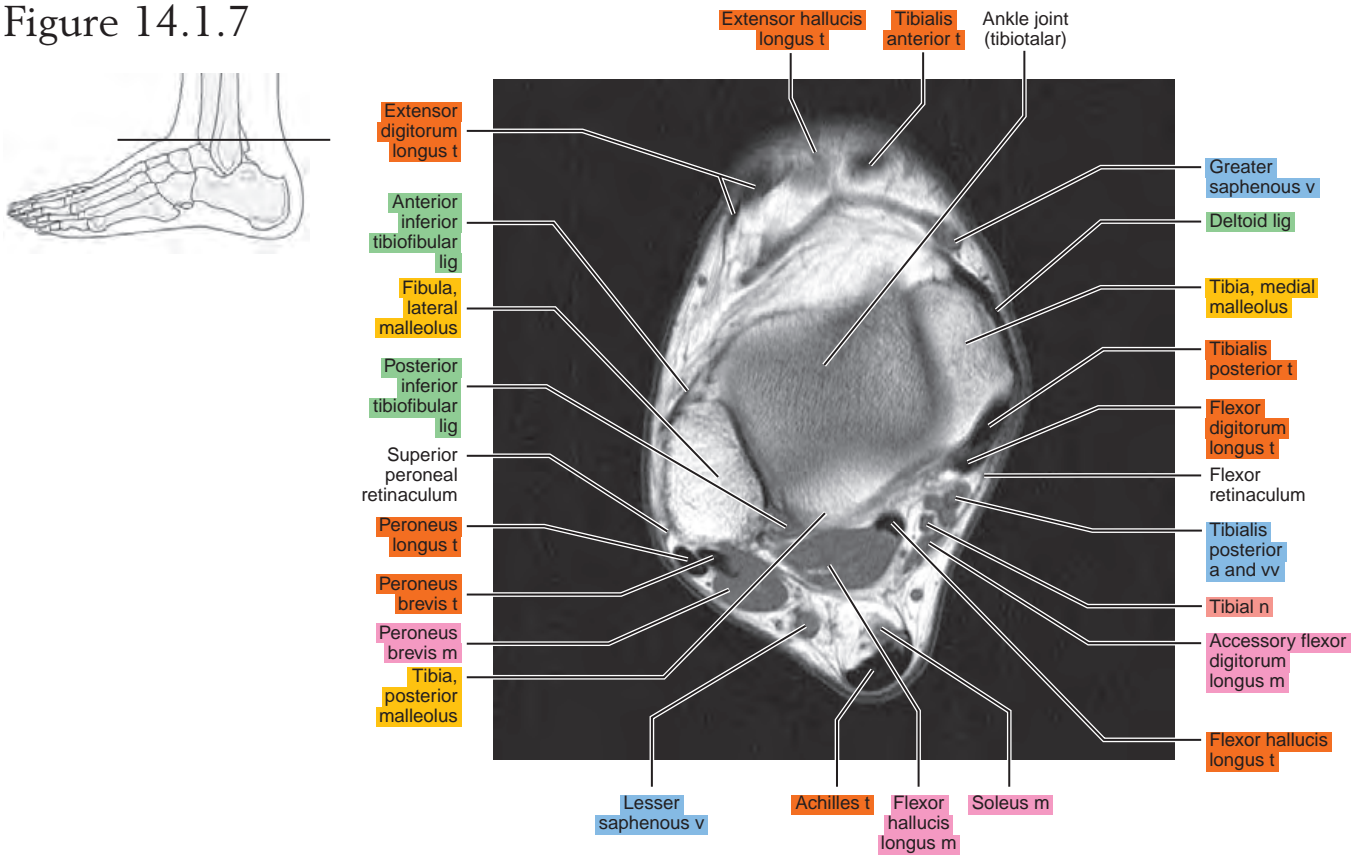


Figure 14.1.8

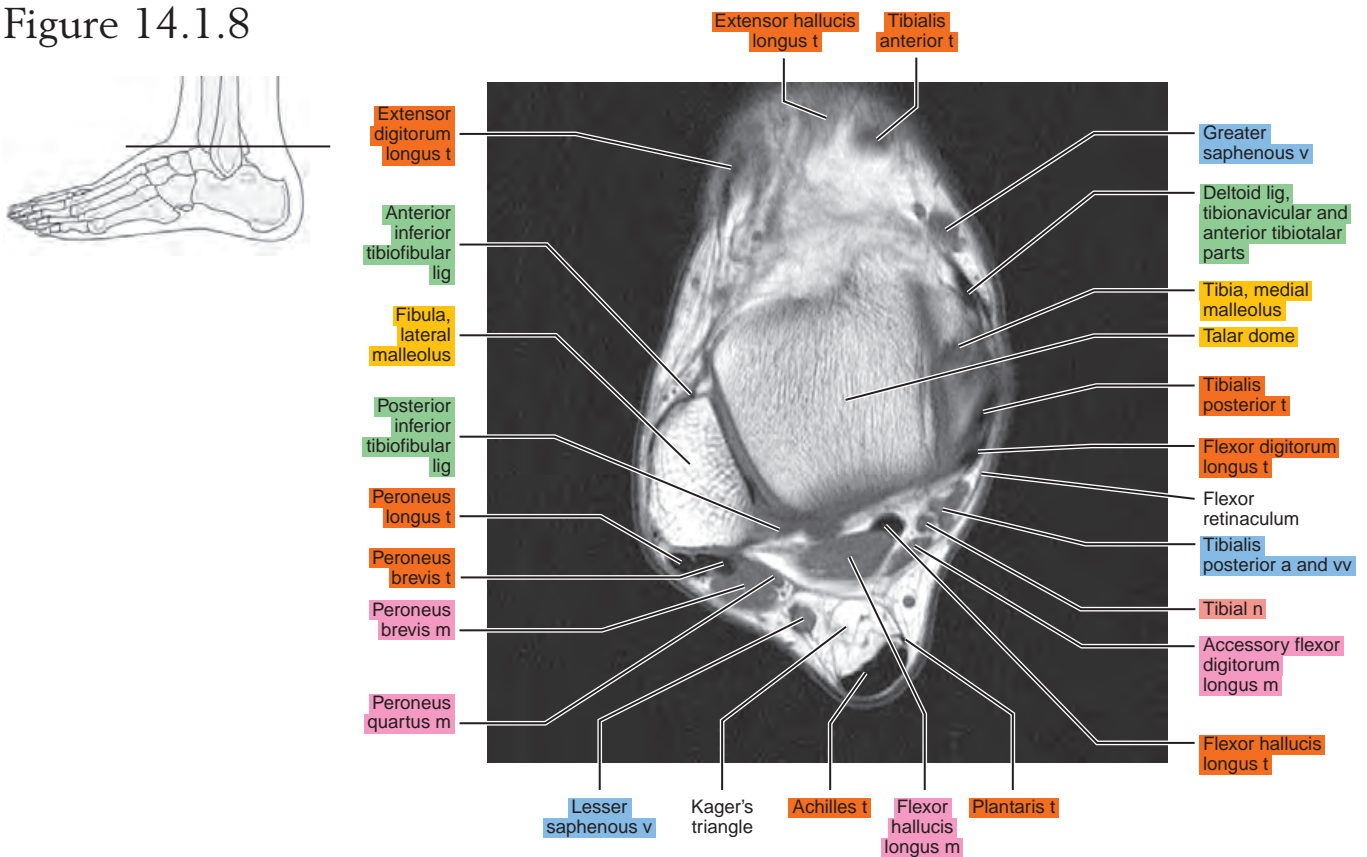


Figure 14.1.9

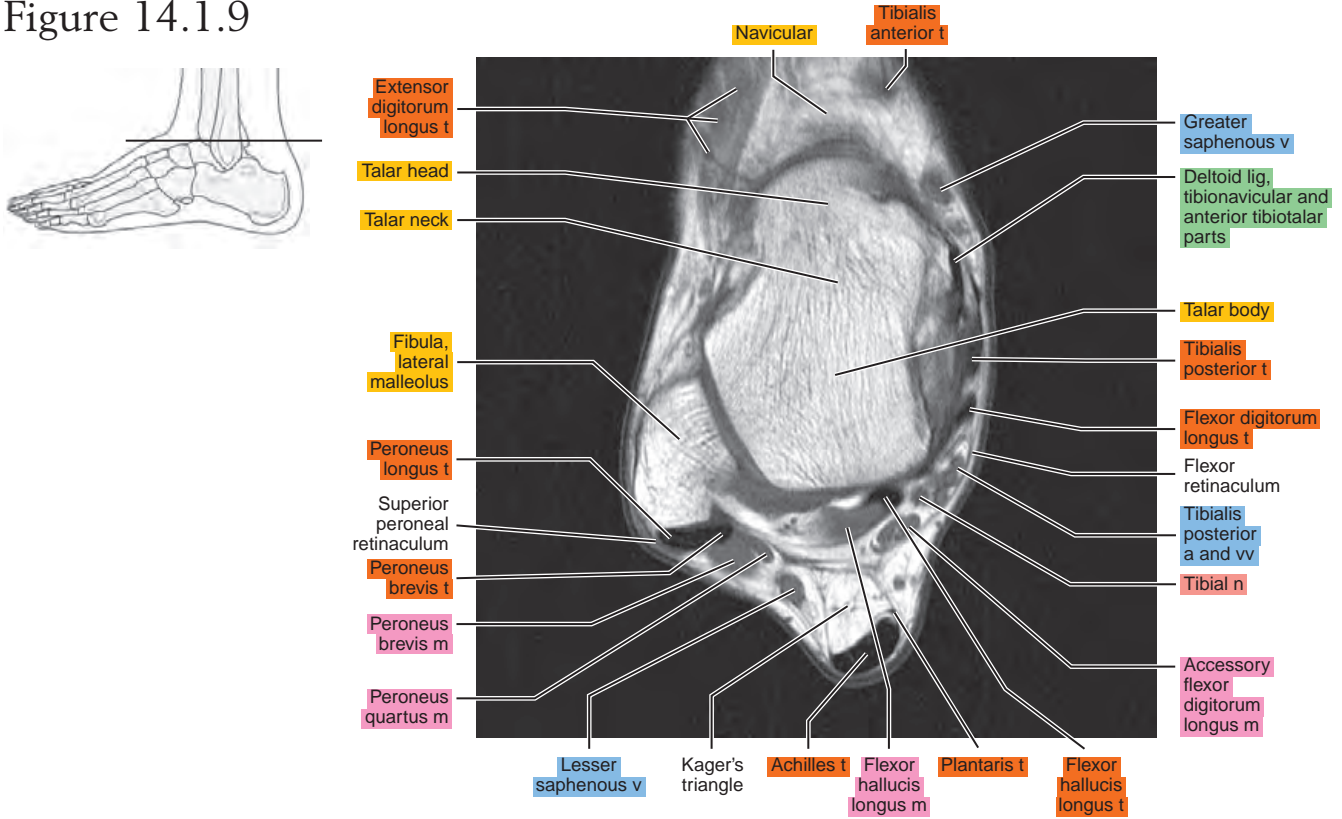


Figure 14.1.10

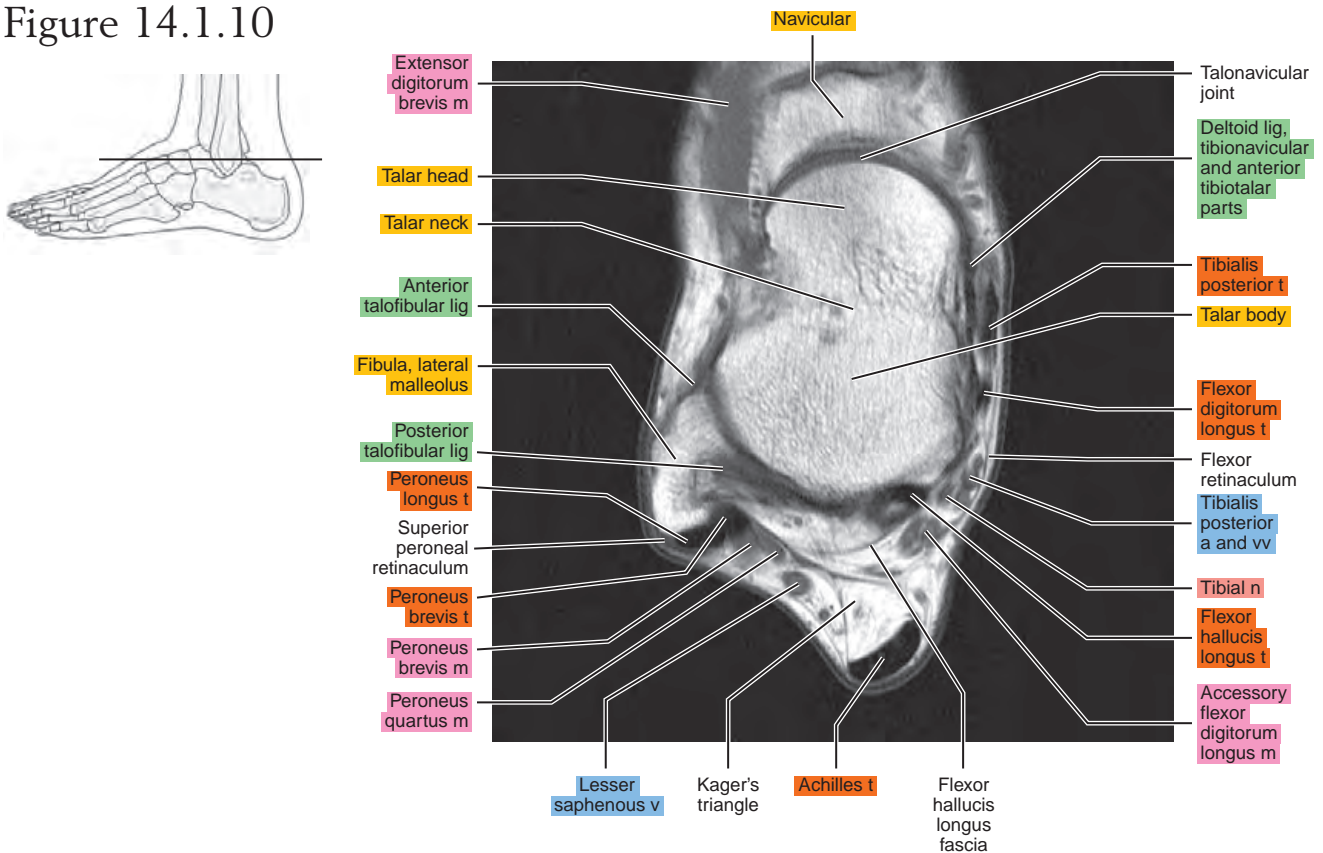


Figure 14.1.11

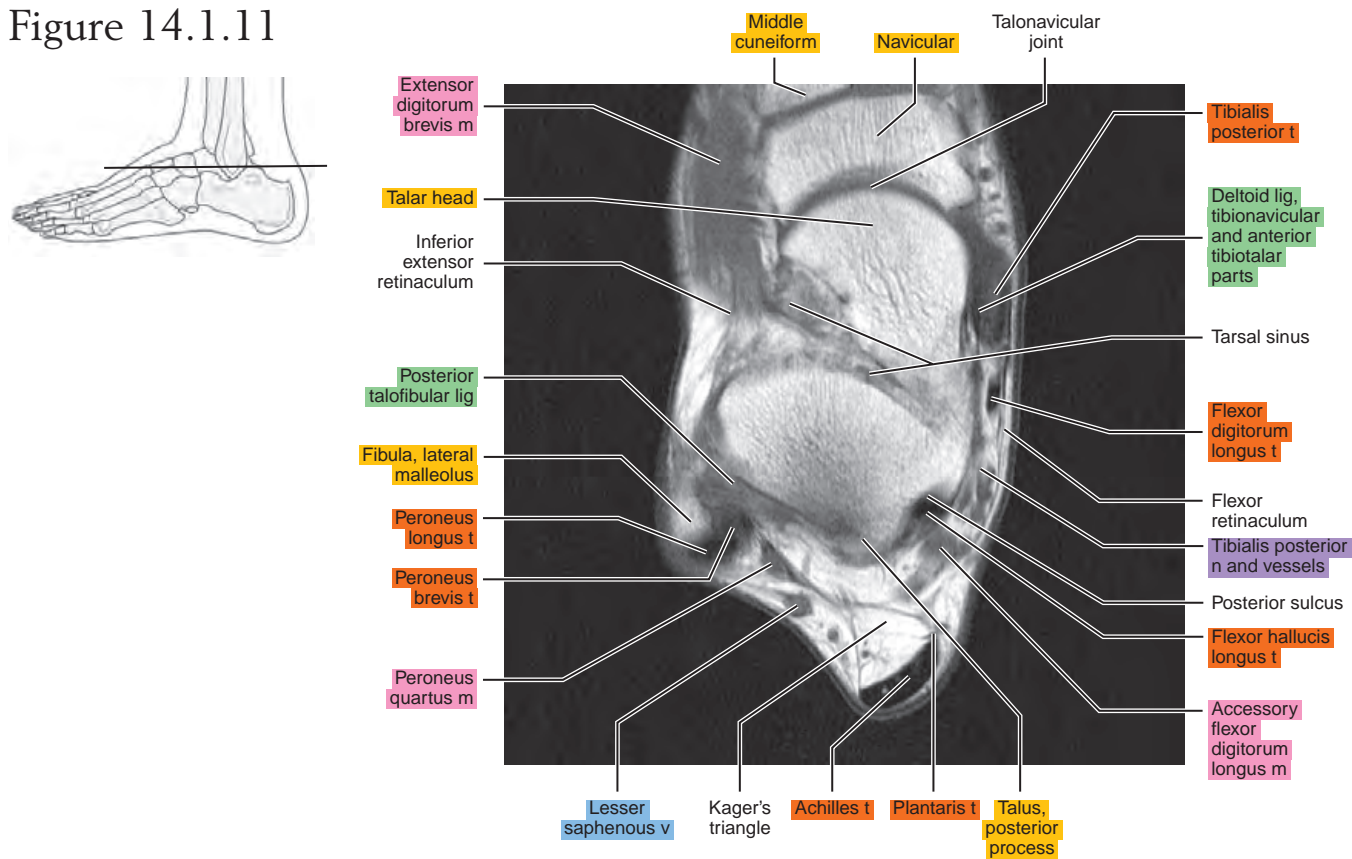


Figure 14.1.12

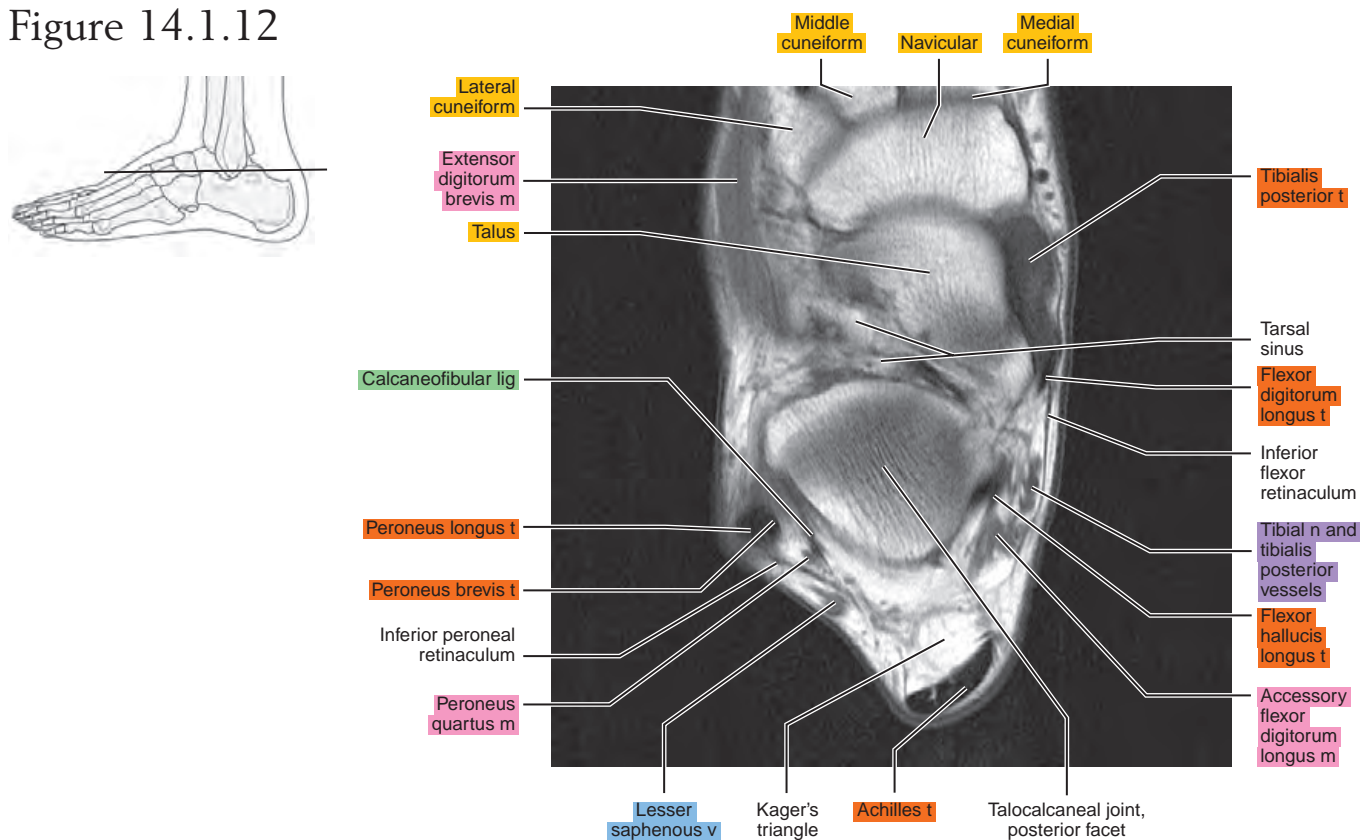


Figure 14.1.13

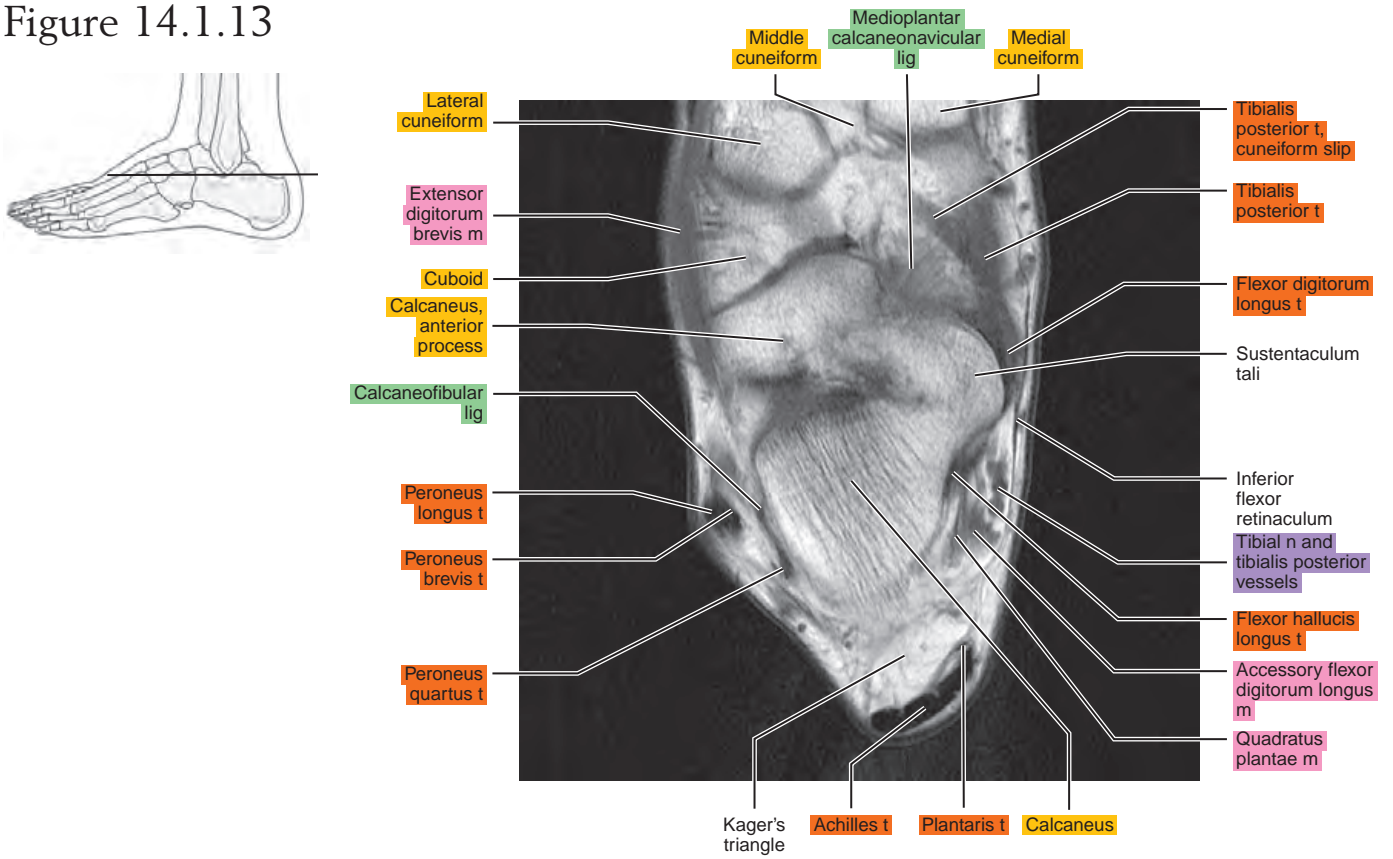


Figure 14.1.14

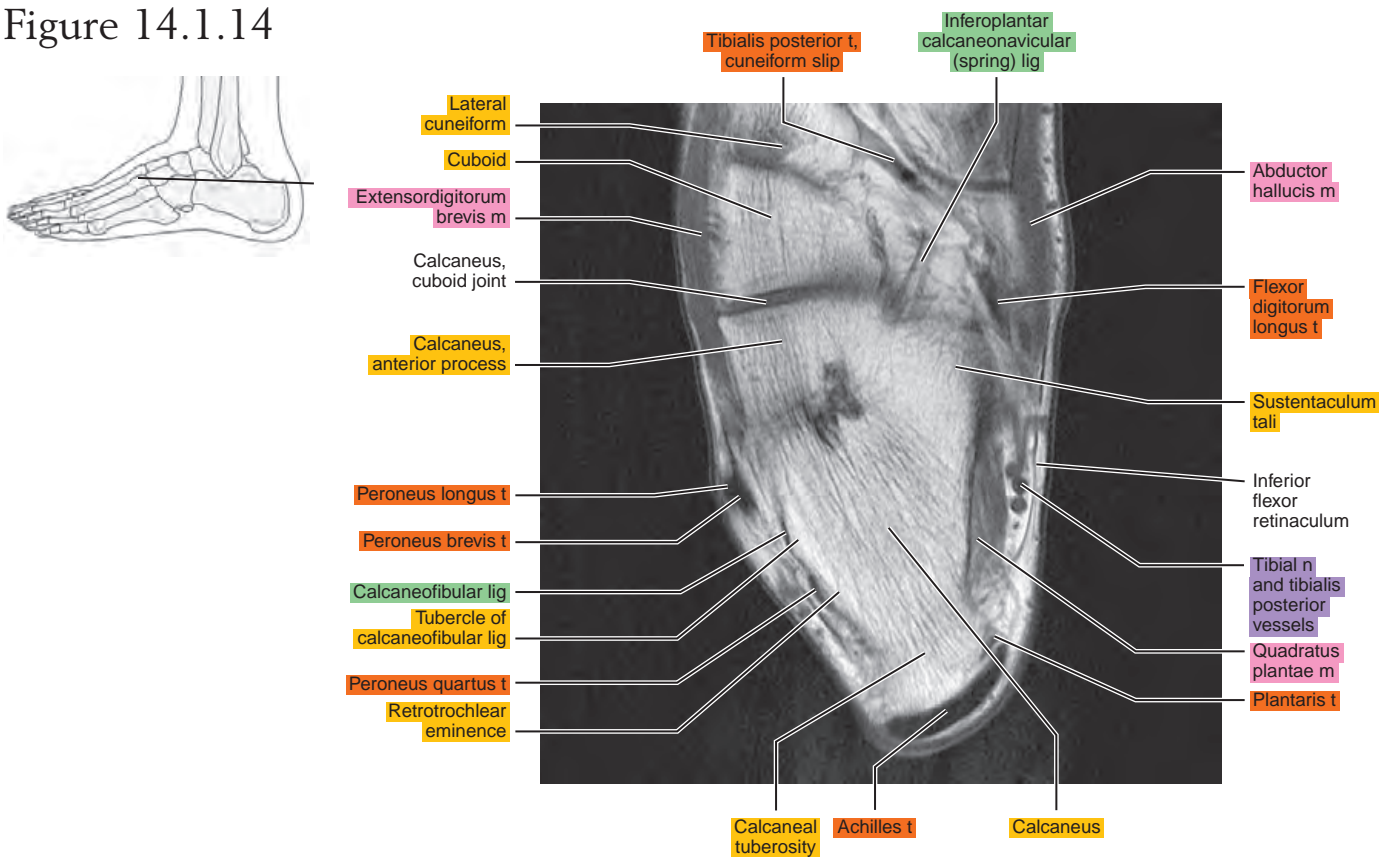


Figure 14.1.15

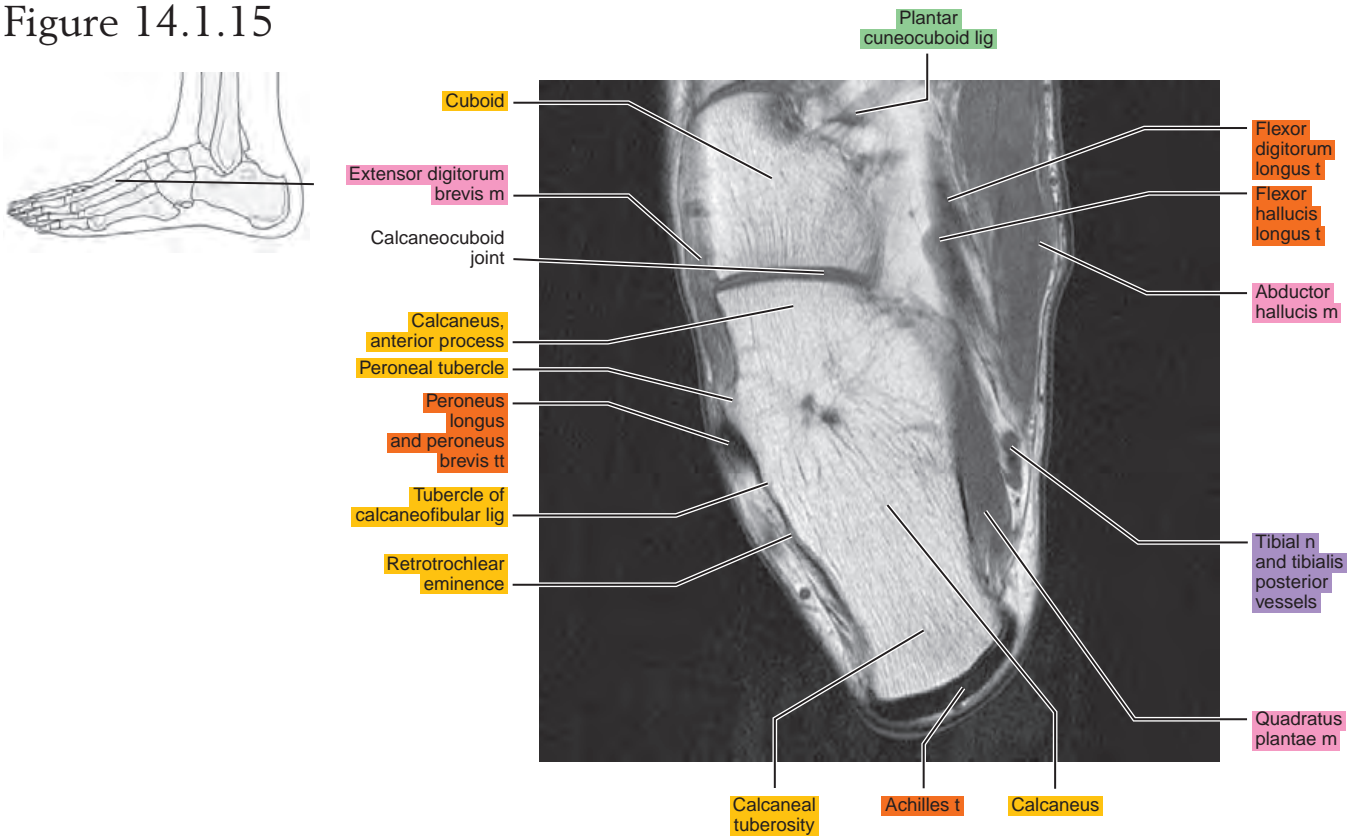


Figure 14.1.16

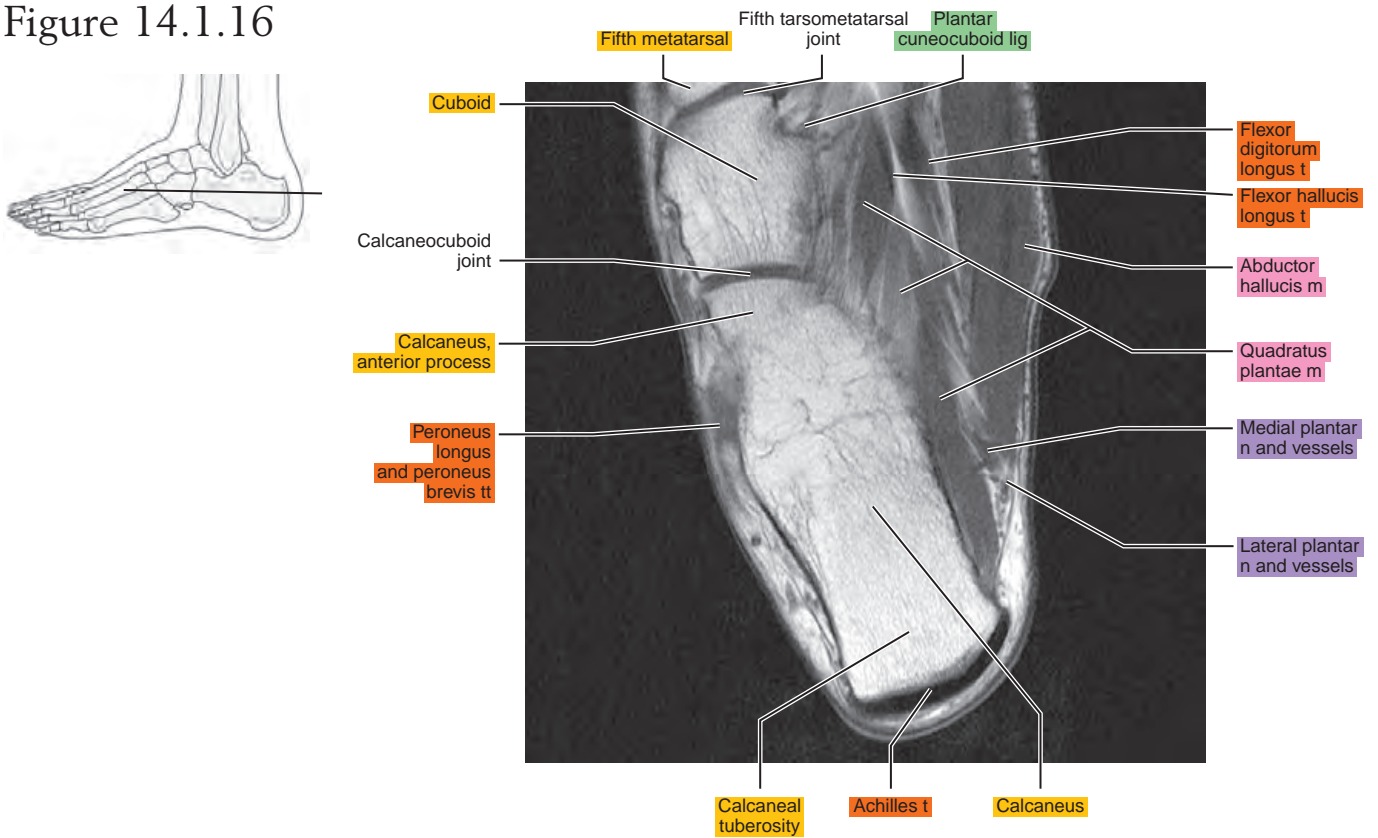


Figure 14.1.17

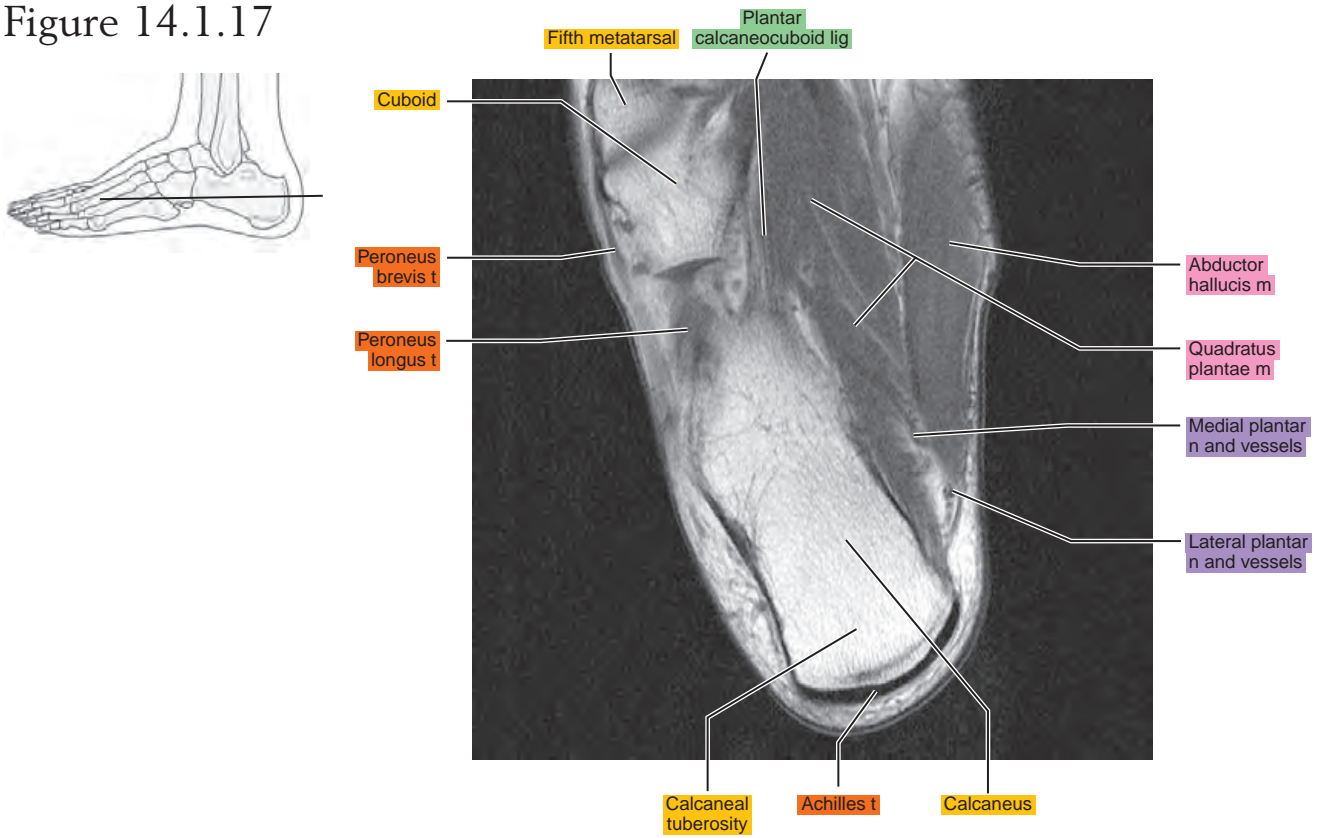


Figure 14.1.18

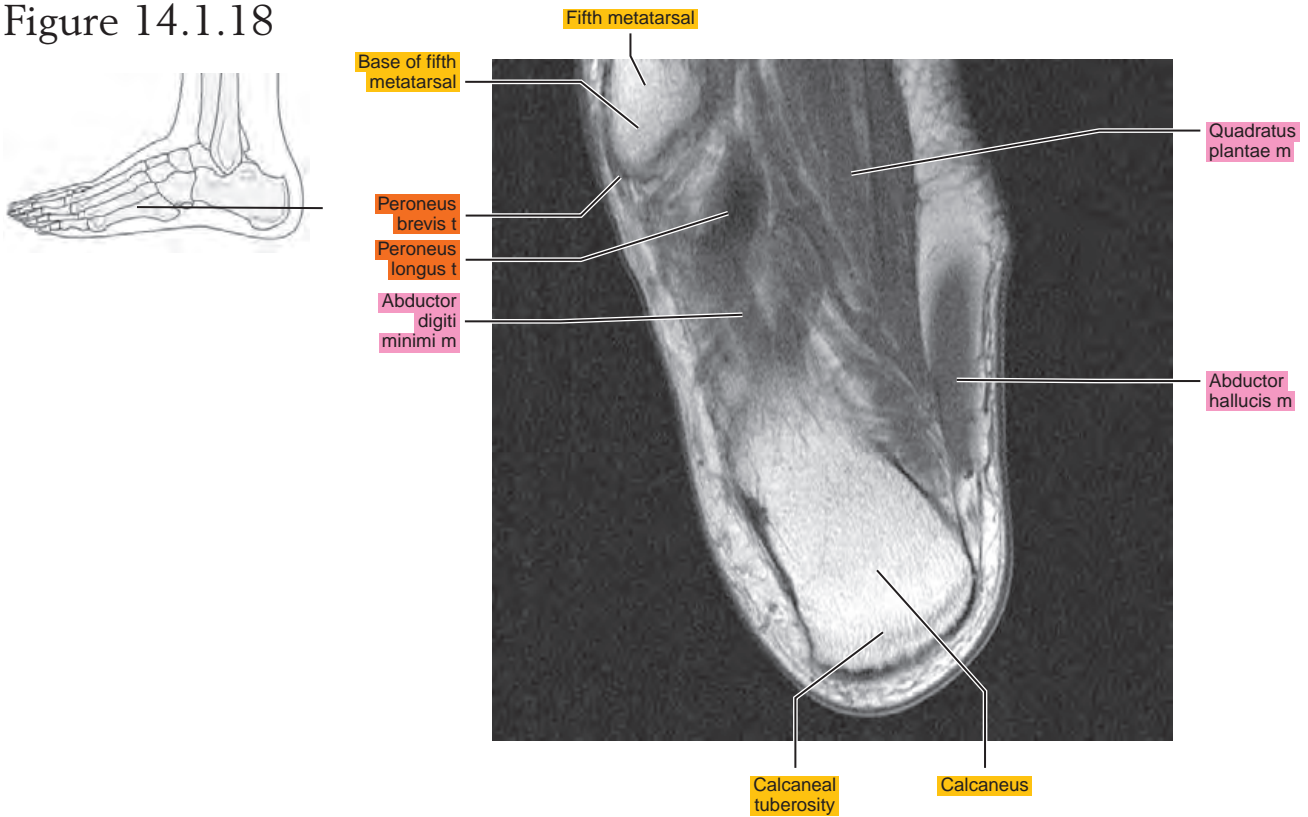


Figure 14.1.19

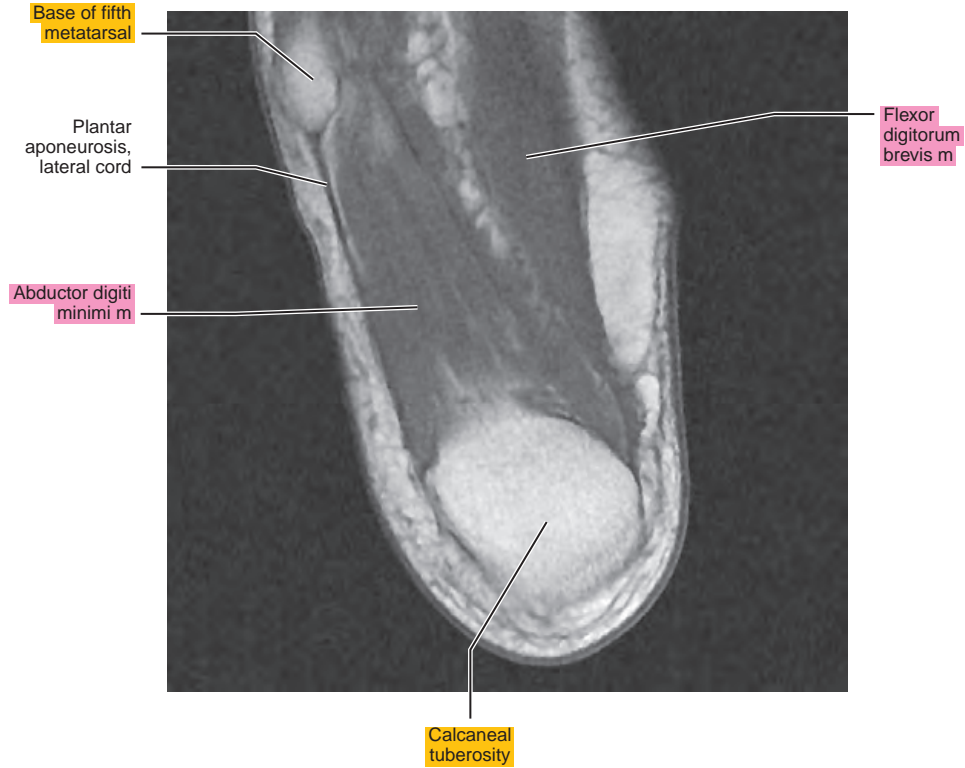
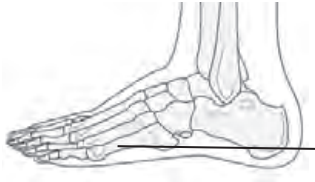
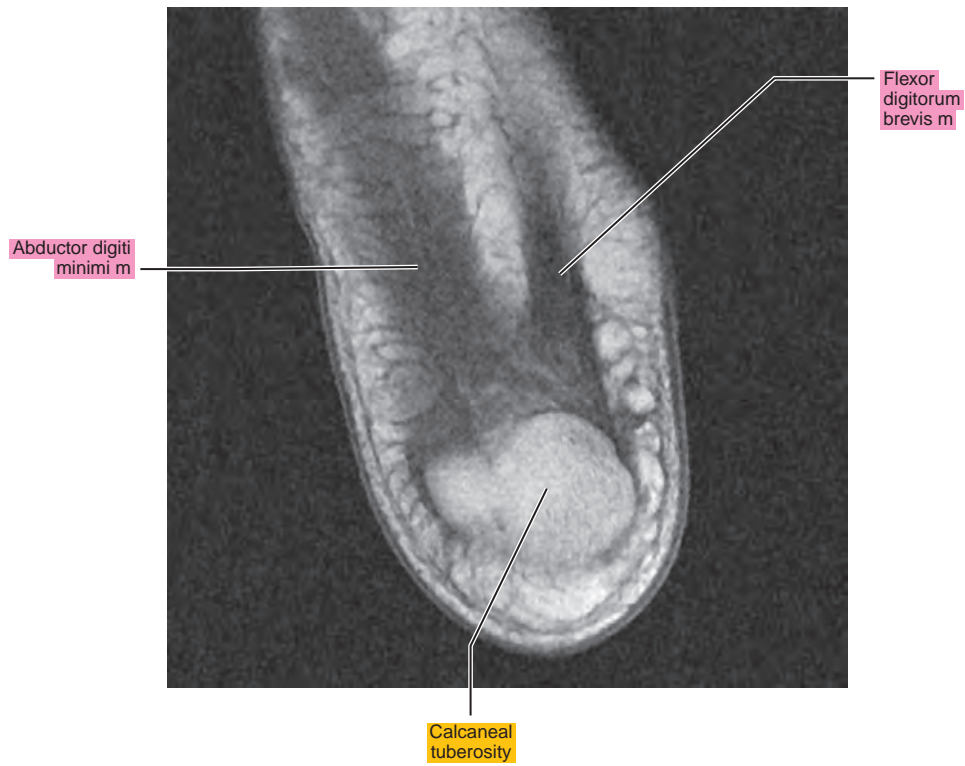
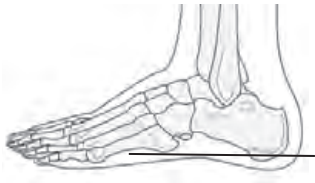Figure 14.1.20



OBLIQUE AXIAL

Figure 14.2.1

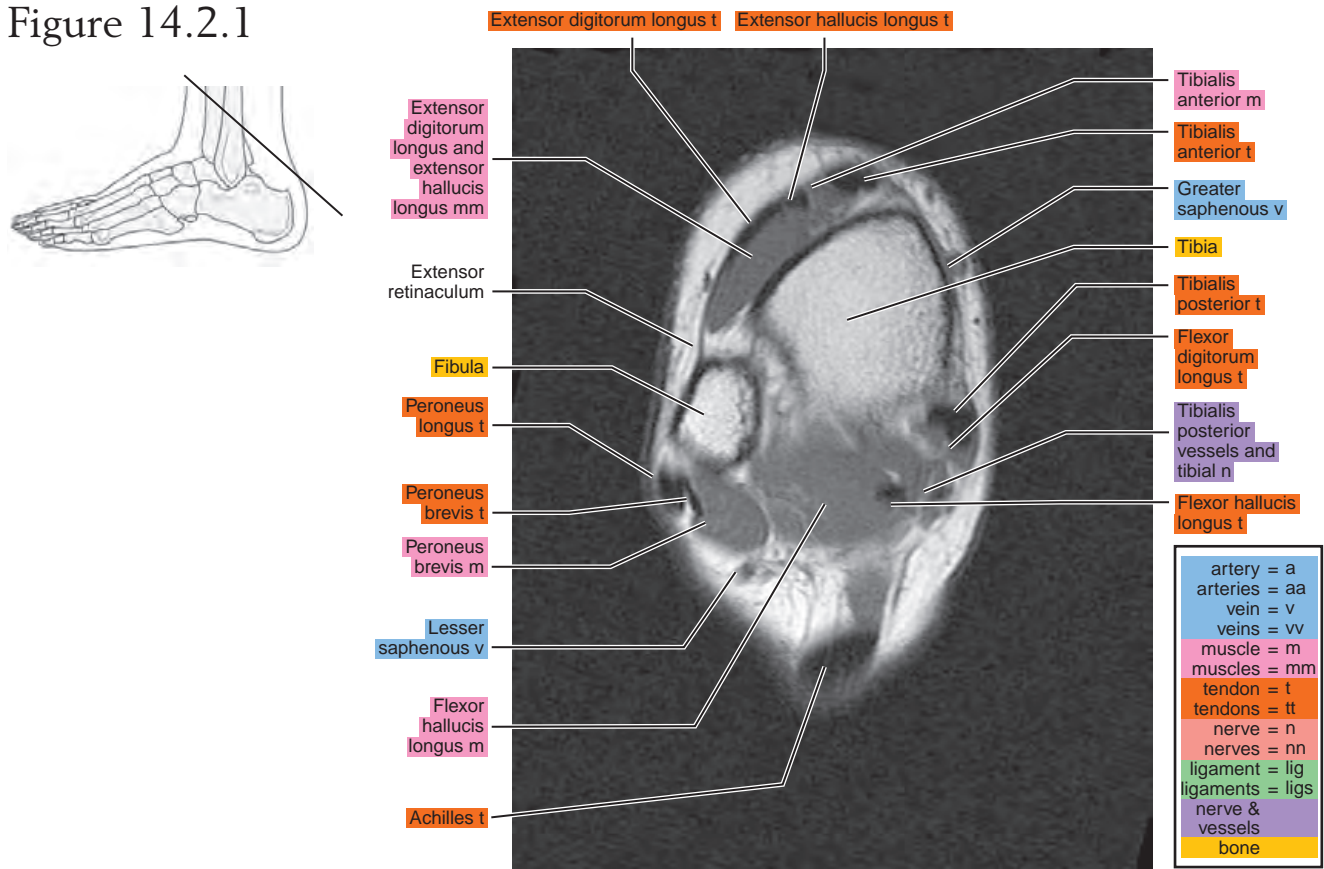


Figure 14.2.2

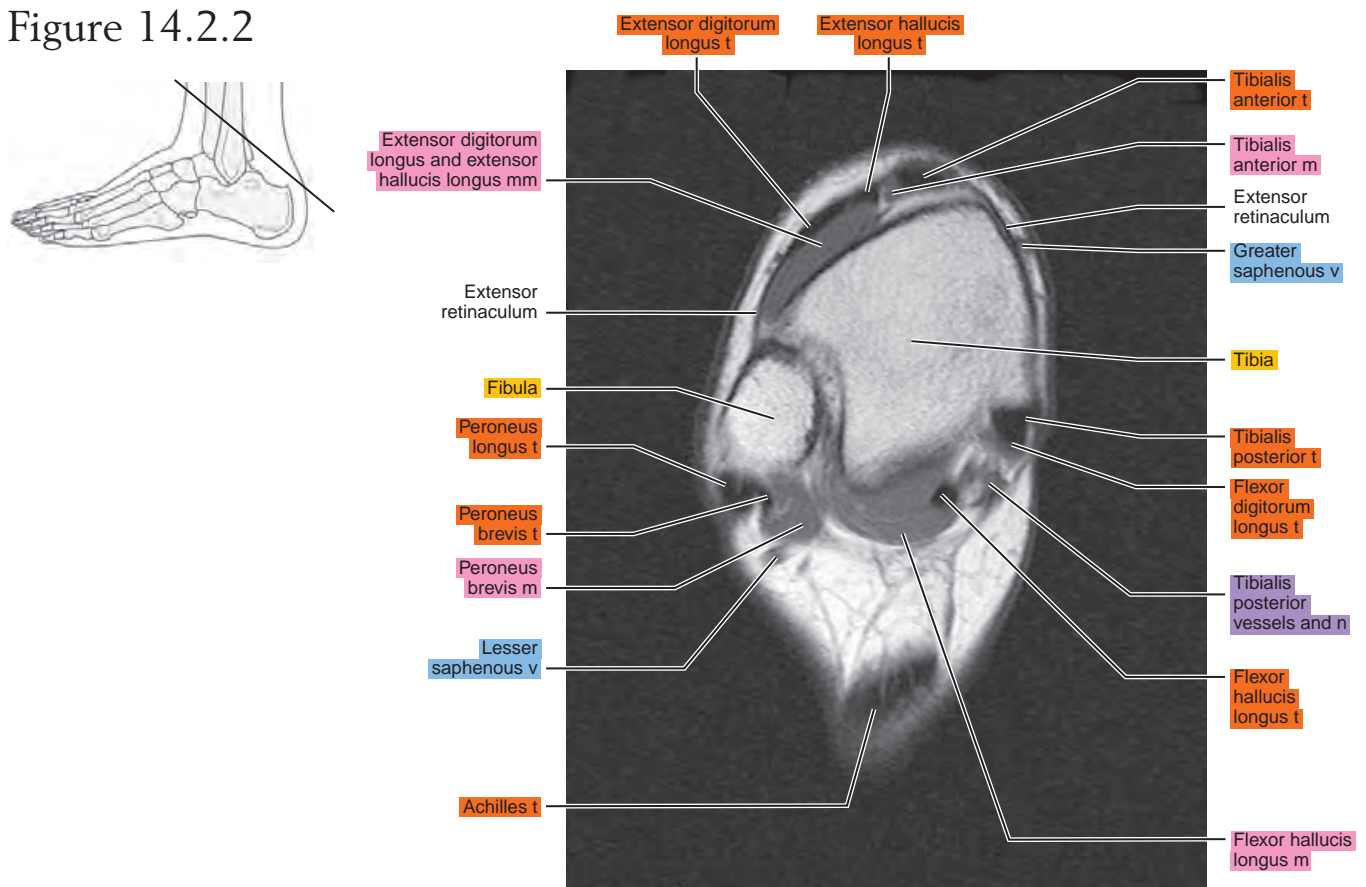


Figure 14.2.3

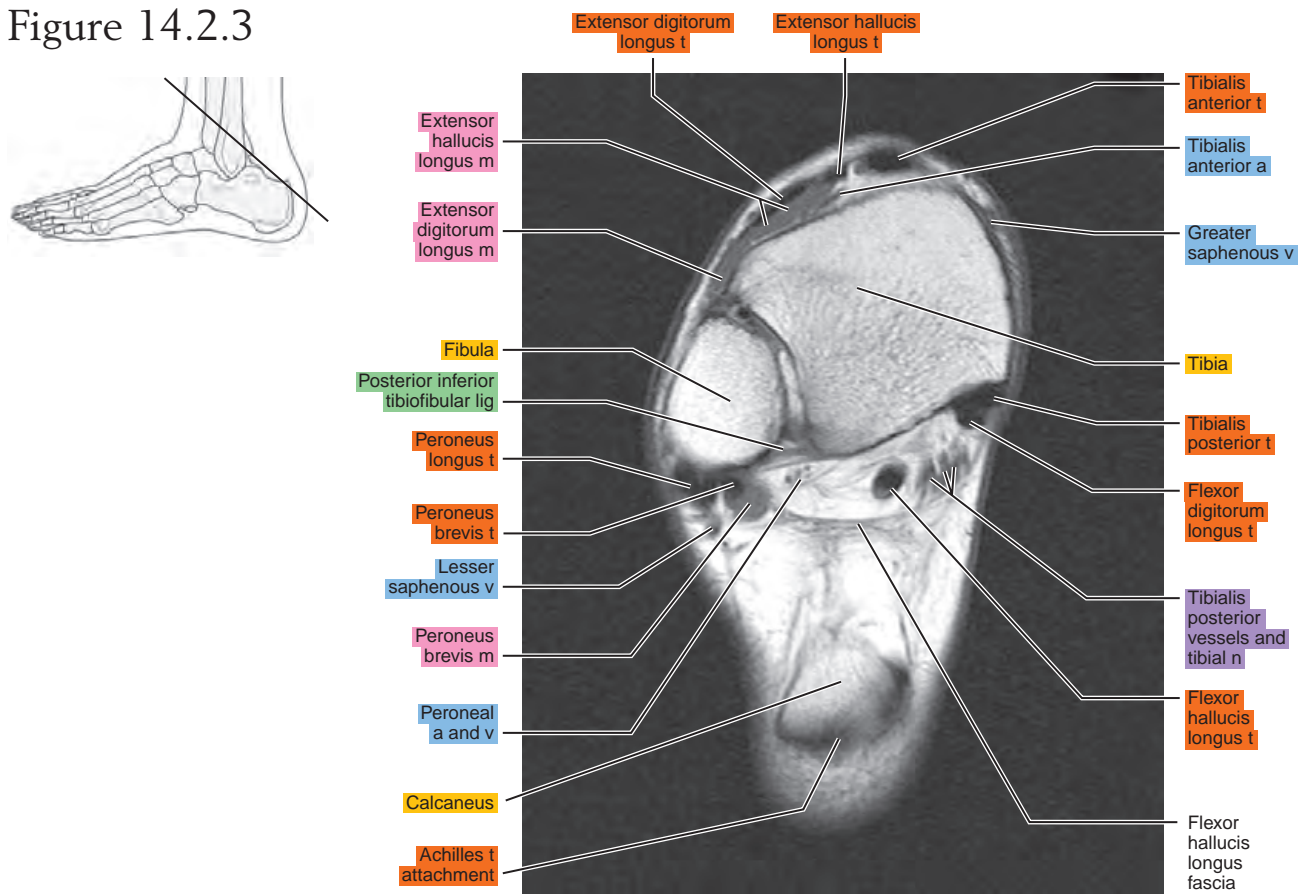


Figure 14.2.4

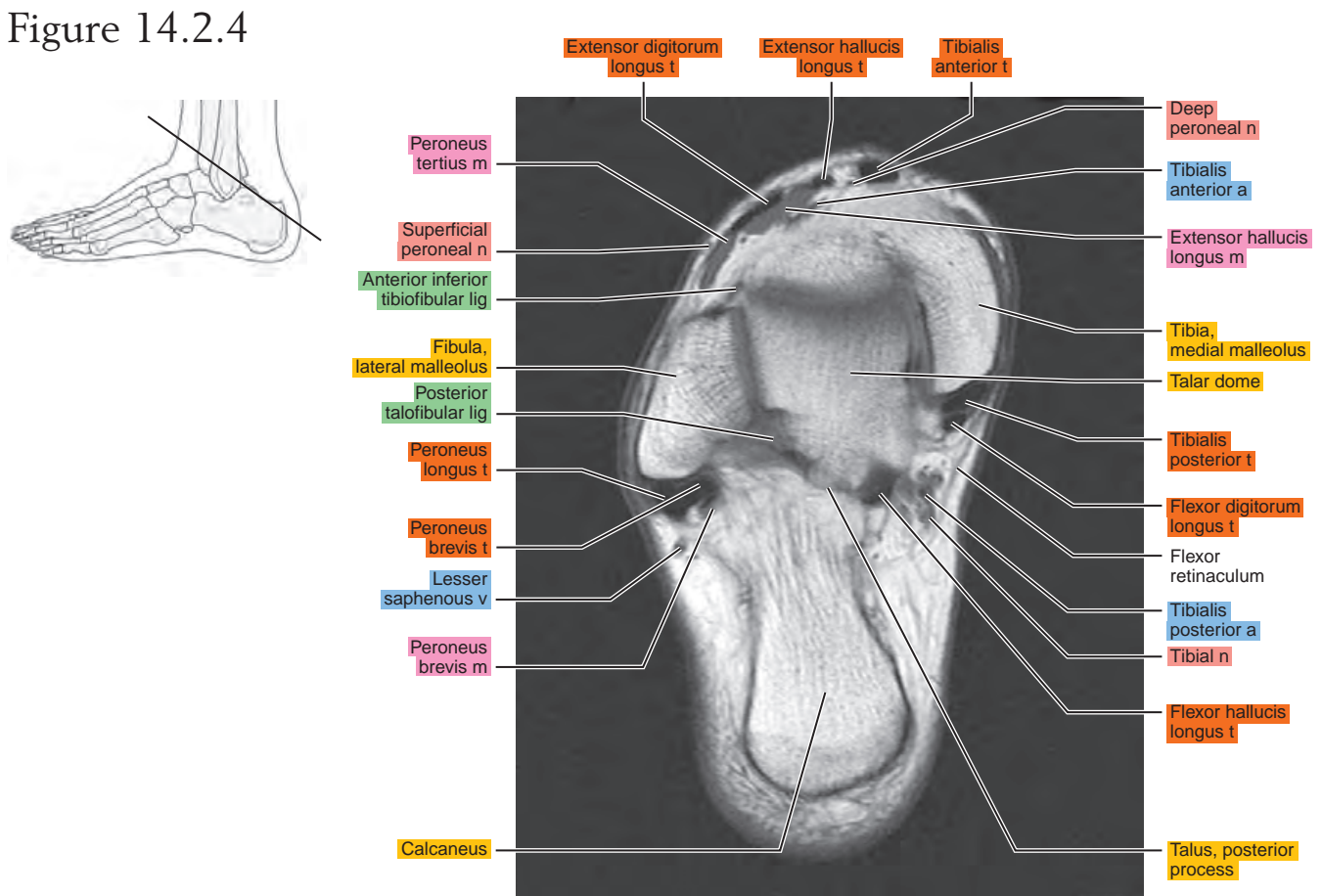


Figure 14.2.5

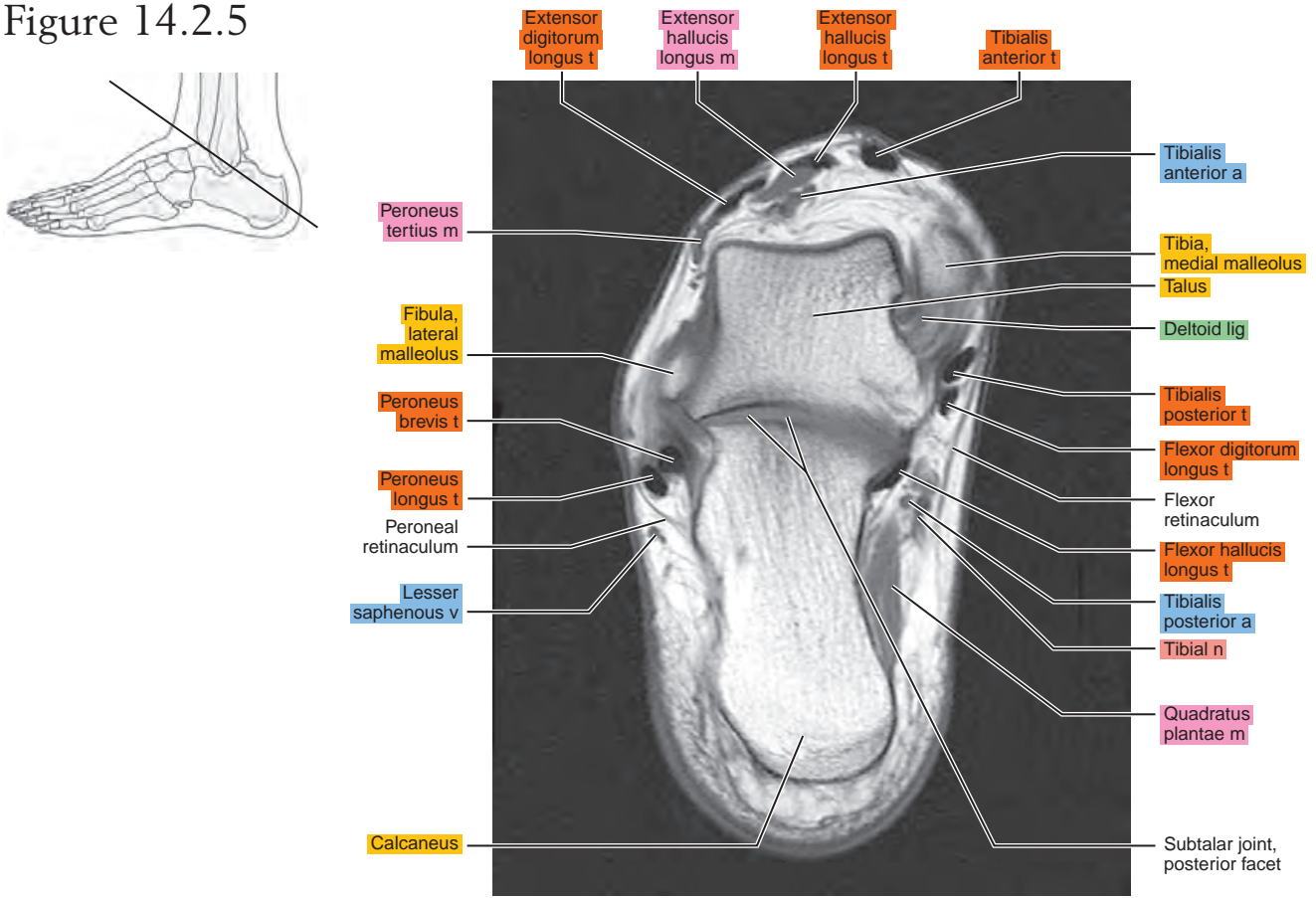


Figure 14.2.6

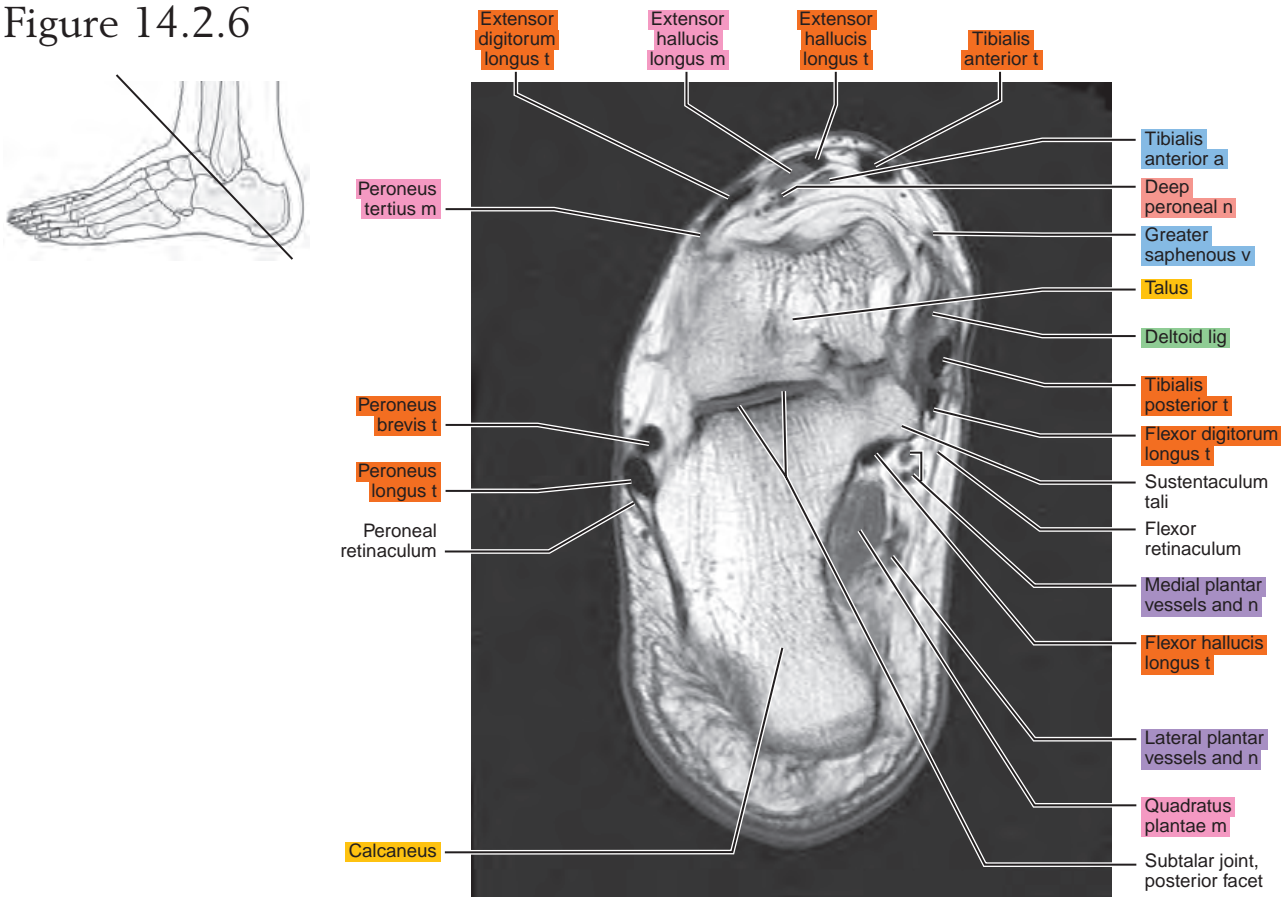


Figure 14.2.7

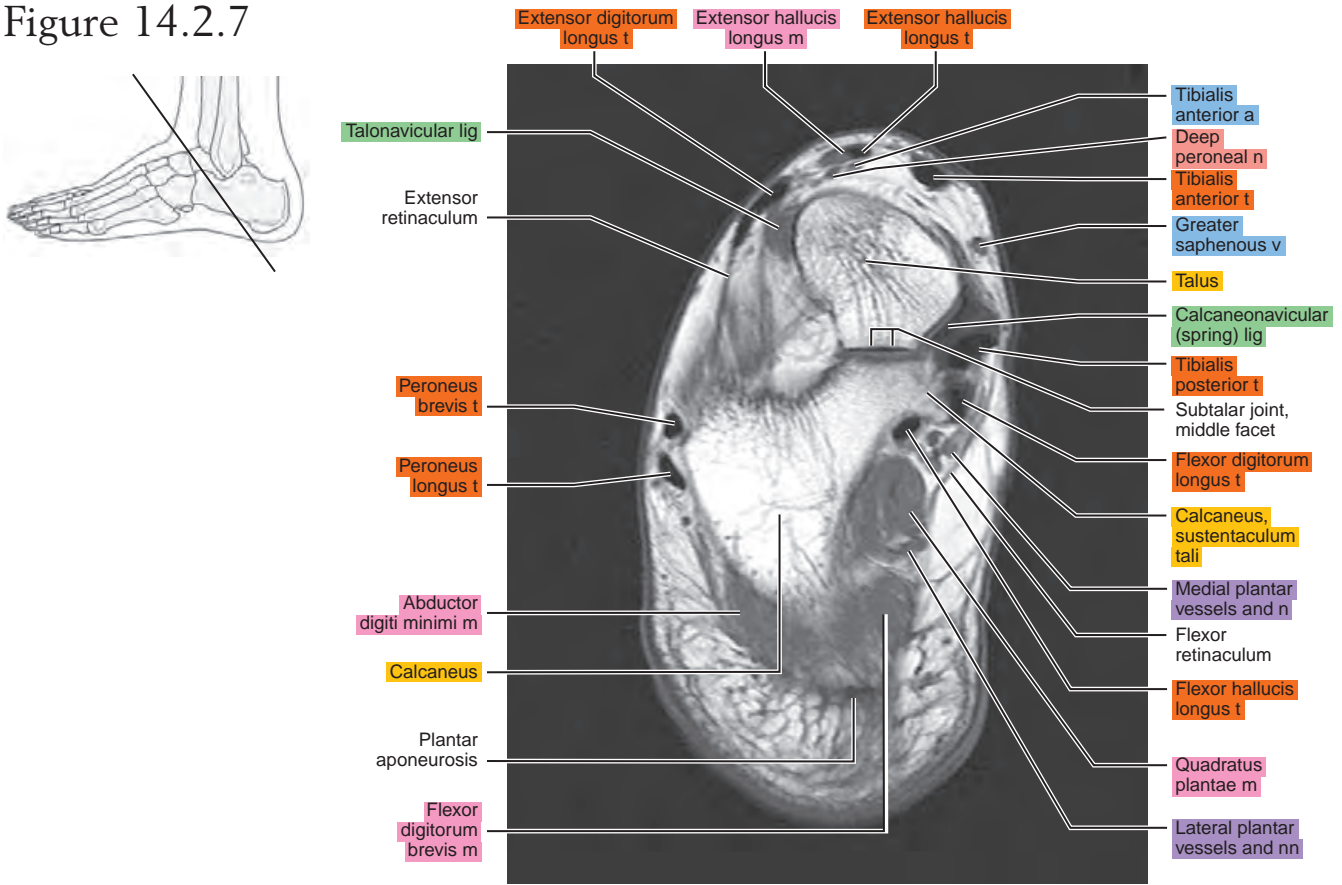


Figure 14.2.8

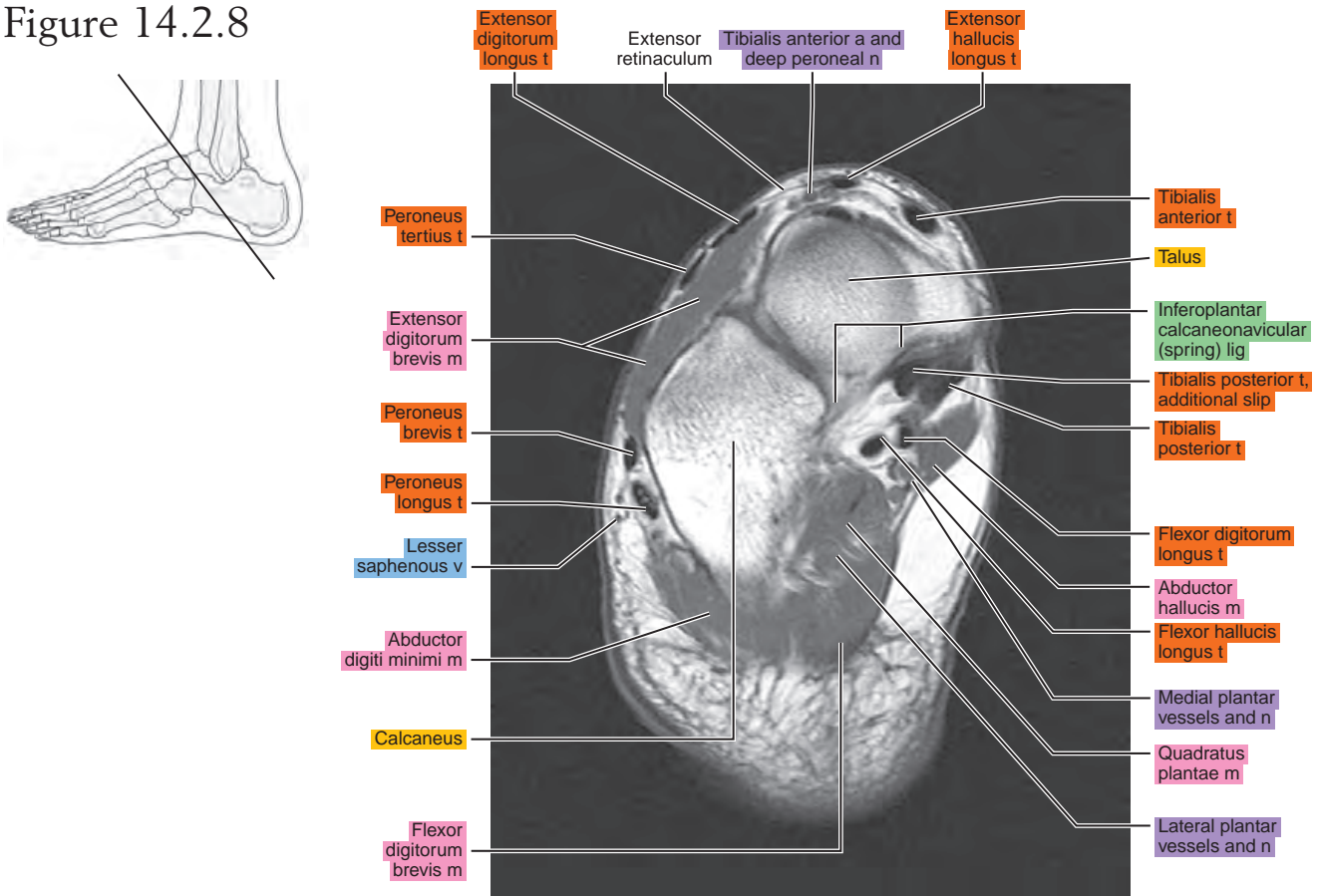


Figure 14.2.9

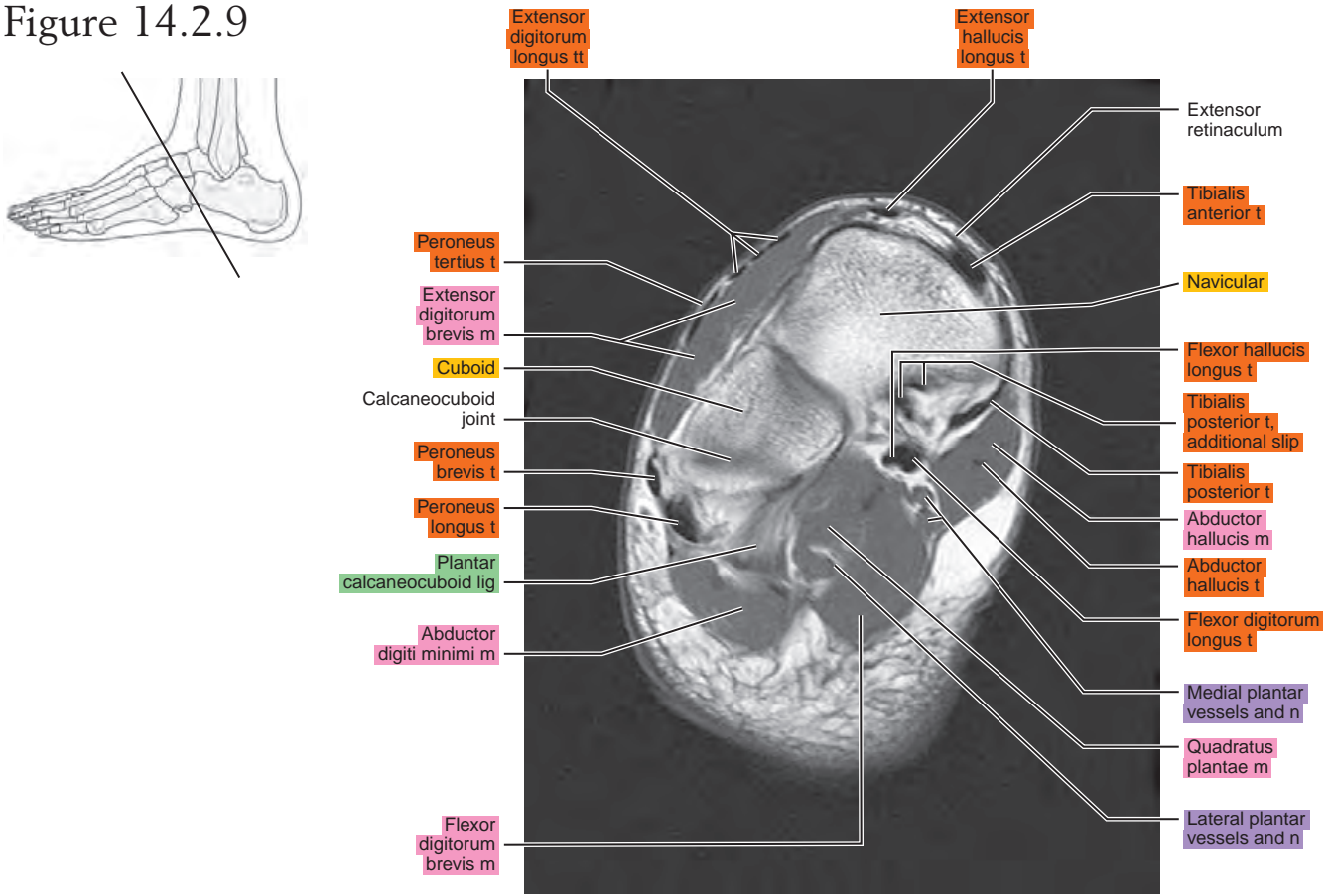


Figure 14.2.10

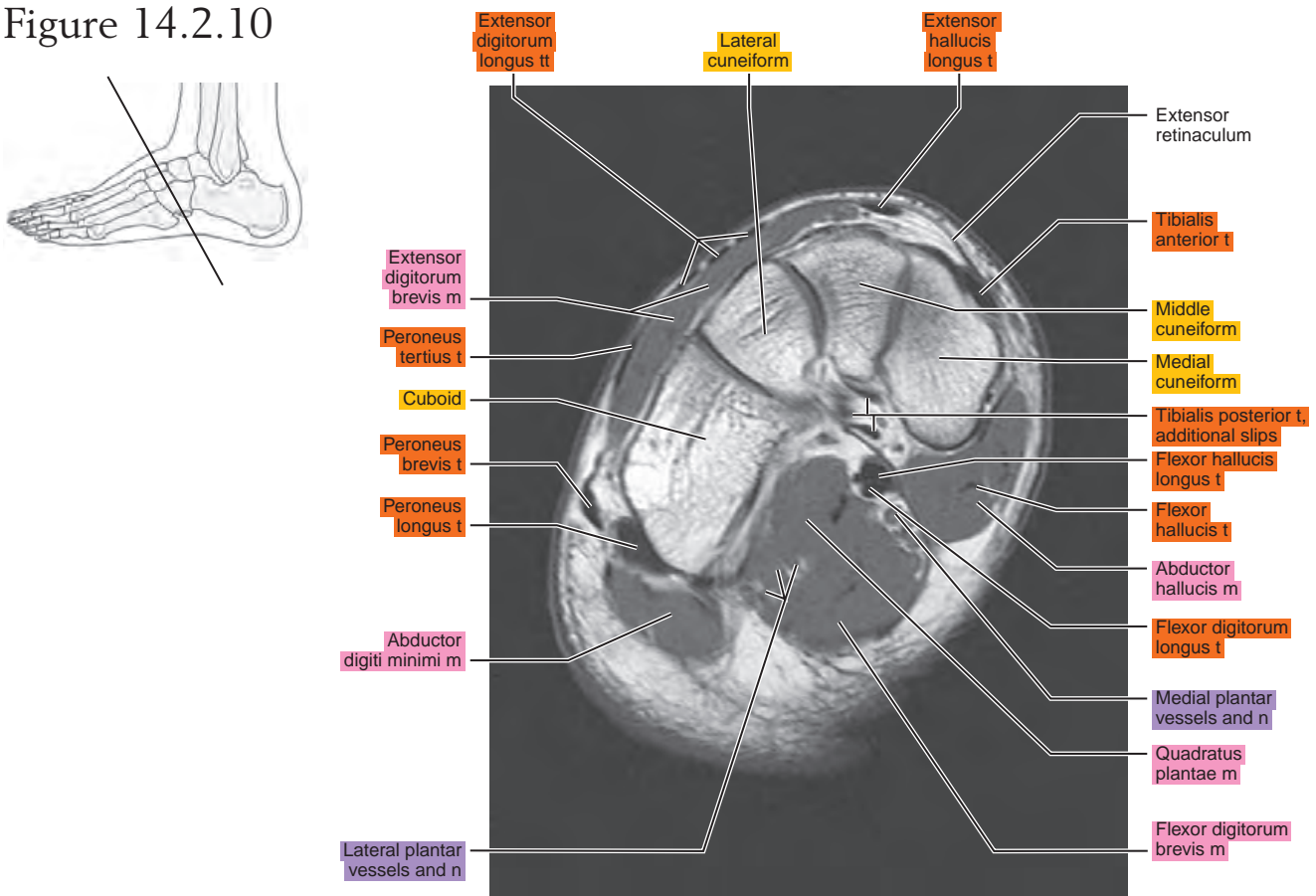
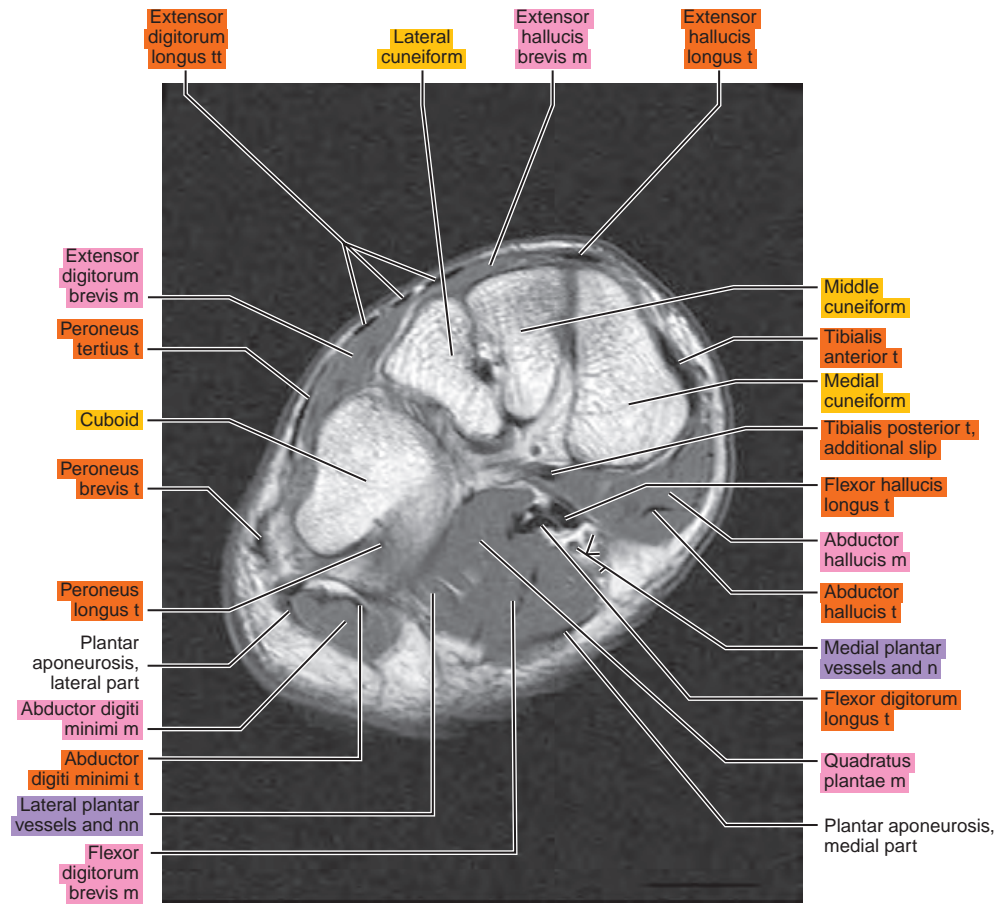
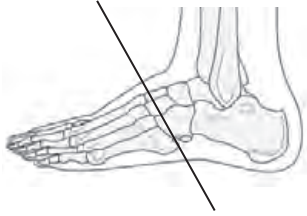

Figure 14.2.11



SAGITTAL

Figure 14.3.1

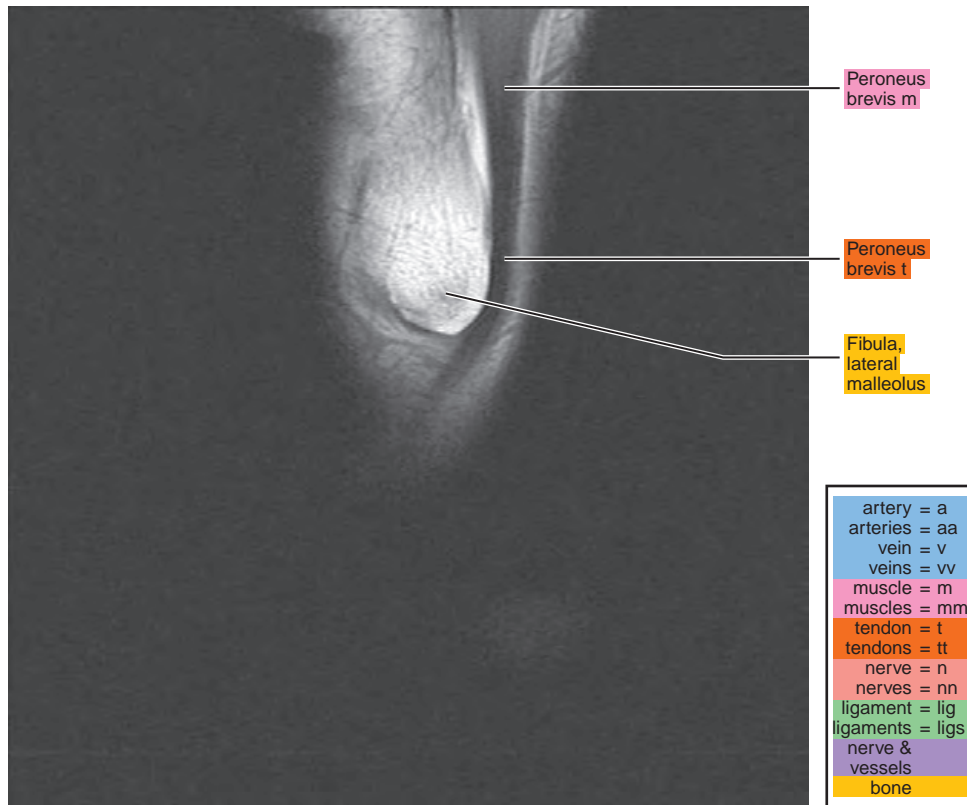
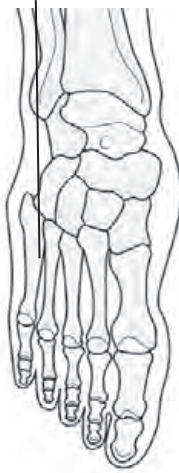

Figure 14.3.2

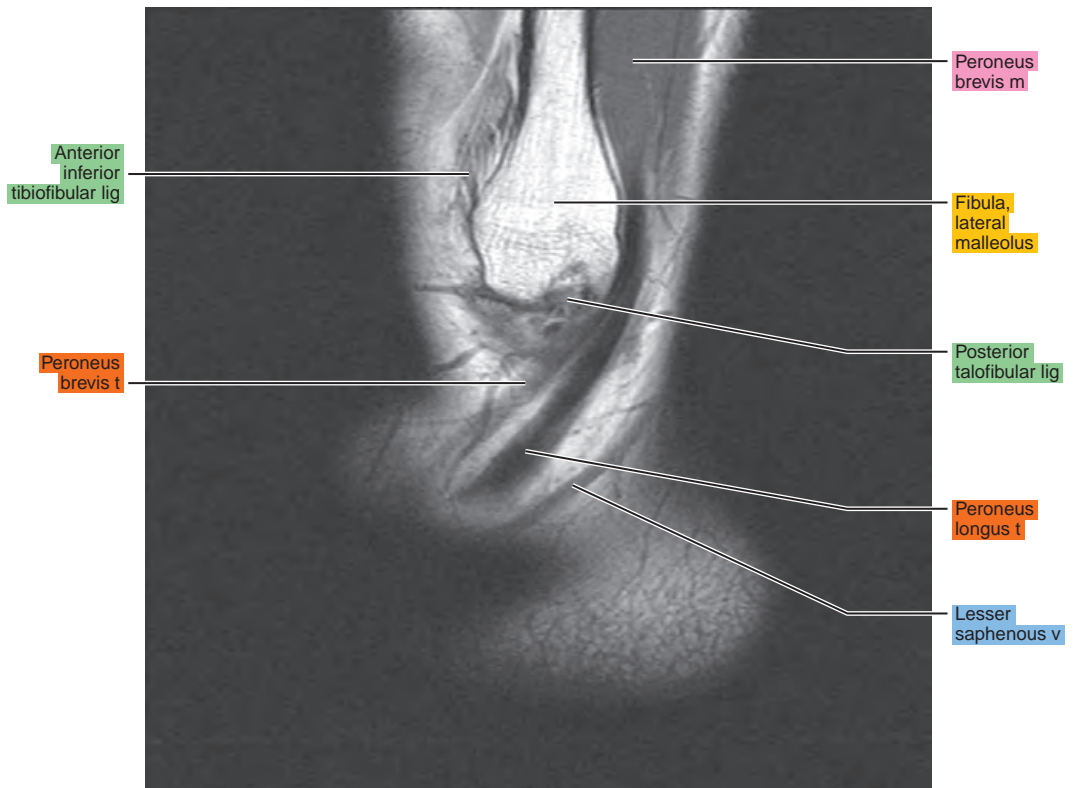
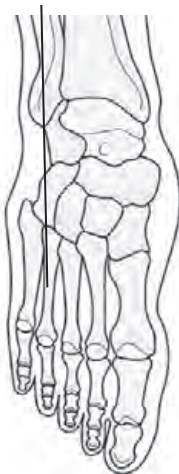

Figure 14.3.3

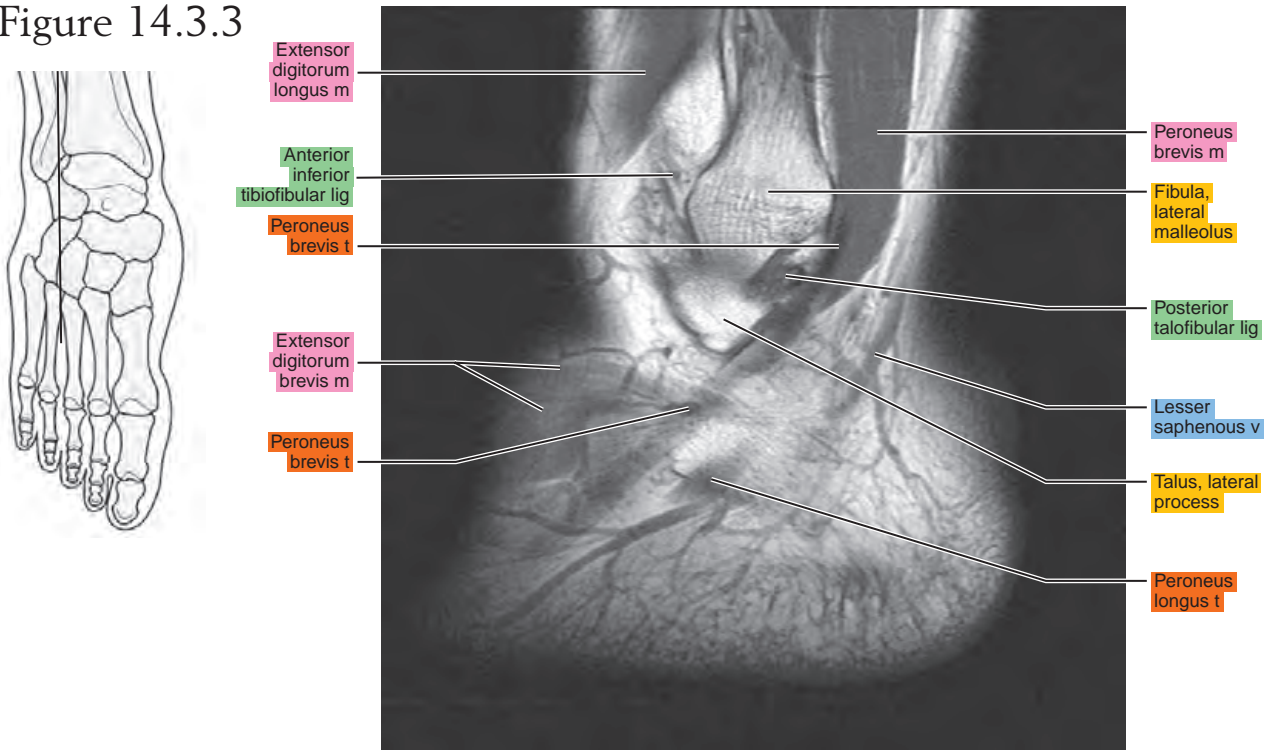


Figure 14.3.4

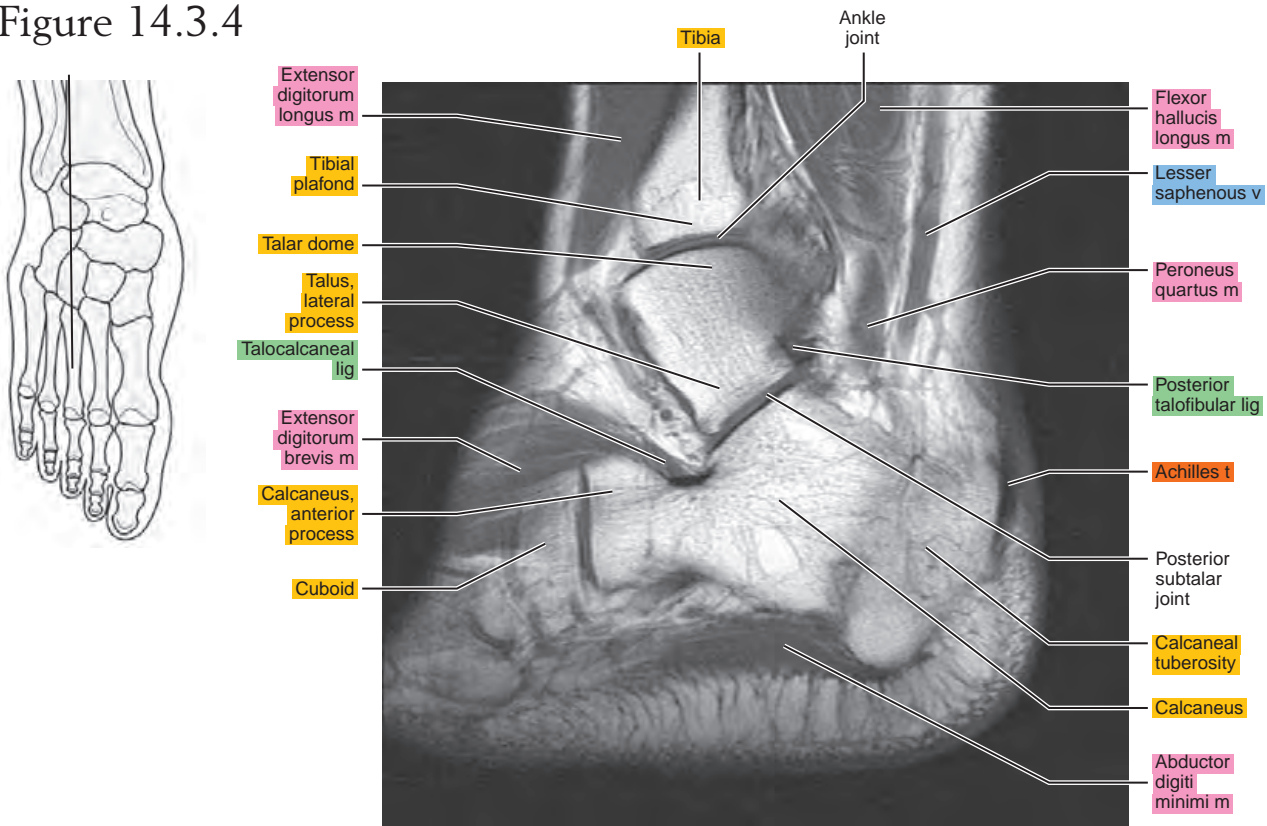


Figure 14.3.5

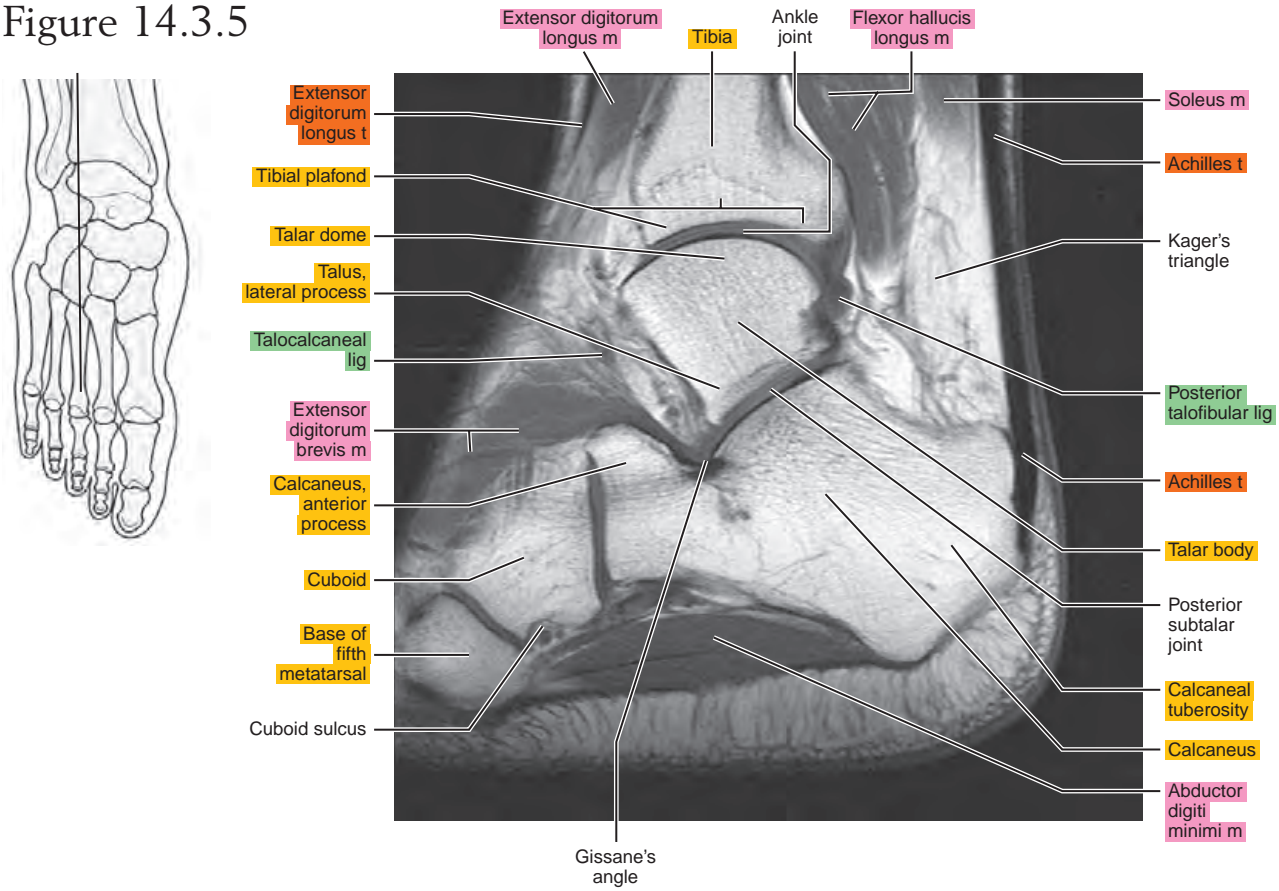


Figure 14.3.6

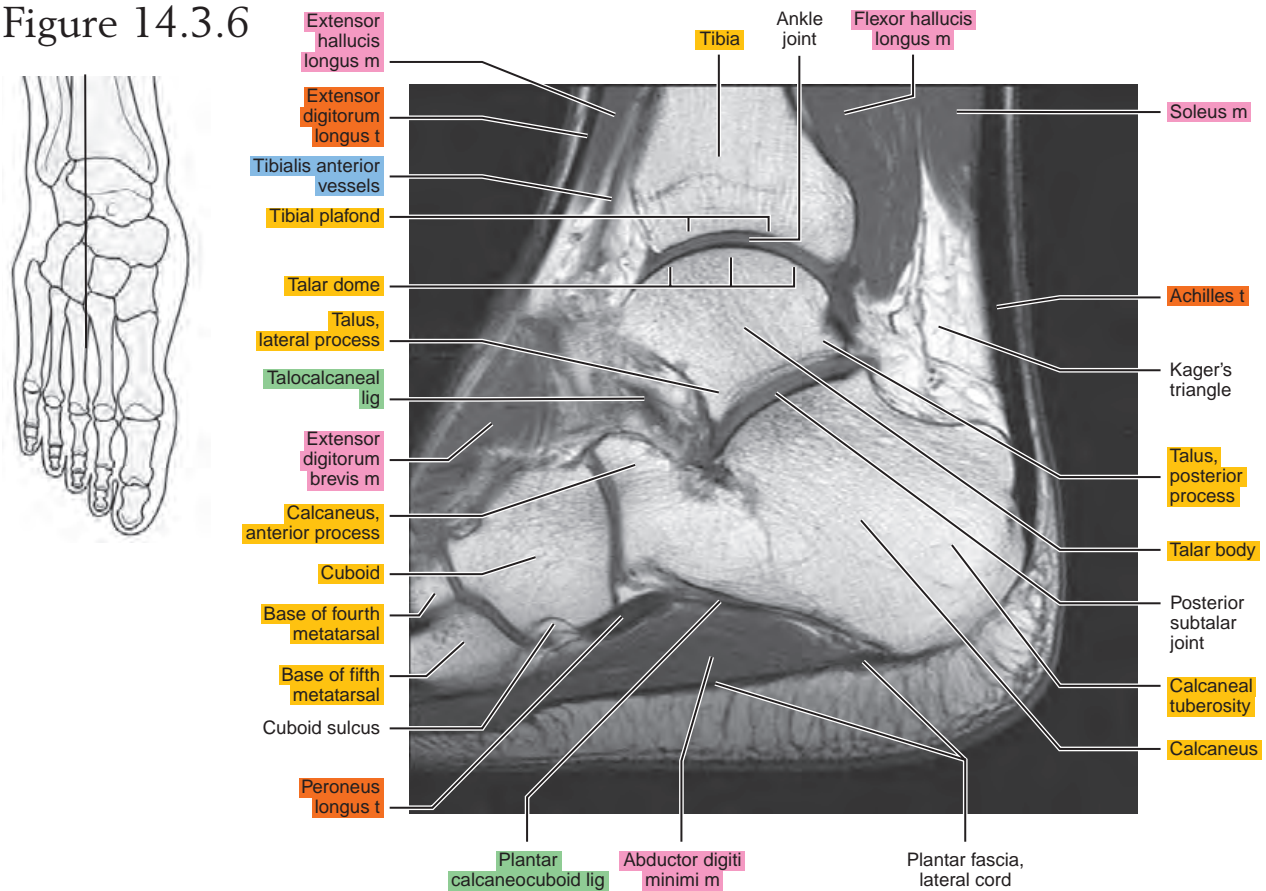


Figure 14.3.7

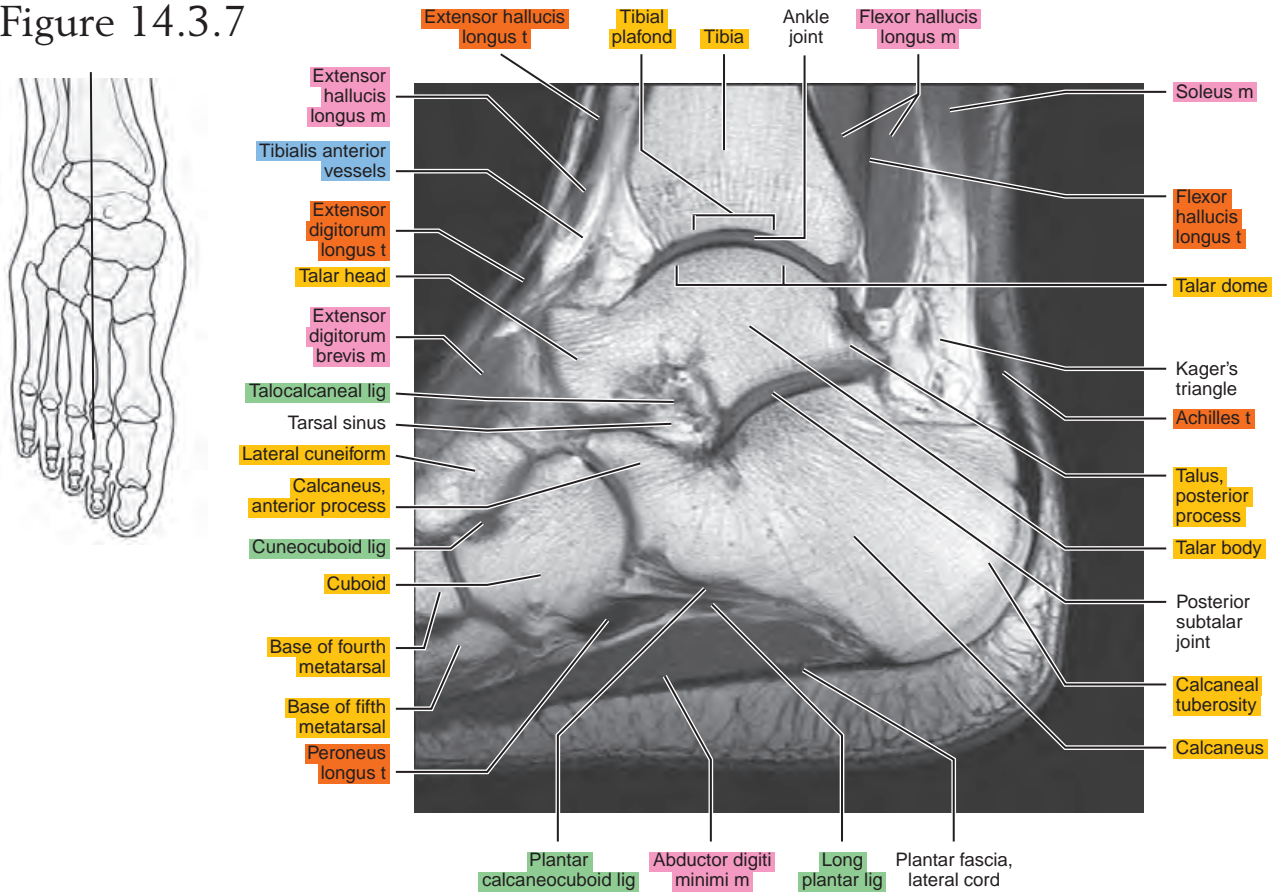


Figure 14.3.8

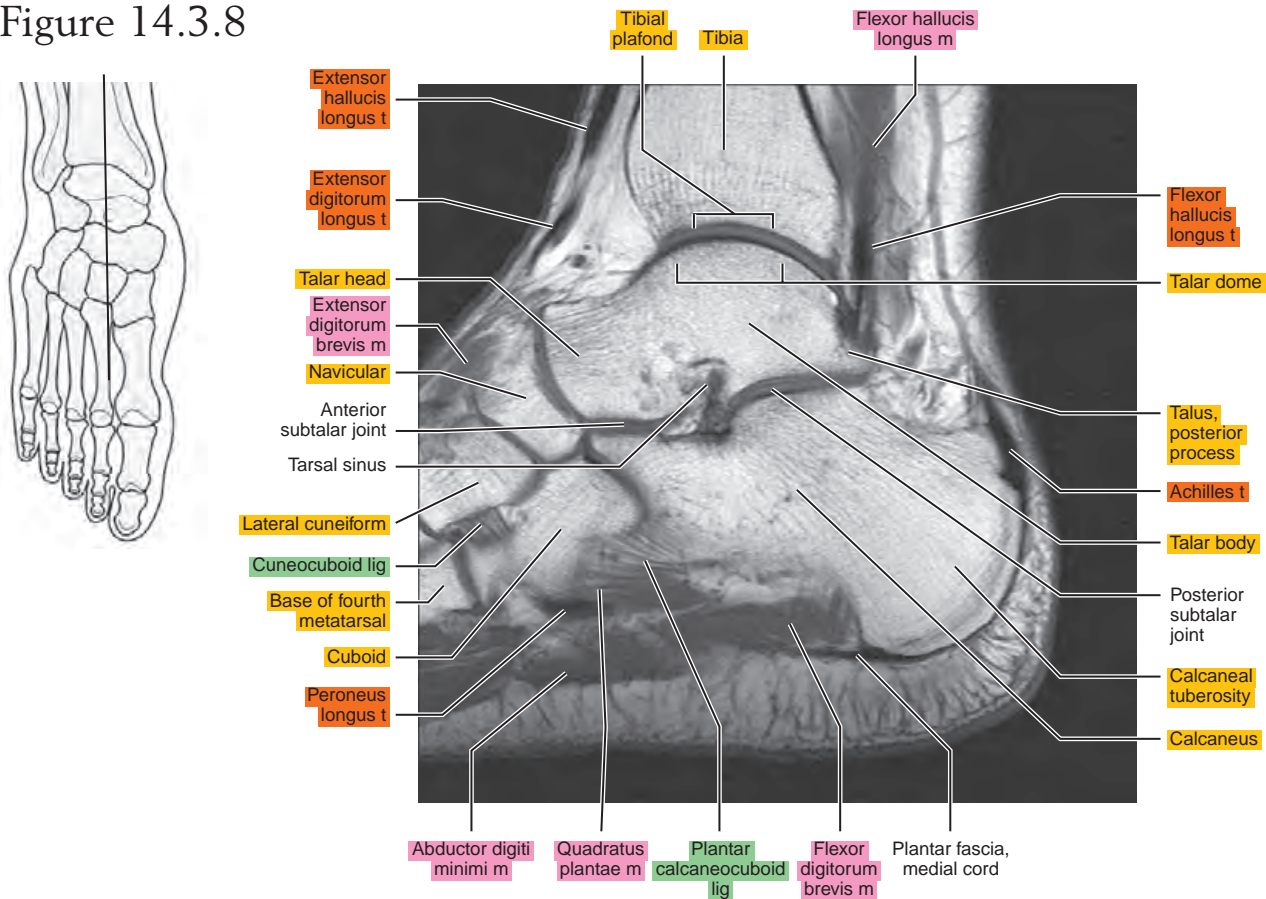


Figure 14.3.9

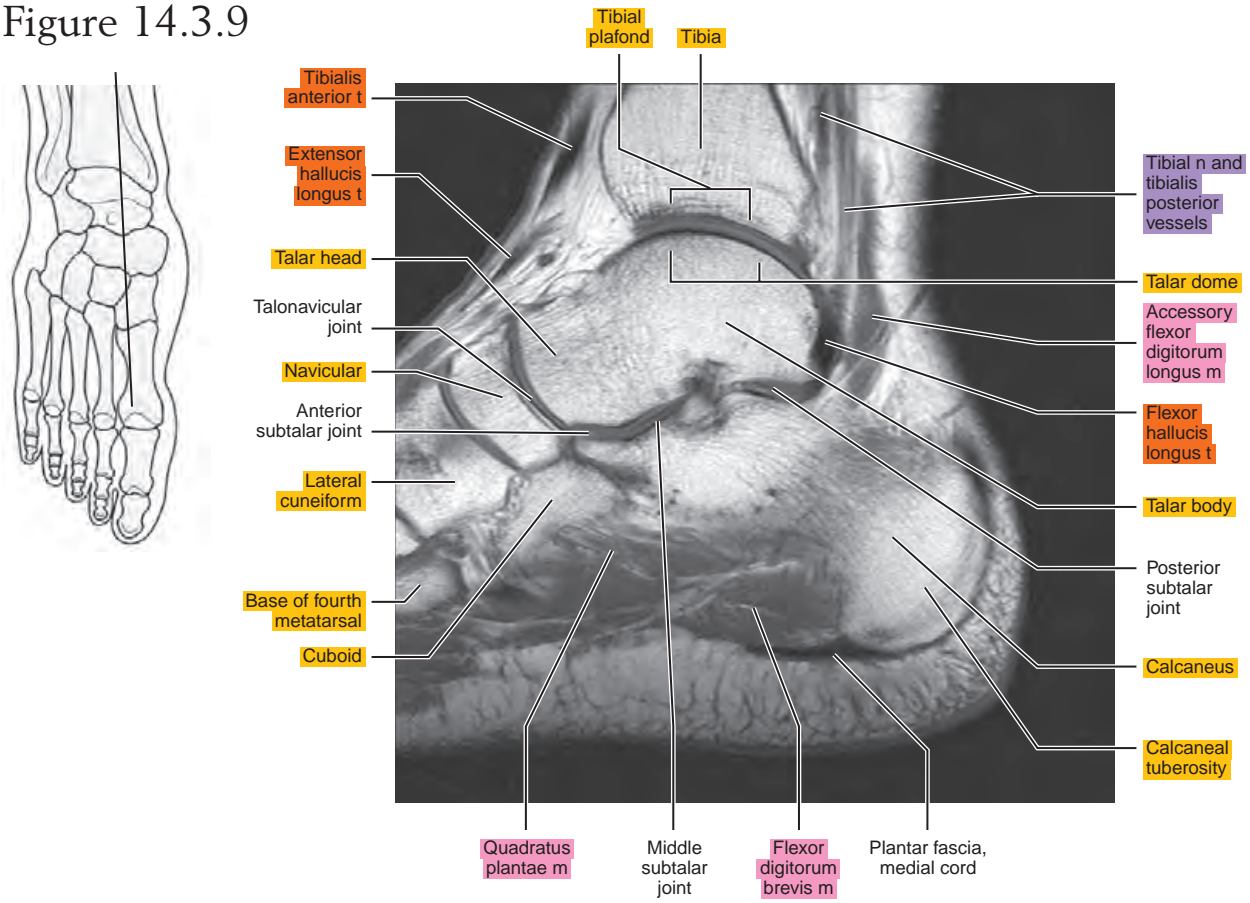


Figure 14.3.10

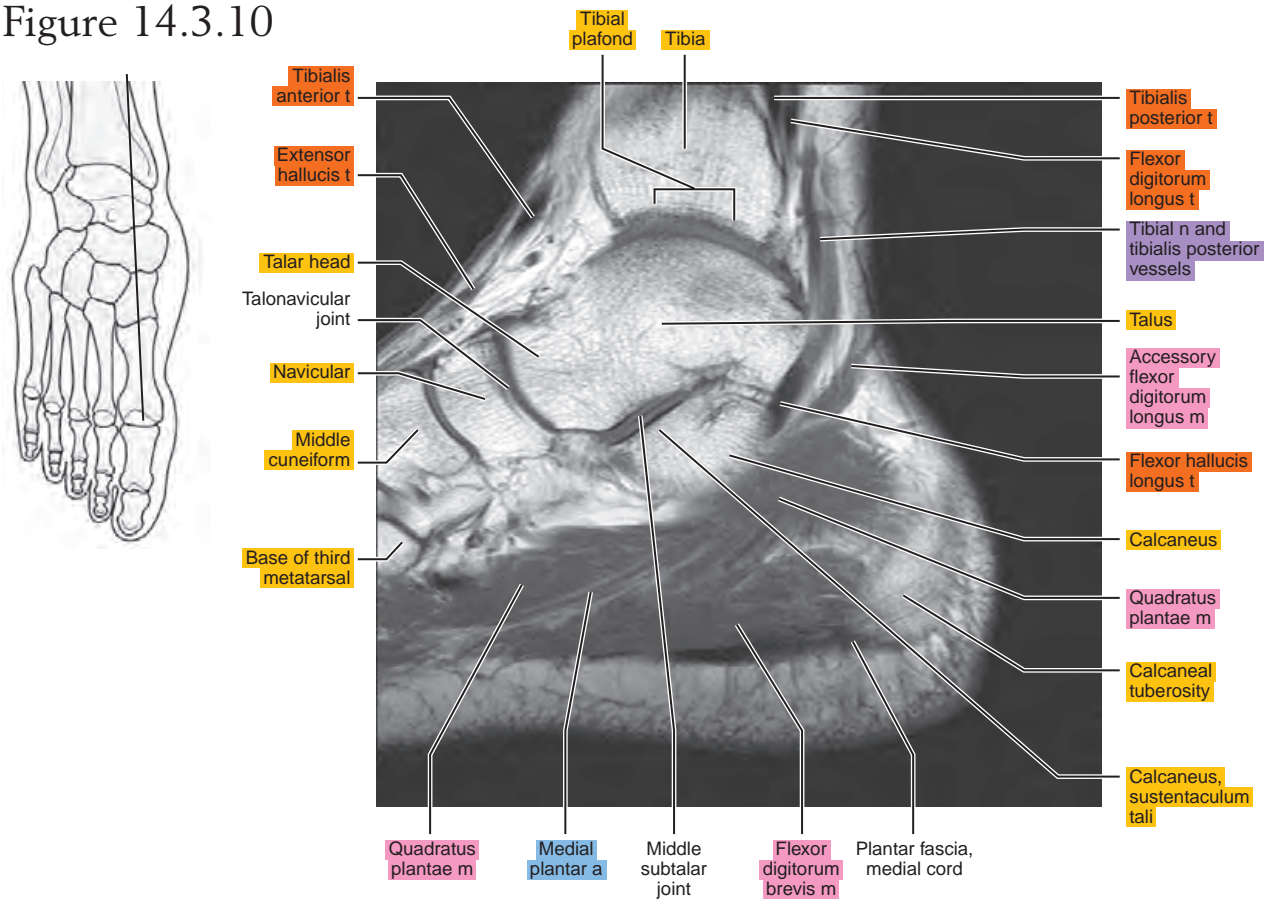


Figure 14.3.11

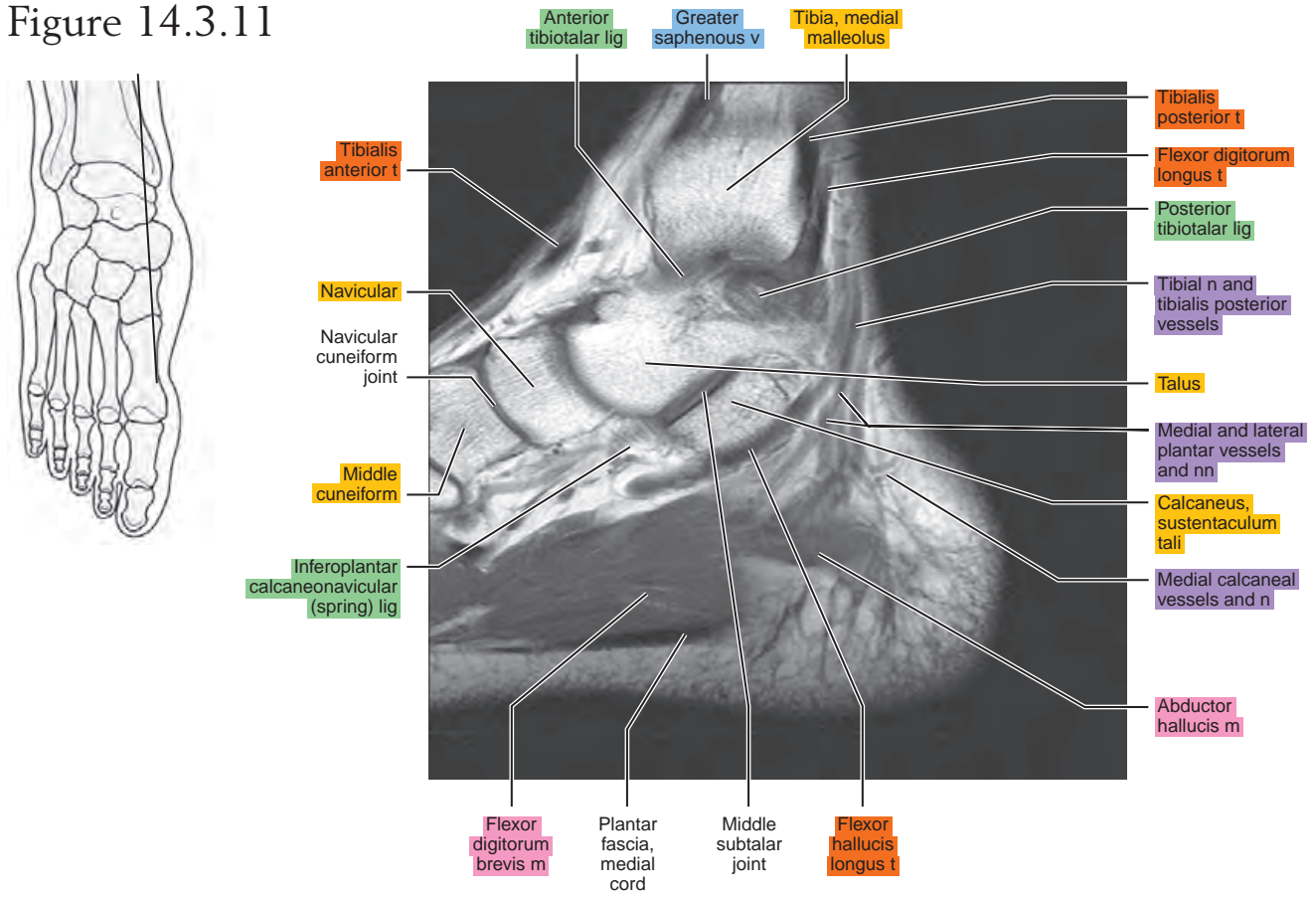


Figure 14.3.12

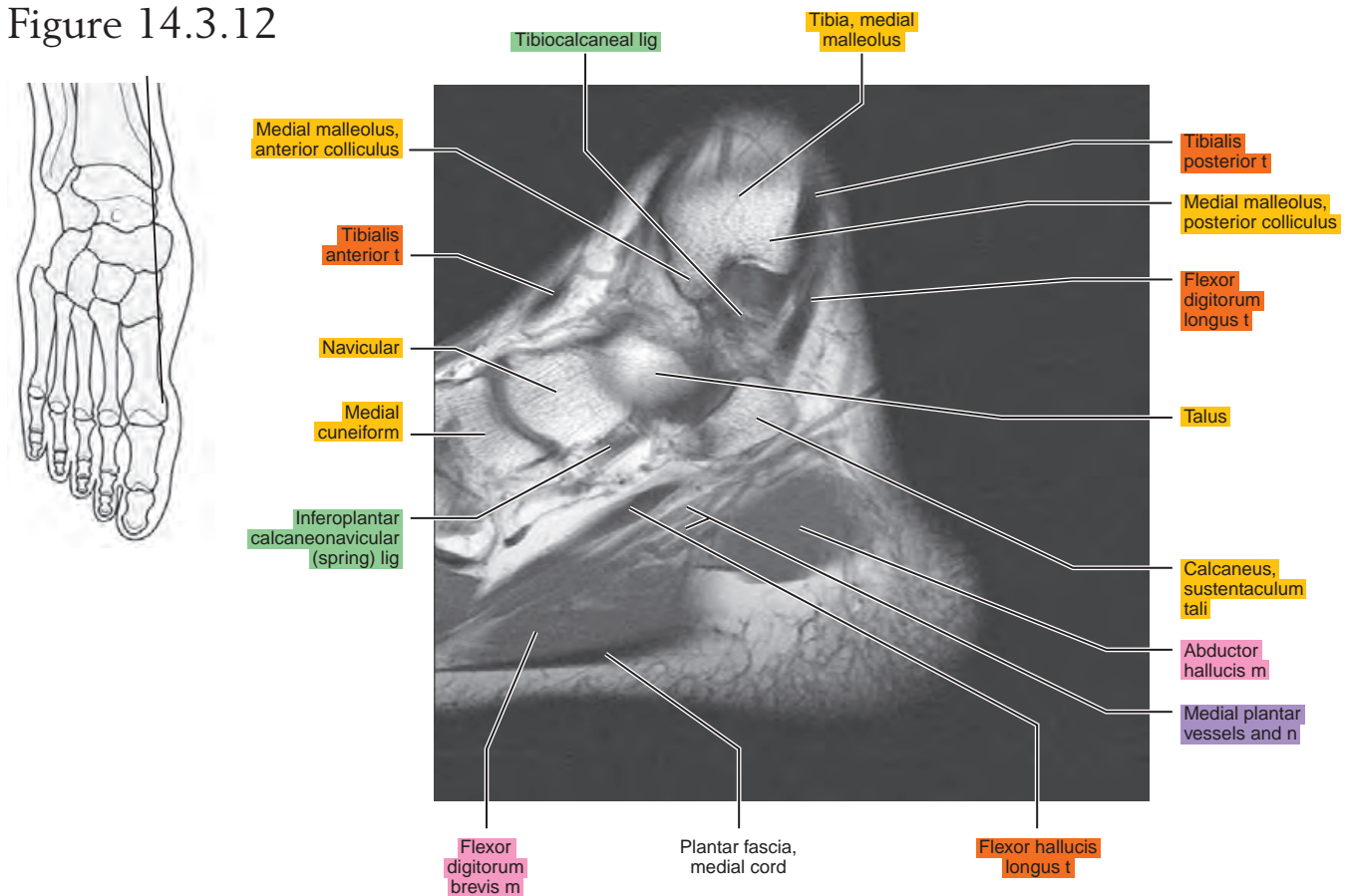
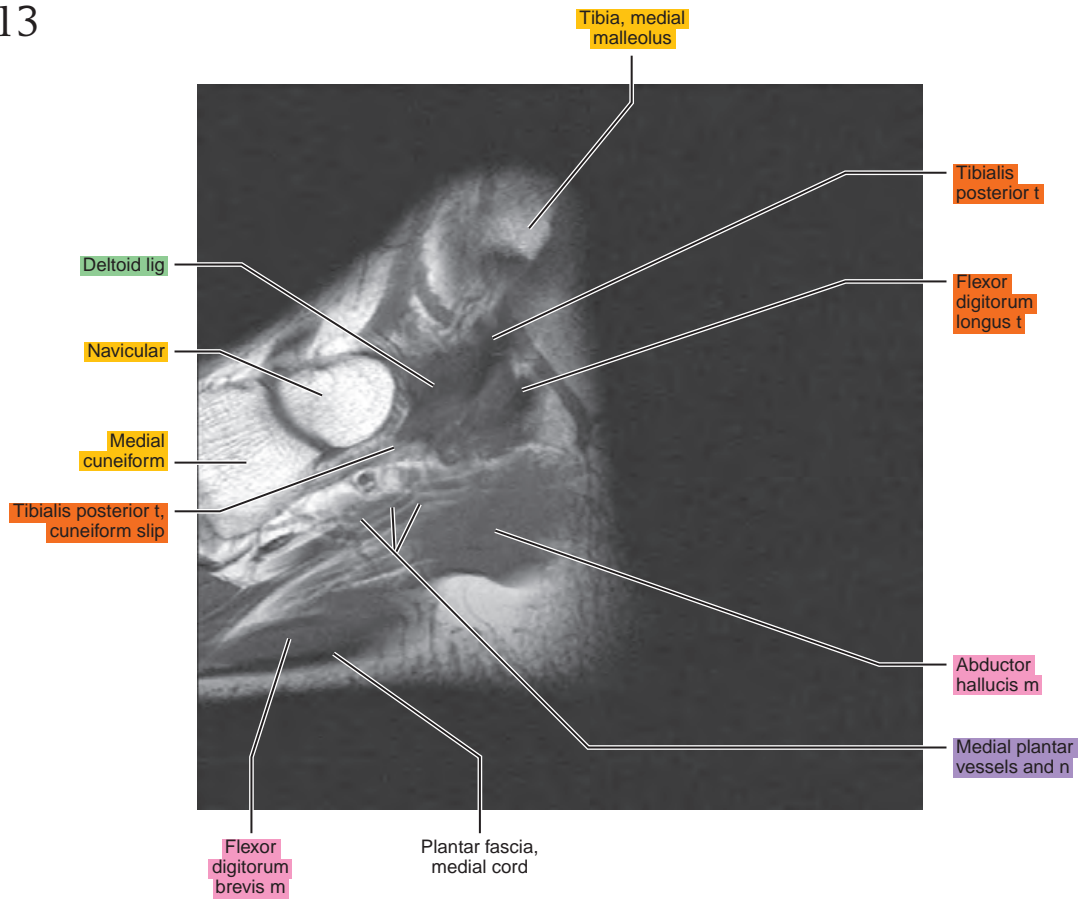
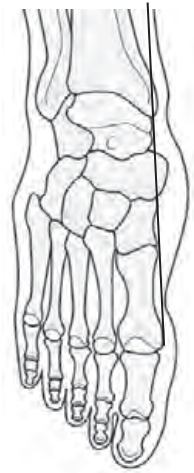

Figure 14.3.13



CORONAL

Figure 14.4.1

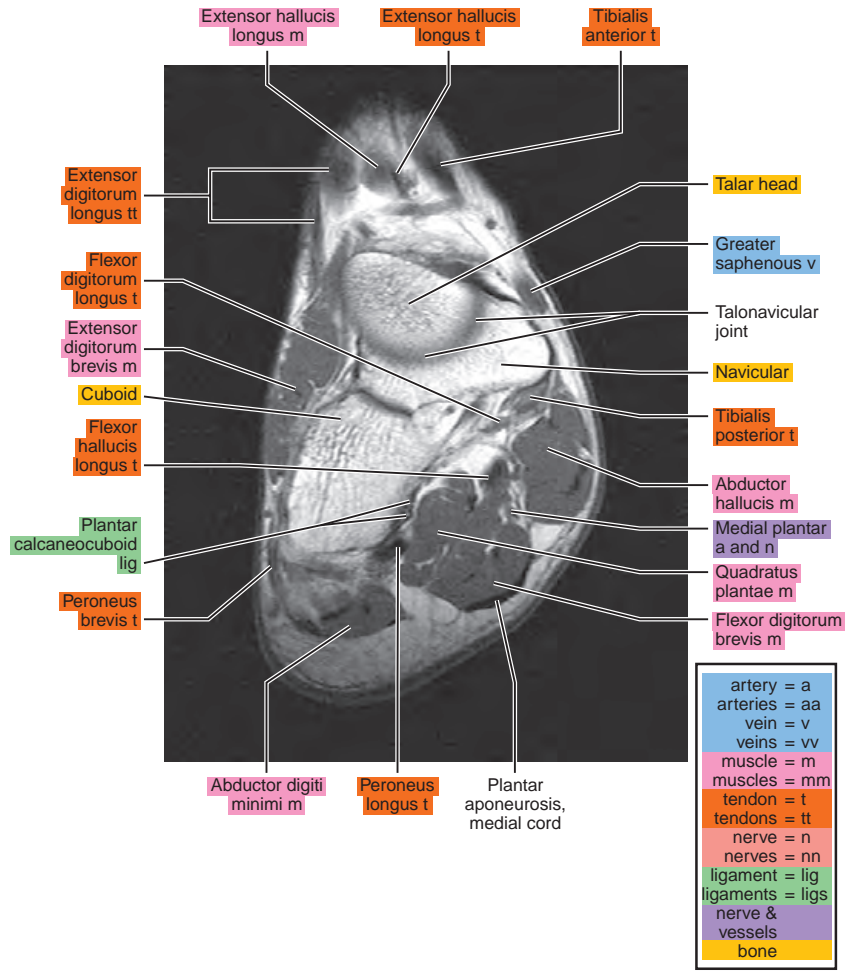
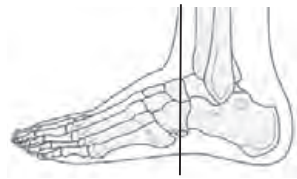

Figure 14.4.2

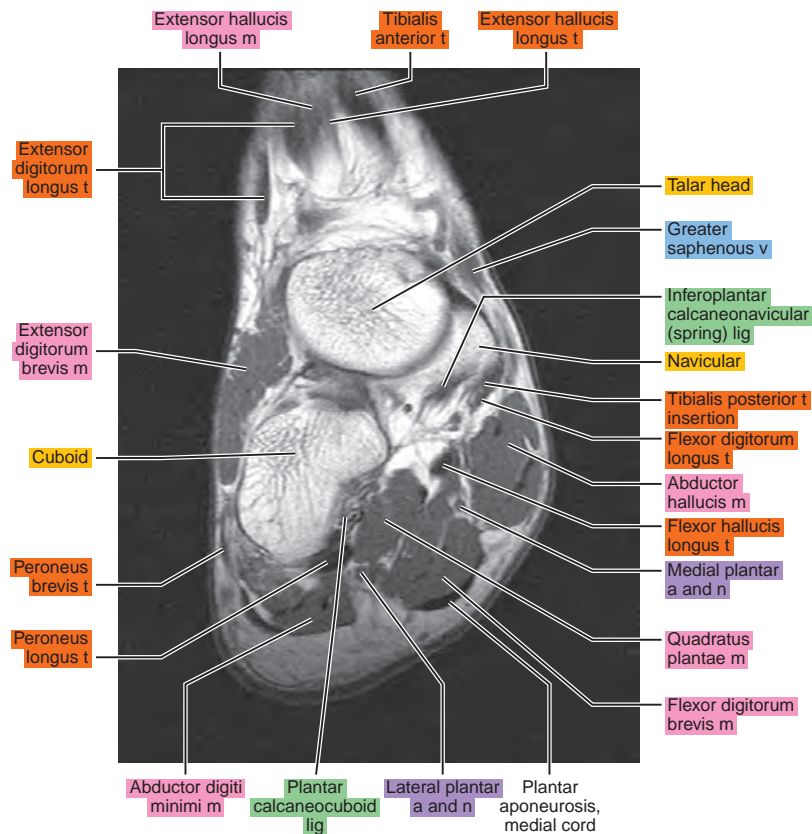
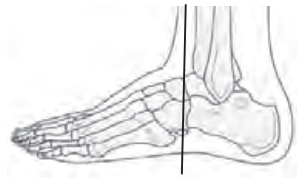

Figure 14.4.3

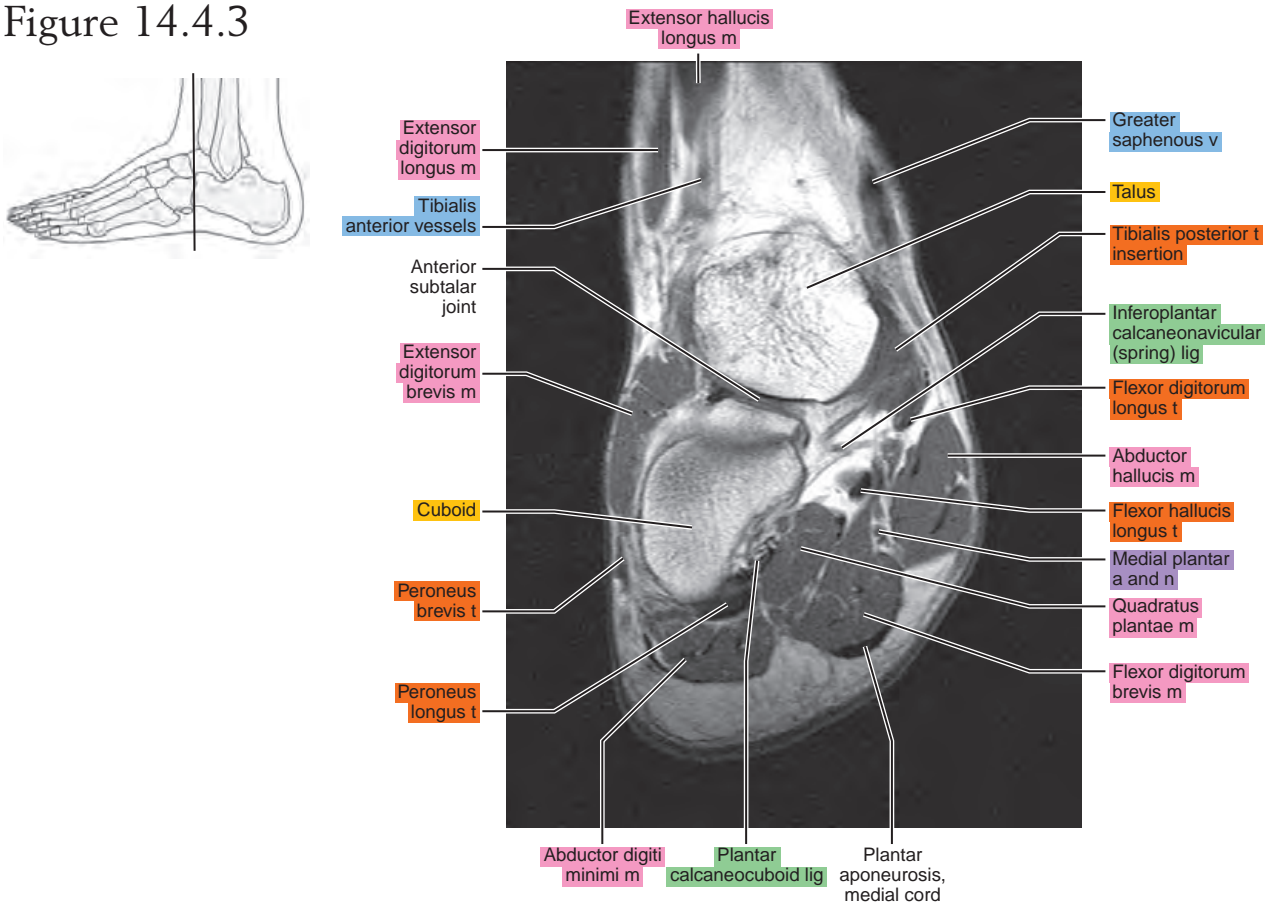


Figure 14.4.4

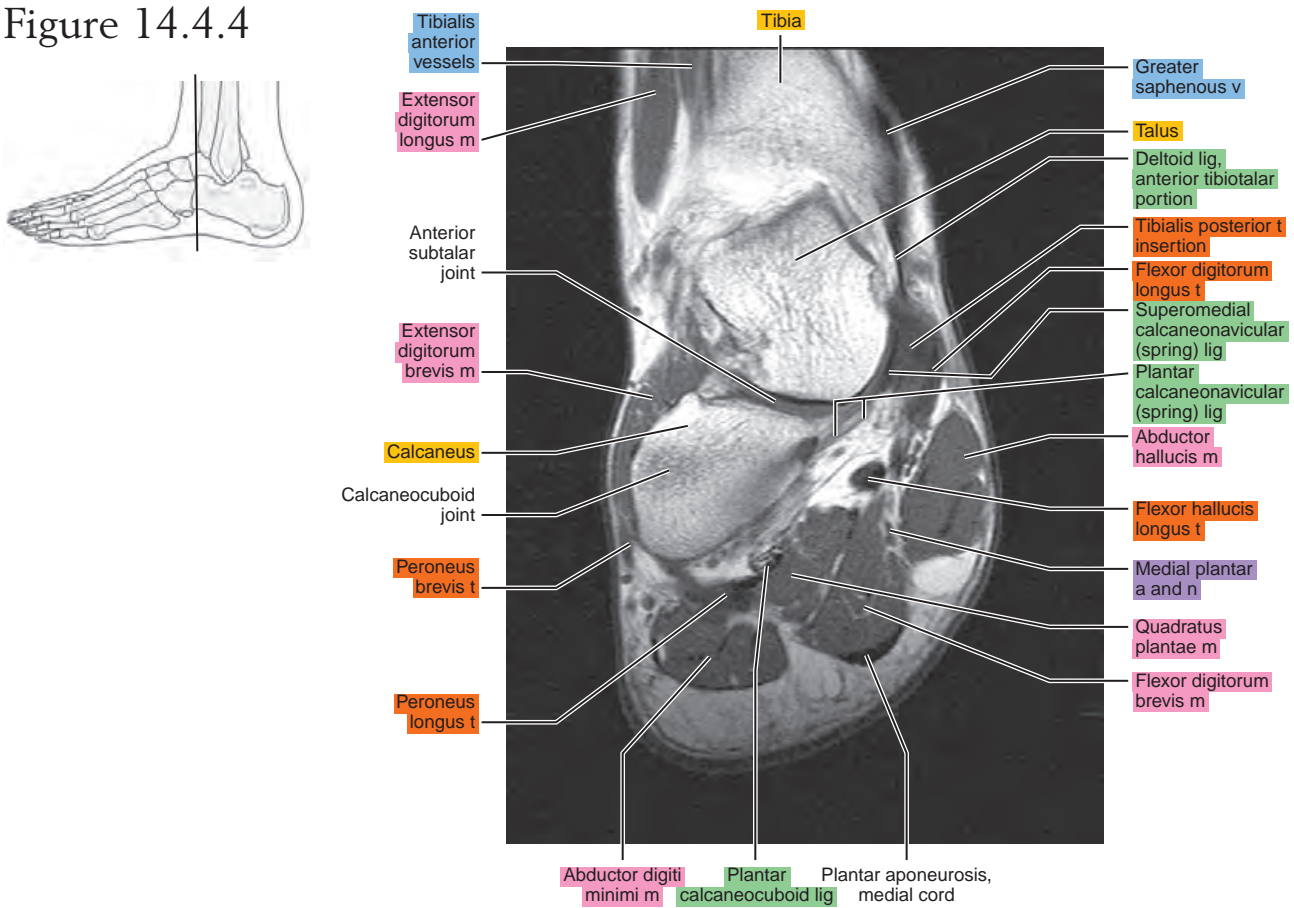


Figure 14.4.5

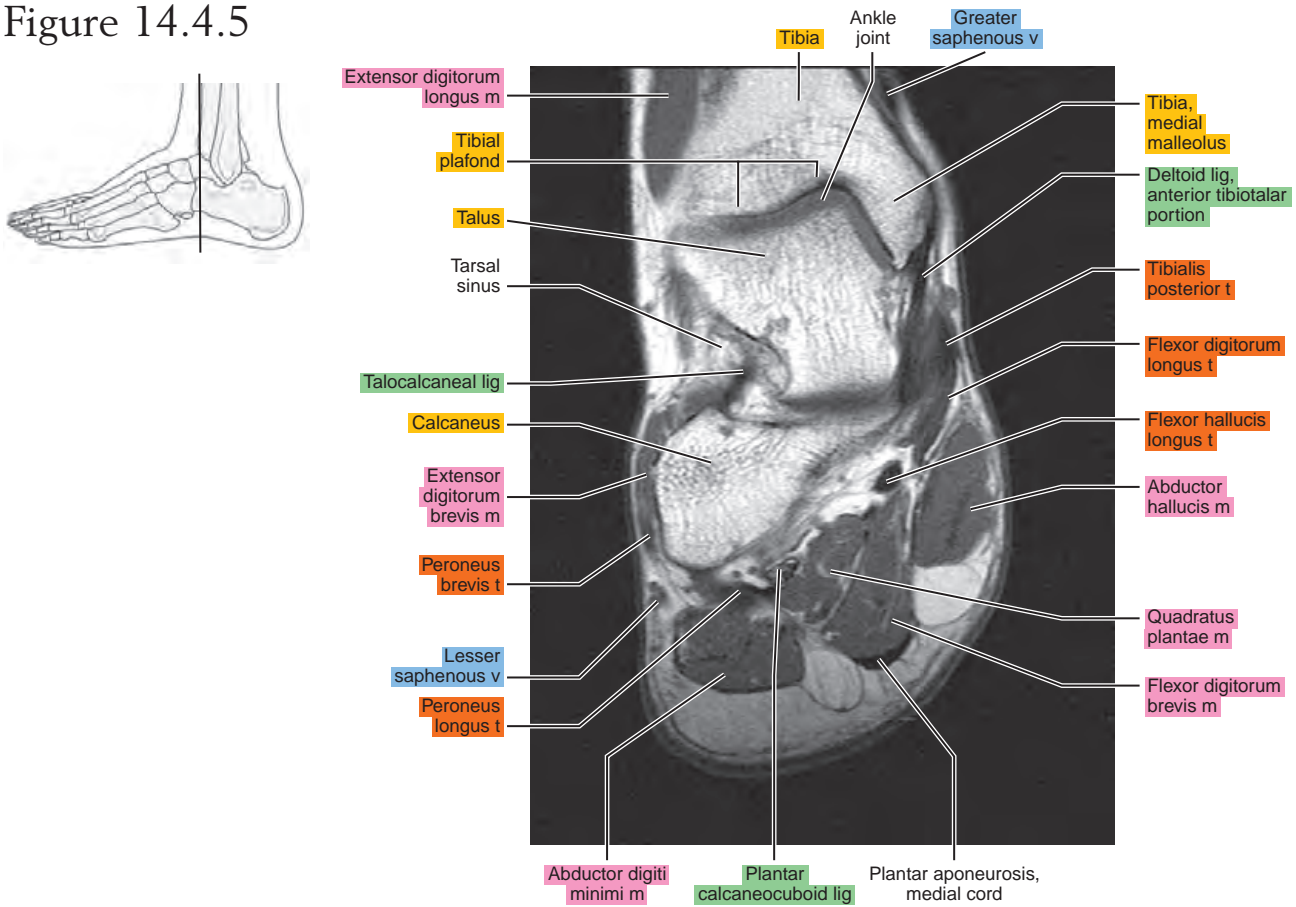


Figure 14.4.6

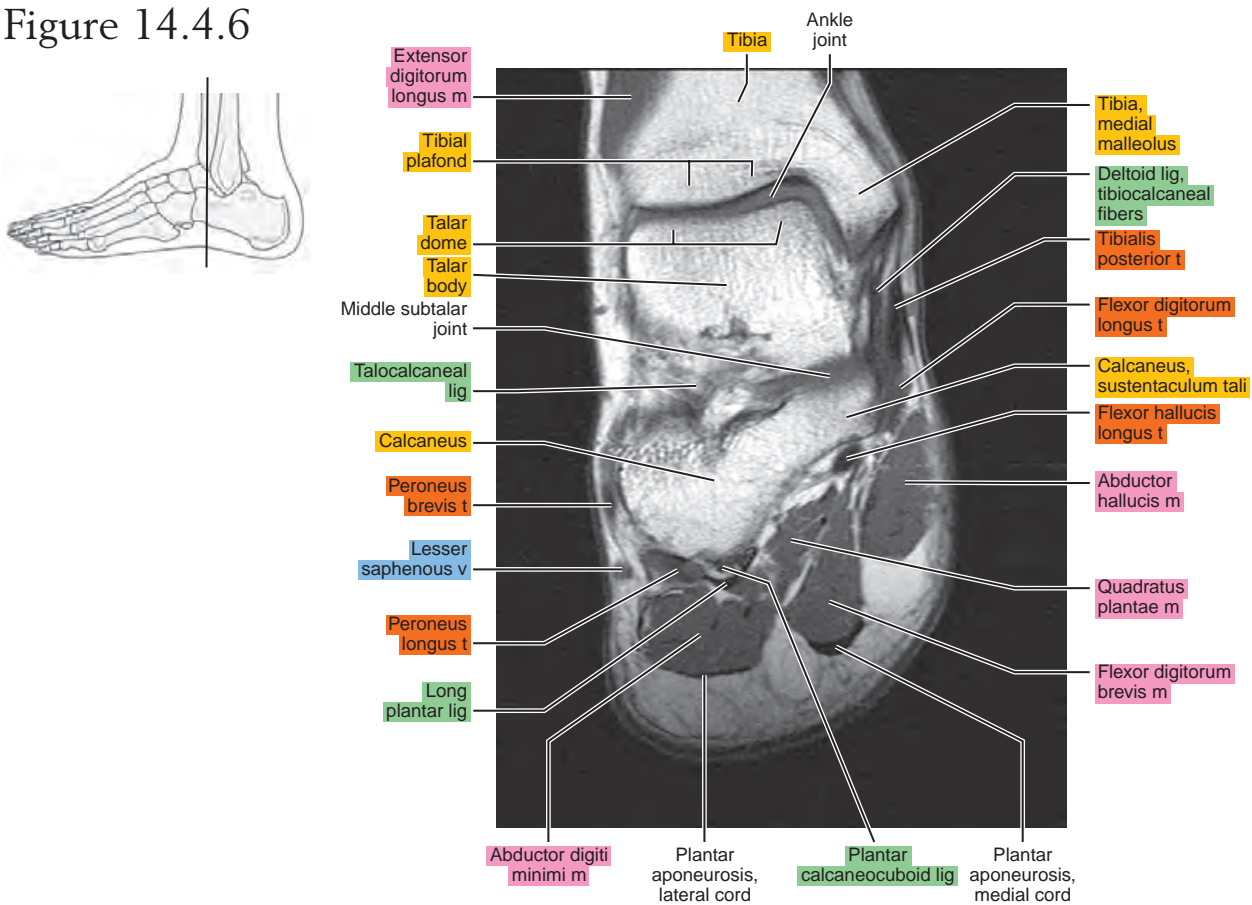


Figure 14.4.7

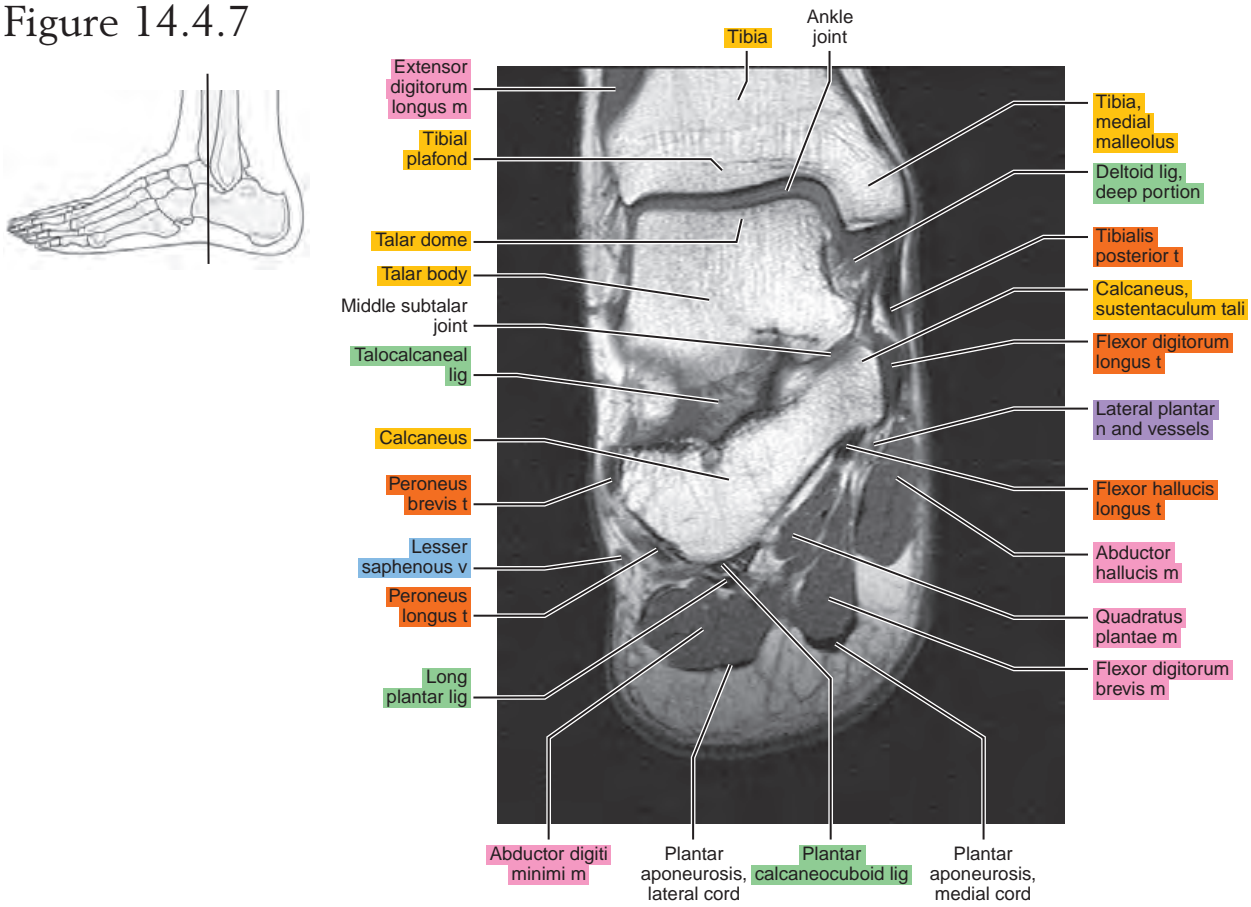


Figure 14.4.8

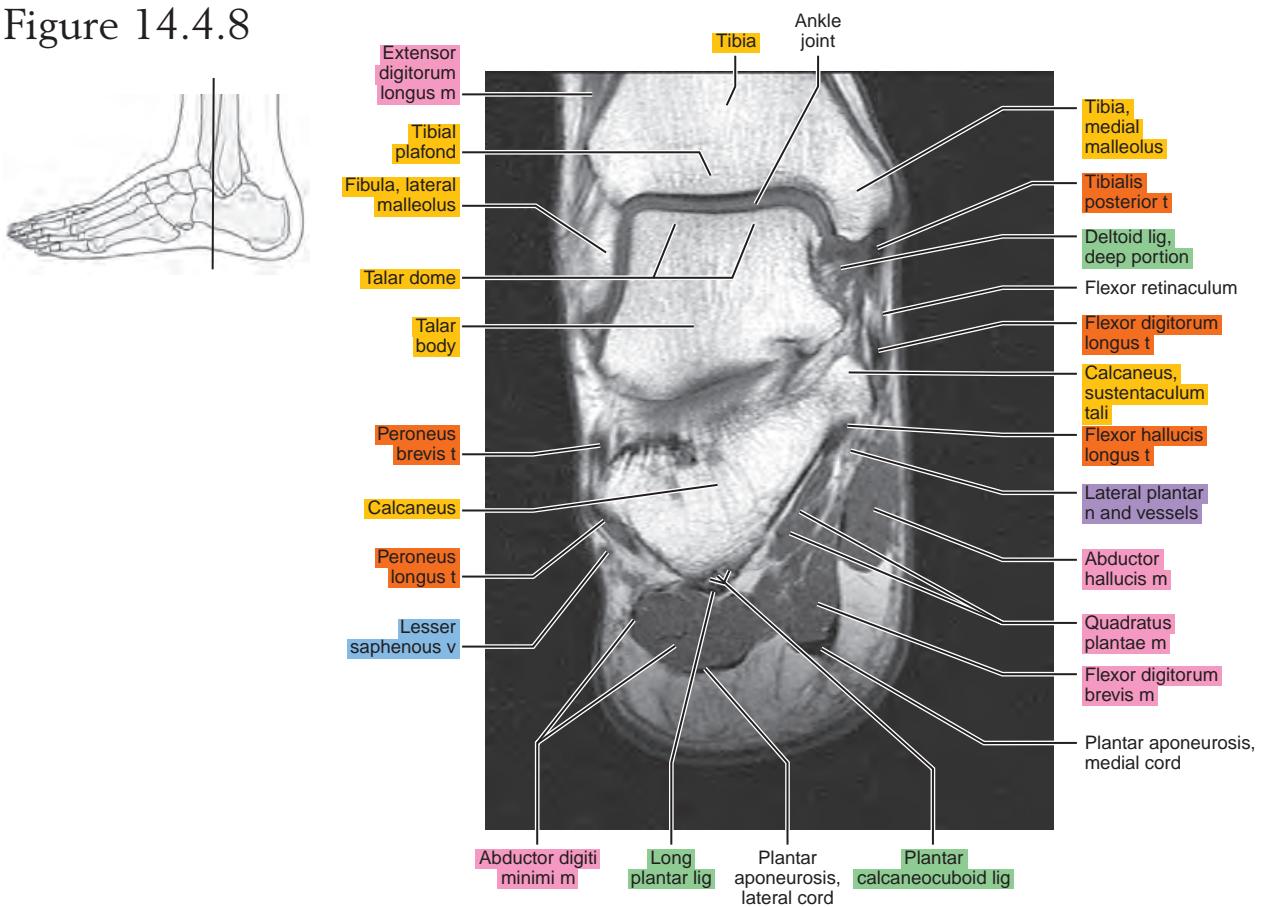


Figure 14.4.9

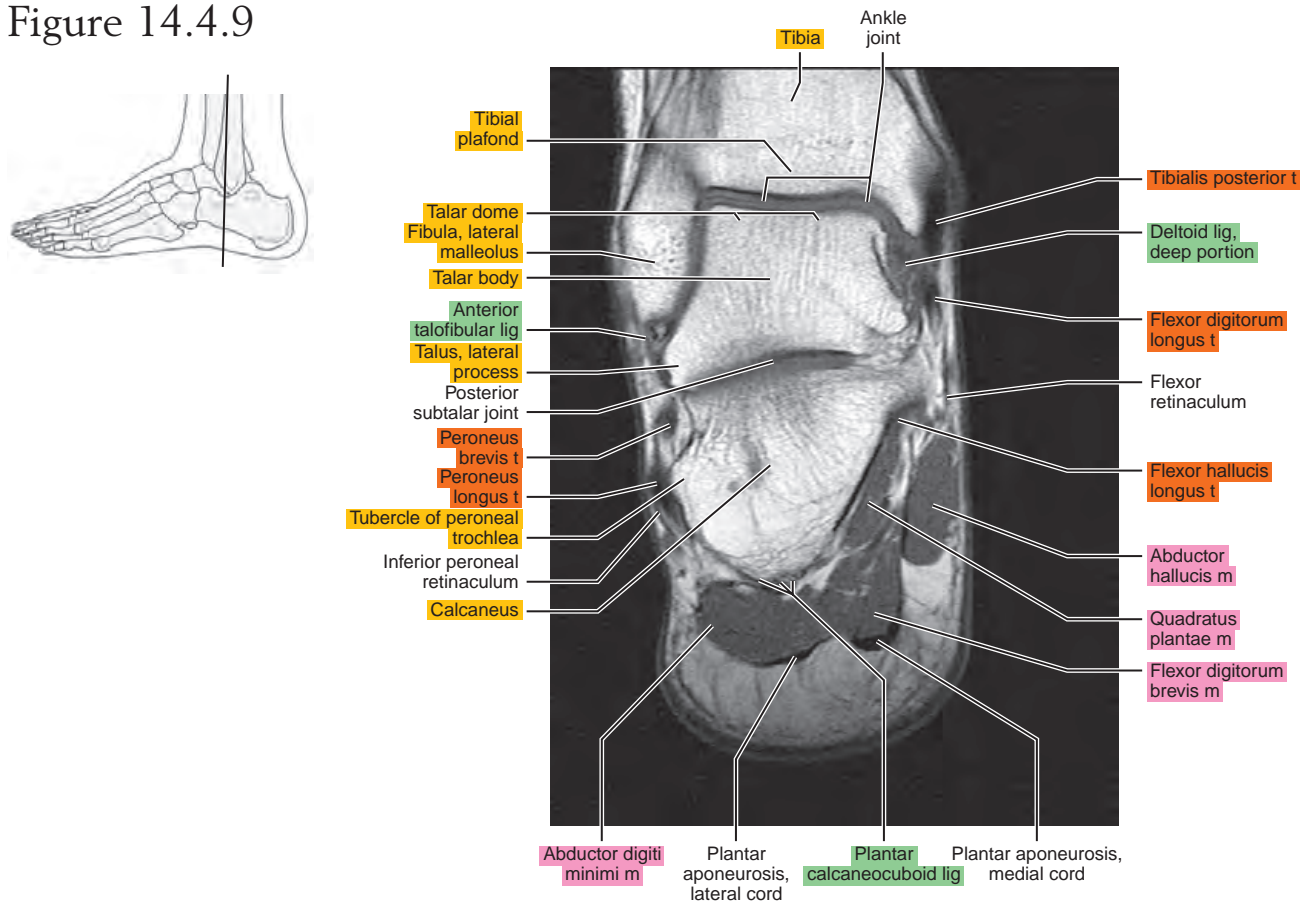


Figure 14.4.10

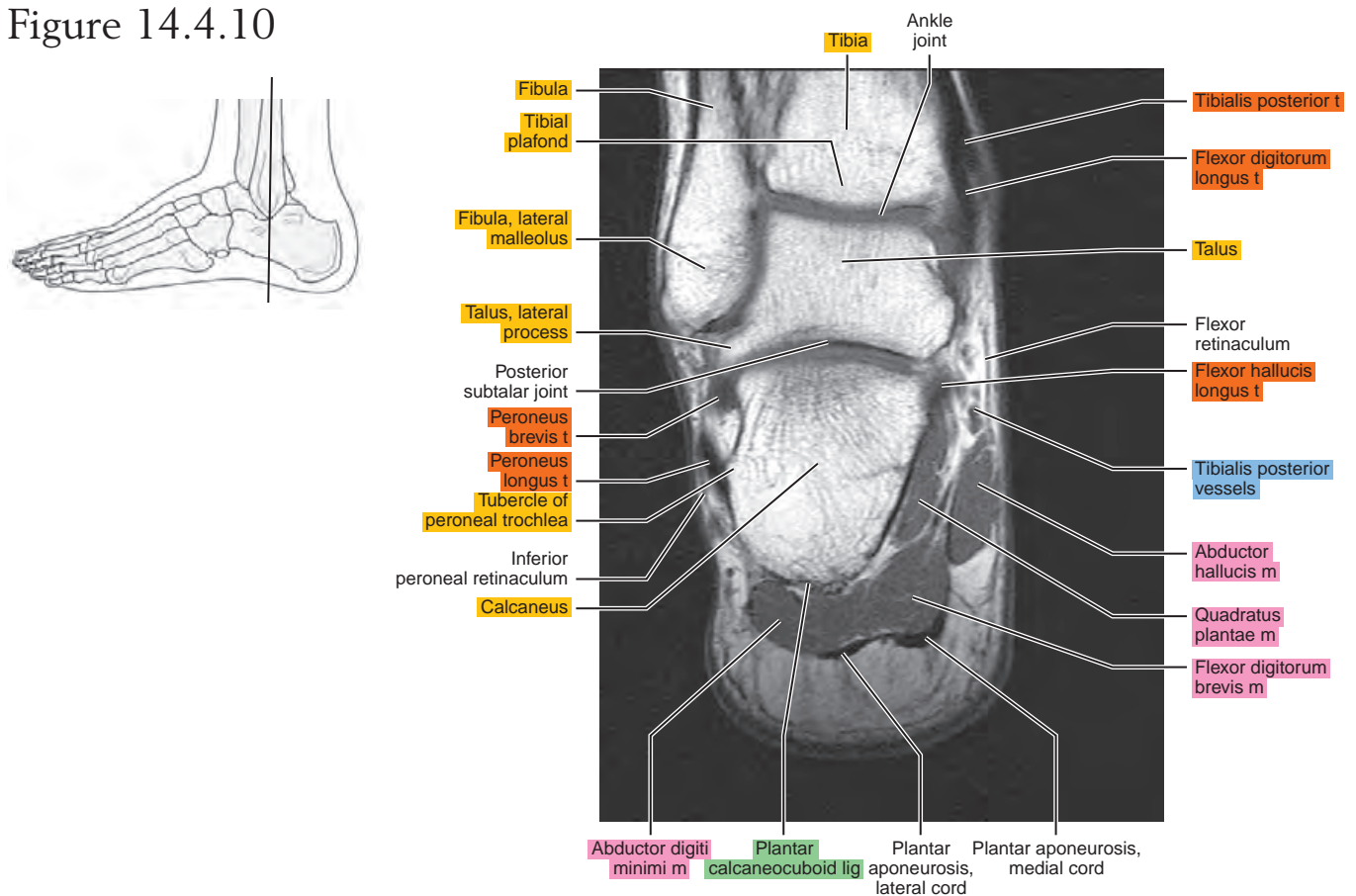


Figure 14.4.11

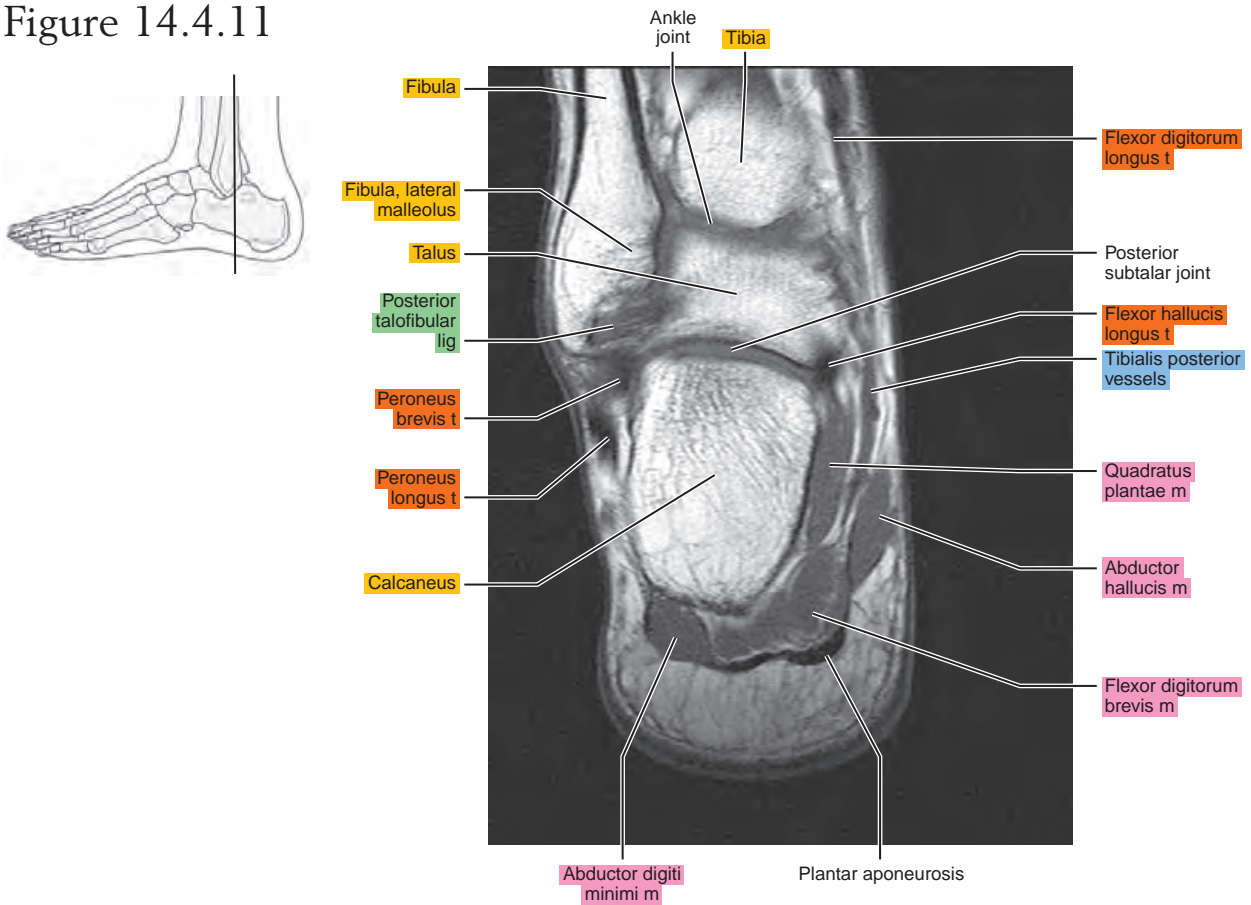


Figure 14.4.12

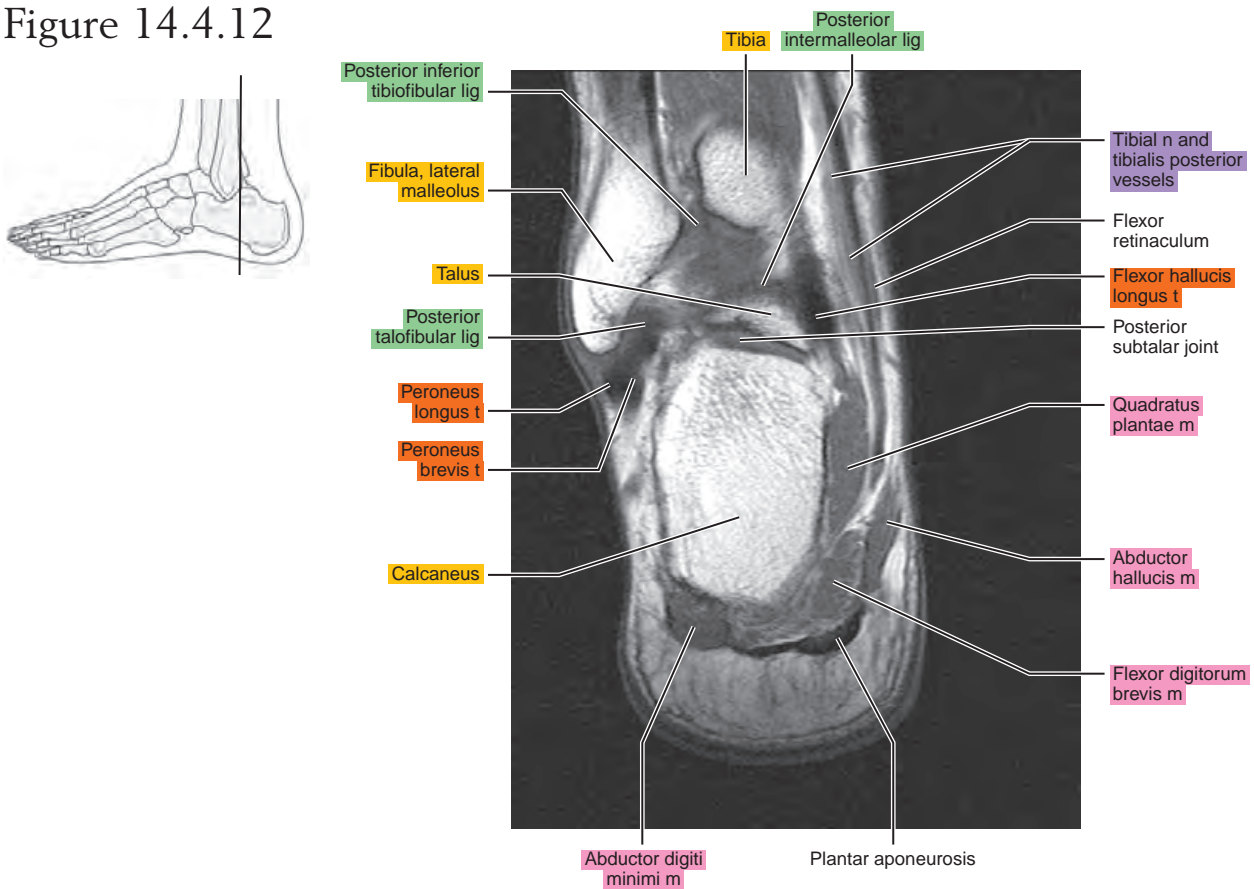


Figure 14.4.13

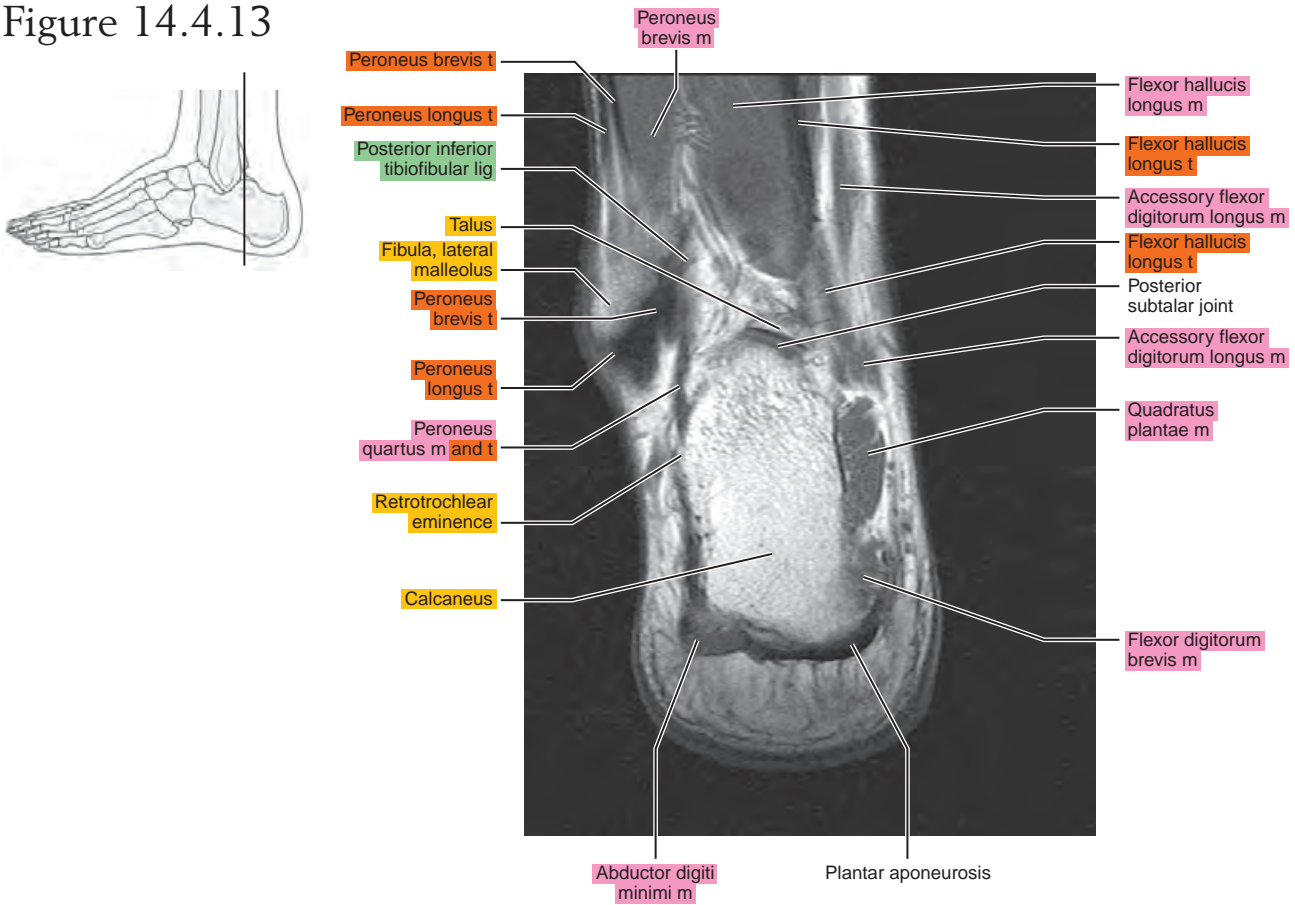


Figure 14.4.14

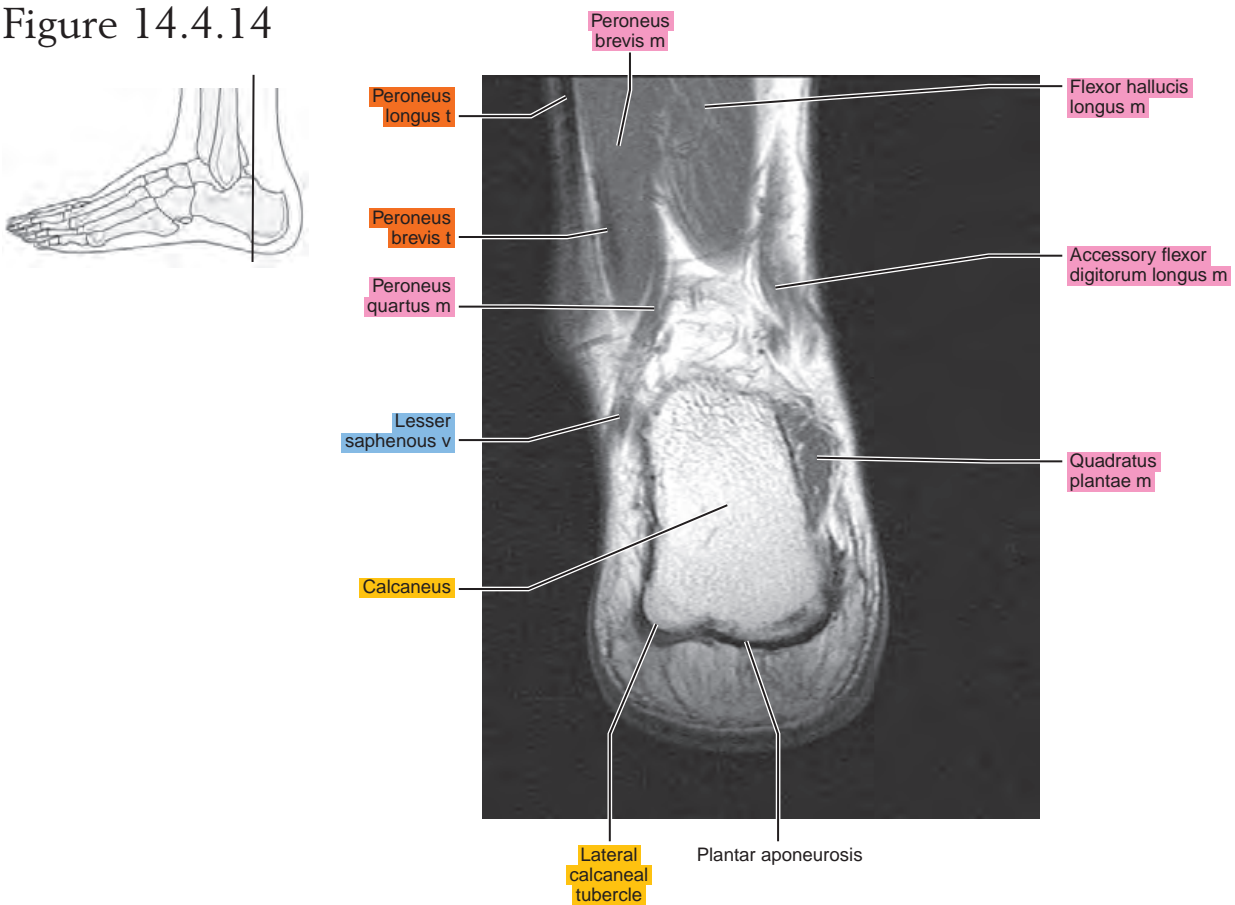


Figure 14.4.15

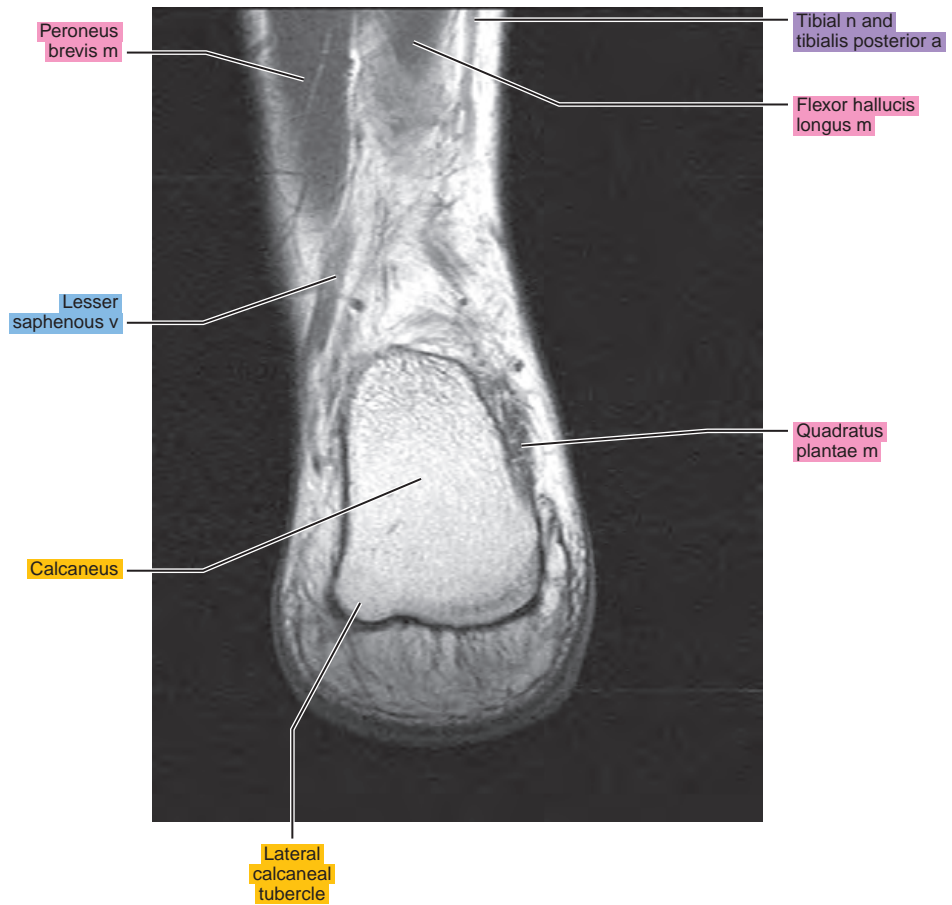
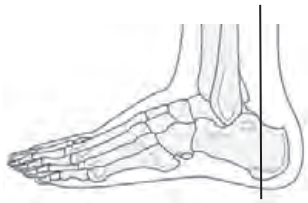

Figure 14.4.16

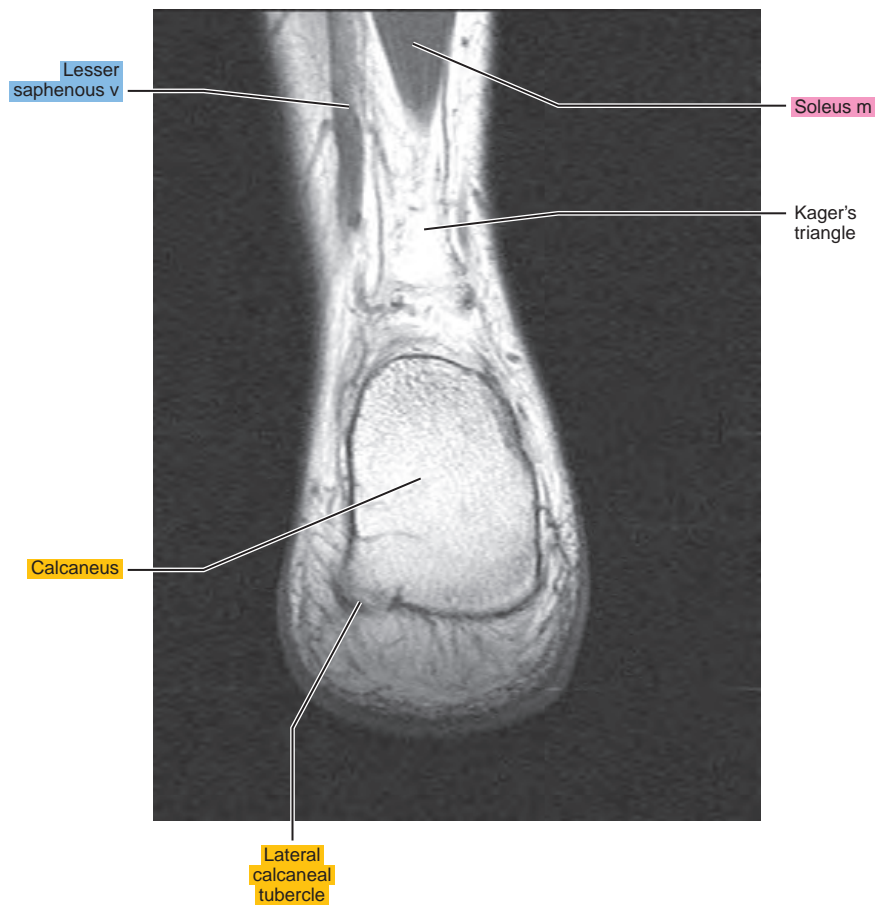
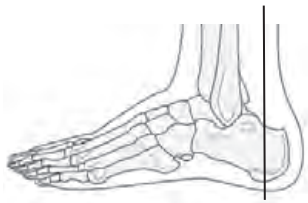

Figure 14.4.17

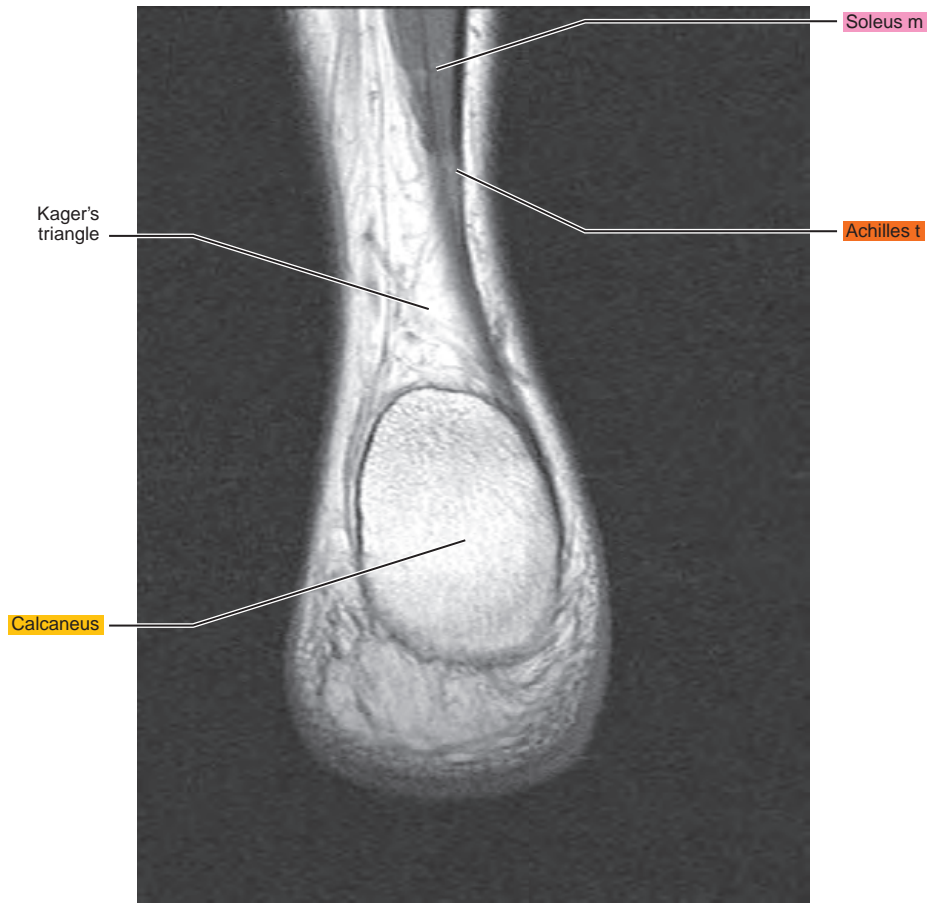
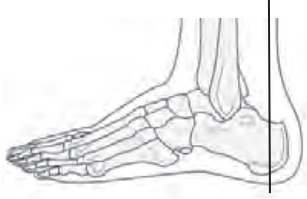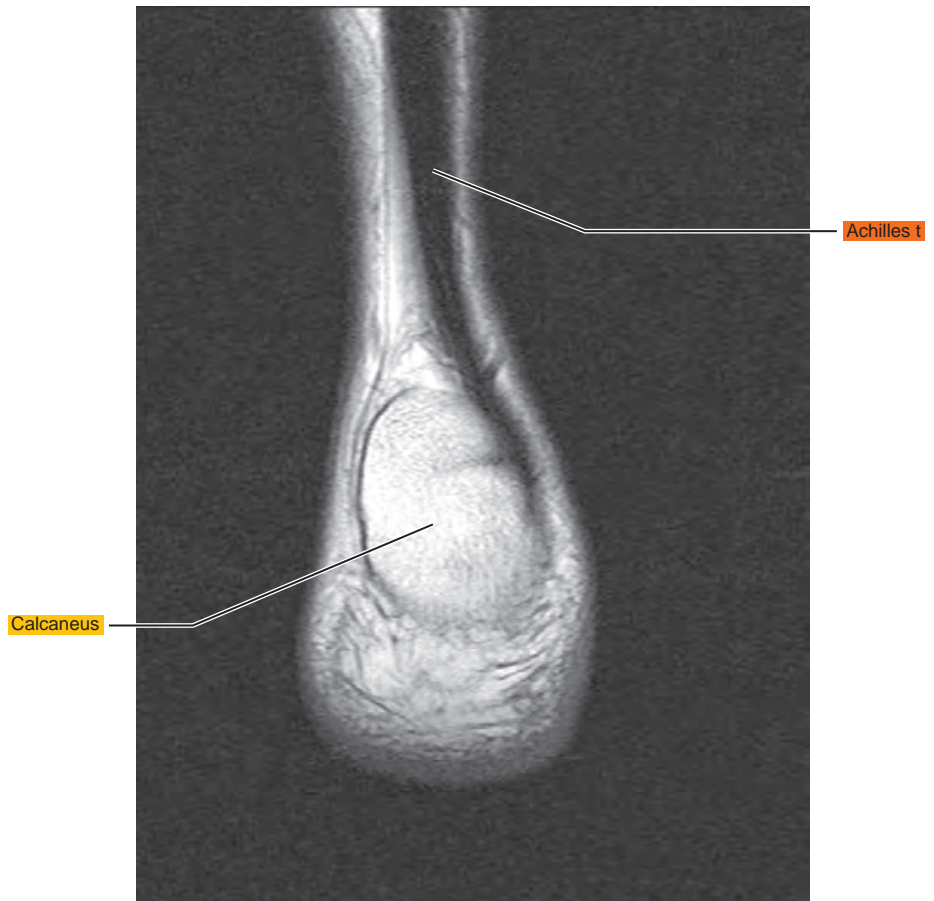

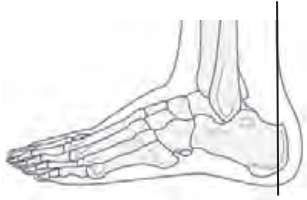
Figure 14.4.18



Chapter
15

MRI of the Foot

Table 15-1. Muscles of the Foot

MUSCLE	ORIGIN	INSERTION	NERVE SUPPLY
Extensor digitorum brevis	Distal part of the lateral and superior surfaces of the calcaneus and the apex of the inferior extensor retinaculum	As the fiber bundles extend distally, they become grouped into four bellies. Those fibers of the most medial and largest belly are known as extensor hallucis brevis. The tendon of this muscle inserts onto the base of the first metatarsal. The remaining fiber bundles have more variable insertions. The second toe fibers usually insert onto the middle dorsal aspect of the base of the proximal phalanx and are often united with the long extensor tendon. The three more lateral tendons are usually fused with the lateral margins of the corresponding long extensor tendons near the bases of the respective middle phalanges and usually extend to the bases of the corresponding proximal phalanges.	Deep peroneal
Flexor digitorum	Medial process of the tuber calcanei, posterior third of the plantar aponeurosis, and medial and lateral intermuscular septa	Tendons of the short (brevis) flexors pass superficial to those of the long flexor into the osteofibrous canals on the flexor surface of the digits. On the proximal phalanx of each toe, the tendon of the short flexor divides and forms an opening through which the tendon of the long flexor passes. The tendons of the short flexor insert onto the base of the middle phalanx	Surface near the medial edge of the muscle
Quadratus plantae (flexor accessorius)	Two heads: a small lateral and a large medial one. (1) Lateral head arises from an elongated tendon from the lateral process of the tuberosity of the calcaneus and from the lateral margin of the long plantar ligament. (2) Medial head originates from the medial surface of the calcaneus in front of the tuberosity and from adjacent ligaments	The two heads are separated at their origin by a short triangular space. The heads fuse to form a single belly, but the fiber bundles of each head are separately inserted. From the lateral head, the fibers insert into the lateral margin of the flexor tendon. The medial head inserts as an aponeurosis into the deep surface of the flexor tendon	Lateral plantar nerve branch that passes obliquely across the superficial surface of the muscle, parallel with the tendon of the flexor digitorum longus
Lumbricals	Three lateral lumbricals arise from the adjacent sides of the digital tendons of the flexor digitorum longus. The first lumbrical arises on the medial margin of the second toe	Fiber bundles of each muscle converge on both sides of a tendon that becomes free near the metatarsophalangeal joint and is inserted onto the medial side of the proximal phalanx of the appropriate toe. A tendinous expansion is inserted into the aponeurosis of the extensor muscle	Three lateral lumbricals are usually supplied by branches of the deep ramus of the lateral plantar nerve. Medial lumbrical is supplied by the first common plantar digital branch of the medial plantar nerve. This nerve may supply the two more medial muscles, or the medial muscles may receive a double nerve supply

Table 15-1. Muscles of the Foot—cont'd

MUSCLE	ORIGIN	INSERTION	NERVE SUPPLY
Abductor hallucis	Medial border of the medial process of the tuber calcanei, flexor retinaculum, and plantar aponeurosis	Along with the tendon of the medial belly of flexor brevis onto the base of the proximal phalanx of the great toe	Branch of the medial plantar
Flexor hallucis brevis	From the plantar surface of the lateral cuneiform and cuboid bones	The medial and lateral sides of the base of the proximal phalanx of the great toe	Branch from the medial plantar or first plantar digital. Rarely, the lateral body may receive a branch from the lateral plantar
Adductor hallucis, oblique head	Tuberosity of the cuboid and sheath of the tendon of the peroneus longus, the plantar calcaneocuboid ligament, the third cuneiform, and bases of the second and third metatarsals	By a flat tendon that inserts in common with that of the flexor brevis onto the lateral part of the plantar surface of the base of the proximal phalanx, and by a slip into the aponeurosis of the long extensor muscle on the back of the great toe	Branch of the deep ramus of the lateral plantar
Adductor hallucis, transverse head	Joint capsules of the third, fourth, and fifth metatarsophalangeal joints and the deep transverse metatarsal ligaments	By a common tendon that splits and passes on each side of the tendon of the oblique head and is inserted into the sheath on the tendon of the long flexor of the great toe	Branch from the deep ramus of the lateral plantar
Abductor digiti minimi	Lateral and medial processes of the tuber calcanei and lateral and plantar surfaces of the body of the bone in front of these, lateral intermuscular septum, deep surface of the lateral plantar fascia, and fibrous band extending from the calcaneus to the lateral side of the base of the fifth metatarsal	Onto the lateral surface of the proximal phalanx of the little toe and the metatarsophalangeal capsule	Lateral plantar
Flexor digiti minimi brevis	Sheath of the peroneus longus, tuberosity of the cuboid, and base of the fifth metatarsal	By short tendinous bands onto the base of the proximal phalanx of the little toe, the capsule of the corresponding joint, and the aponeurosis on the dorsal surface of the toe	Branch from the superficial ramus of the lateral plantar
Opponens digiti minimi	An inconstant muscle, it may arise from the sheath of the peroneus longus and the tuberosity of the cuboid by a thin tendon that passes over the tuberosity of the fifth metatarsal	Onto the lateral surface of the fifth metatarsal	Branch from the nerve to the flexor brevis and the superficial ramus of the lateral plantar

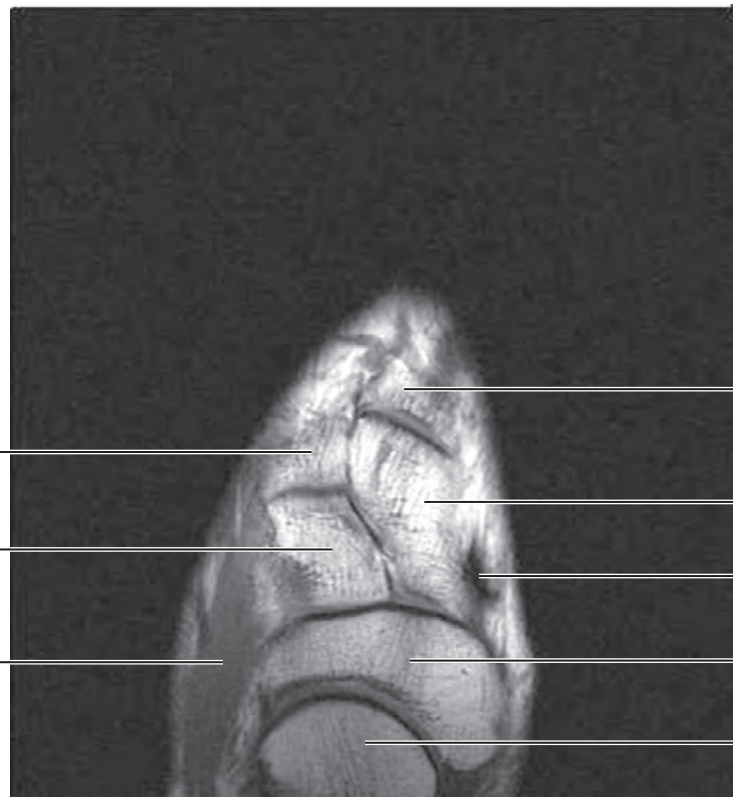
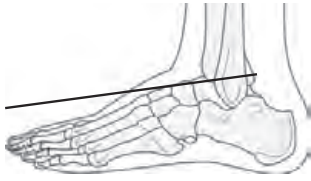Continued

Table 15-1. Muscles of the Foot—cont'd

MUSCLE	ORIGIN	INSERTION	NERVE SUPPLY
Interosseous, dorsal	Each of the three lateral dorsal interosseous muscles arises from the sides of the shaft and the plantar surface of the bases of the metatarsals, bounding the space in which each lies, from the fascia covering it dorsally, and from the fibrous prolongations from the long plantar ligament. The first (medial) has a similar origin, except that its medial origin is by a tendinous slip from the peroneus longus tendon and, occasionally, by fiber bundles from the medial side of the proximal end of the first metatarsal	The first and second interosseous muscles onto each side of the base of the proximal phalanx of the second toe; the third and fourth onto the lateral side of the bases of the proximal phalanges of the third and fourth toes. Each tendon adheres to the capsule of the adjacent joint	Deep branch of the lateral plantar. The interosseous muscles of the fourth interspace are usually supplied by a branch from the superficial ramus of the lateral plantar
Interosseous, plantar	The plantar interosseous muscle arises from the proximal third of the medial plantar surface of the shaft, from the base of the metatarsal on which it lies, and from the fascial expansions of the long plantar ligament	Onto a tubercle on the medial side of the base of the proximal phalanx of the digit to which it goes	Lateral plantar

AXIAL

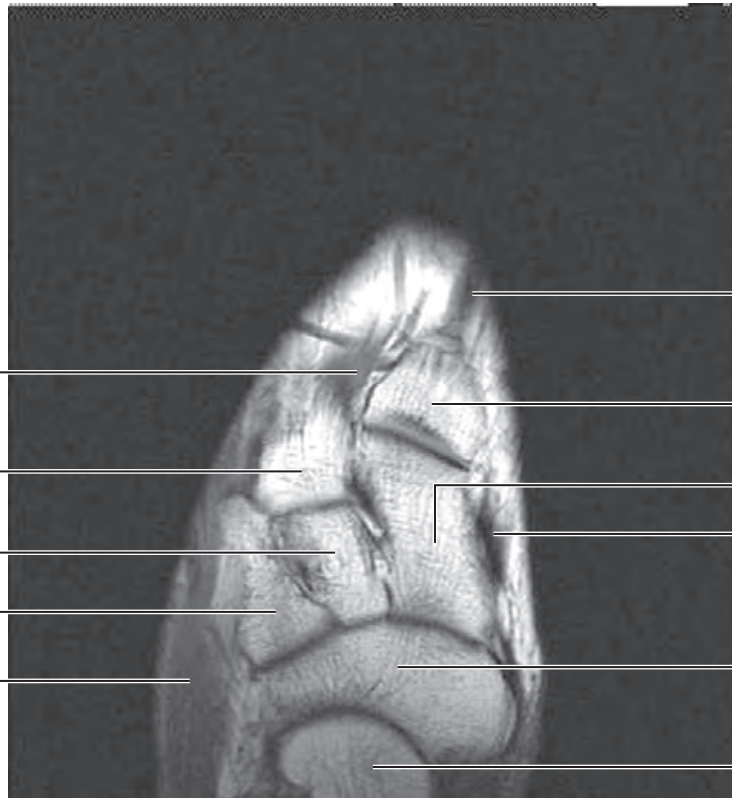
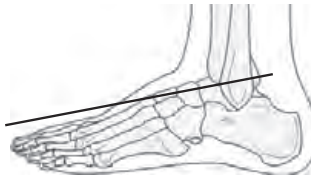Figure 15.1.1



artery = a
arteries = aa
vein = v
veins = vv
muscle = m
muscles = mm
tendon = t
tendons = tt
nerve = n
nerves = nn
ligament = lig
ligaments = lig
nerve & vessels
bone

- Base of first metatarsal
- Medial cuneiform
- Tibialis anterior t
- Navicular
- Talar head
- Base of second metatarsal
- Middle cuneiform
- Extensor digitorum brevis m

Figure 15.1.2



- Extensor hallucis longus t
- Base of first metatarsal
- Medial cuneiform
- Tibialis anterior t
- Navicular
- Talar head
- Dorsal interosseous m
- Base of second metatarsal
- Middle cuneiform
- Lateral cuneiform
- Extensor digitorum brevis m

Figure 15.1.3

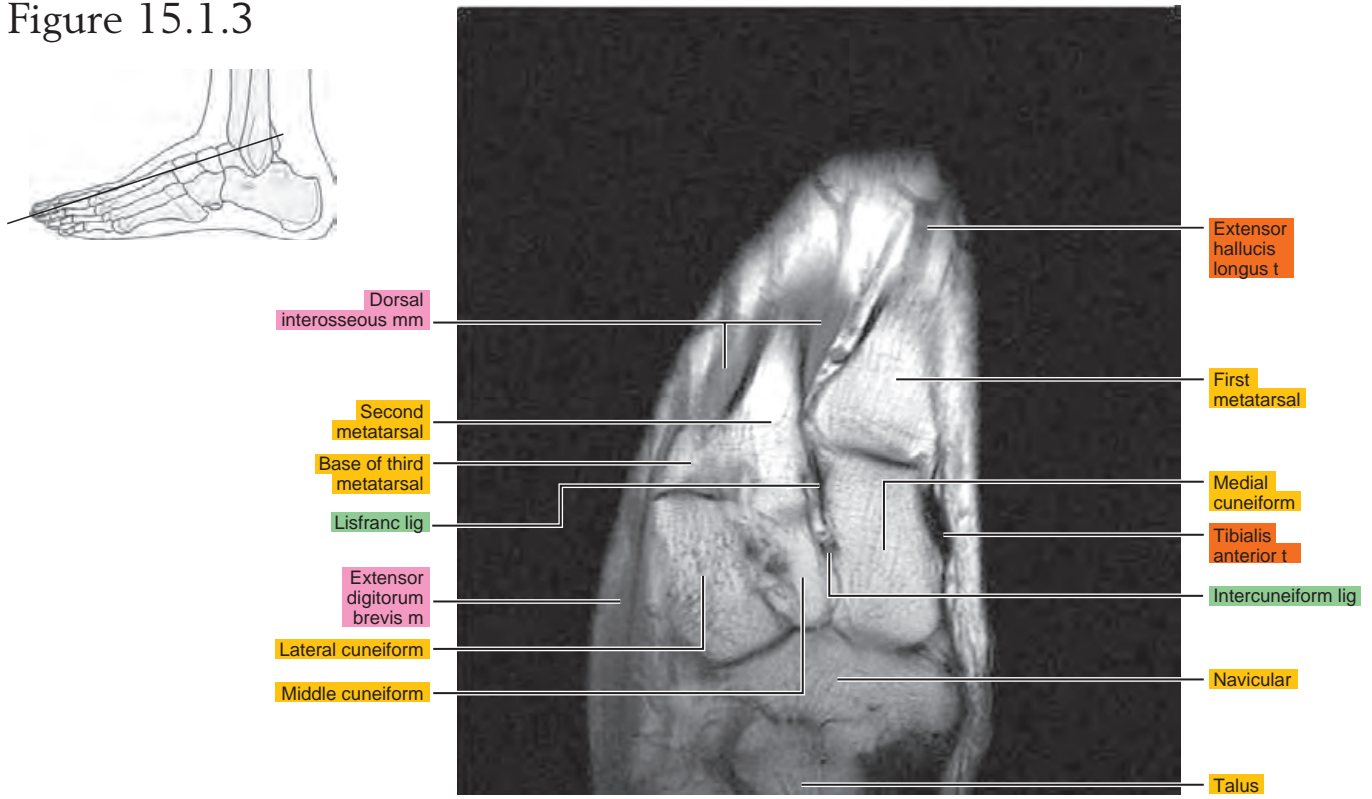


Figure 15.1.4

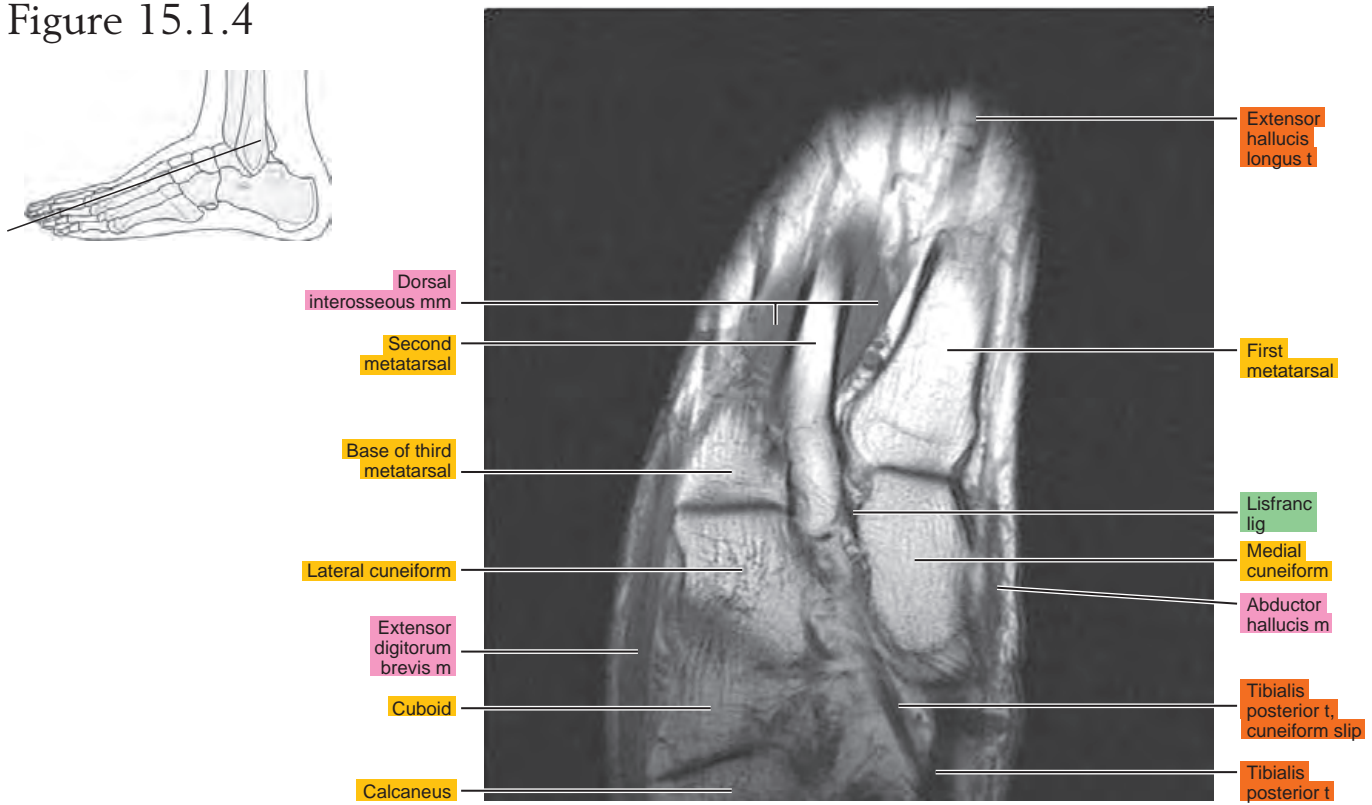


Figure 15.1.5

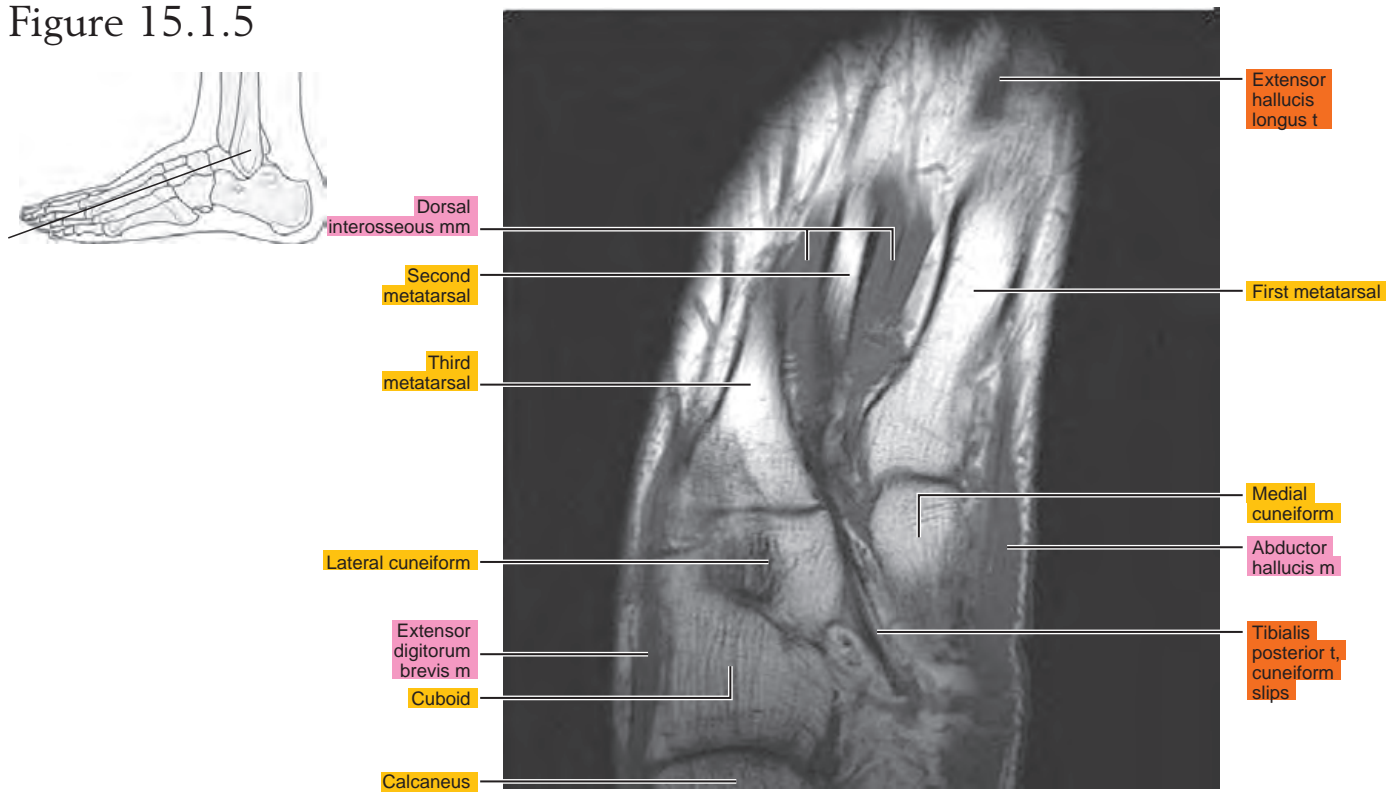


Figure 15.1.6

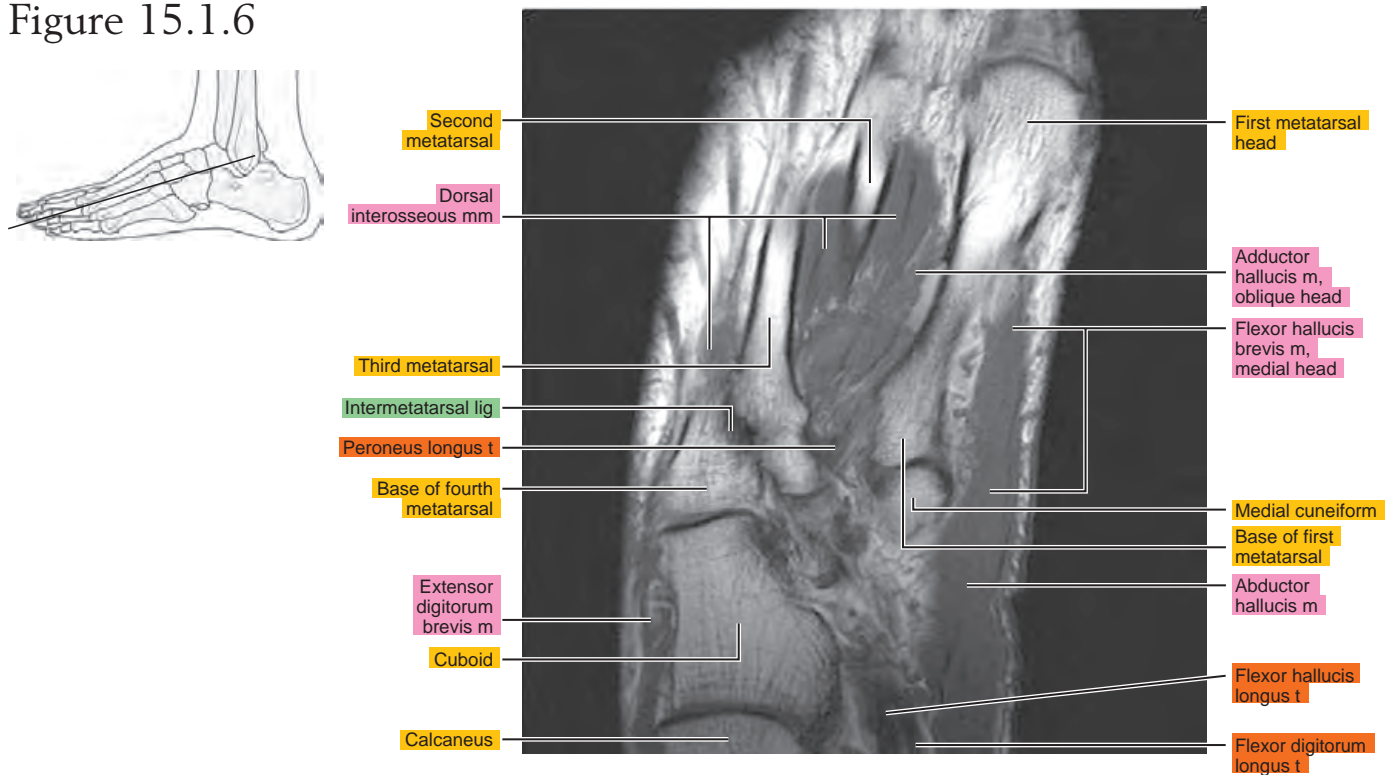


Figure 15.1.7

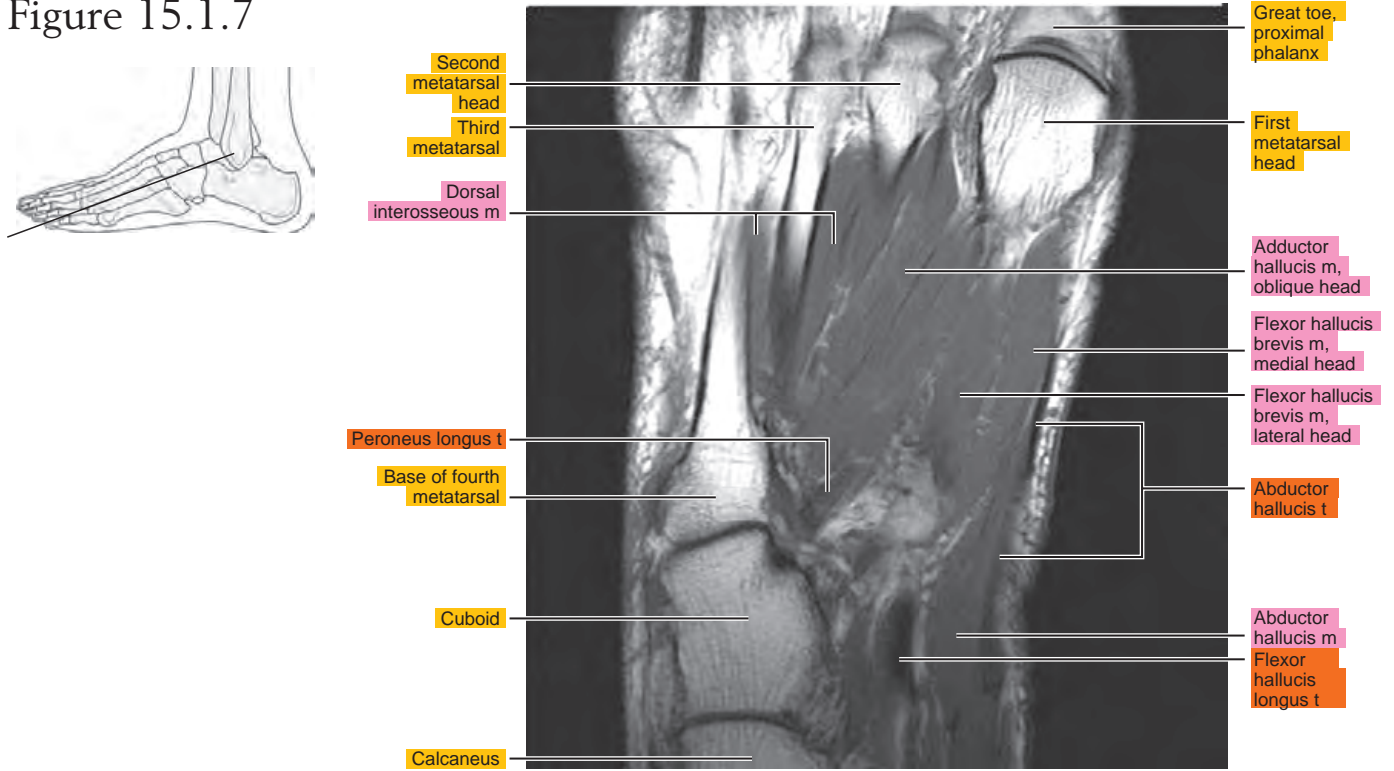


Figure 15.1.8

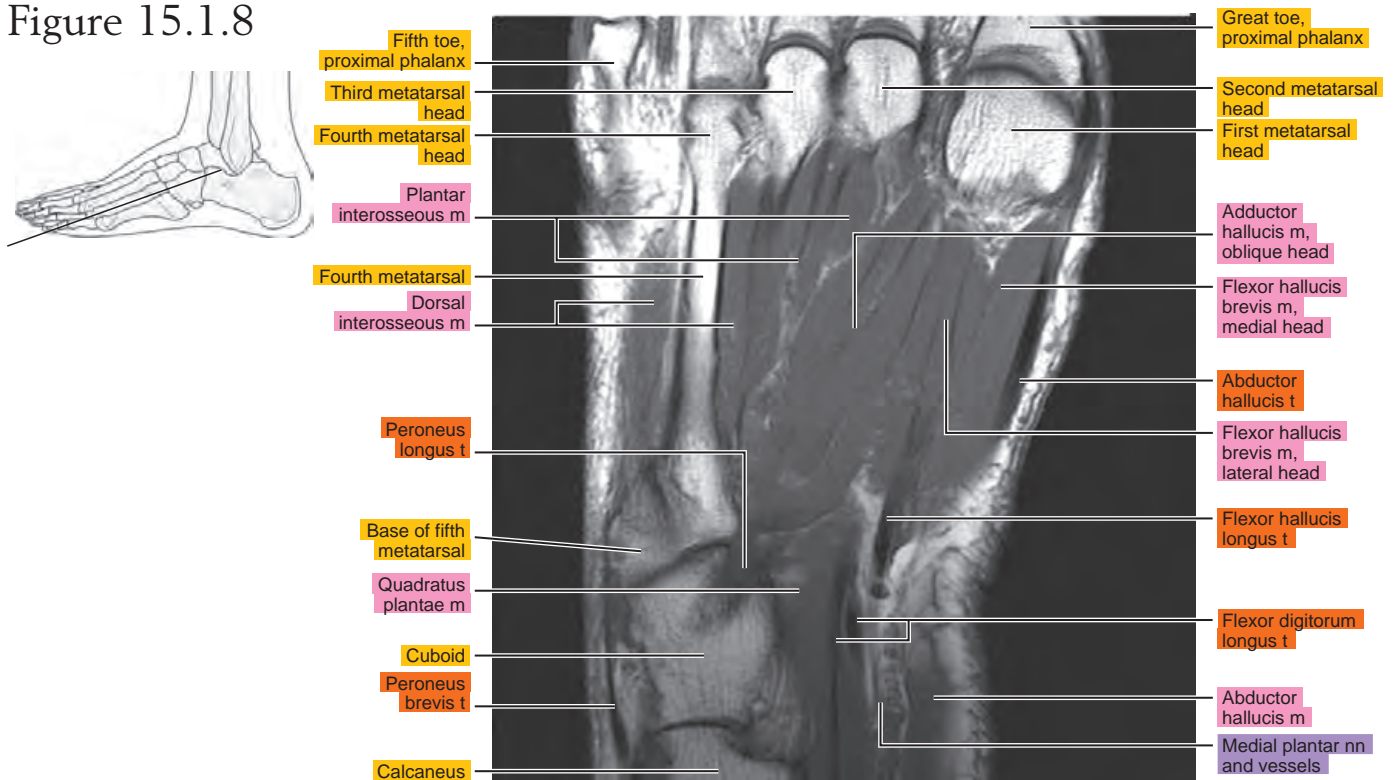


Figure 15.1.9

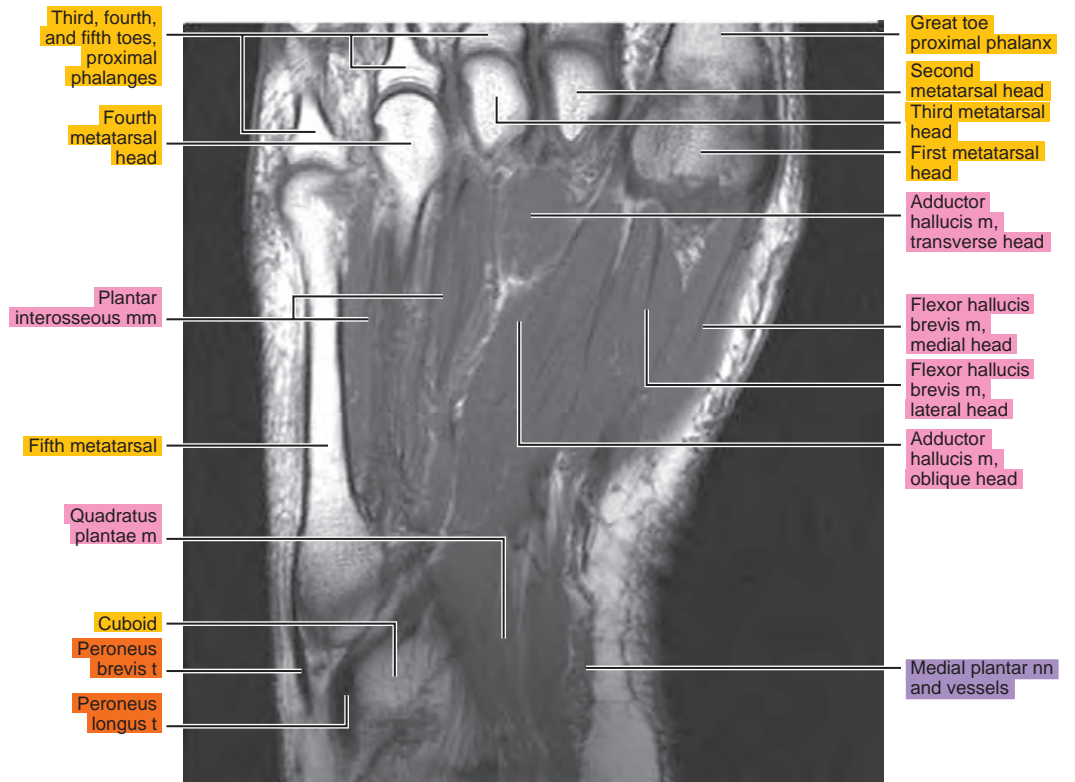
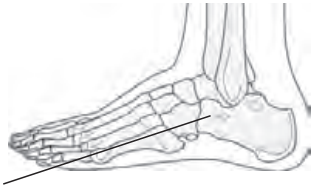

Figure 15.1.10

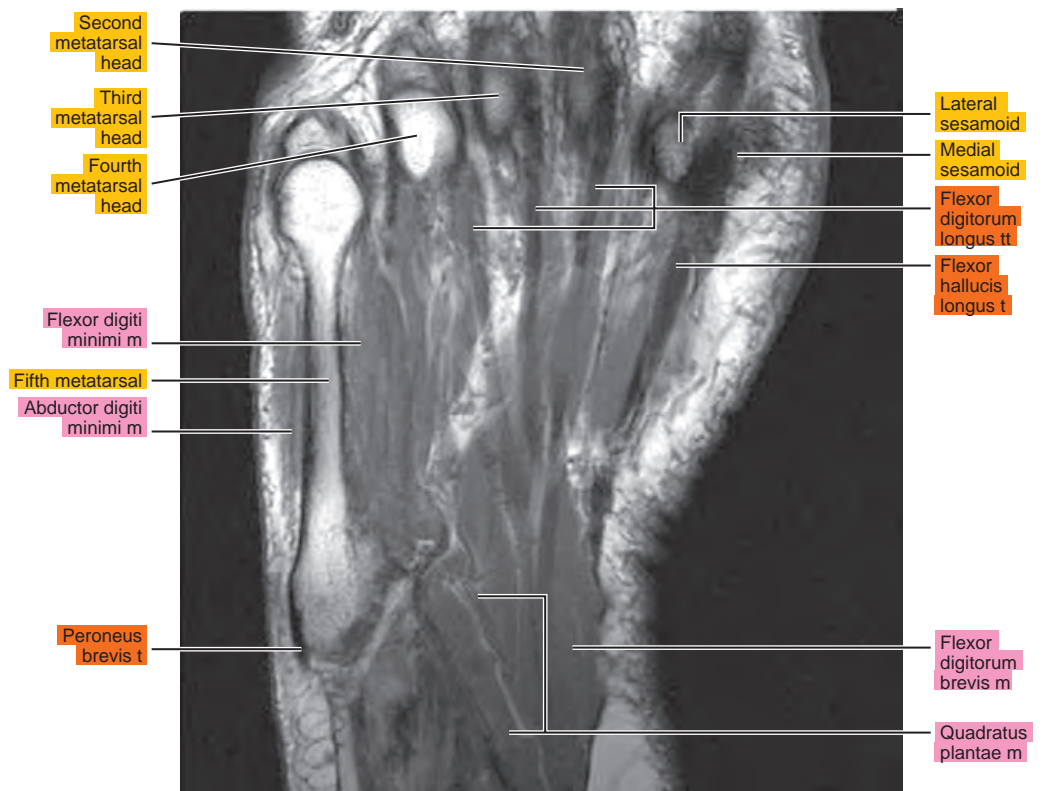
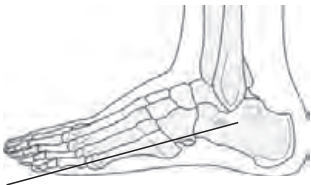
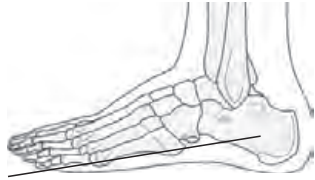
Figure 15.1.11



Fifth metatarsal head

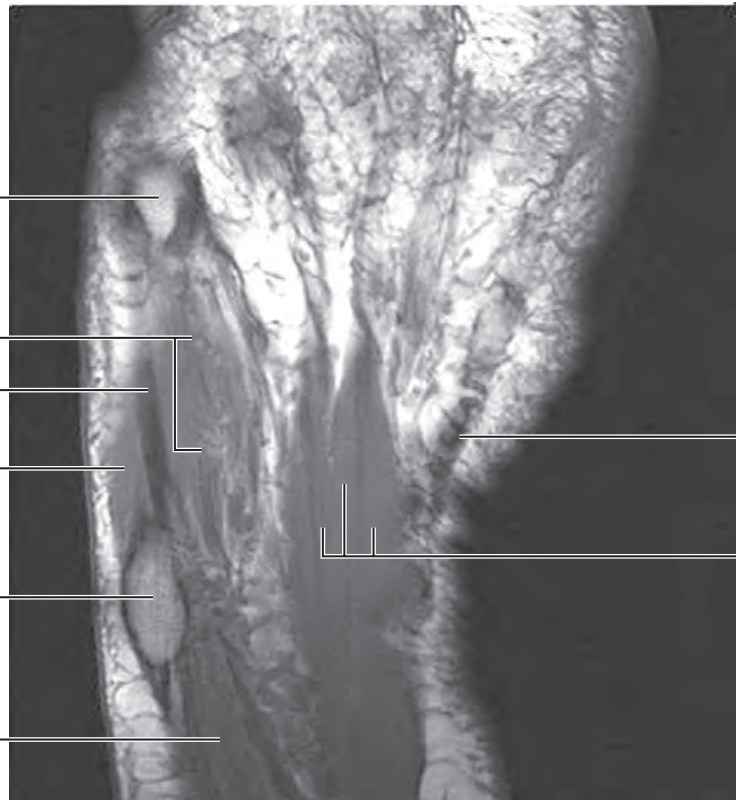
Flexor digiti minimi m

Abductor digiti minimi t

Abductor digiti minimi m

Base of fifth metatarsal

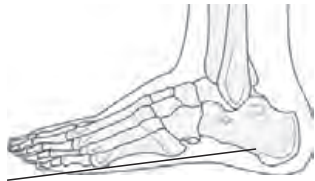Abductor digiti minimi m



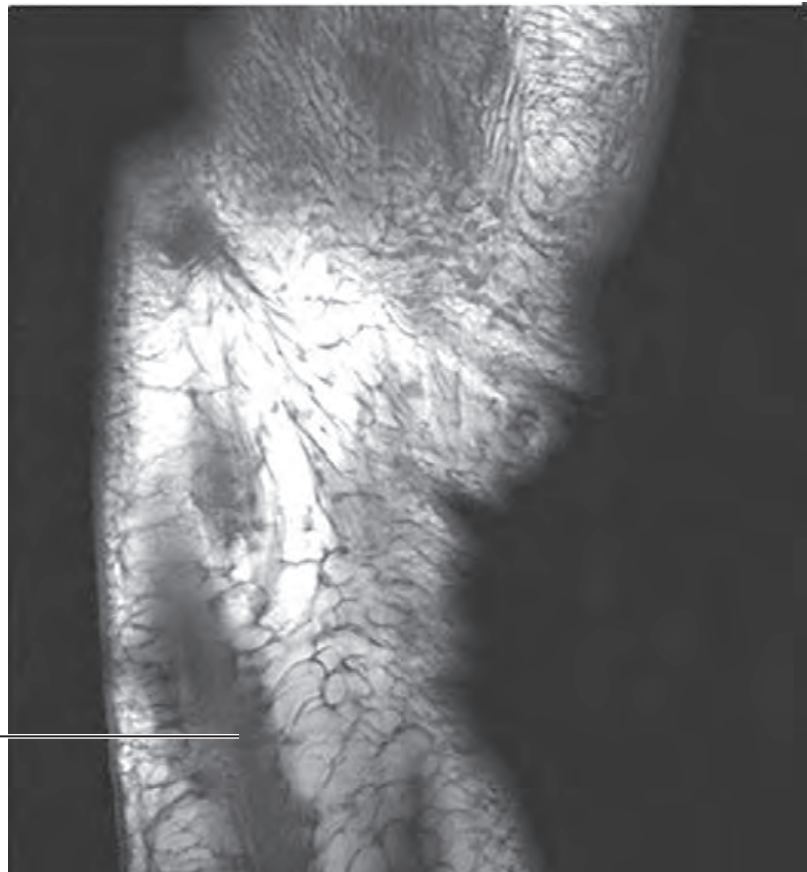
Flexor hallucis longus t

Flexor digitorum brevis m

Figure 15.1.12



Abductor digiti minimi m



SAGITTAL

Figure 15.2.1

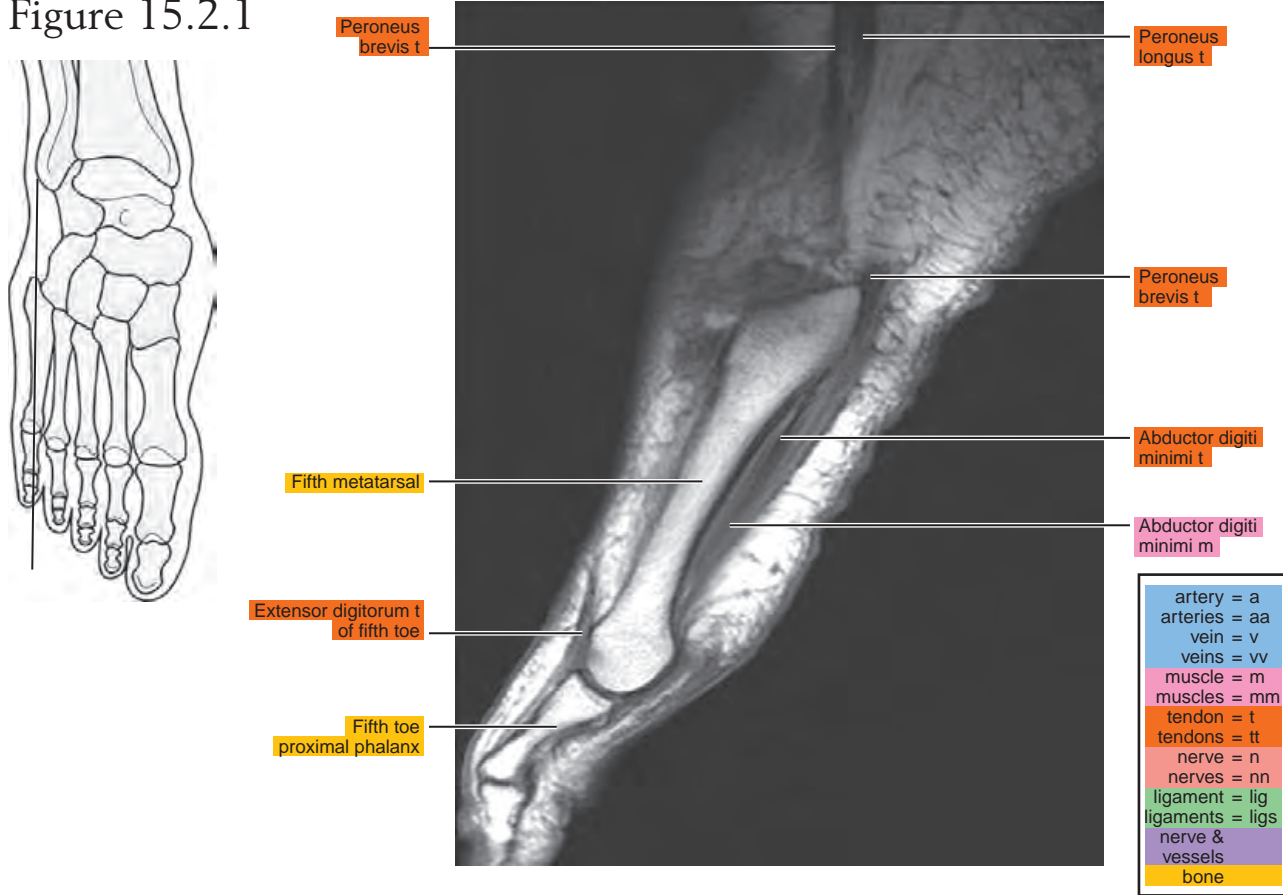


Figure 15.2.2

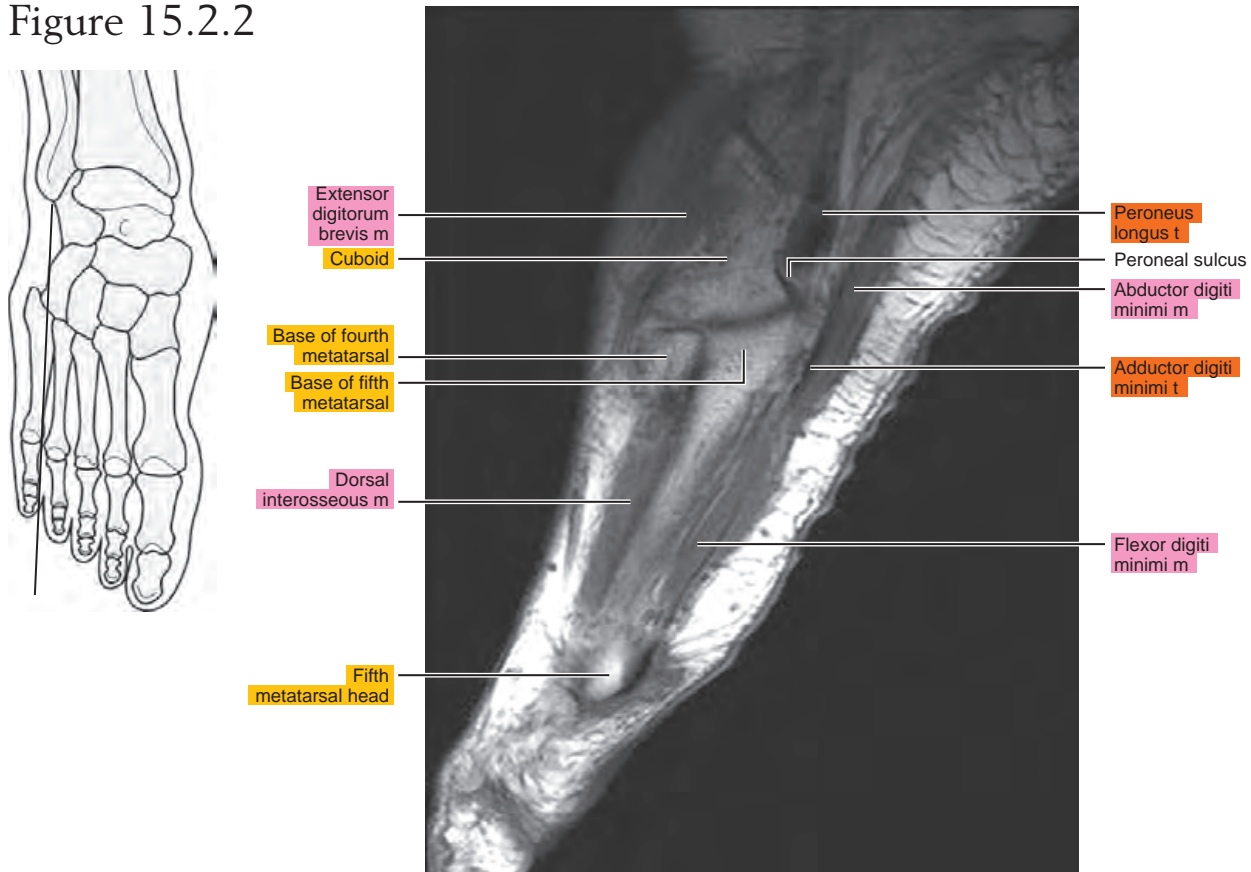


Figure 15.2.3

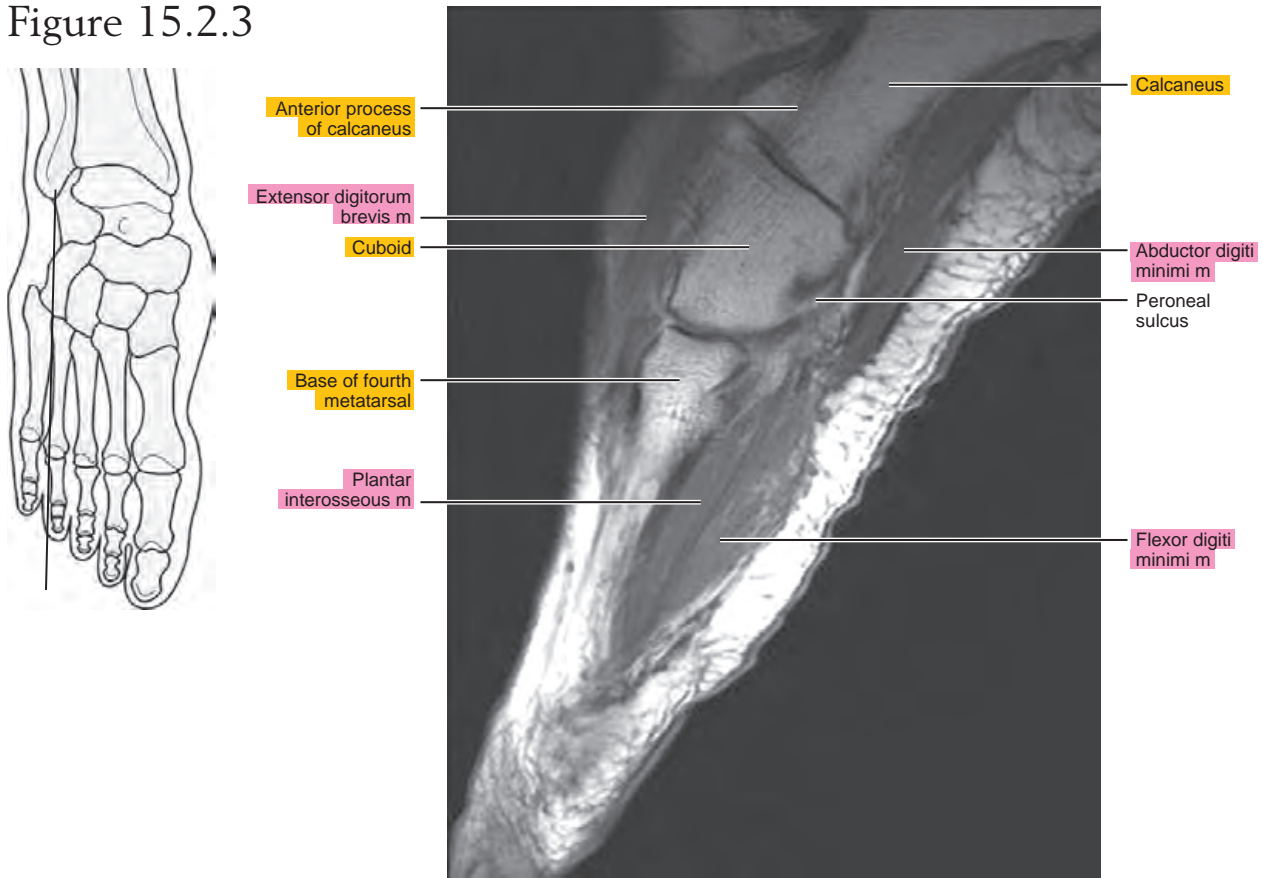


Figure 15.2.4

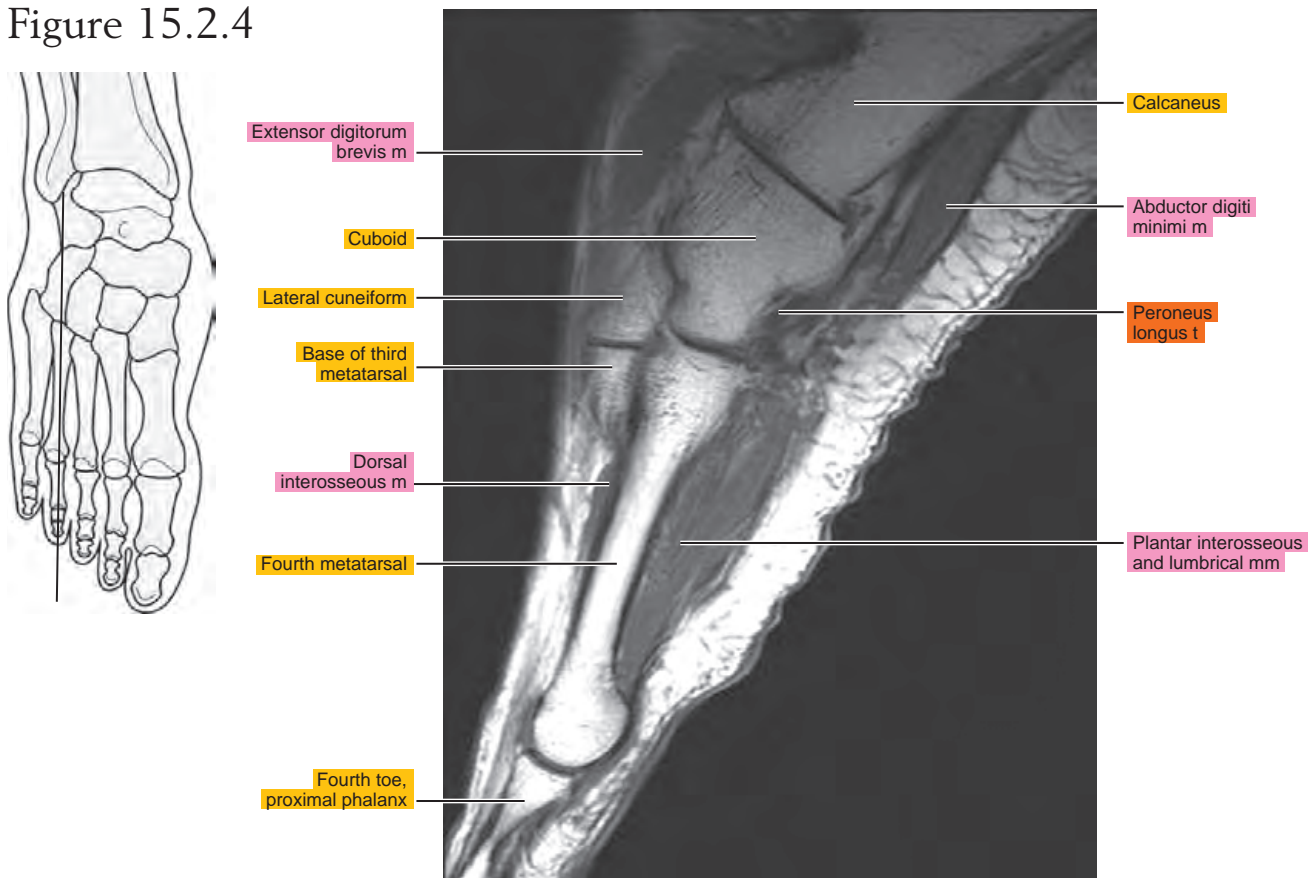


Figure 15.2.5

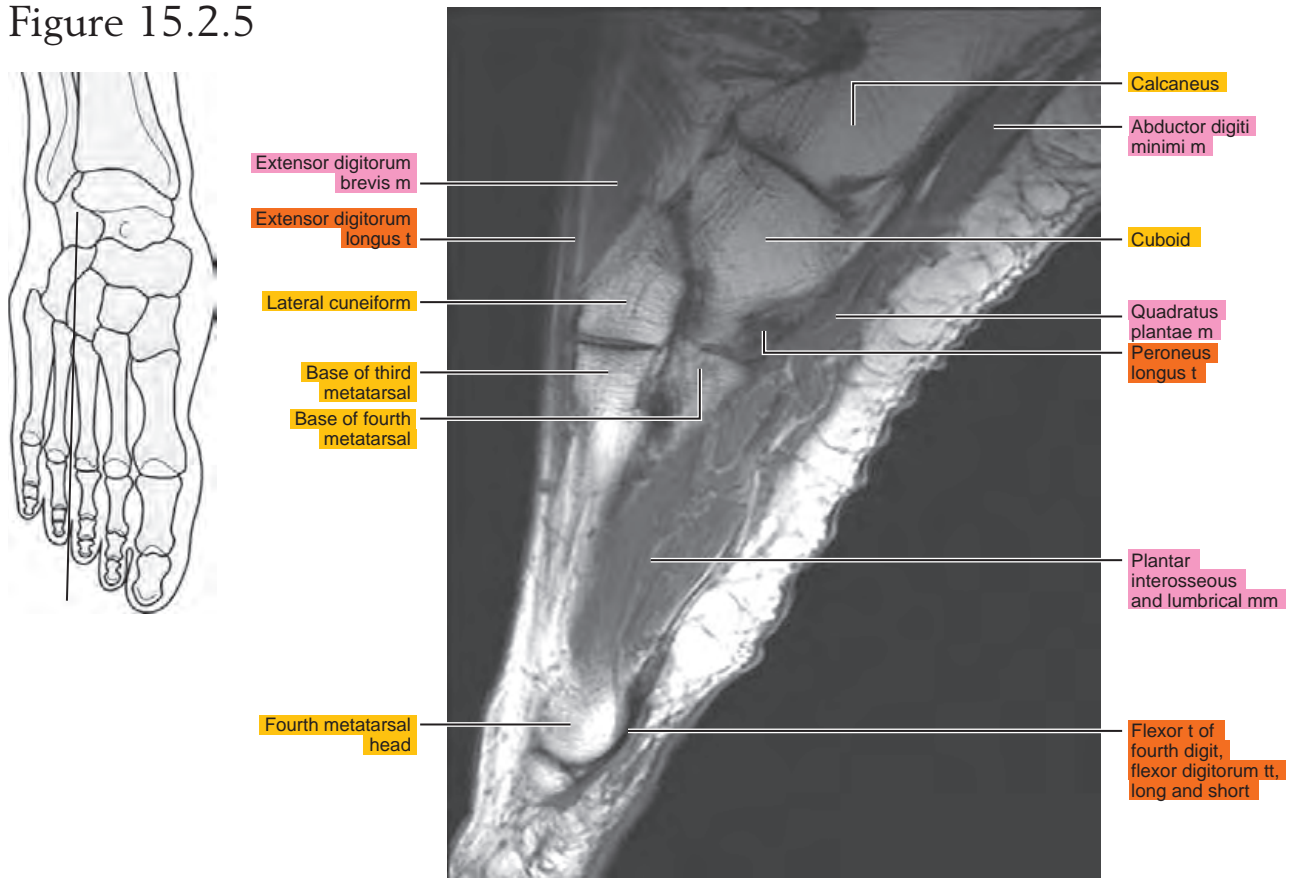


Figure 15.2.6

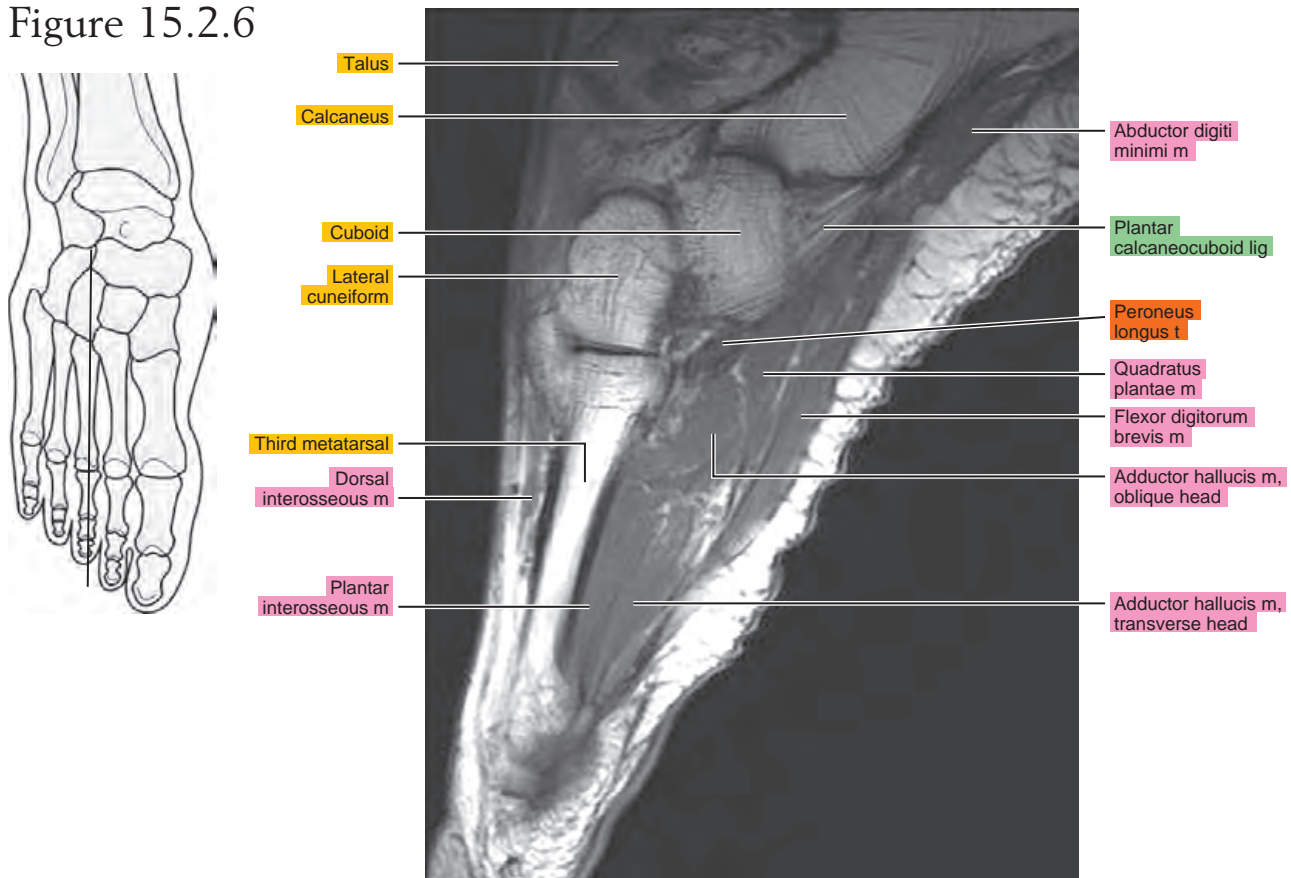


Figure 15.2.7

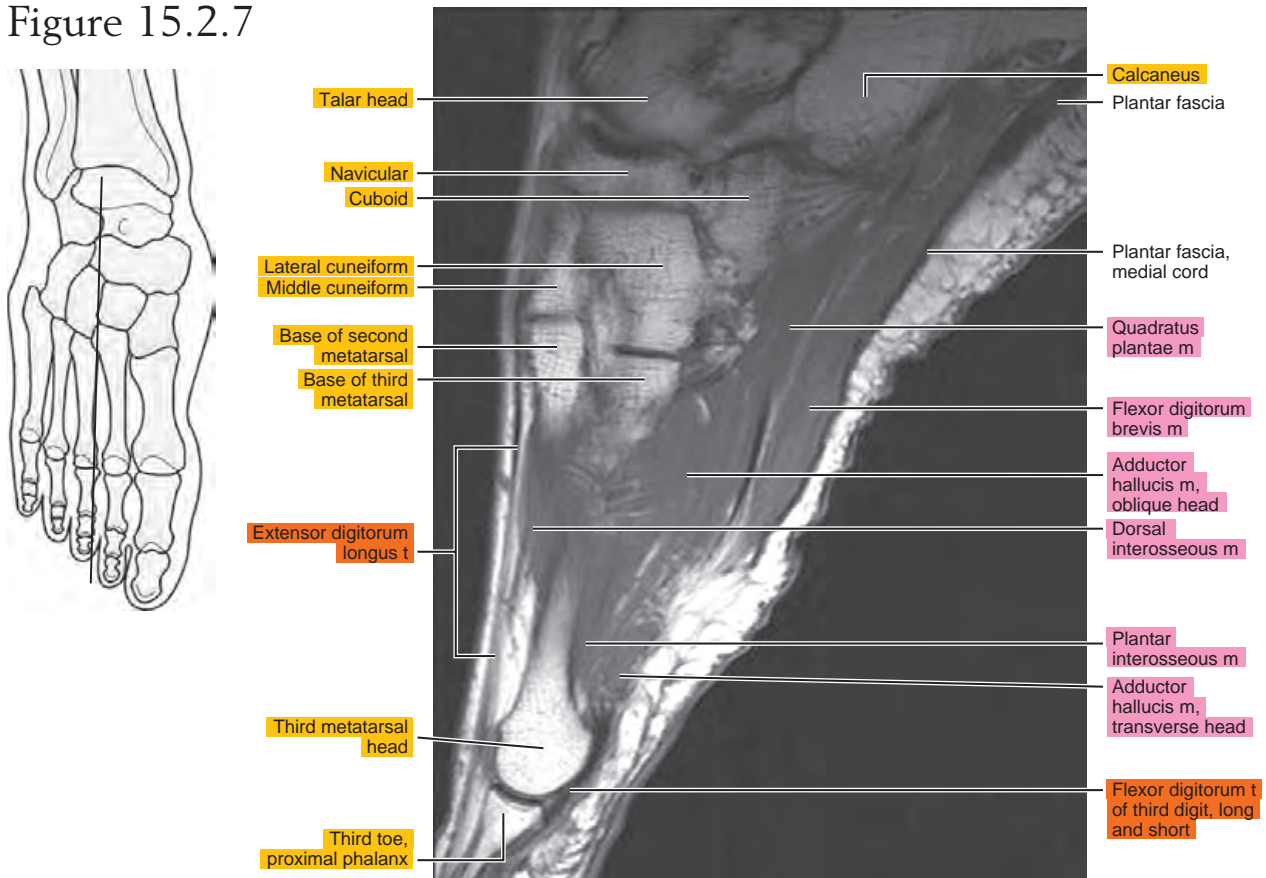


Figure 15.2.8

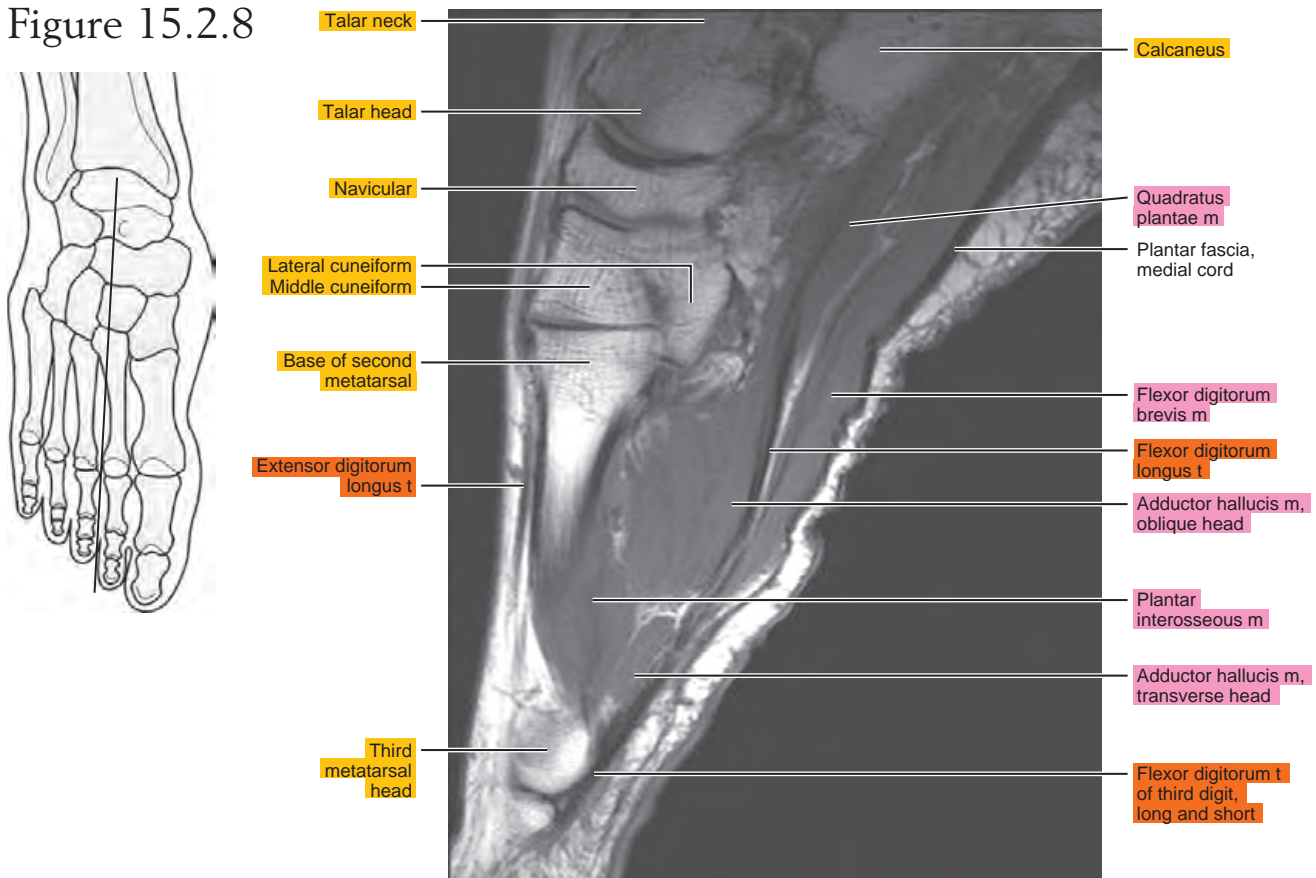


Figure 15.2.9

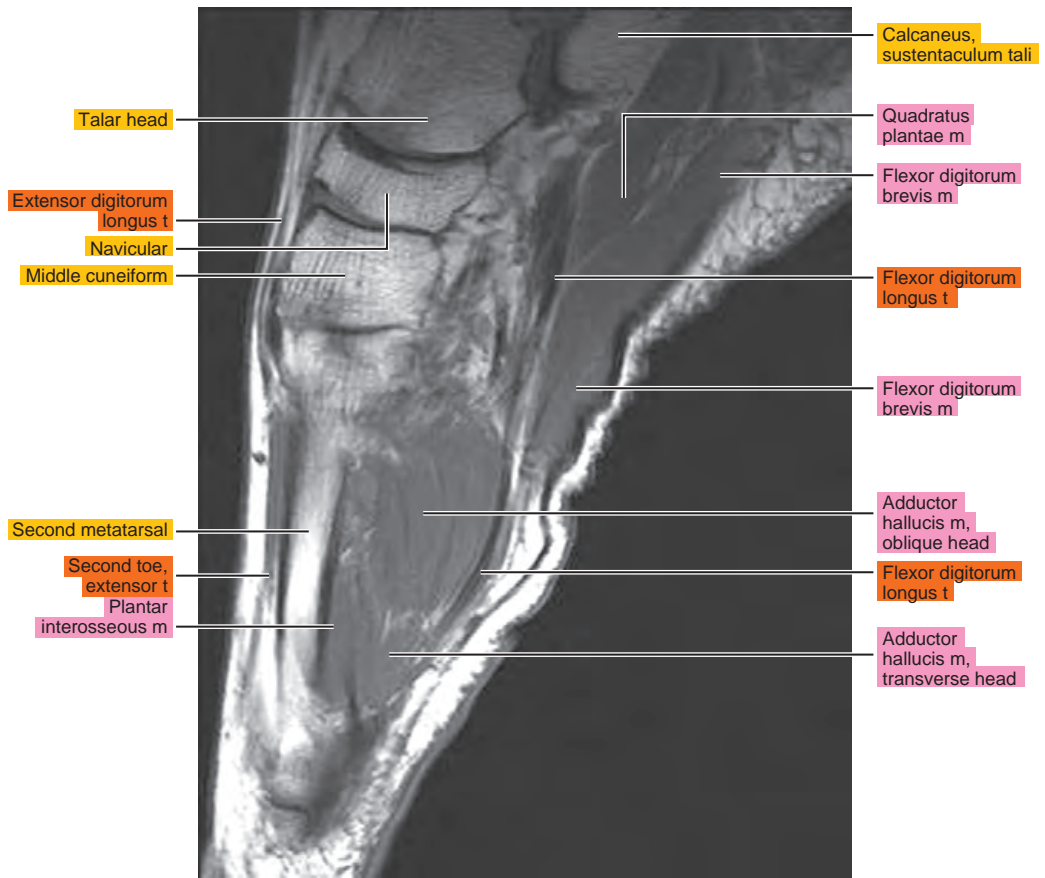
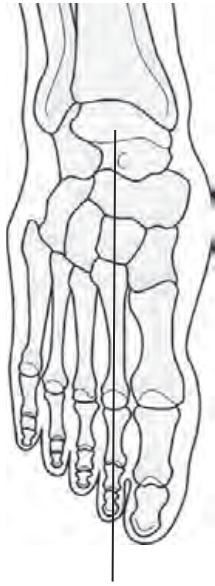

Figure 15.2.10

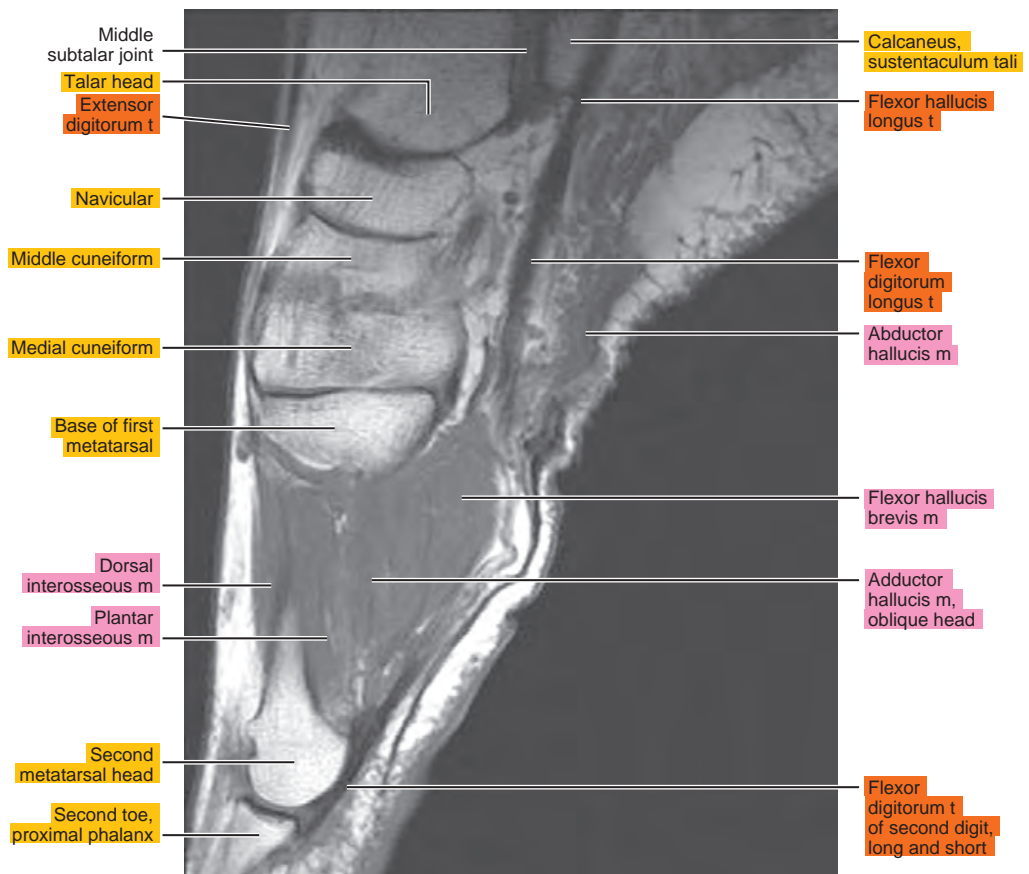
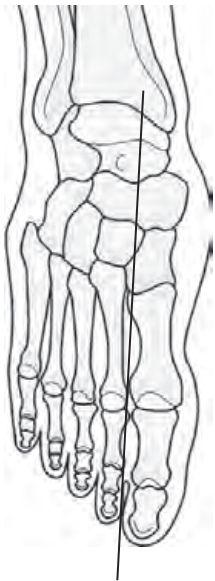

Figure 15.2.11

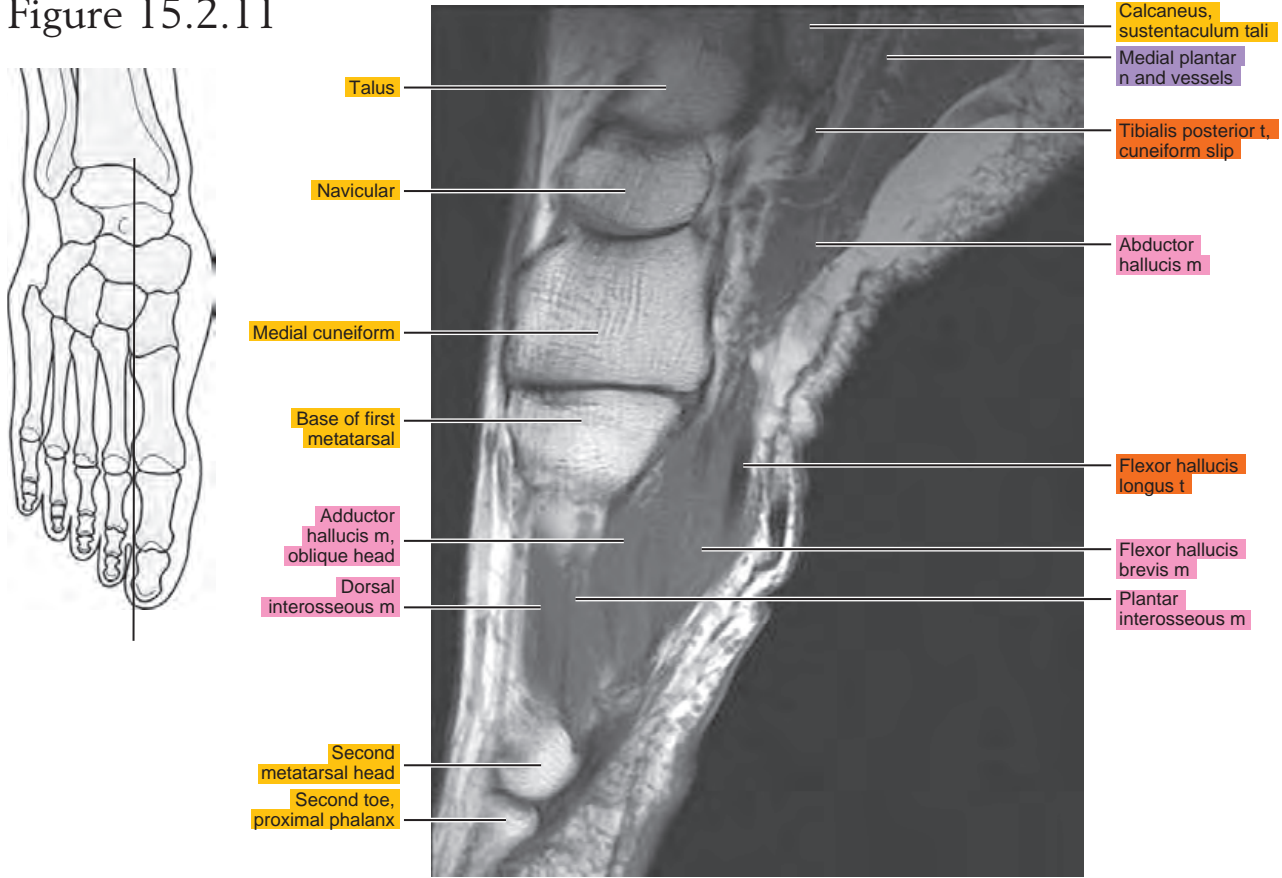


Figure 15.2.12

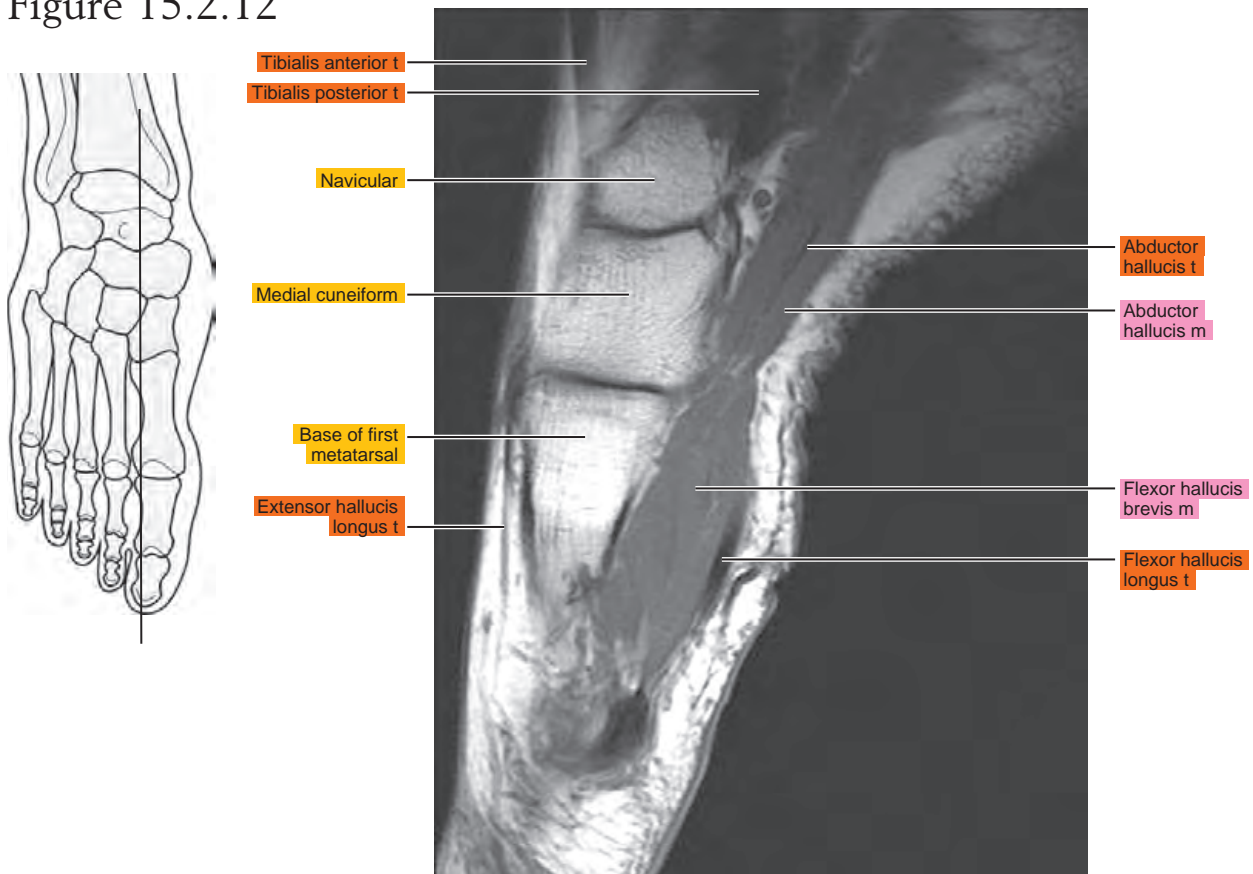


Figure 15.2.13

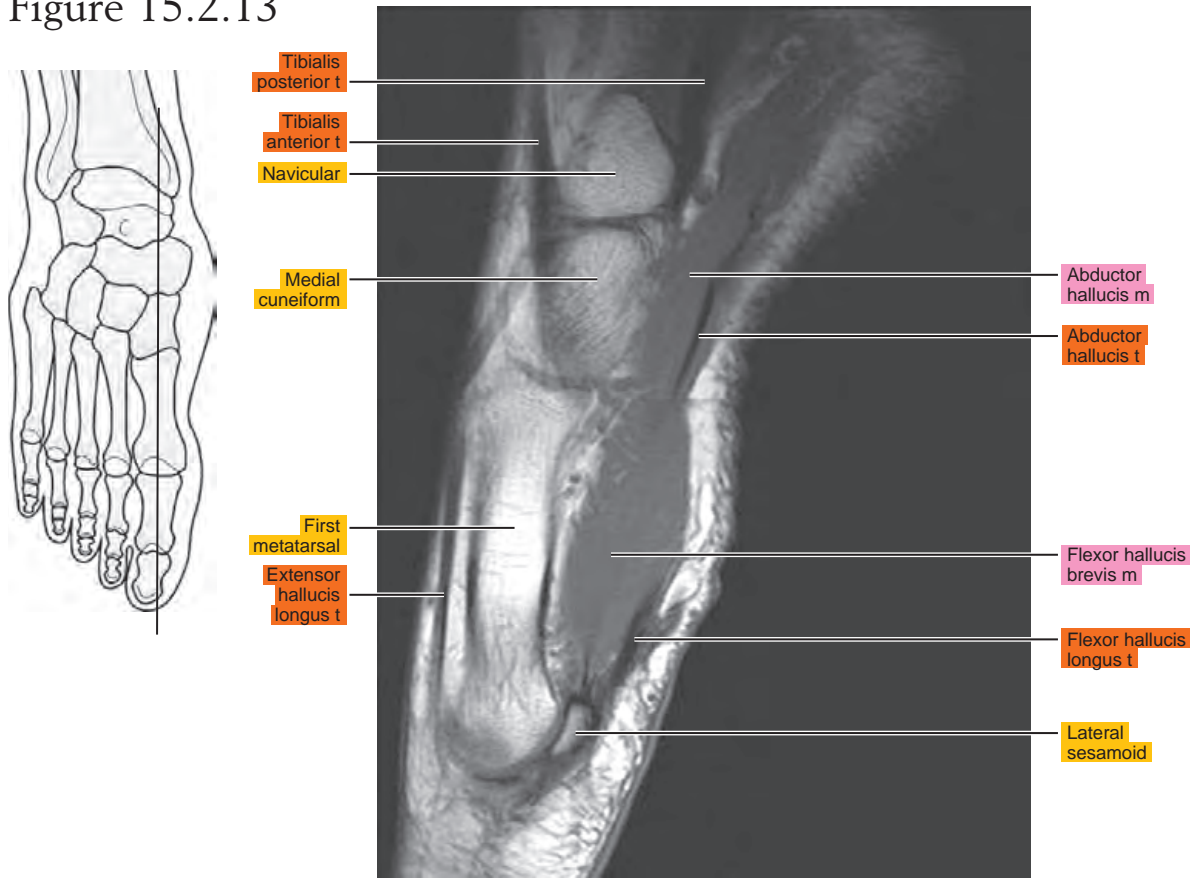


Figure 15.2.14

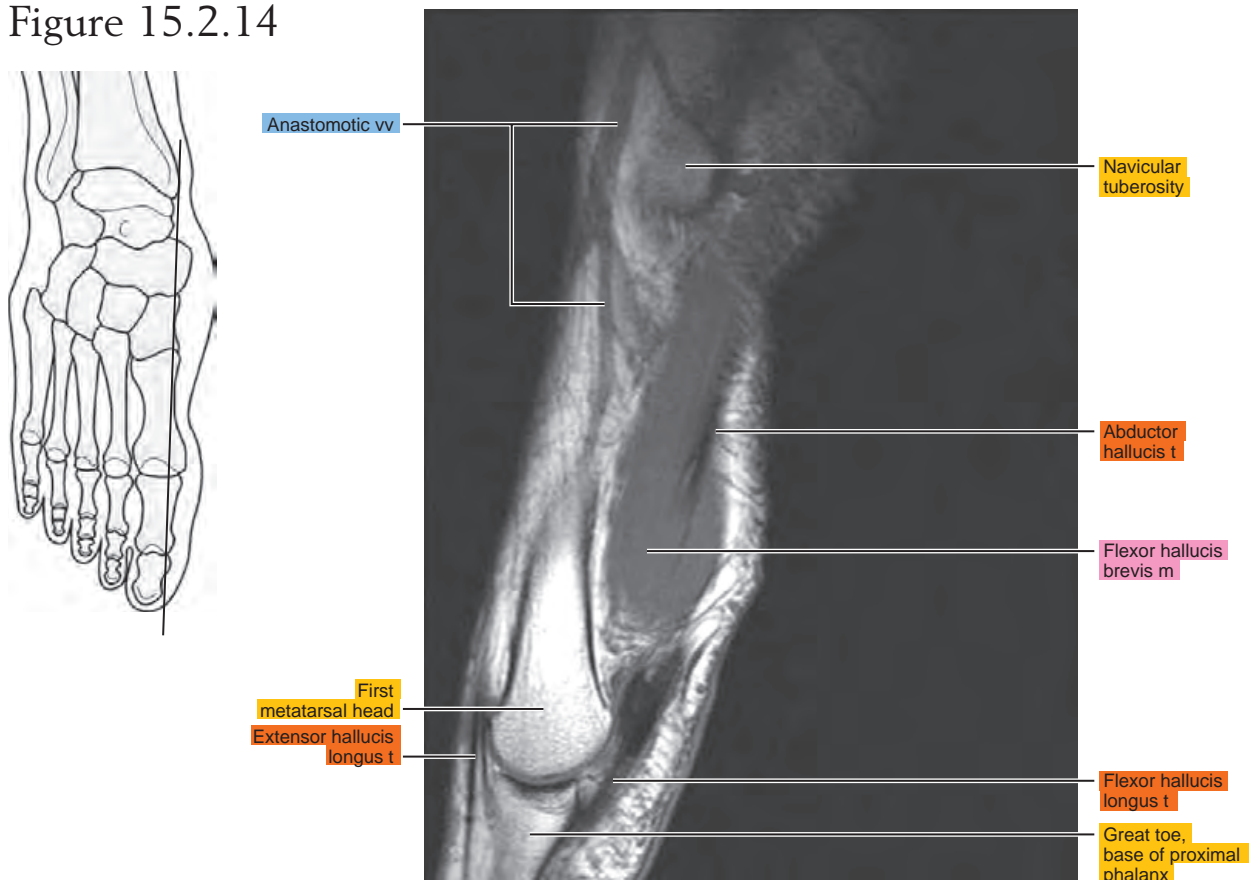
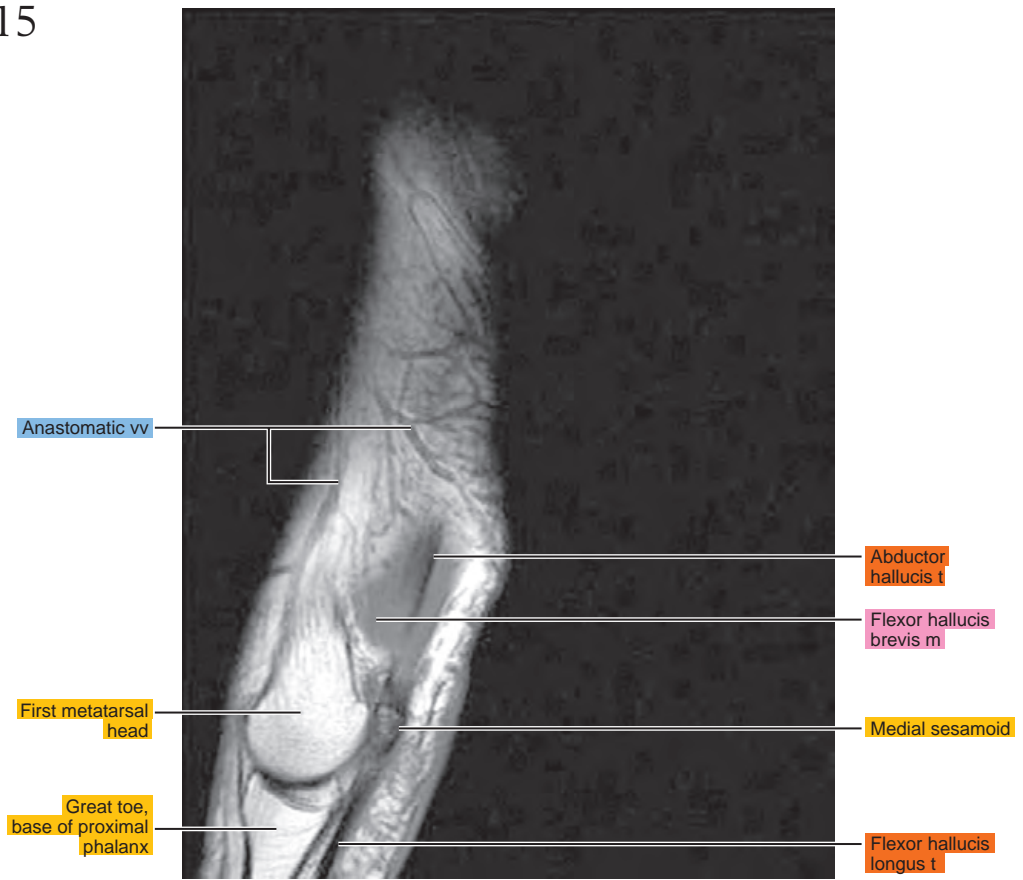
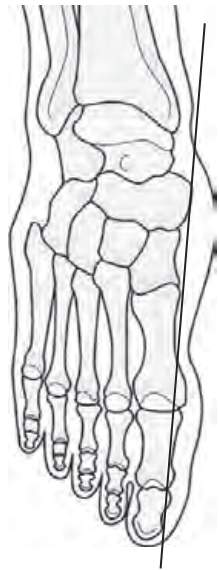


Figure 15.2.15



CORONAL

Figure 15.3.1

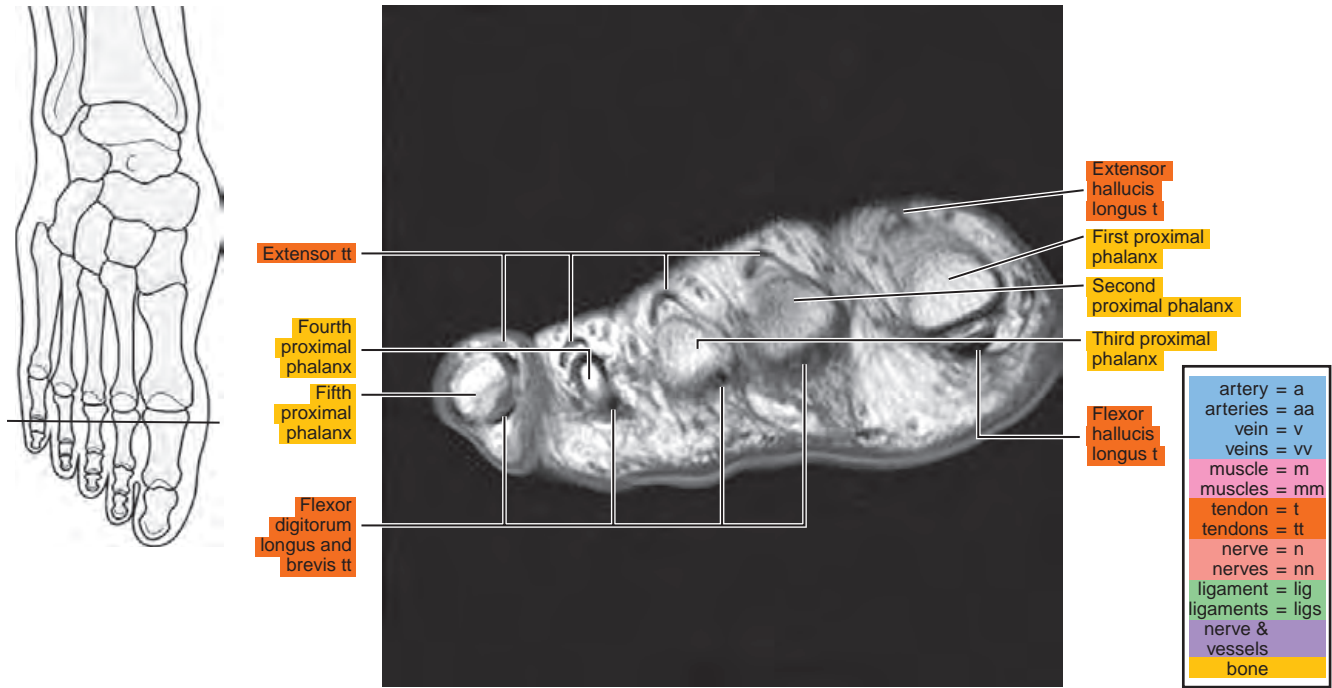


Figure 15.3.2

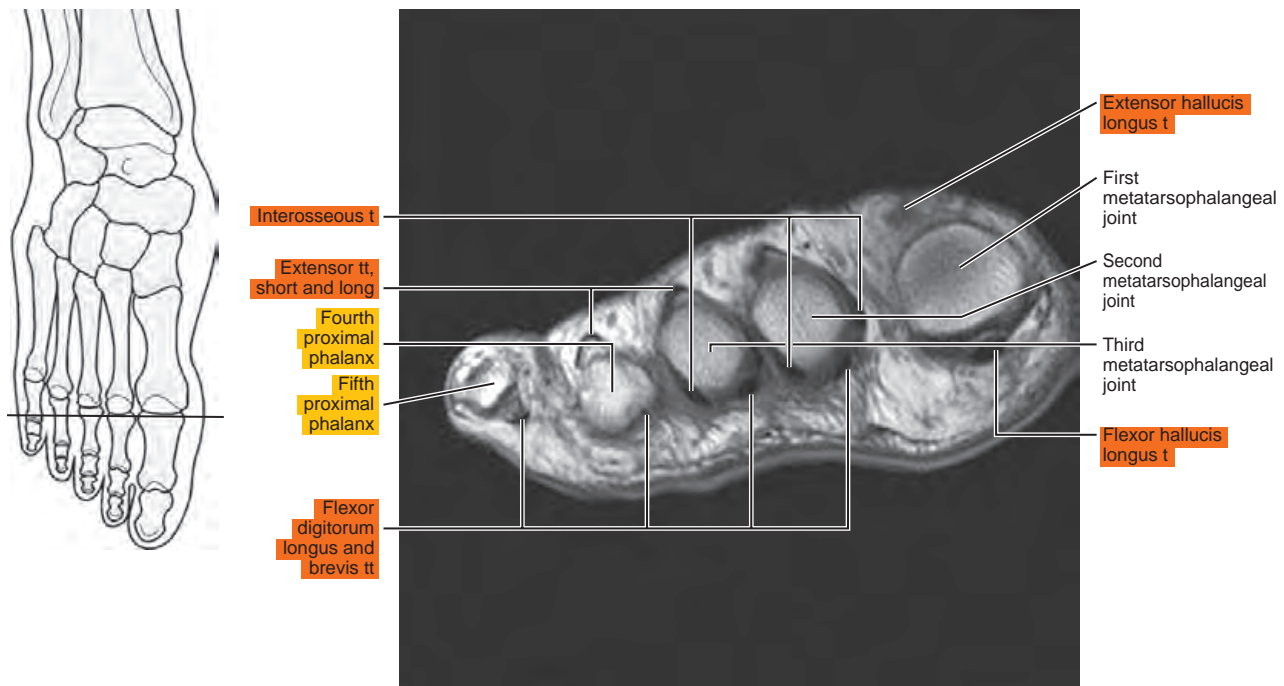


Figure 15.3.3

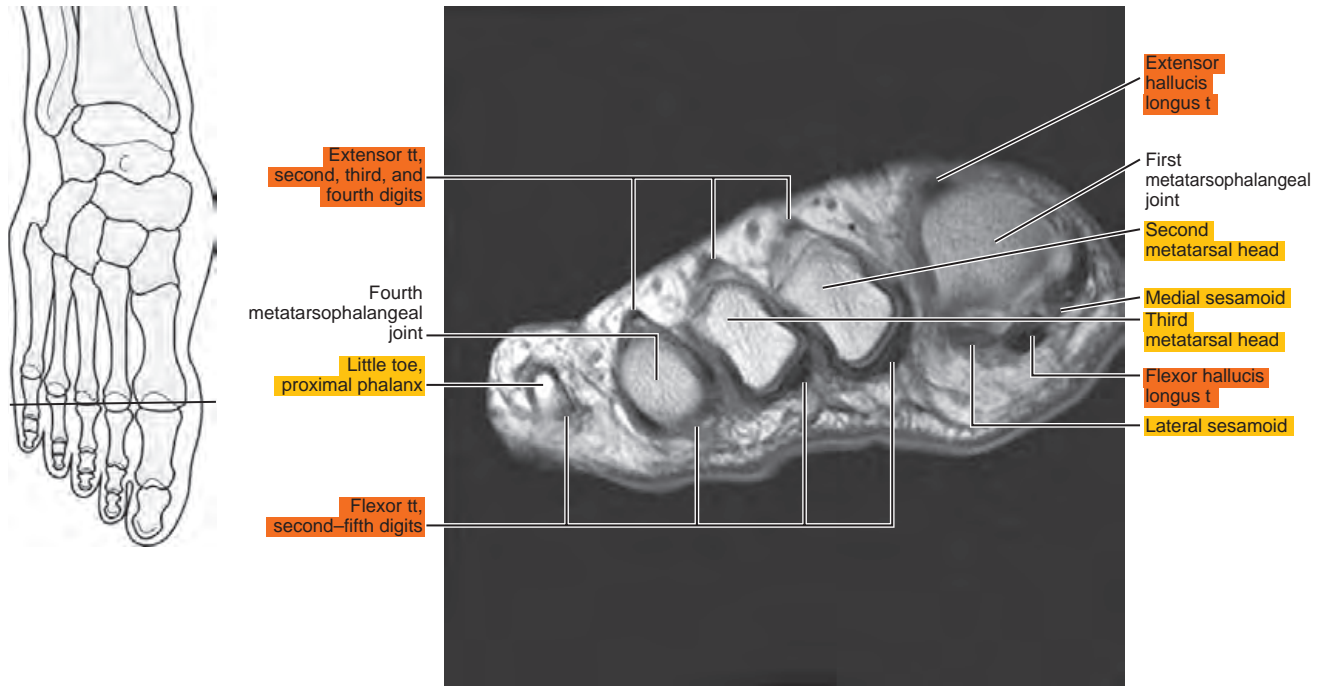


Figure 15.3.4

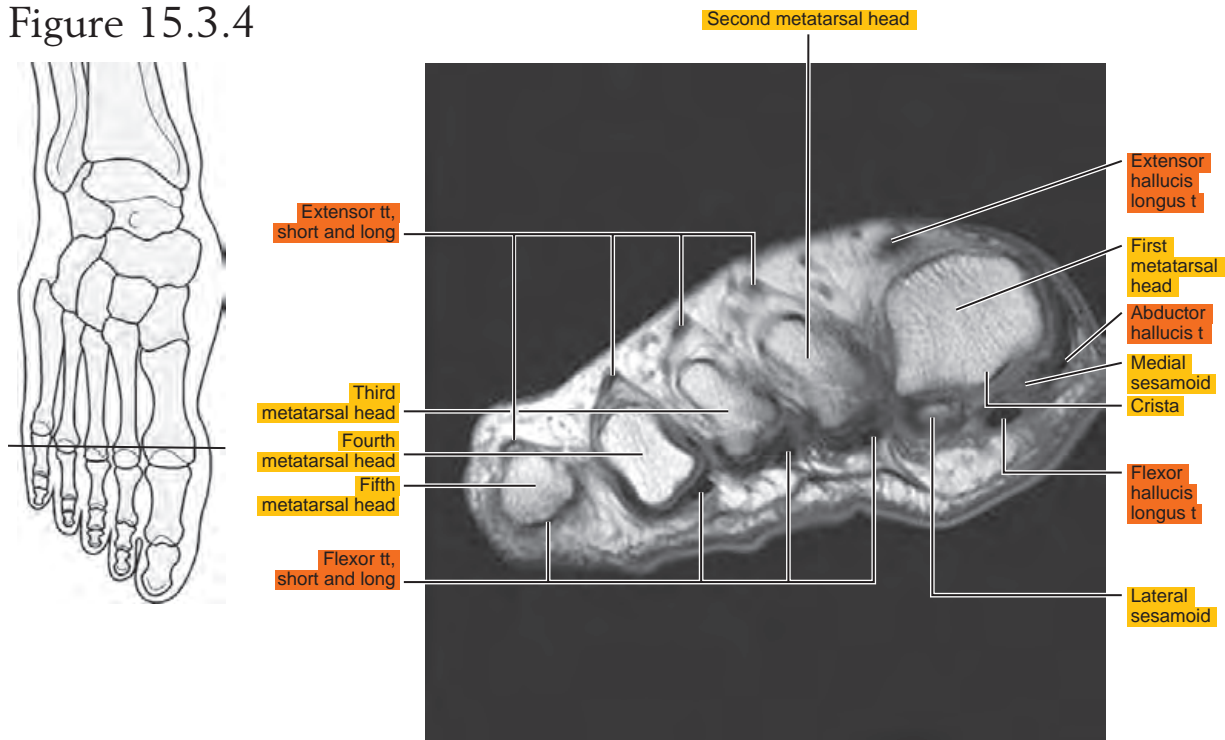


Figure 15.3.5

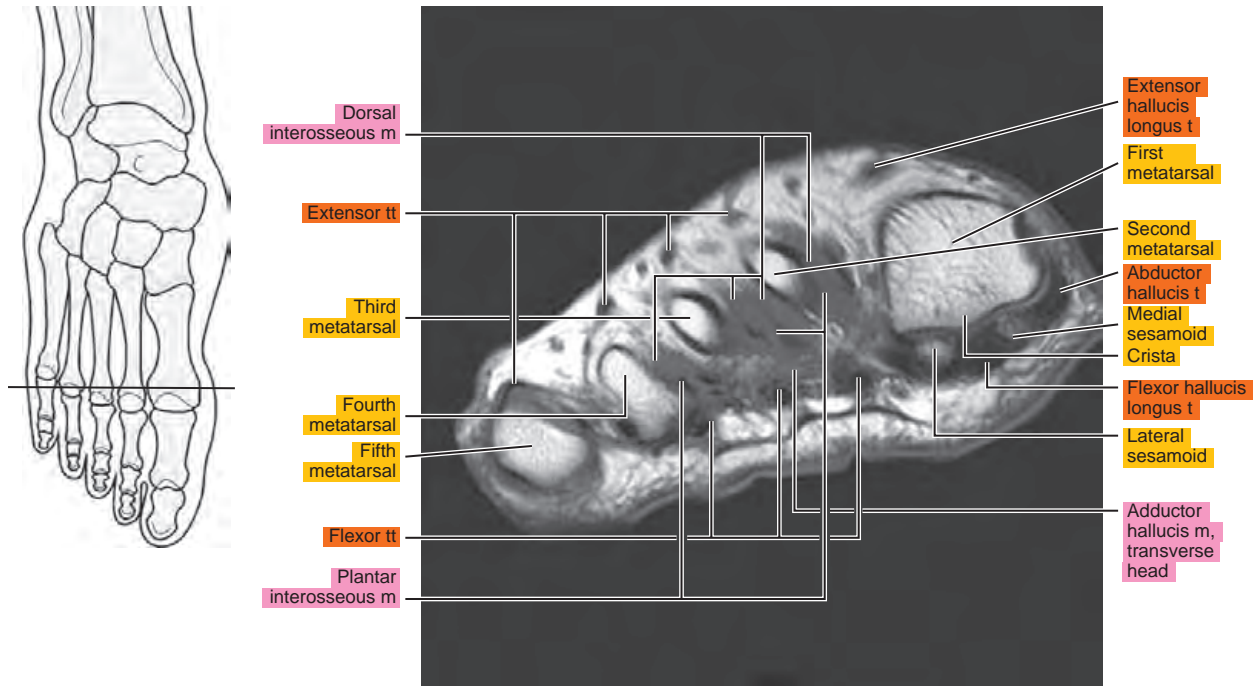


Figure 15.3.6

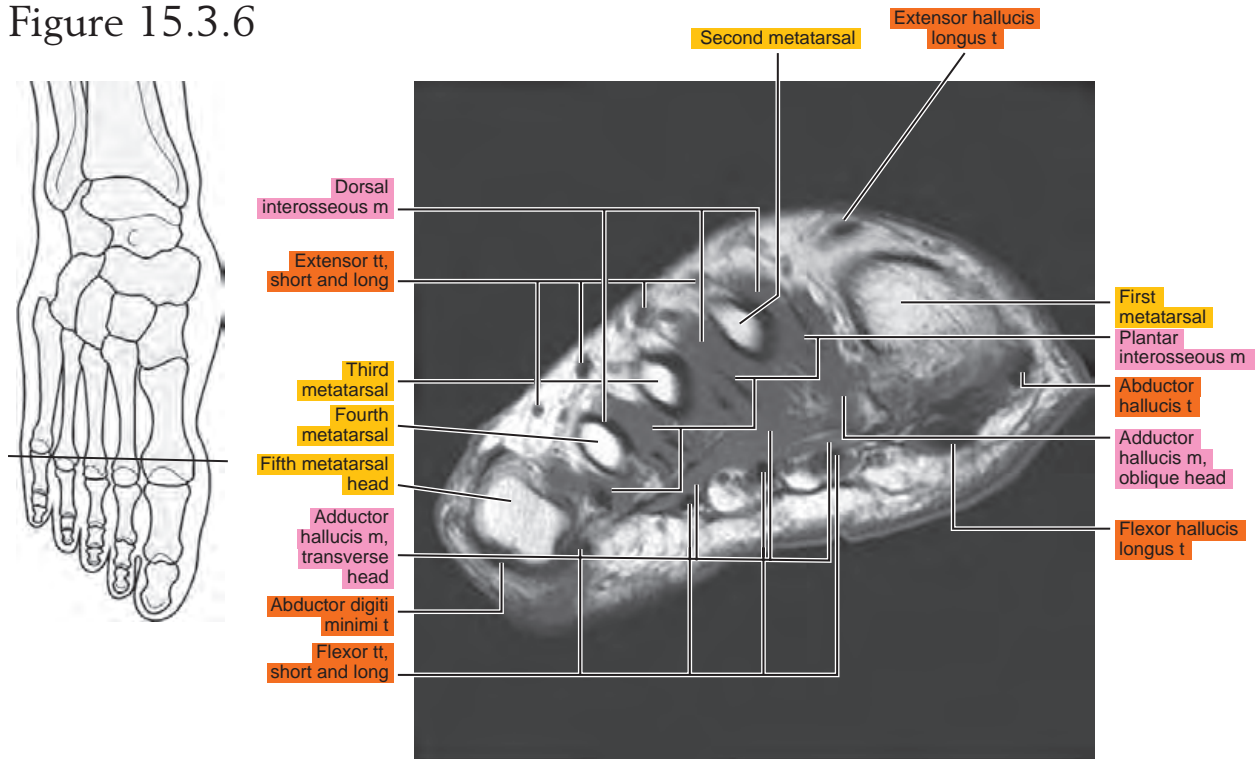


Figure 15.3.7

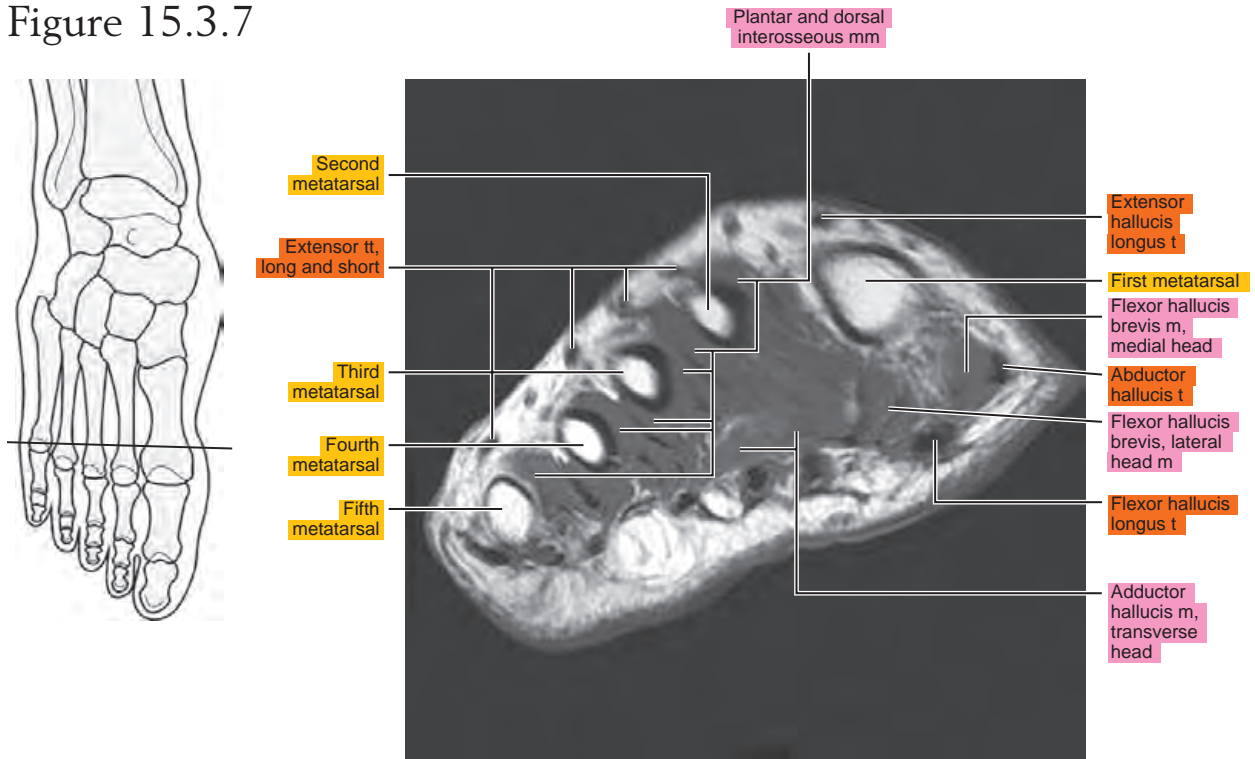


Figure 15.3.8

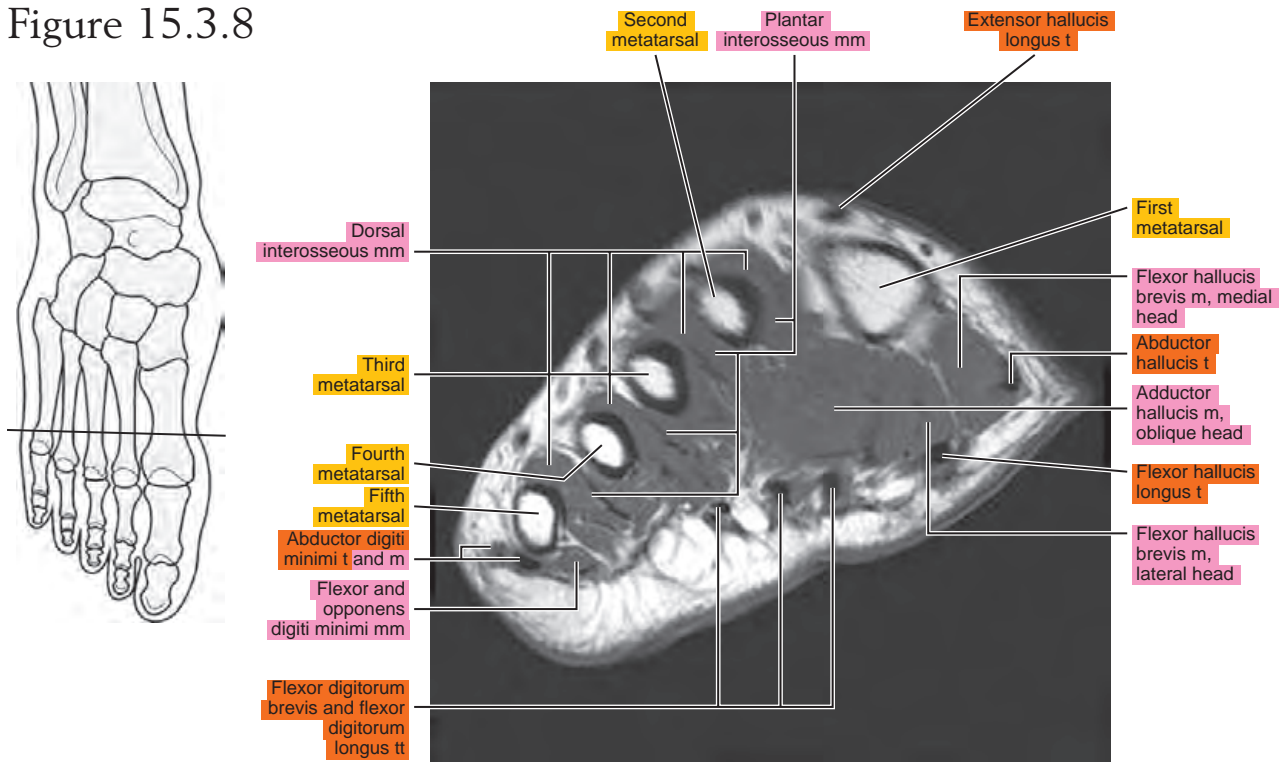


Figure 15.3.9

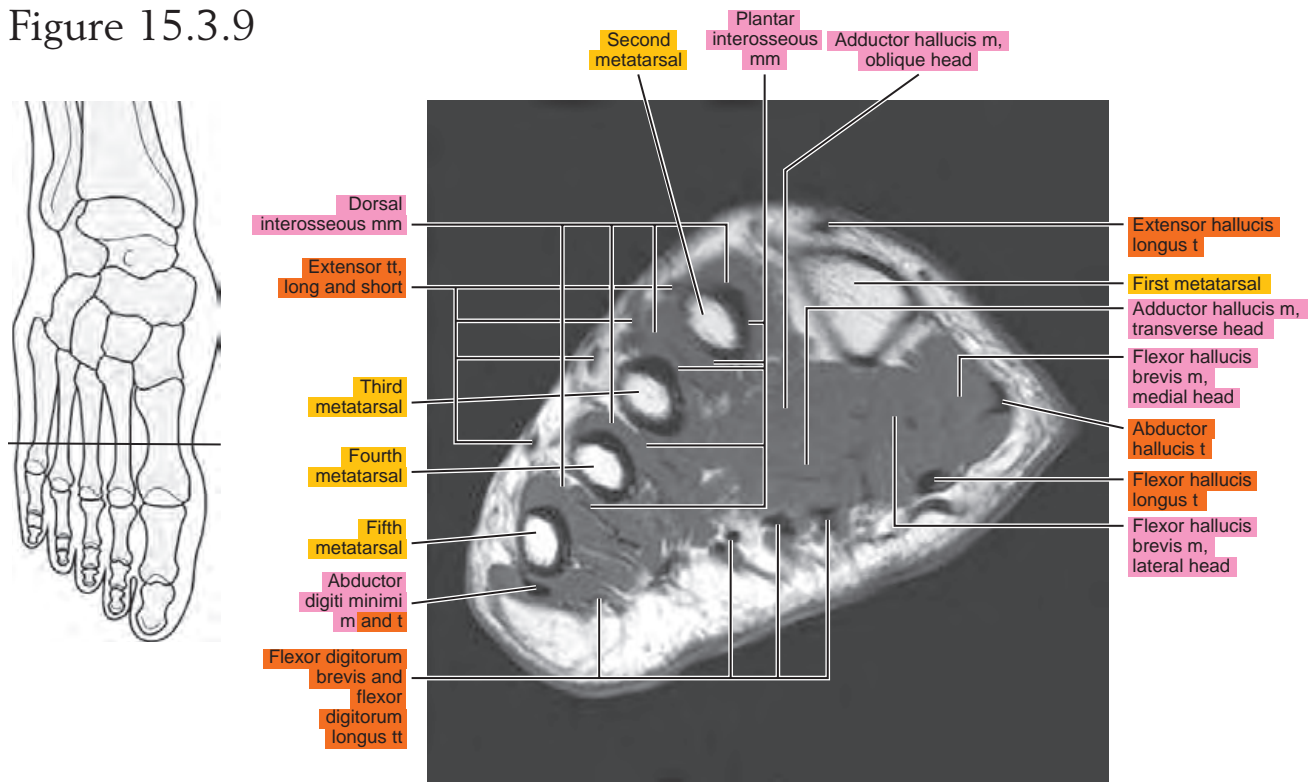


Figure 15.3.10

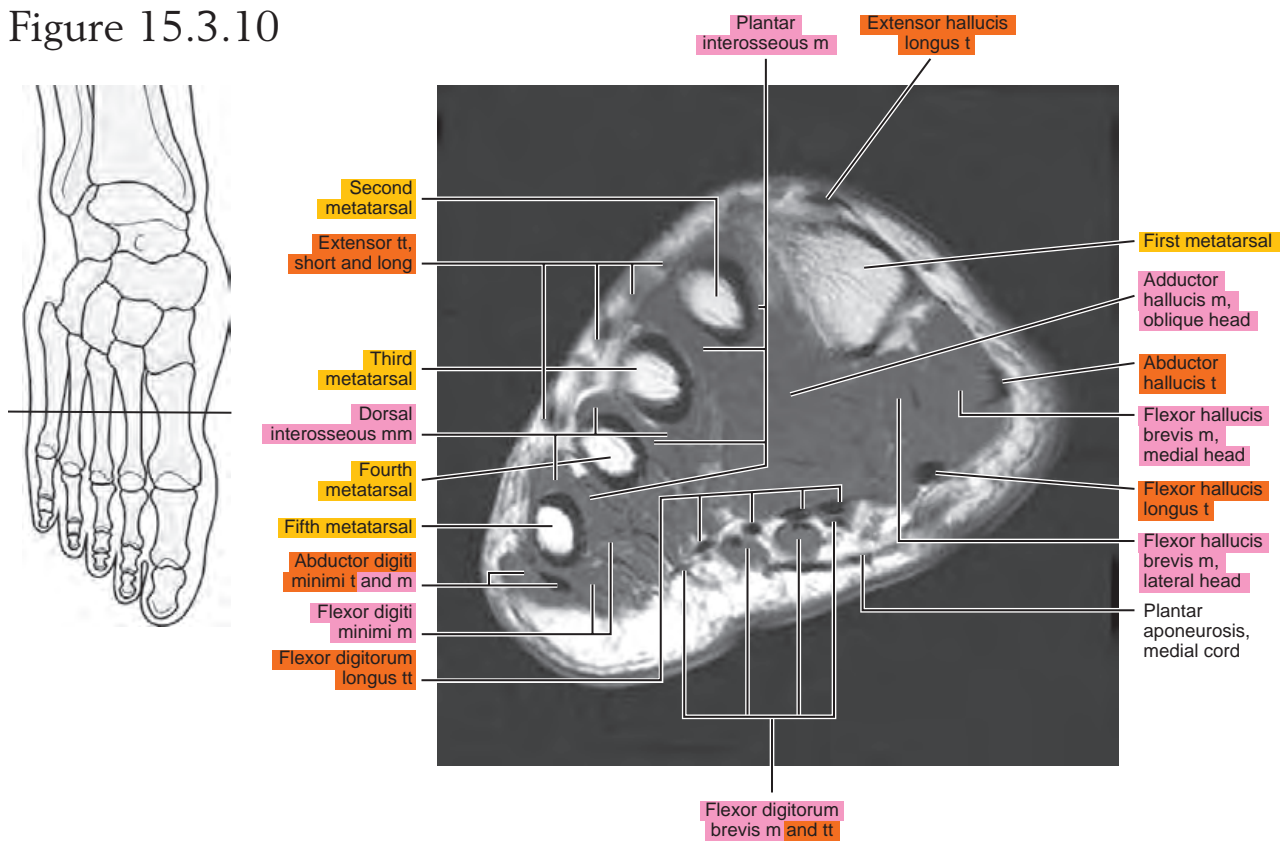


Figure 15.3.11

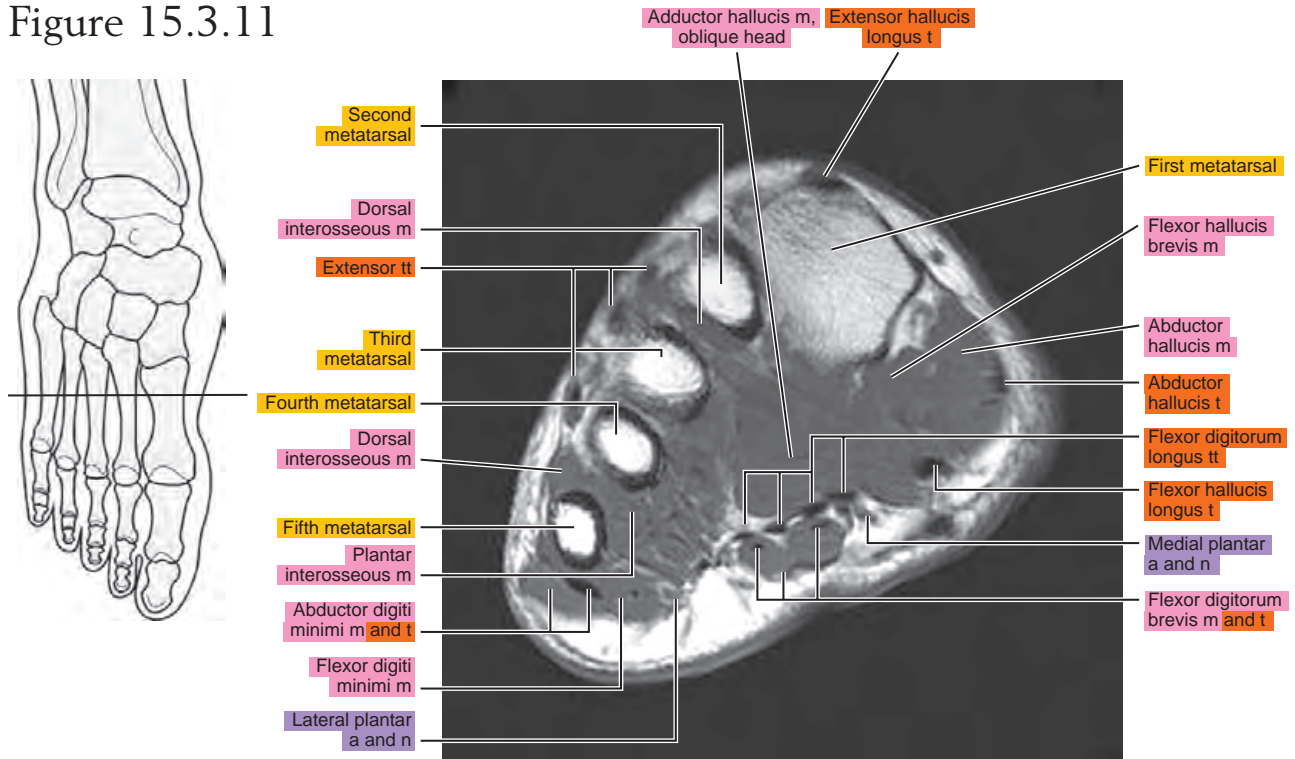


Figure 15.3.12

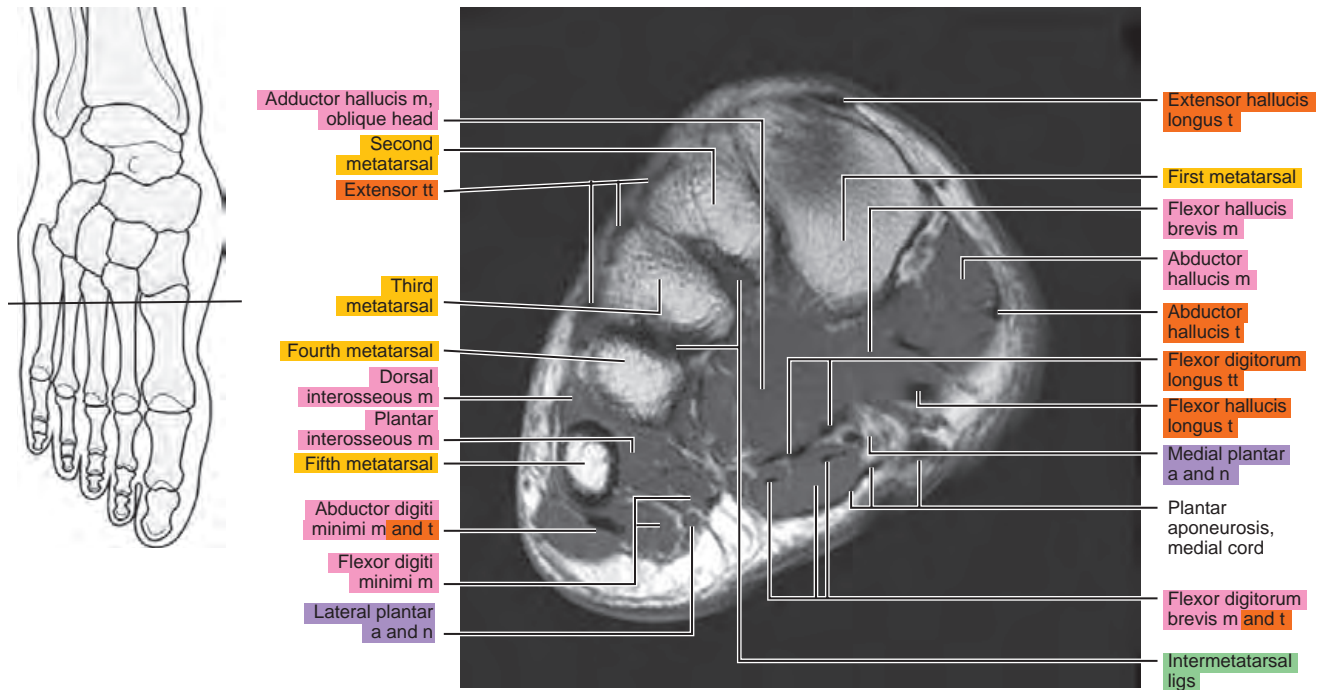


Figure 15.3.13

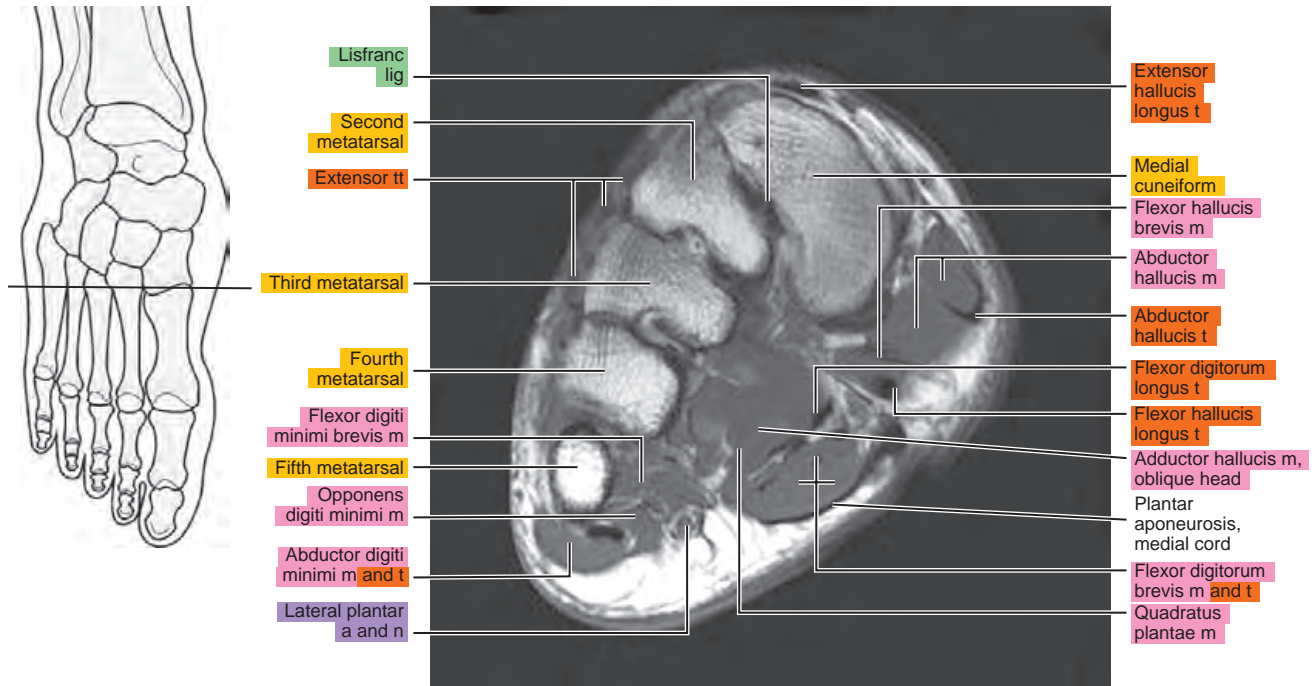


Figure 15.3.14

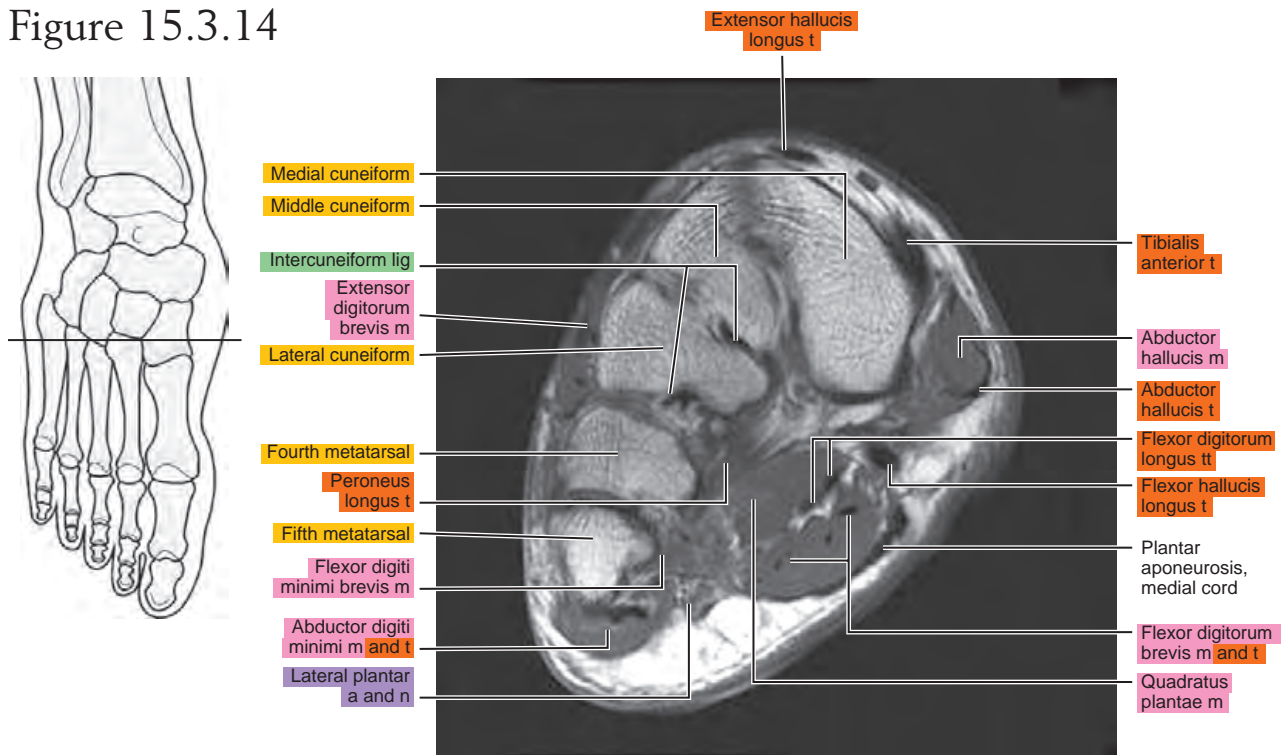


Figure 15.3.15

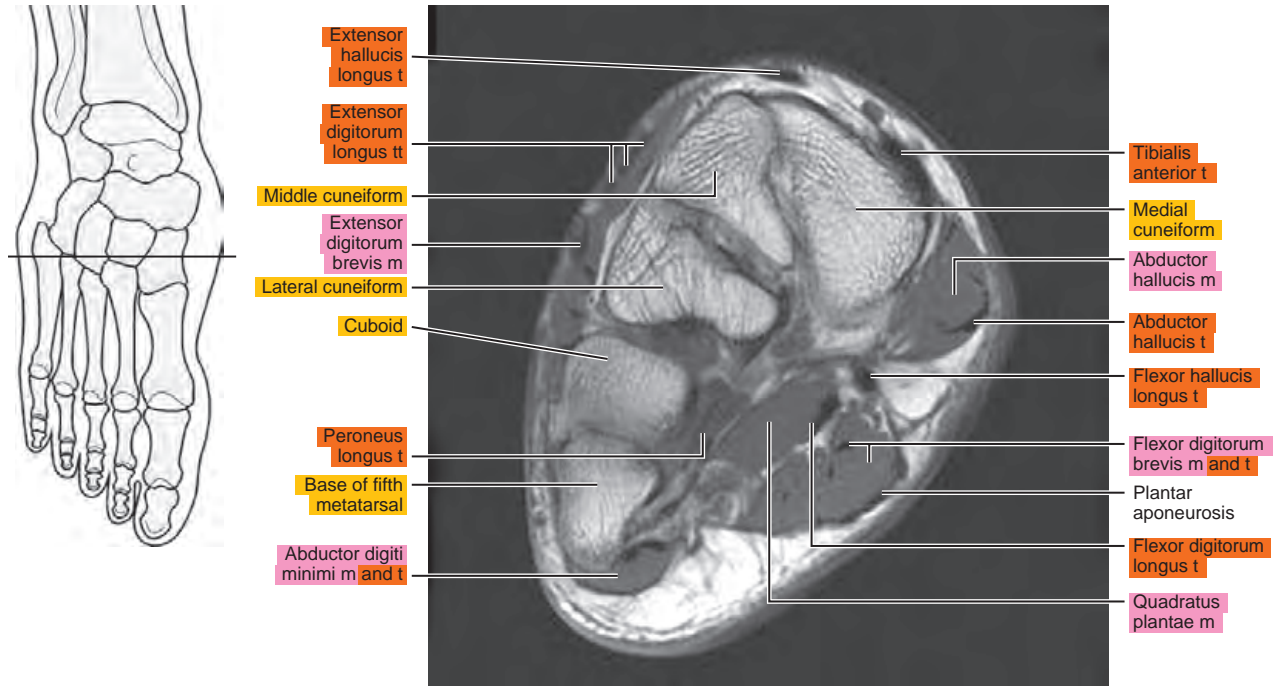


Figure 15.3.16

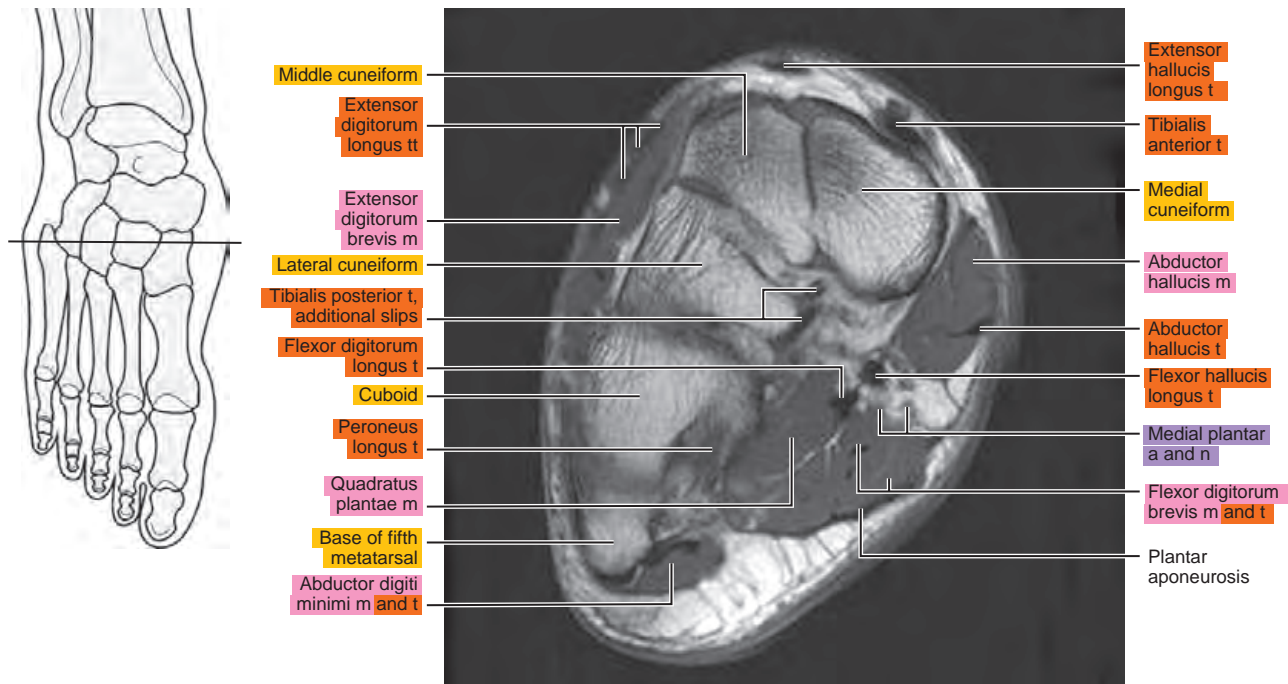


Figure 15.3.17

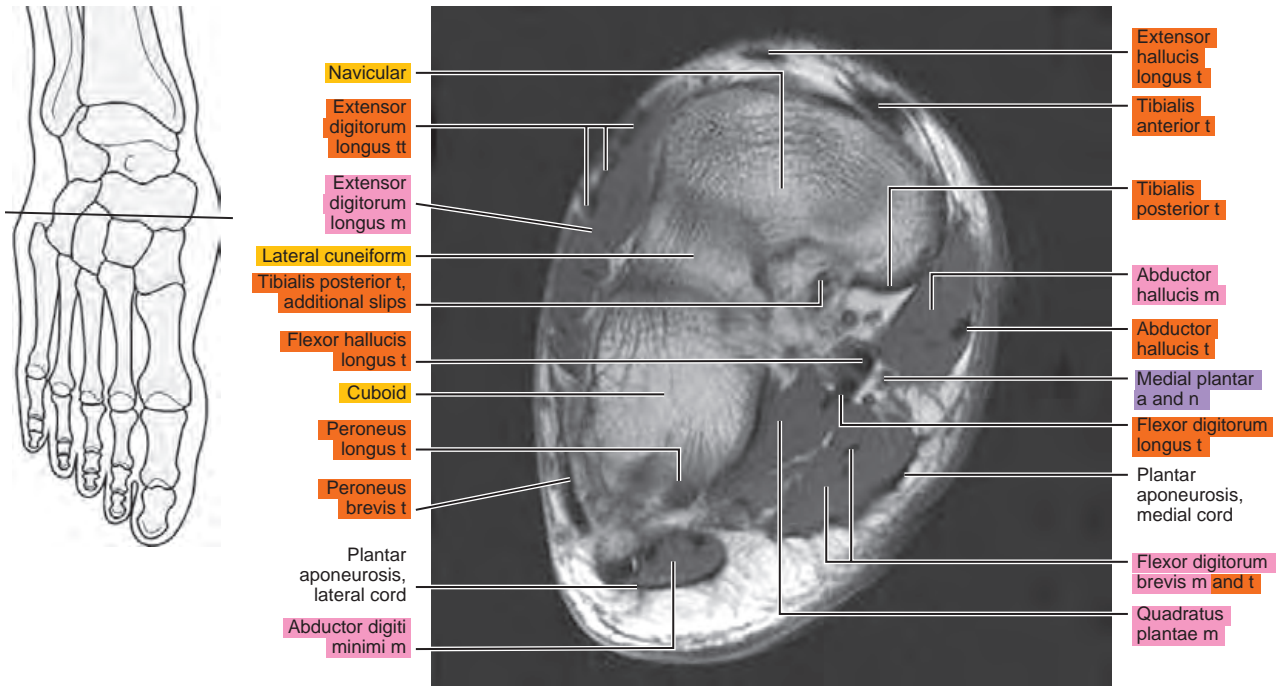
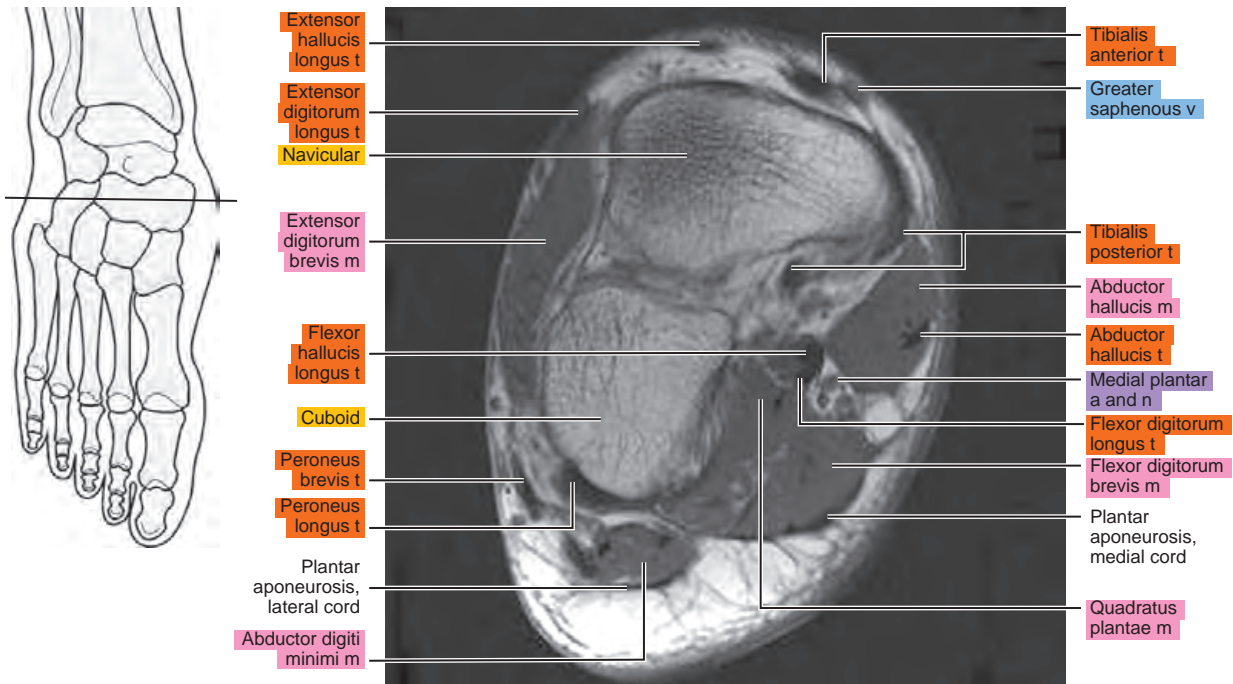


Figure 15.3.18



This page intentionally left blank

III
Section

Spine and Back

This page intentionally left blank

Chapter
16

MRI of the Thoracic Spine

Table 16-1. Muscles of the Back

MUSCLE	ORIGIN	INSERTION	NERVE SUPPLY
Trapezius	Medial third of the superior nuchal line, external occipital protuberance, ligamentum nuchae, spinous processes of the seventh cervical and thoracic vertebrae, and corresponding supraspinous ligaments	Lateral third of the posterior surface of the clavicle, medial side of the acromion, and upper border of the spine of the scapula	Accessory and cervical plexus
Rhomboideus major	Spinous processes and corresponding supraspinous ligaments of the first four thoracic vertebrae	Medial border of the scapula below the scapular spine	Dorsal scapular
Rhomboideus minor	Spinous processes of the sixth and seventh cervical vertebrae	Medial margin of the scapula above the scapular spine	Dorsal scapular
Levator scapulae	Posterior tubercles of the transverse processes of the four upper cervical vertebrae	Superior angle of the scapula	Dorsal scapular
Serratus posterior superior	From spinous processes of the two lower cervical and two upper thoracic vertebrae	Onto the lateral side of the angles of the second to fifth ribs	First to fourth intercostal
Serratus posterior inferior	With latissimus dorsi, from the spinous processes of the two lower thoracic and two upper lumbar vertebrae	Onto the lower borders of the last four ribs	Ninth to twelfth intercostal
Serratus anterior	From the center of the lateral aspect of the first eight or nine ribs	Superior and inferior angles and intervening medial margin of the scapula	Long thoracic from brachial plexus
Deltoid	Lateral third of the clavicle, lateral border of the acromion process, lower border of the scapular spine	Lateral margin of the proximal half of the humeral shaft	Axillary from fifth and sixth cervical nerves through brachial plexus
Latissimus dorsi	Spinous processes of the lower five or six thoracic and lumbar vertebrae, median ridge of the sacrum, and outer lip of the iliac crest	With teres major, onto the medial border of the bicipital groove of the humerus	Thoracodorsal
Infraspinatus	Infraspinous fossa of the scapula	Middle facet of the greater tuberosity of the humerus	Suprascapular from fifth to sixth cervical
Supraspinatus	Supraspinous fossa of the scapula	Greater tuberosity of the humerus	Suprascapular from fifth to sixth cervical
Teres major	Inferior angle and lower third of the border of the scapula	Medial border of the bicipital groove of the humerus	Lower subscapular from fifth and sixth cervical
Teres minor	Upper two thirds of the lateral border of the scapula	Lower facet of the greater tuberosity of the humerus	Axillary from fifth and sixth cervical
Spinalis capitis	Rarely a separate muscle; it arises with the semispinalis capitis from the upper thoracic spinous process	Inserts with the semispinalis capitis on the occiput	Branches of the dorsal primary divisions of the spinal nerves
Spinalis cervicis	Spinous processes of the sixth and seventh cervical vertebrae	Spinous processes of the axis and the third cervical vertebra	Dorsal branches of cervical
Spinalis thoracis	Spinous processes of the upper lumbar and two lower thoracic vertebrae	Spinous processes of the middle and upper thoracic vertebrae	Dorsal branches of thoracic and upper lumbar

Table 16-1. Muscles of the Back—cont’d

MUSCLE	ORIGIN	INSERTION	NERVE SUPPLY
Iliocostalis cervicis	Angles of the upper six ribs	Transverse processes of the middle cervical vertebrae	Dorsal branches of upper thoracic
Iliocostalis thoracis	Medial side of the angles of the lower six ribs	Angles of the upper six ribs	Dorsal branches of thoracic
Iliocostalis lumborum	With erector spinae, from the sacrum, ilium, and spines of the lumbar vertebrae	Angles of the lower six ribs	Dorsal branches of thoracic and lumbar nerves
Longissimus capitis	From the transverse processes of the upper thoracic and transverse and articular processes of the lower and middle cervical vertebrae	Onto the mastoid process	Dorsal branches of cervical
Longissimus cervicis	Transverse processes of the upper thoracic vertebrae	Transverse processes of the middle and upper cervical vertebrae	Dorsal branches of lower cervical and upper thoracic
Longissimus thoracis	With the iliocostalis and from the transverse processes of the lower thoracic vertebrae	By lateral slips onto most or all of the ribs between the angles and the tubercles and onto the tips of the transverse processes of the upper lumbar vertebrae, and by medial slips into the accessory processes of the upper lumbar and transverse processes of the thoracic vertebrae	Dorsal branches of thoracic and lumbar
Splenius capitis	From the ligamentum nuchae of the last four cervical vertebrae and the supraspinous ligament of first and second thoracic vertebrae	Lateral half of the superior nuchal line and mastoid process	Dorsal branches of second to sixth cervical
Splenius cervicis	From the supraspinous ligament and the spinous processes of the third to fifth thoracic vertebrae	Posterior tubercles of the transverse processes of the first and second (sometimes third) cervical vertebrae	Dorsal branches of fourth to eighth cervical
Semispinalis capitis	Transverse processes of the five or six upper thoracic and articular processes of the four lower cervical vertebrae	Occipital bone between the superior and inferior nuchal lines	Dorsal branches of cervical
Semispinalis cervicis	Transverse processes of the second to fifth thoracic vertebrae	Spinous processes of the axis and the third to fifth cervical vertebrae	Dorsal branches of cervical and thoracic
Semispinalis thoracis	Transverse processes of the fifth to eleventh thoracic vertebrae	Spinous processes of the first four thoracic and fifth and seventh cervical vertebrae	Dorsal branches of cervical and thoracic
Multifidus	From the sacrum, the sacroiliac ligament, mammillary processes of the lumbar vertebrae, transverse processes of the thoracic vertebrae, and articular processes of the last four cervical vertebrae	Onto the spinous processes of all the vertebrae, up to and including the axis	Dorsal branches of spinal
Rotatores	Primarily developed in the thoracic region from the transverse processes of the vertebrae	Into the root of the spinous processes of the next two or three vertebrae above	Dorsal branches of spinal
Interspinales cervicis	Tubercle of the spinous process of the cervical vertebrae	Tubercle of the spinous process of the next superior vertebra	Dorsal branches of cervical

Continued

Table 16-1. Muscles of the Back—cont'd

MUSCLE	ORIGIN	INSERTION	NERVE SUPPLY
Interspinales thoracis	Often poorly developed or absent between the spinous processes of the thoracic vertebrae	Spinous processes of thoracic vertebrae	Dorsal branches of thoracic
Interspinales lumborum	Superior margin of the lumbar spinous processes	Inferior margin of the next superior spinous process	Dorsal branches of lumbar
Intertransversarii anteriores cervicis	Anterior tubercle of the cervical transverse process	Anterior tubercle of the next superior transverse process	Ventral branch of cervical
Intertransversarii laterales lumborum	Transverse processes of the lumbar vertebrae	Next superior transverse process	Ventral branches of lumbar
Intertransversarii thoracis	Transverse processes of the thoracic vertebrae	Next superior transverse process	Dorsal branches of thoracic

AXIAL

Figure 16.1.1

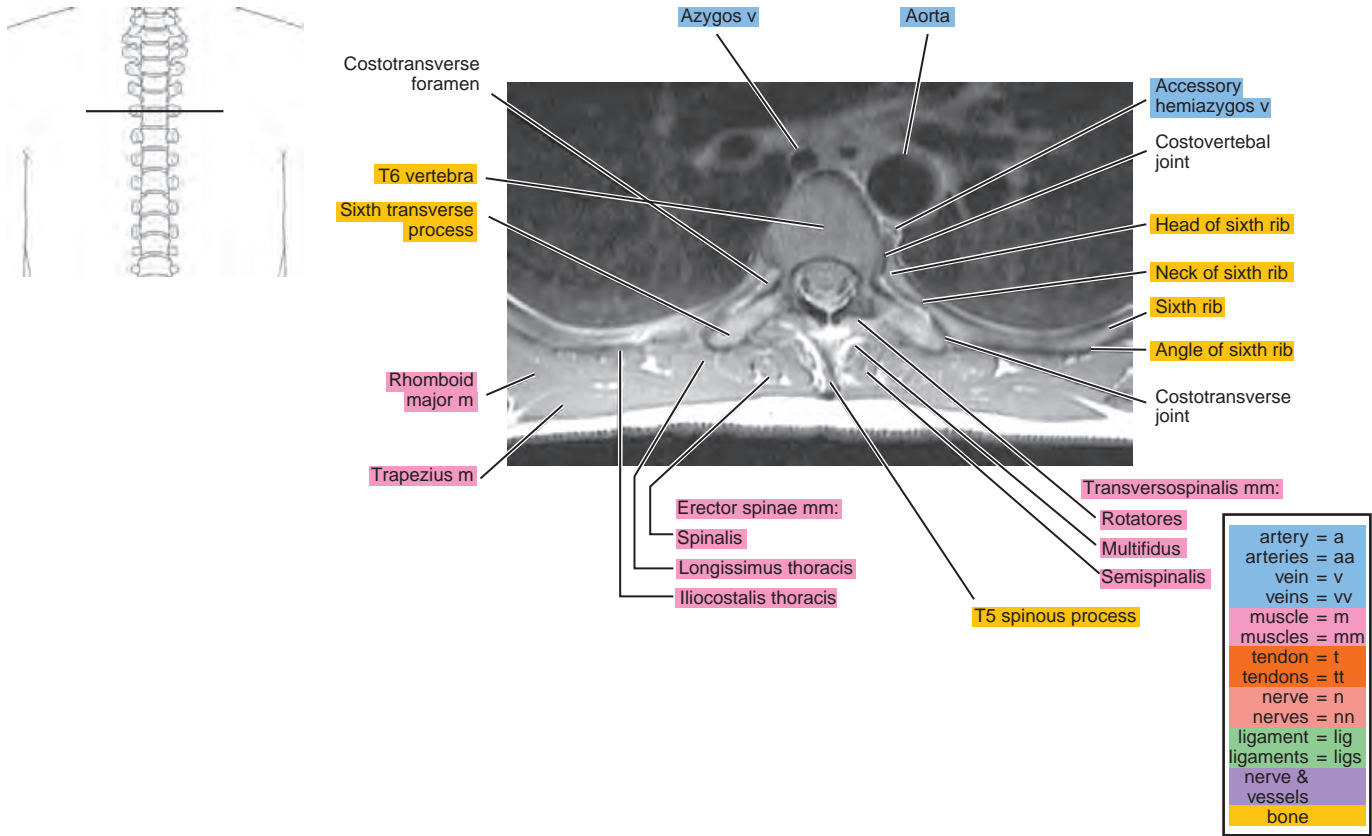


Figure 16.1.2

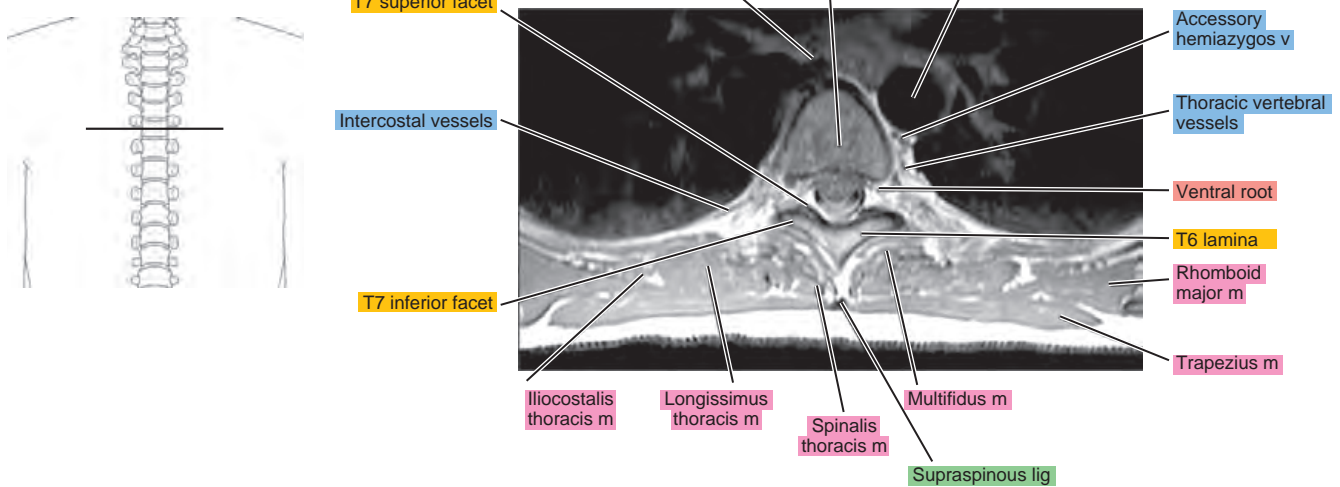


Figure 16.1.3

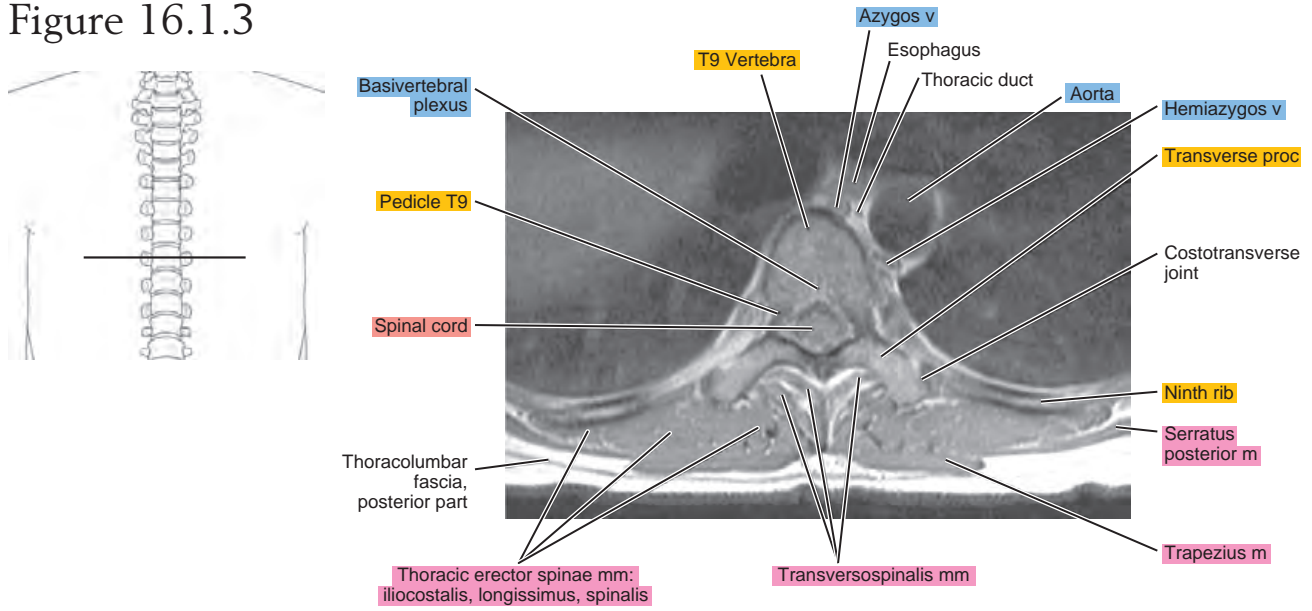
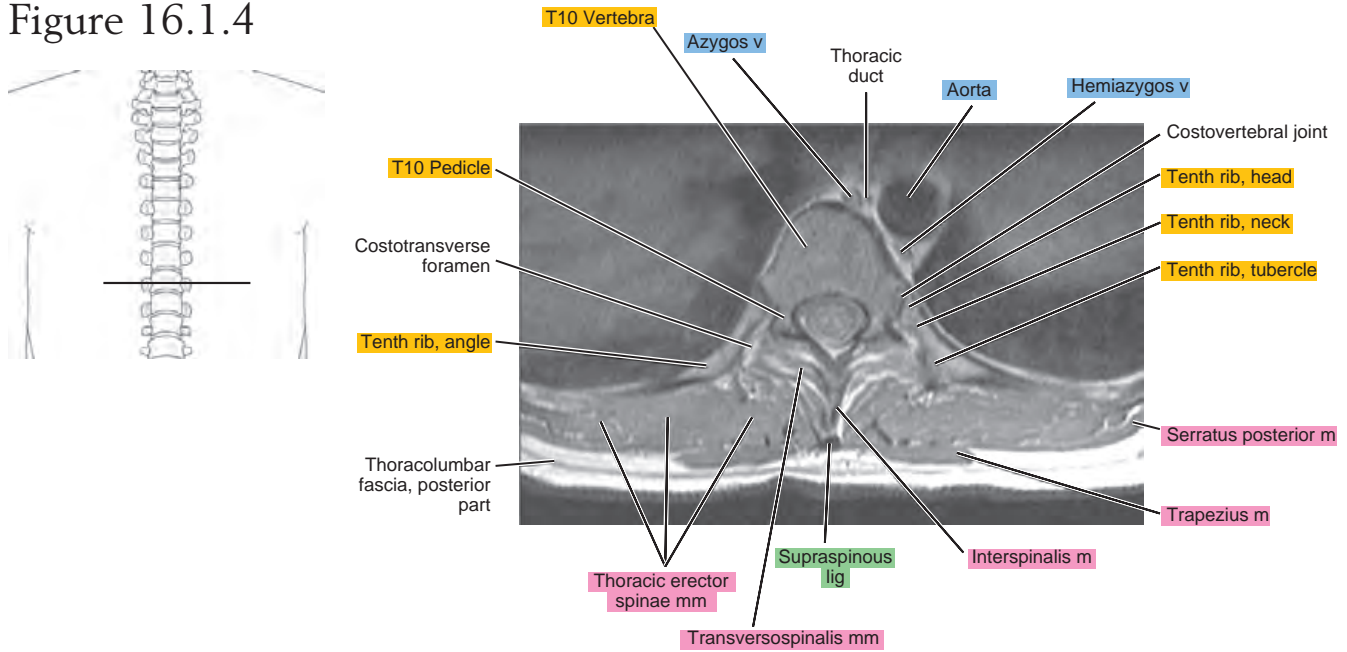


Figure 16.1.4



SAGITTAL

Figure 16.2.1

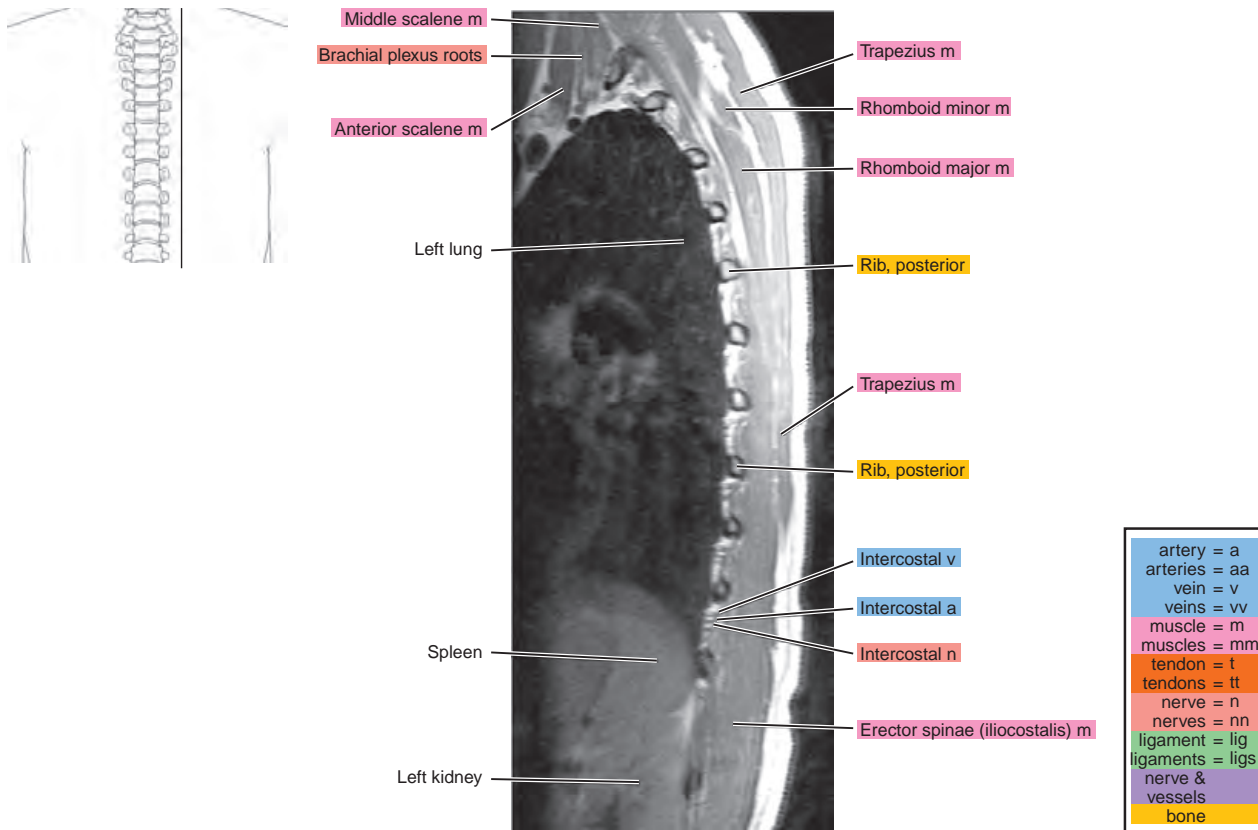


Figure 16.2.2

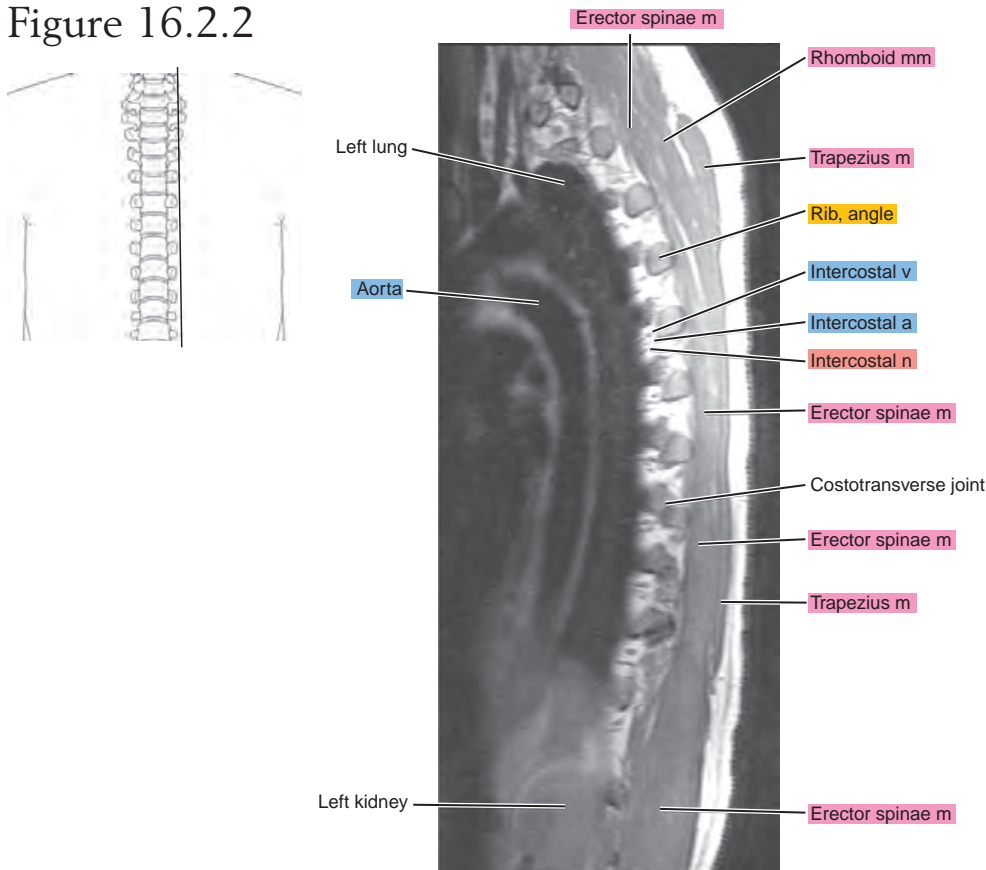


Figure 16.2.3

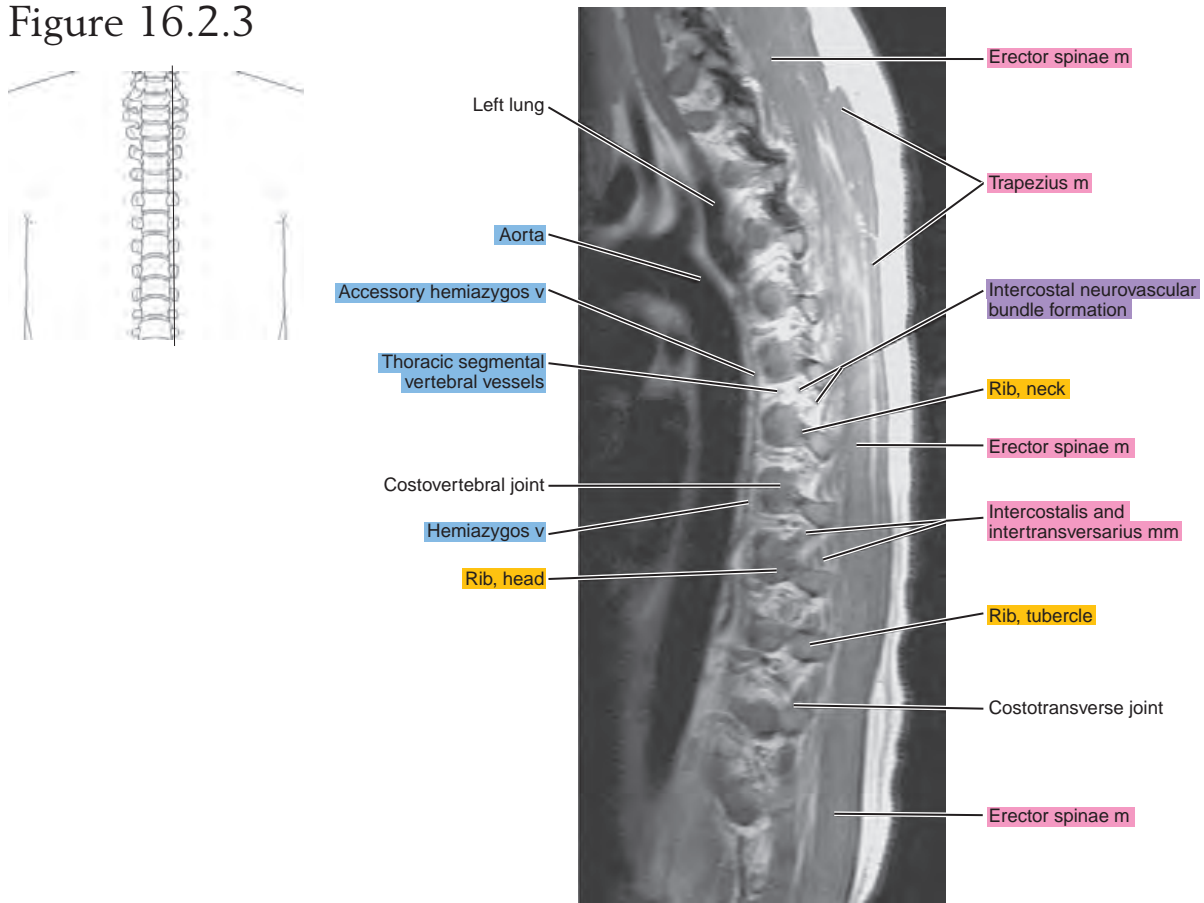


Figure 16.2.4

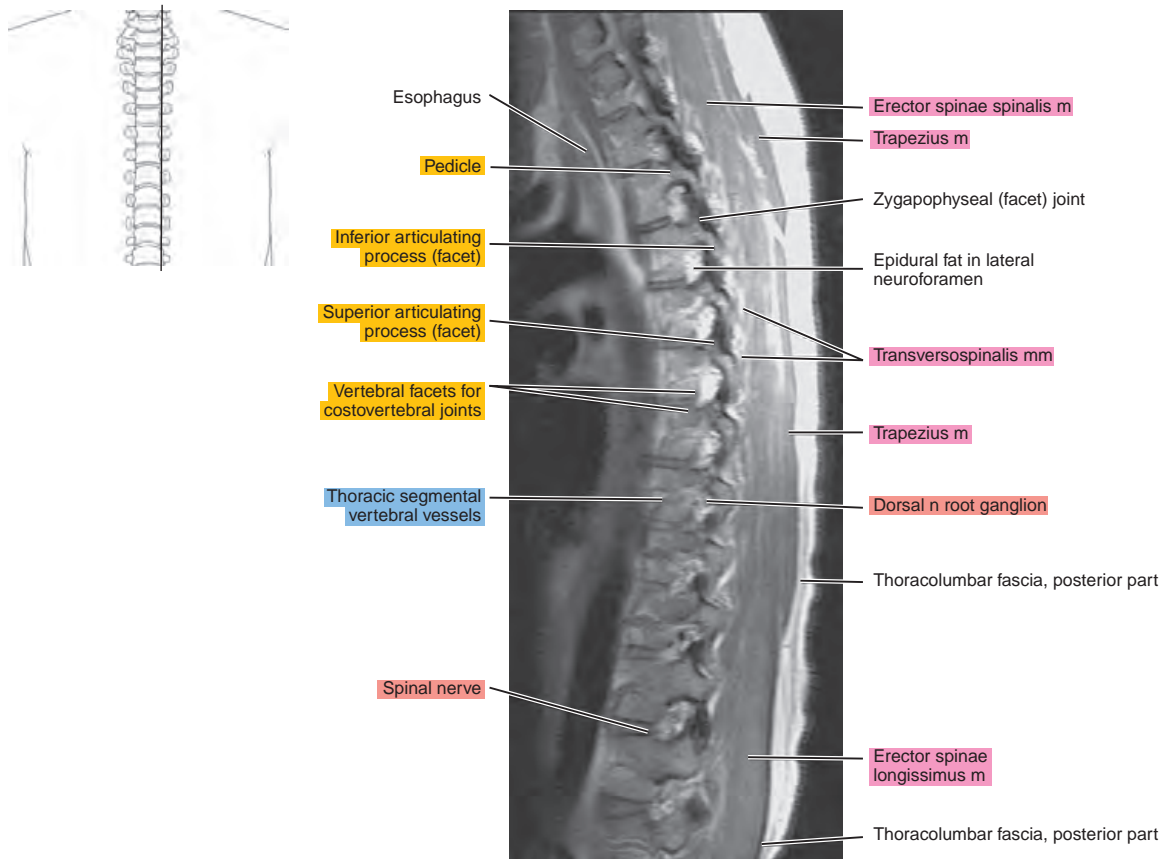


Figure 16.2.5

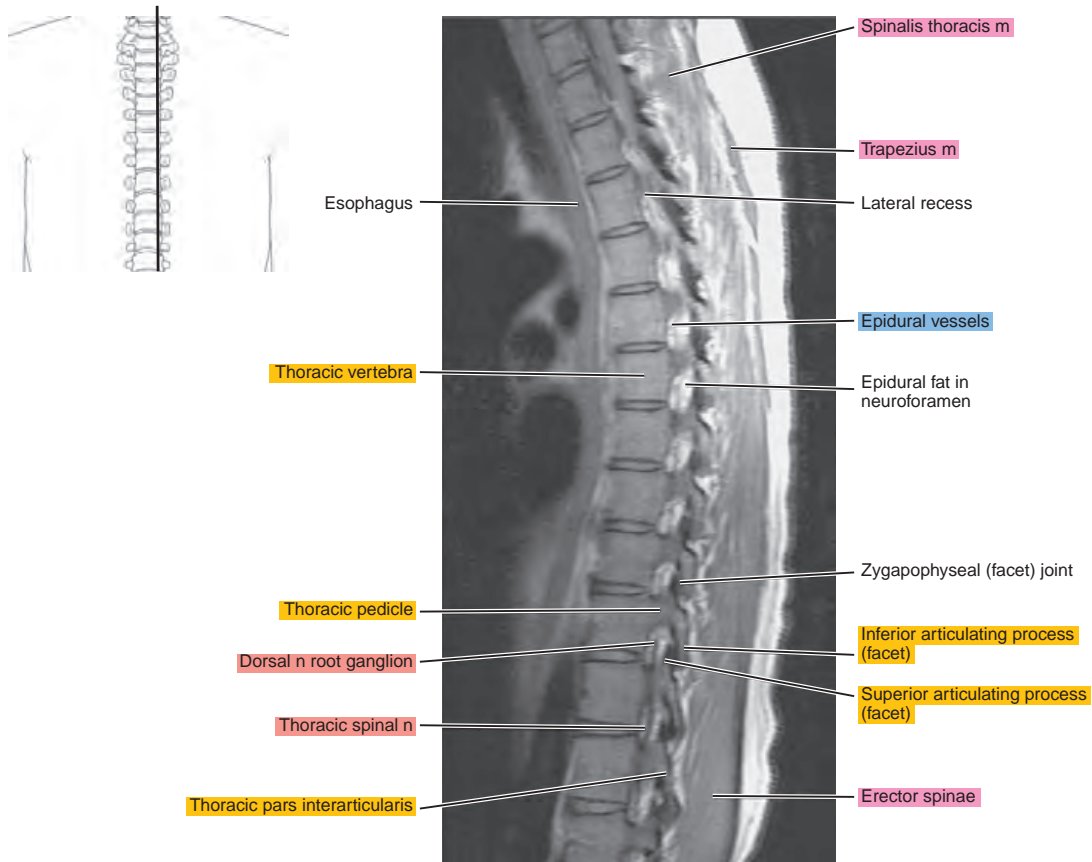
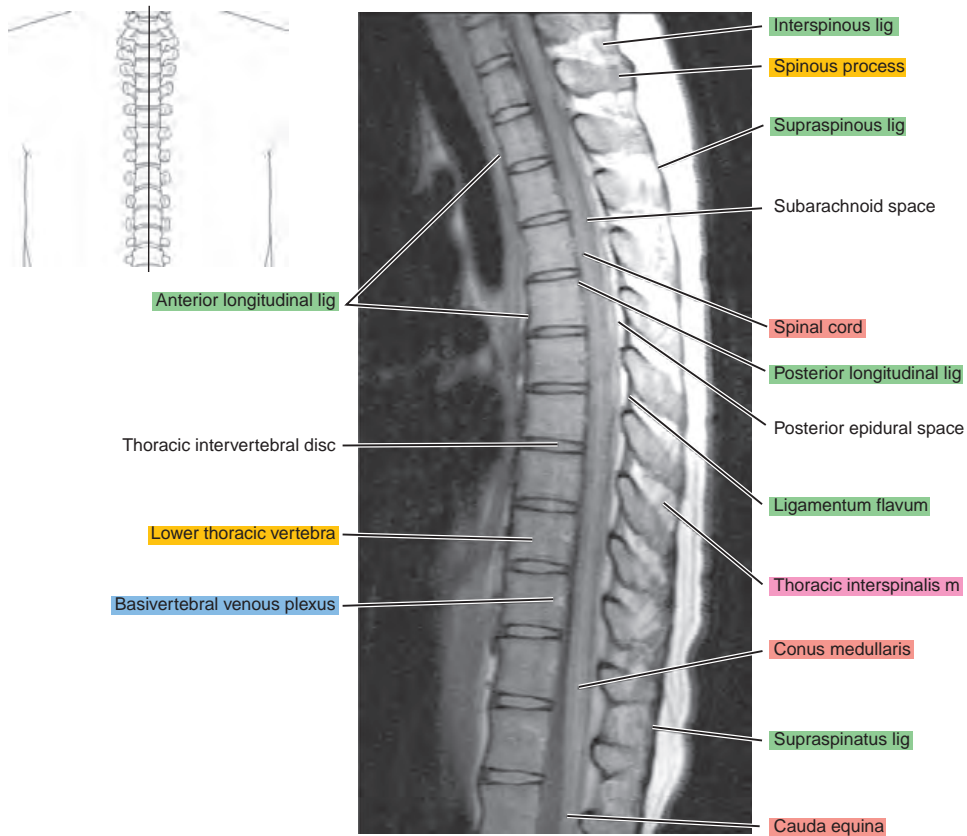


Figure 16.2.6



CORONAL

Figure 16.3.1

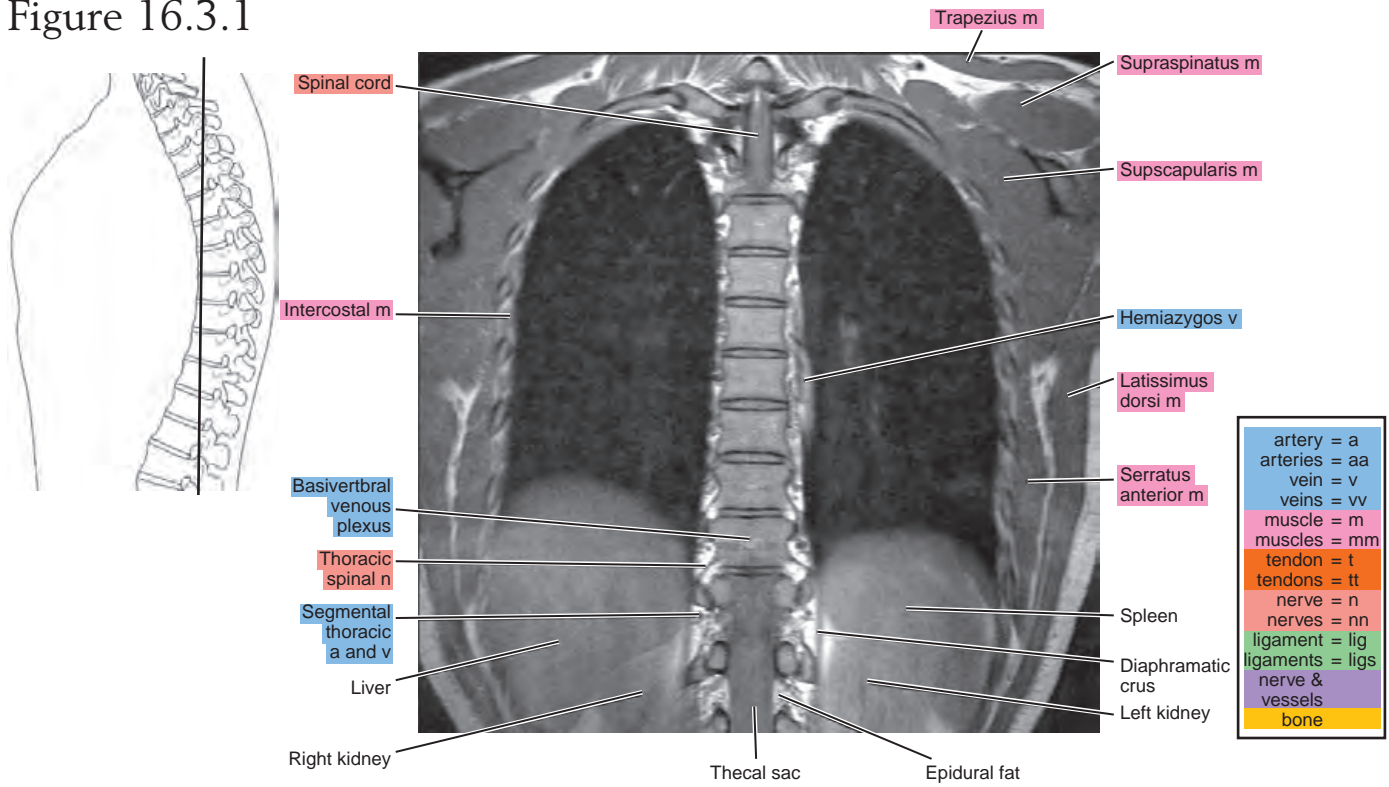


Figure 16.3.2

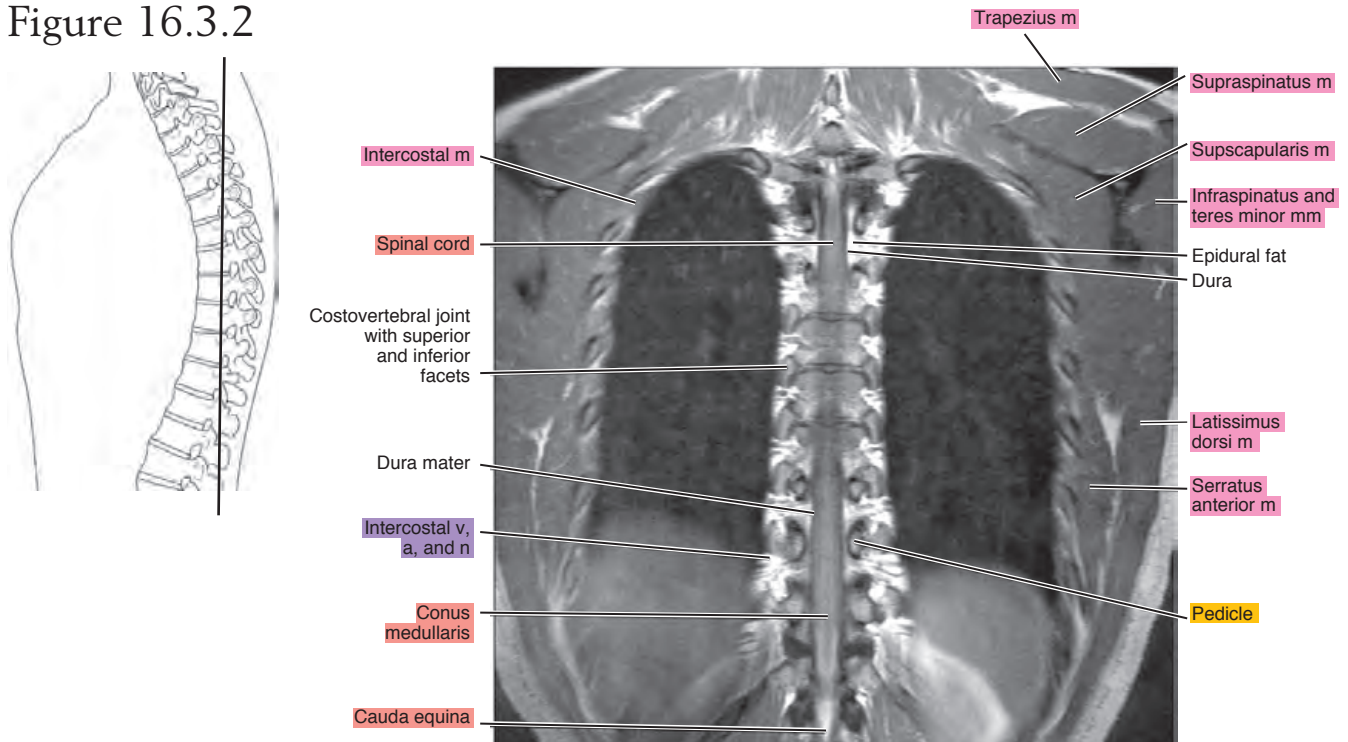


Figure 16.3.3

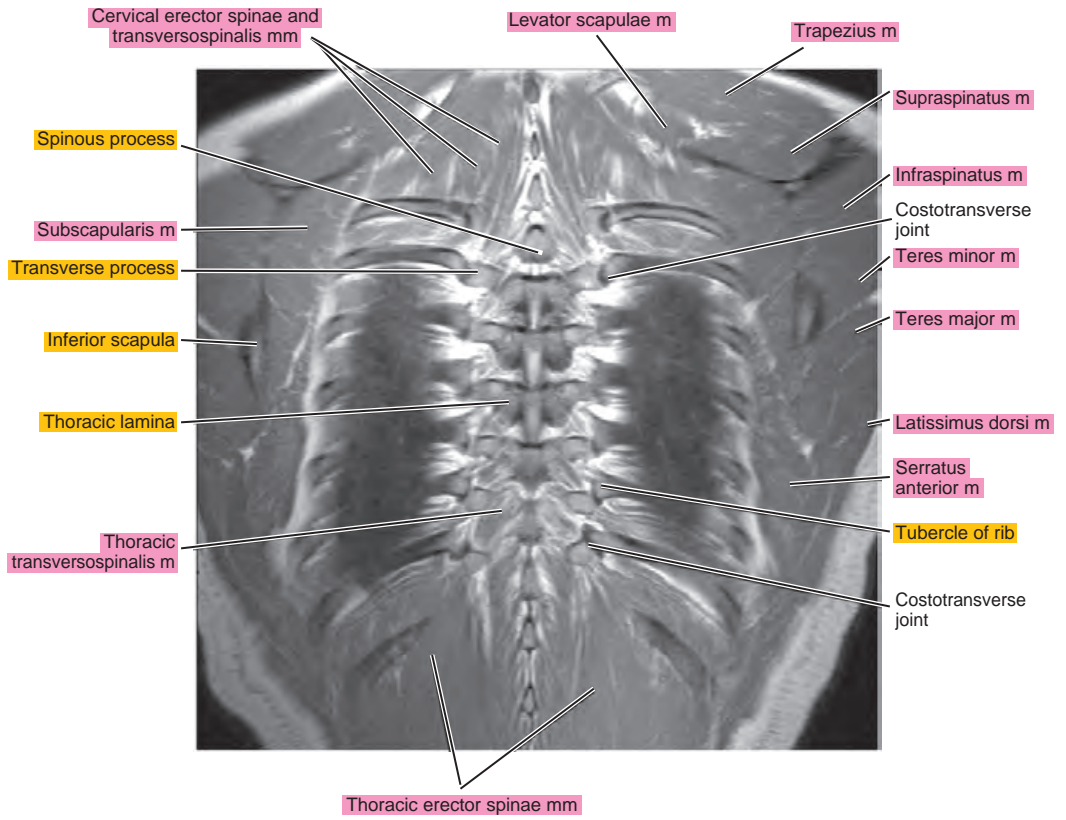
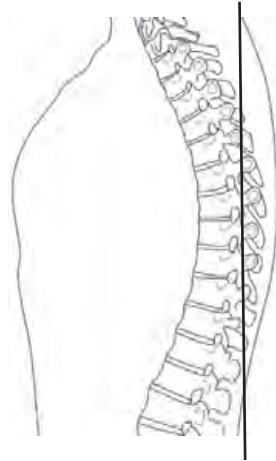


Figure 16.3.4

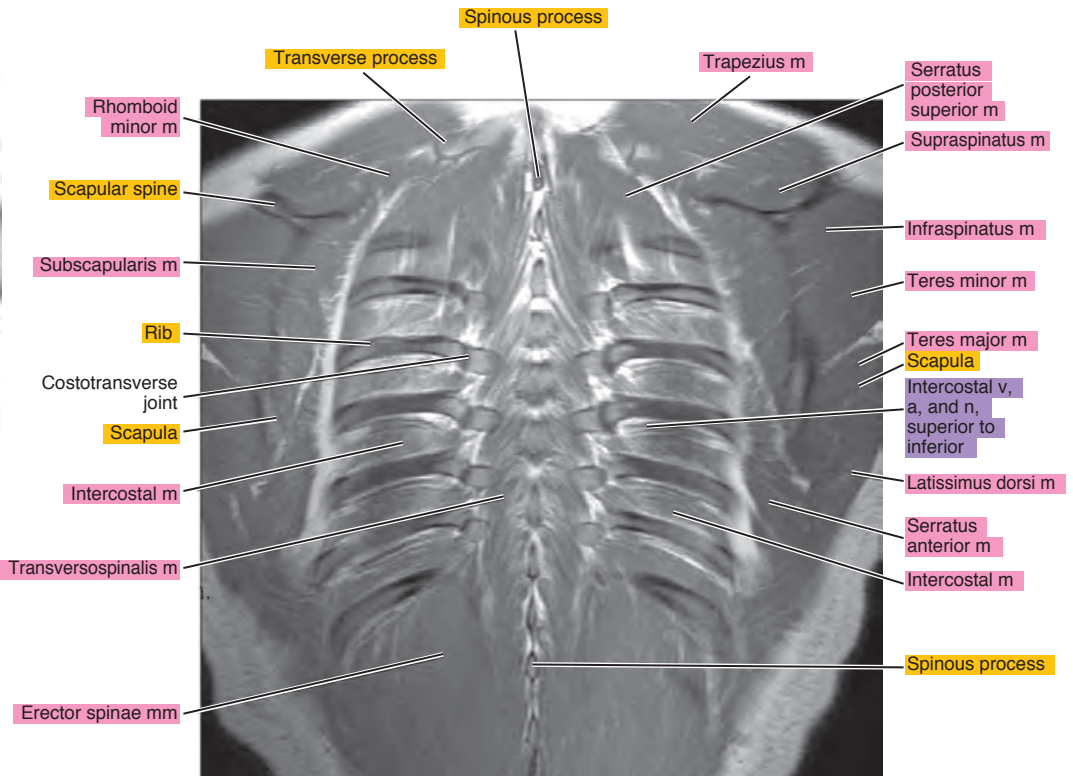
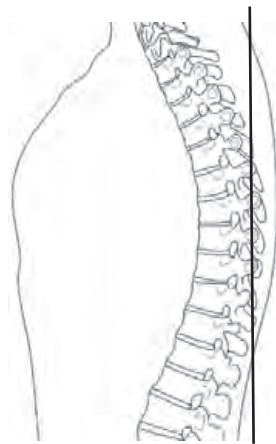


Figure 16.3.5

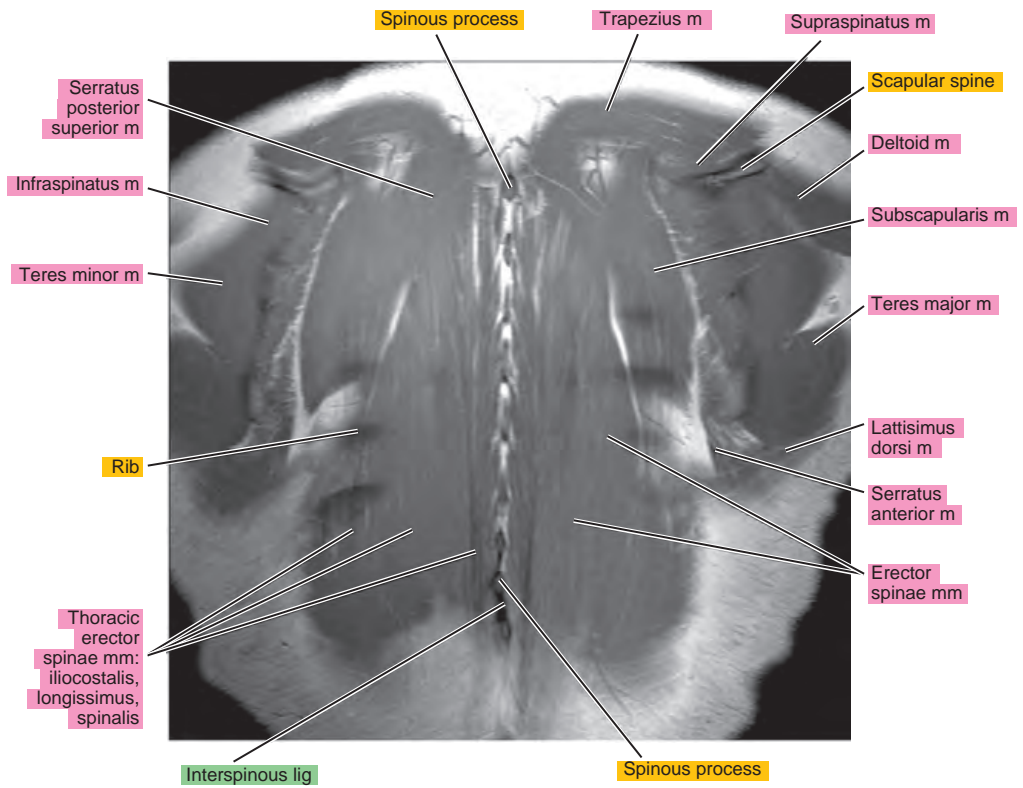
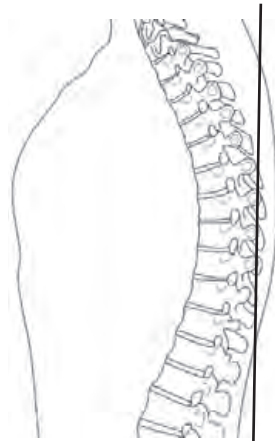


Figure 16.3.6

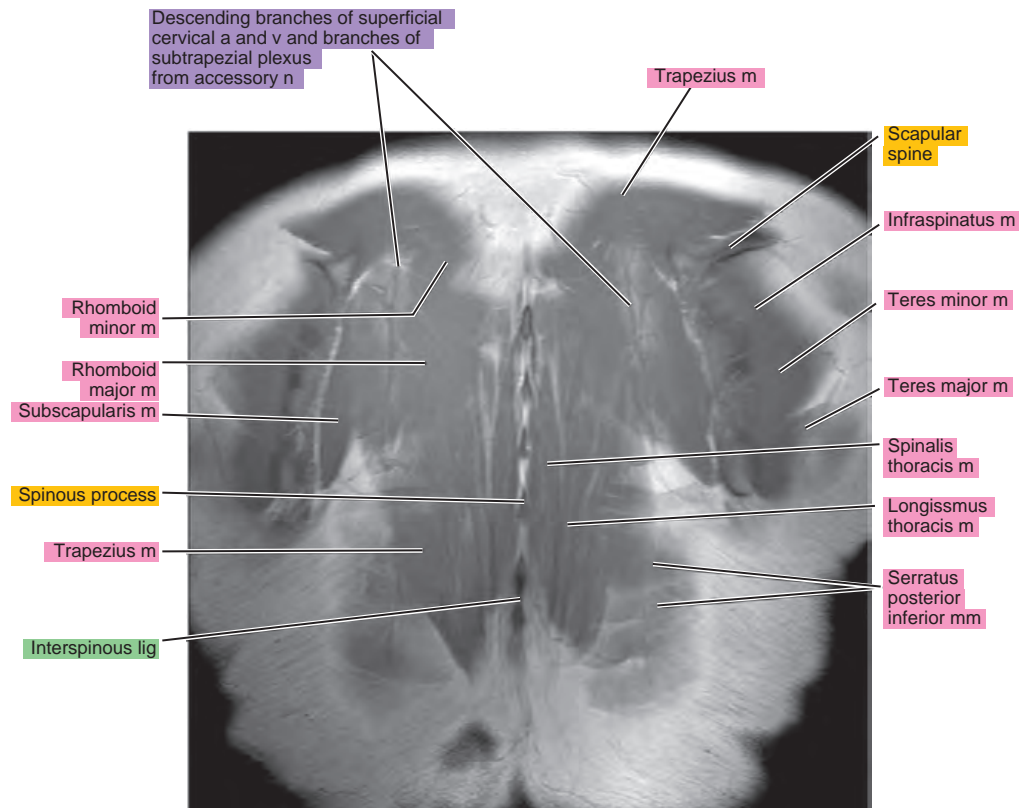
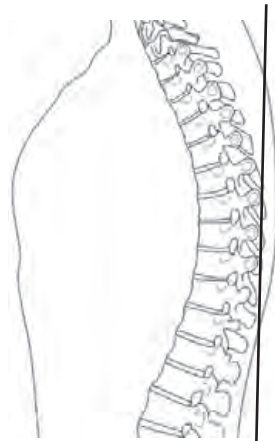
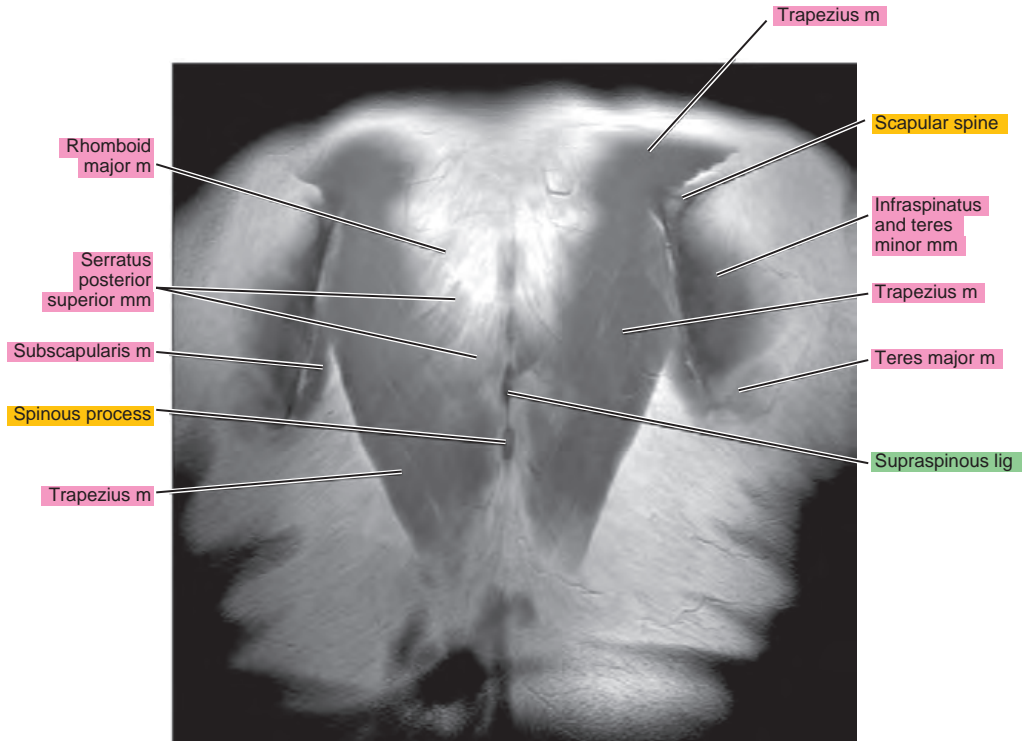
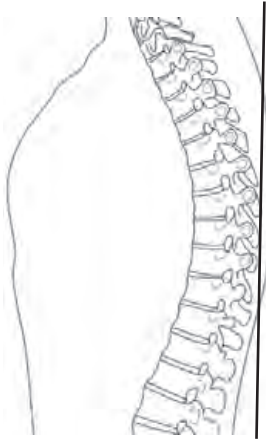


Figure 16.3.7



Chapter
17

MRI of the Lumbar Spine

AXIAL

Figure 17.1.1

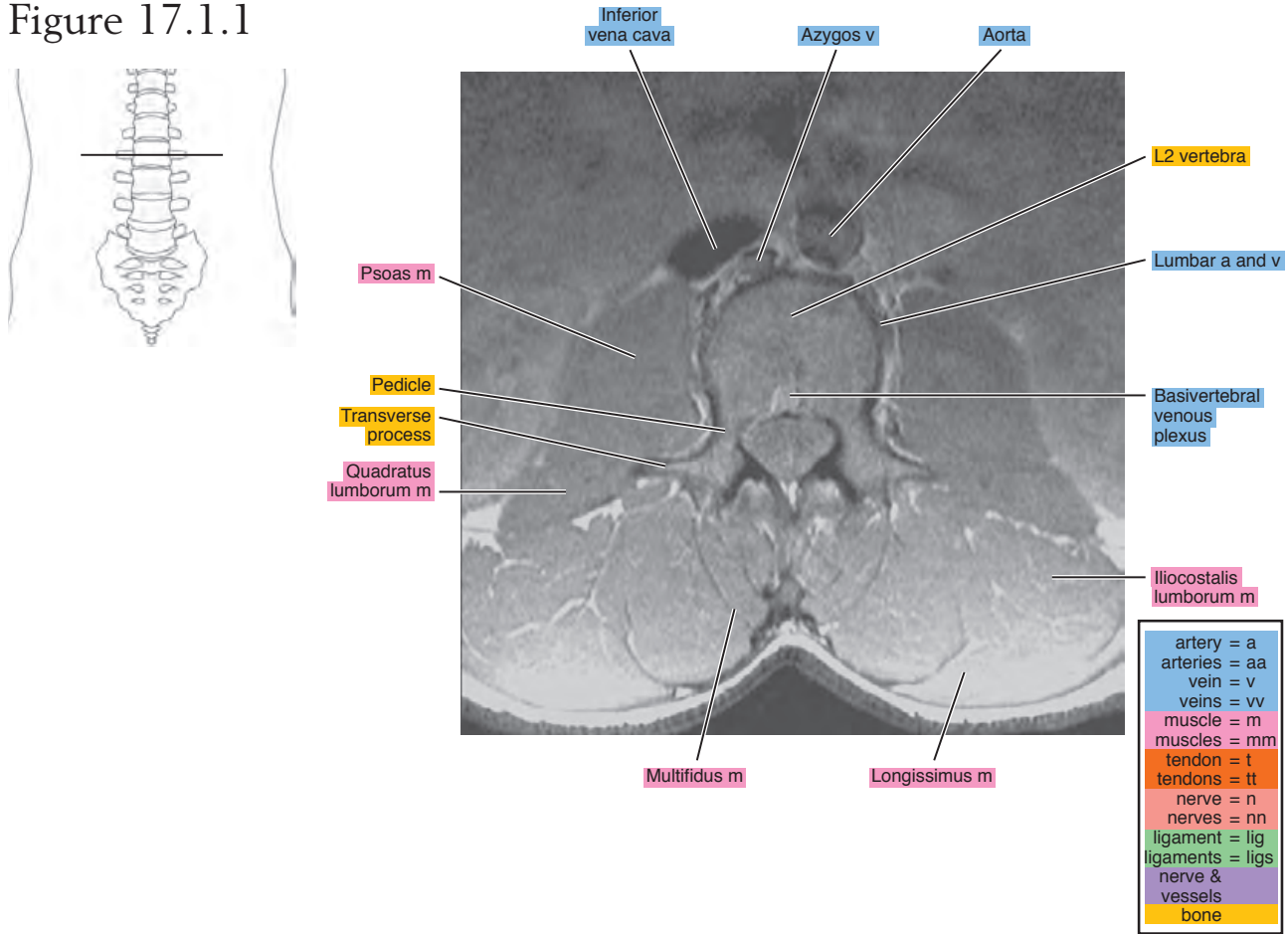


Figure 17.1.2

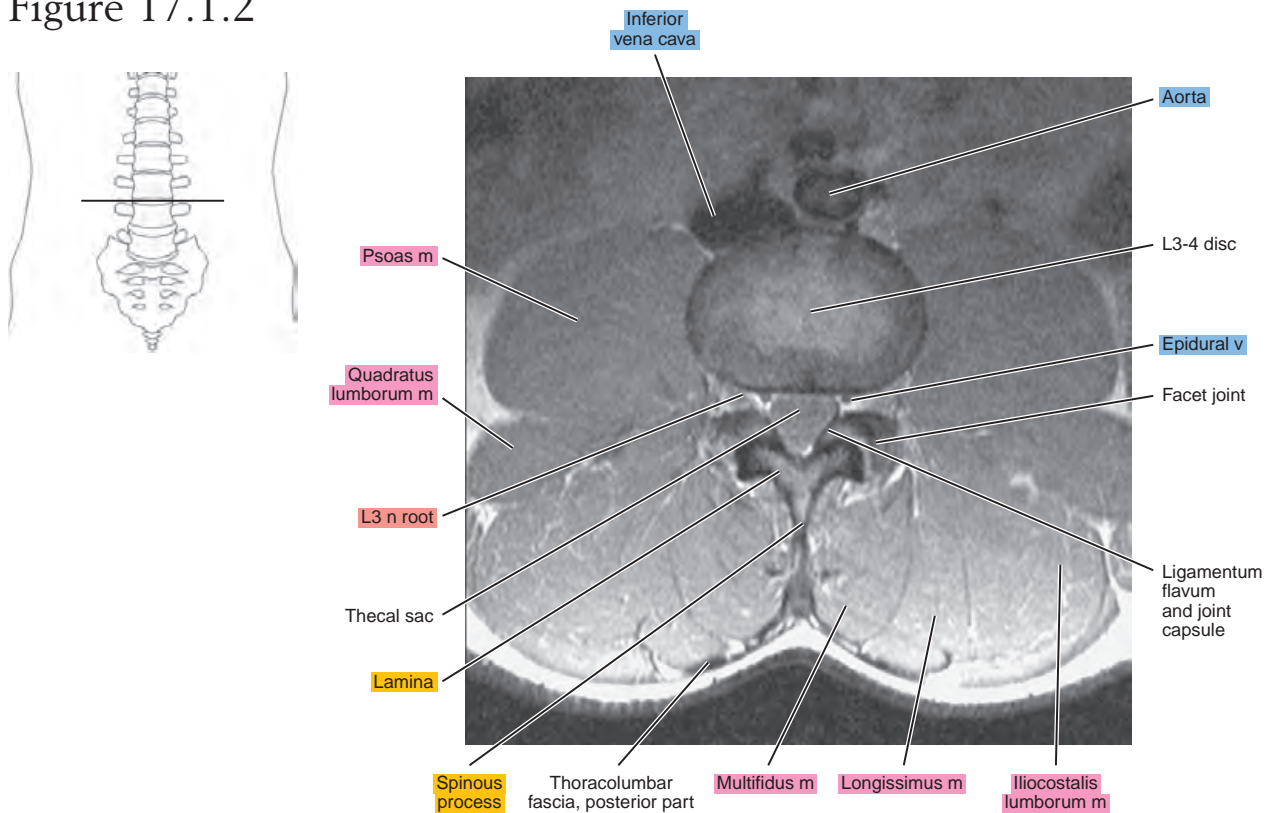


Figure 17.1.3

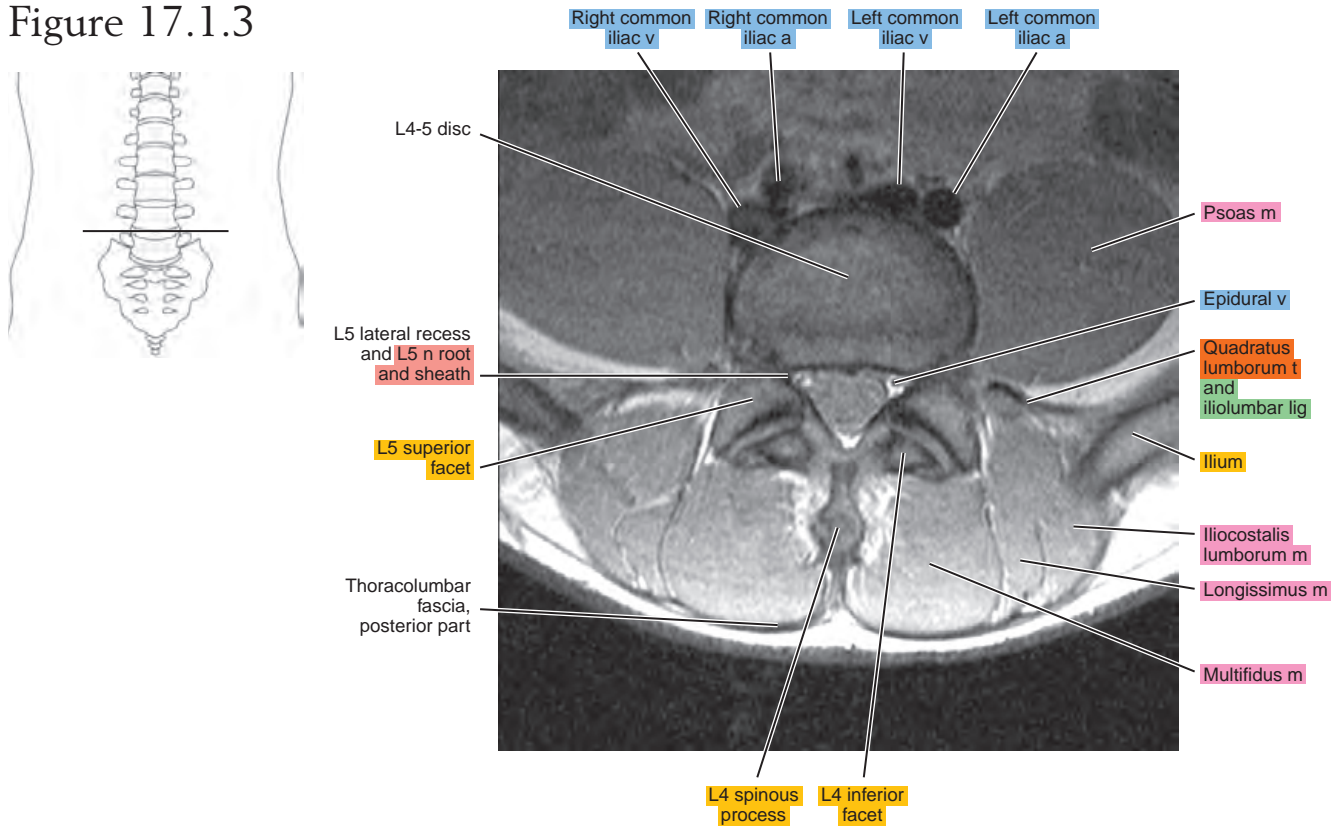


Figure 17.1.4

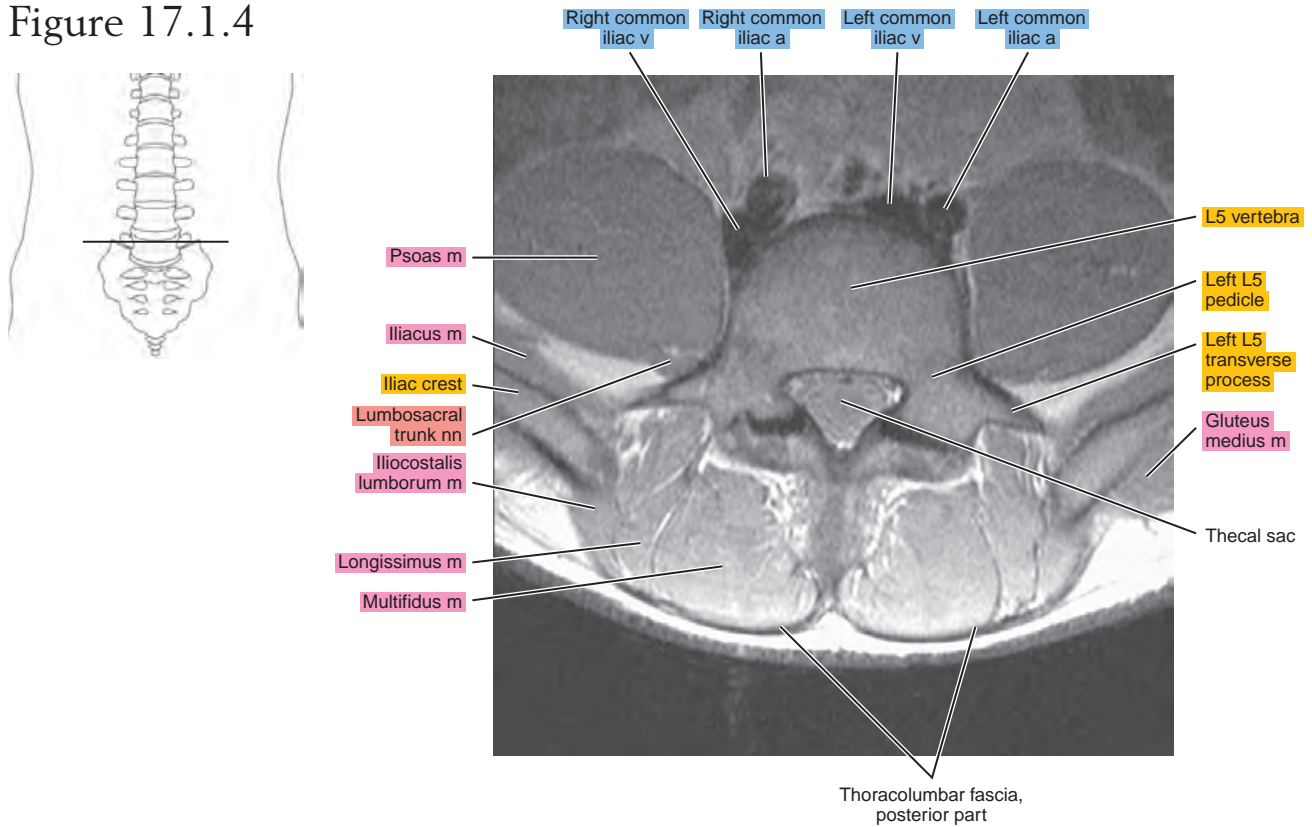


Figure 17.1.5

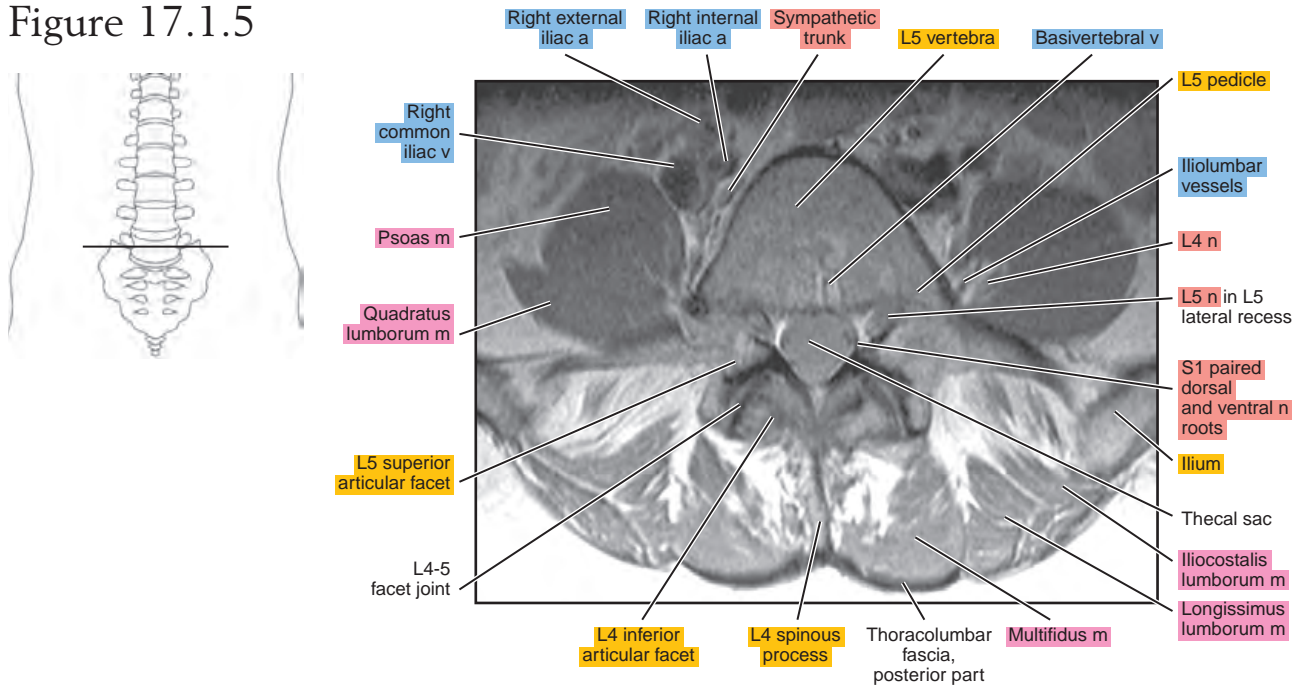


Figure 17.1.6

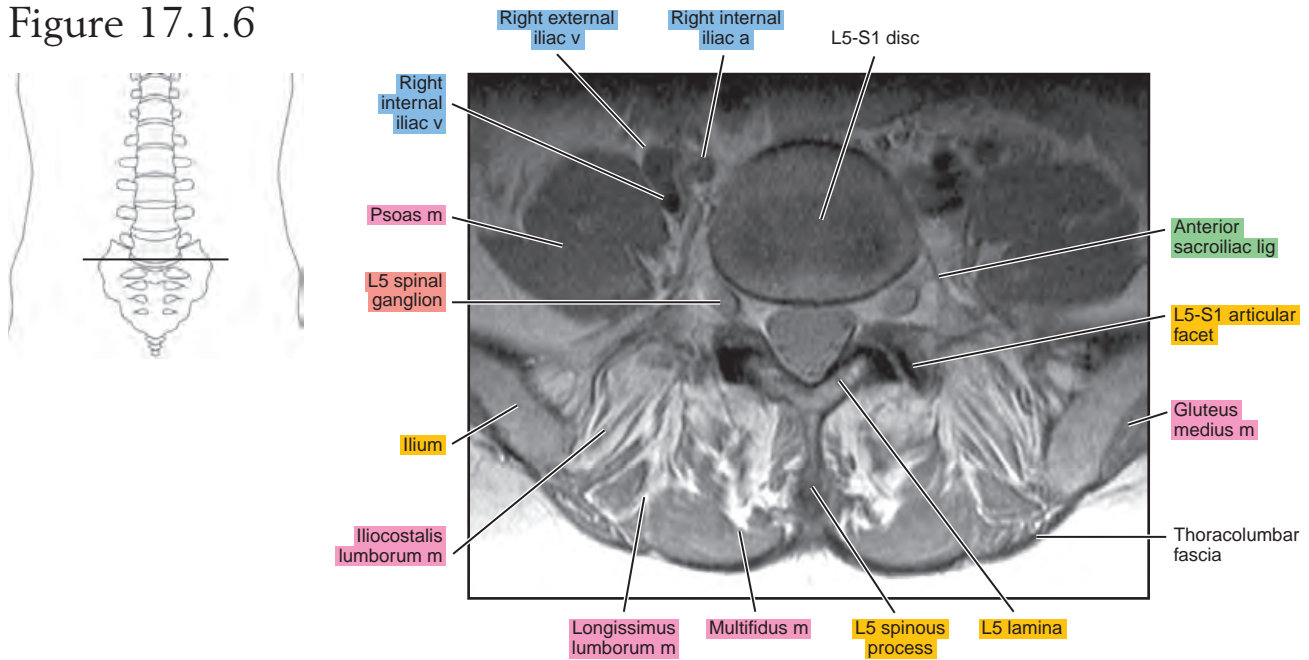


Figure 17.1.7

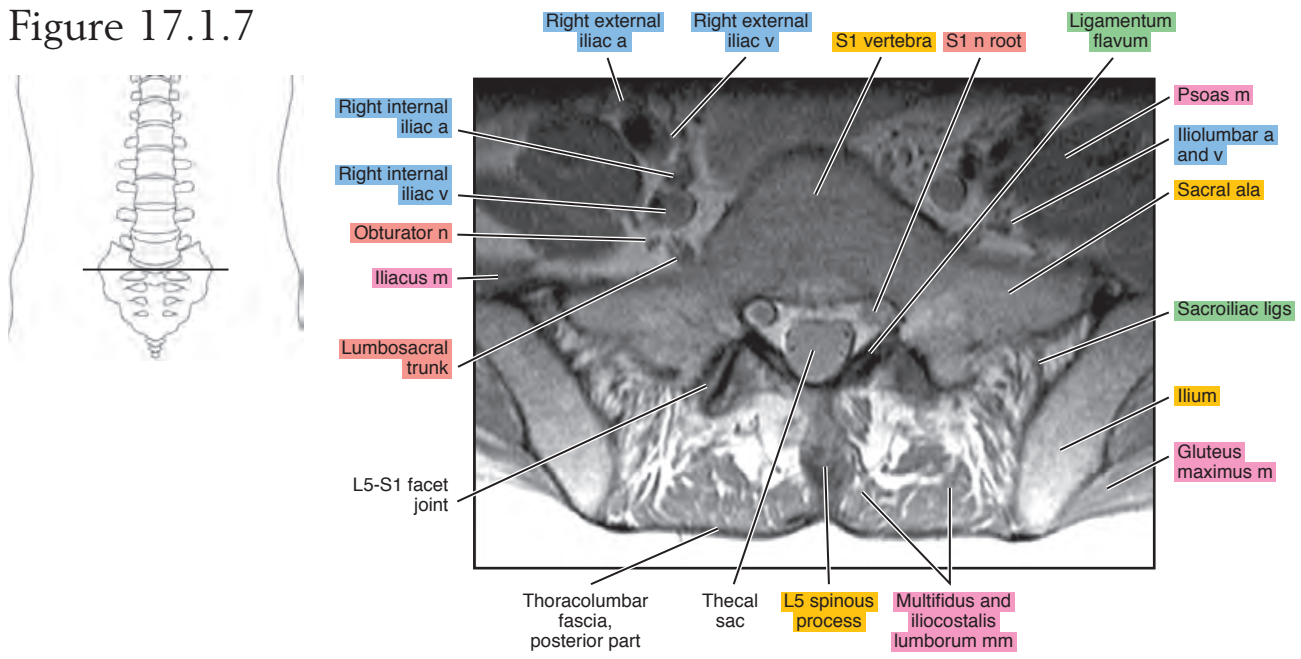
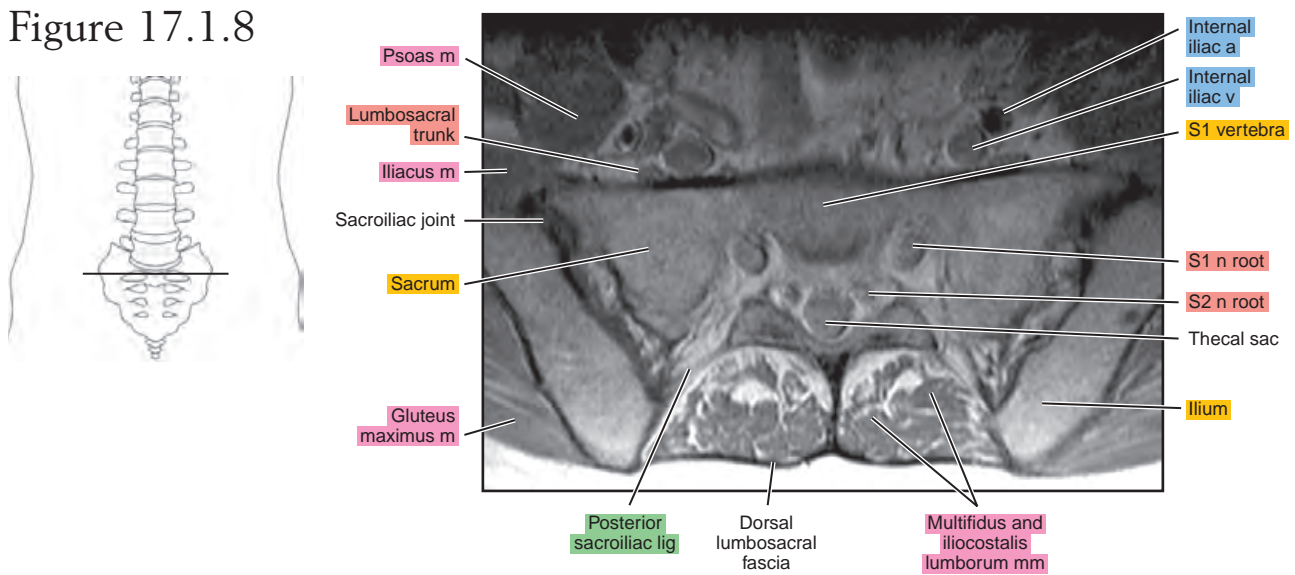


Figure 17.1.8



SAGITTAL

Figure 17.2.1

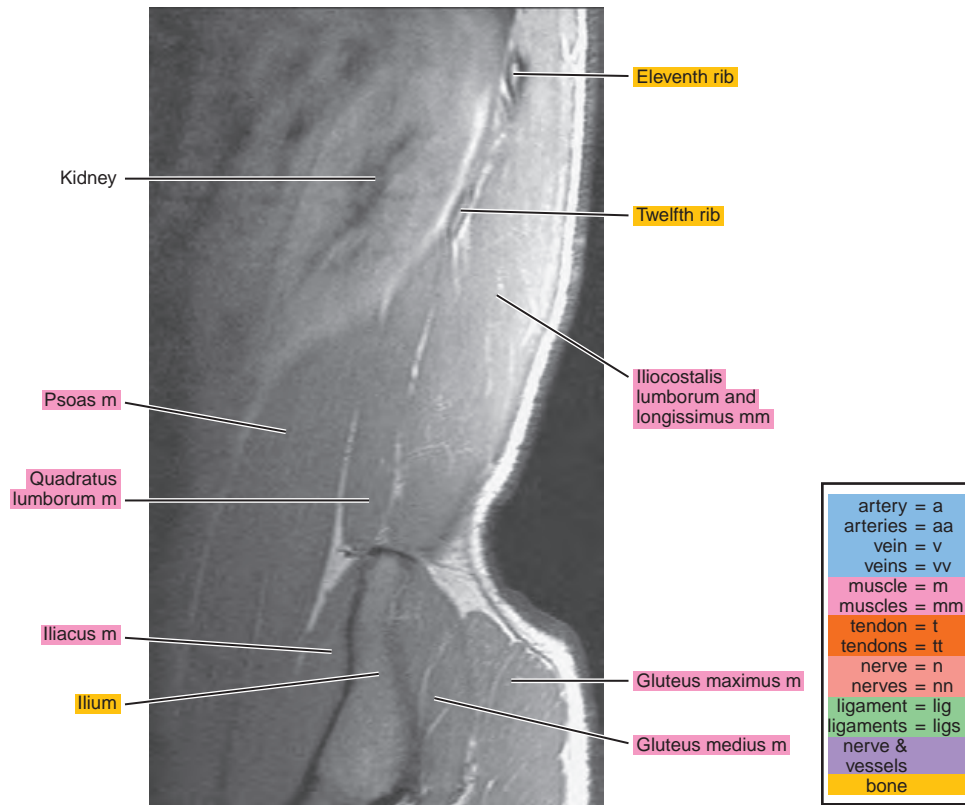
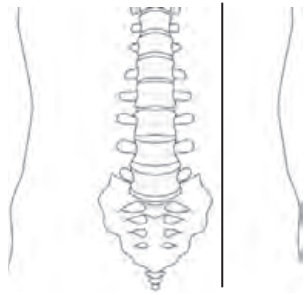


Figure 17.2.2

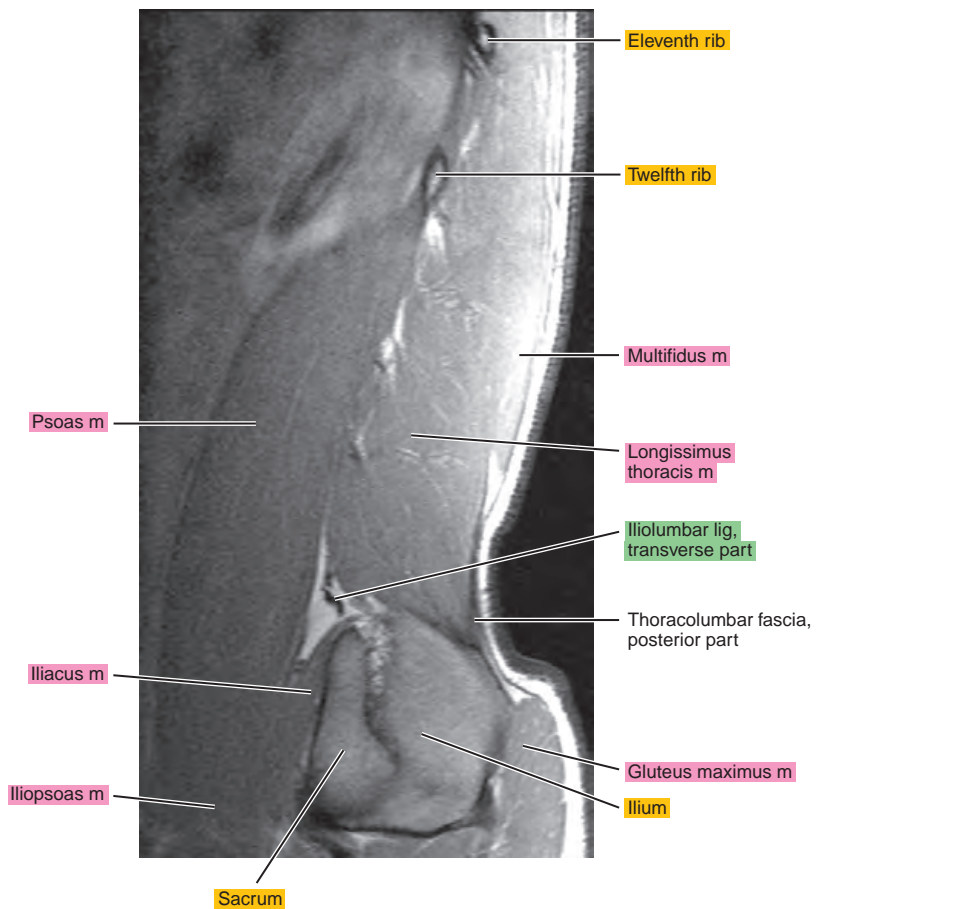
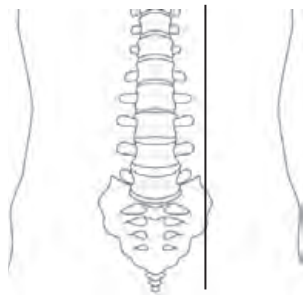


Figure 17.2.3

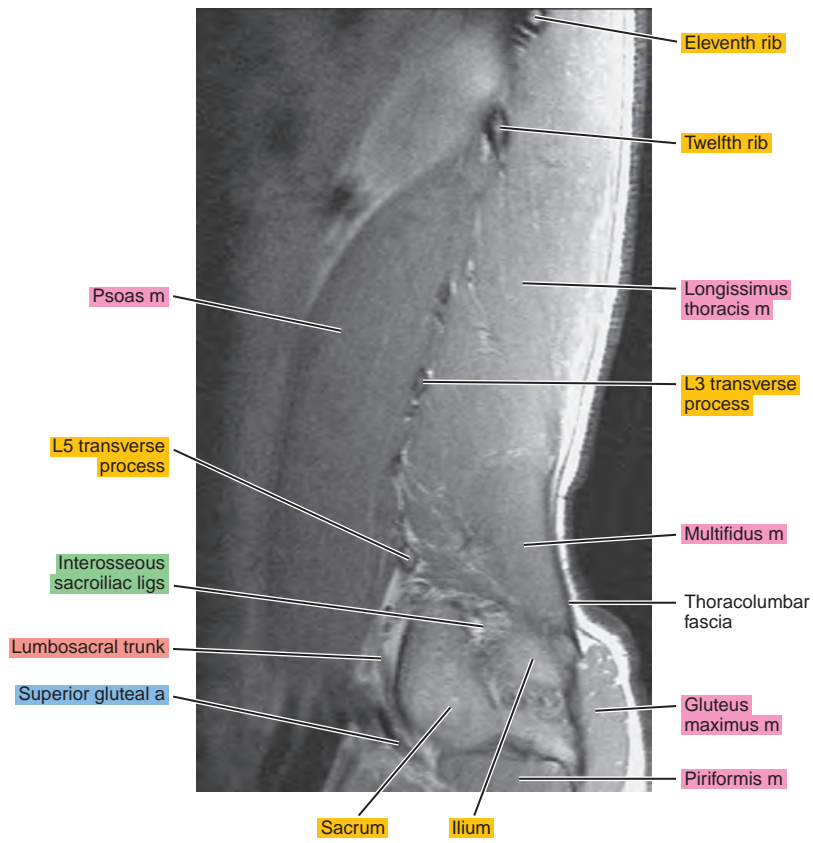
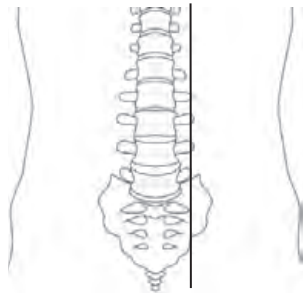


Figure 17.2.4

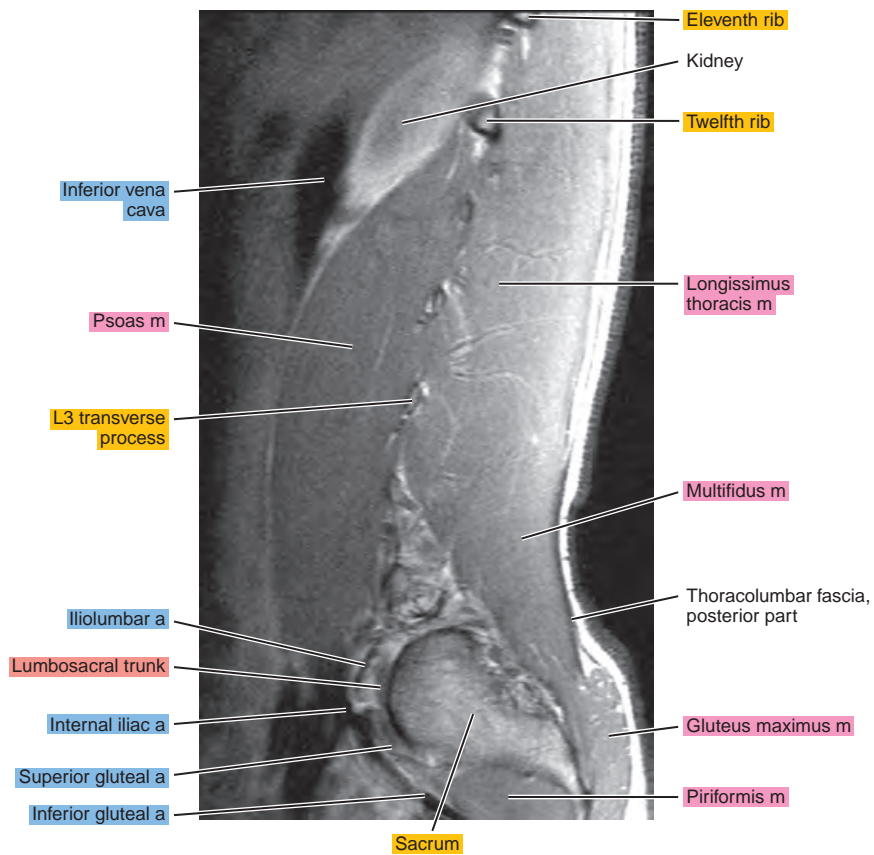
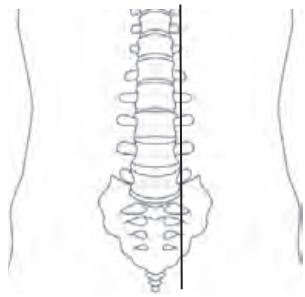


Figure 17.2.5

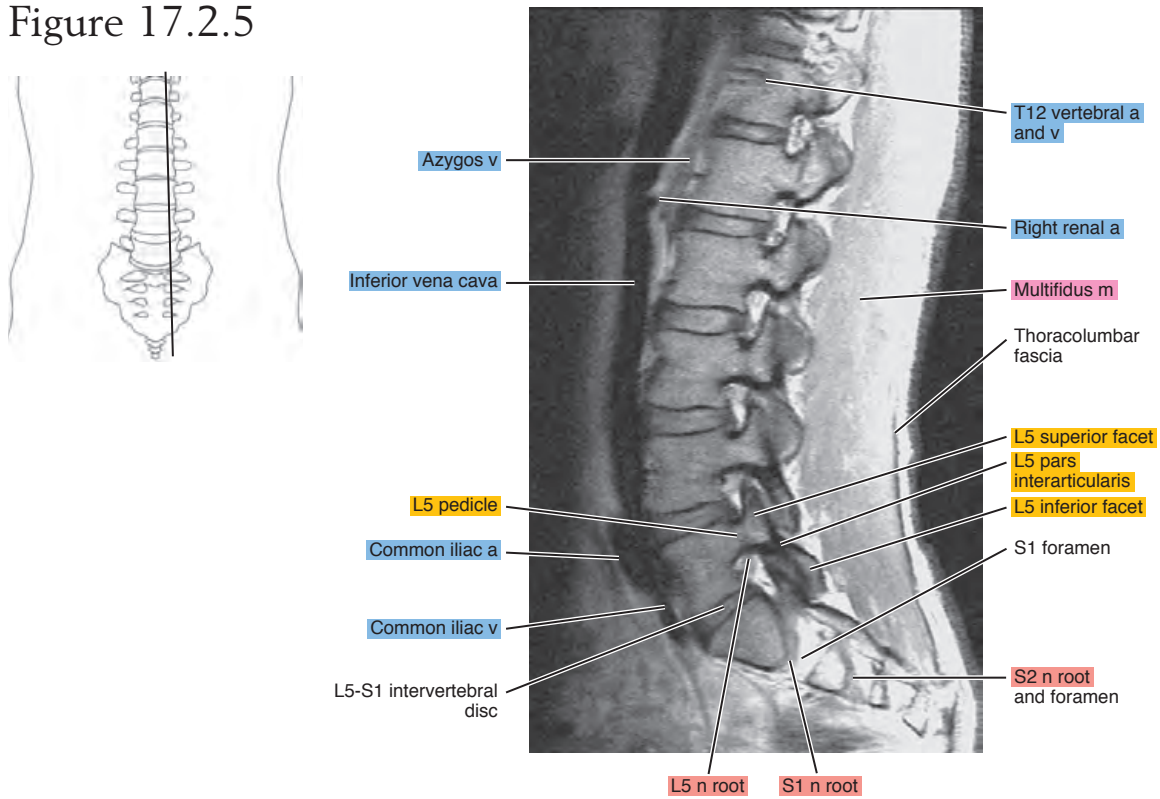
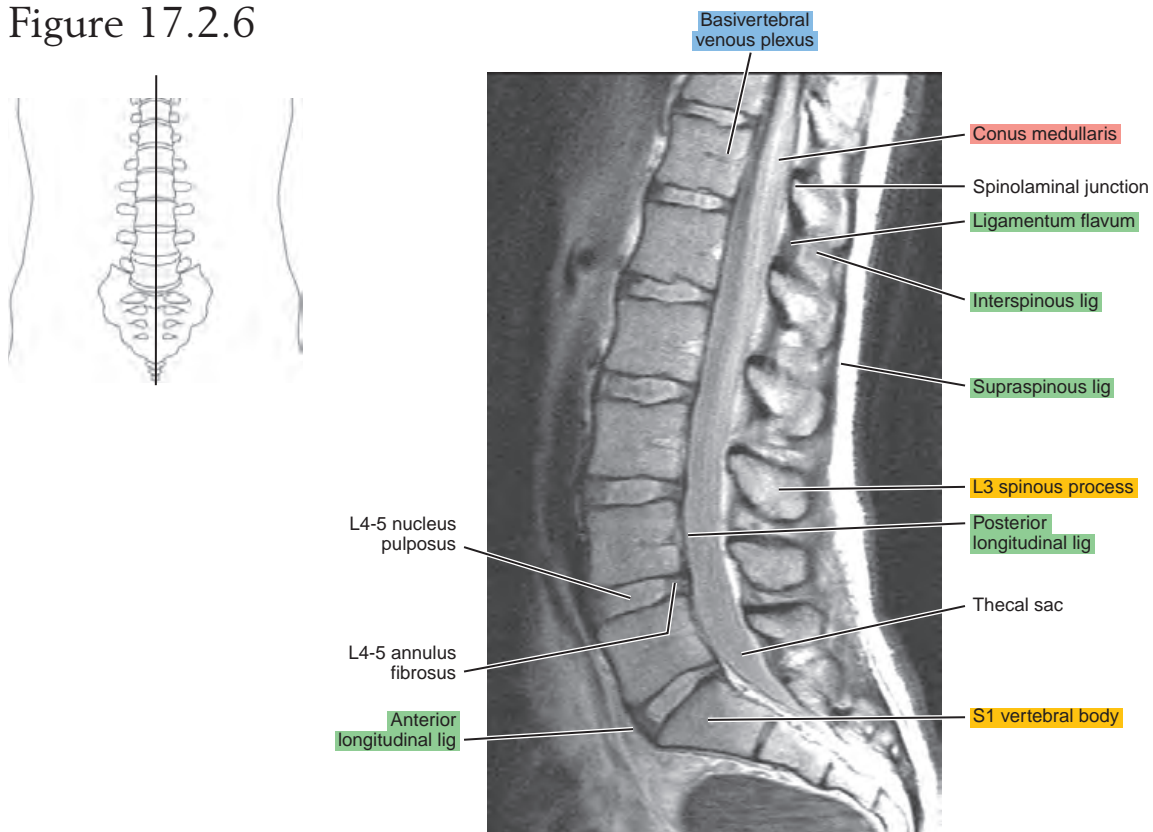


Figure 17.2.6



CORONAL

Figure 17.3.1

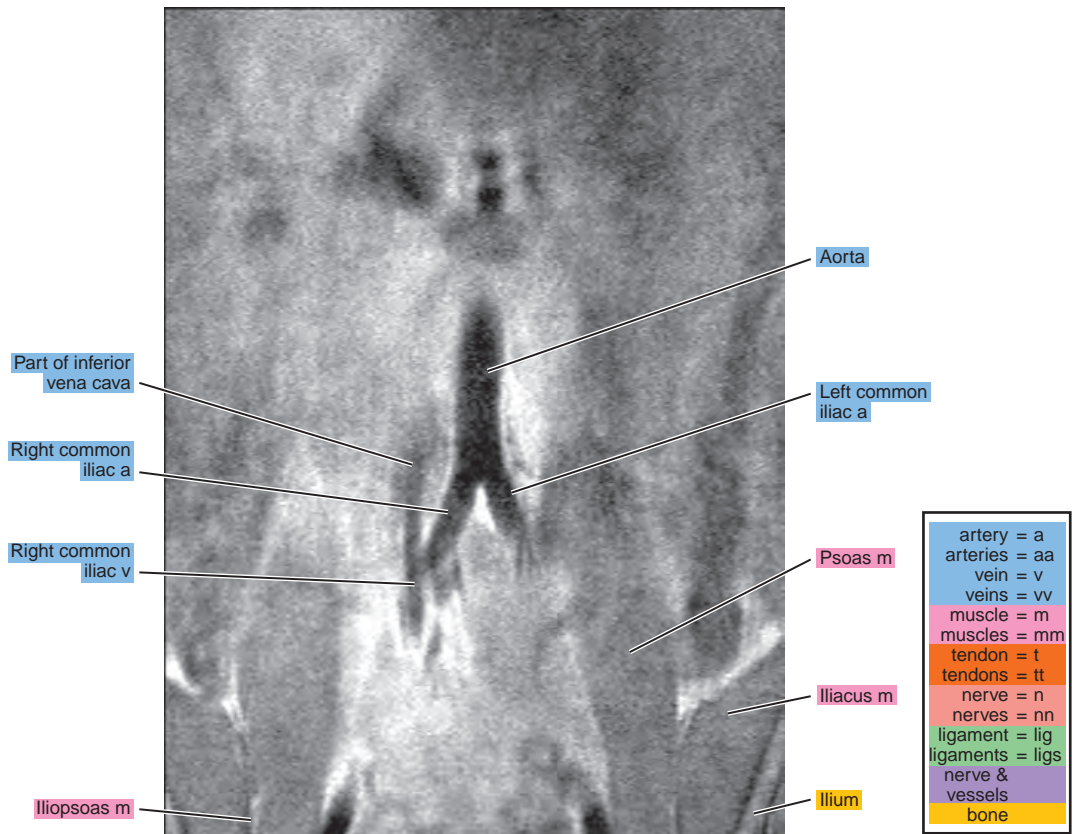
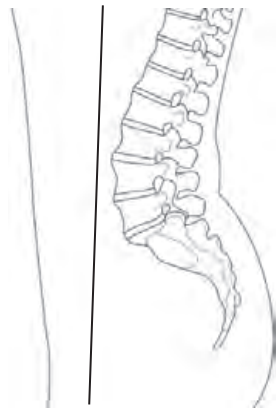


Figure 17.3.2

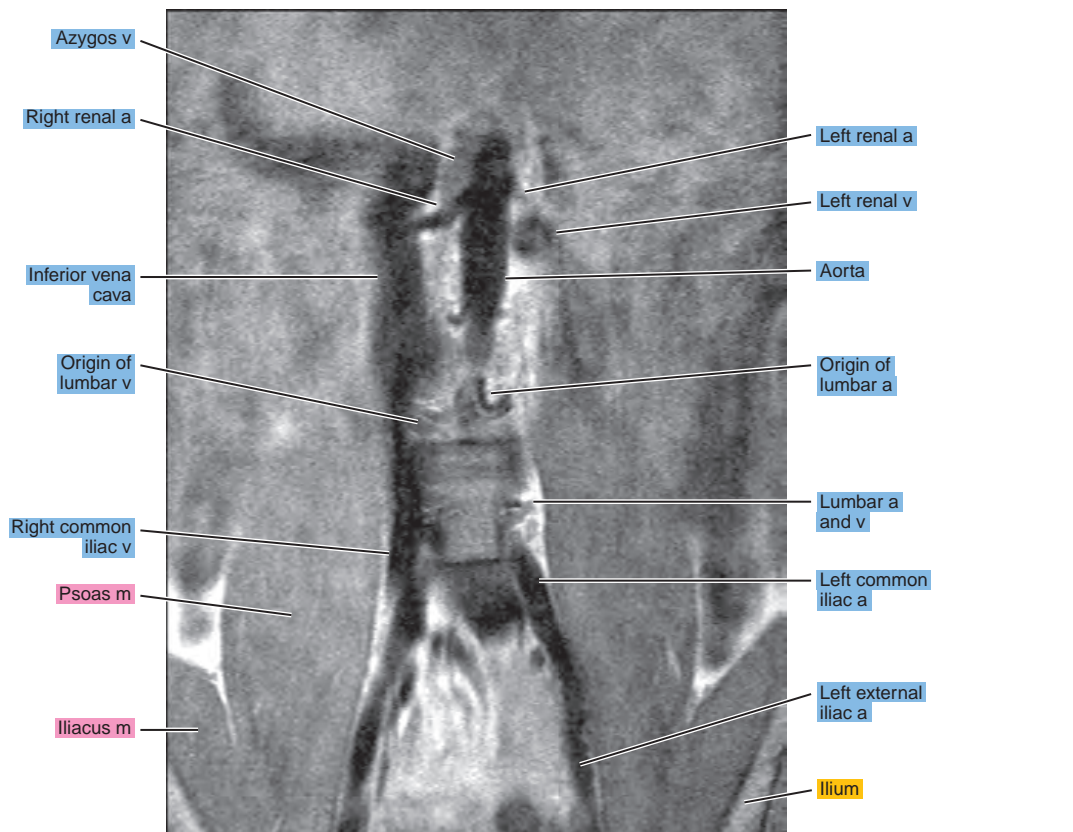
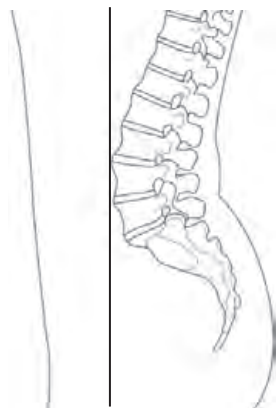


Figure 17.3.3

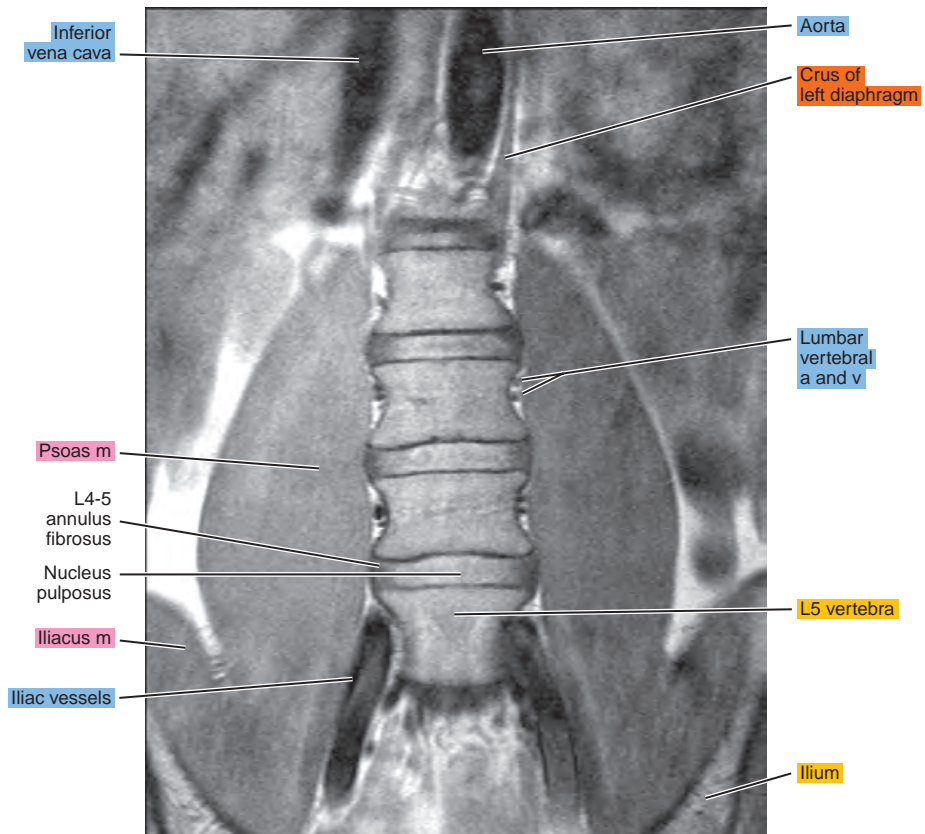
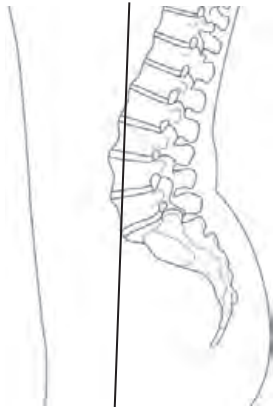

Figure 17.3.4

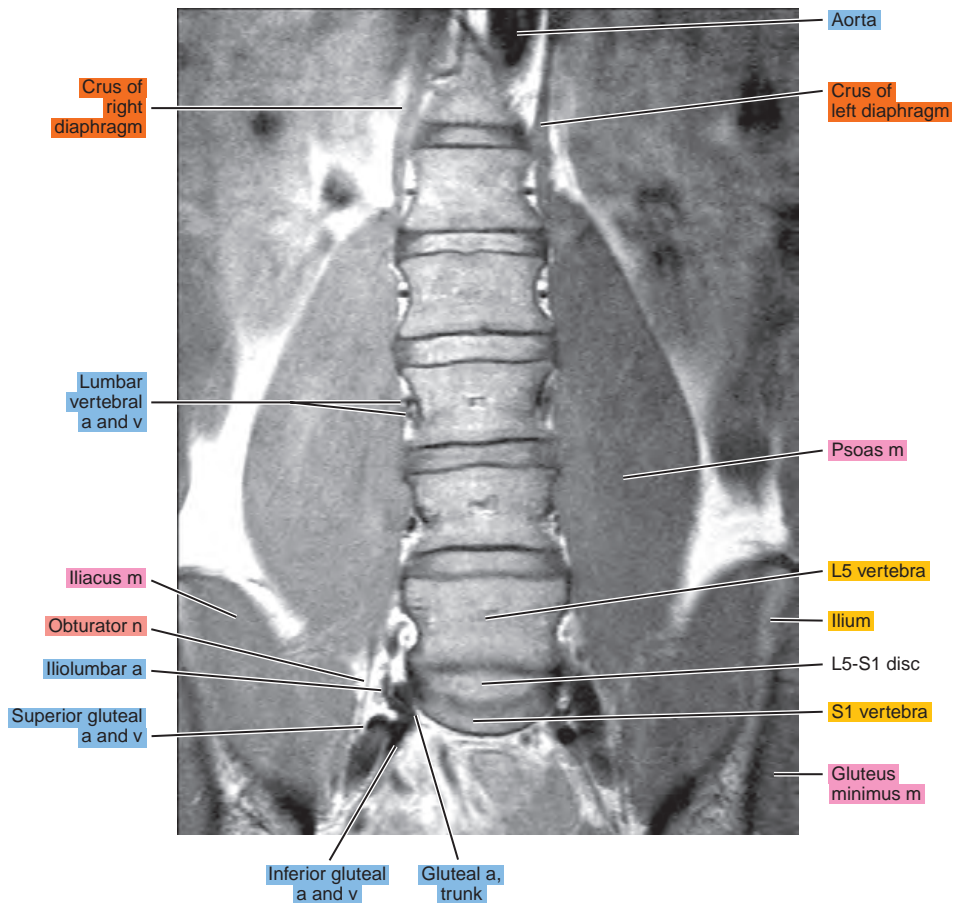
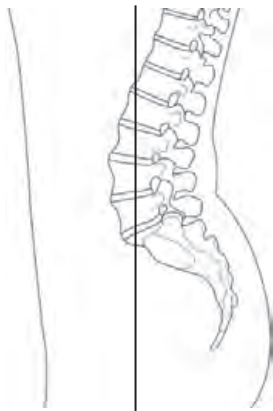


Figure 17.3.5

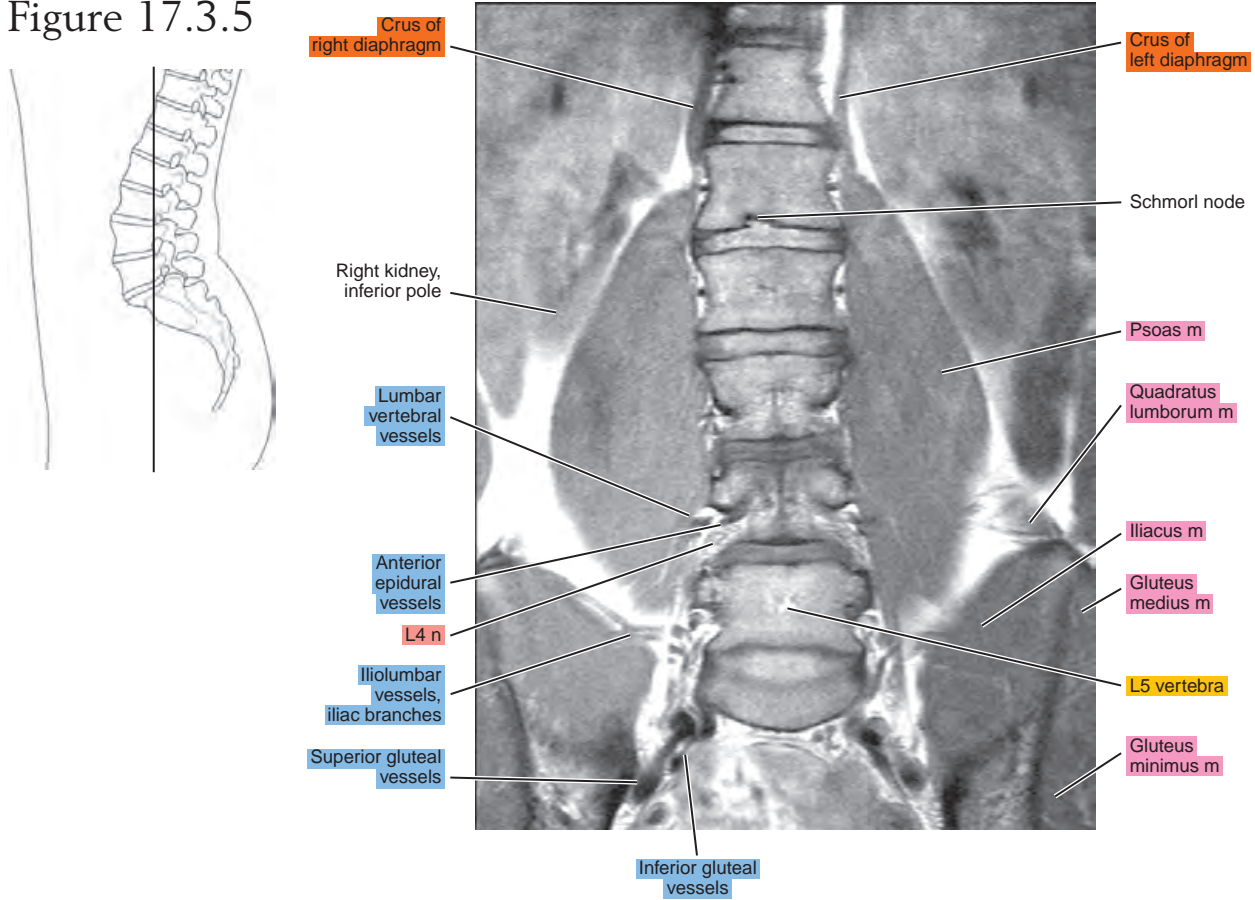


Figure 17.3.6

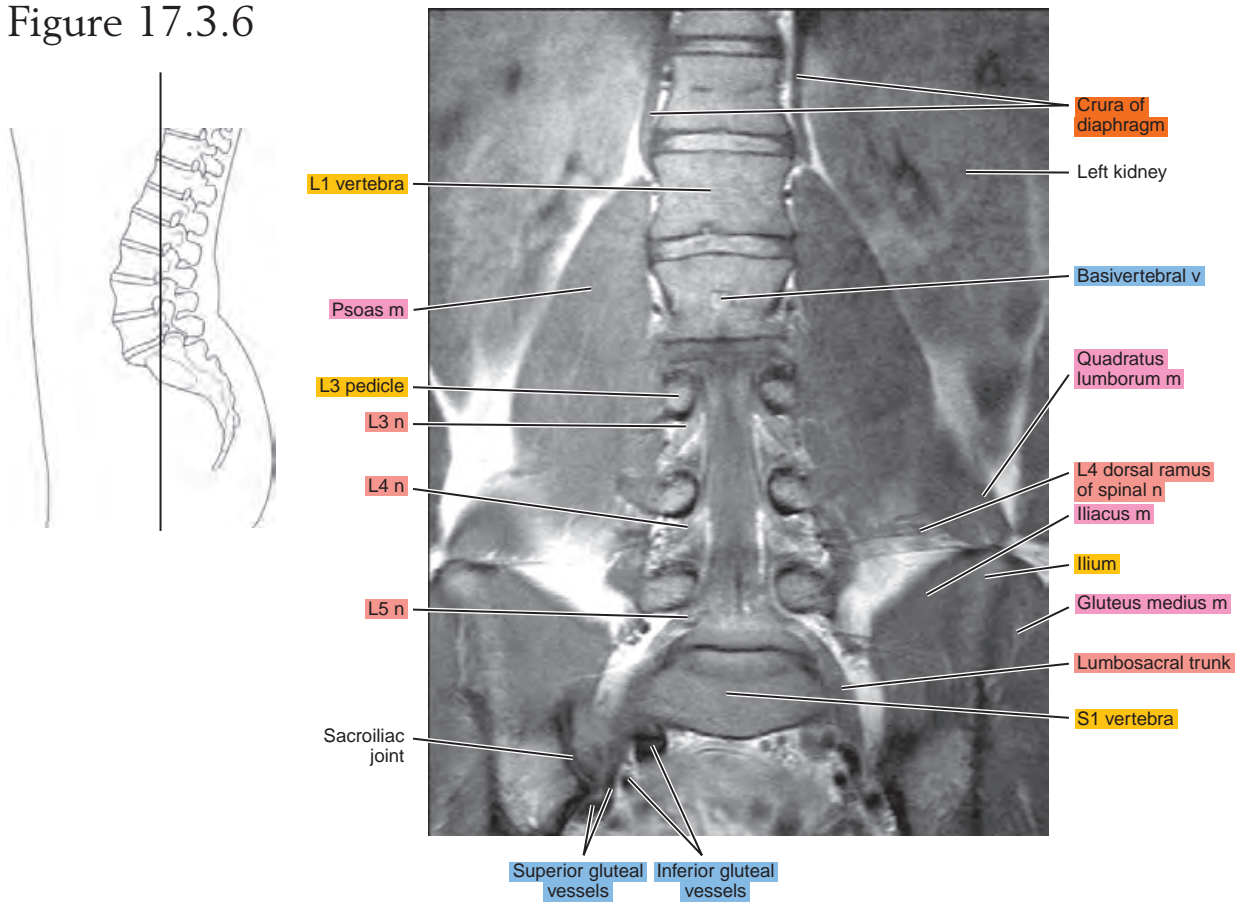


Figure 17.3.7

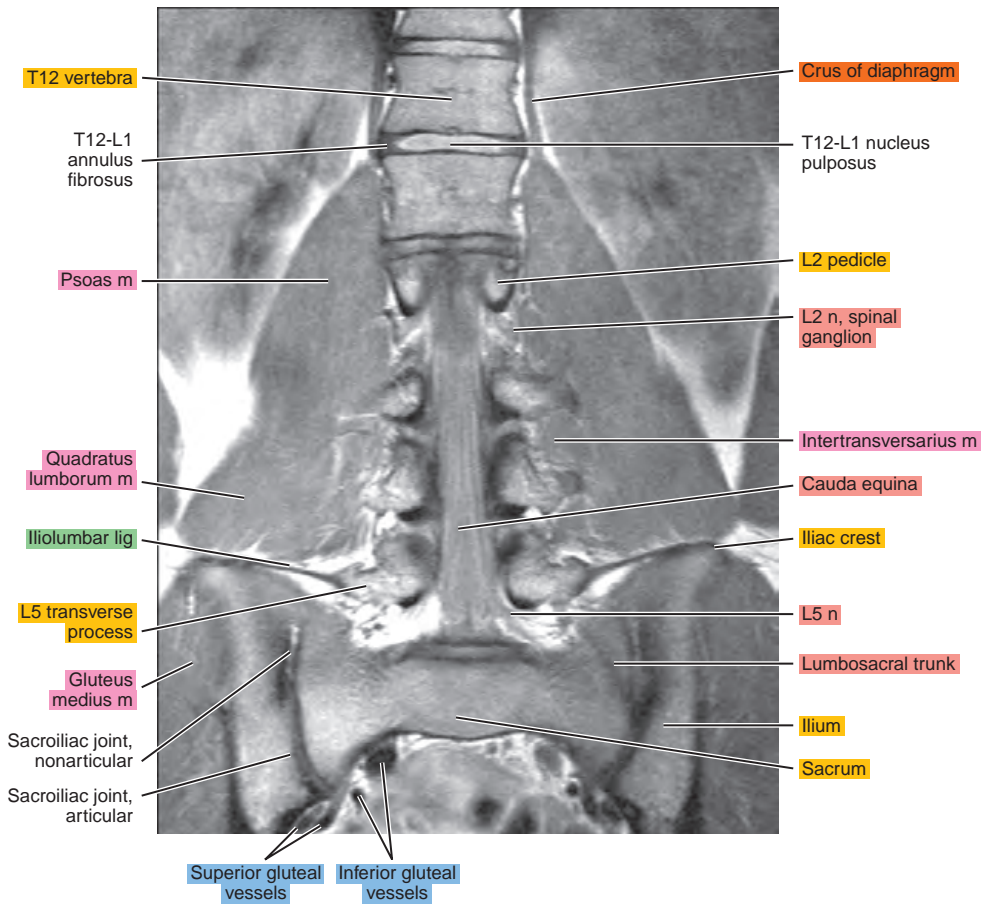
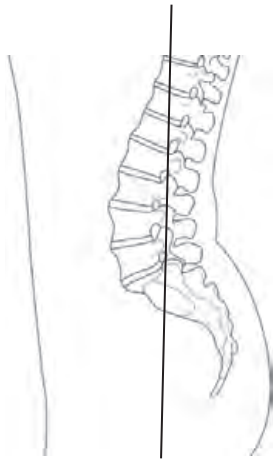


Figure 17.3.8

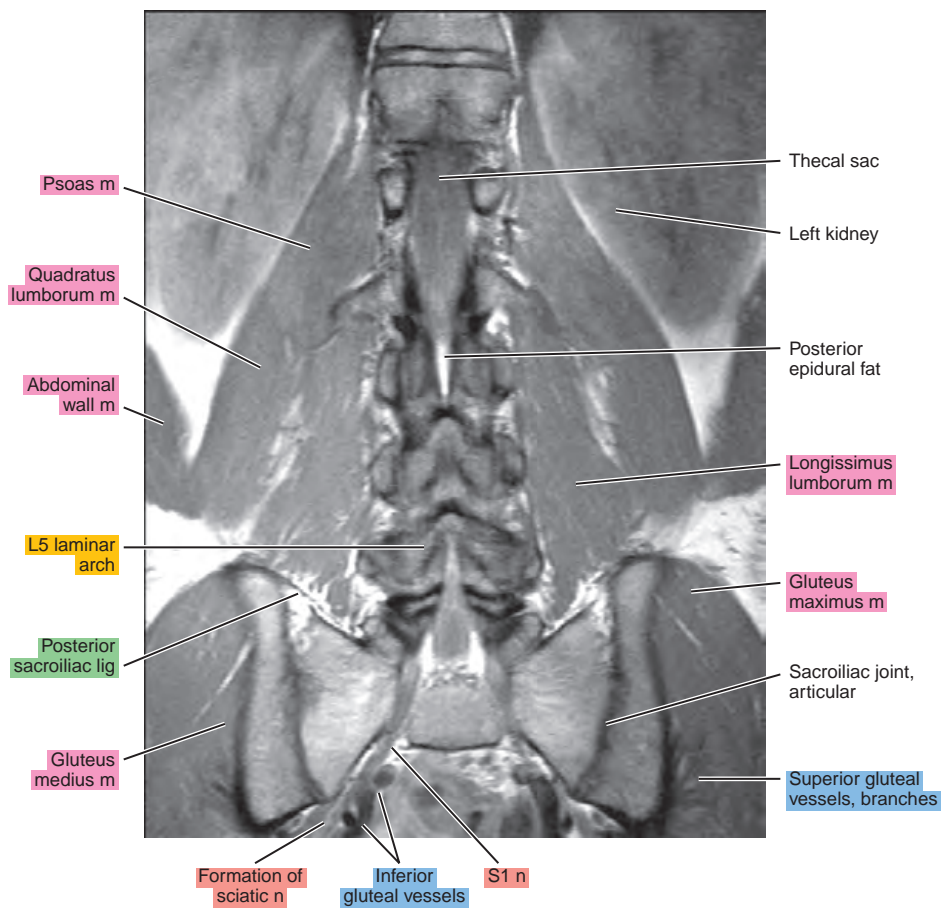
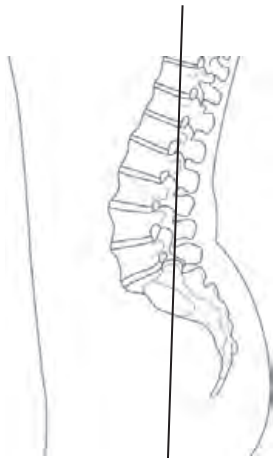


Figure 17.3.9

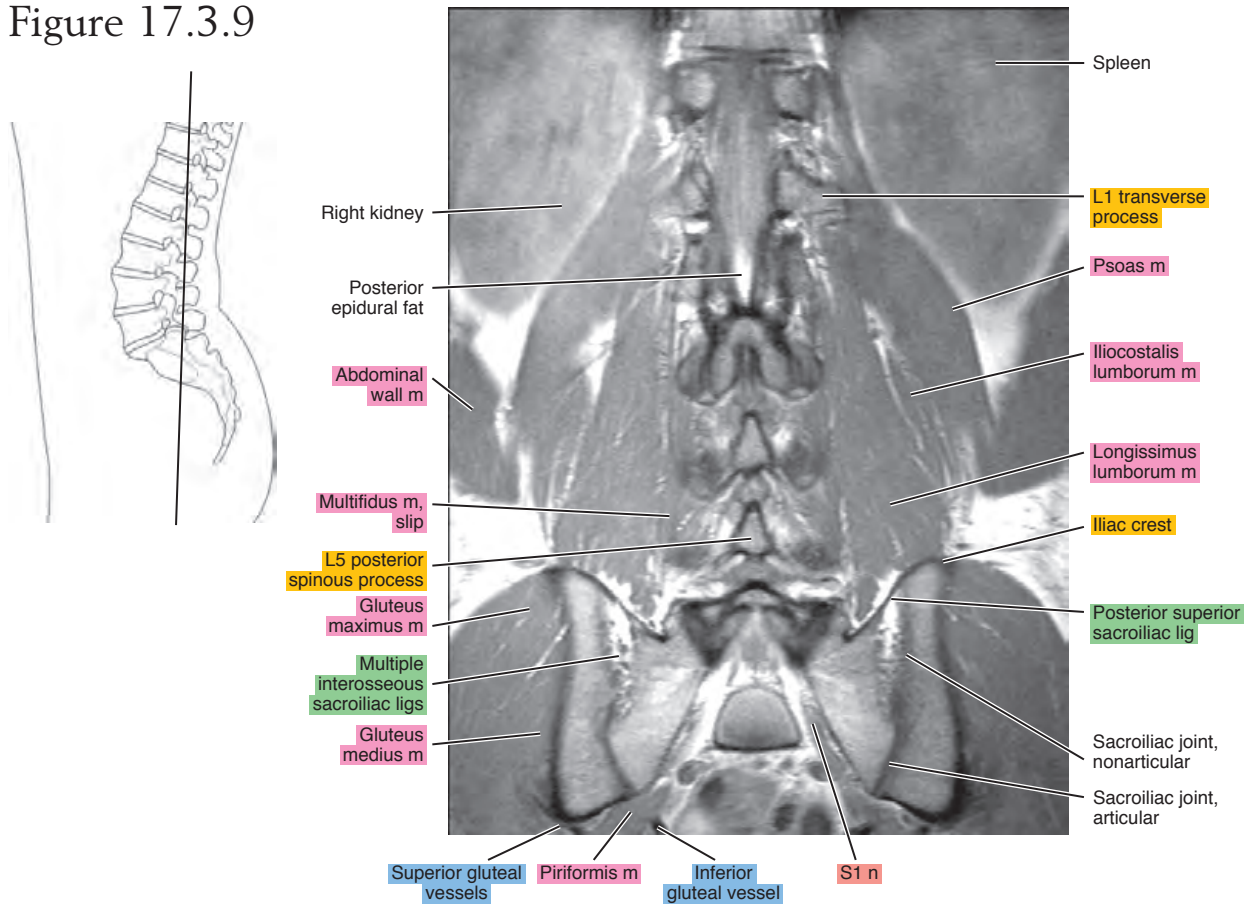


Figure 17.3.10

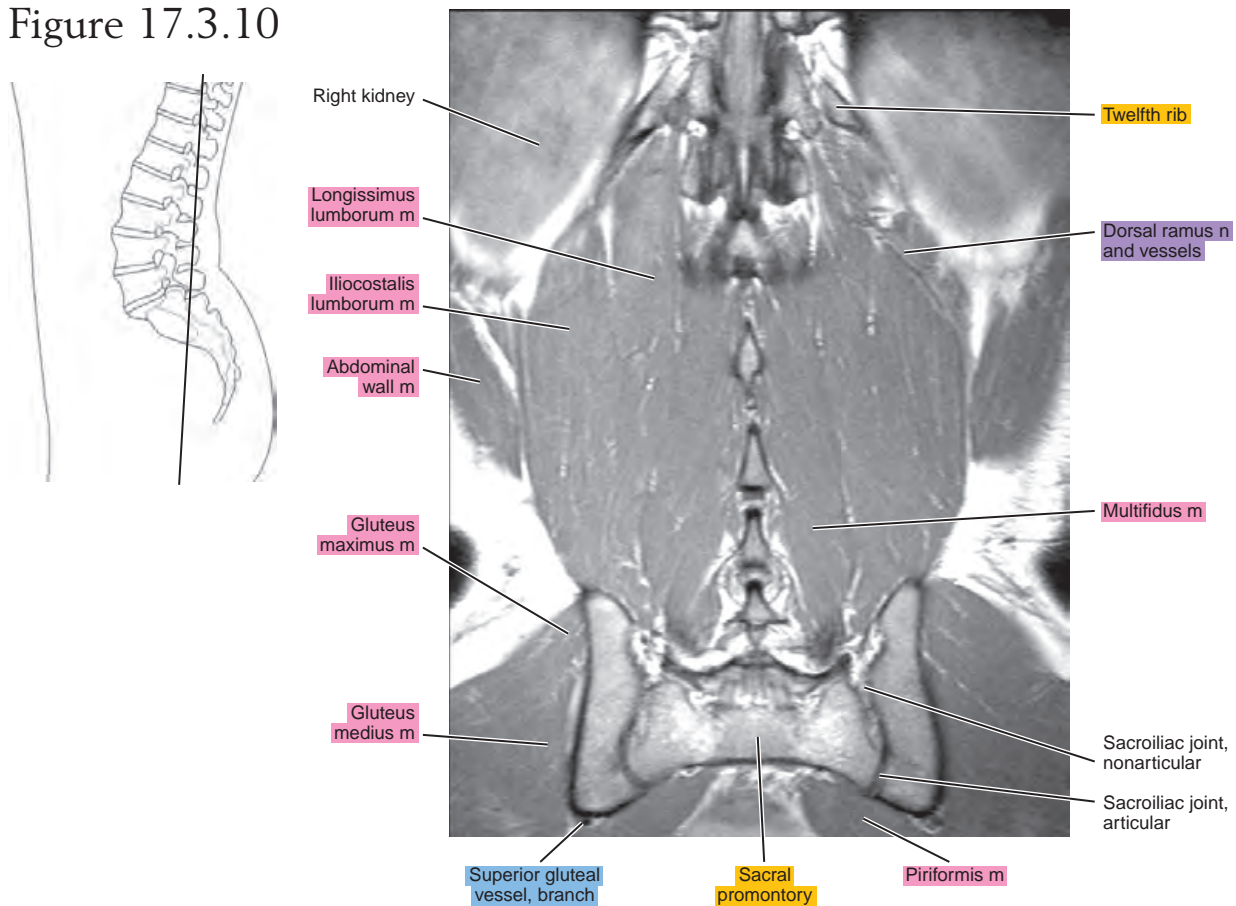
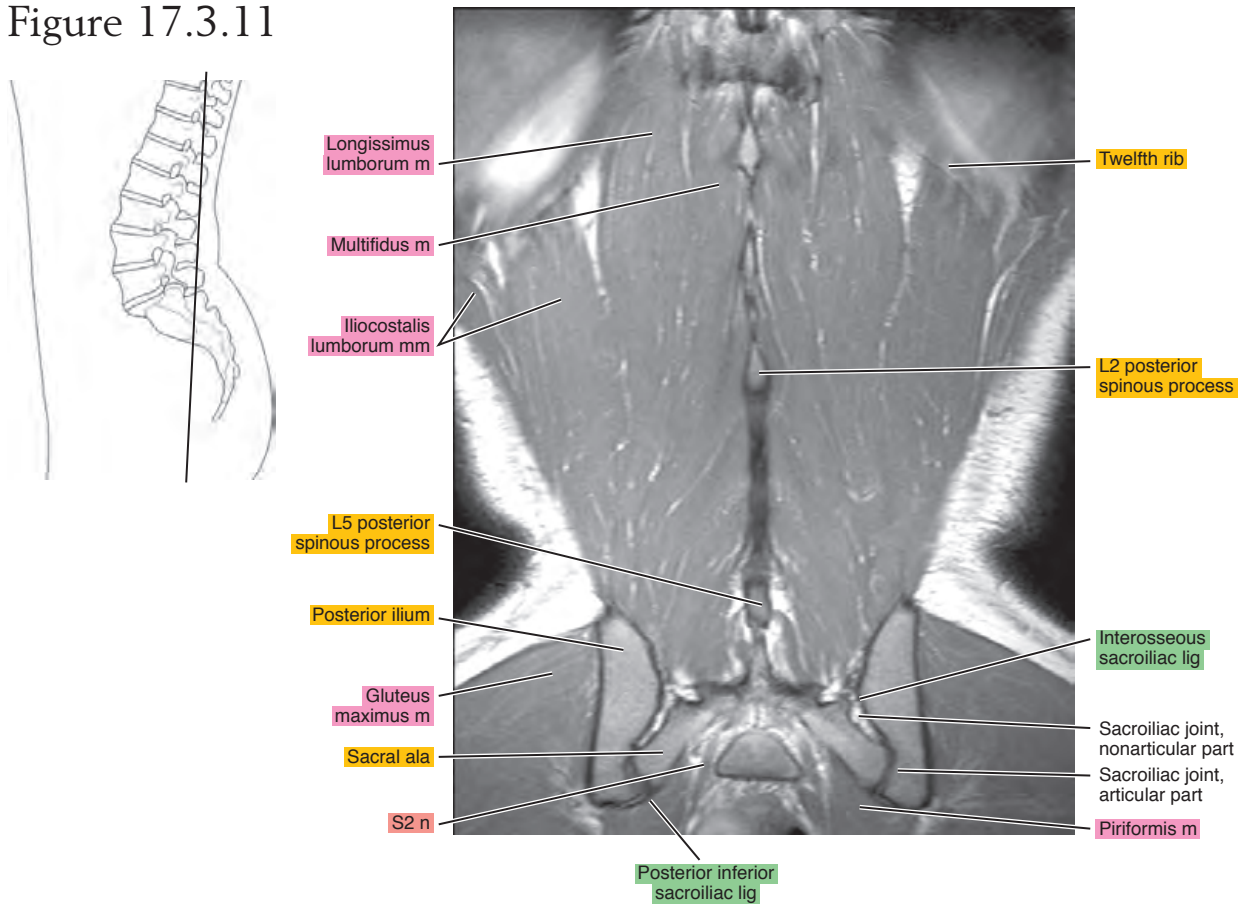


Figure 17.3.11



This page intentionally left blank

The background of the page is a green geometric pattern consisting of overlapping triangles and hexagons, creating a textured, crystalline effect. The color transitions from a darker green at the top to a lighter, almost white green at the bottom.

IV

Section

Thorax

This page intentionally left blank

Chapter
18

CT of the Thorax

AXIAL

Figure 18.1.1

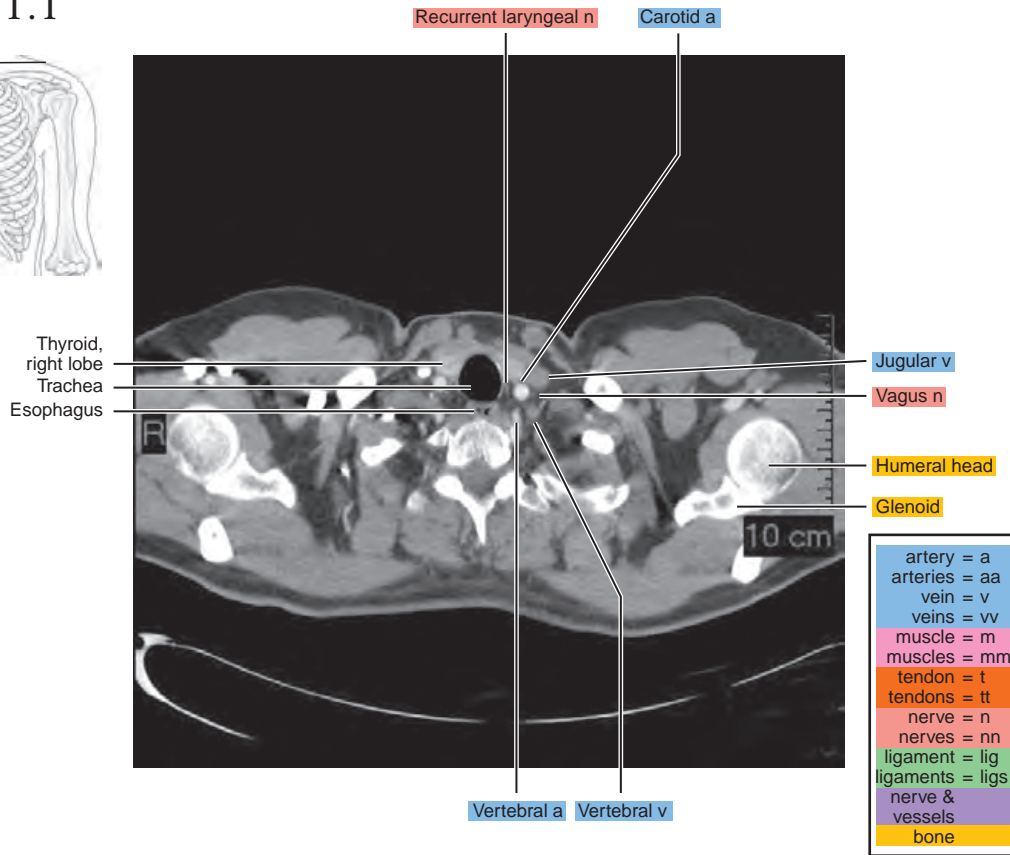
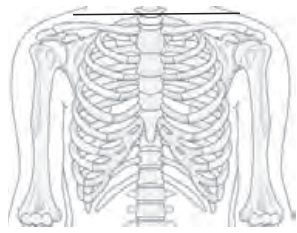


Figure 18.1.2

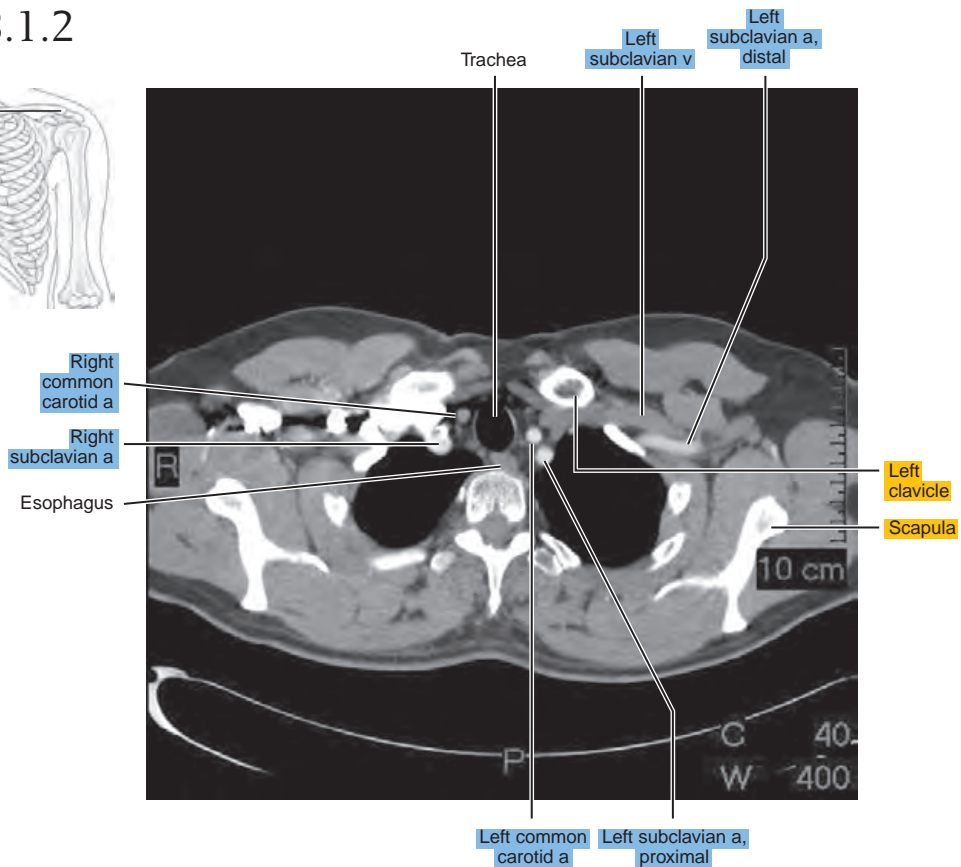
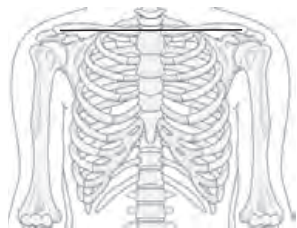


Figure 18.1.3

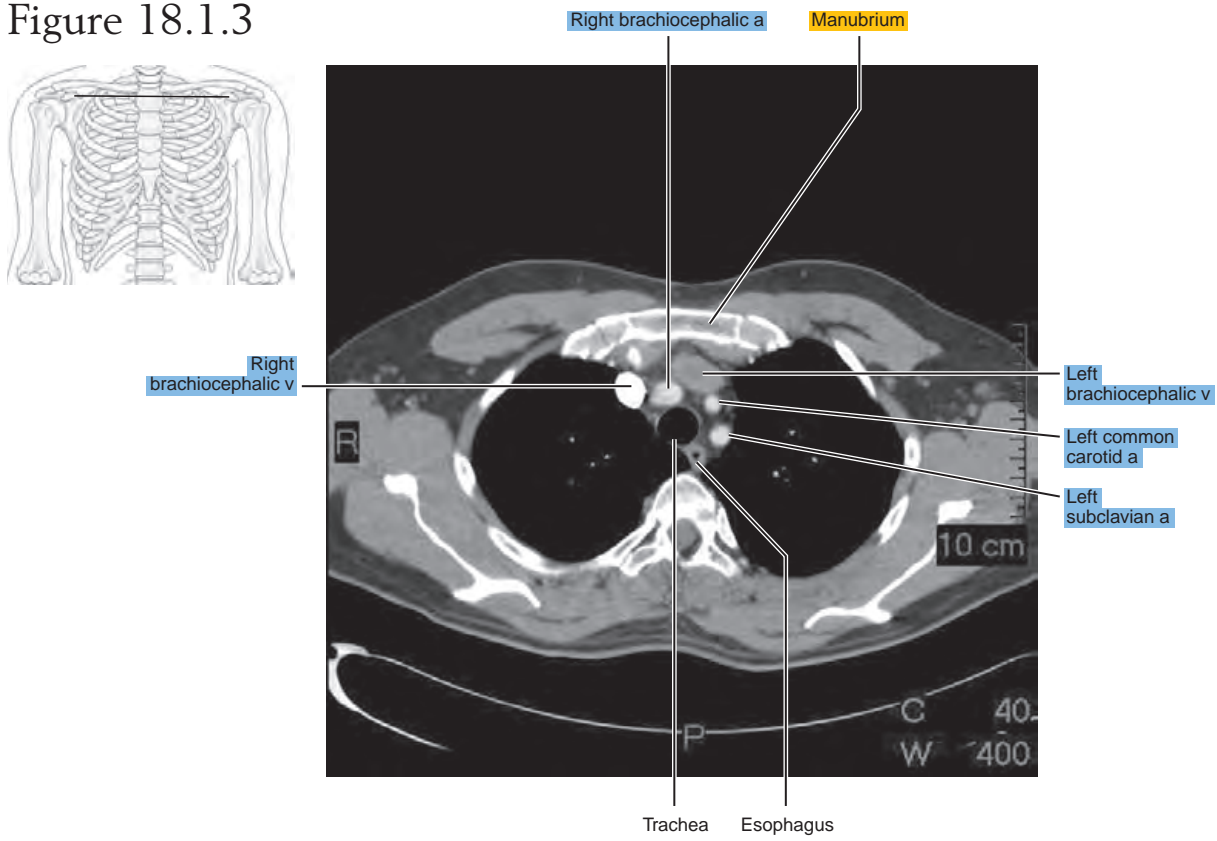


Figure 18.1.4

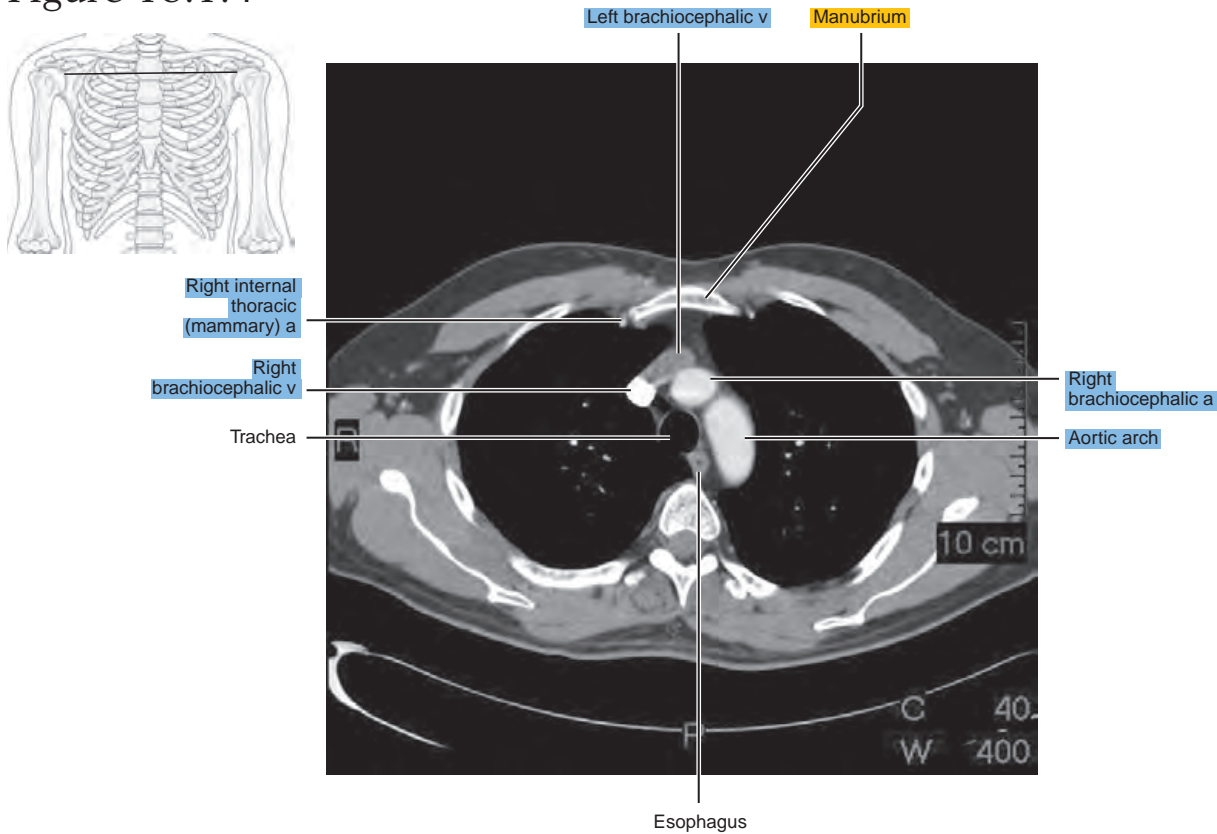


Figure 18.1.5

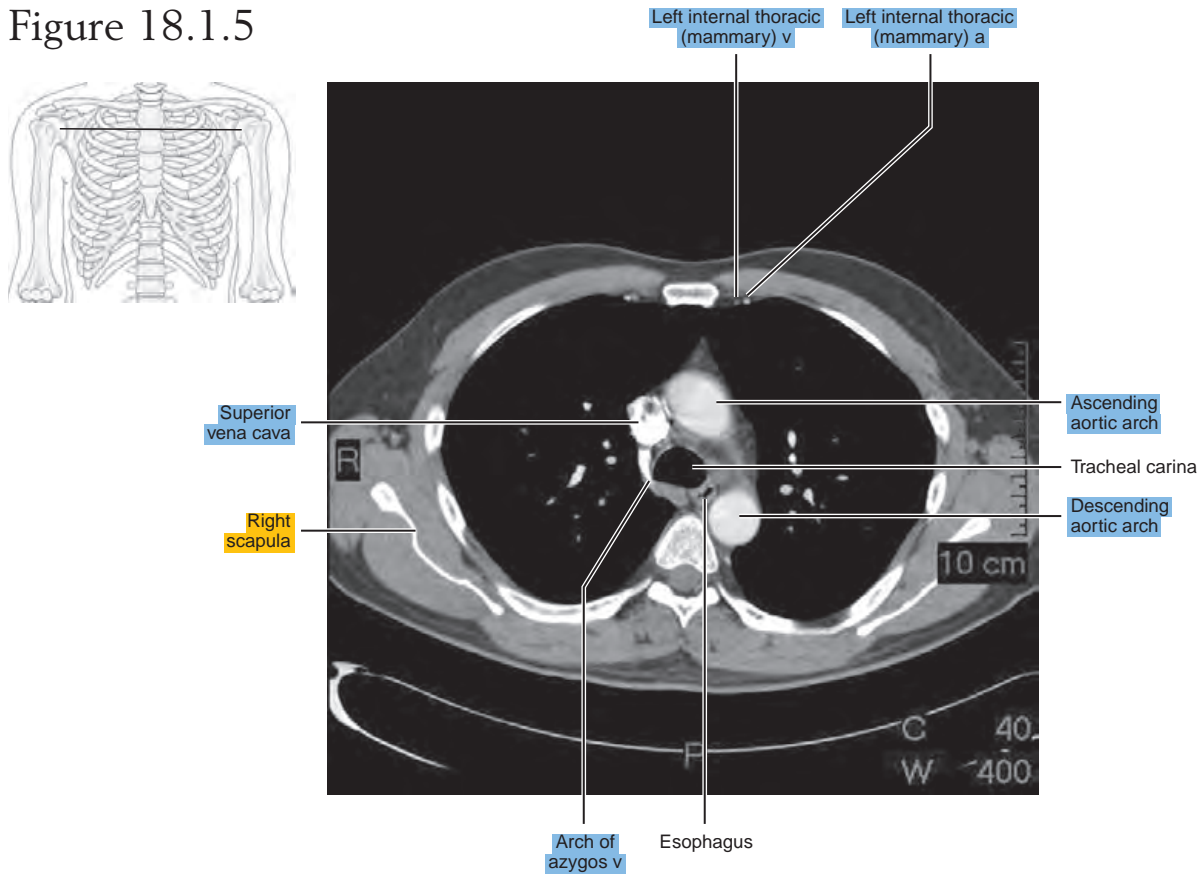


Figure 18.1.6

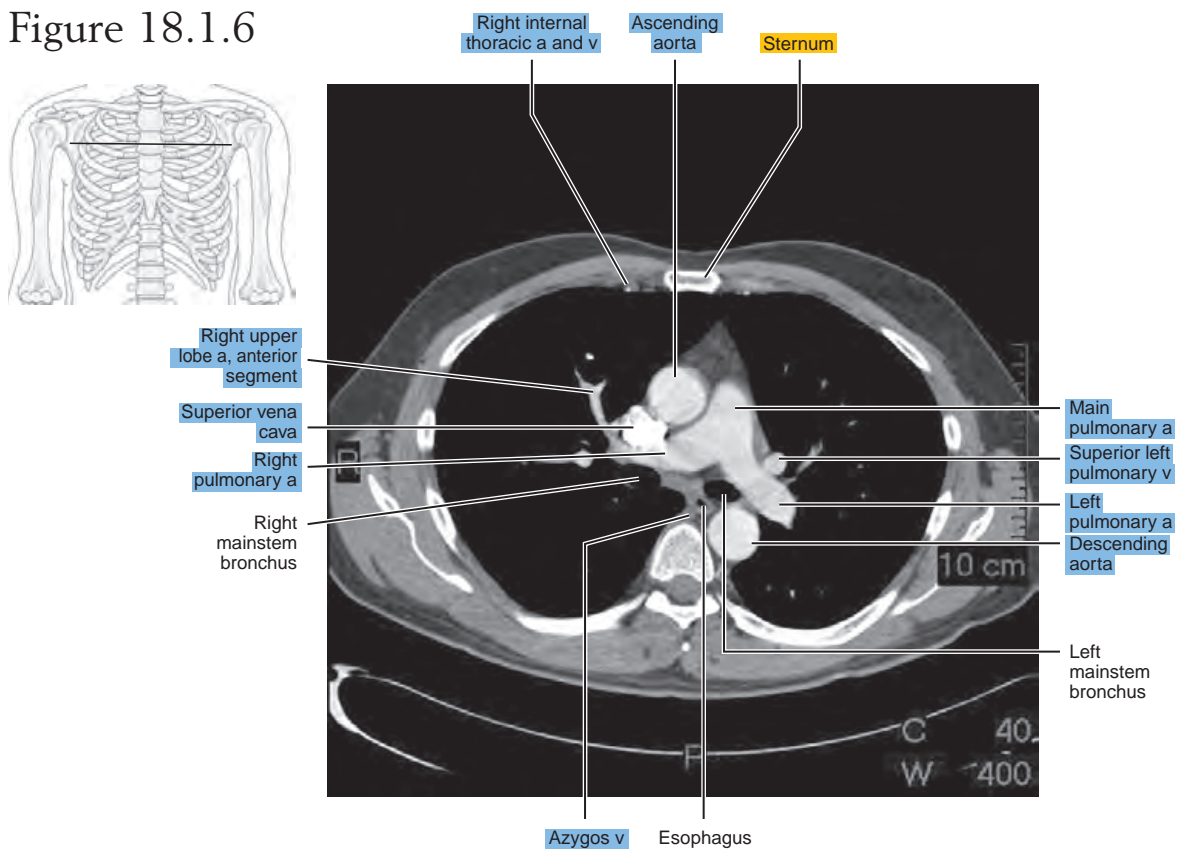


Figure 18.1.7

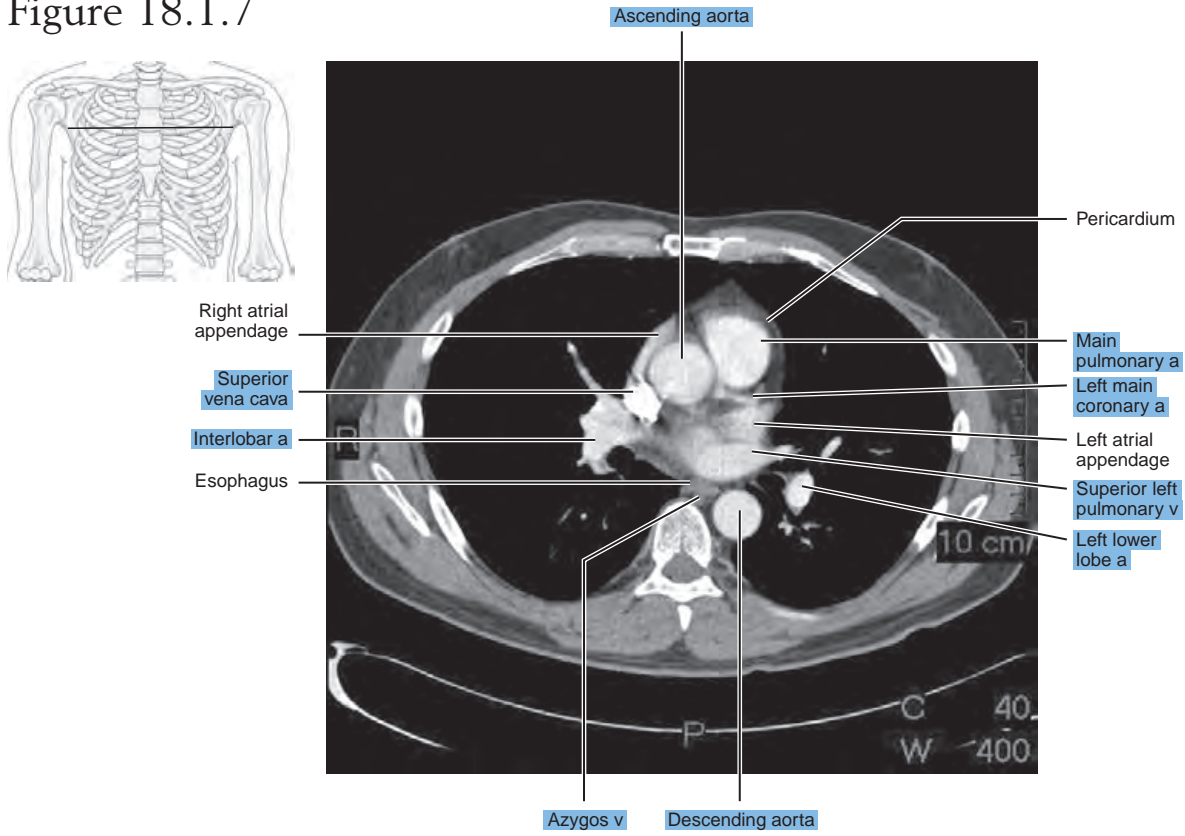


Figure 18.1.8

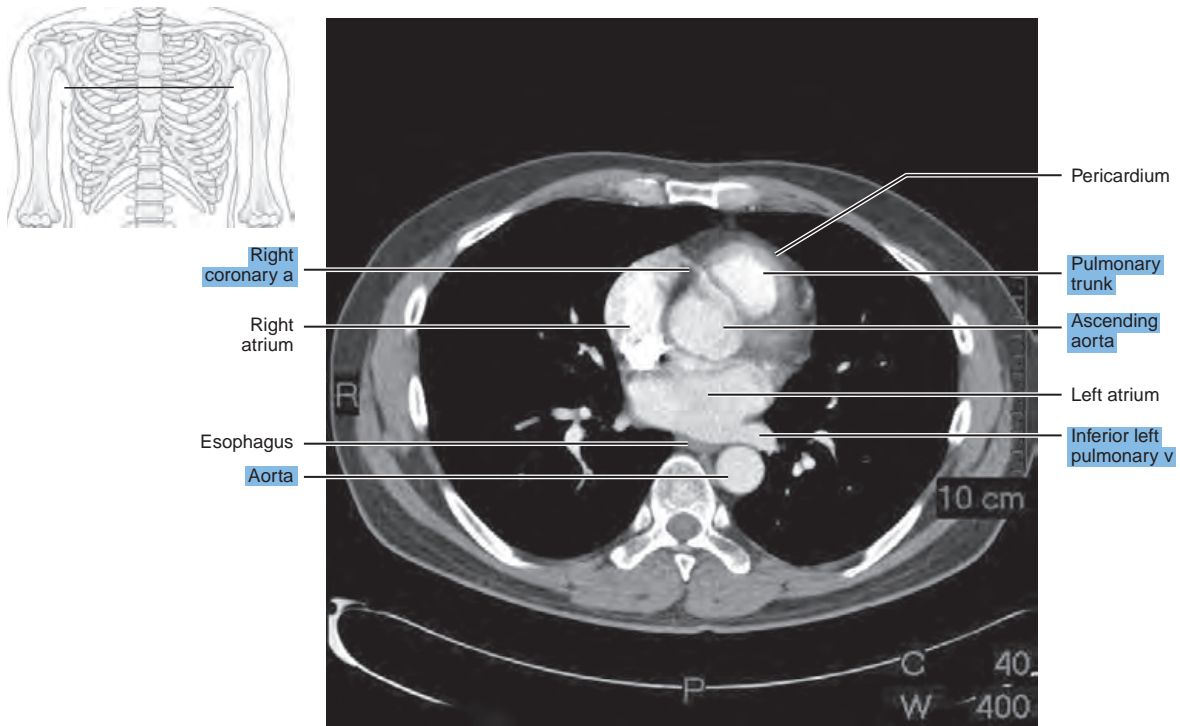


Figure 18.1.9

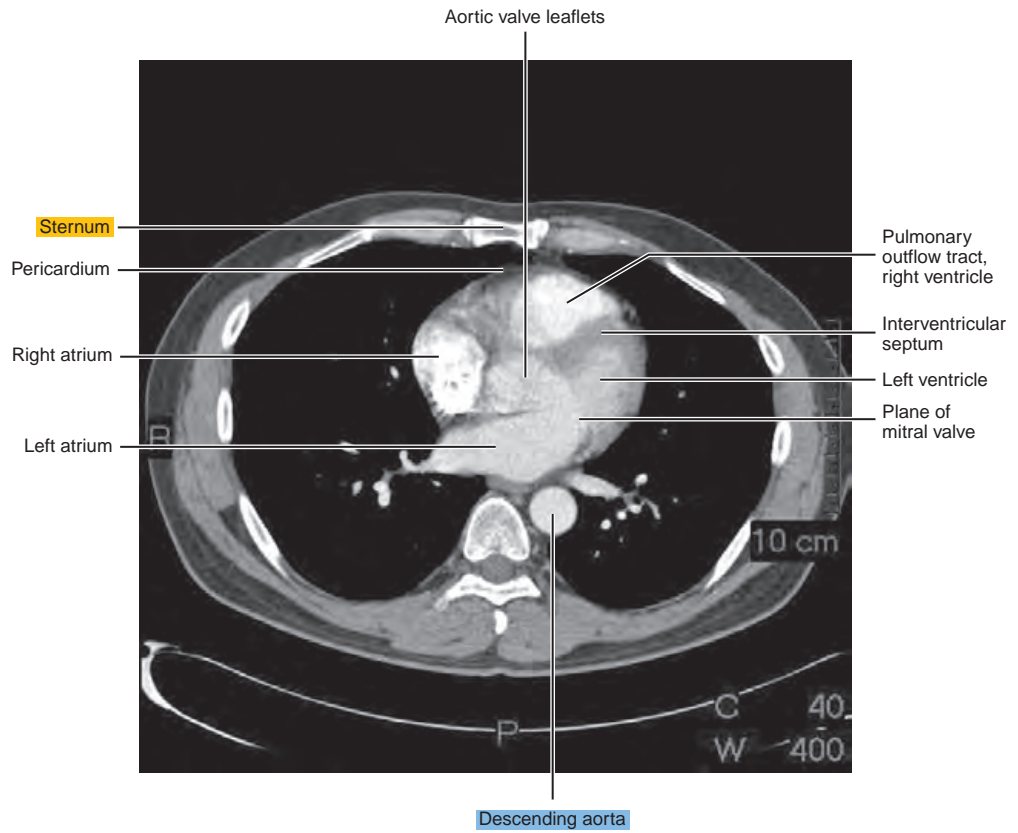
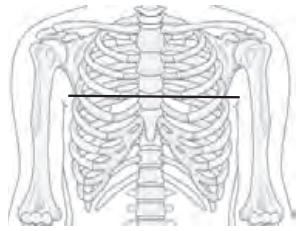


Figure 18.1.10

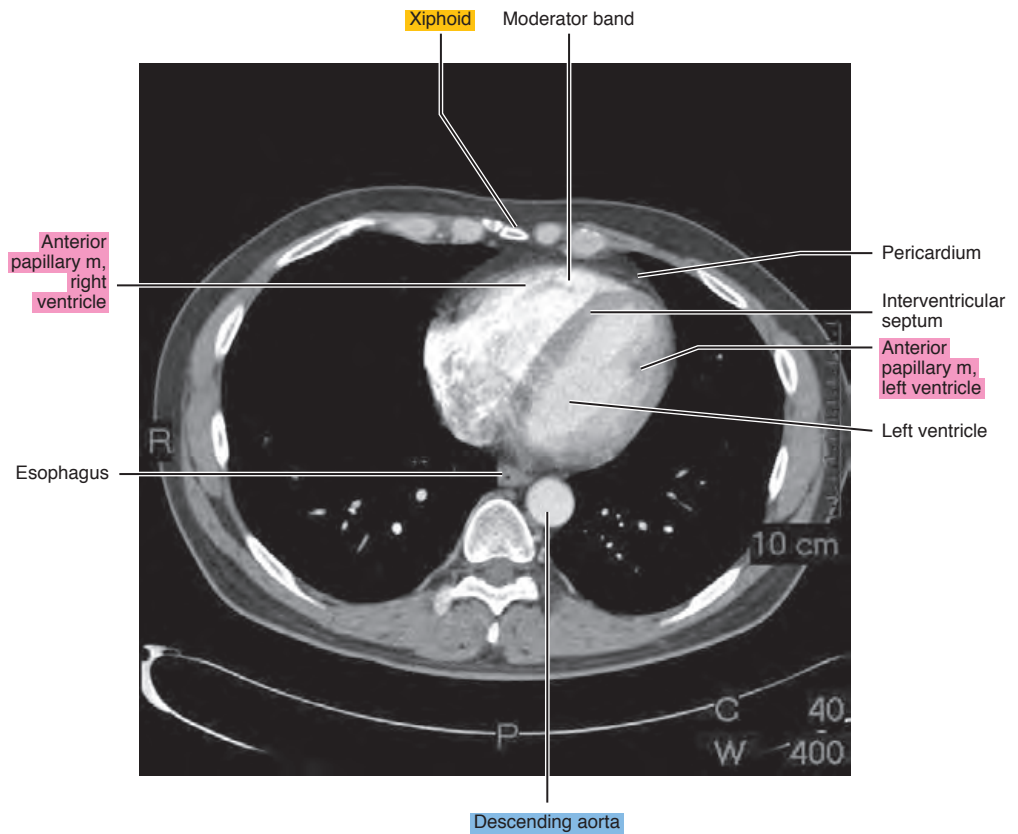
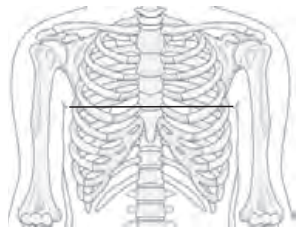


Figure 18.1.11

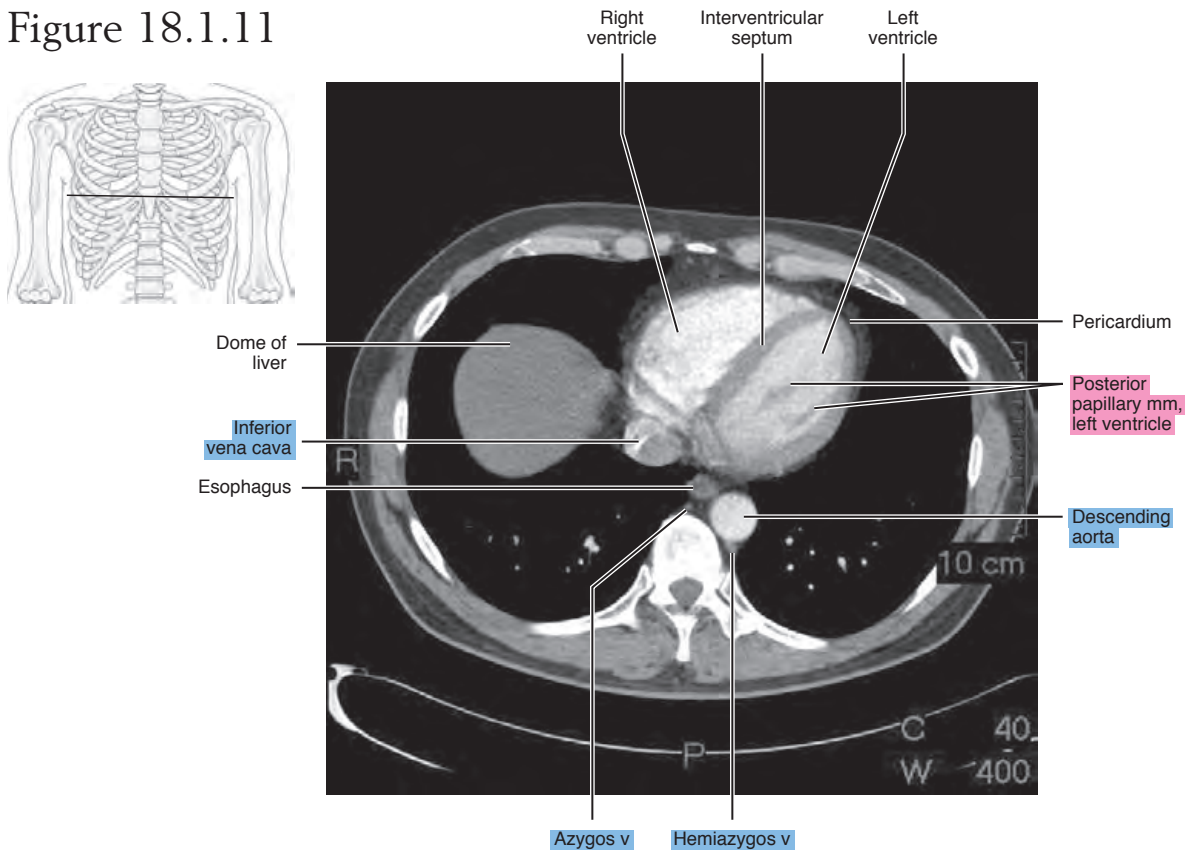


Figure 18.1.12

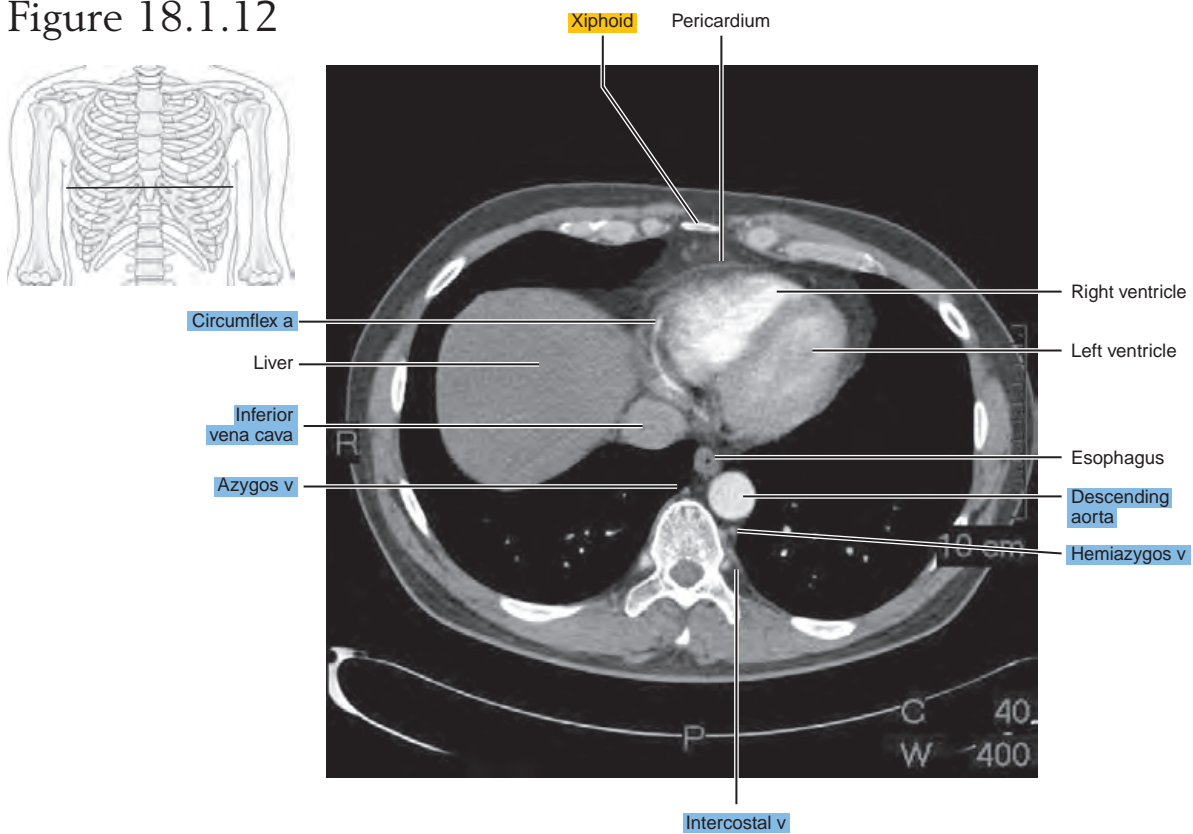
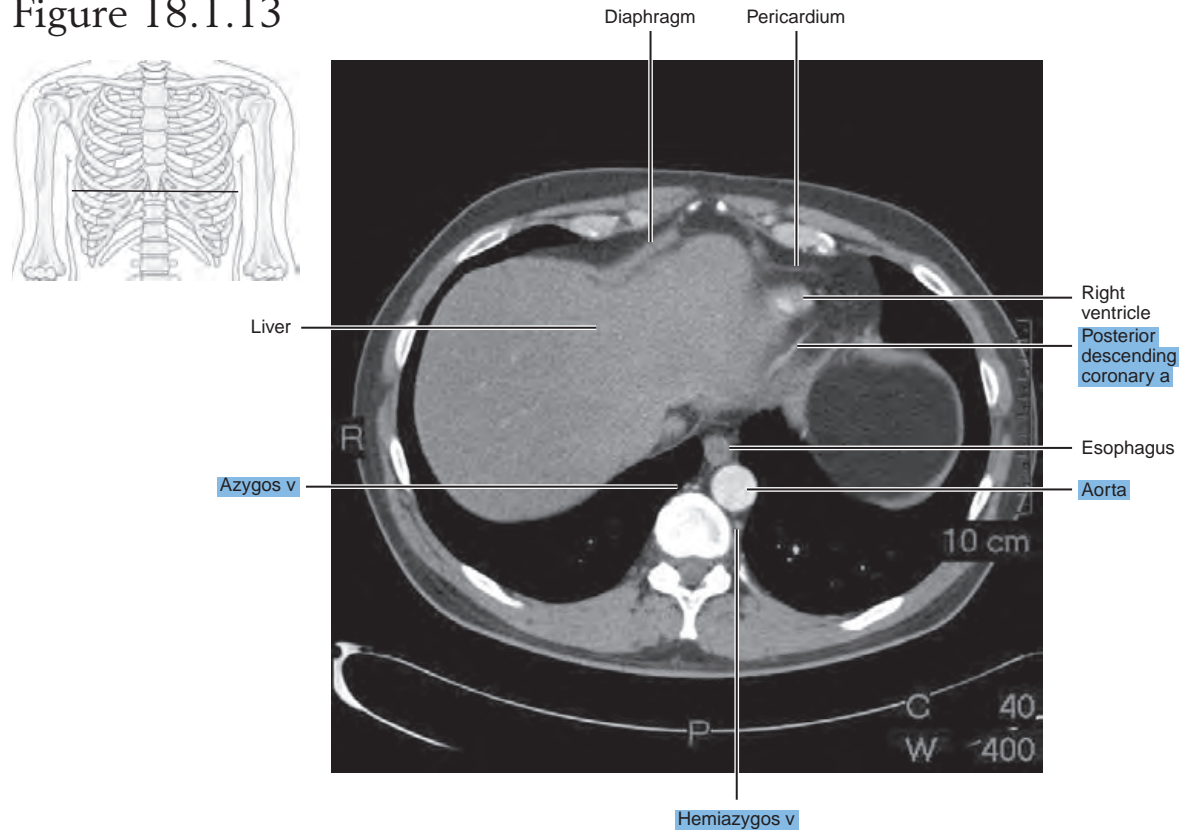


Figure 18.1.13



SAGITTAL

Figure 18.2.1A

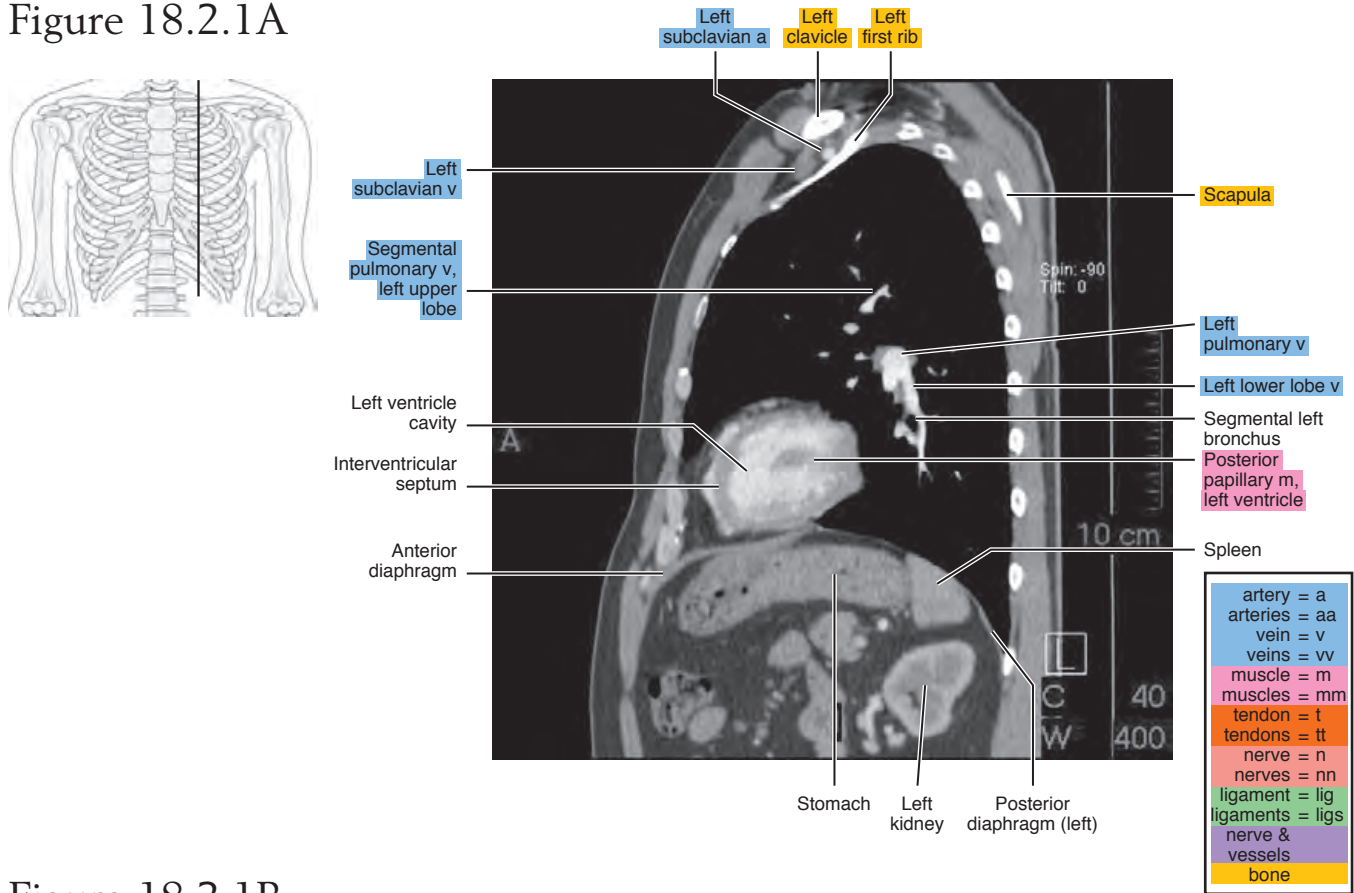


Figure 18.2.1B

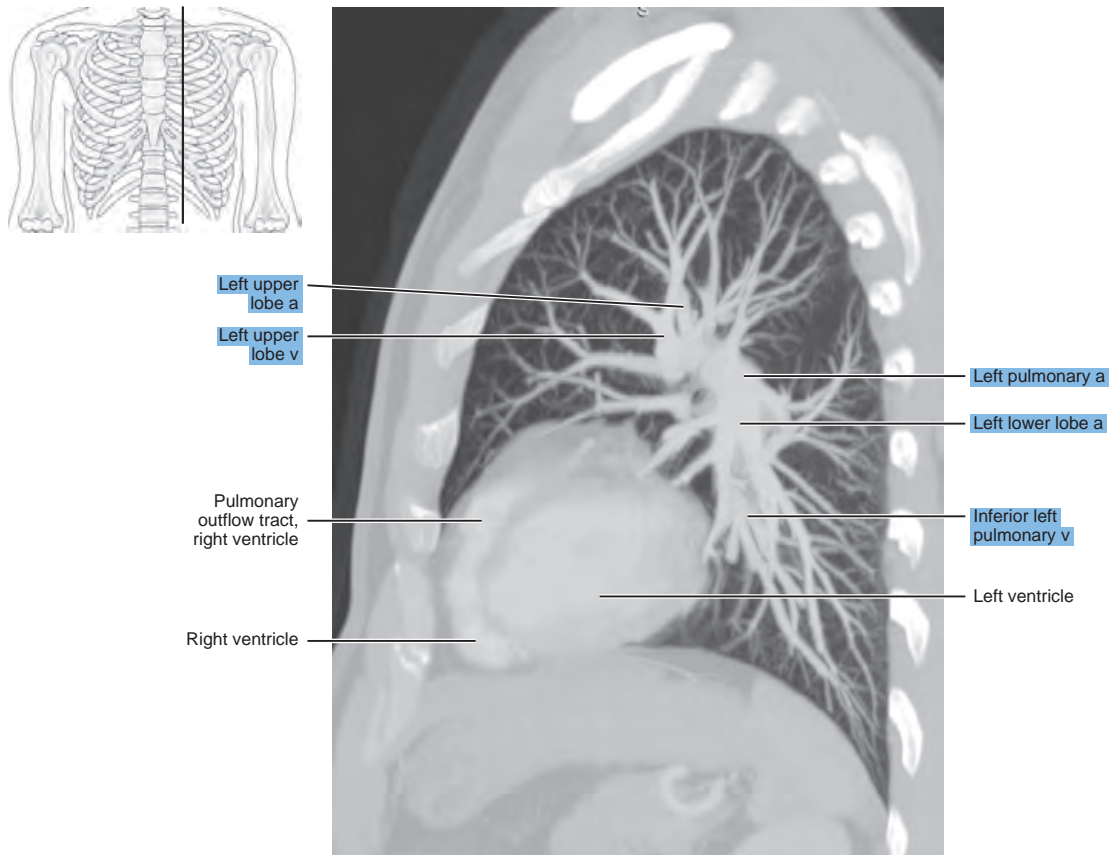


Figure 18.2.2

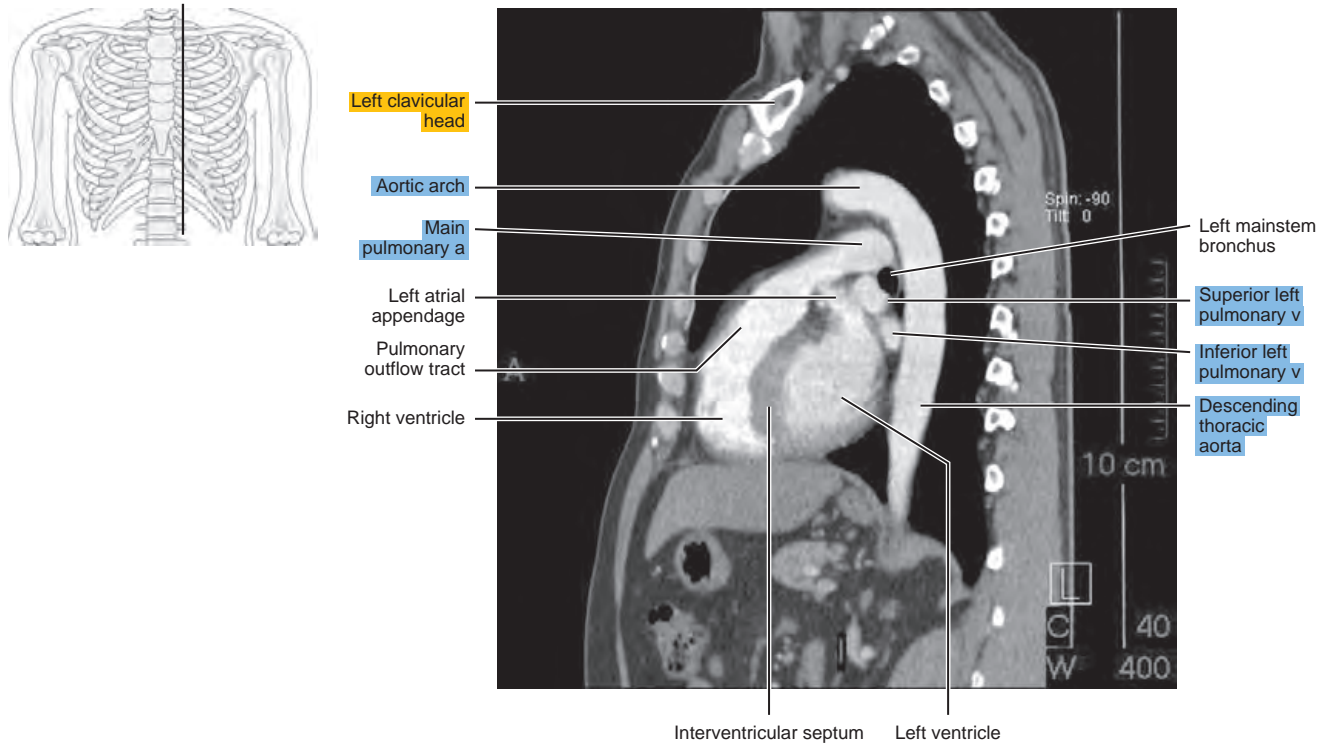


Figure 18.2.3

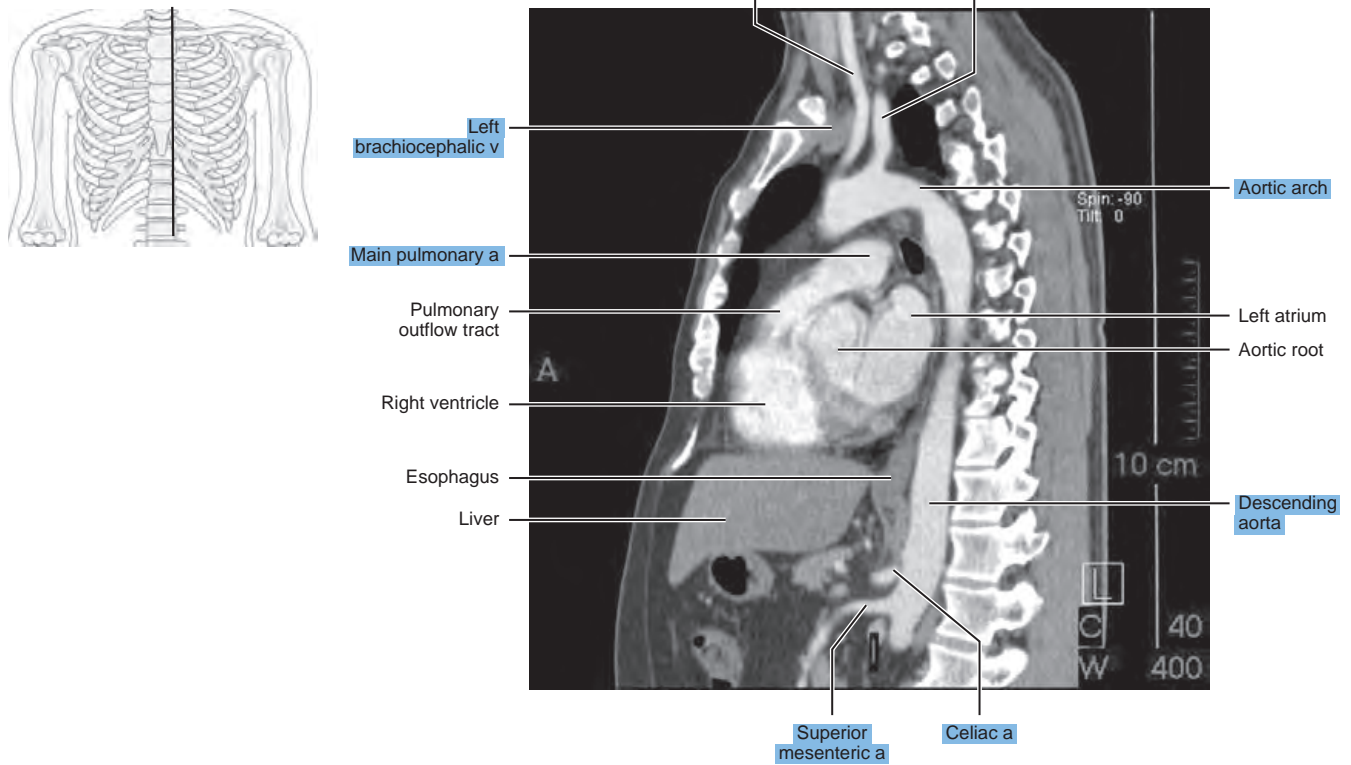


Figure 18.2.4

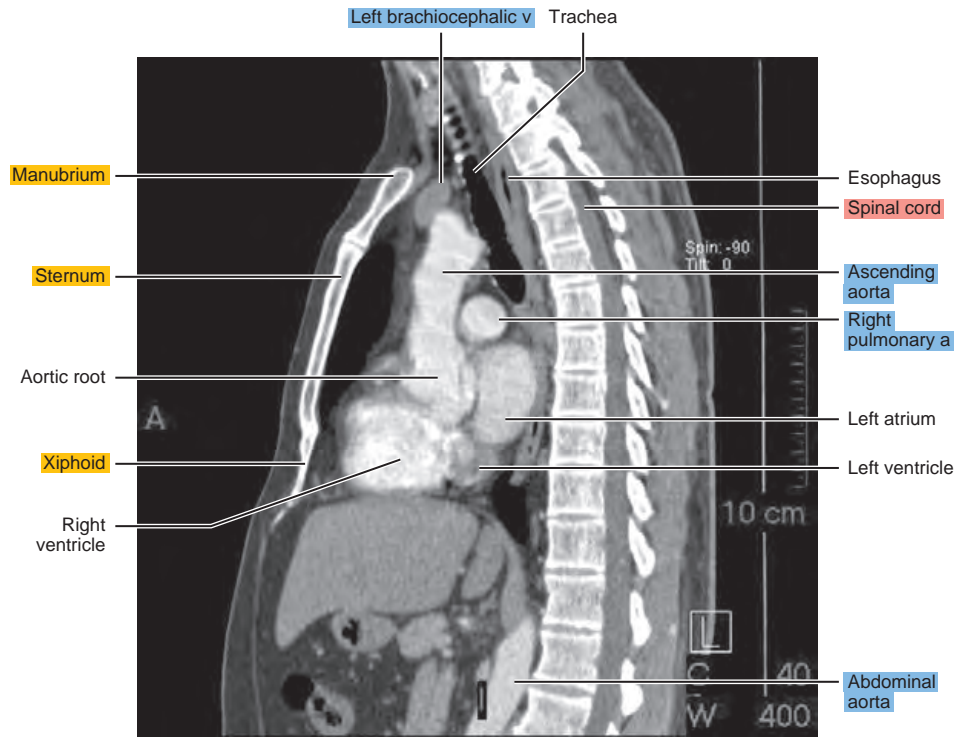
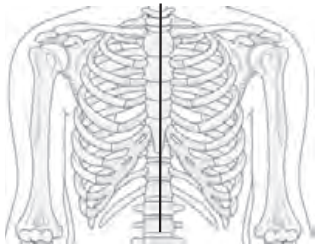


Figure 18.2.5

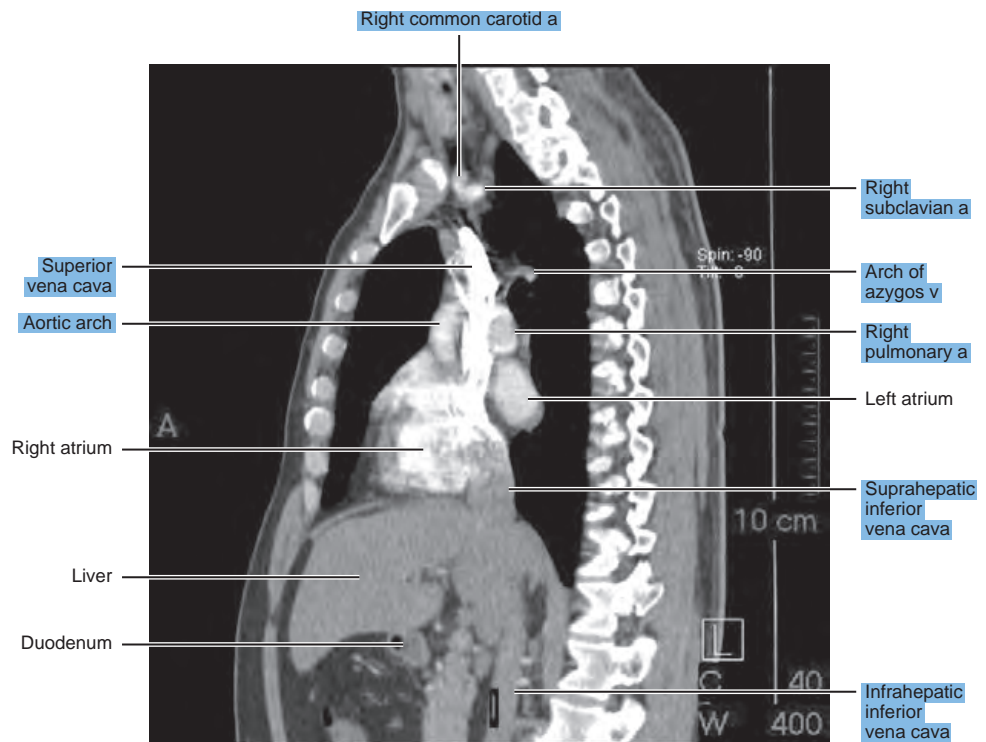
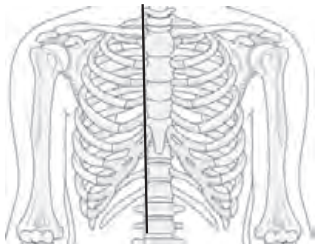
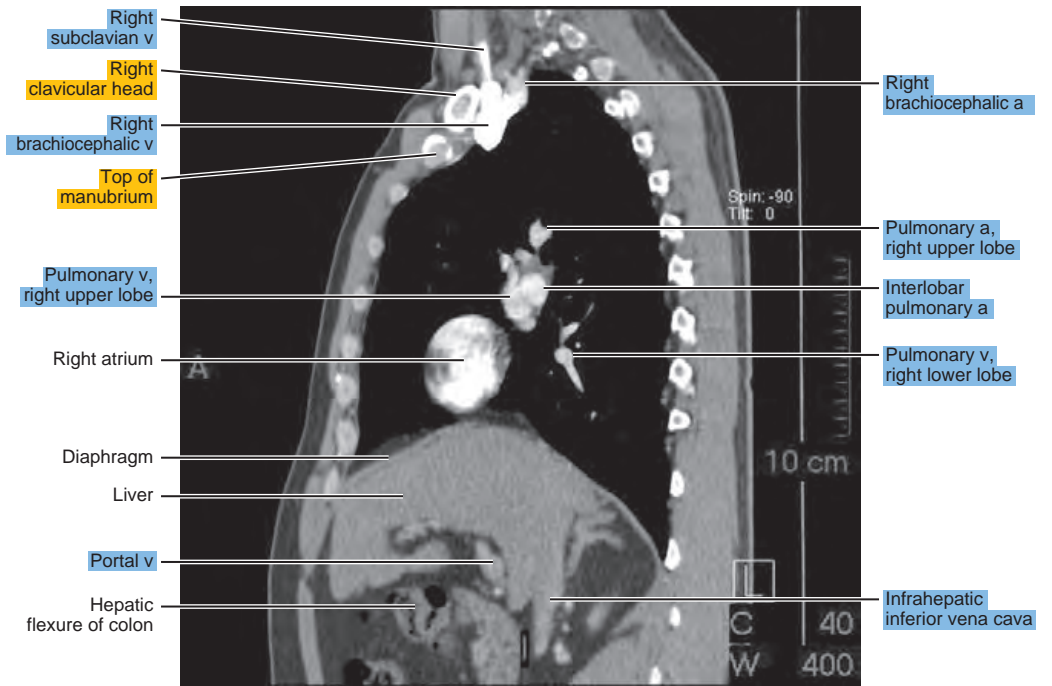
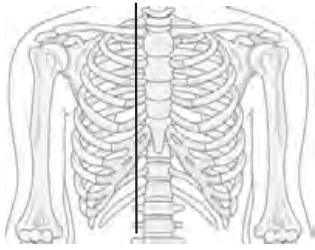


Figure 18.2.6



CORONAL

Figure 18.3.1

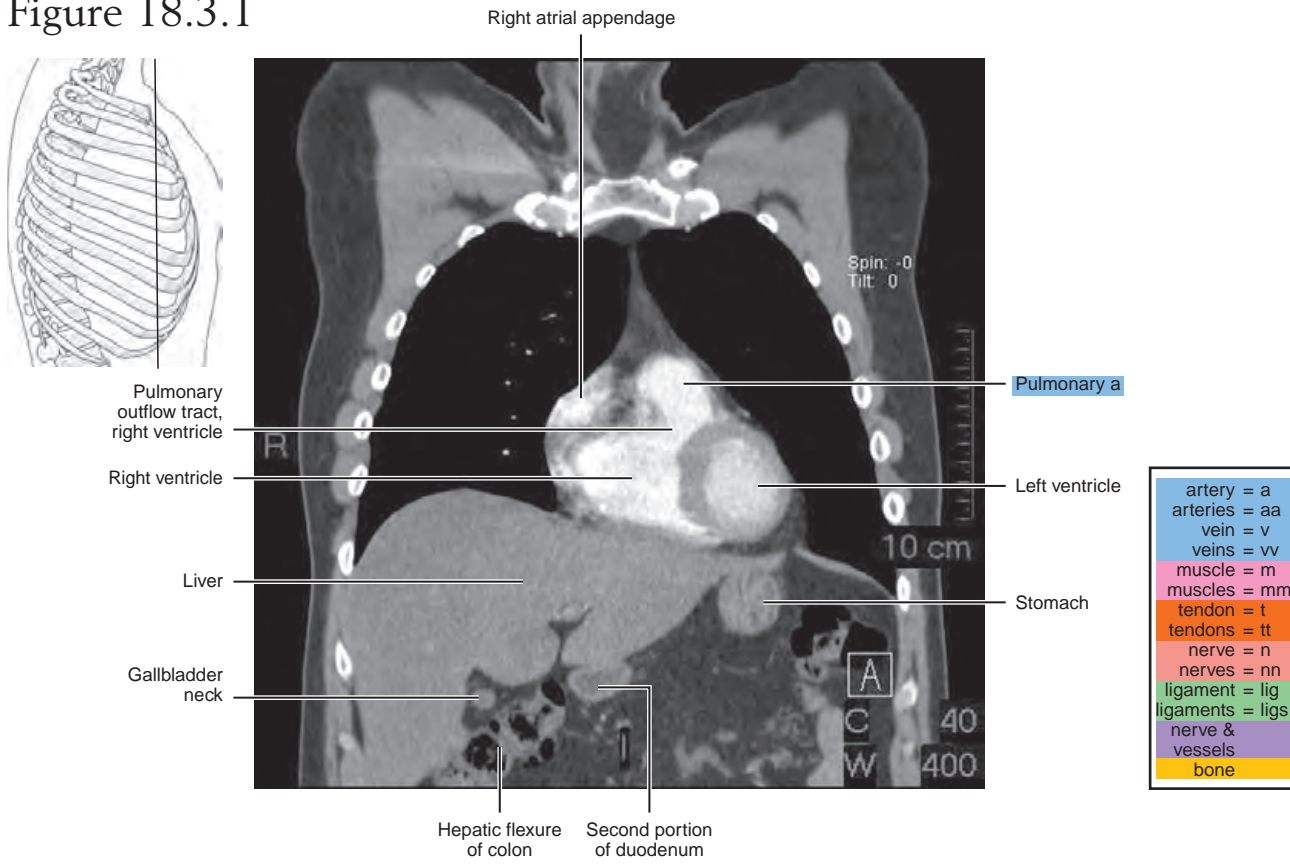


Figure 18.3.2

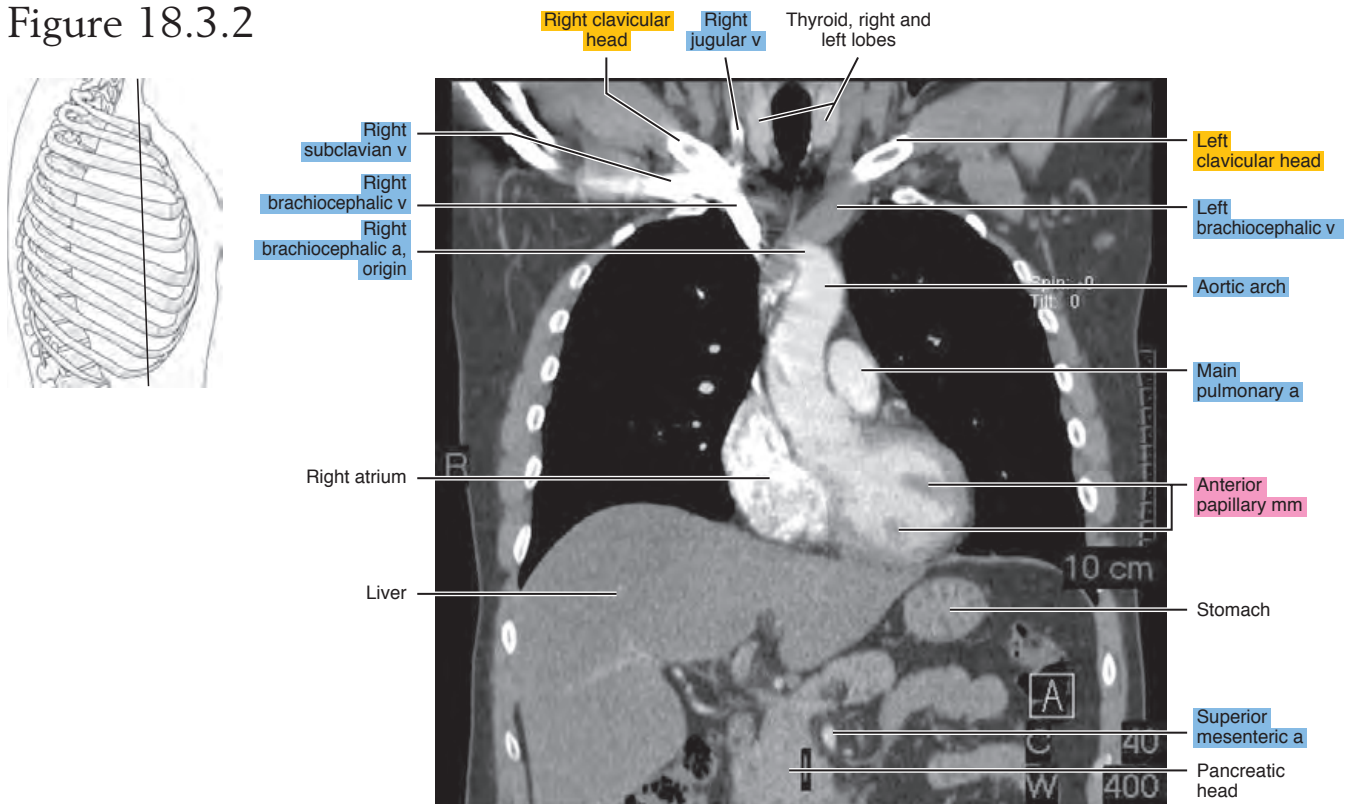


Figure 18.3.3A

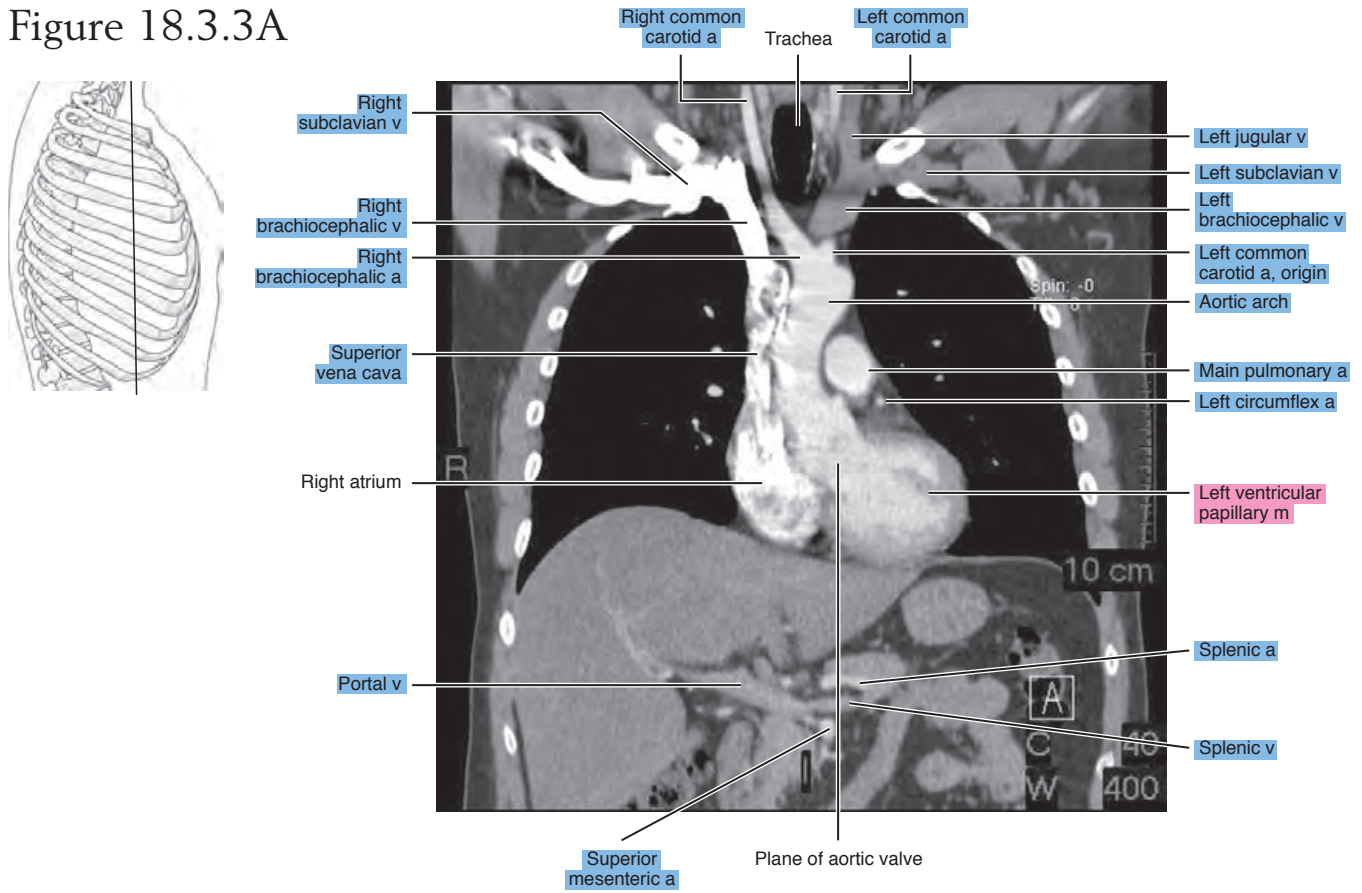


Figure 18.3.3B

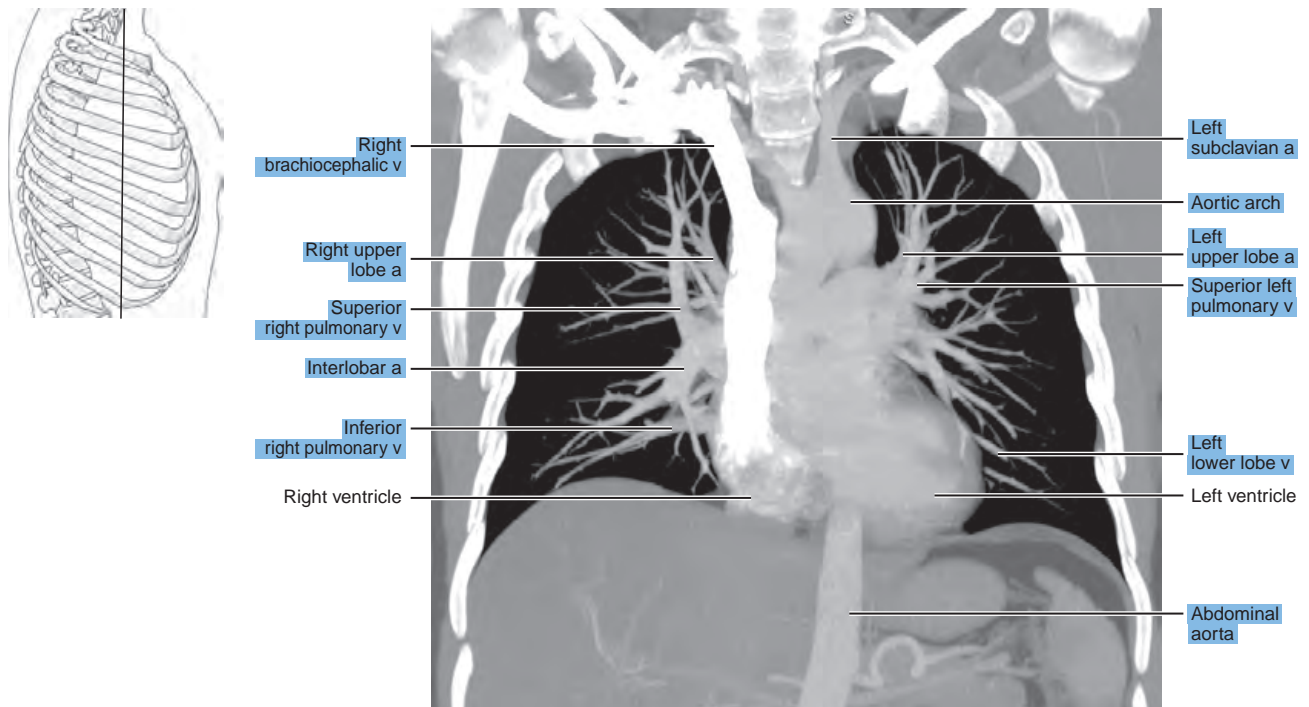


Figure 18.3.4

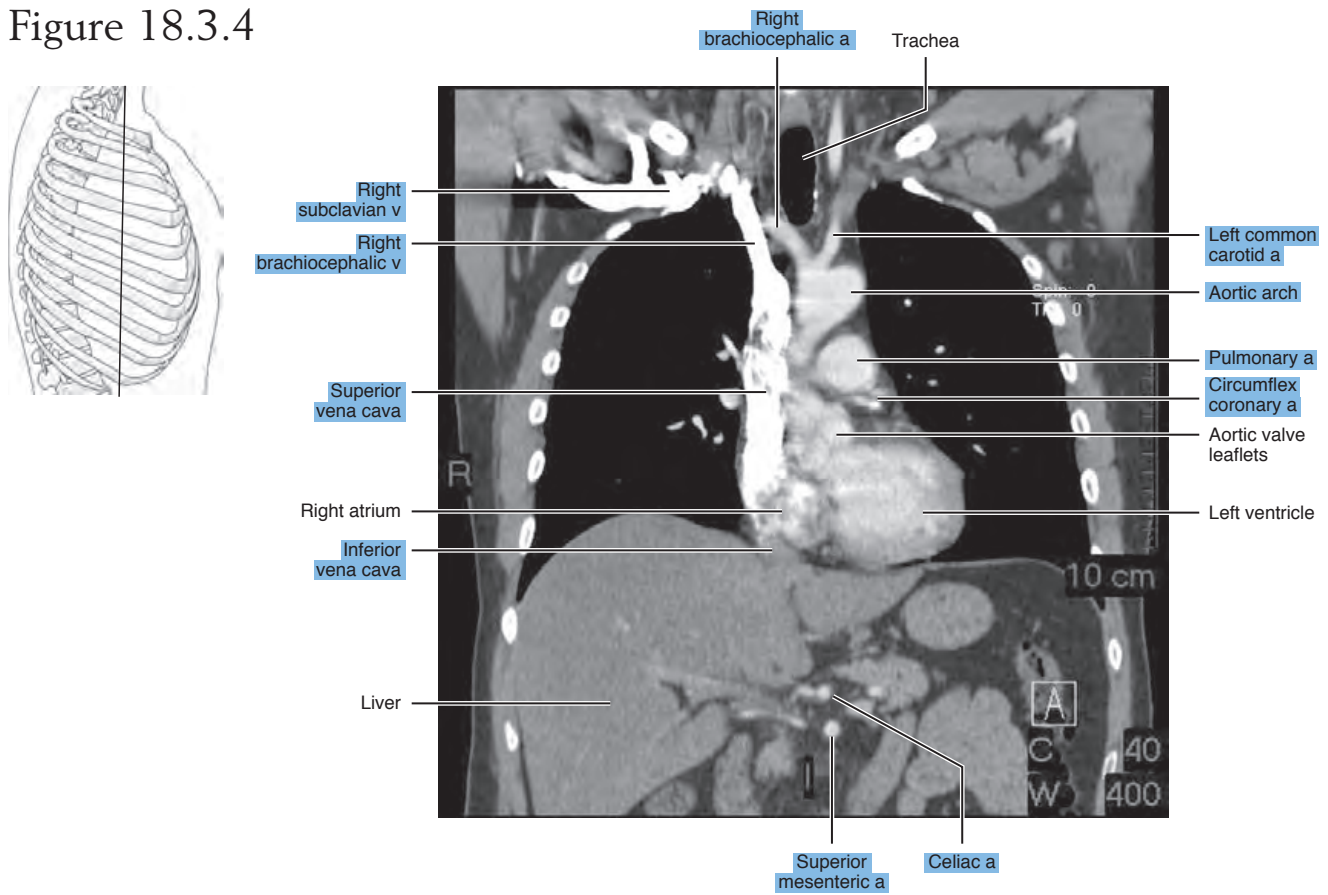


Figure 18.3.5

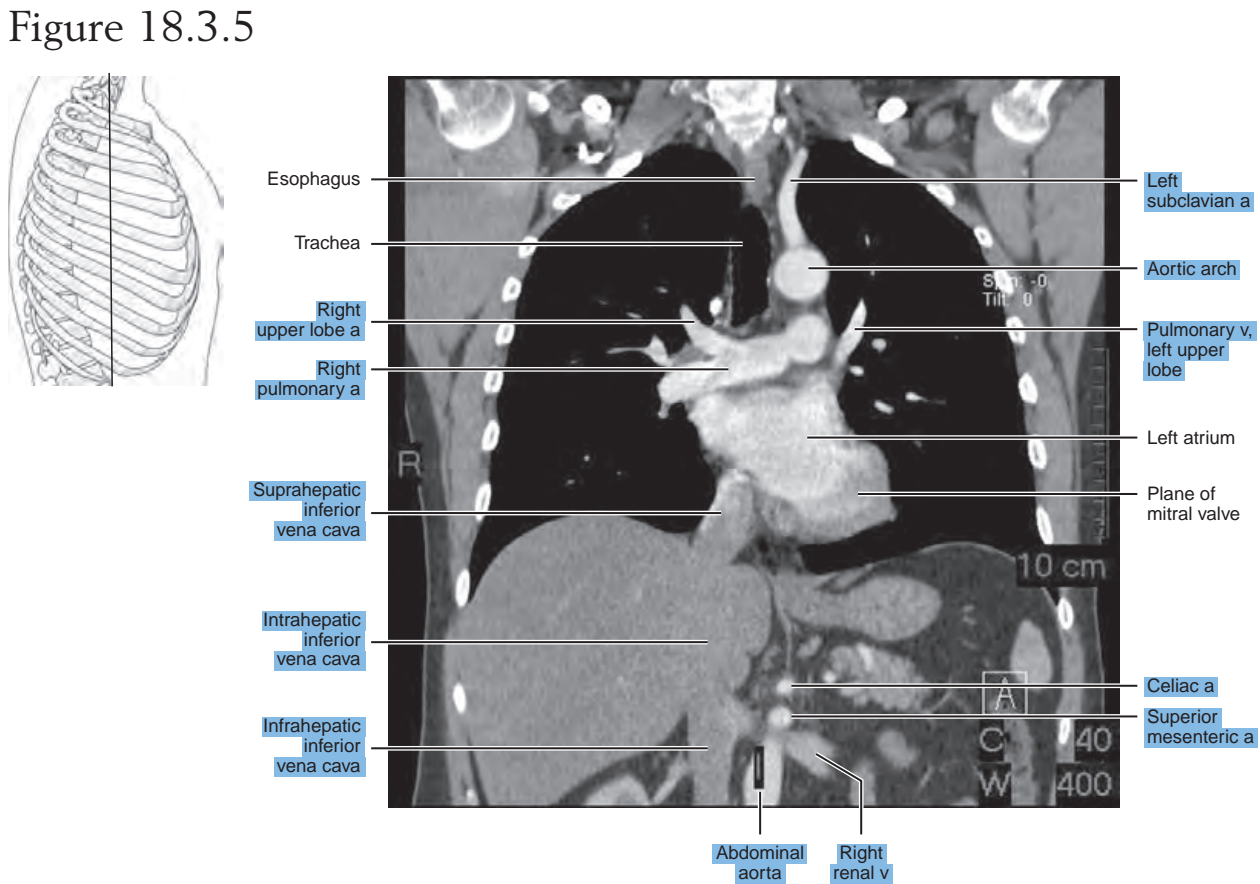


Figure 18.3.6A

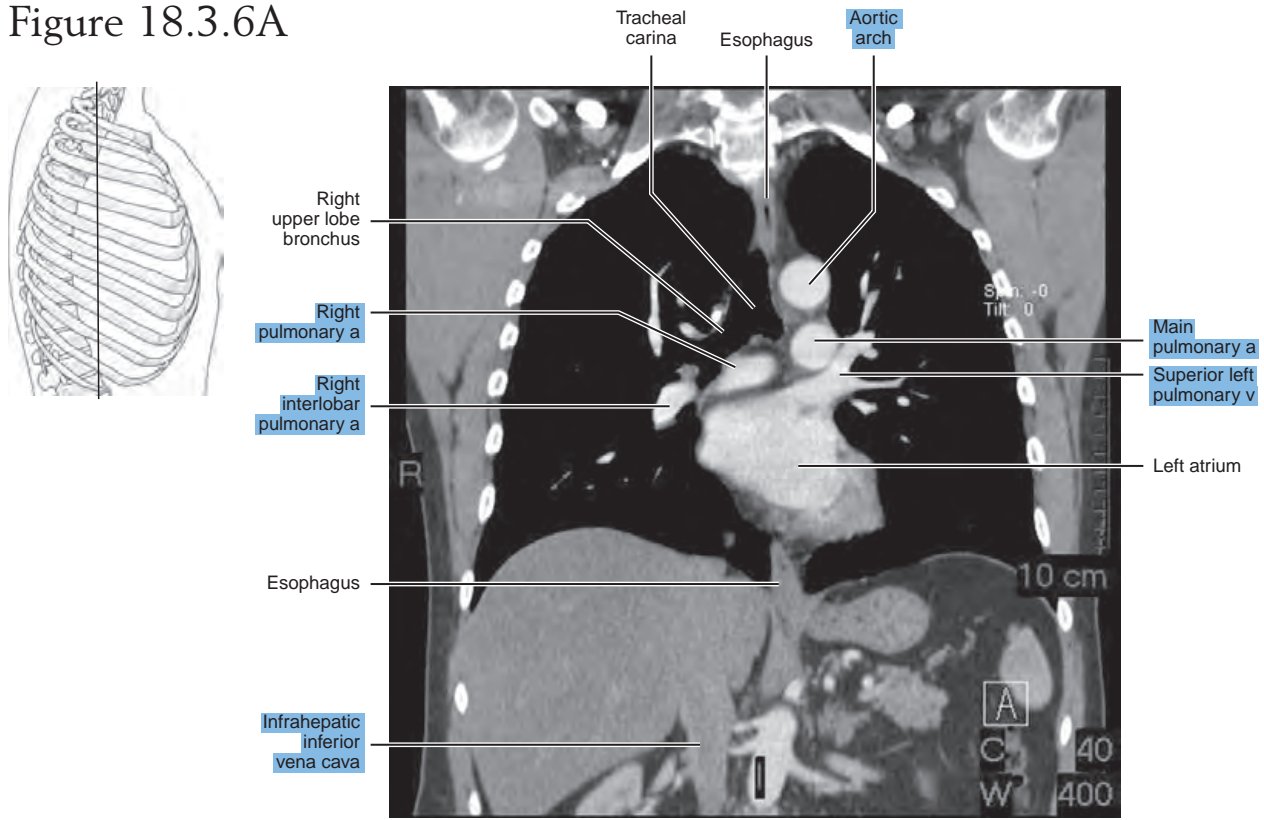


Figure 18.3.6B

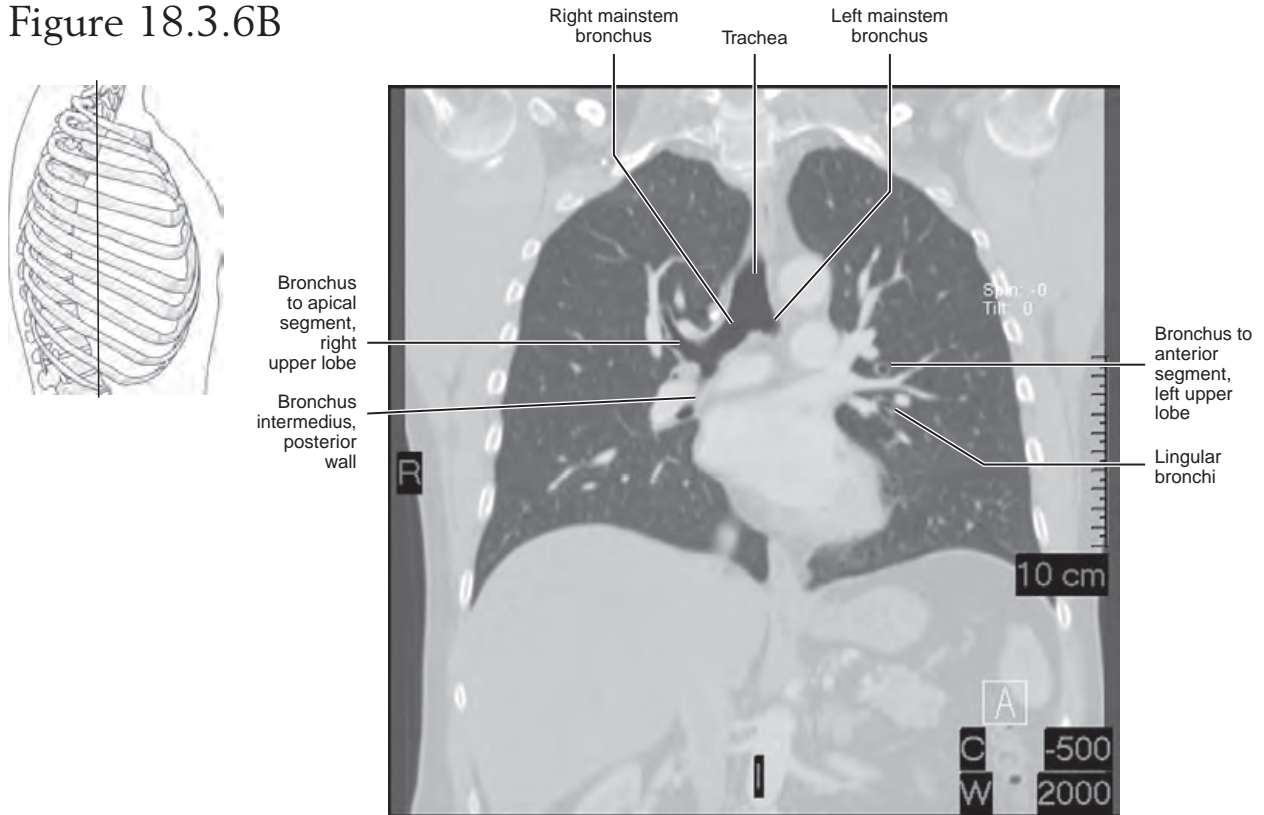


Figure 18.3.7A

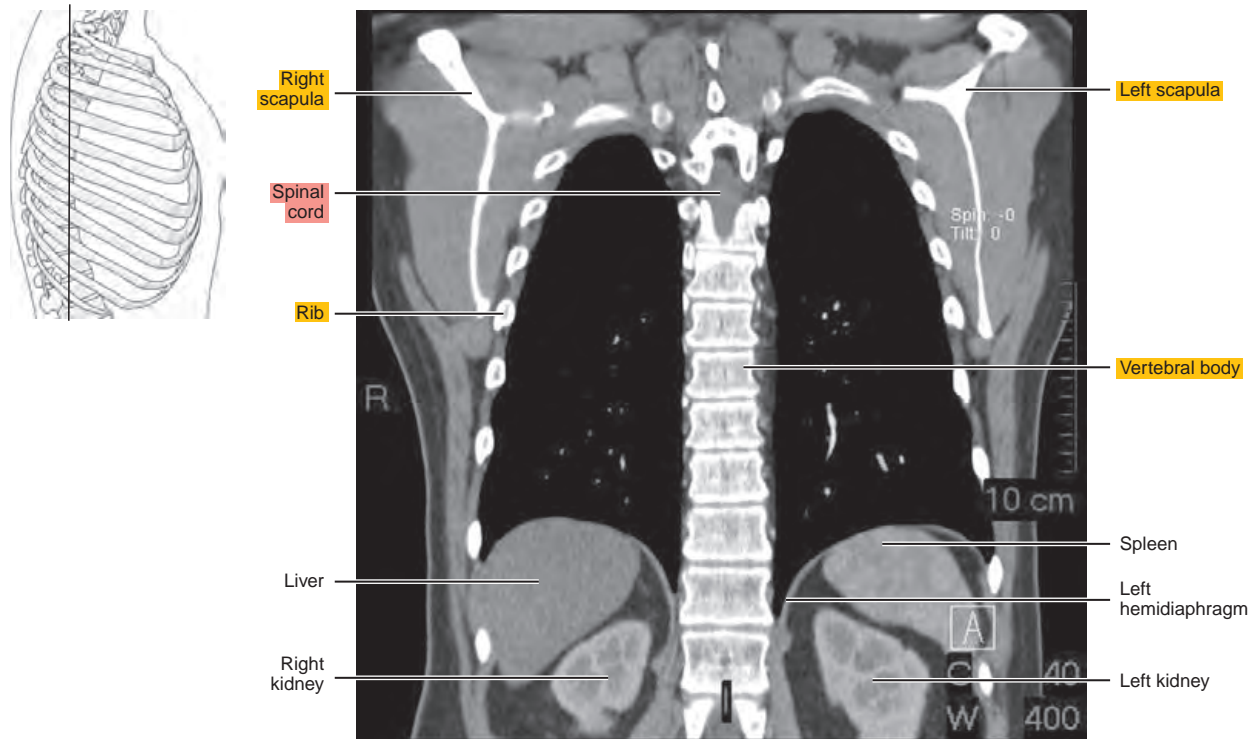


Figure 18.3.7B

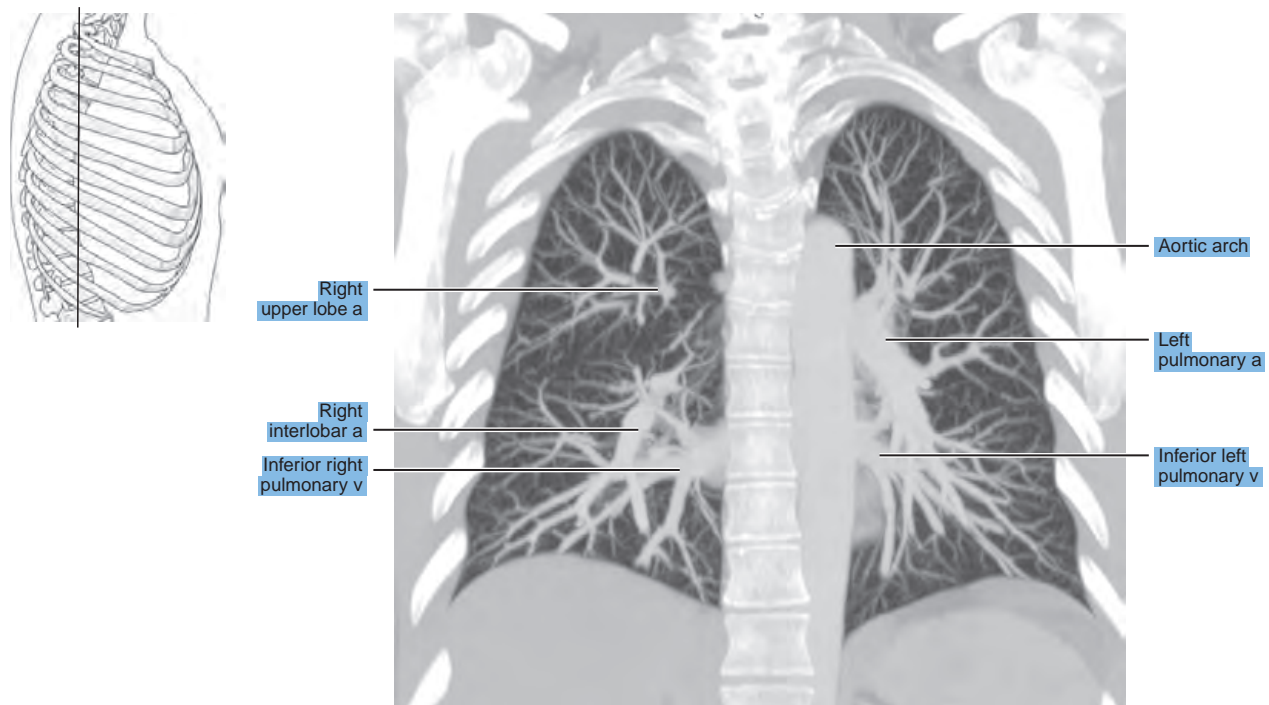
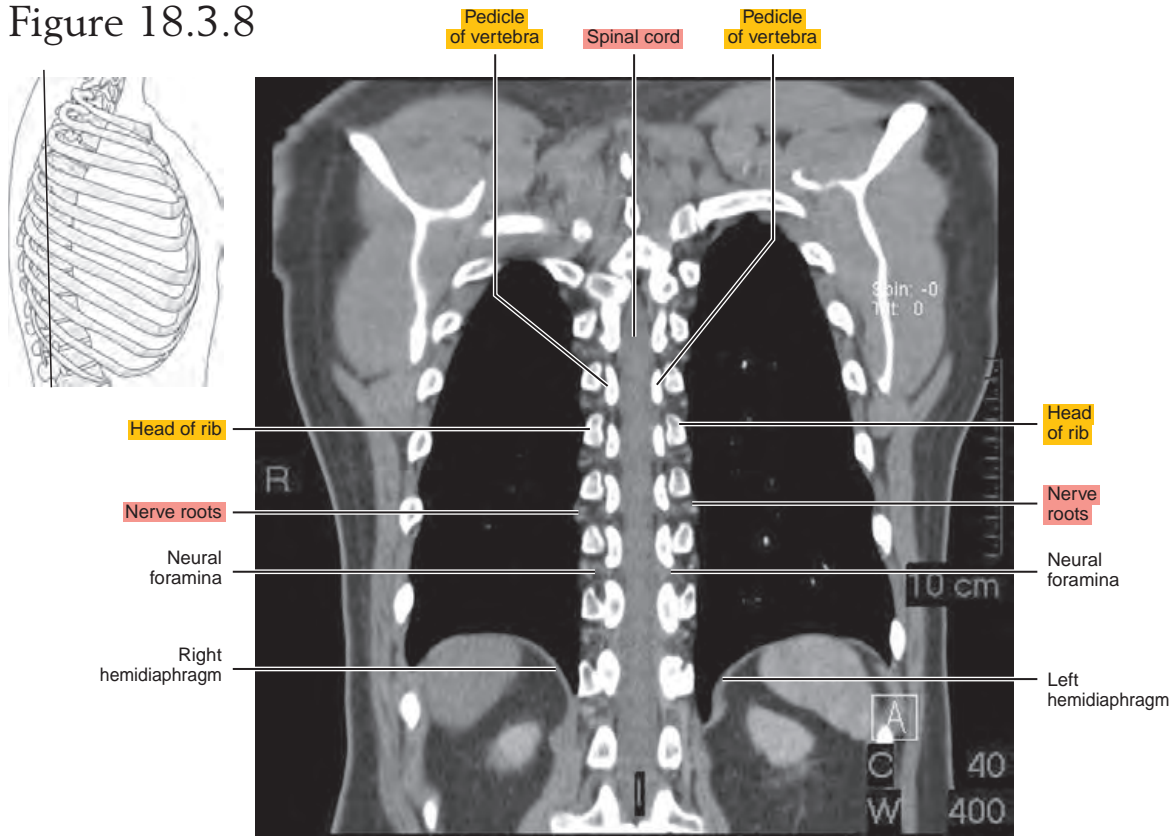


Figure 18.3.8



Chapter
19

MRI of the Heart

AXIAL

Figure 19.1.1

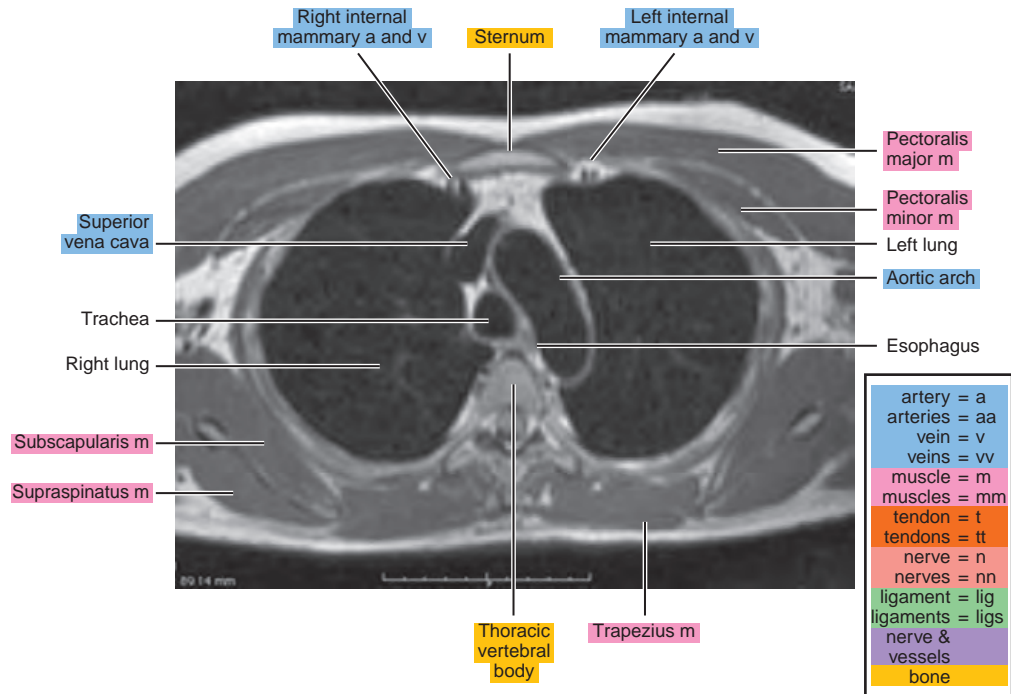
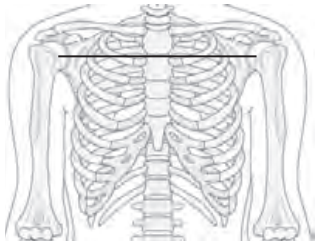


Figure 19.1.2

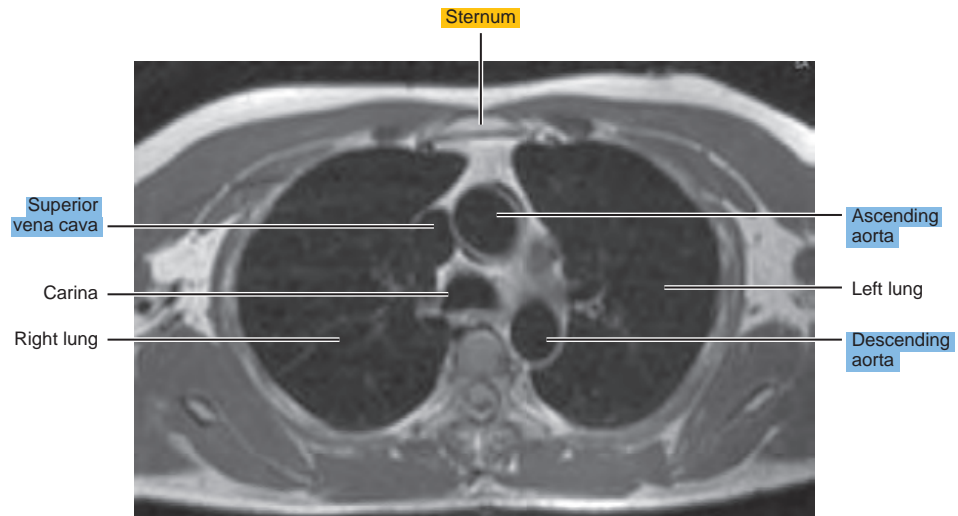
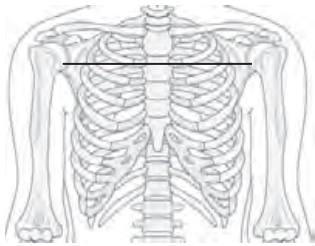


Figure 19.1.3

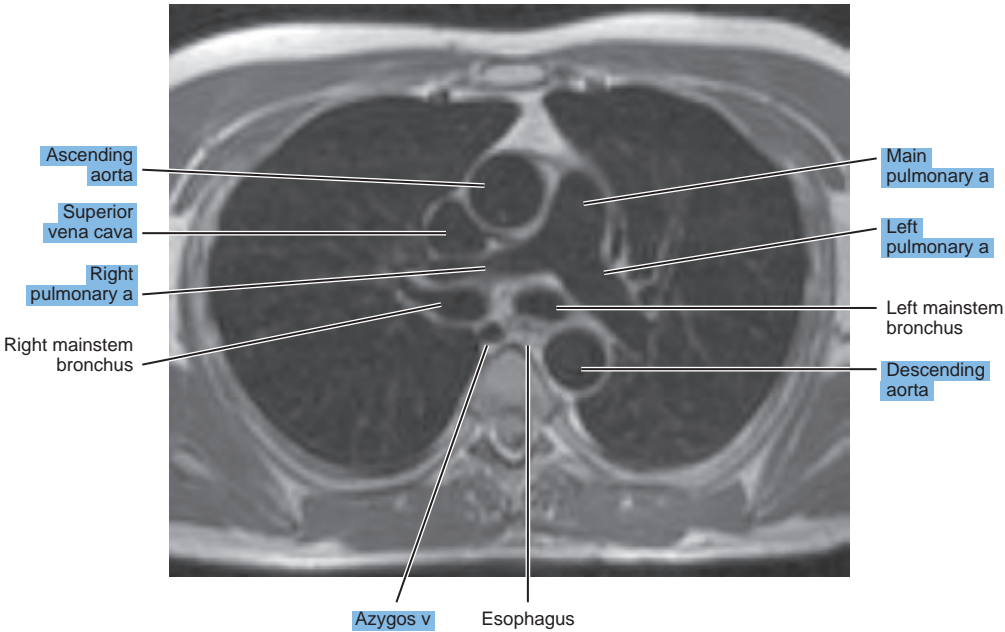
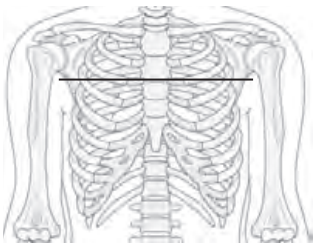


Figure 19.1.4

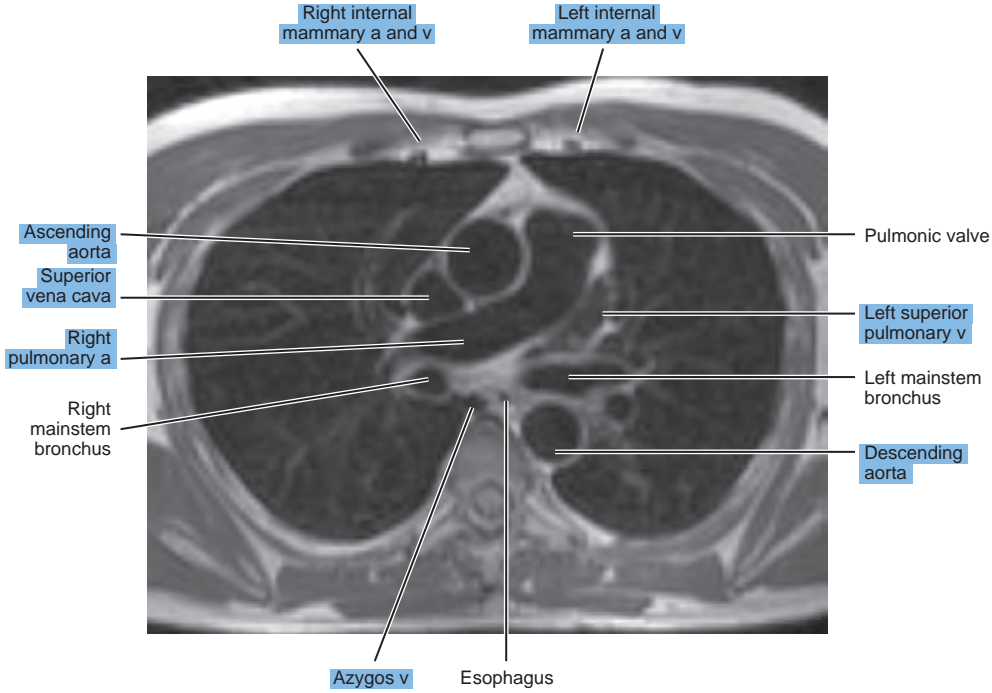
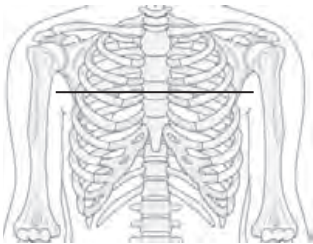


Figure 19.1.5

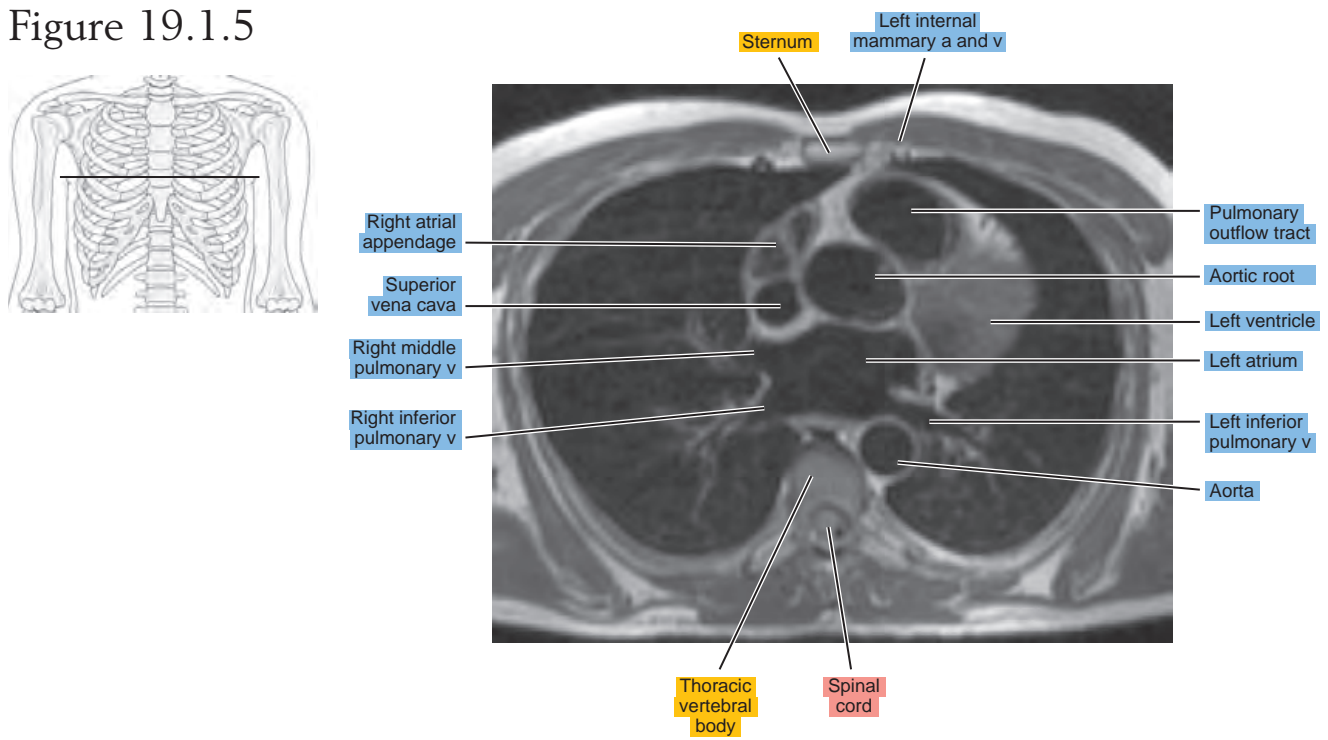


Figure 19.1.6

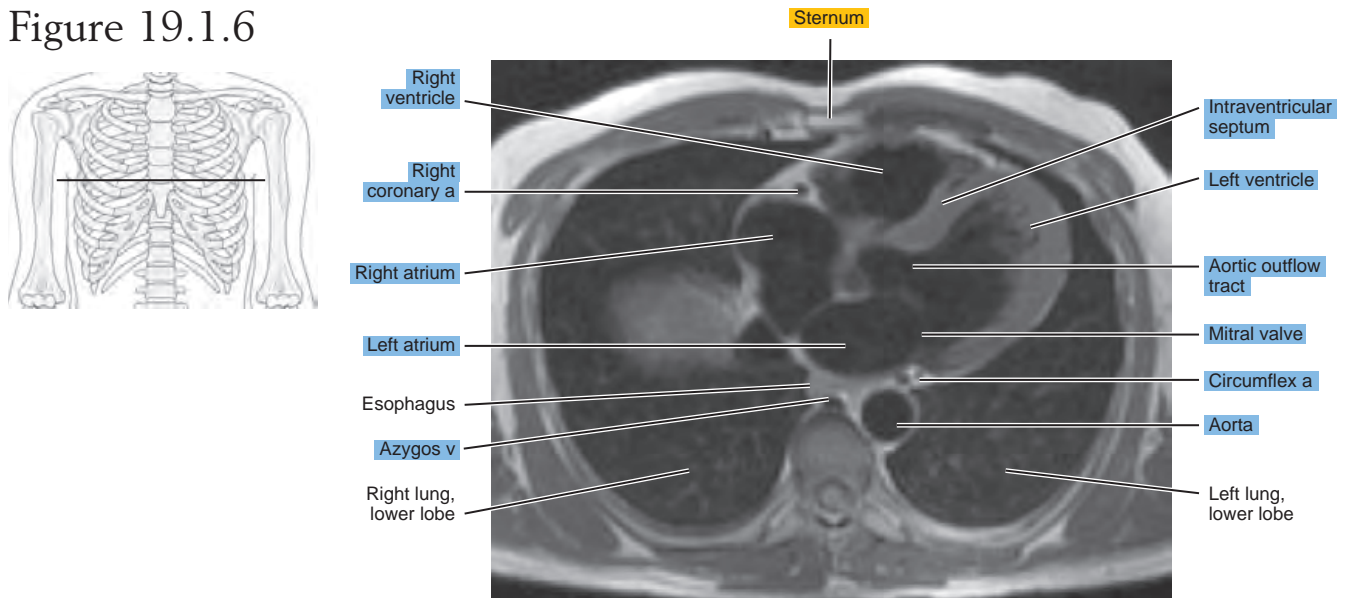
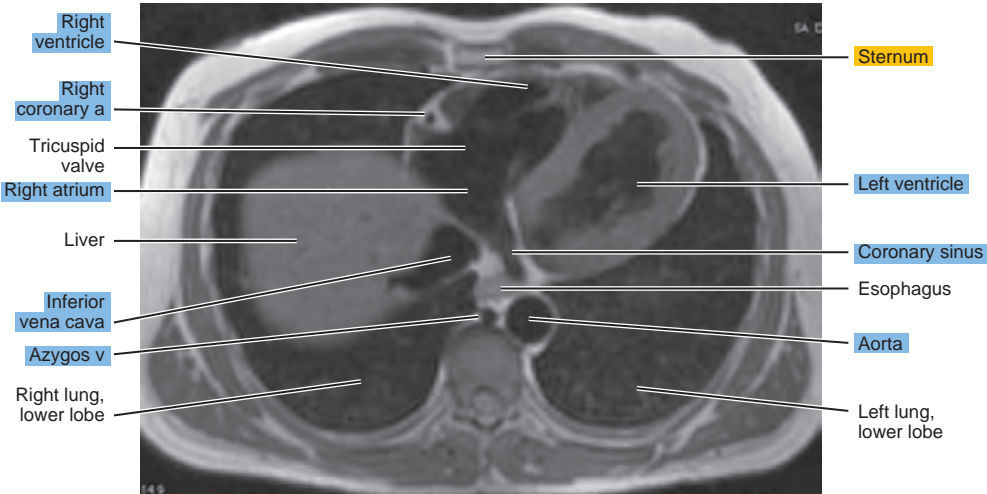
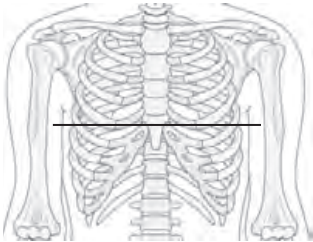


Figure 19.1.7



SAGITTAL

Figure 19.2.1

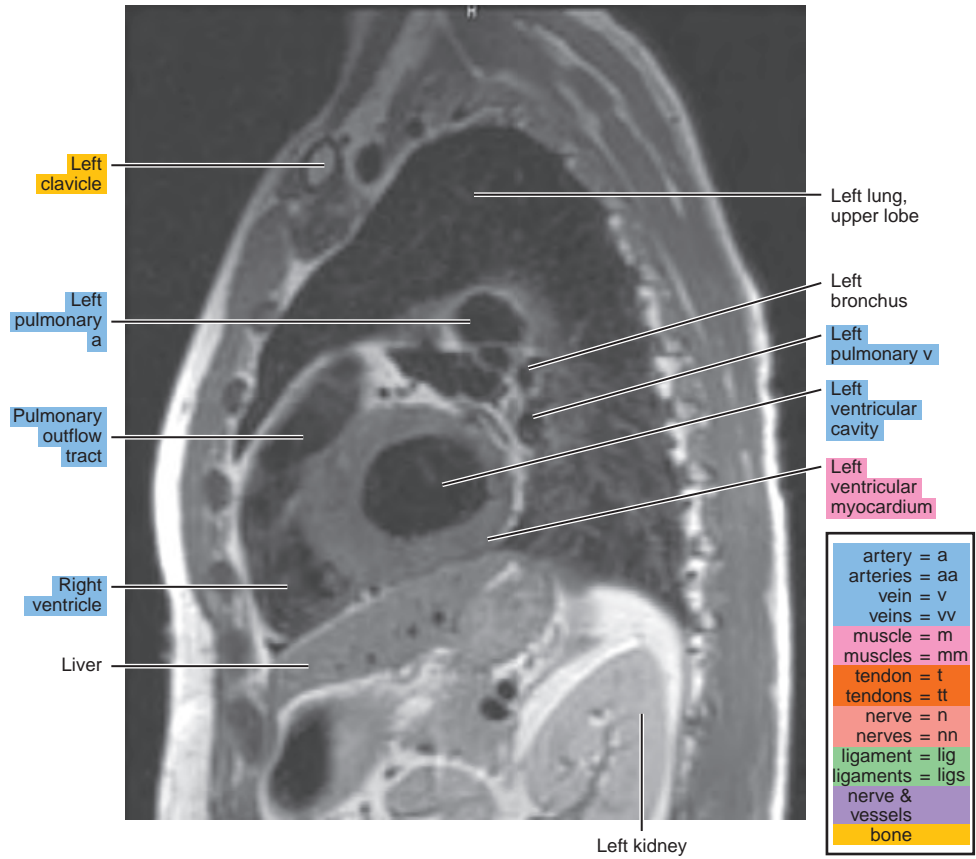
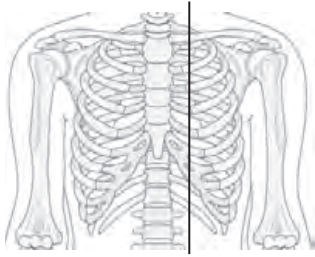


Figure 19.2.2

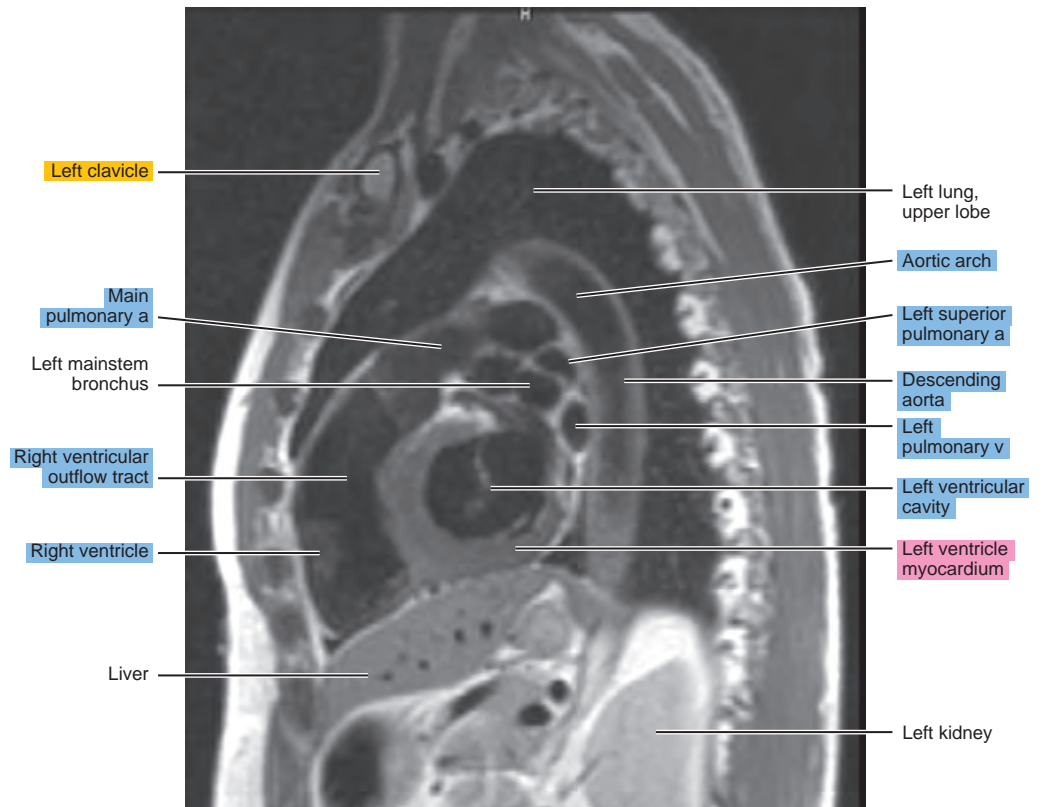
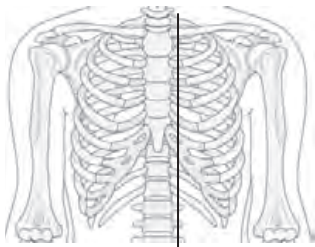
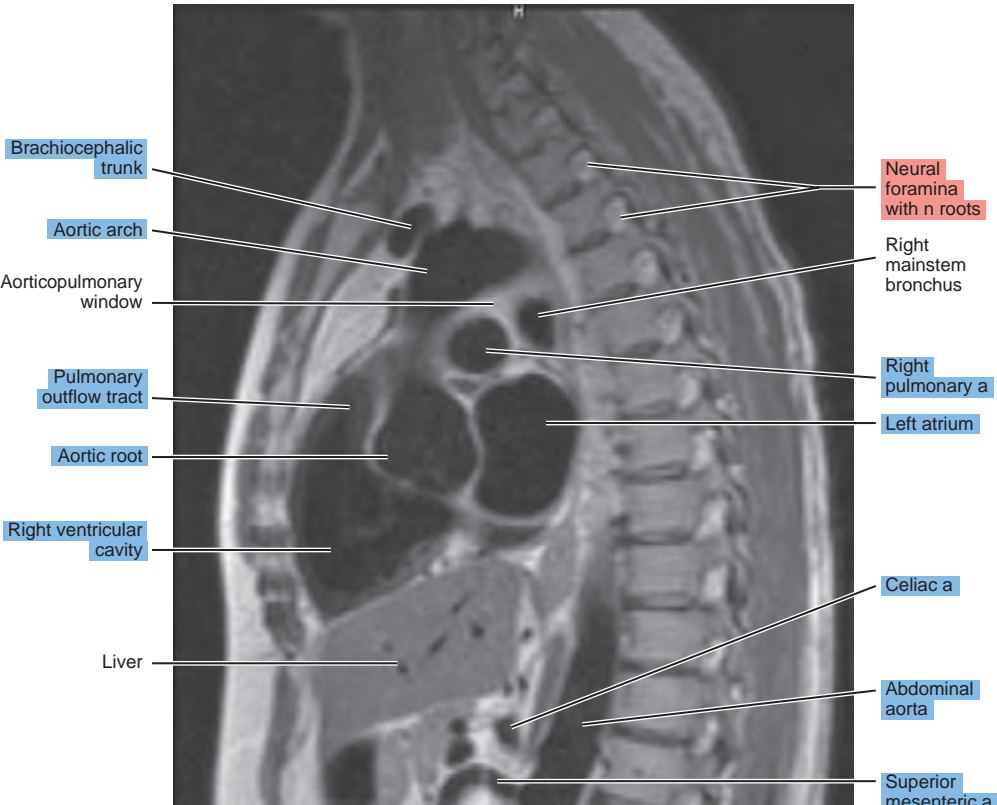
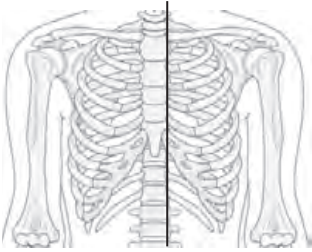


Figure 19.2.3



Brachiocephalic trunk

Aortic arch

Aorticopulmonary window

Pulmonary outflow tract

Aortic root

Right ventricular cavity

Liver

Neural foramina with n roots

Right mainstem bronchus

Right pulmonary a

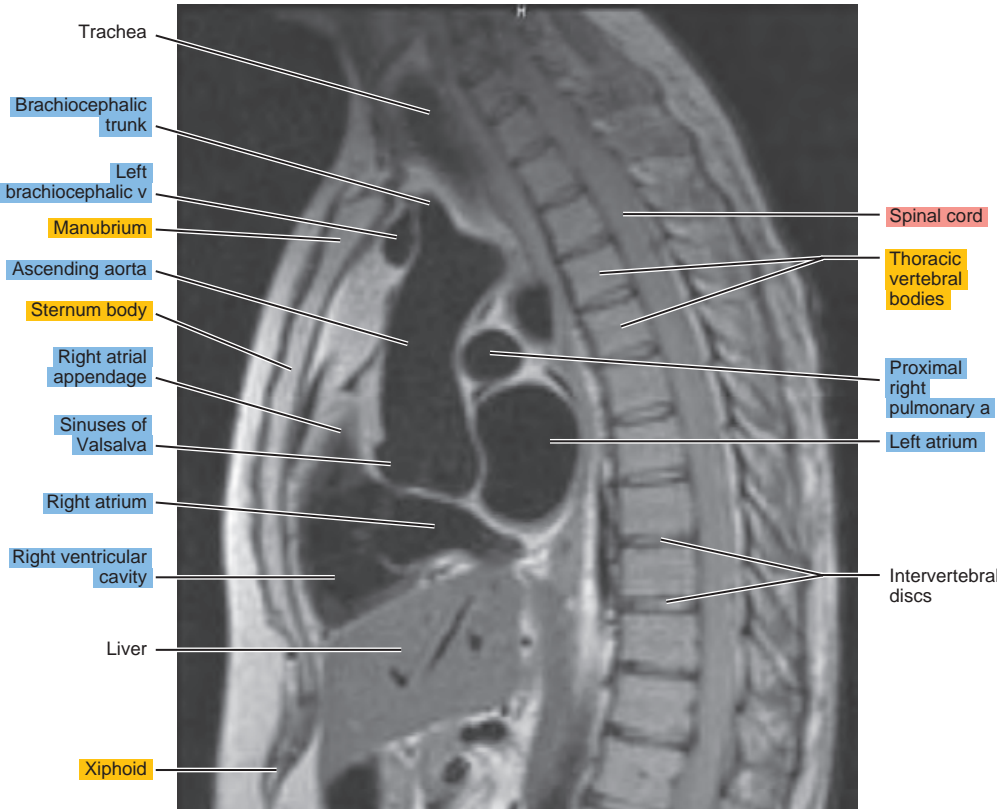
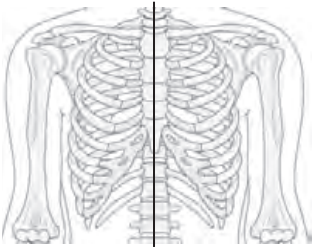
Left atrium

Celiac a

Abdominal aorta

Superior mesenteric a

Figure 19.2.4



Trachea

Brachiocephalic trunk

Left brachiocephalic v

Manubrium

Ascending aorta

Sternum body

Right atrial appendage

Sinuses of Valsalva

Right atrium

Right ventricular cavity

Liver

Xiphoid

Spinal cord

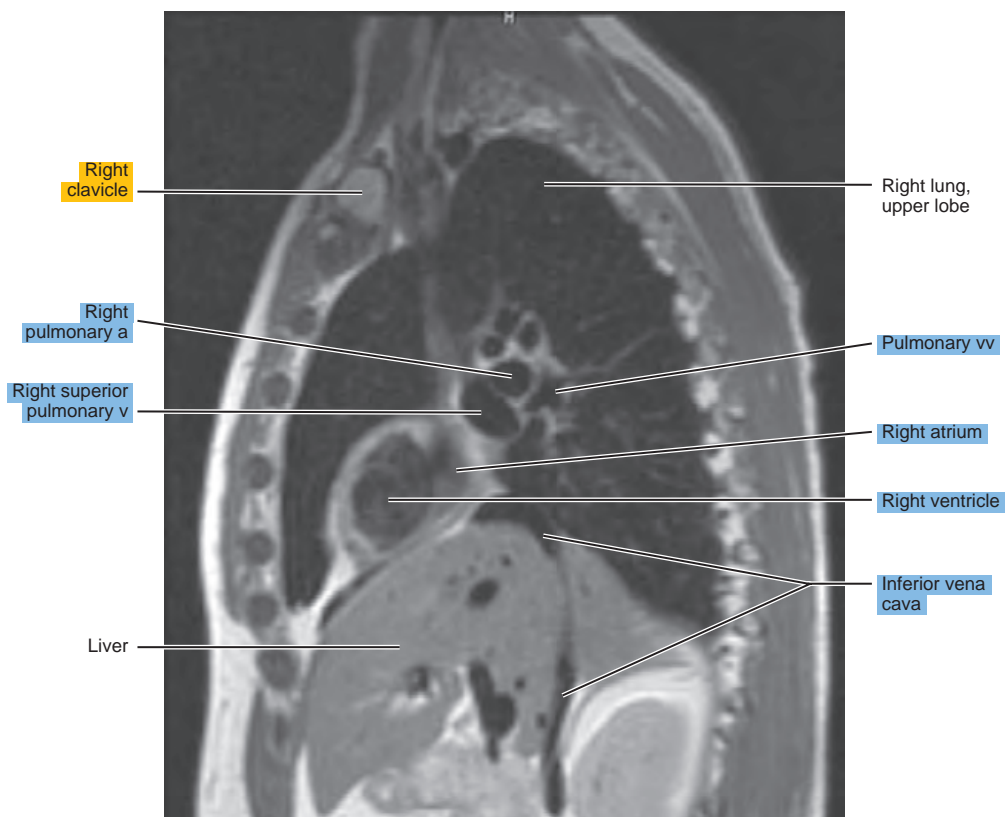
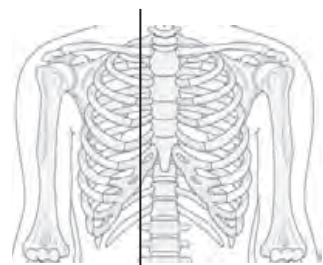
Thoracic vertebral bodies

Proximal right pulmonary a

Left atrium

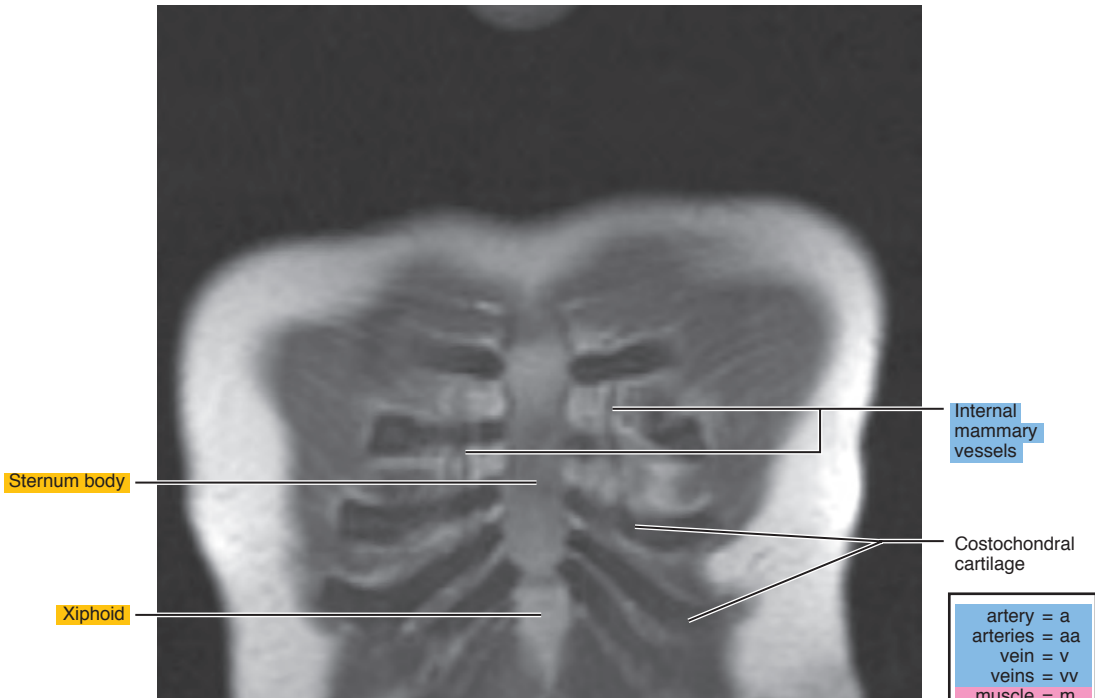
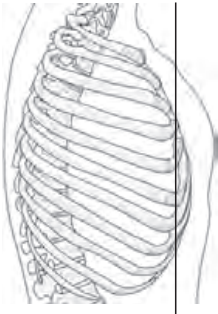
Intervertebral discs

Figure 19.2.5



CORONAL

Figure 19.3.1



Internal mammary vessels

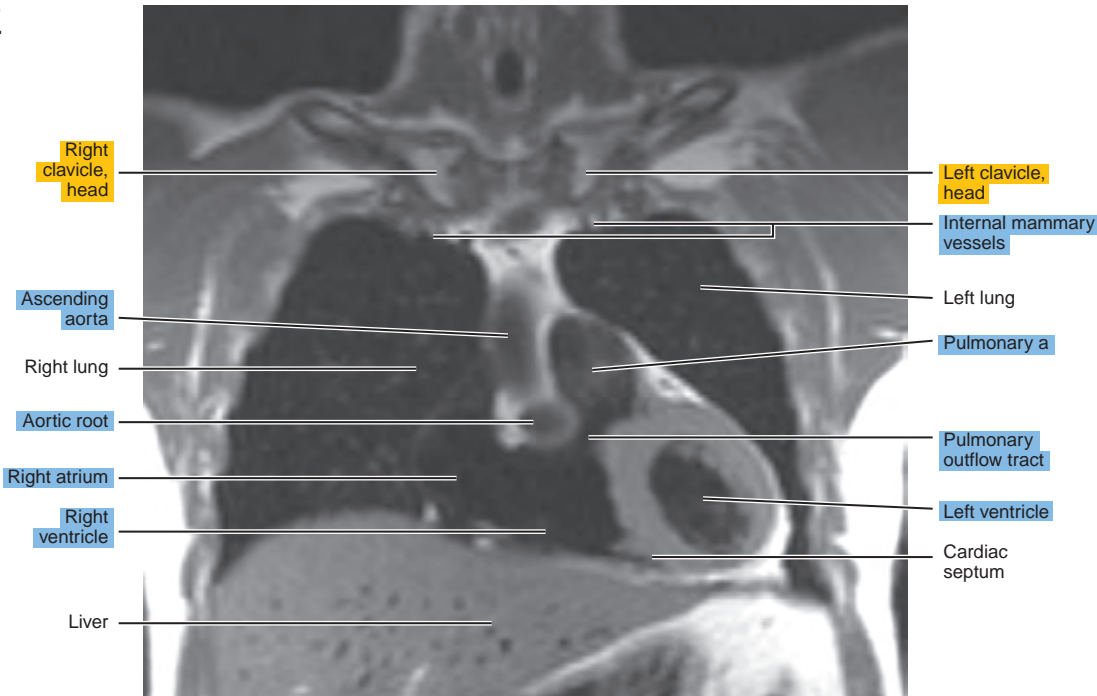
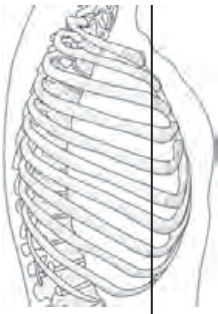
Sternum body

Costochondral cartilage

Xiphoid

artery = a
arteries = aa
vein = v
veins = vv
muscle = m
muscles = mm
tendon = t
tendons = tt
nerve = n
nerves = nn
ligament = lig
ligaments = lig
nerve & vessels
bone

Figure 19.3.2



Right clavicle, head

Left clavicle, head

Internal mammary vessels

Ascending aorta

Left lung

Right lung

Pulmonary a

Aortic root

Pulmonary outflow tract

Right atrium

Left ventricle

Right ventricle

Cardiac septum

Liver

Figure 19.3.3

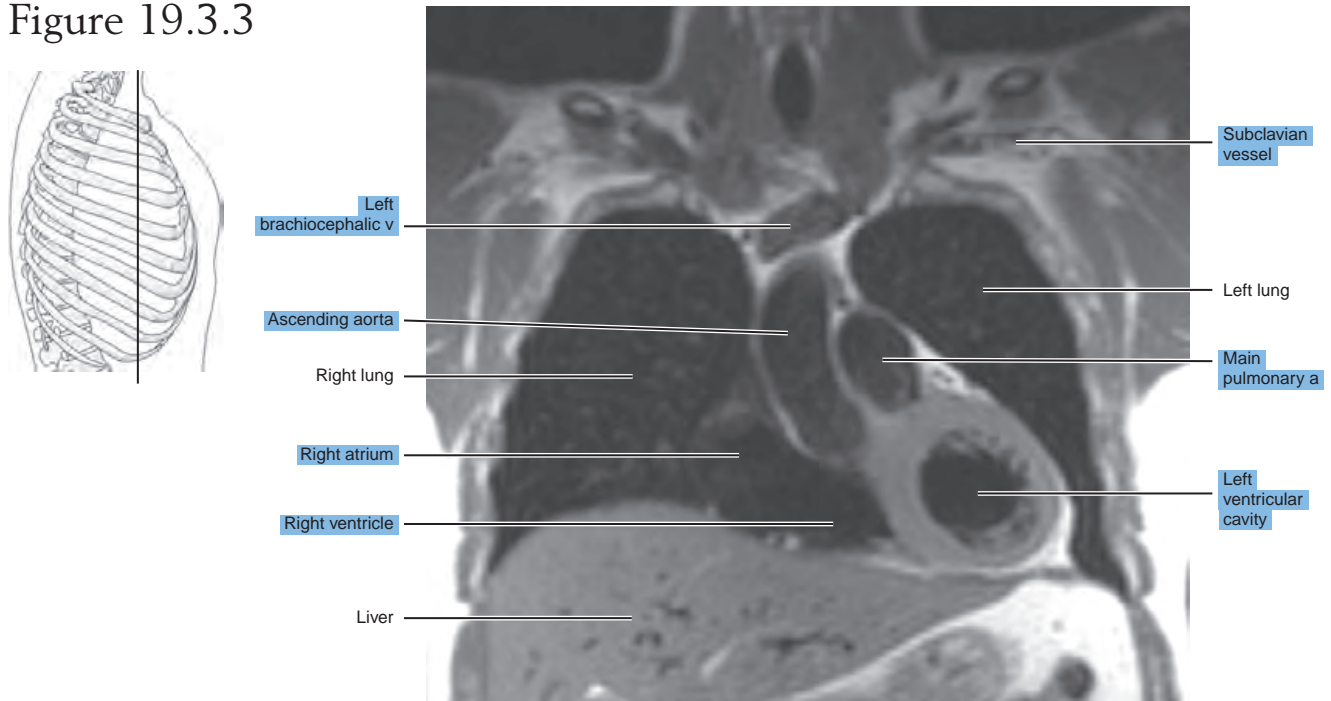


Figure 19.3.4

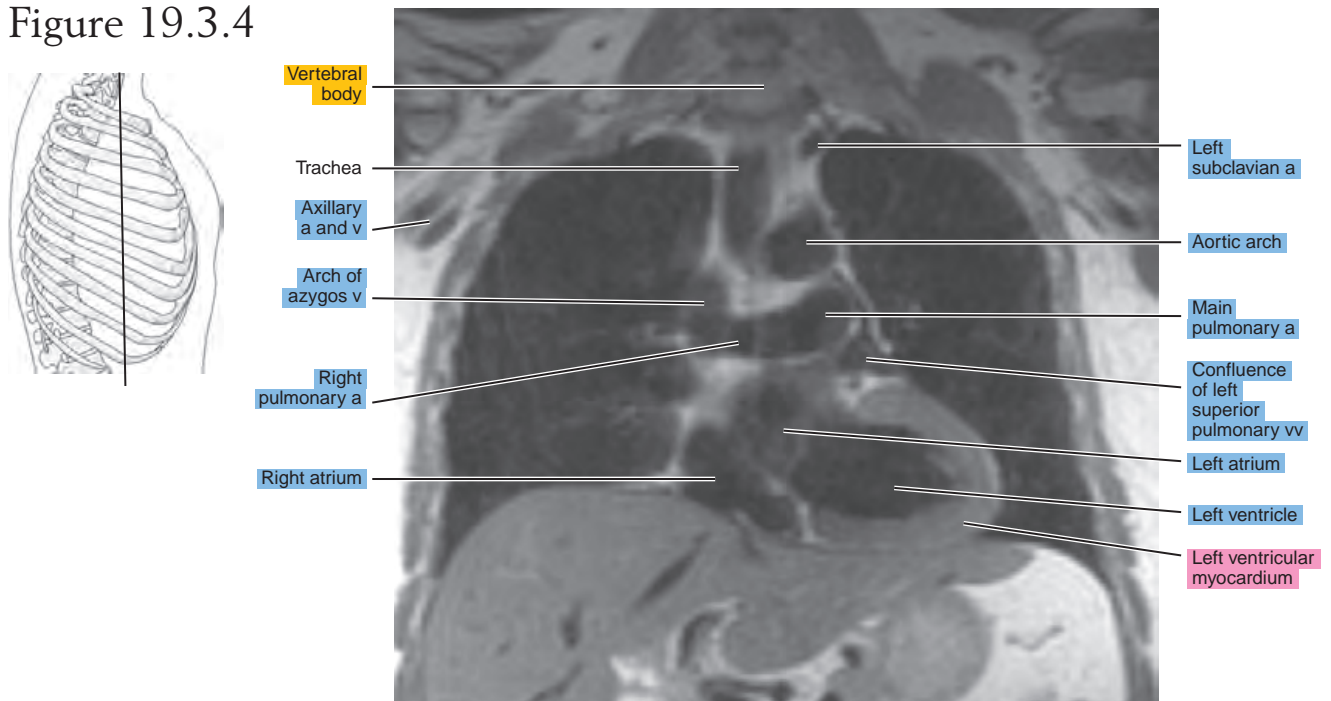
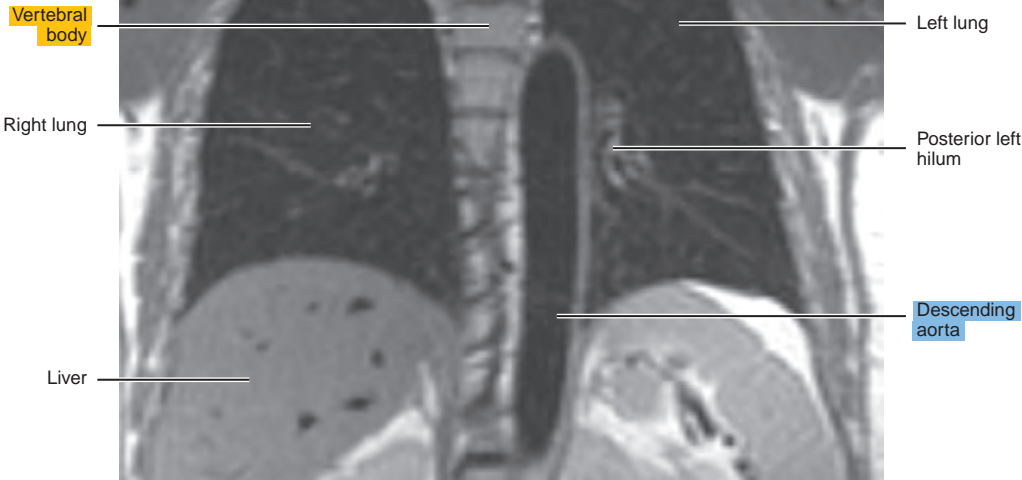
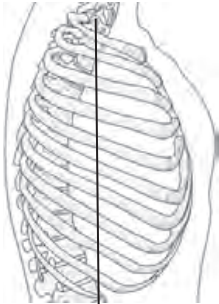


Figure 19.3.5



This page intentionally left blank

V
Section

Abdomen

This page intentionally left blank

Chapter
20

CT of the Abdomen

Table 20-1. Muscles of the Abdominal Wall

MUSCLE	ORIGIN	INSERTION	NERVE SUPPLY
Rectus abdominis	Crest and symphysis of the pubis	Xiphoid process and fifth to seventh costal cartilages	Branches of the lower thoracic
External oblique (obliquus externus abdominis)	Fifth to twelfth ribs	Anterior half of the iliac crest, inguinal ligament, and anterior layer of the sheath of the rectus abdominis	Ventral branches of the lower thoracic
Internal oblique (obliquus internus abdominis)	Tenth to twelfth ribs and sheath of the rectus abdominis; some fibers from the inguinal ligament terminate in the falx inguinalis	Iliac fascia deep to the lateral part of the inguinal ligament, the anterior half of the iliac crest, and the lumbar fascia	Lower thoracic
Transversus abdominis	Seventh to twelfth costal cartilages, lumbar fascia, iliac crest, and inguinal ligament	Xiphoid cartilage and linea alba and through the falx inguinalis, pubic tubercle, and pecten	Lower thoracic

AXIAL

Figure 20.1.1

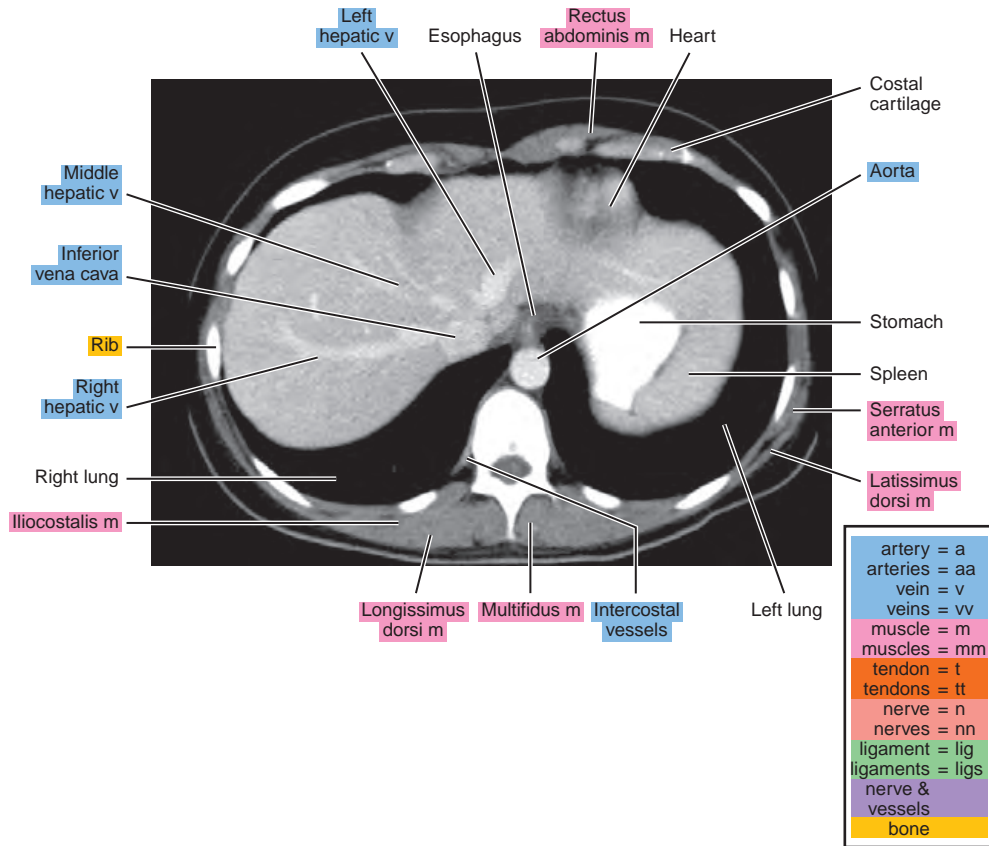
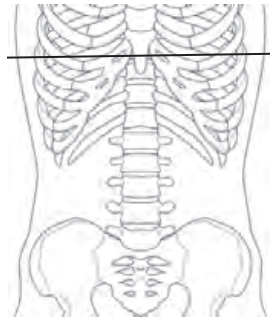


Figure 20.1.2

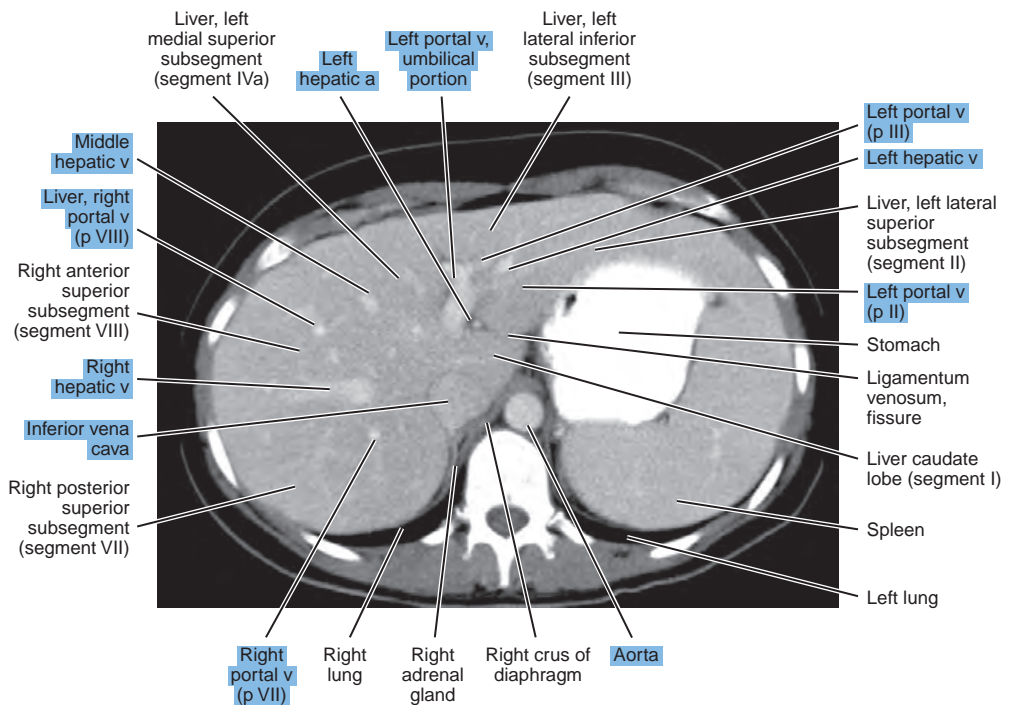
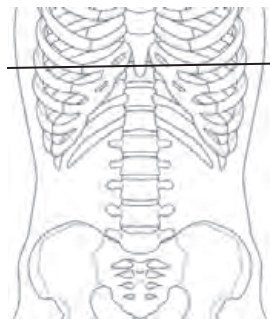


Figure 20.1.3

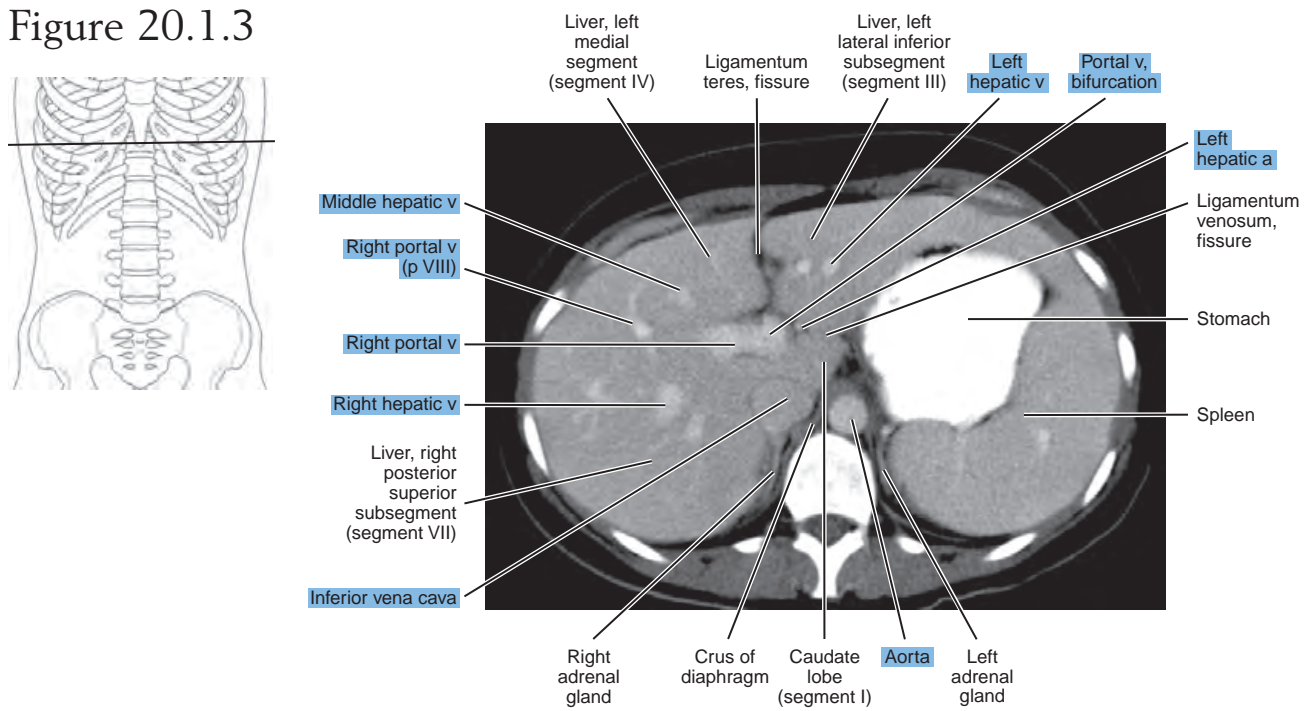


Figure 20.1.4

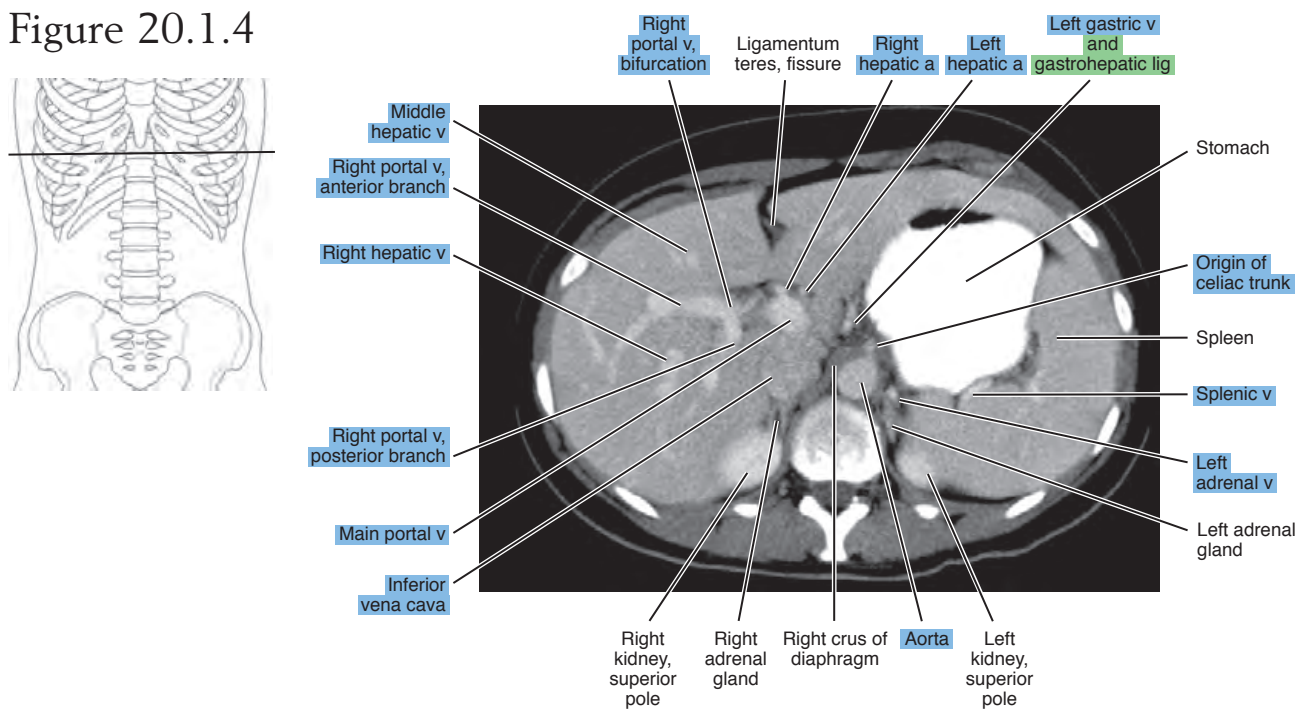


Figure 20.1.5

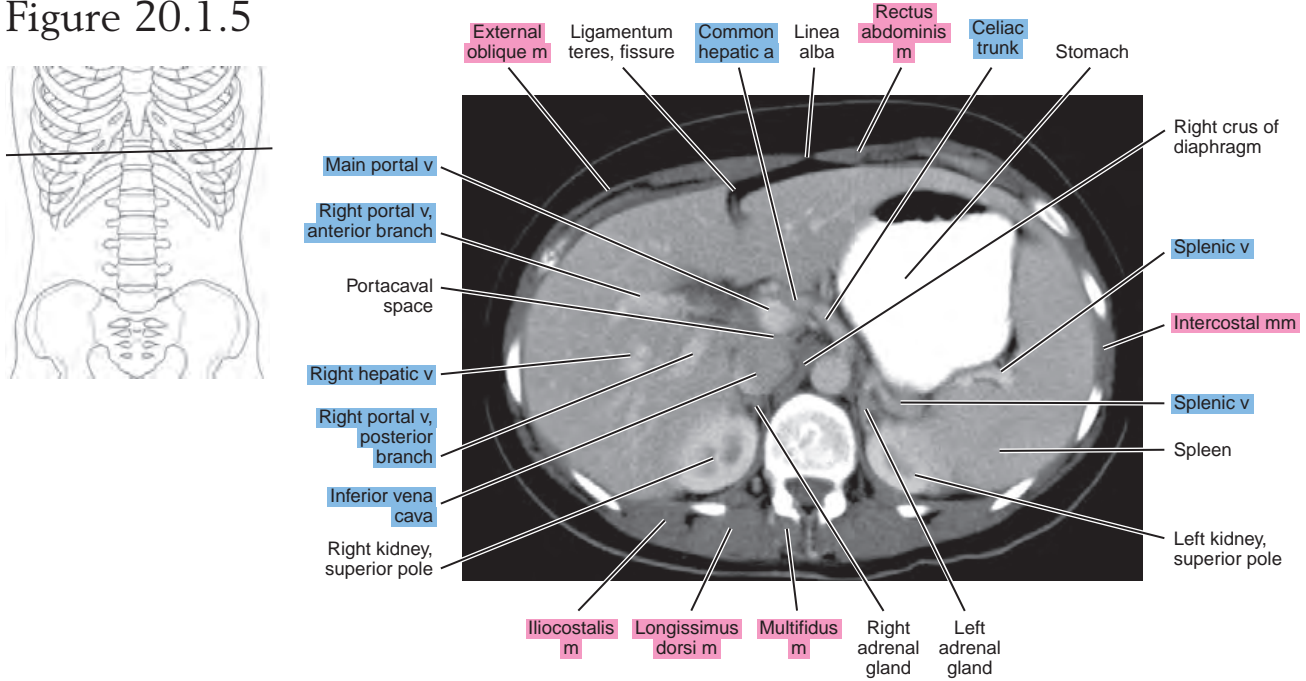


Figure 20.1.6

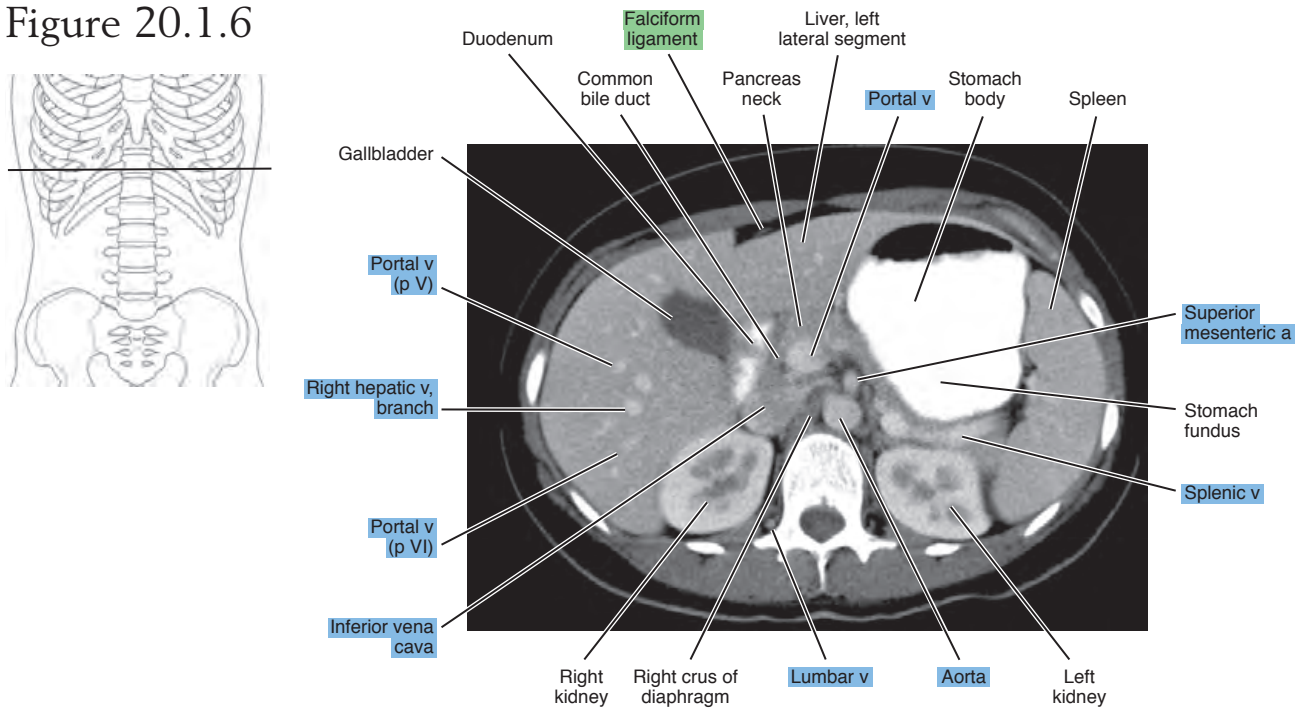


Figure 20.1.7

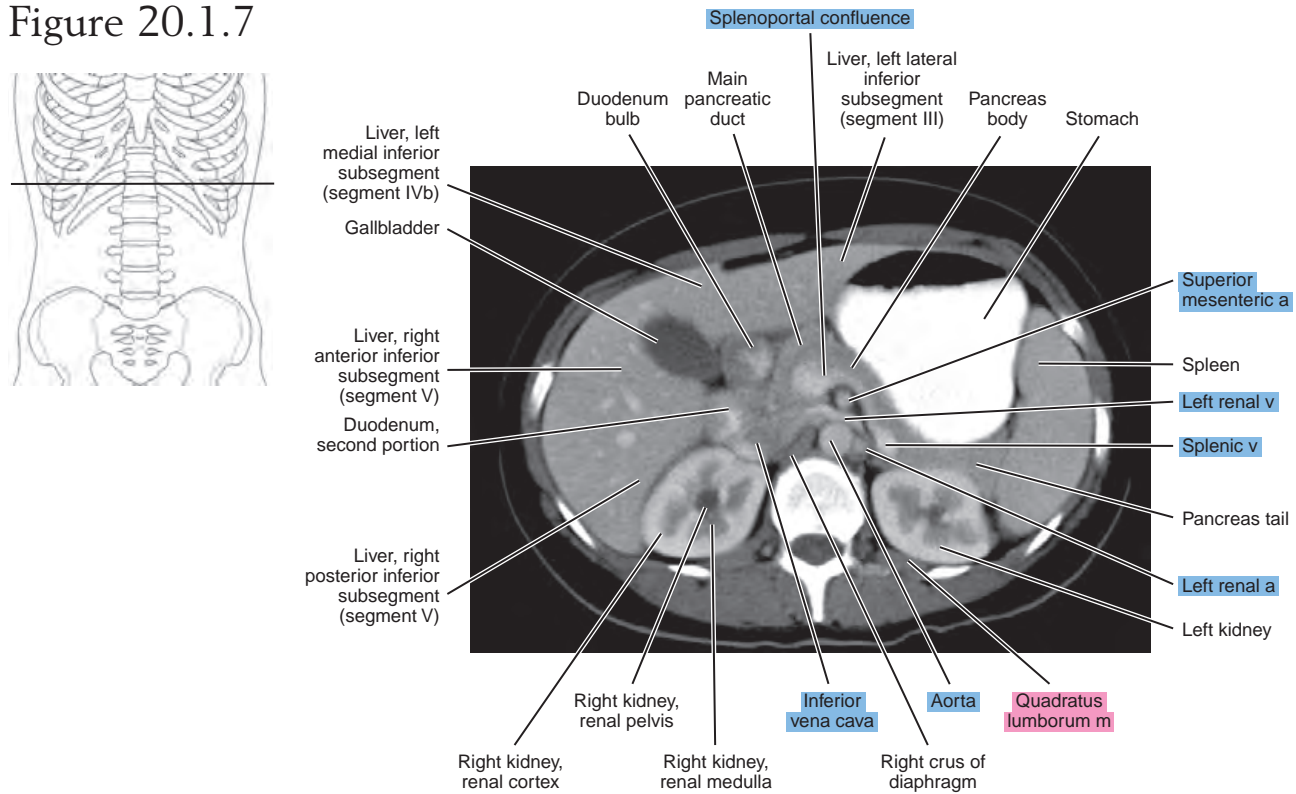


Figure 20.1.8

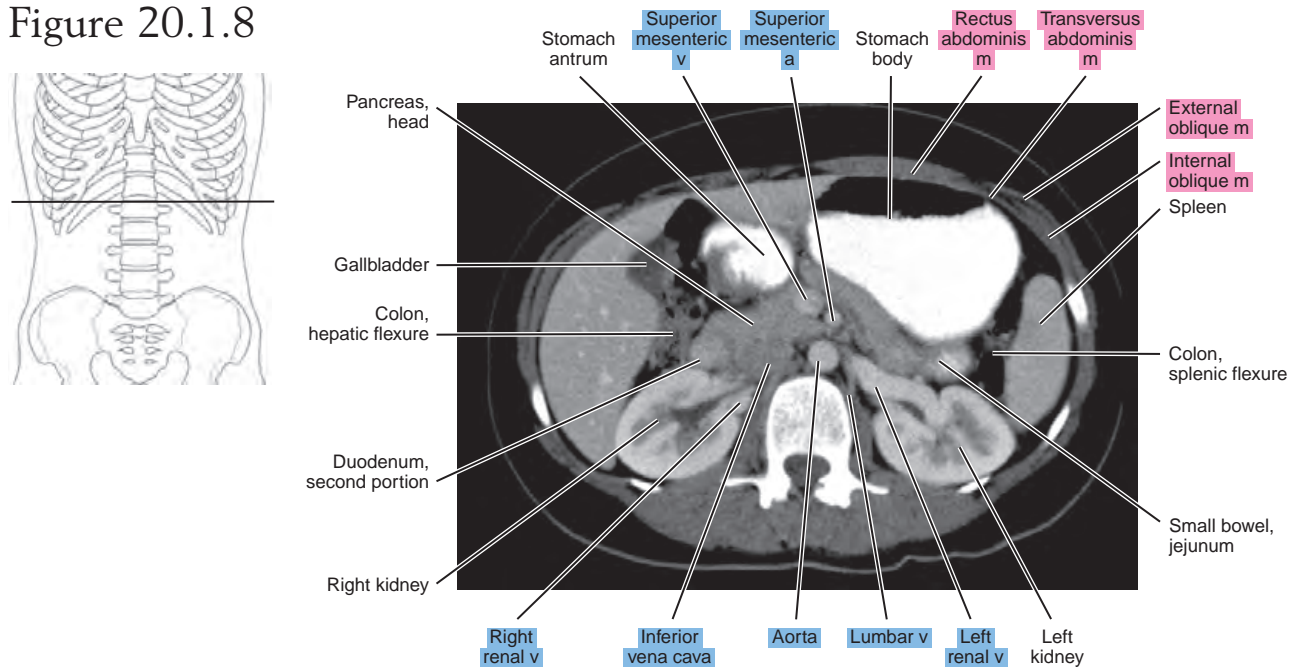


Figure 20.1.9

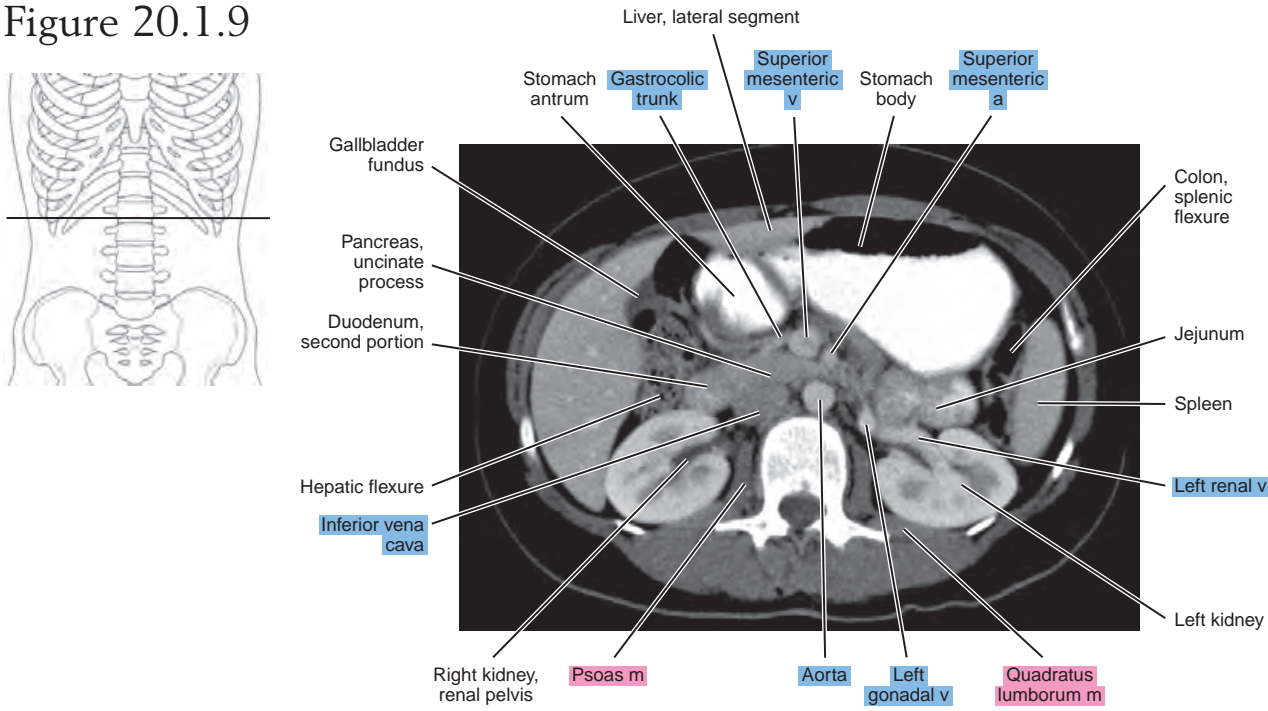


Figure 20.1.10

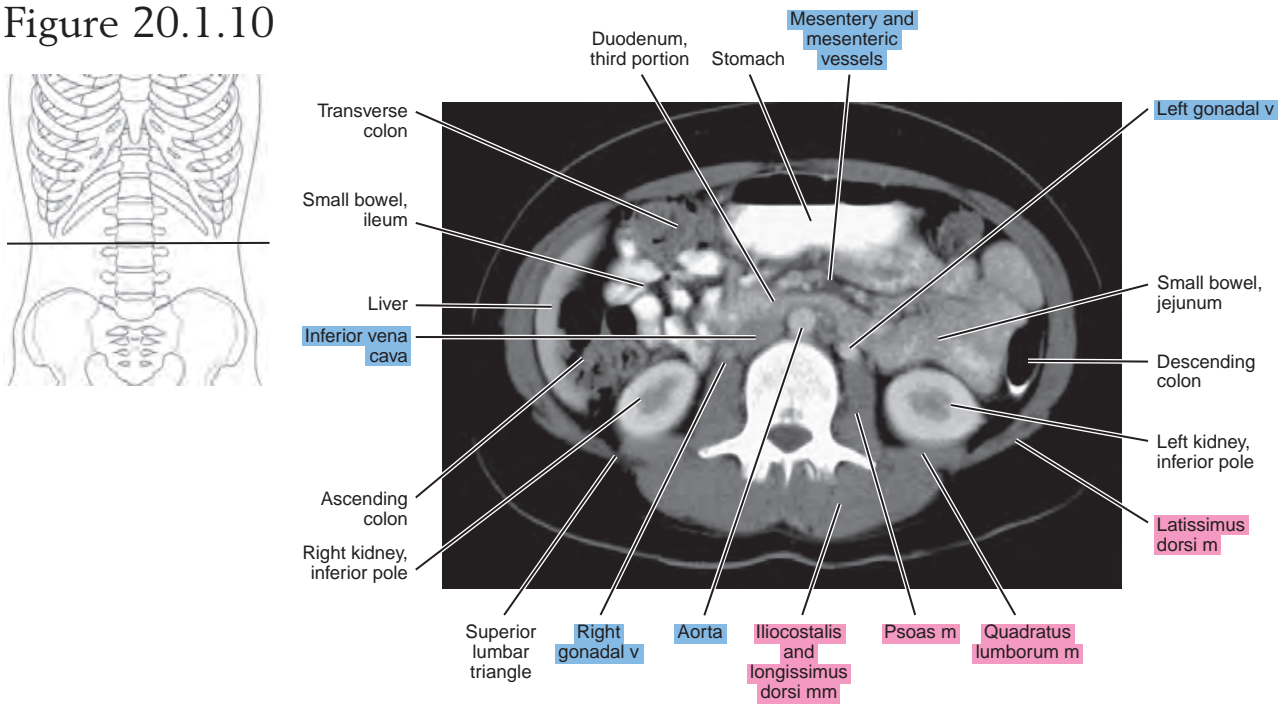


Figure 20.1.11

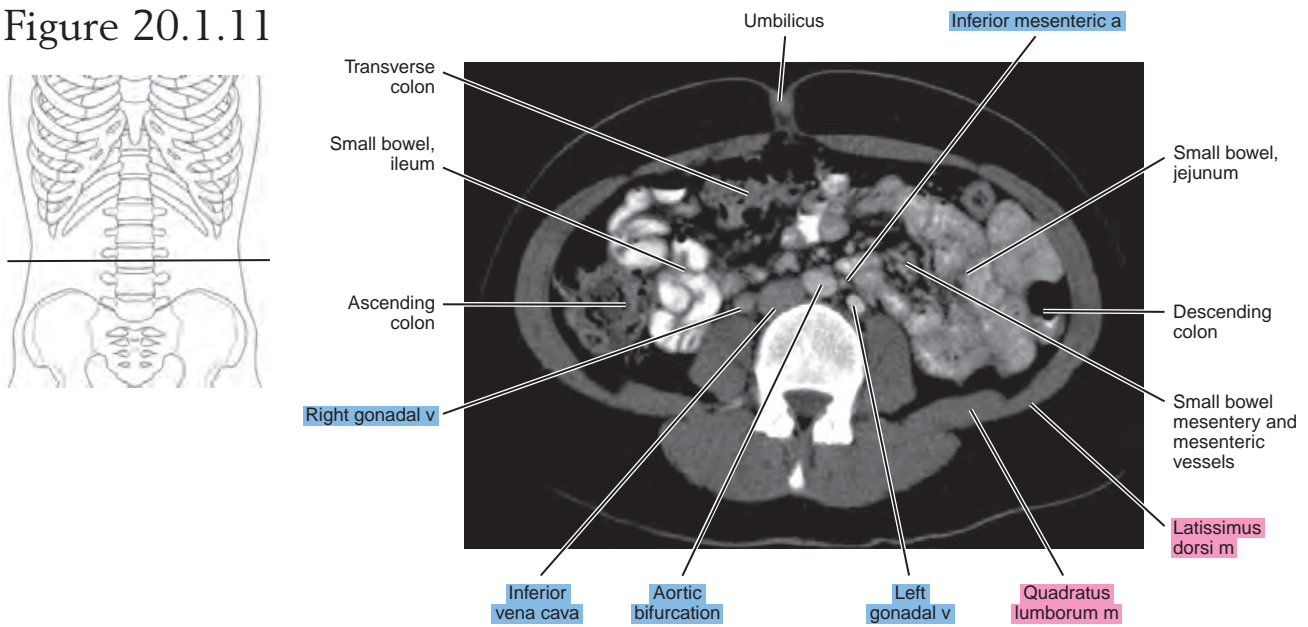
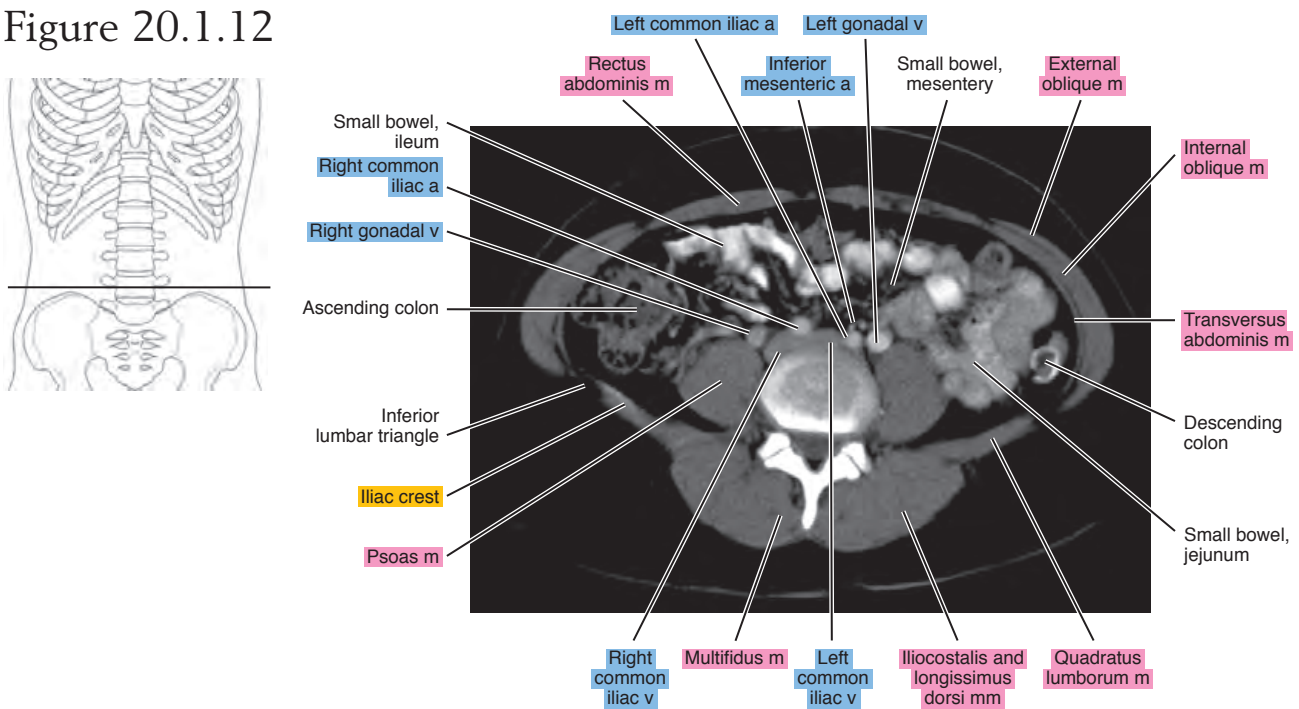


Figure 20.1.12



SAGITTAL

Figure 20.2.1

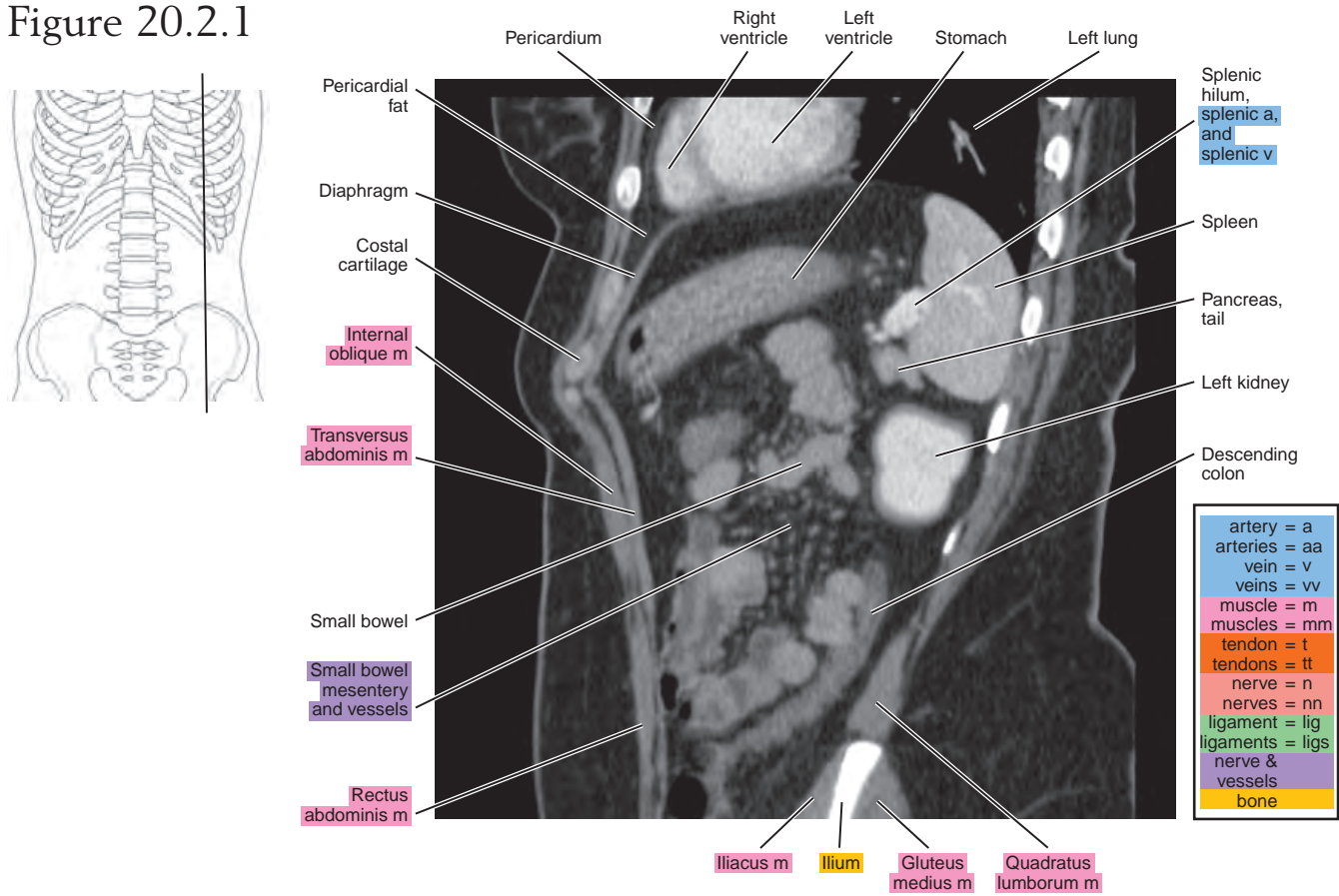


Figure 20.2.2

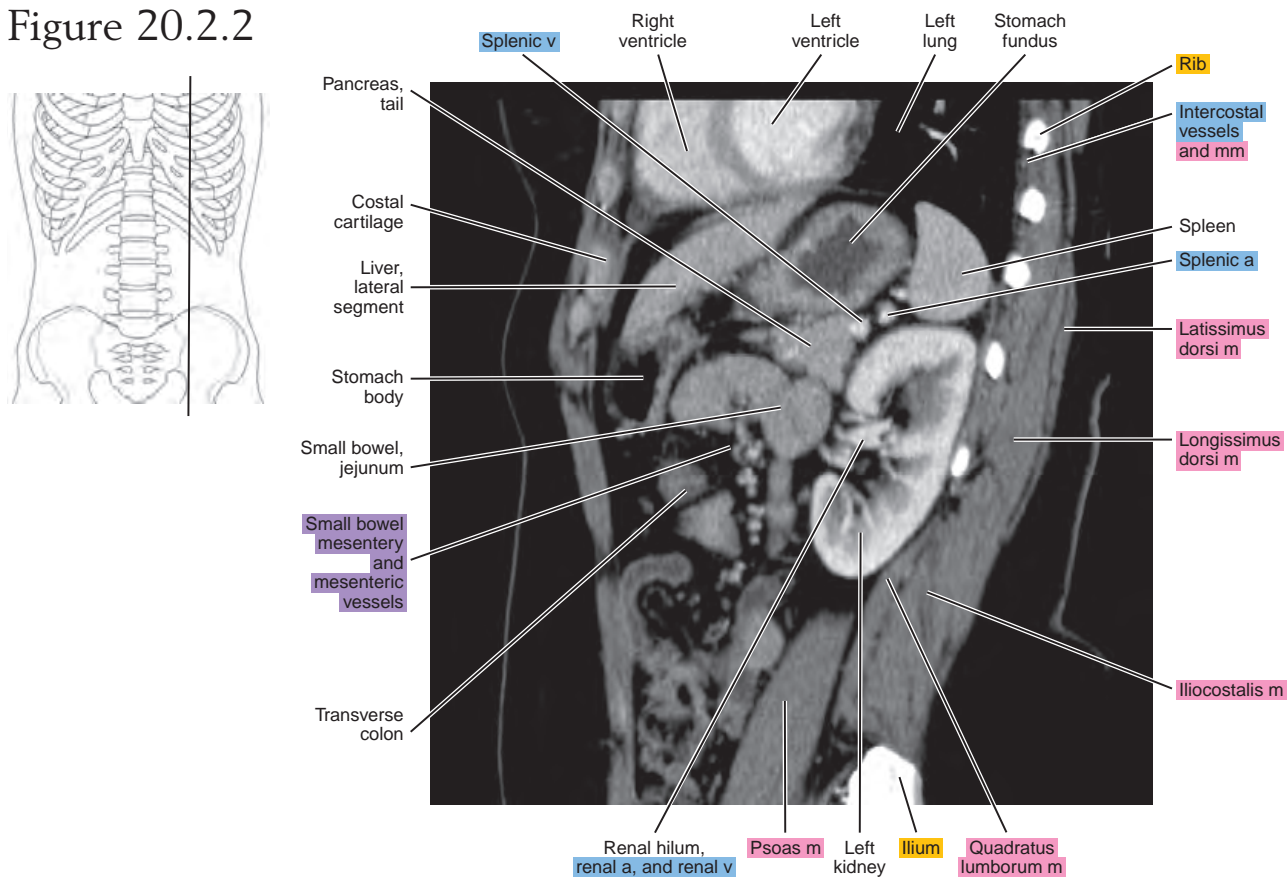


Figure 20.2.3

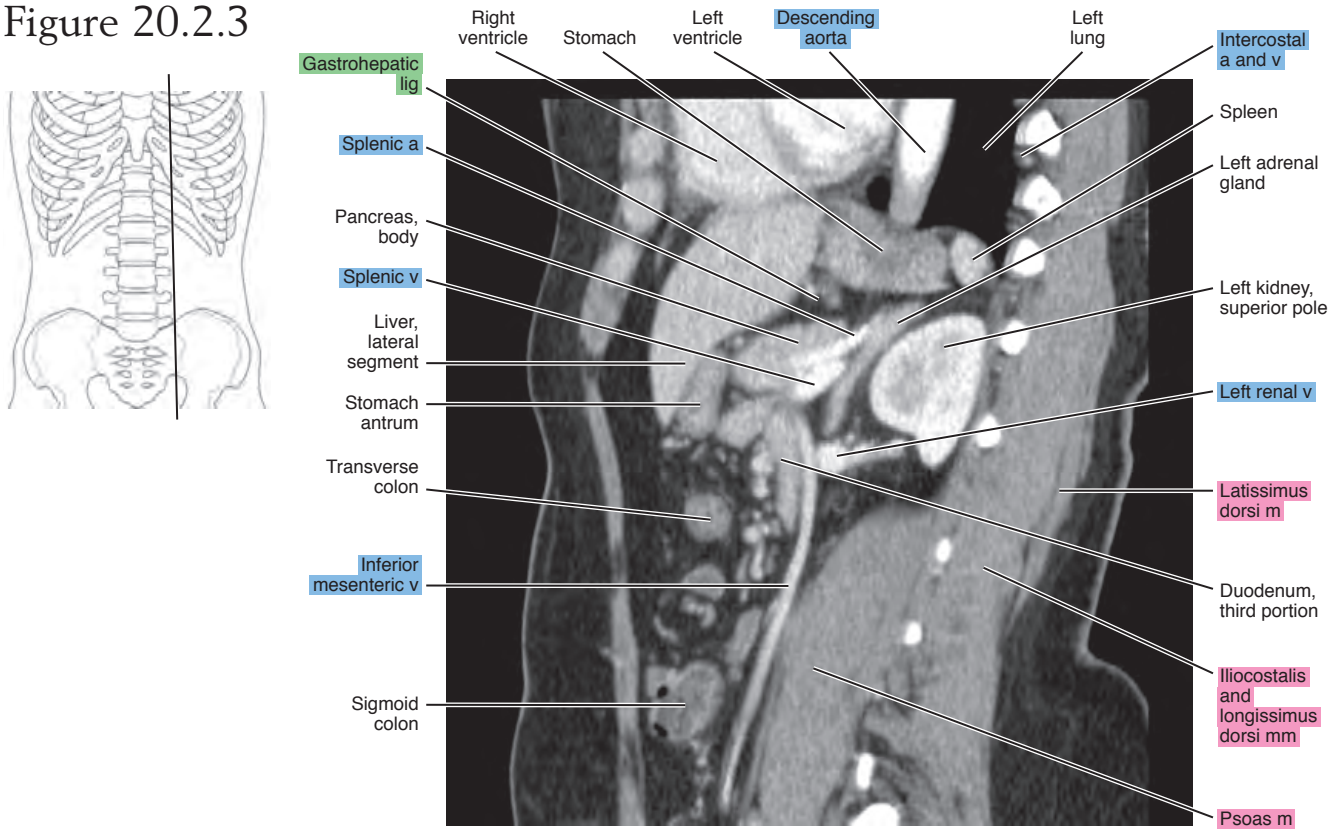


Figure 20.2.4

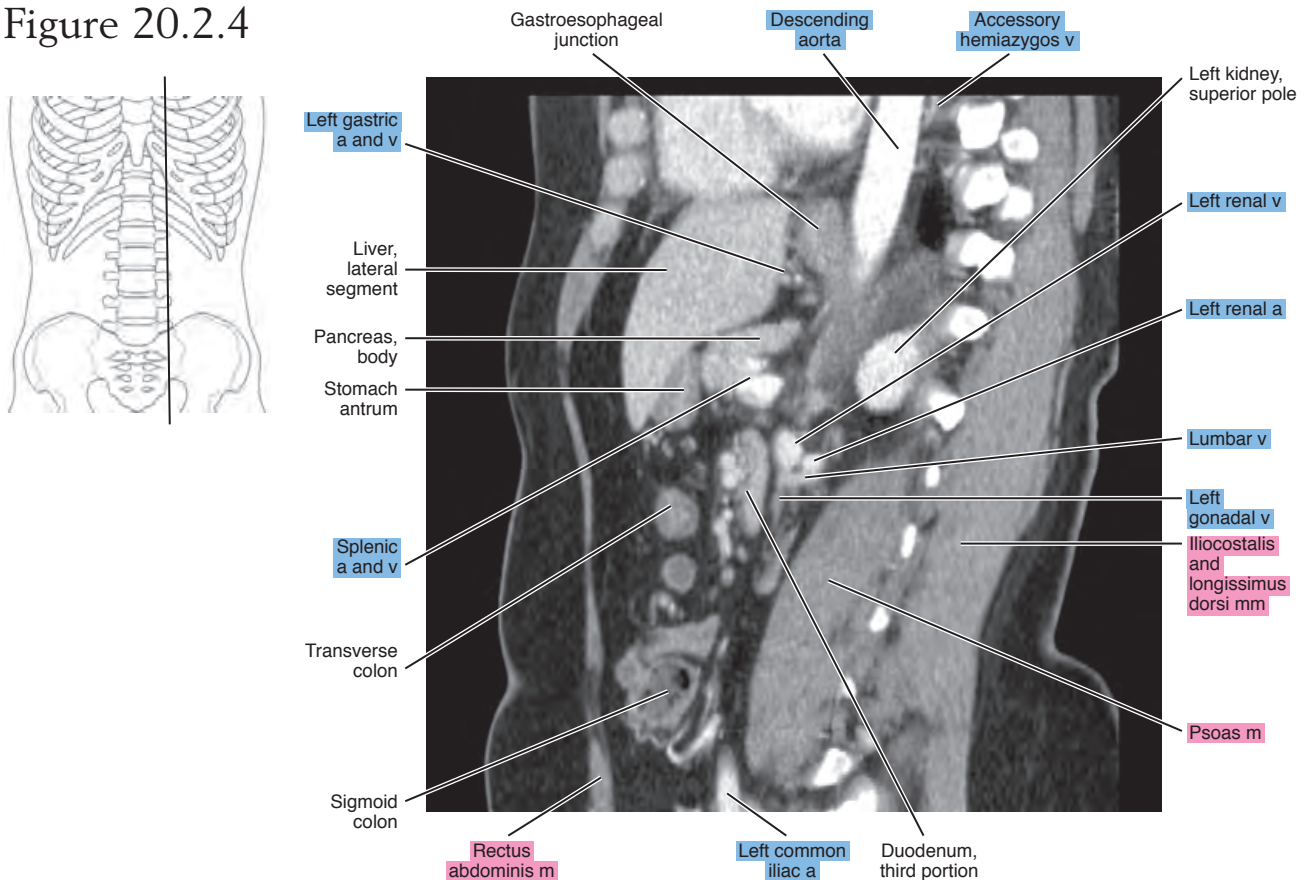


Figure 20.2.5

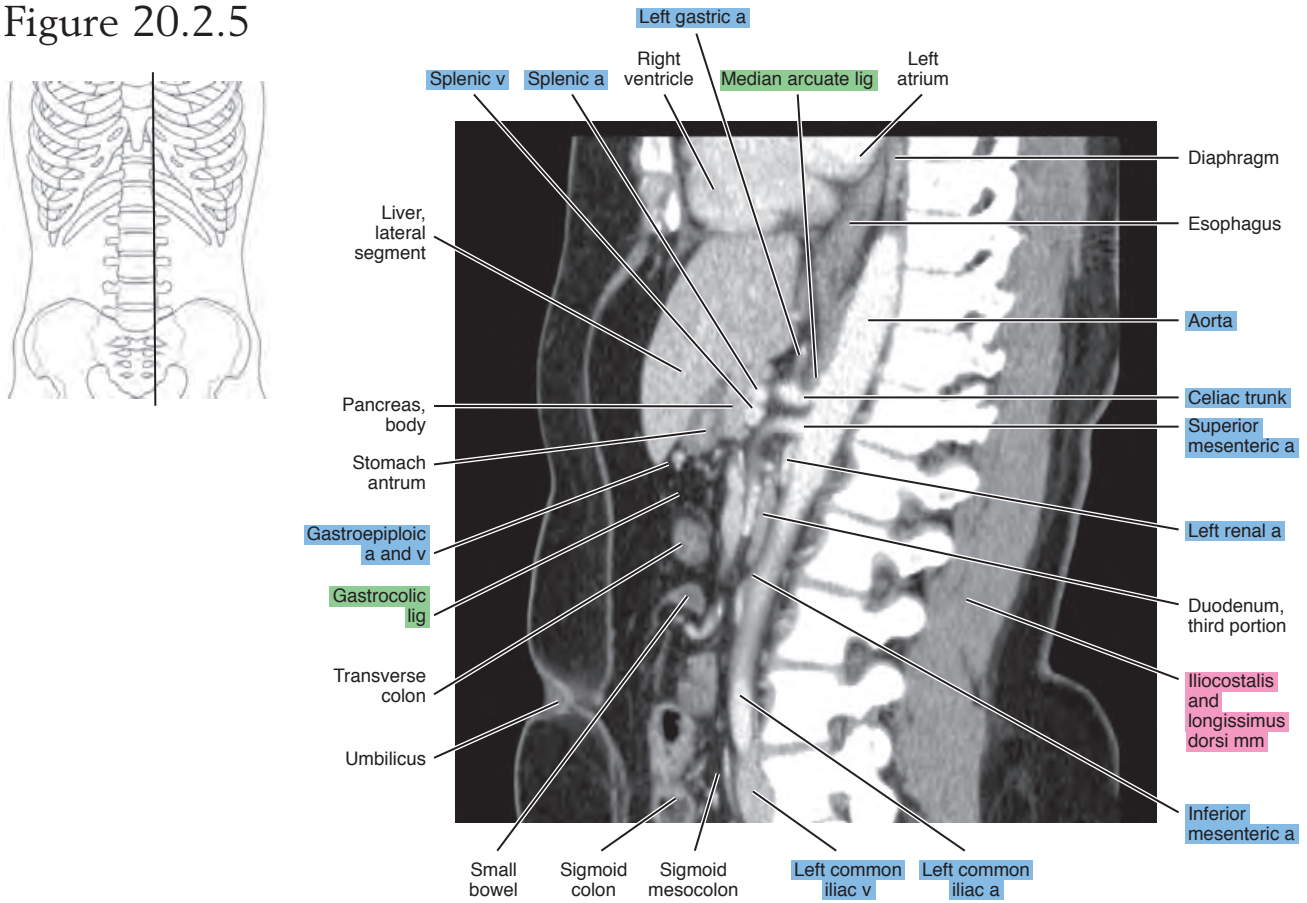


Figure 20.2.6

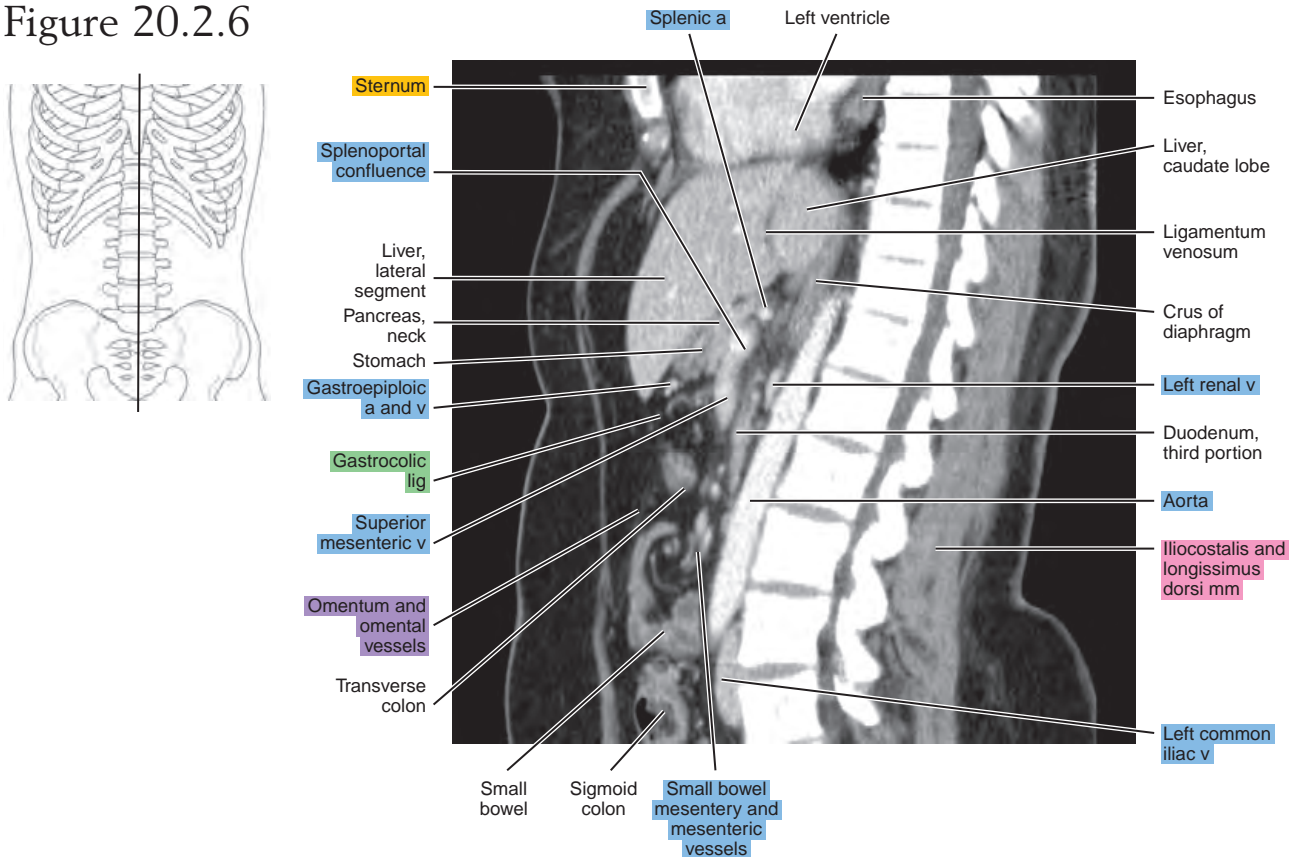


Figure 20.2.7

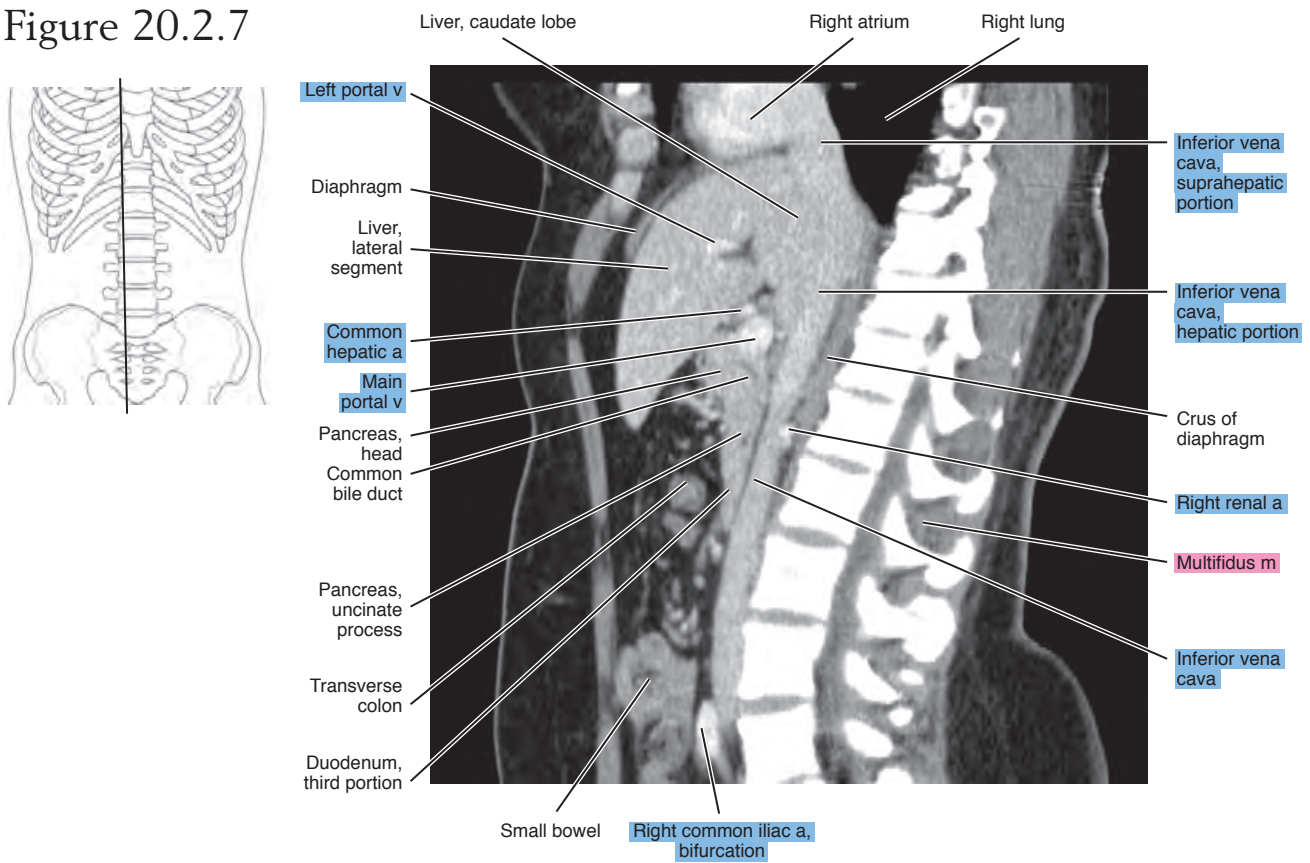


Figure 20.2.8

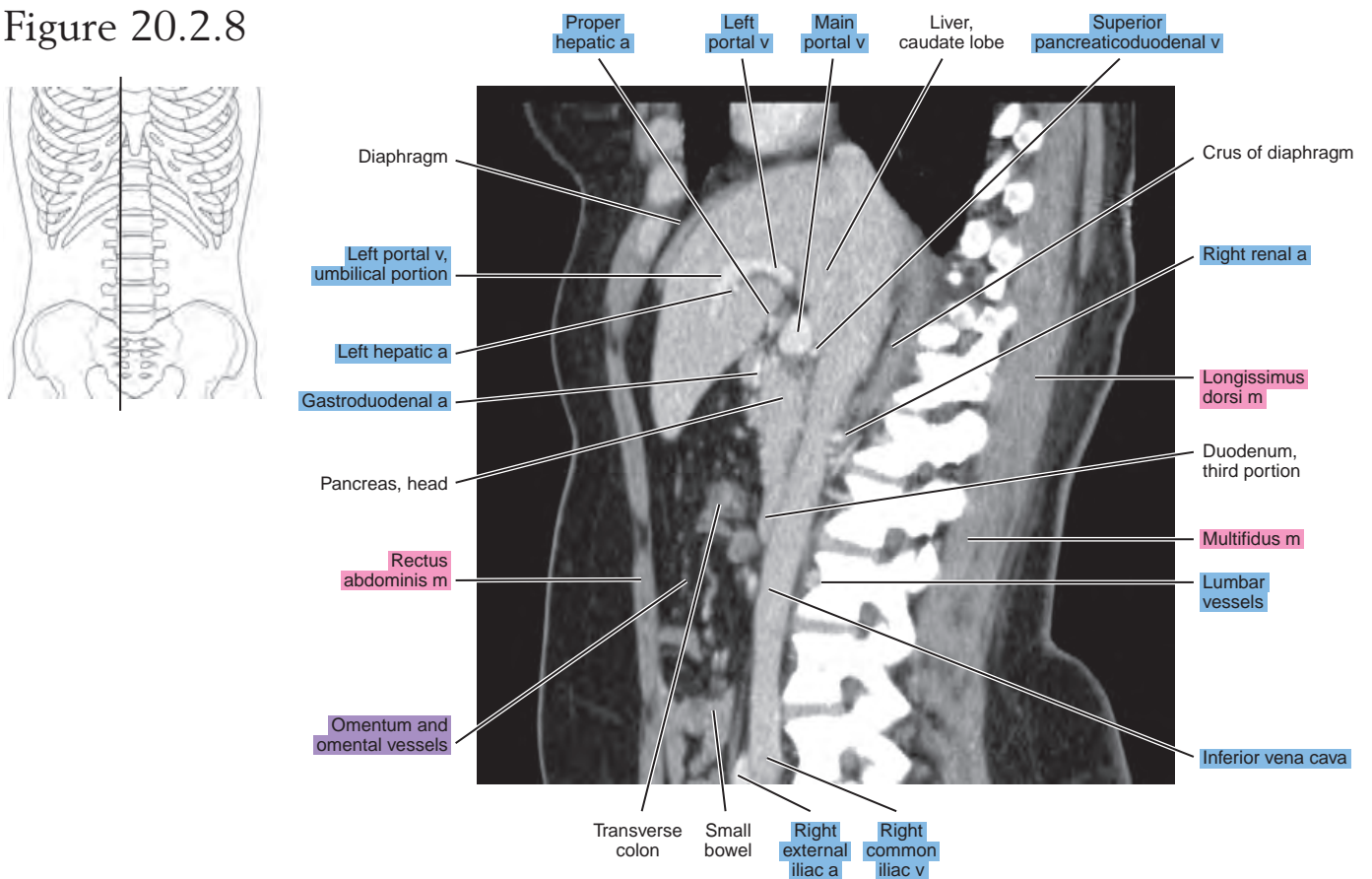


Figure 20.2.9

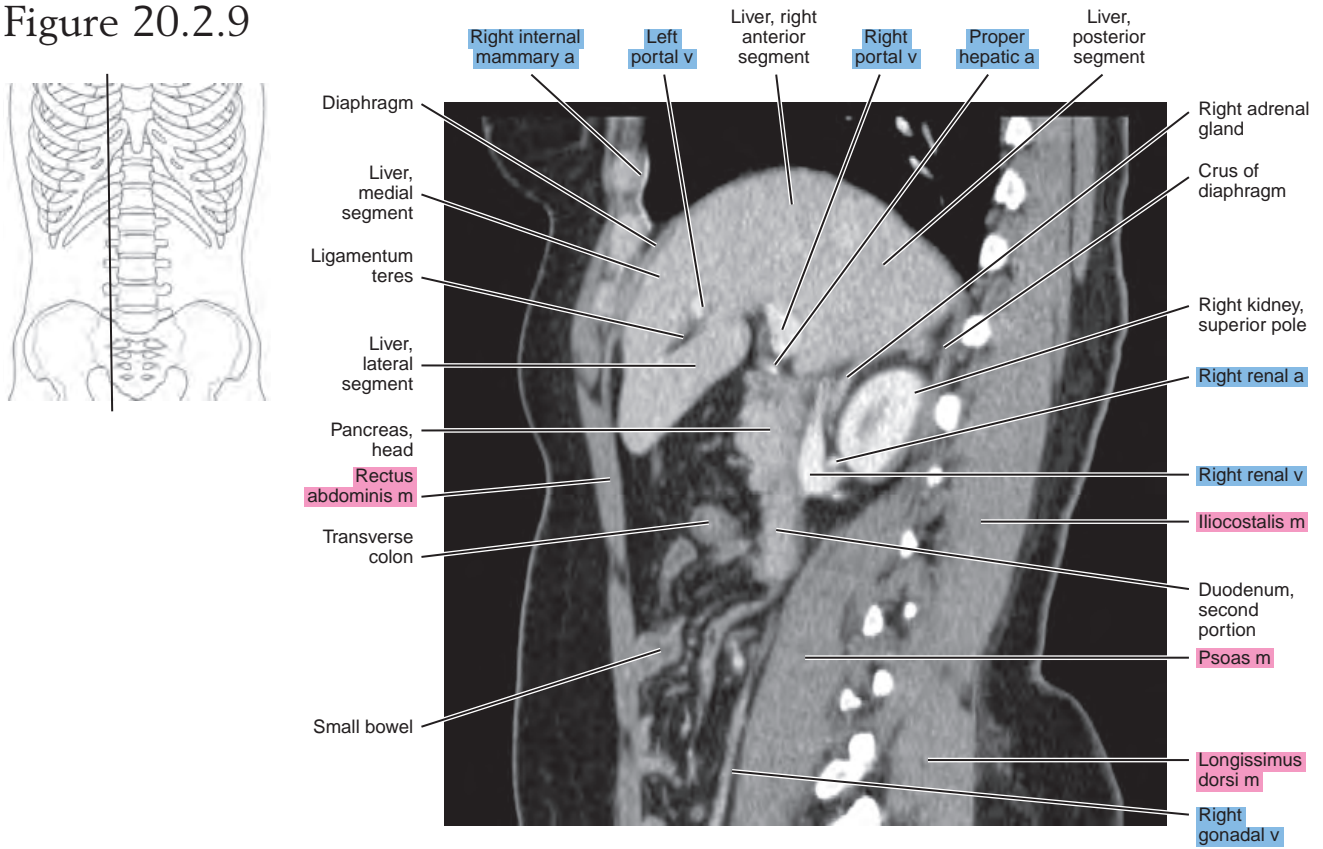


Figure 20.2.10

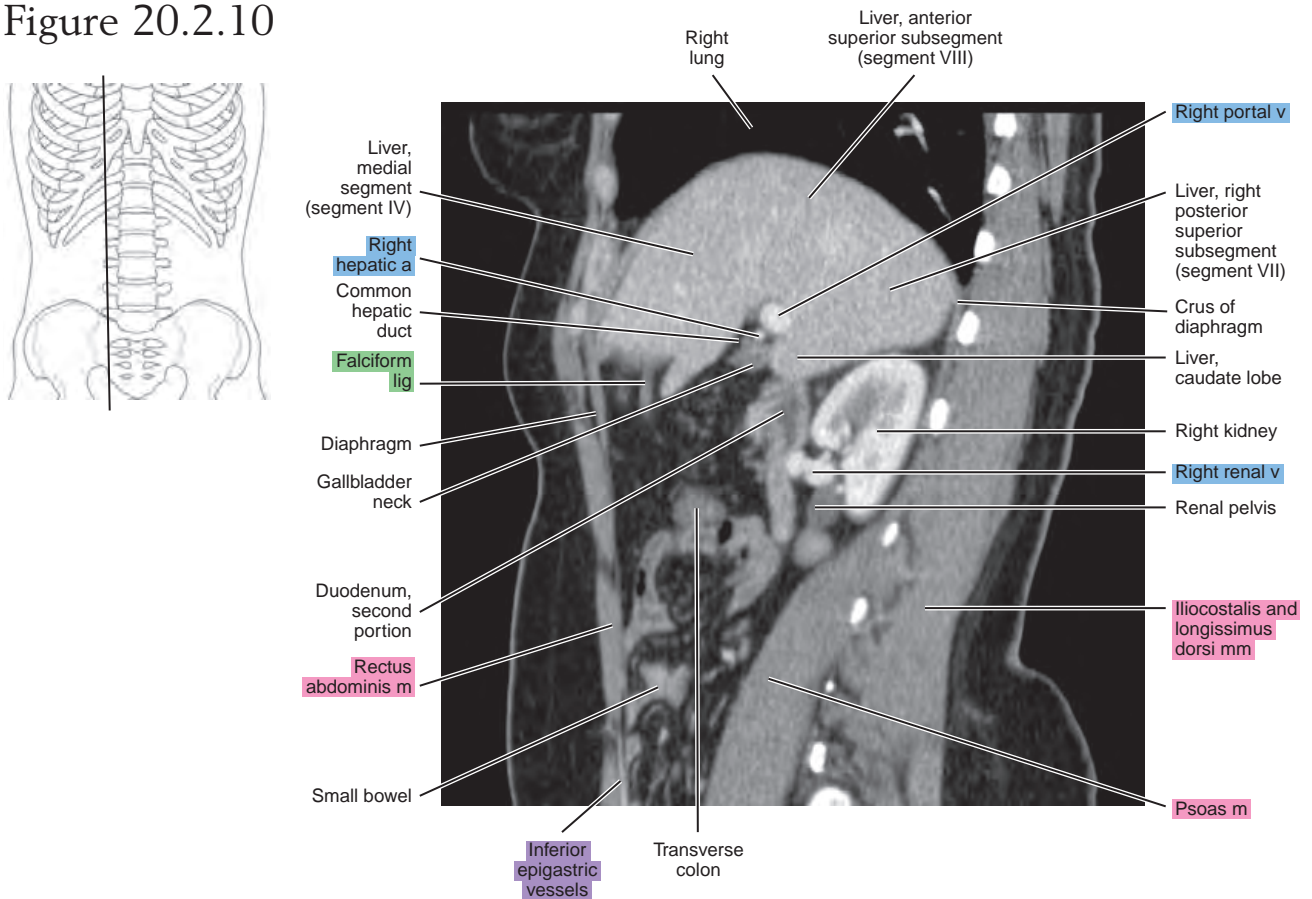


Figure 20.2.11

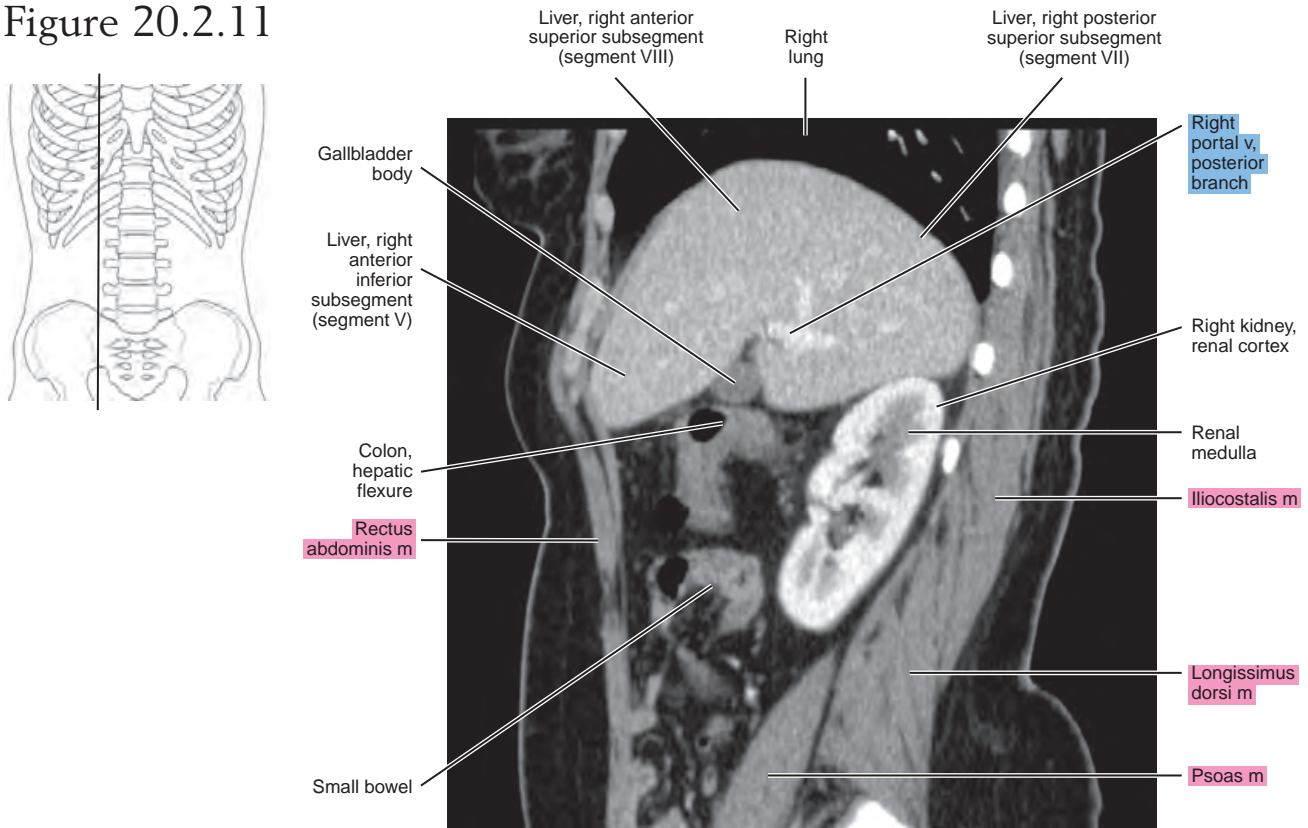
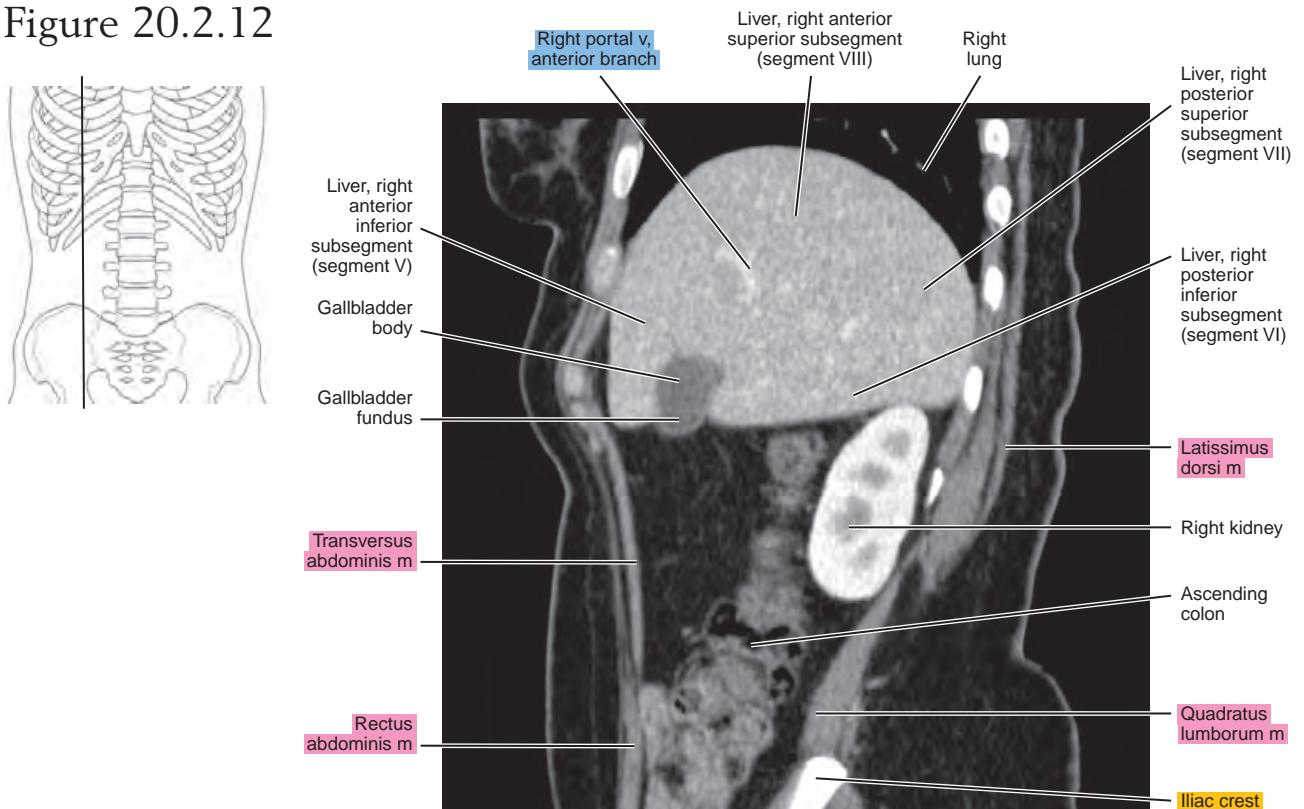


Figure 20.2.12



CORONAL

Figure 20.3.1

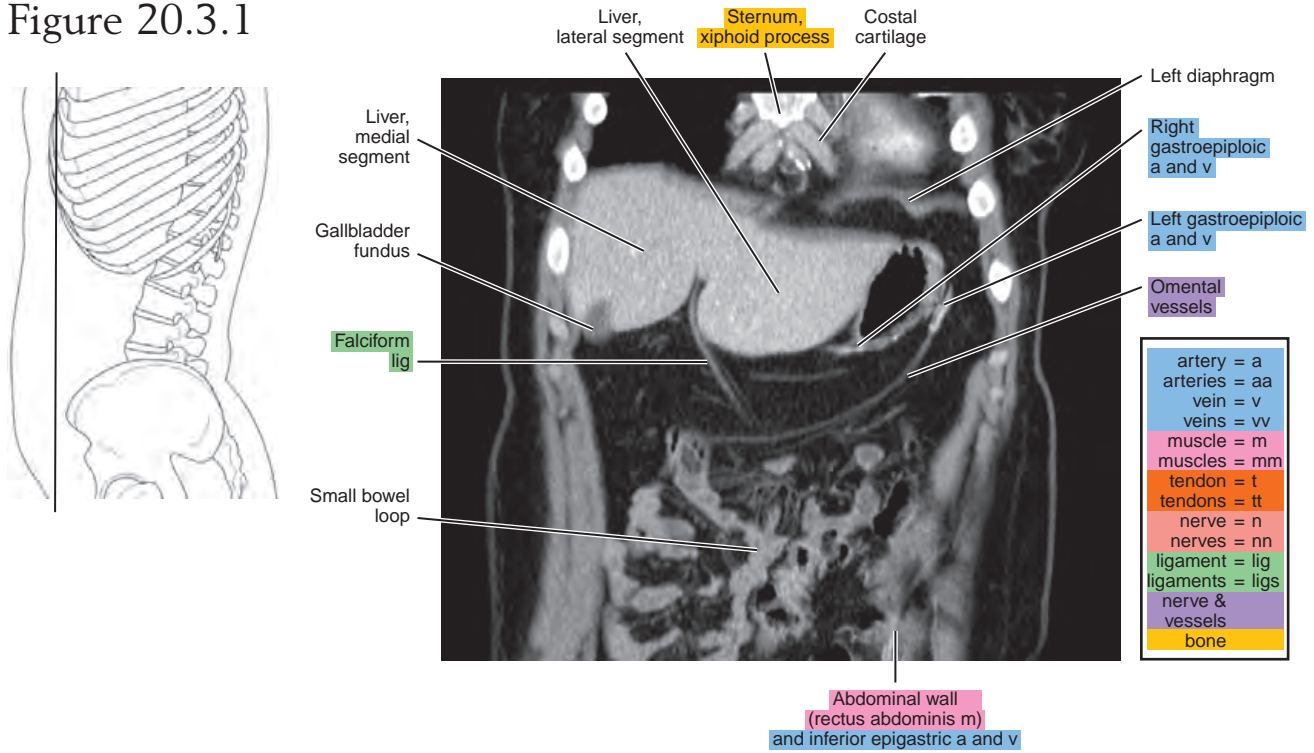


Figure 20.3.2

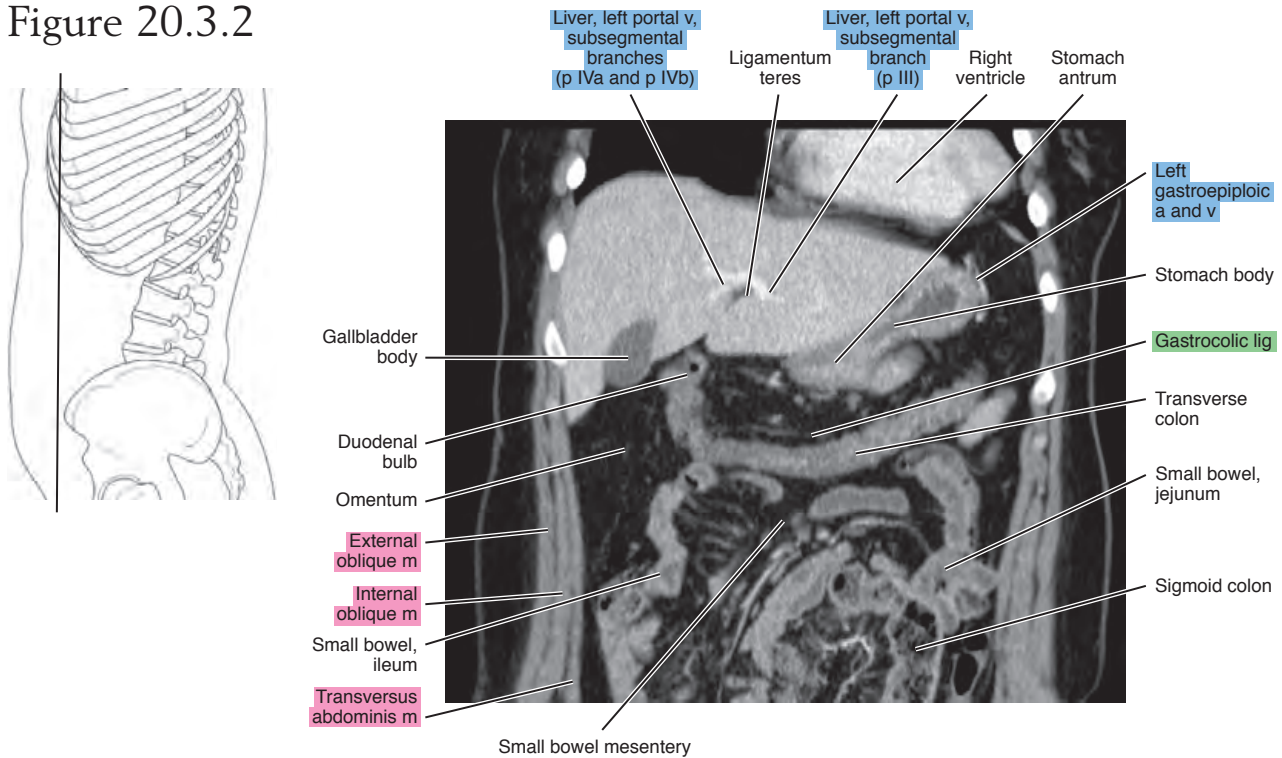


Figure 20.3.3

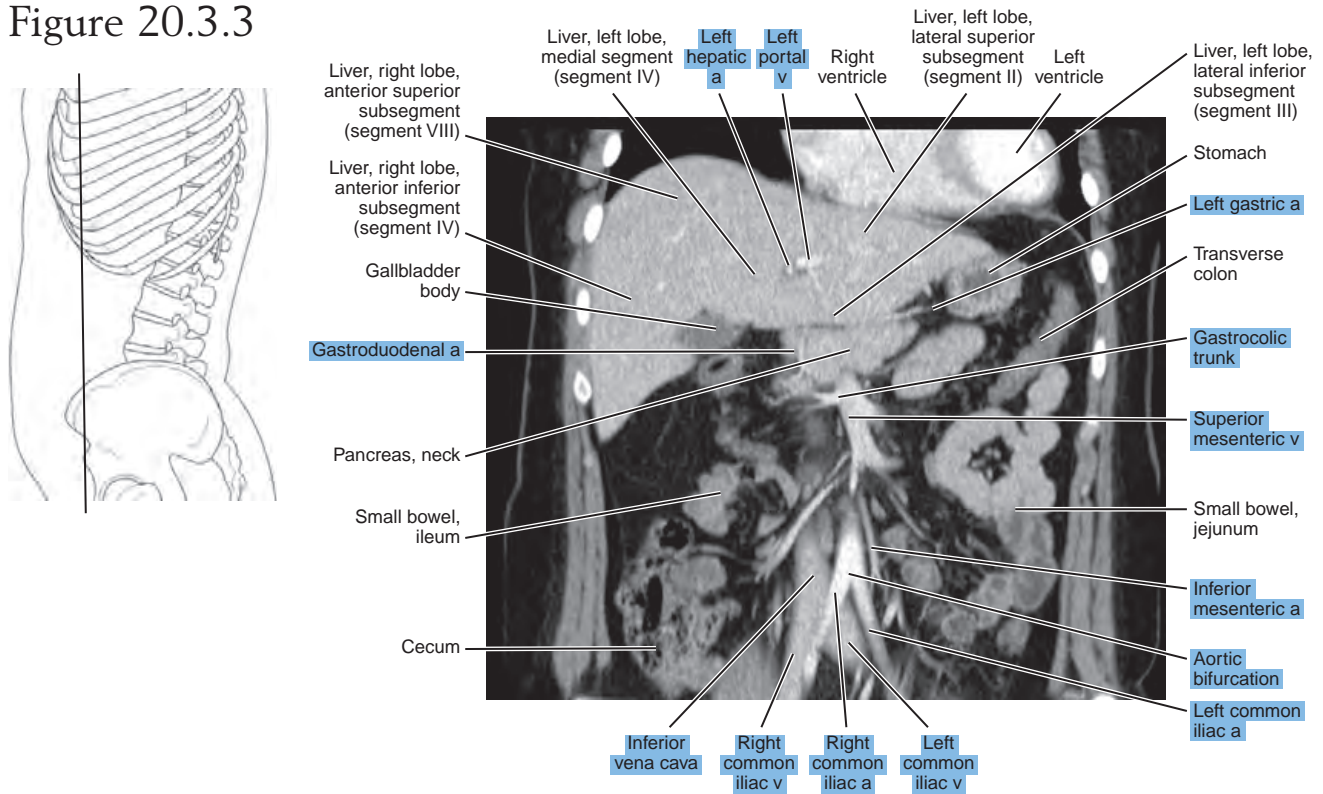


Figure 20.3.4

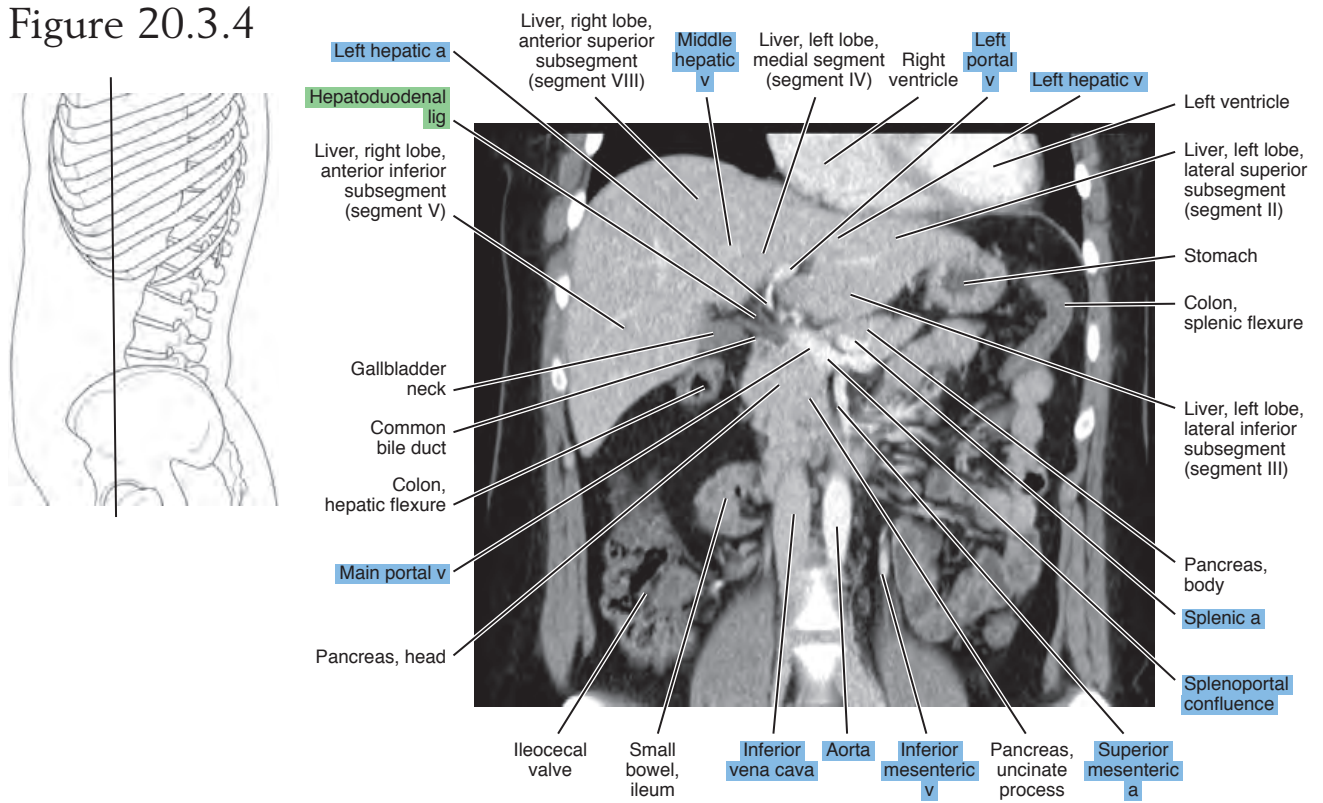


Figure 20.3.5

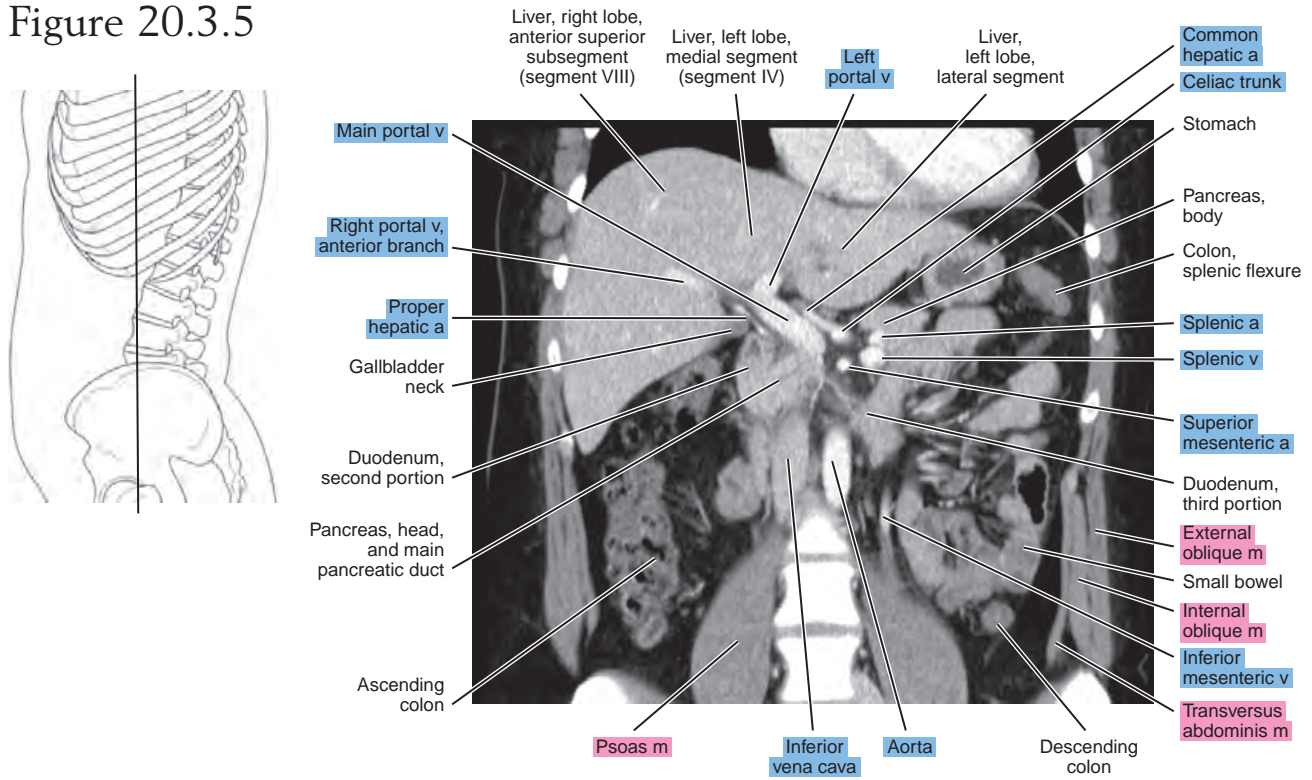


Figure 20.3.6

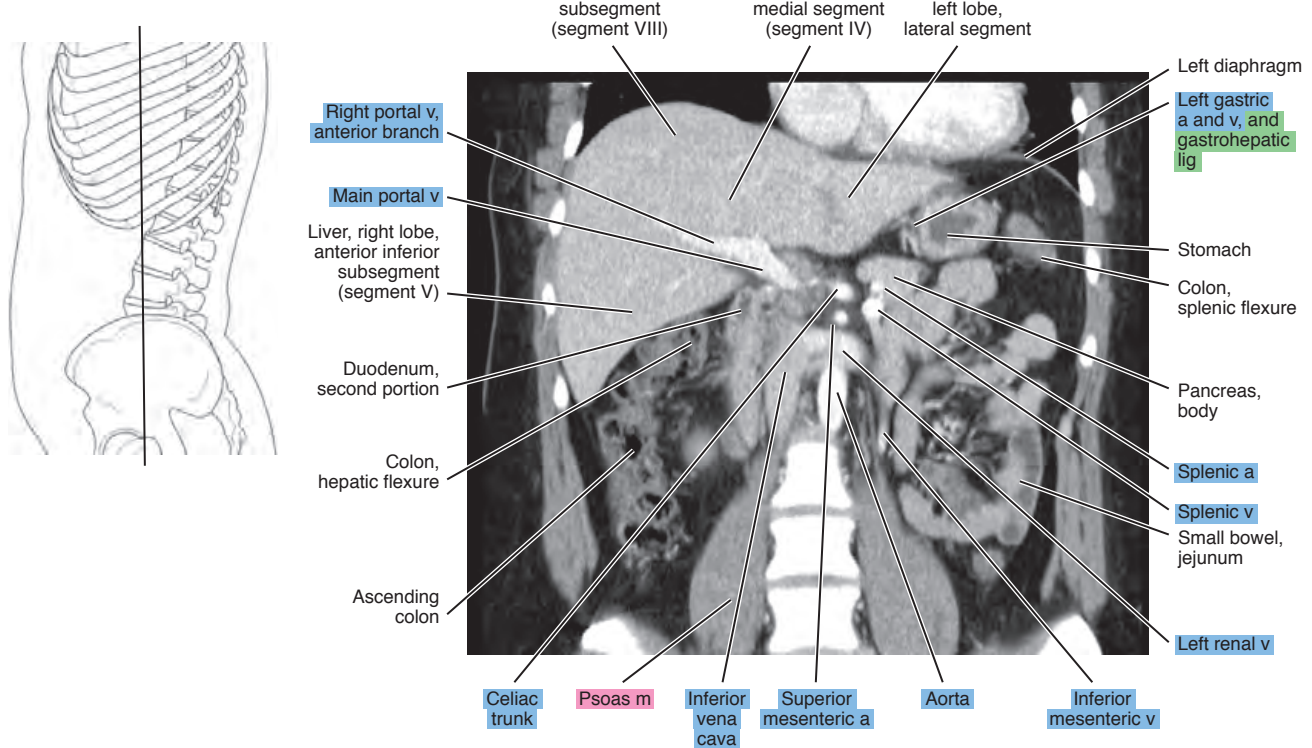


Figure 20.3.7

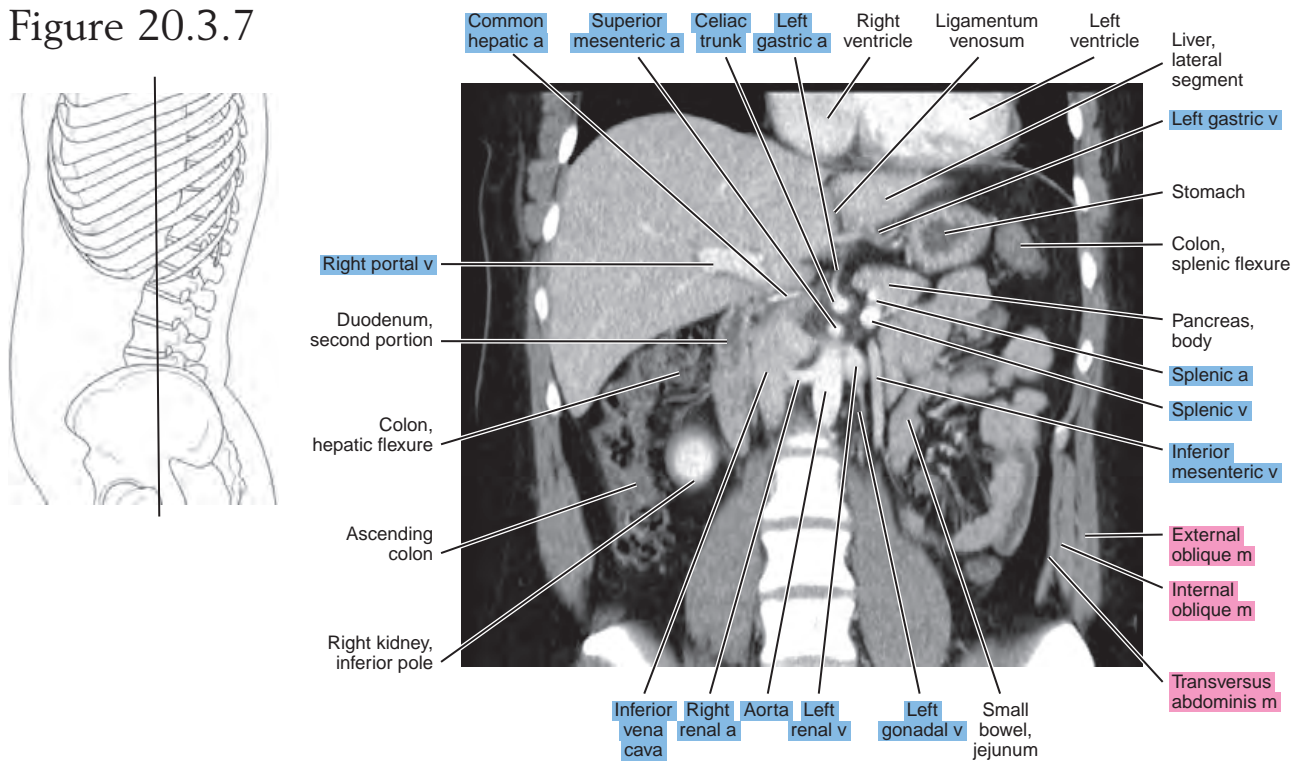


Figure 20.3.8

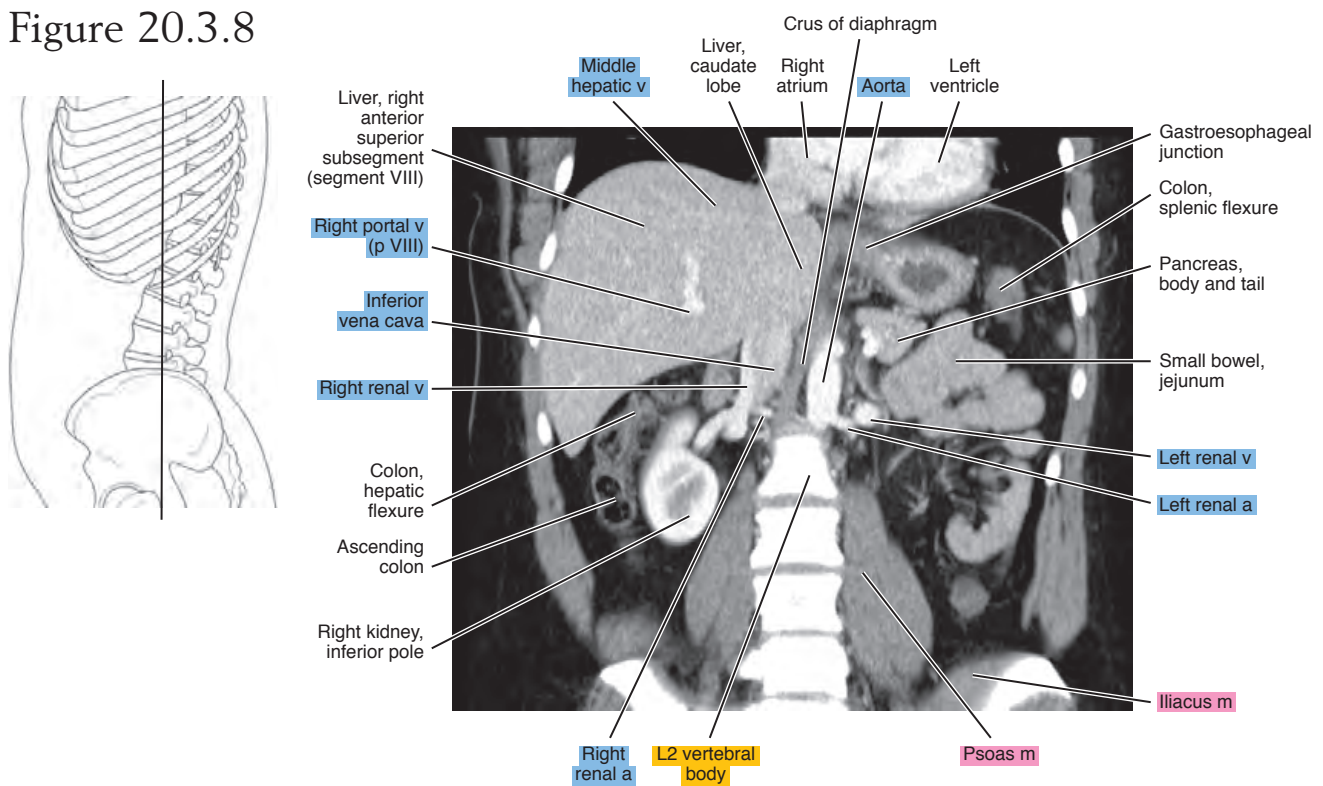


Figure 20.3.9

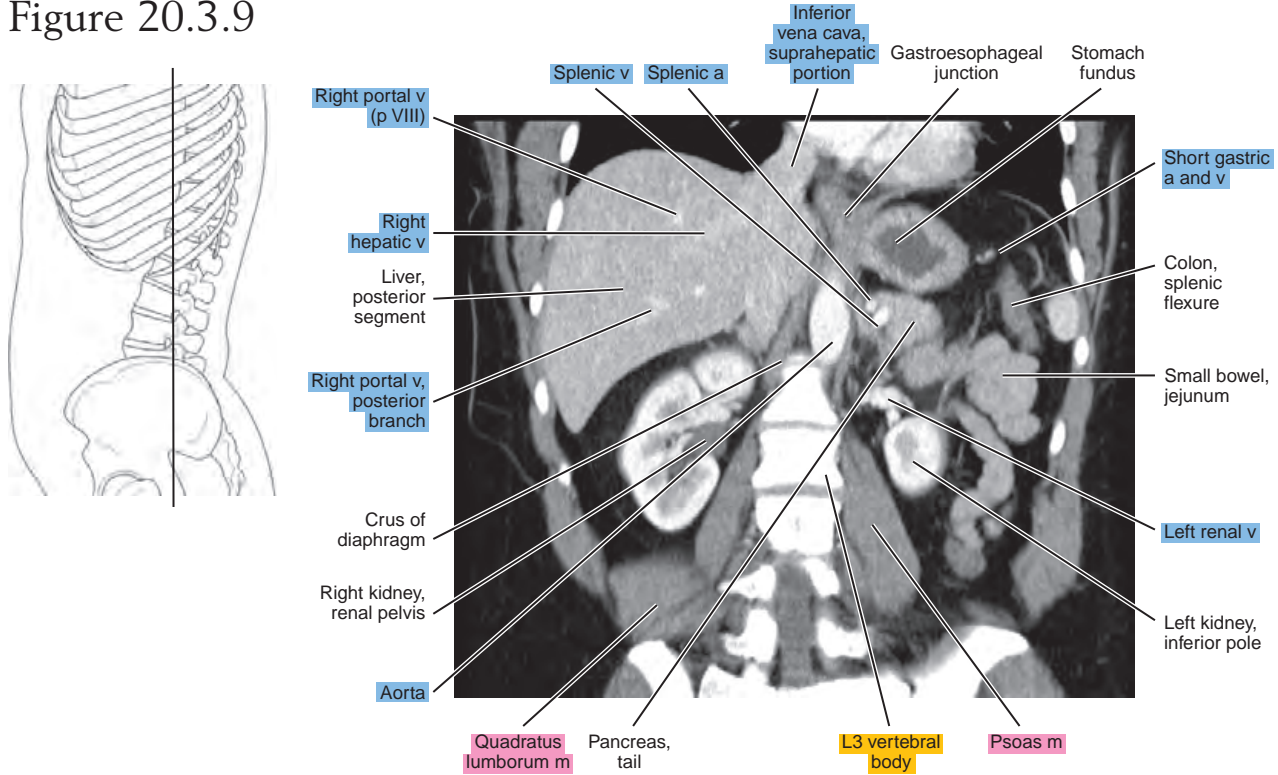


Figure 20.3.10

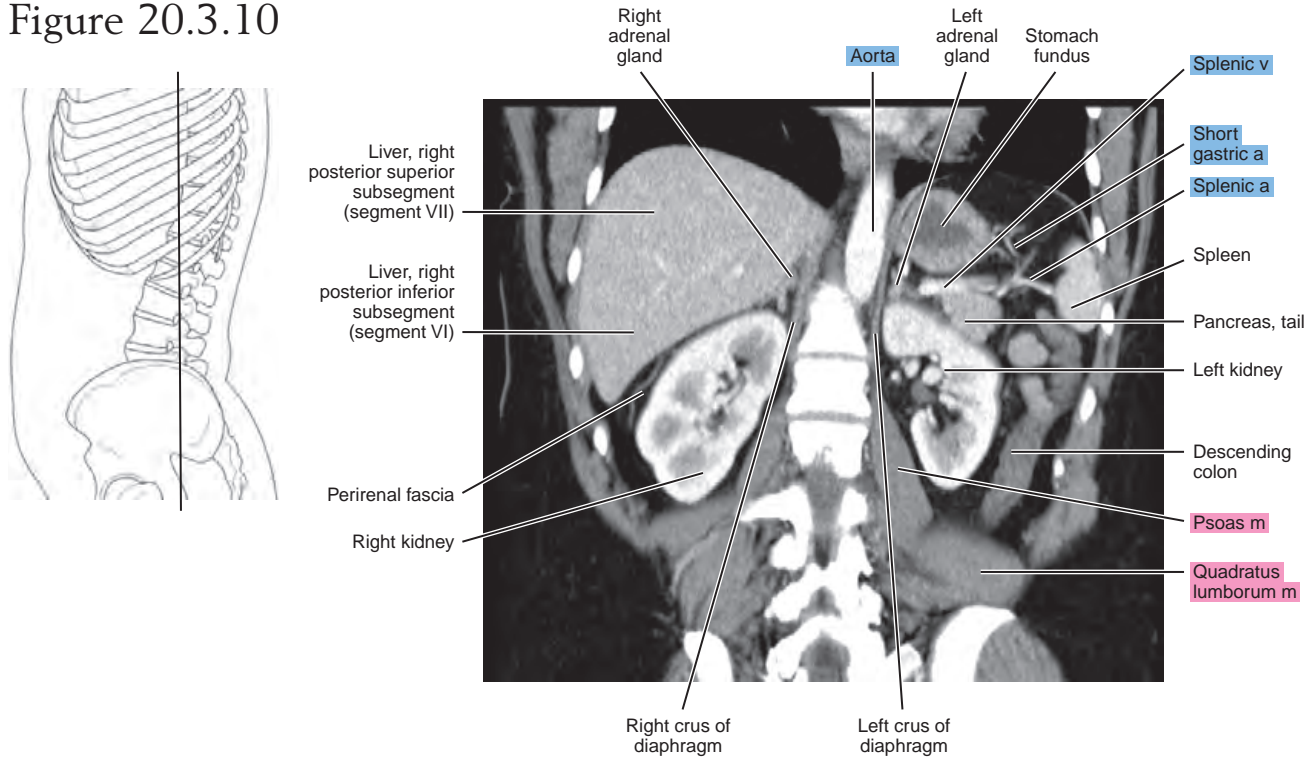


Figure 20.3.11

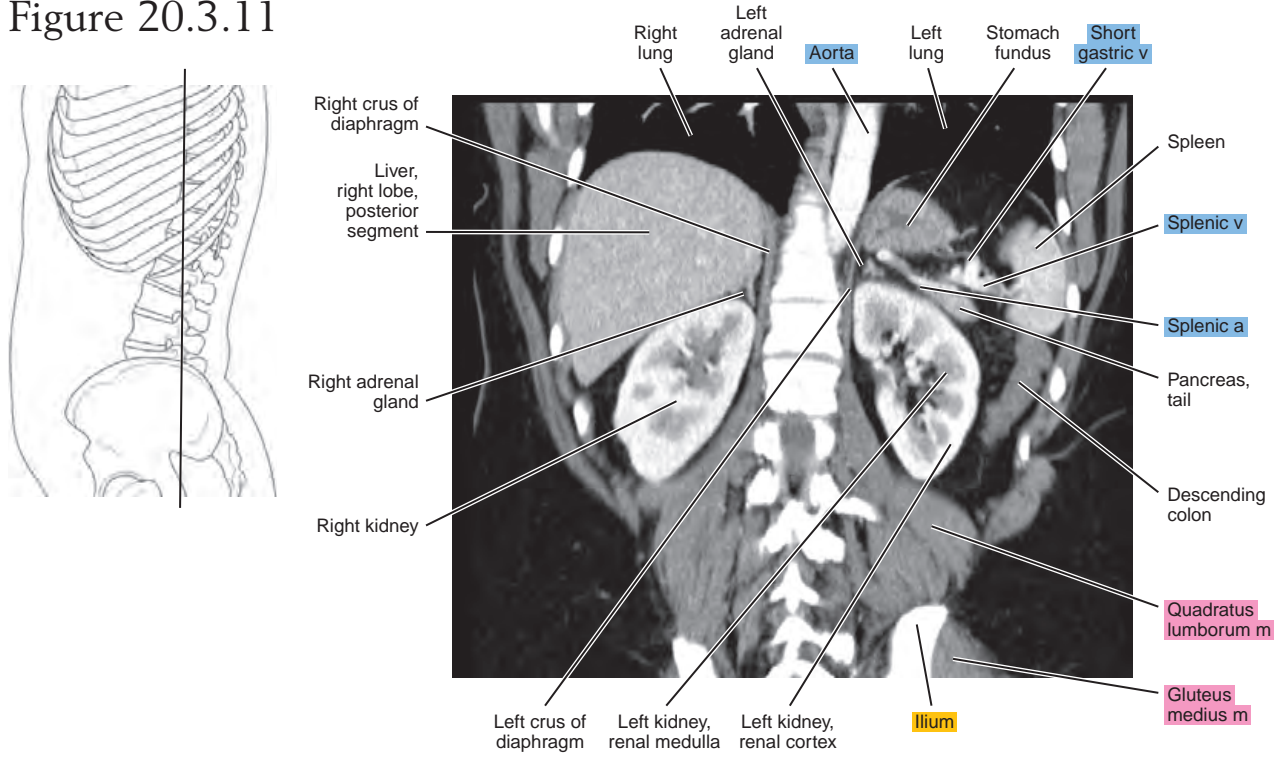
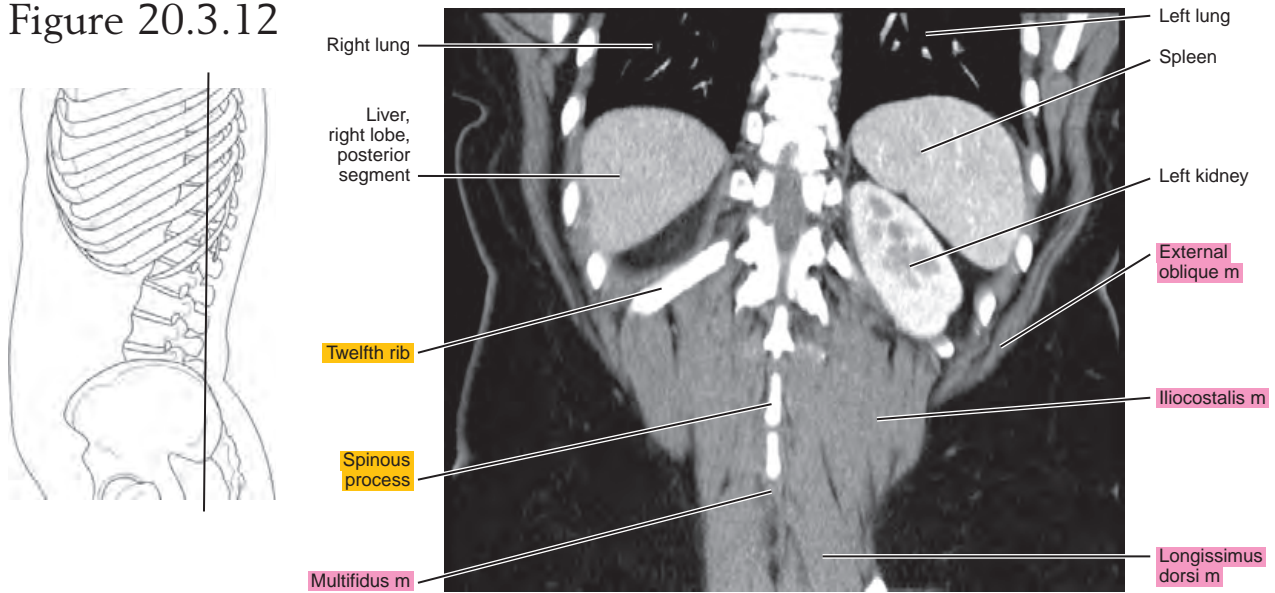


Figure 20.3.12



Chapter
21

MRI of the Abdomen

AXIAL

Figure 21.1.1

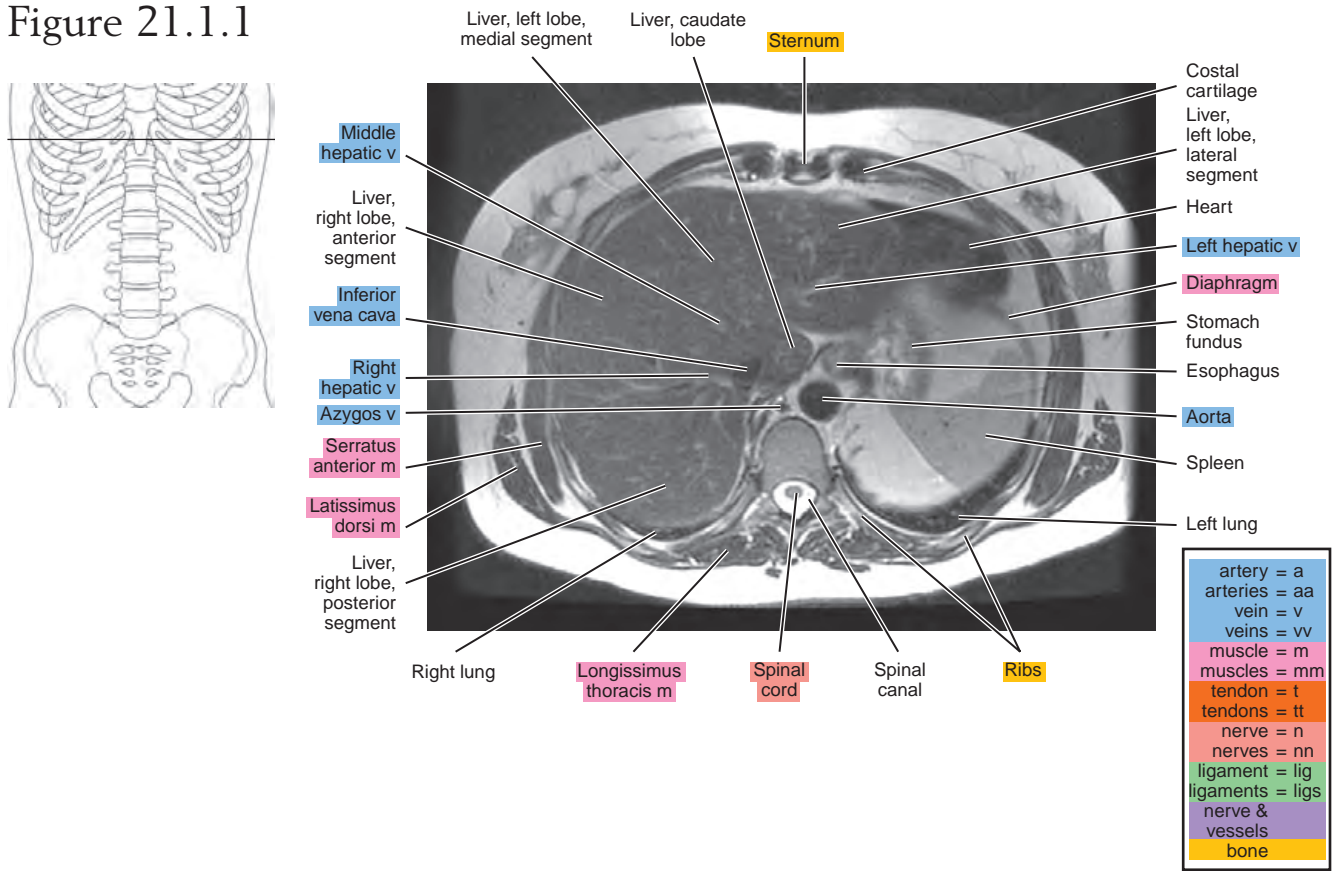


Figure 21.1.2

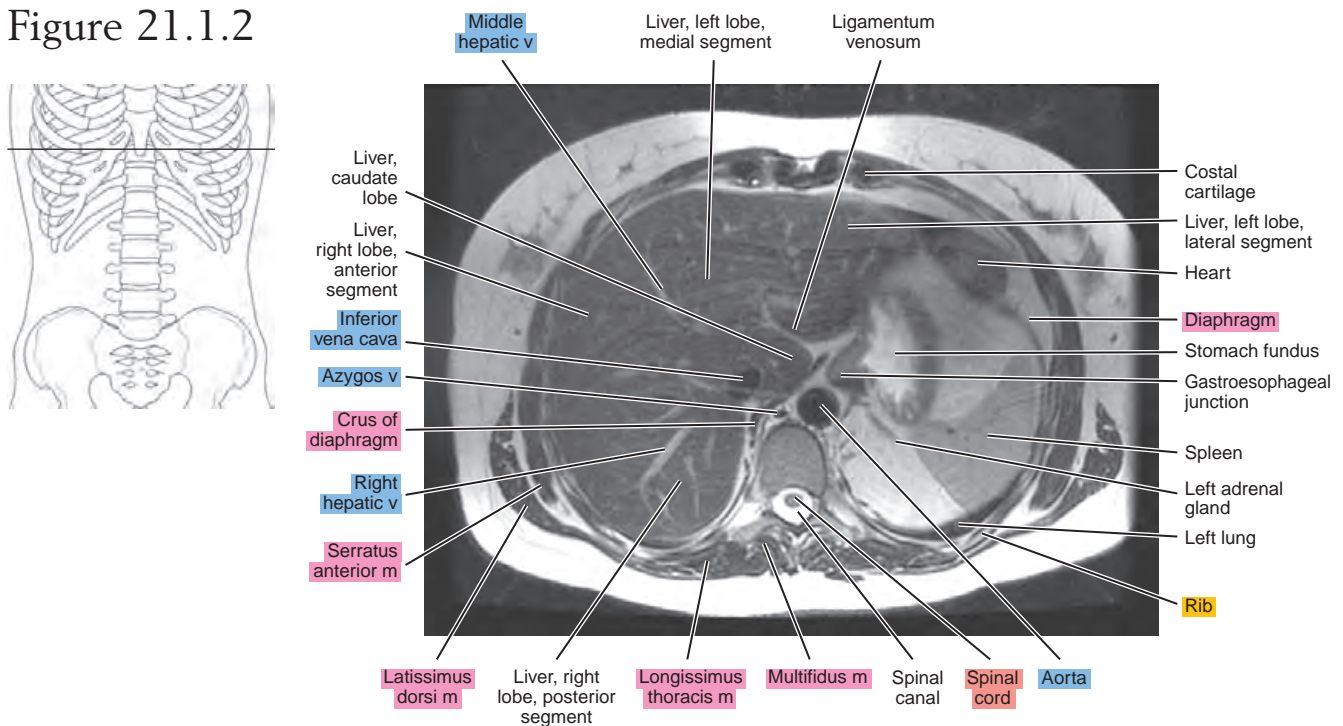


Figure 21.1.3

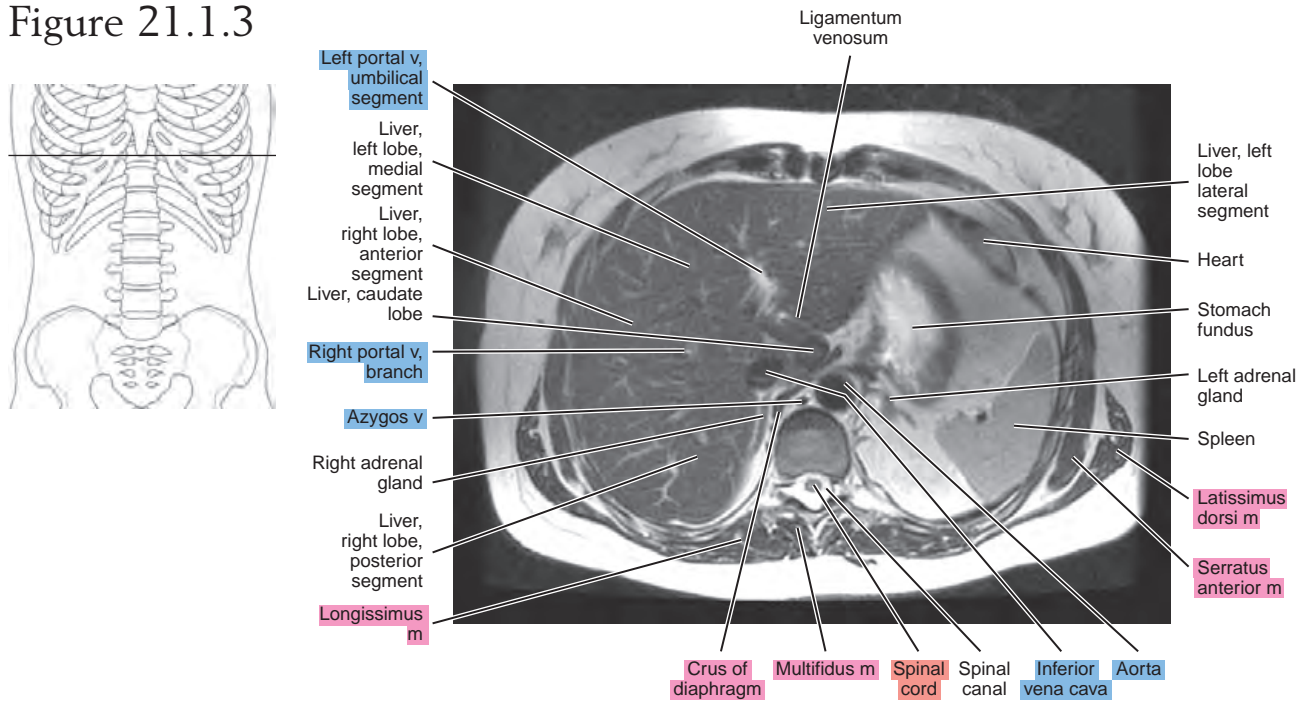


Figure 21.1.4

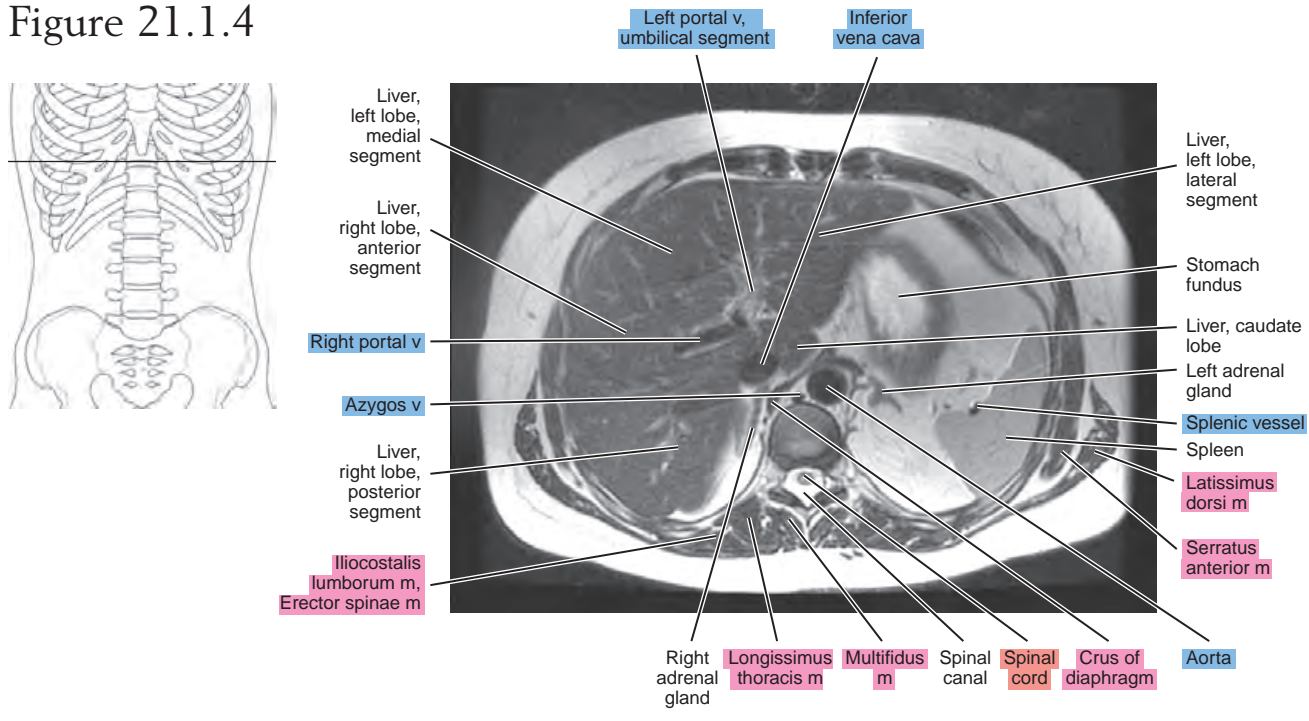


Figure 21.1.5

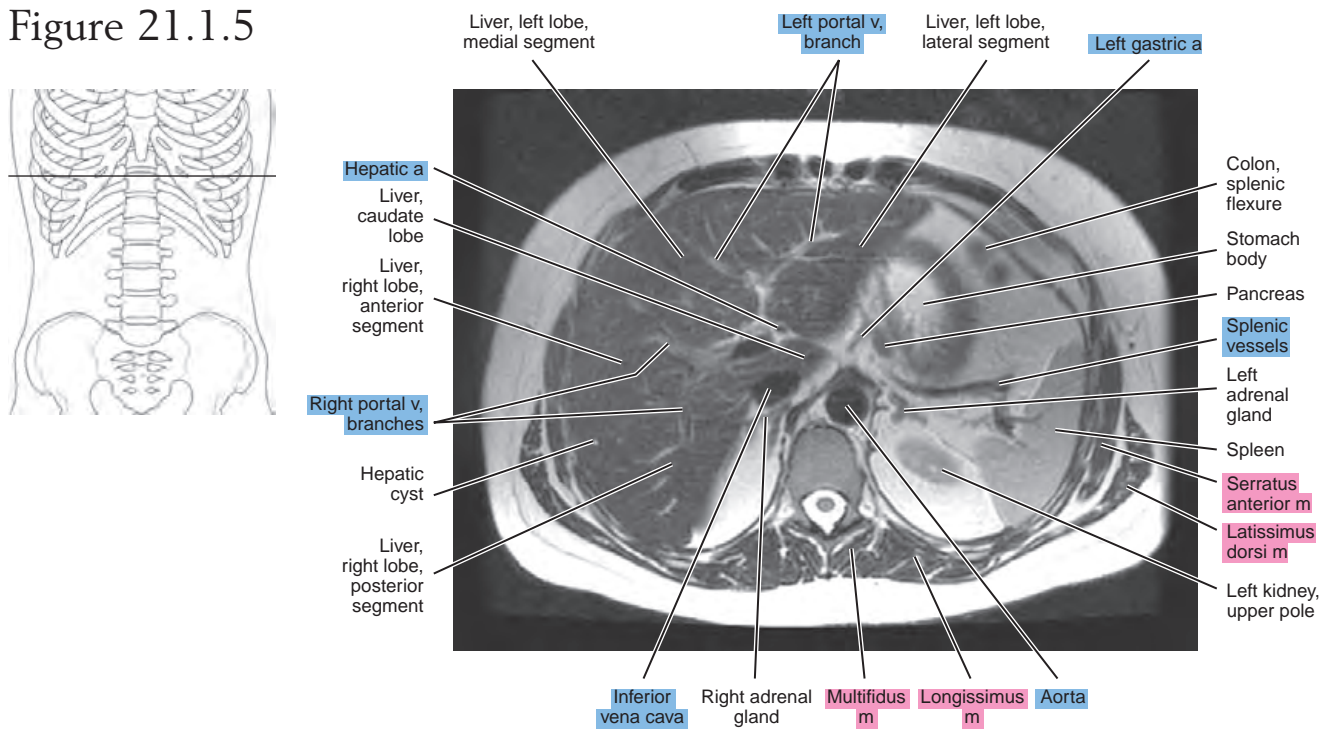


Figure 21.1.6

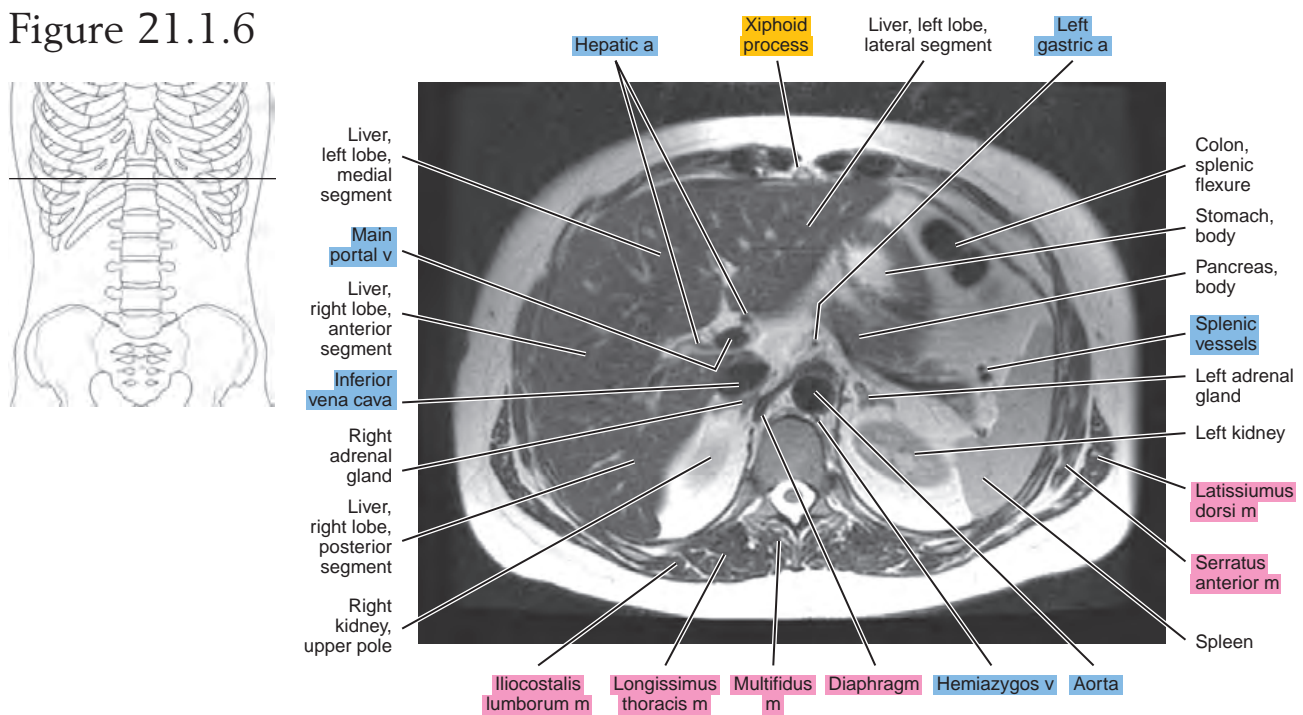


Figure 21.1.7

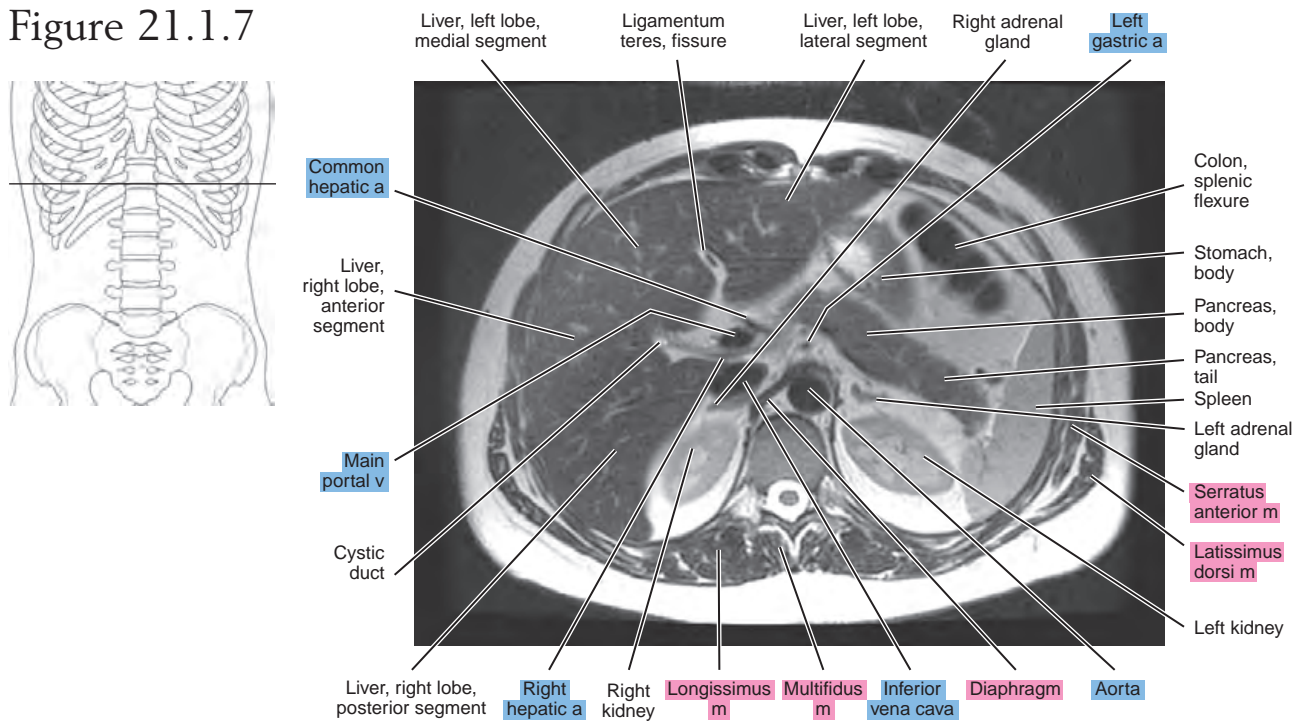


Figure 21.1.8

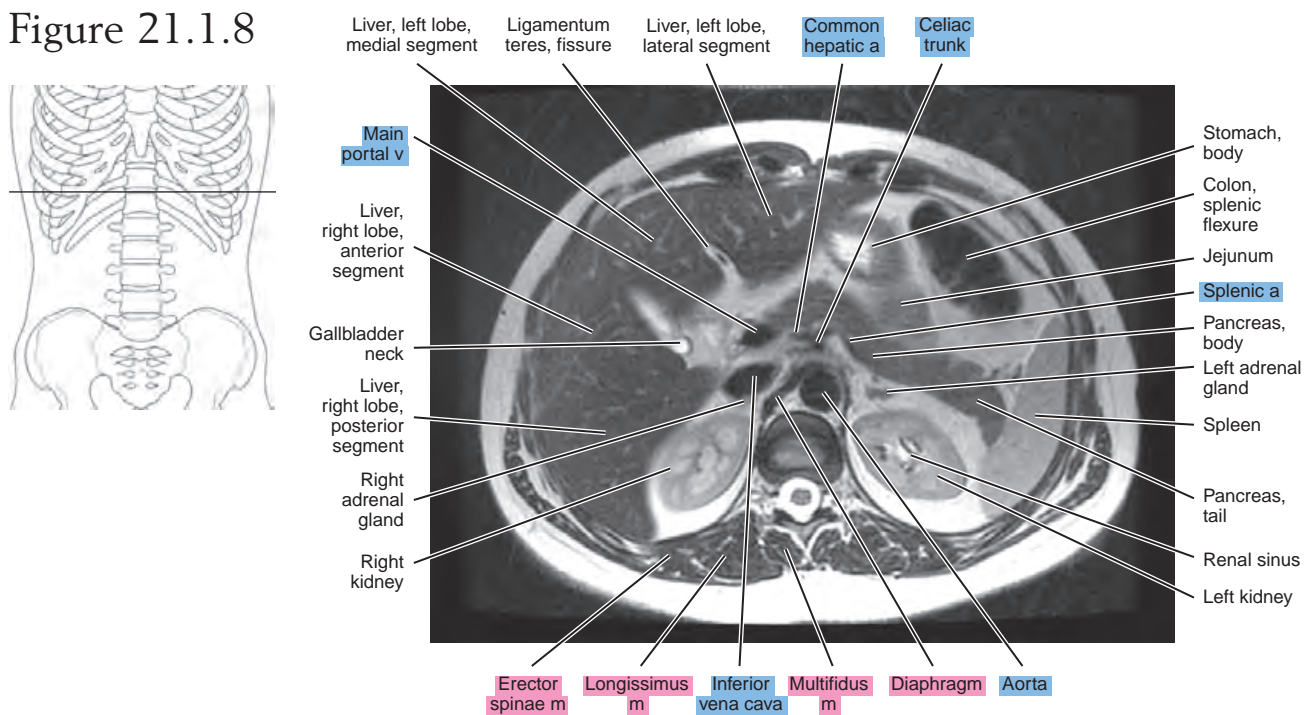


Figure 21.1.9

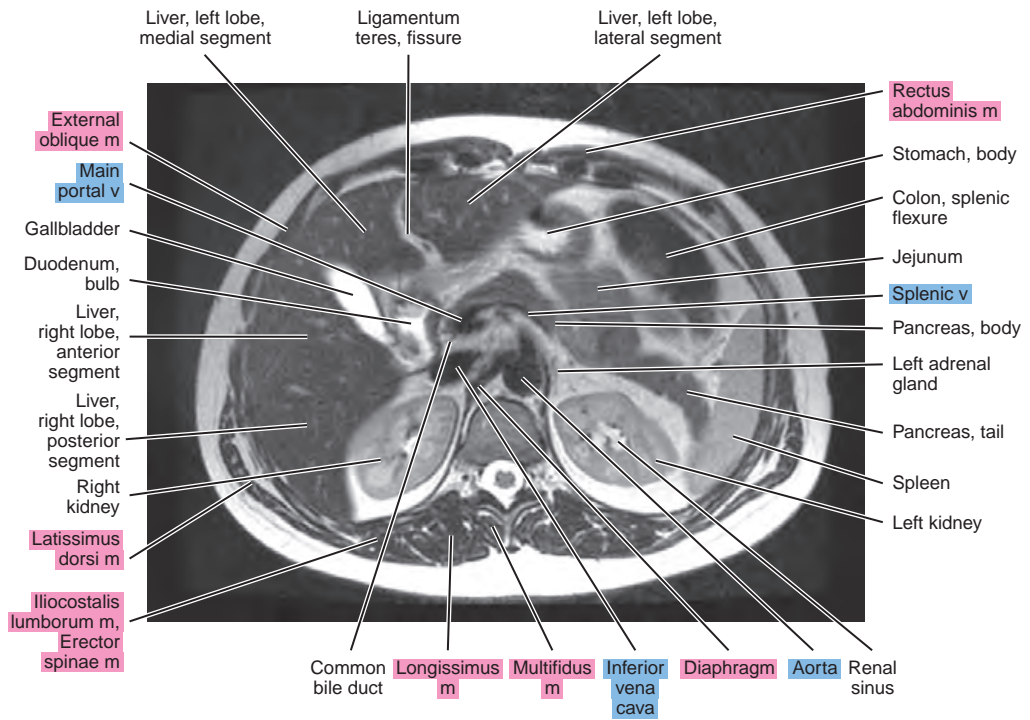
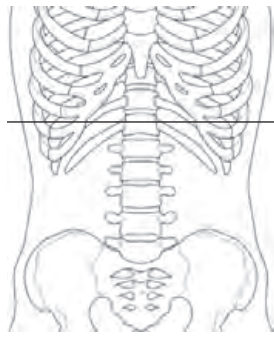


Figure 21.1.10

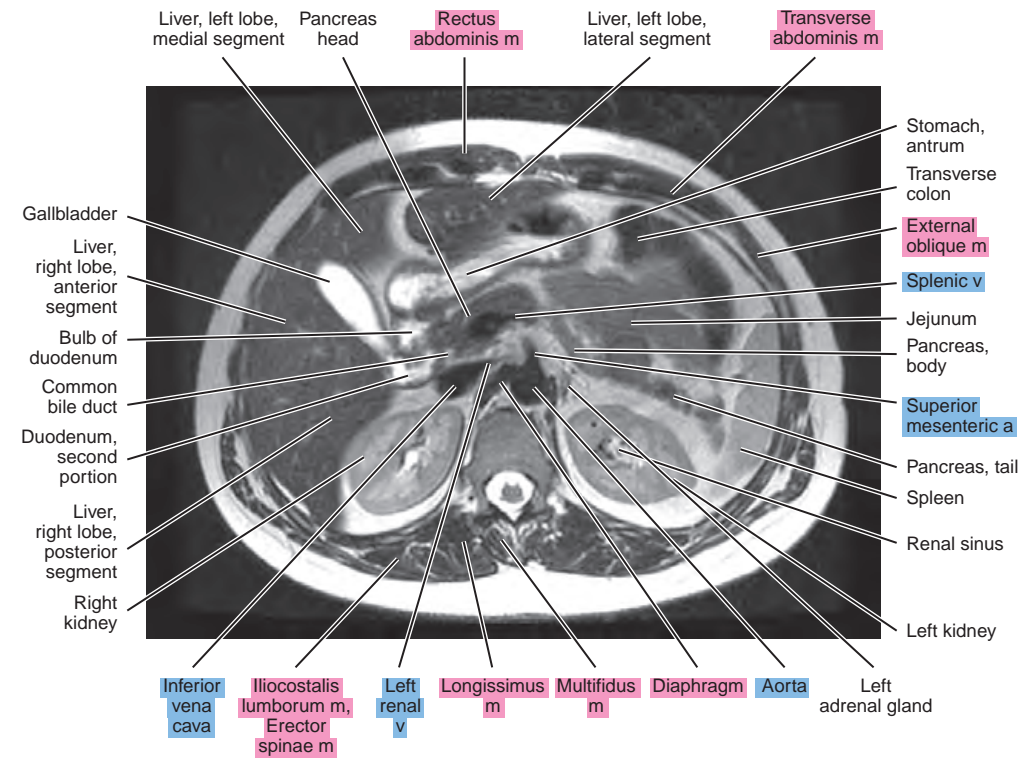
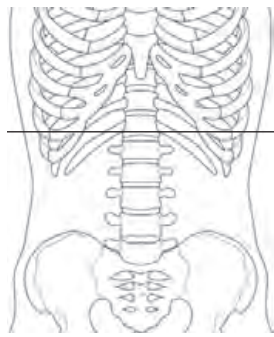


Figure 21.1.11

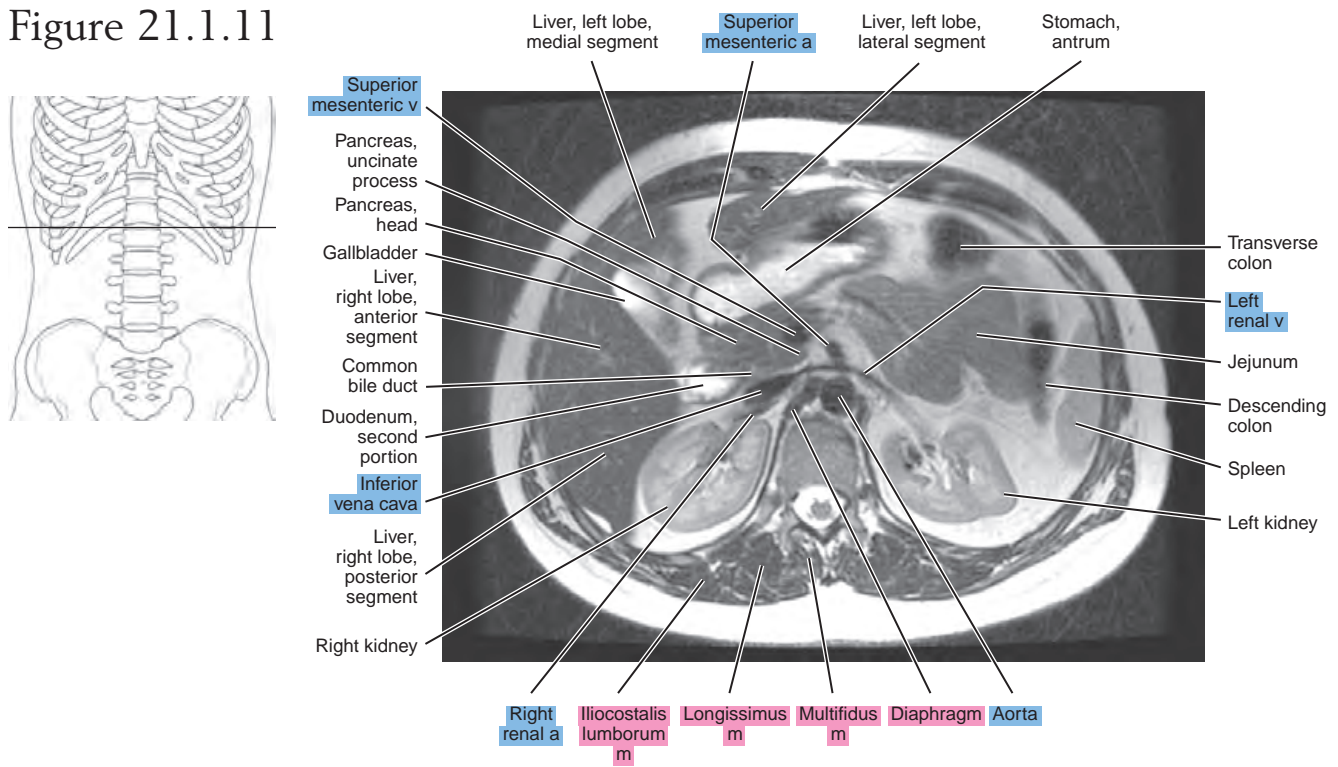


Figure 21.1.12

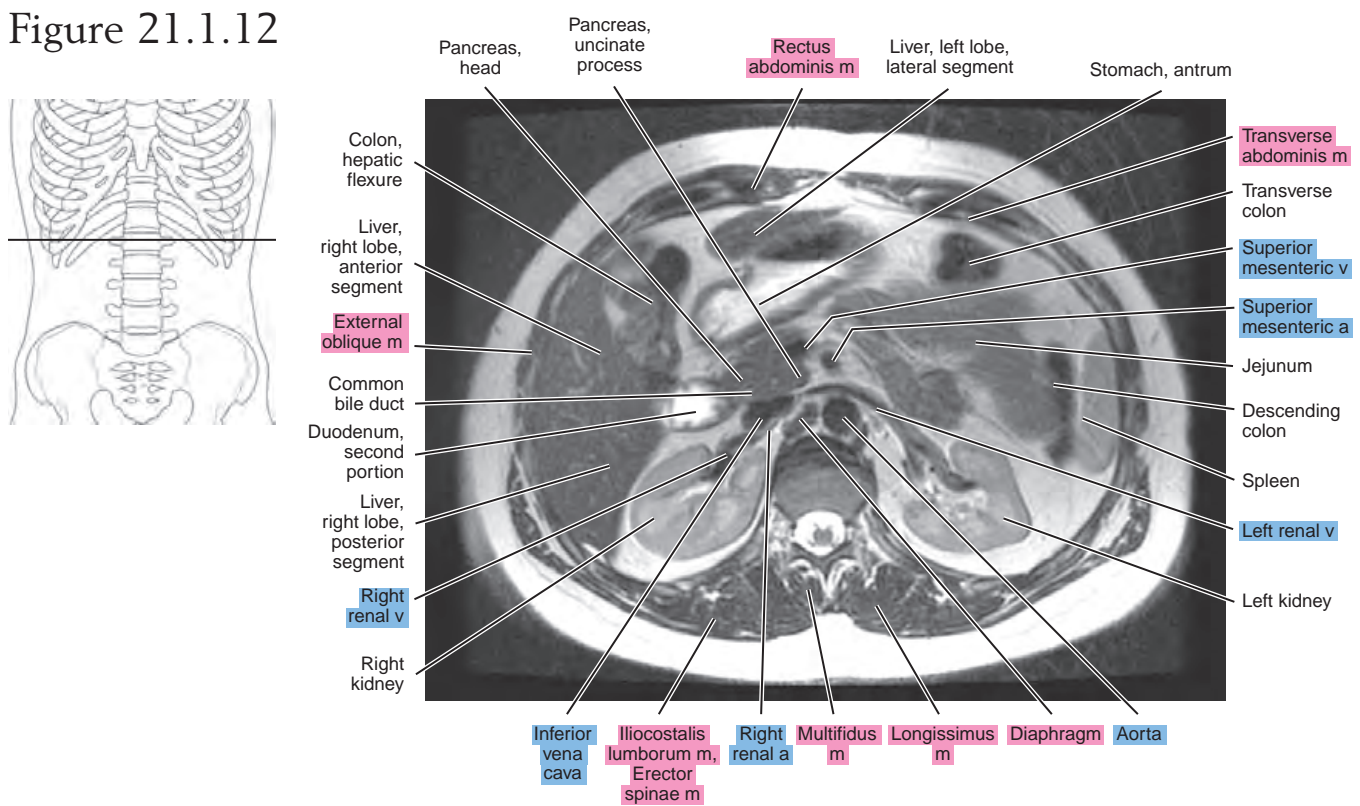


Figure 21.1.13

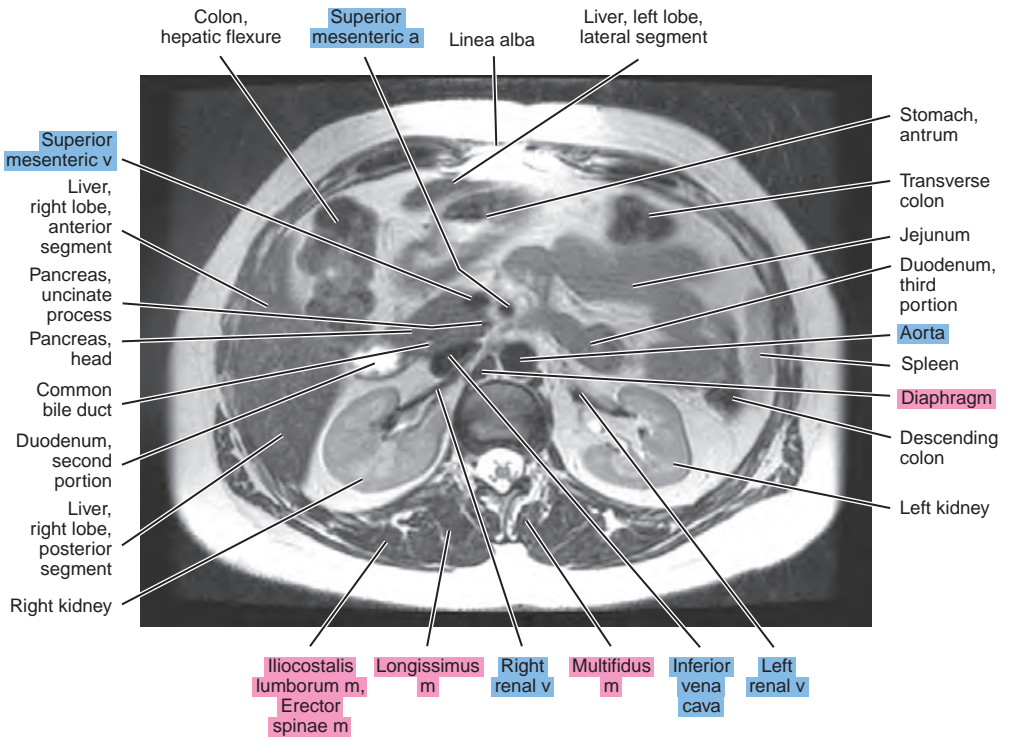
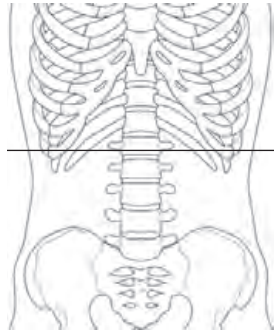


Figure 21.1.14

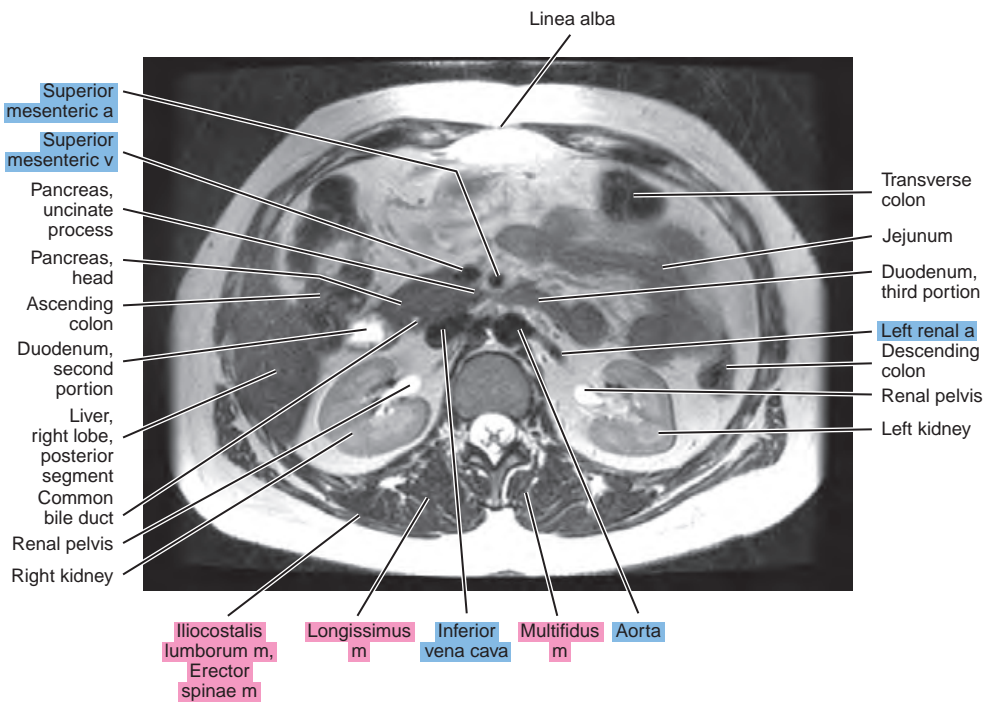
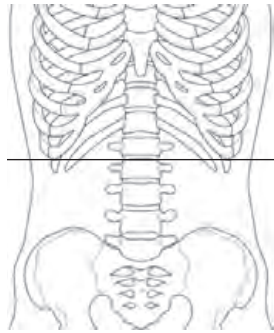


Figure 21.1.15

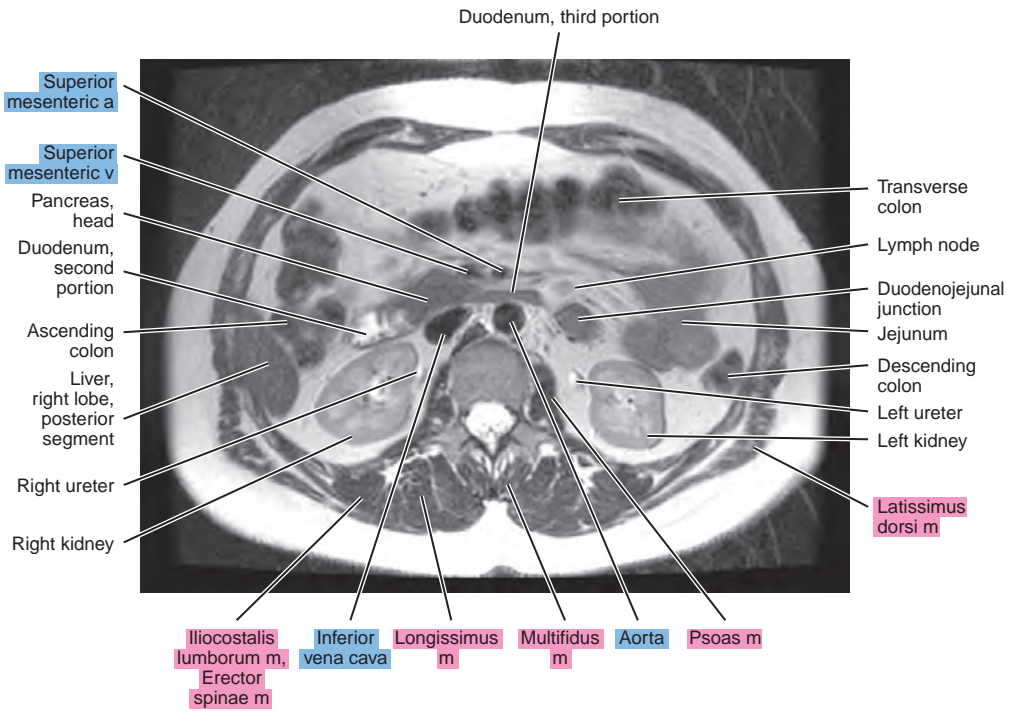
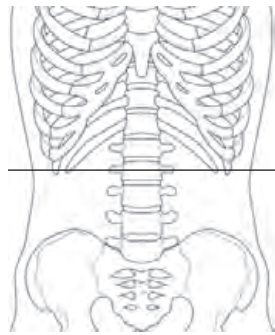
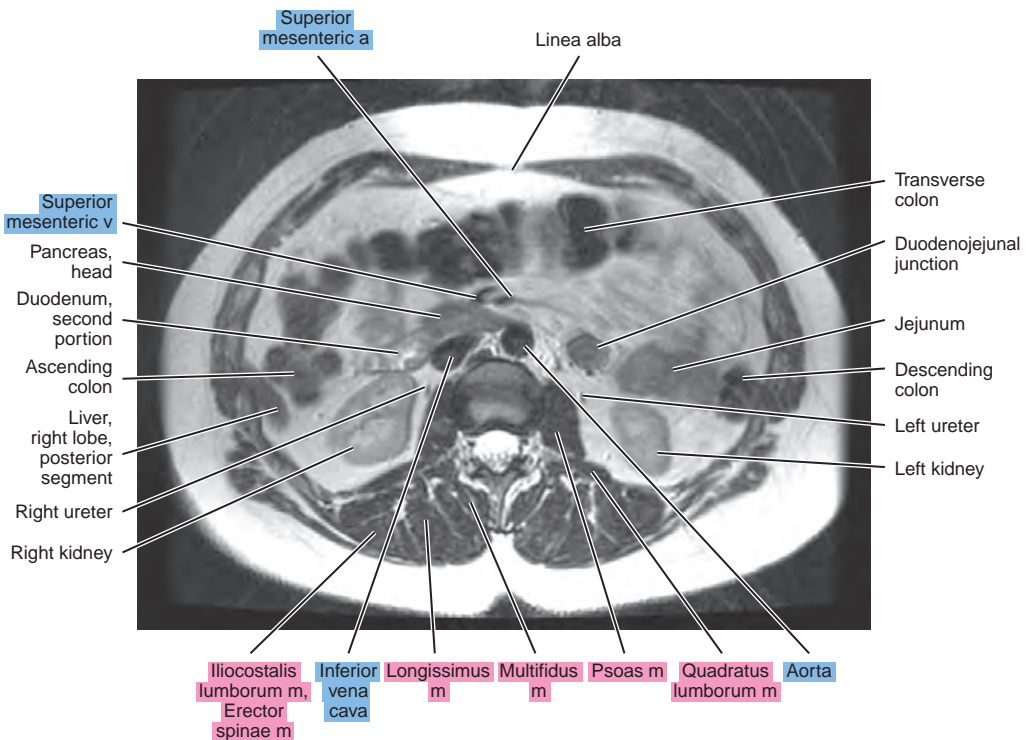
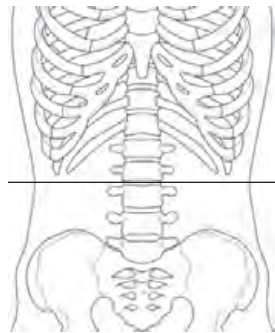


Figure 21.1.16



SAGITTAL

Figure 21.2.1

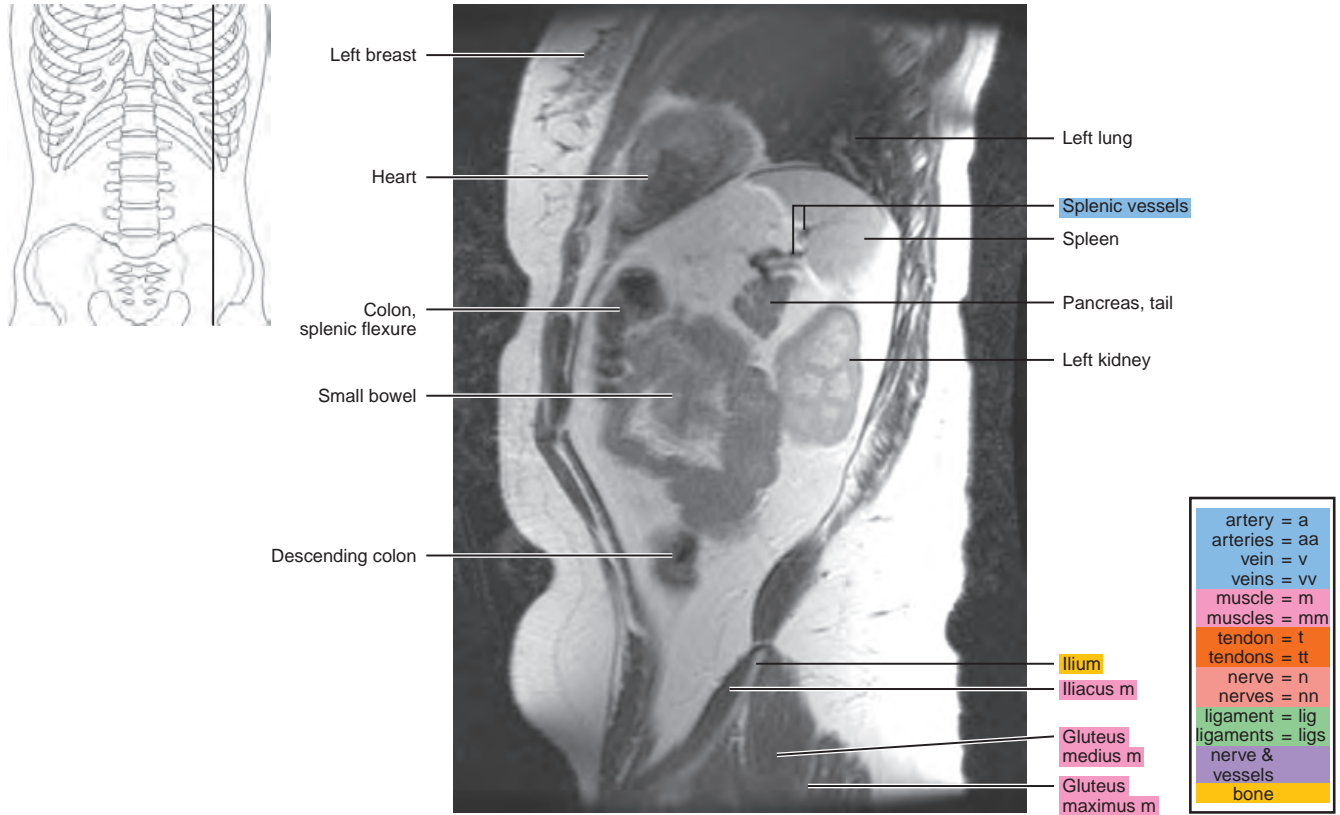


Figure 21.2.2

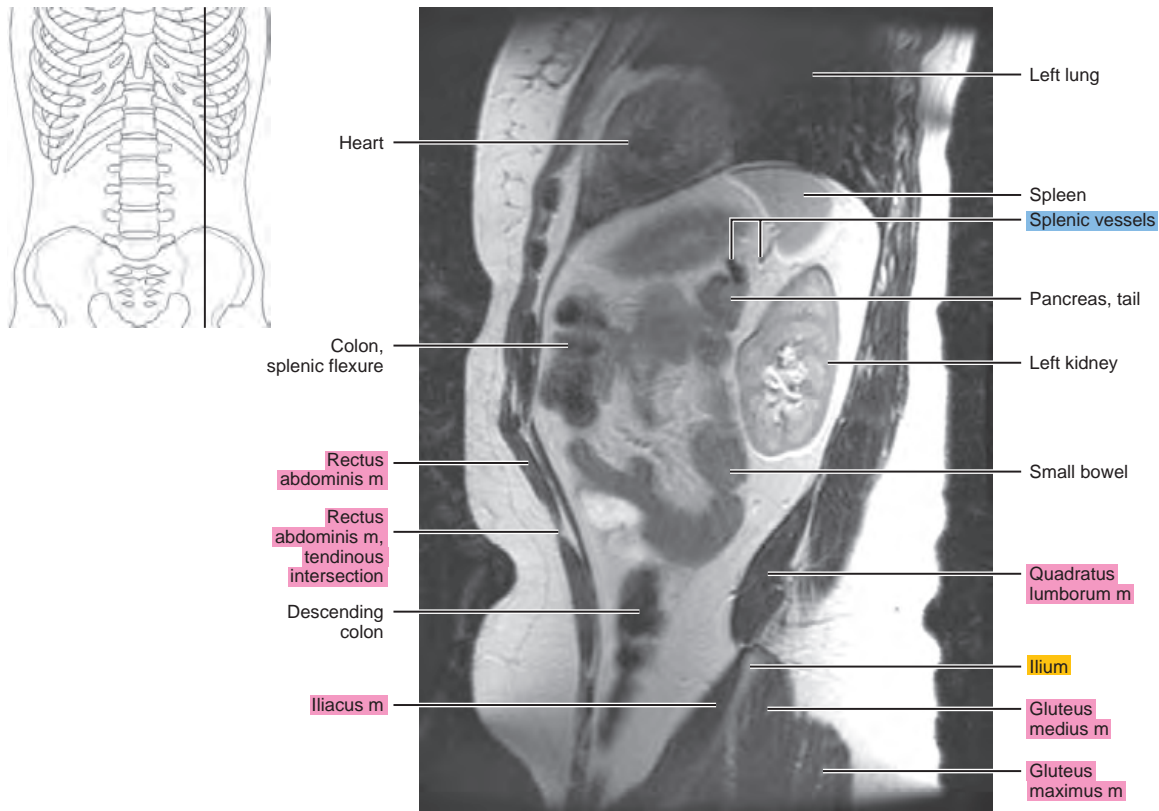


Figure 21.2.3

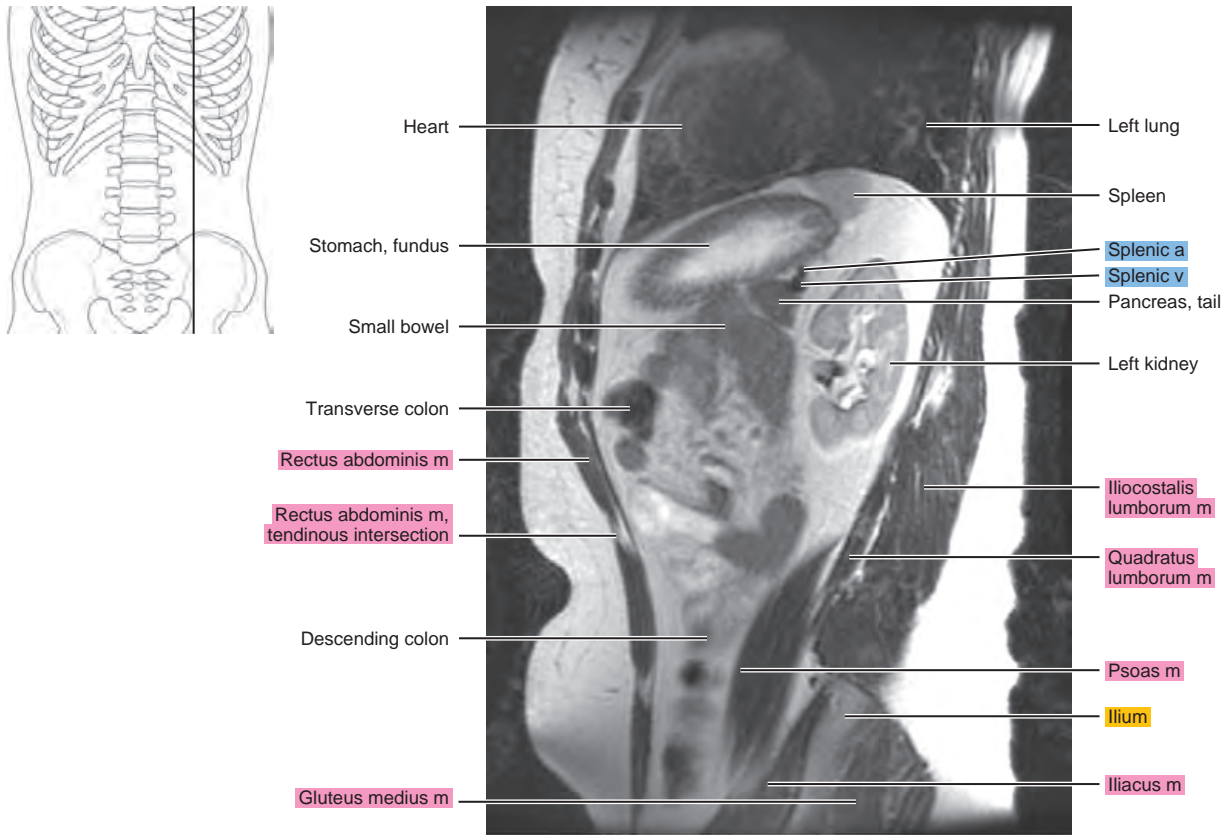


Figure 21.2.4

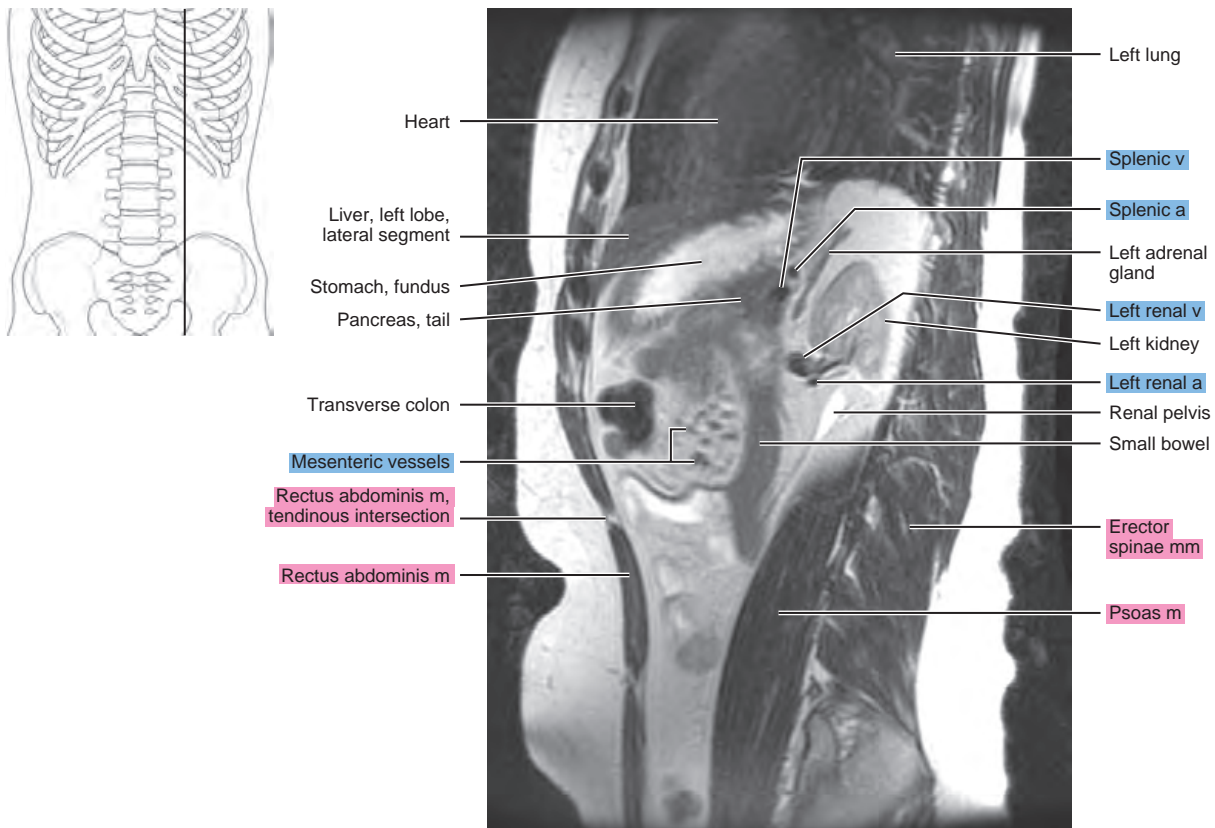


Figure 21.2.5

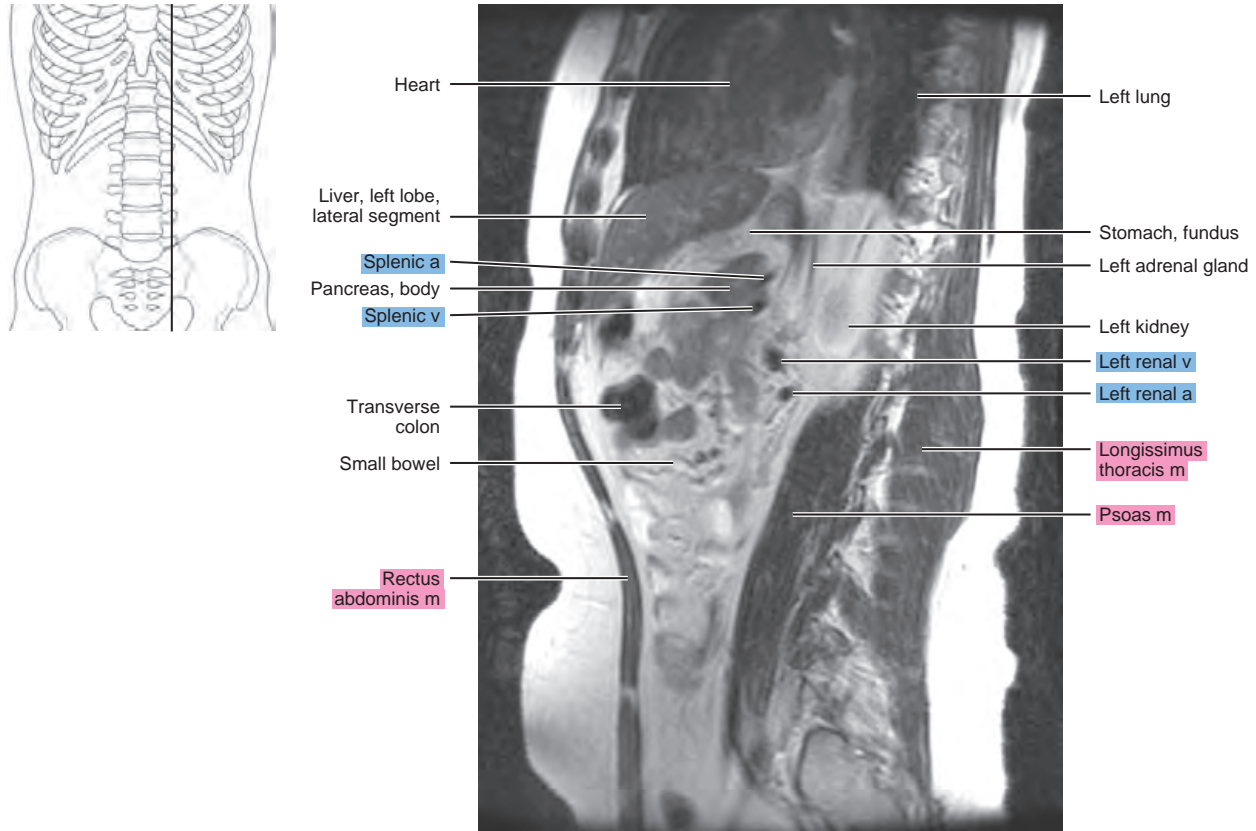


Figure 21.2.6

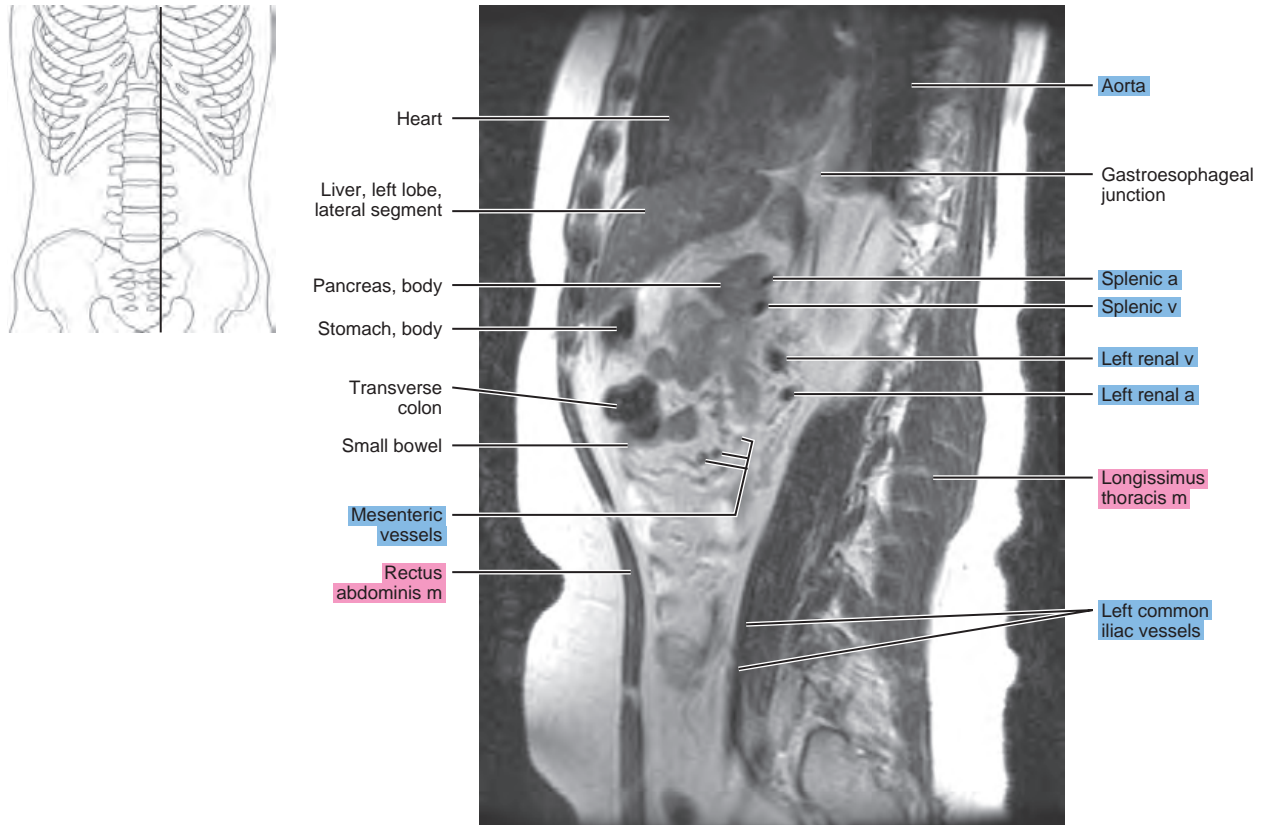


Figure 21.2.7

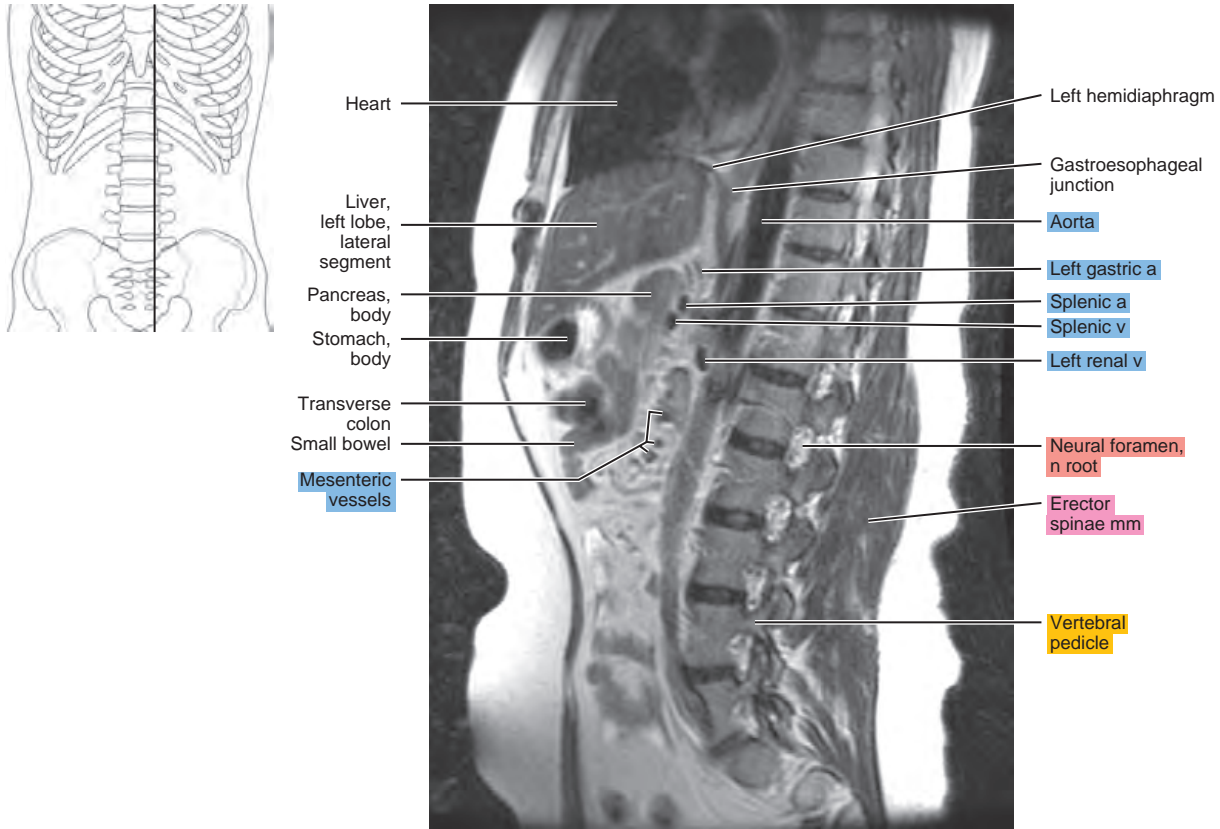


Figure 21.2.8

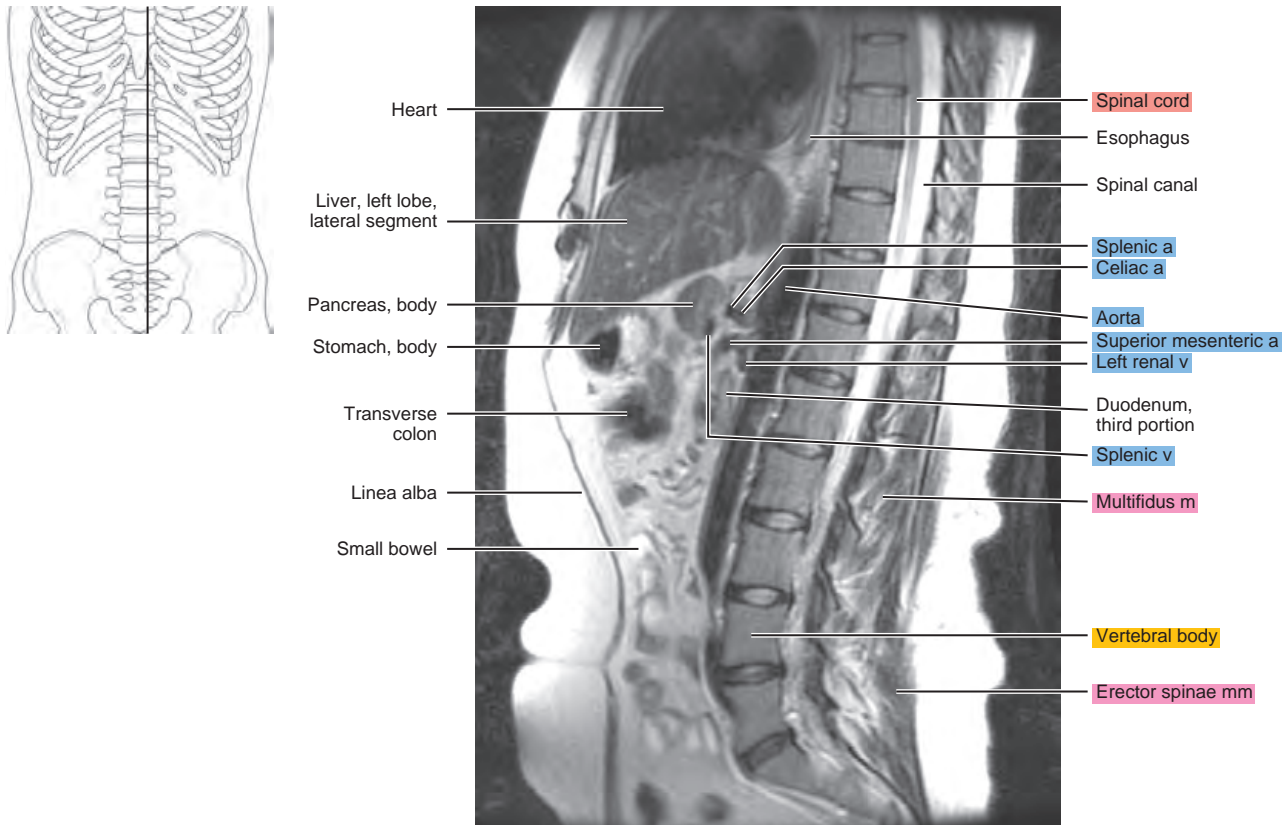


Figure 21.2.9

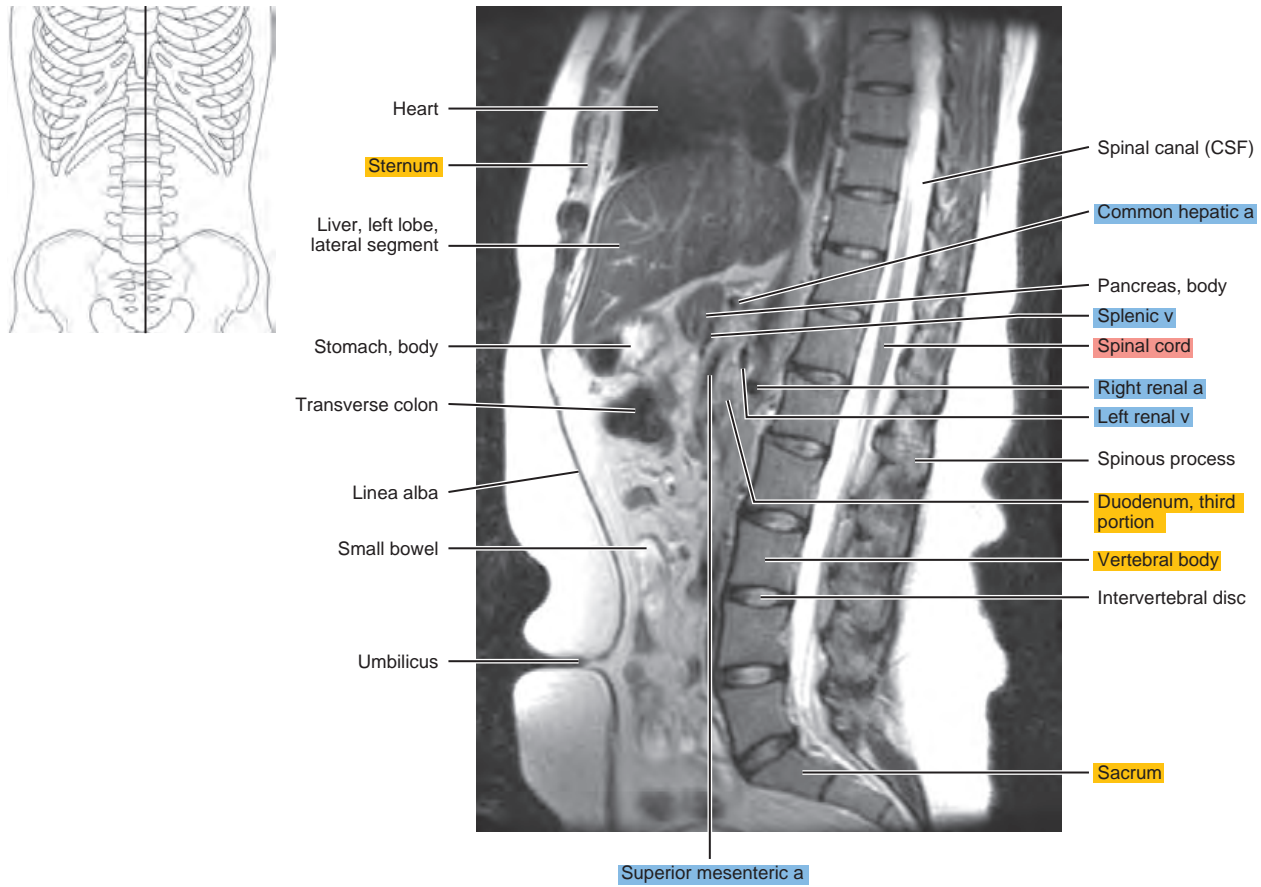


Figure 21.2.10

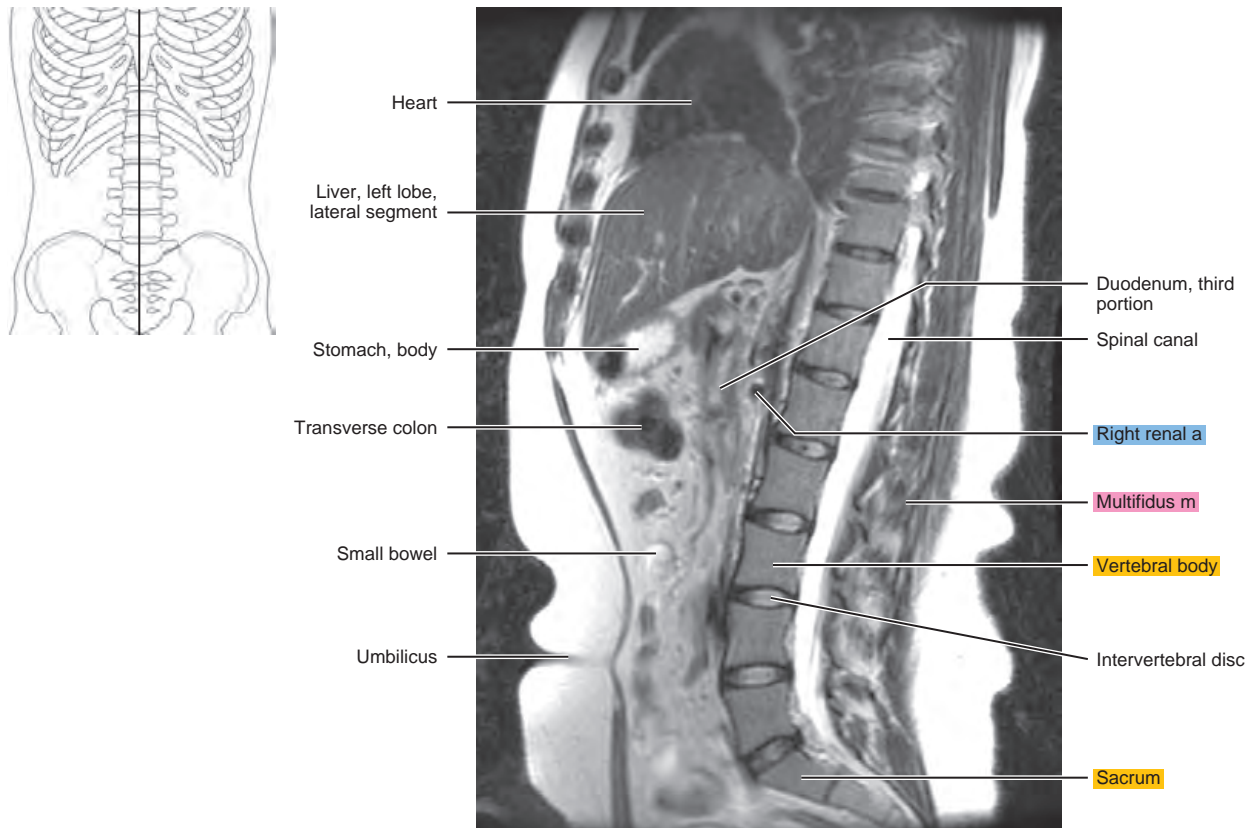


Figure 21.2.11

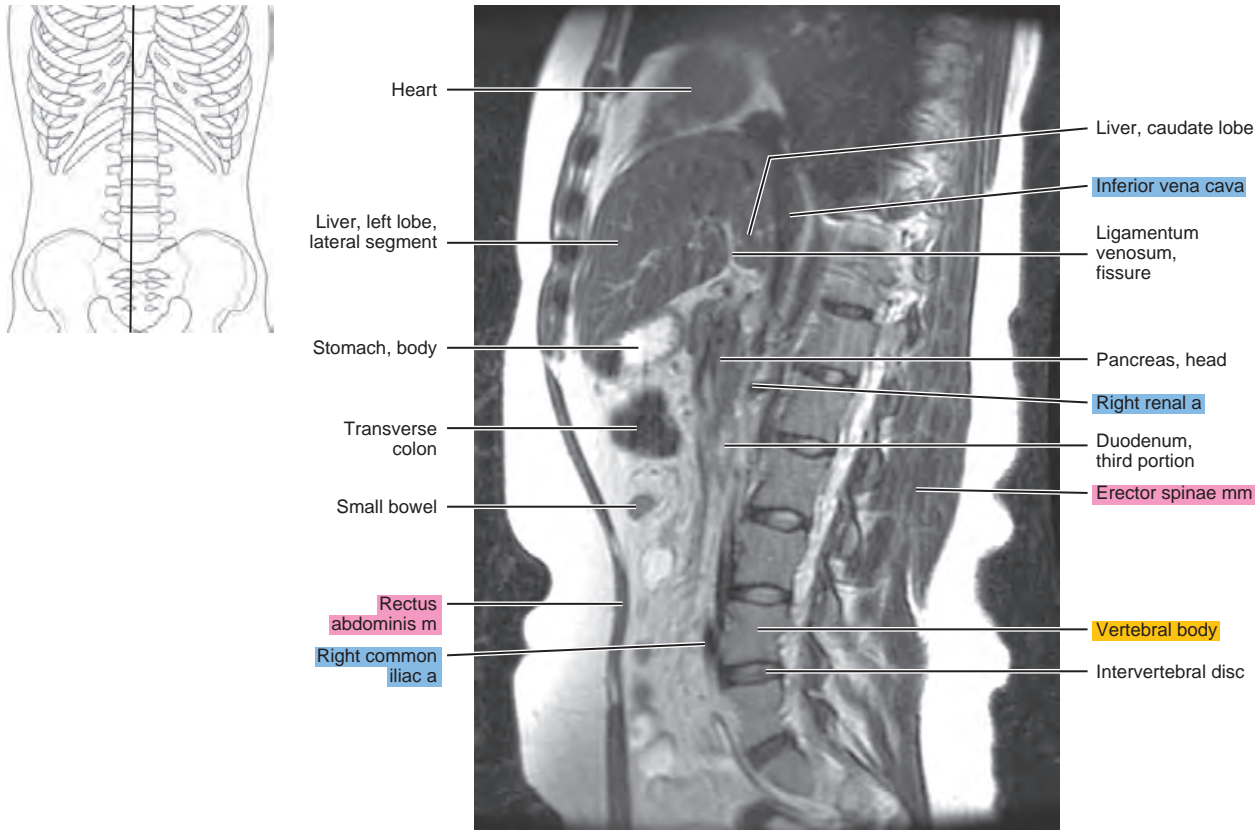


Figure 21.2.12

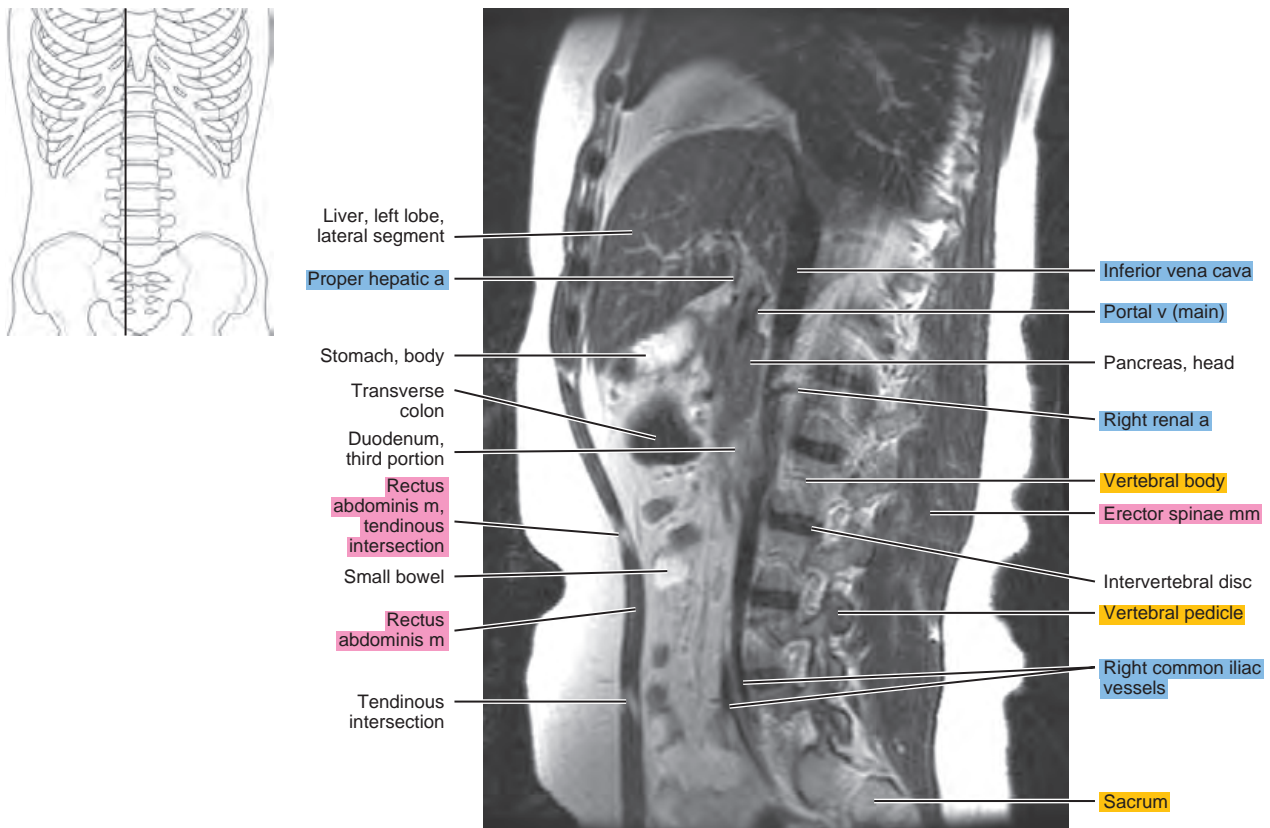


Figure 21.2.13

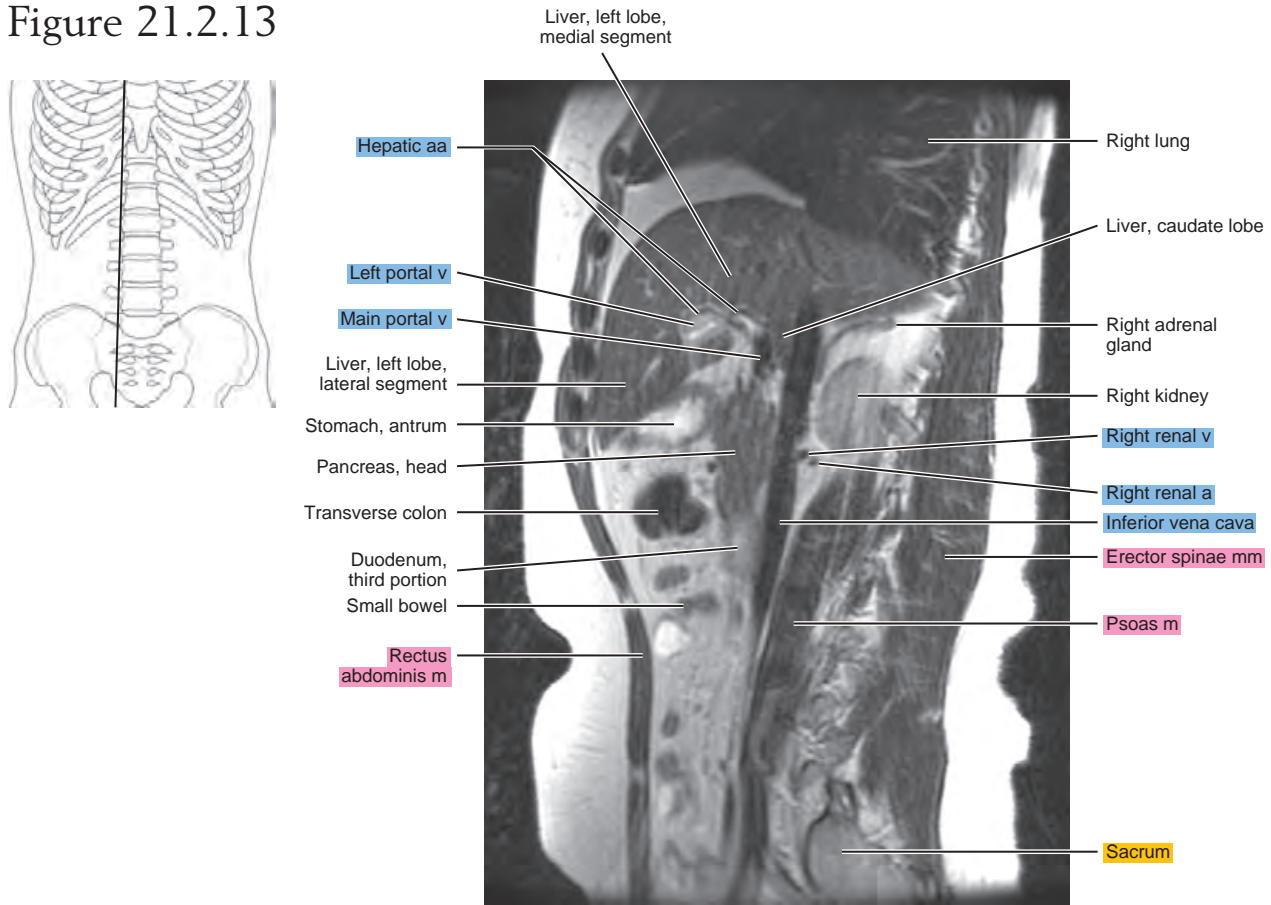


Figure 21.2.14

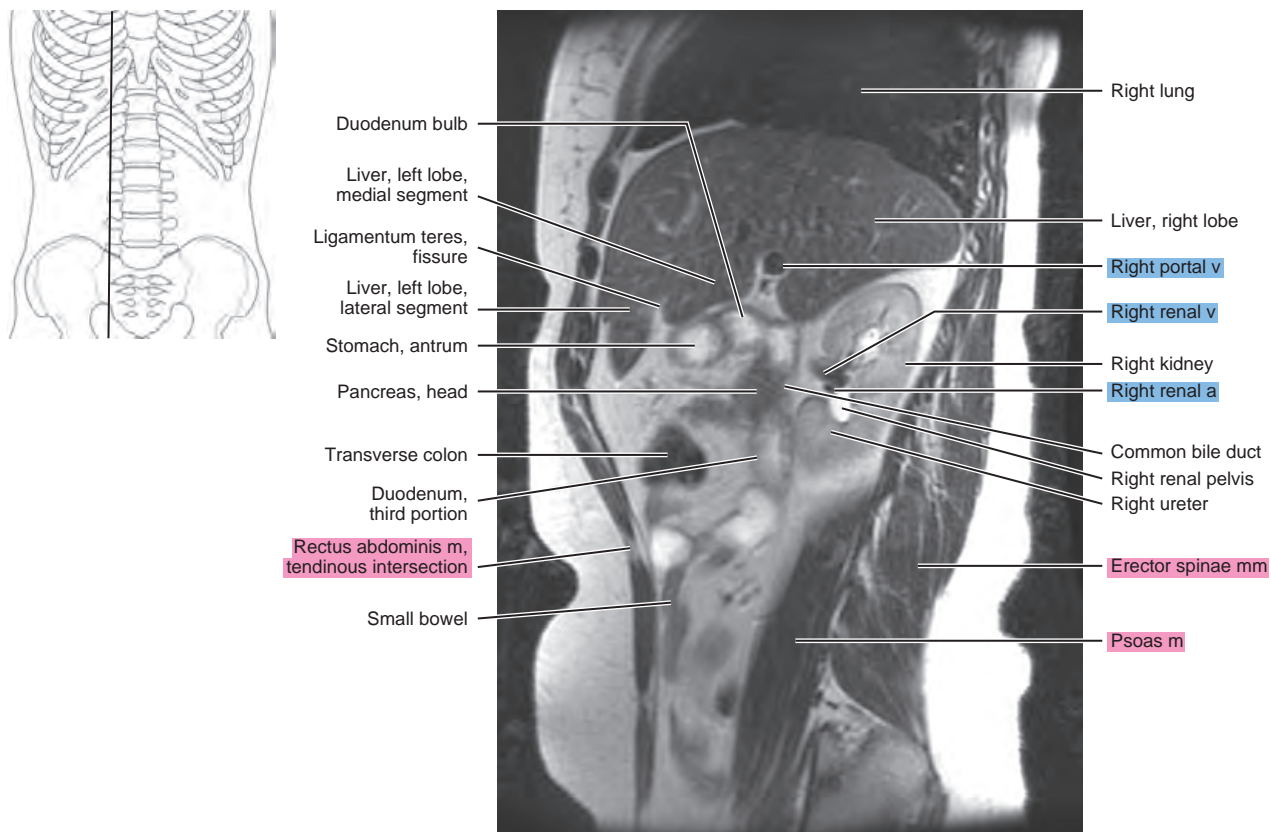


Figure 21.2.15

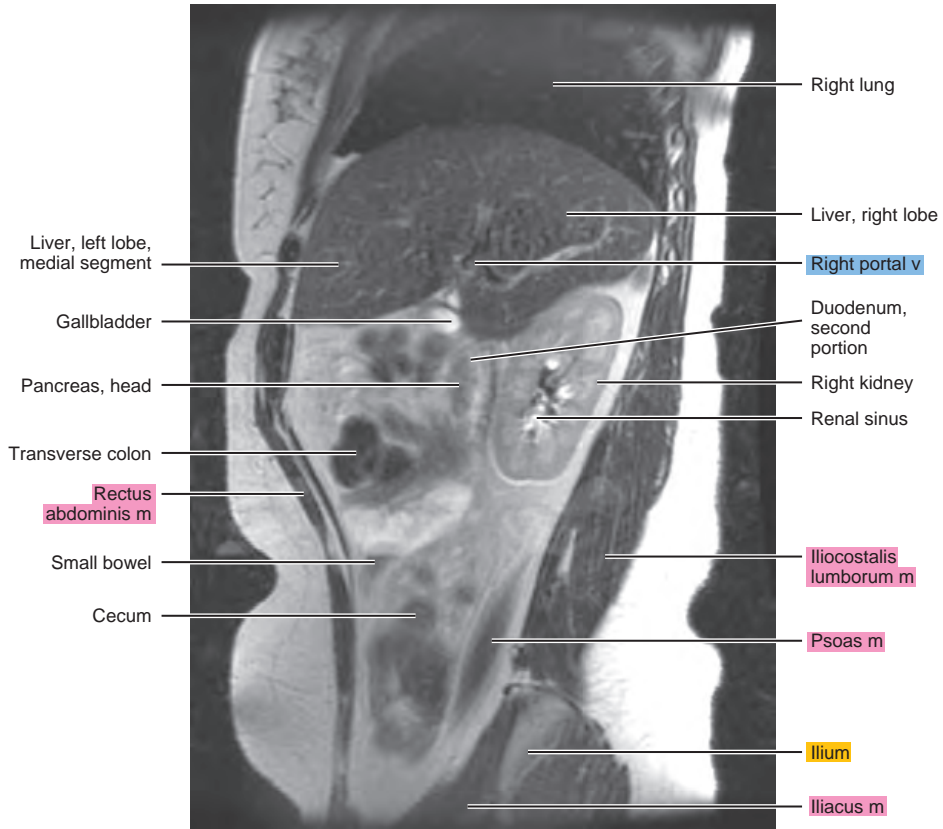
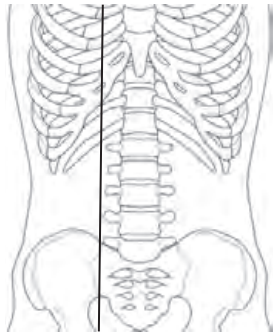
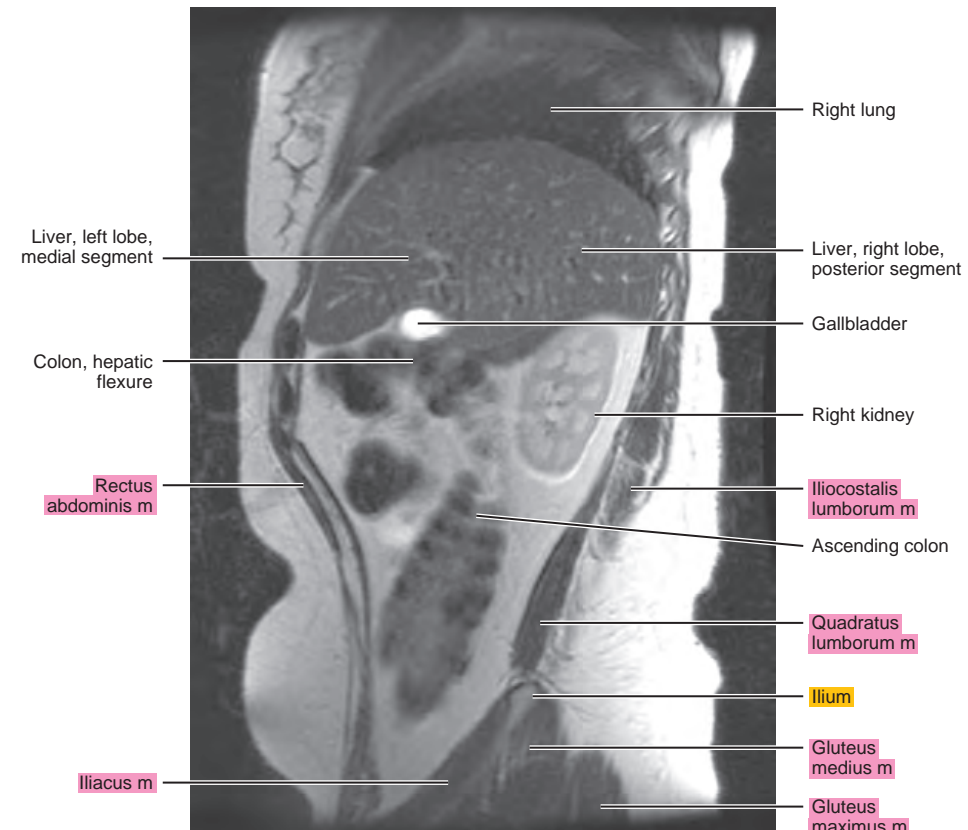
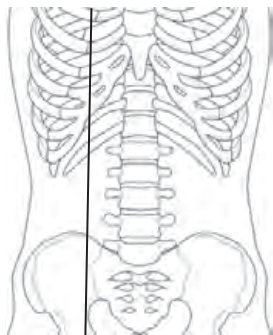


Figure 21.2.16



CORONAL

Figure 21.3.1

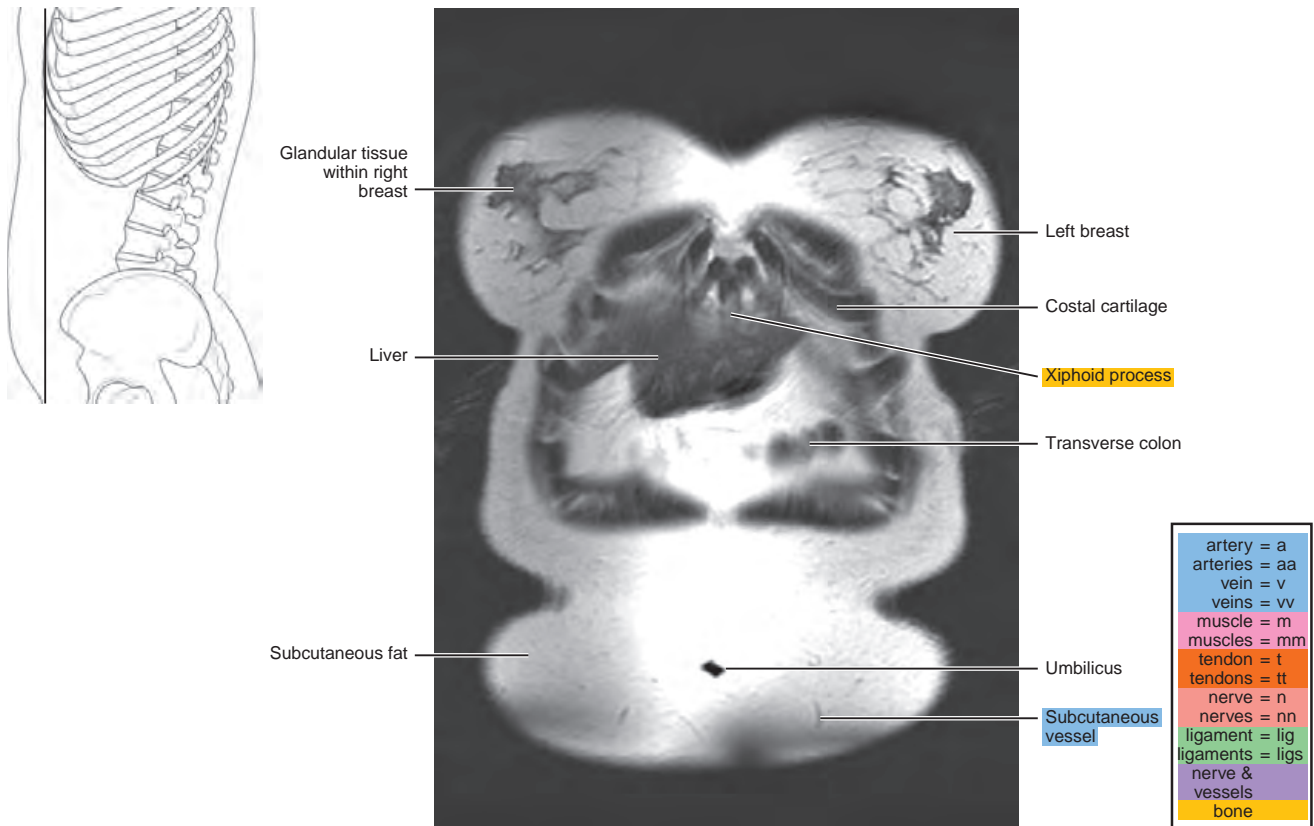


Figure 21.3.2

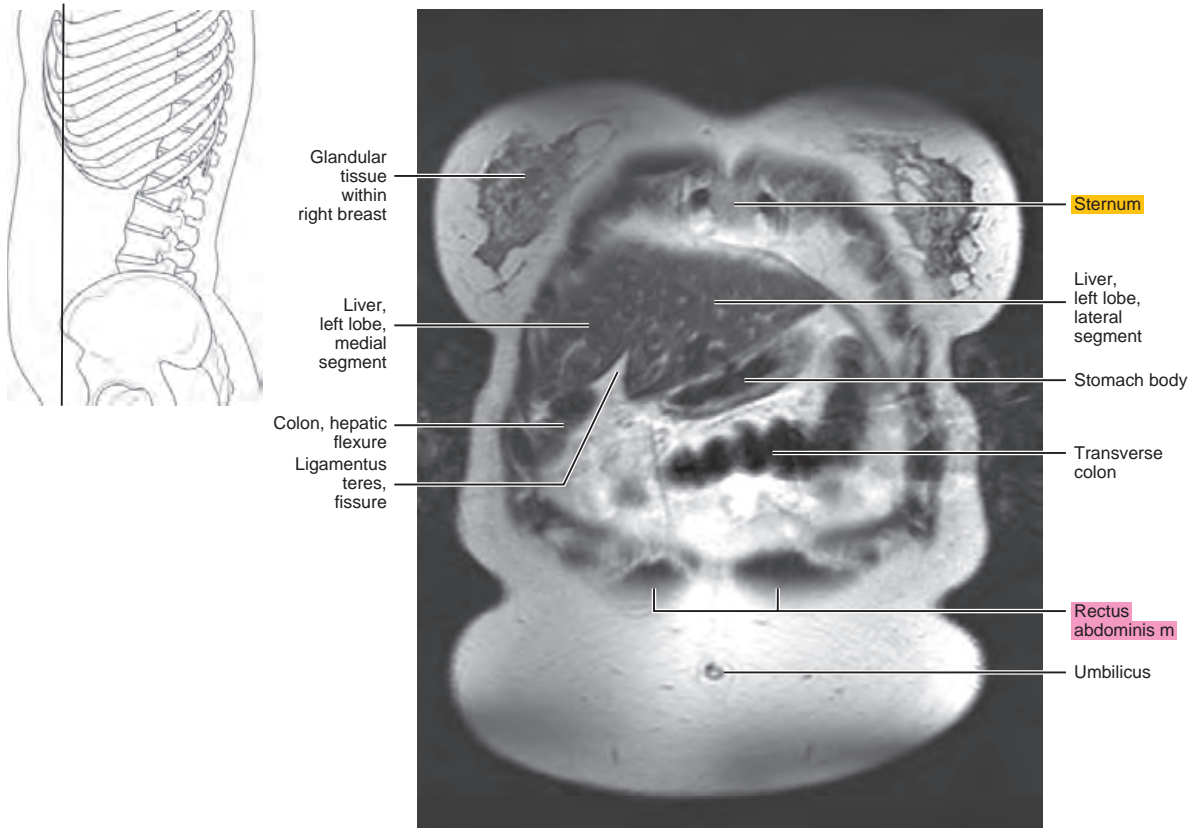


Figure 21.3.3

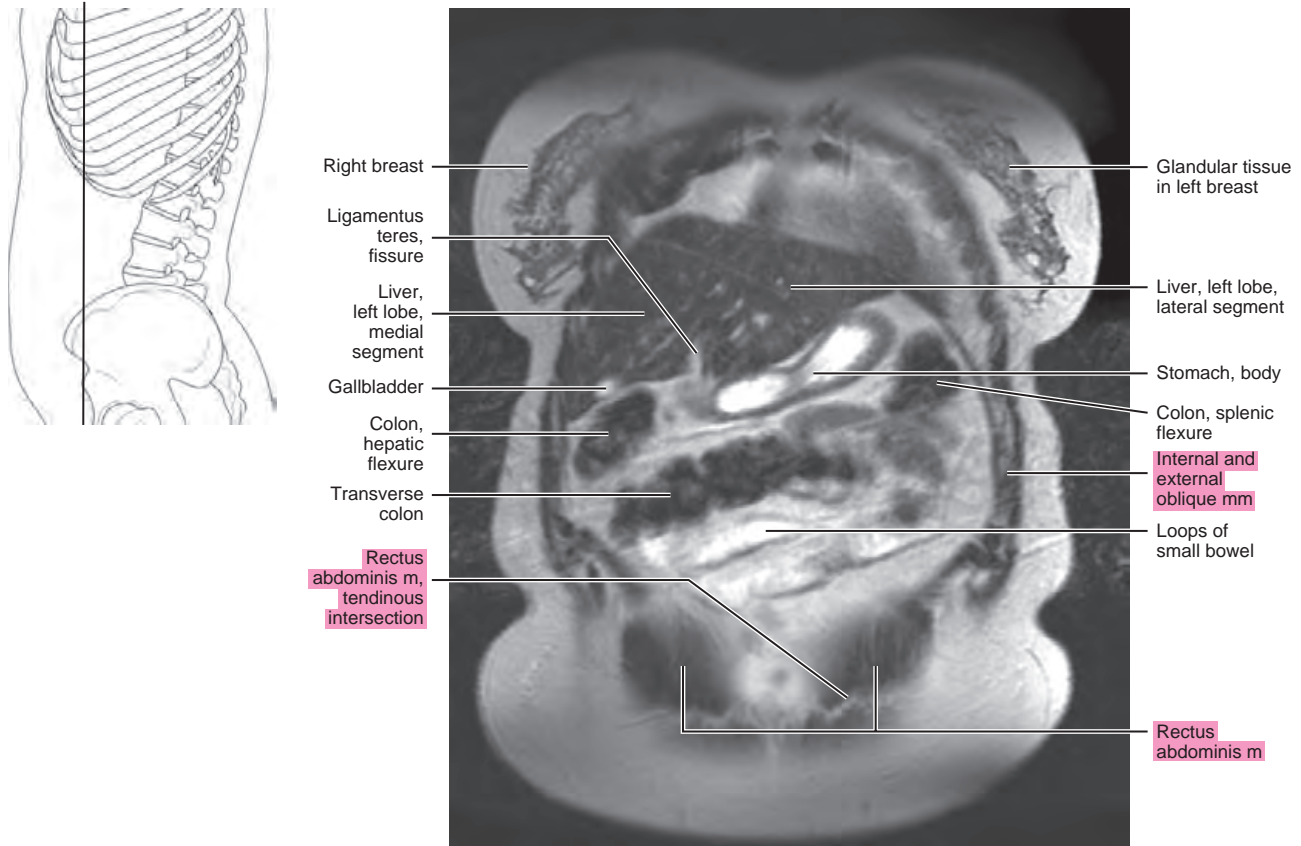


Figure 21.3.4

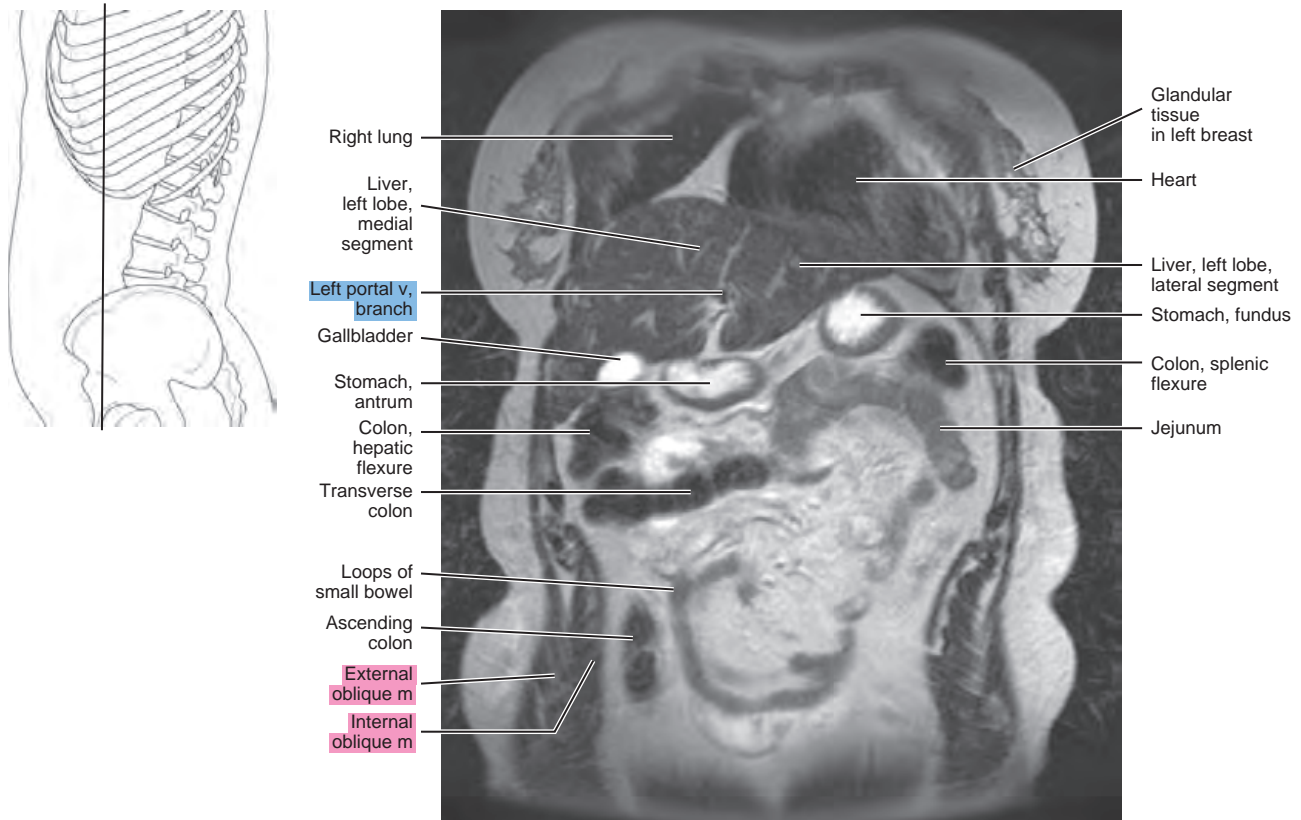


Figure 21.3.5

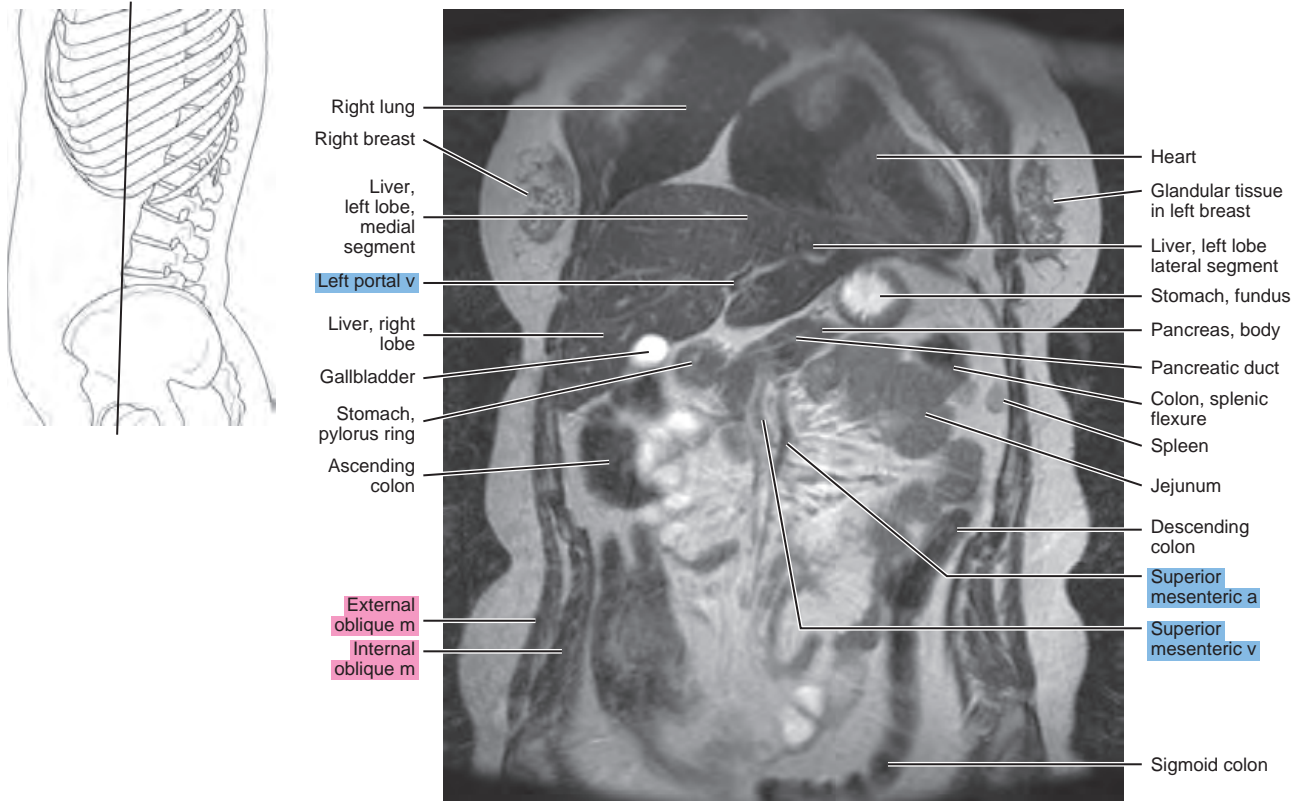


Figure 21.3.6

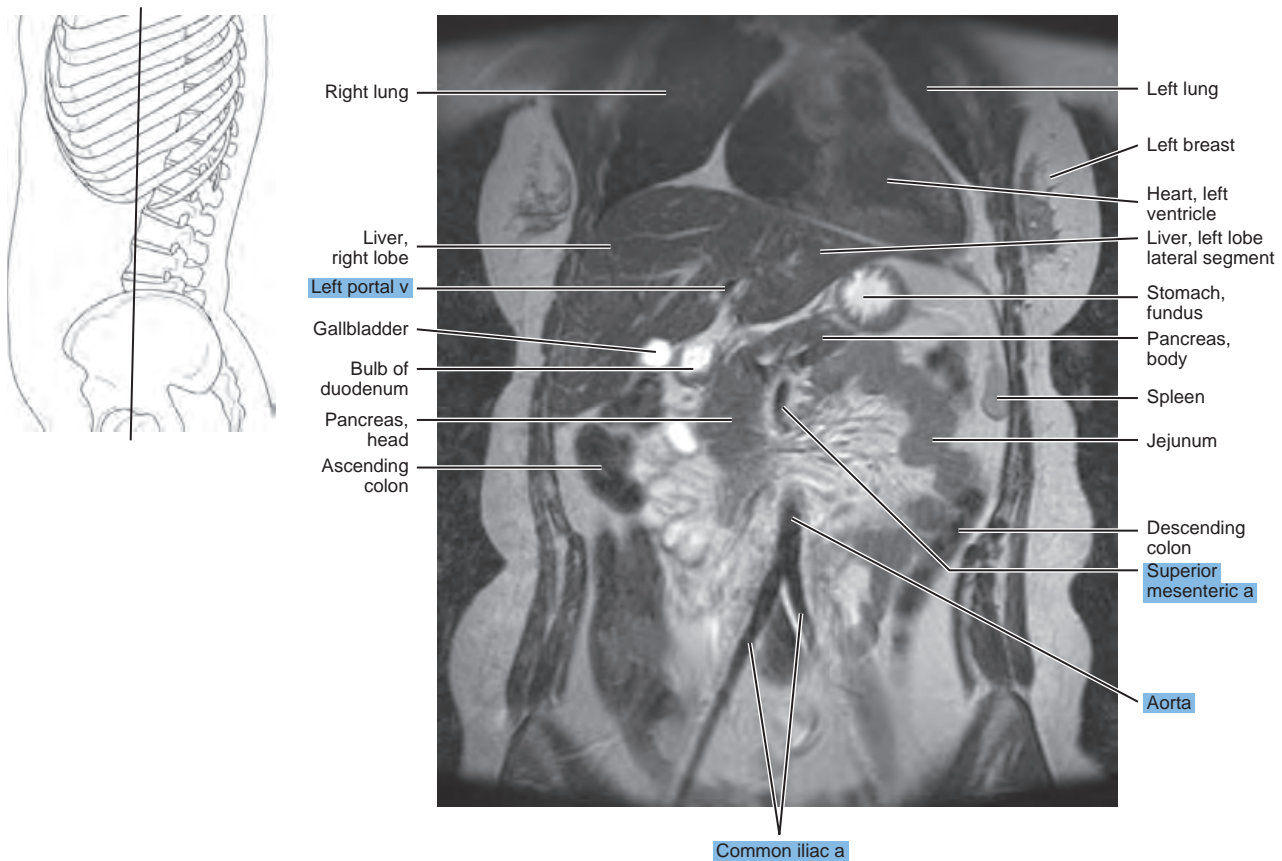


Figure 21.3.7

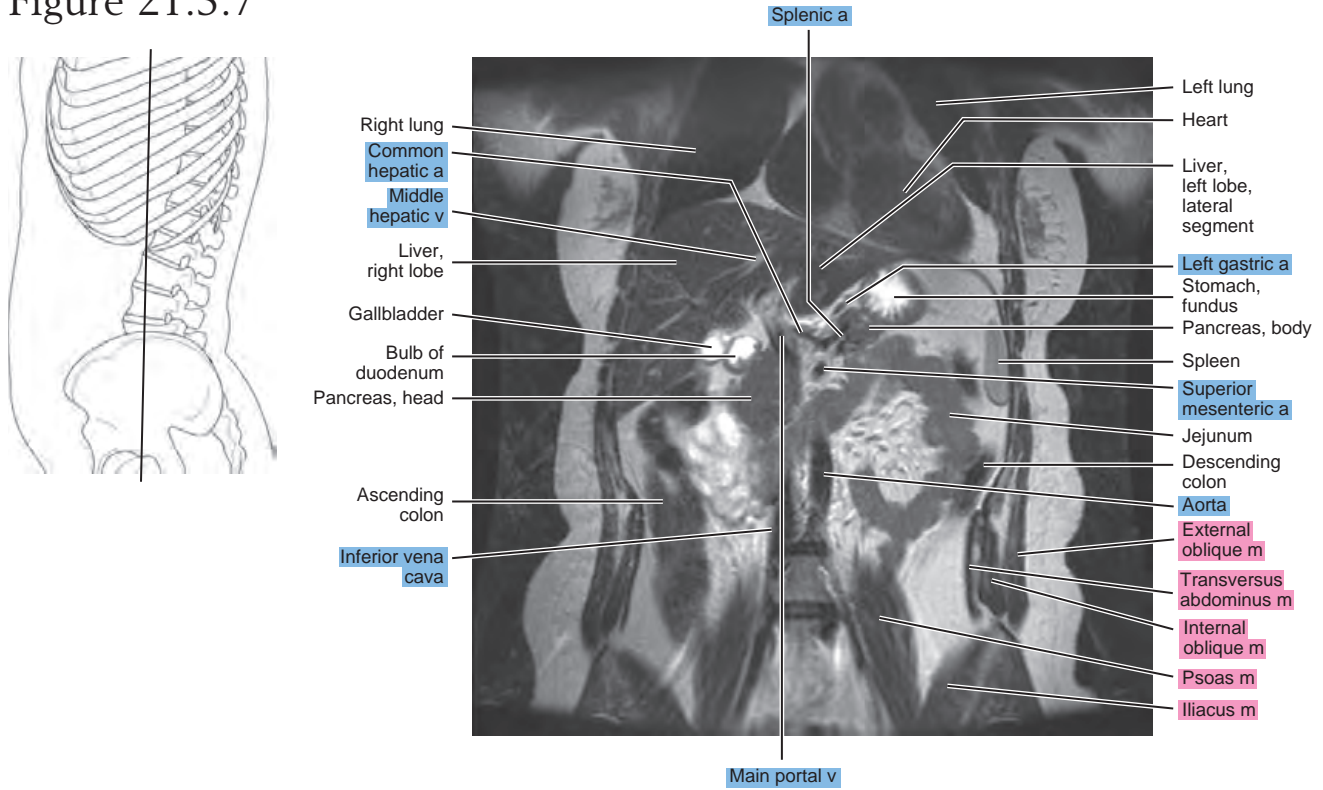


Figure 21.3.8

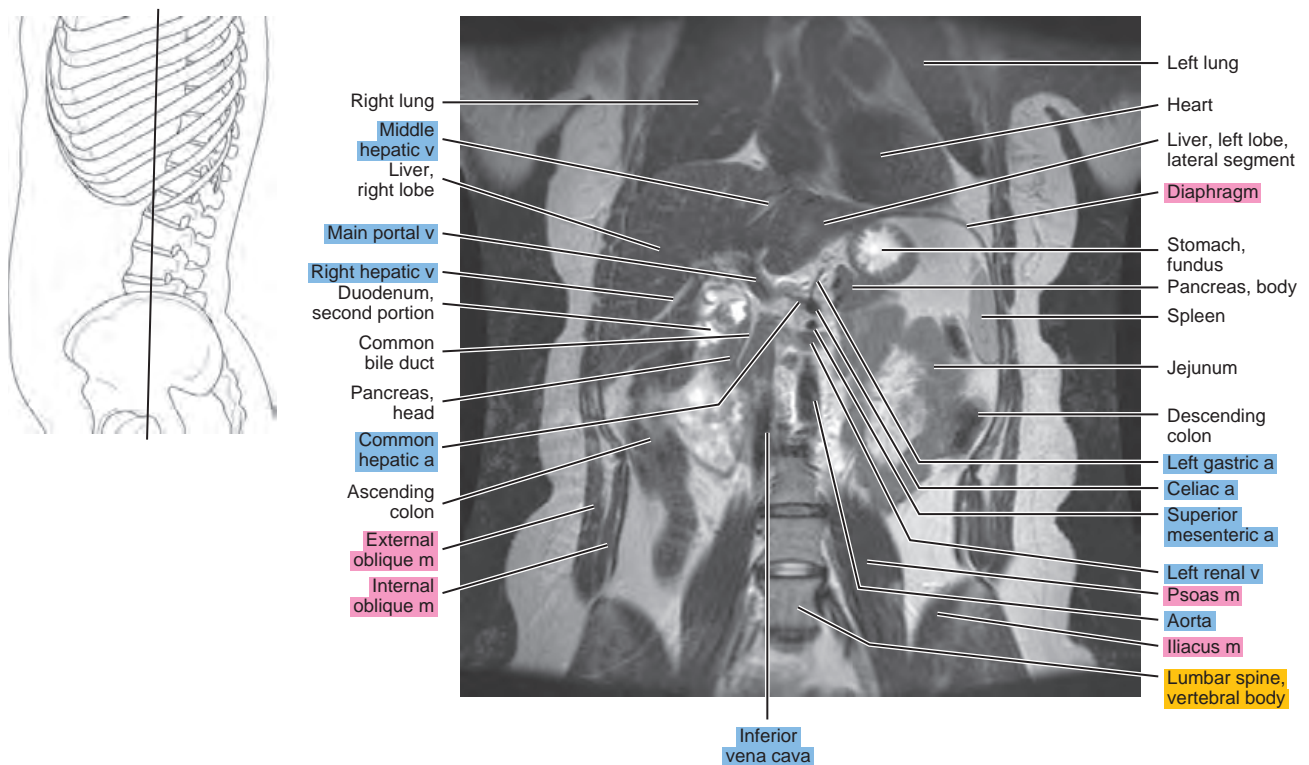


Figure 21.3.9

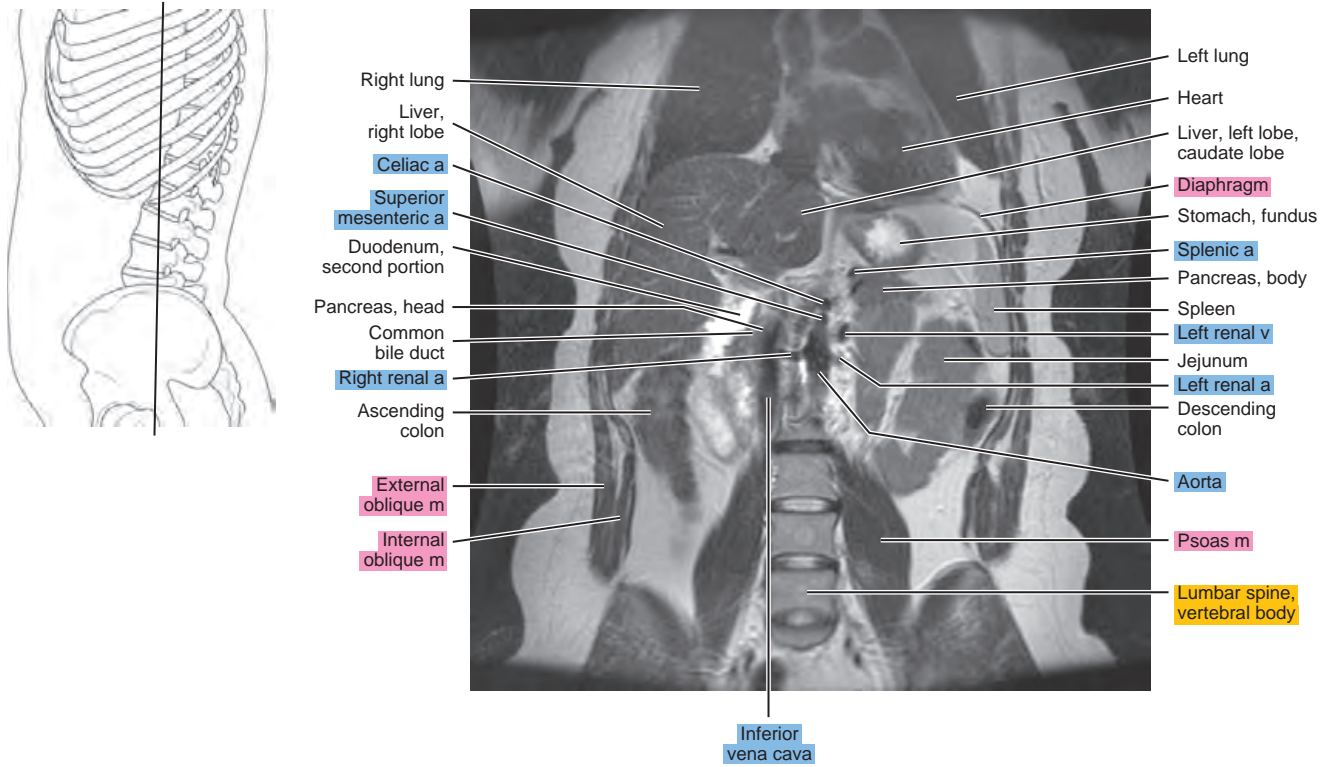


Figure 21.3.10

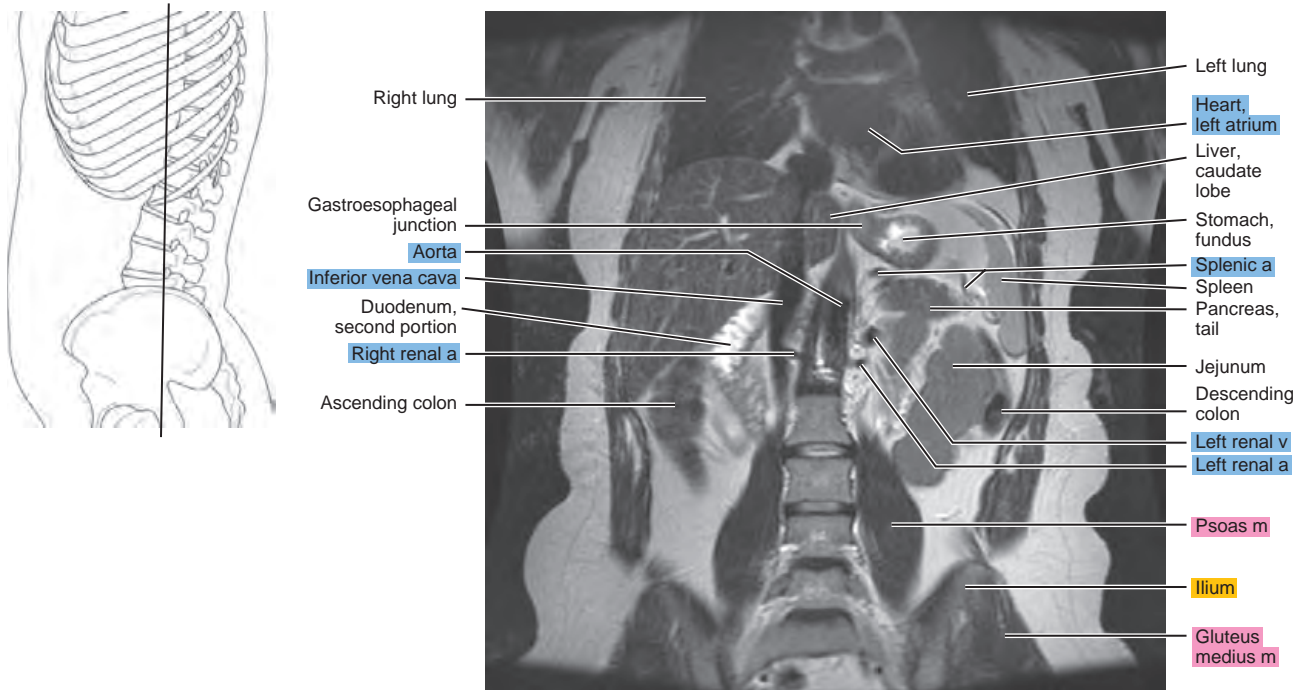


Figure 21.3.11

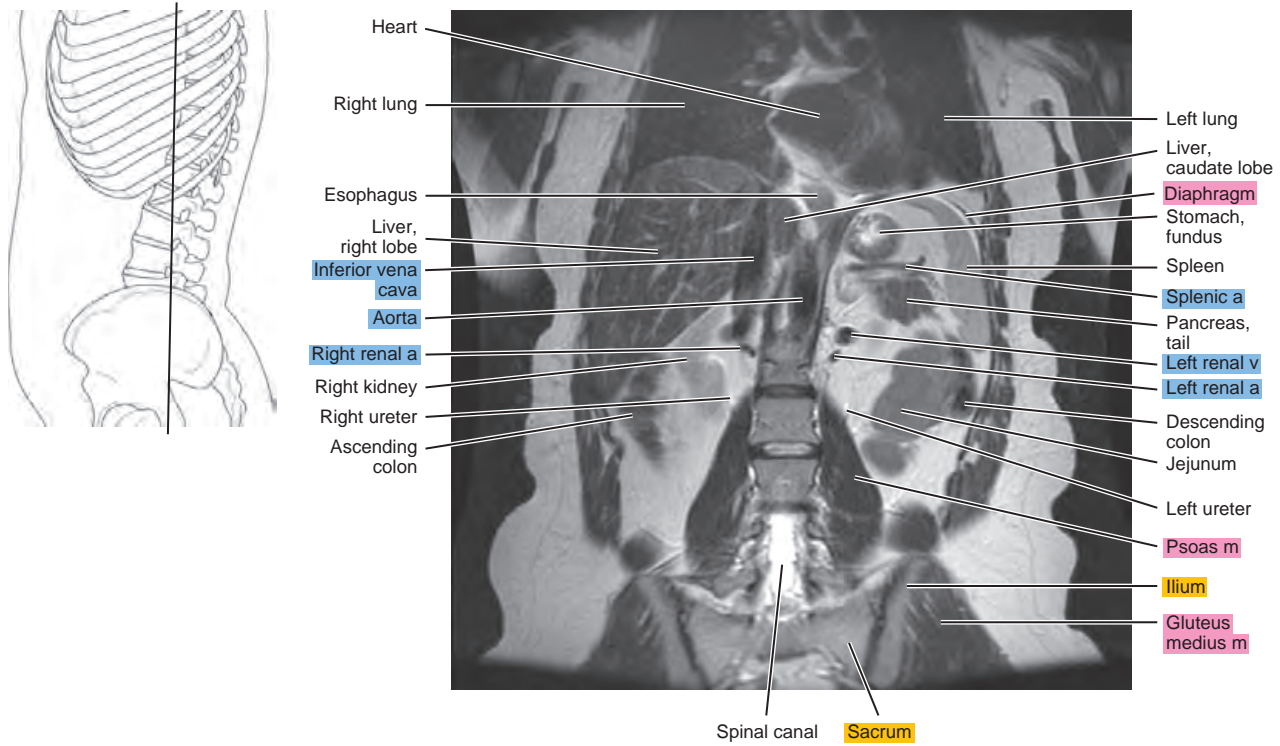


Figure 21.3.12

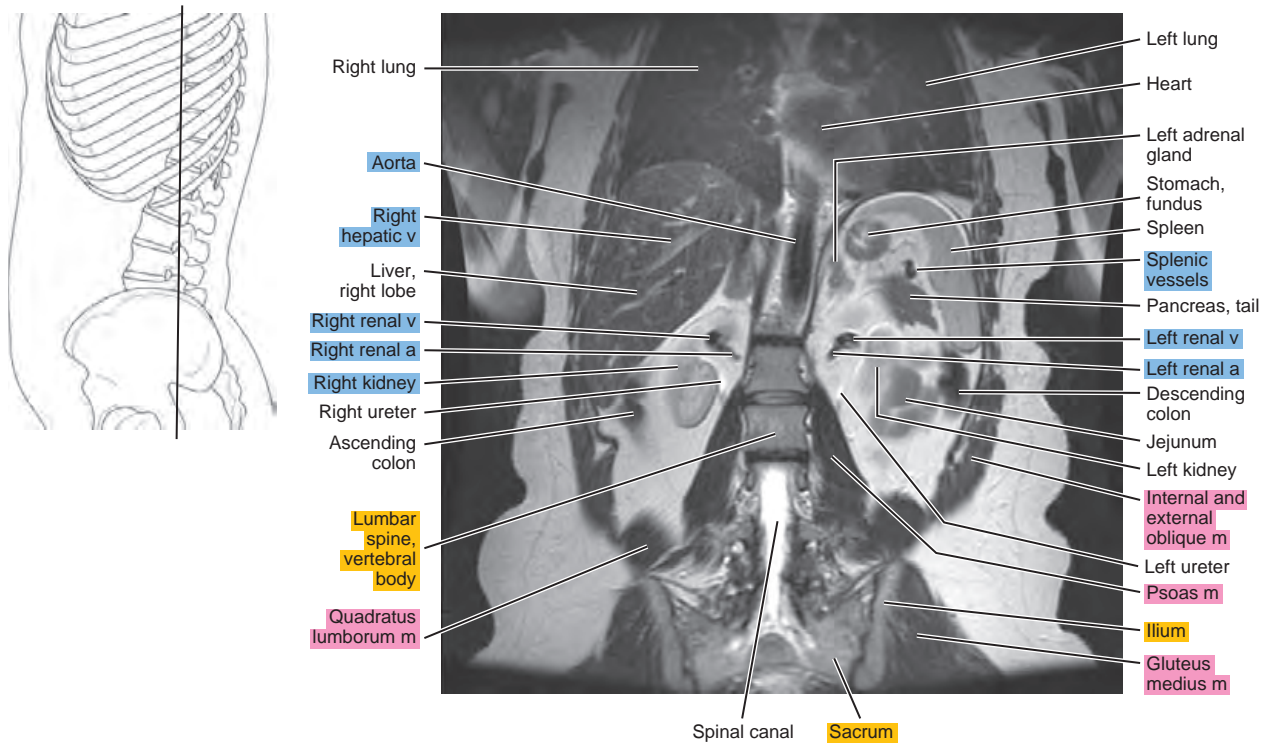


Figure 21.3.13

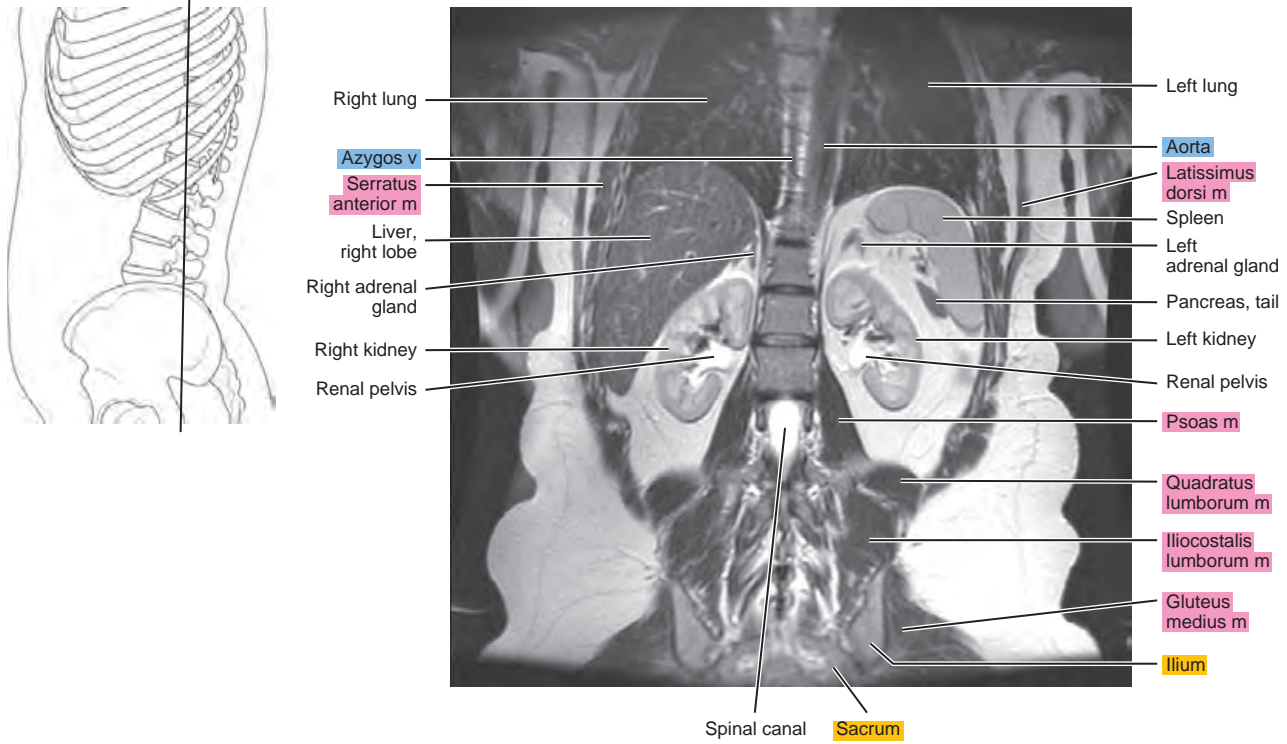


Figure 21.3.14

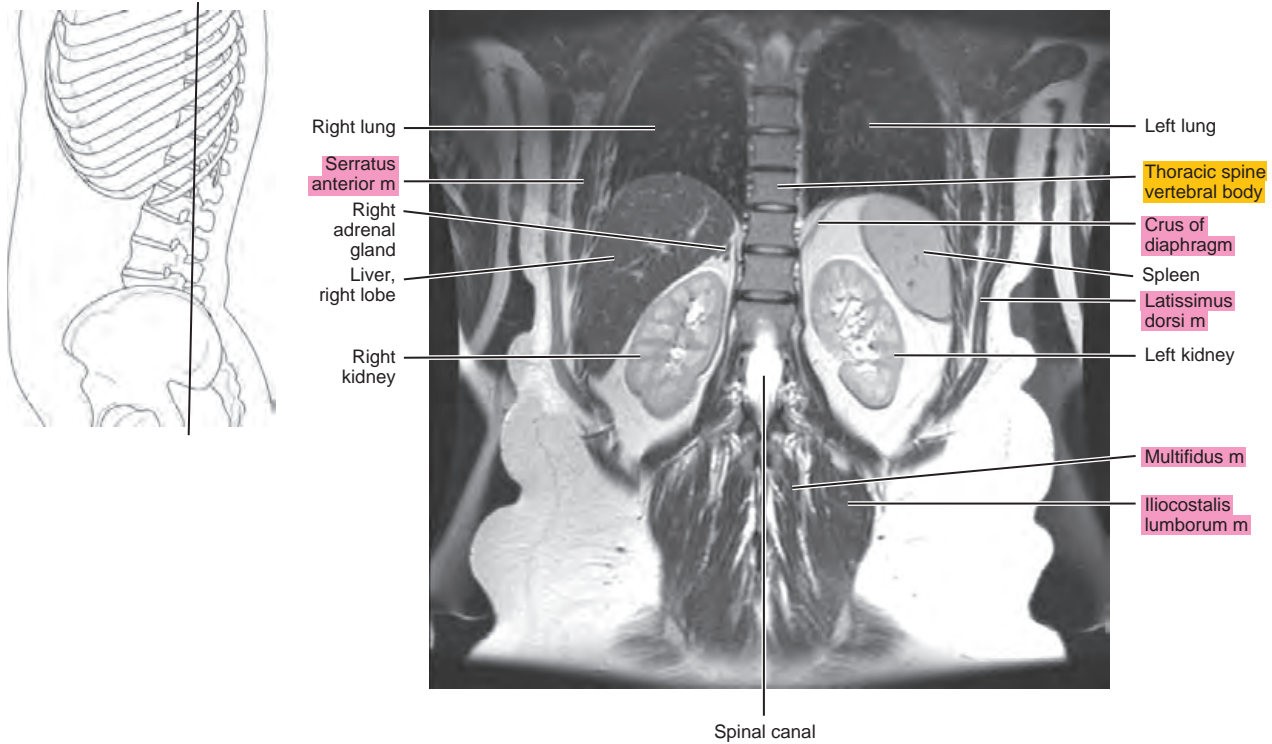


Figure 21.3.15

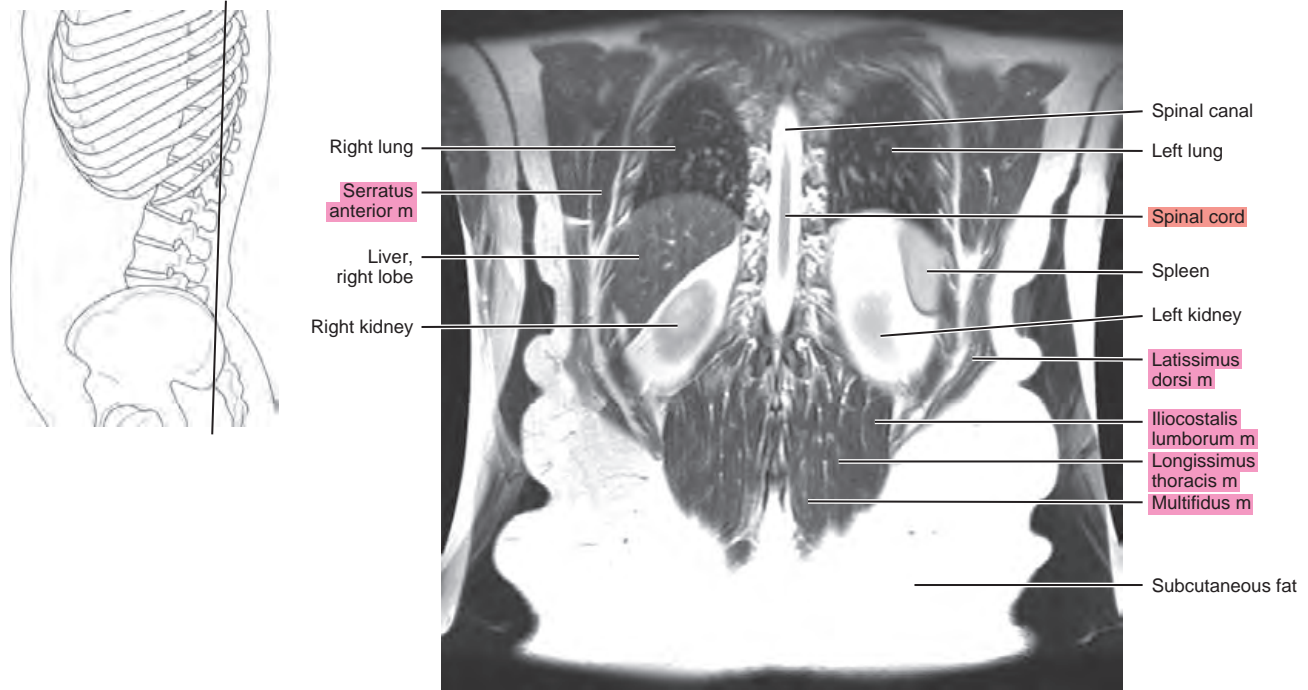
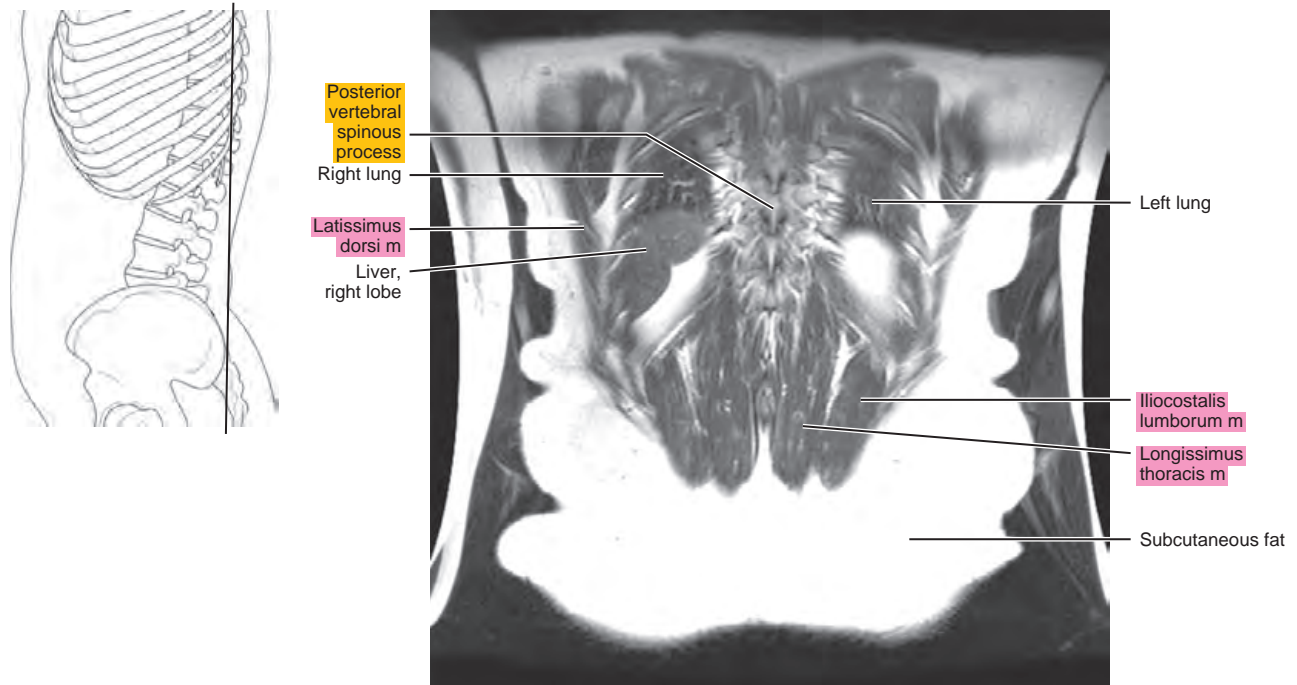


Figure 21.3.16



This page intentionally left blank

Section
VI

Pelvis

This page intentionally left blank

Chapter
22

CT of the Male Pelvis

AXIAL

Figure 22.1.1

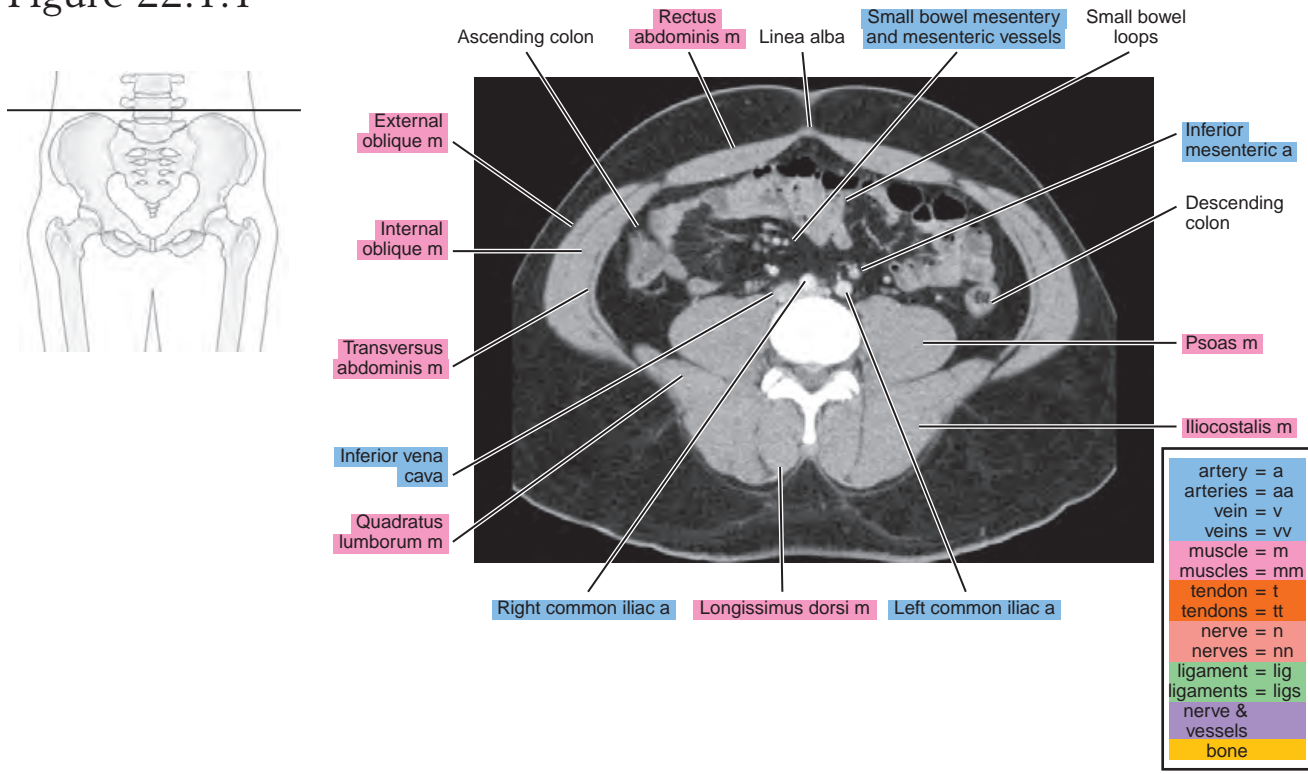


Figure 22.1.2

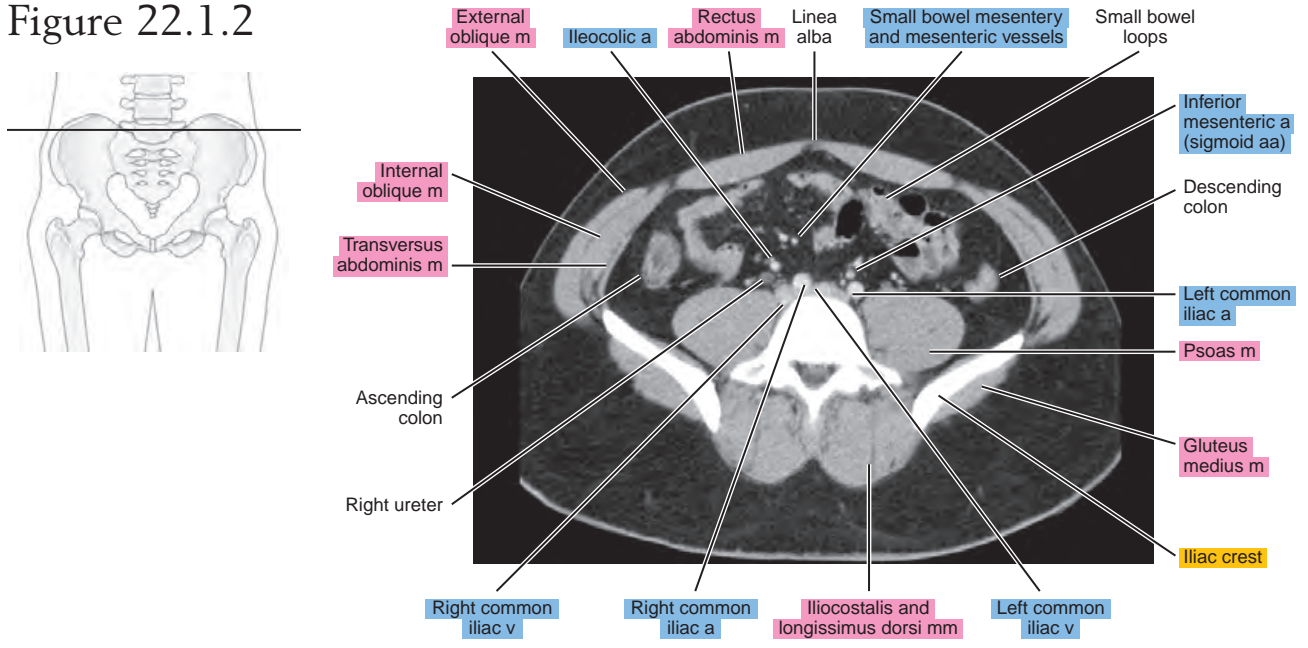


Figure 22.1.3

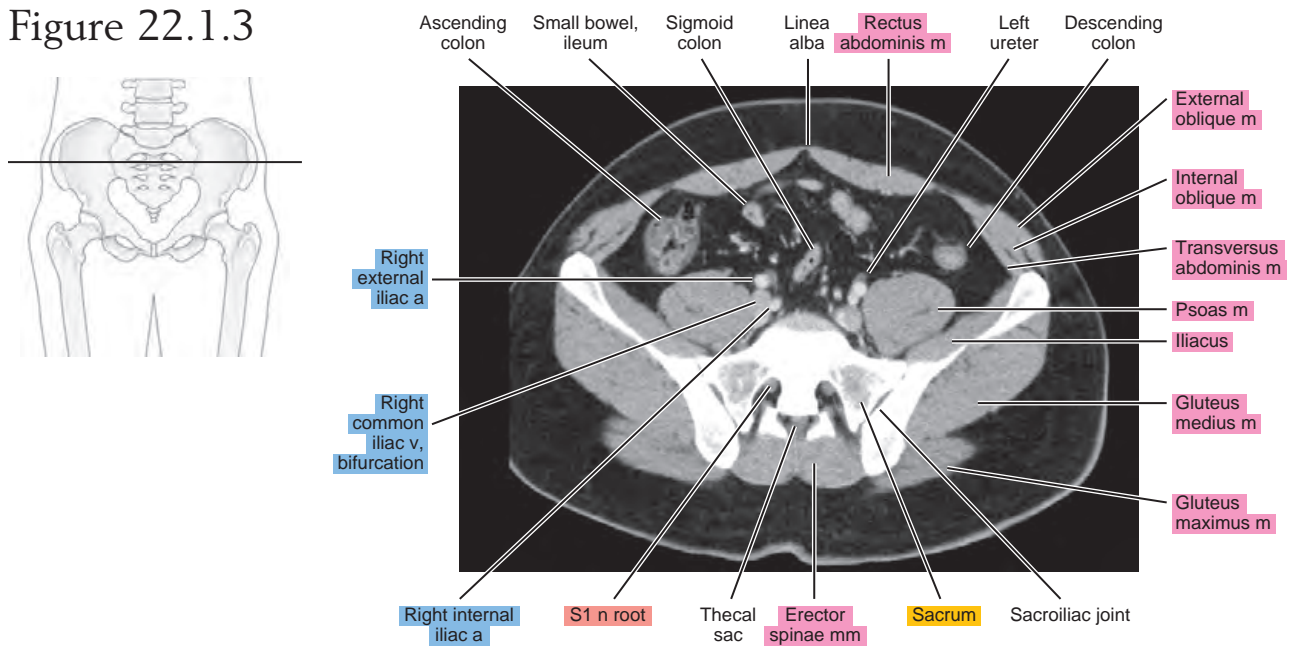


Figure 22.1.4

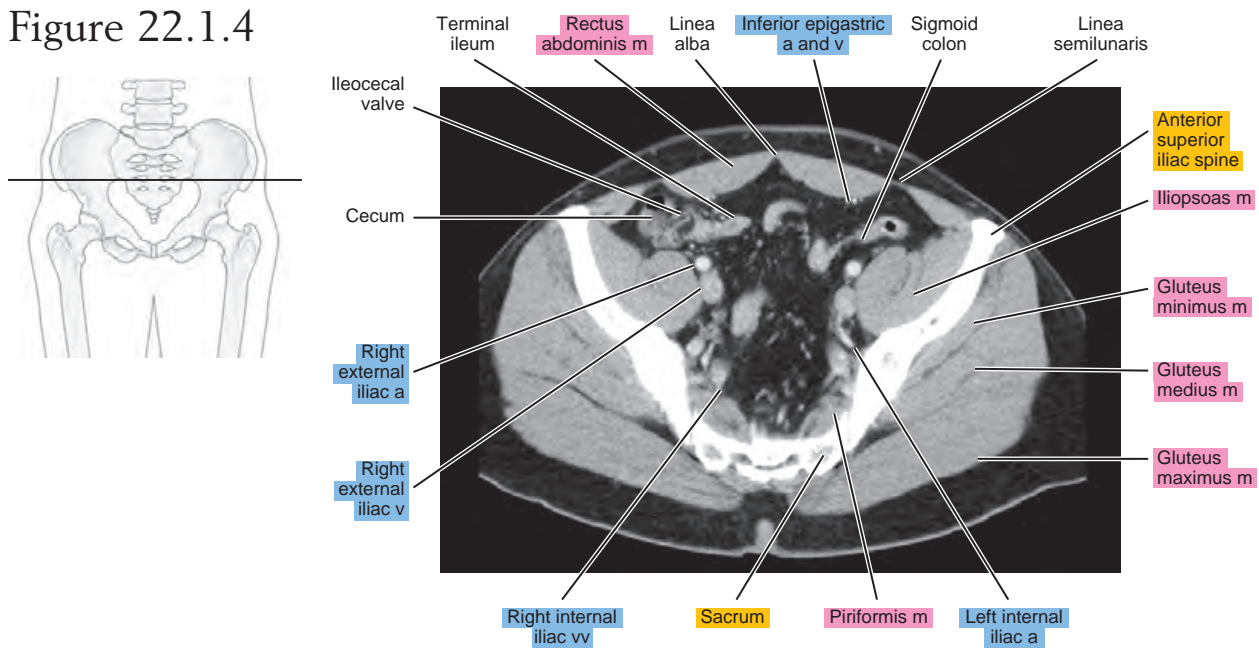


Figure 22.1.5

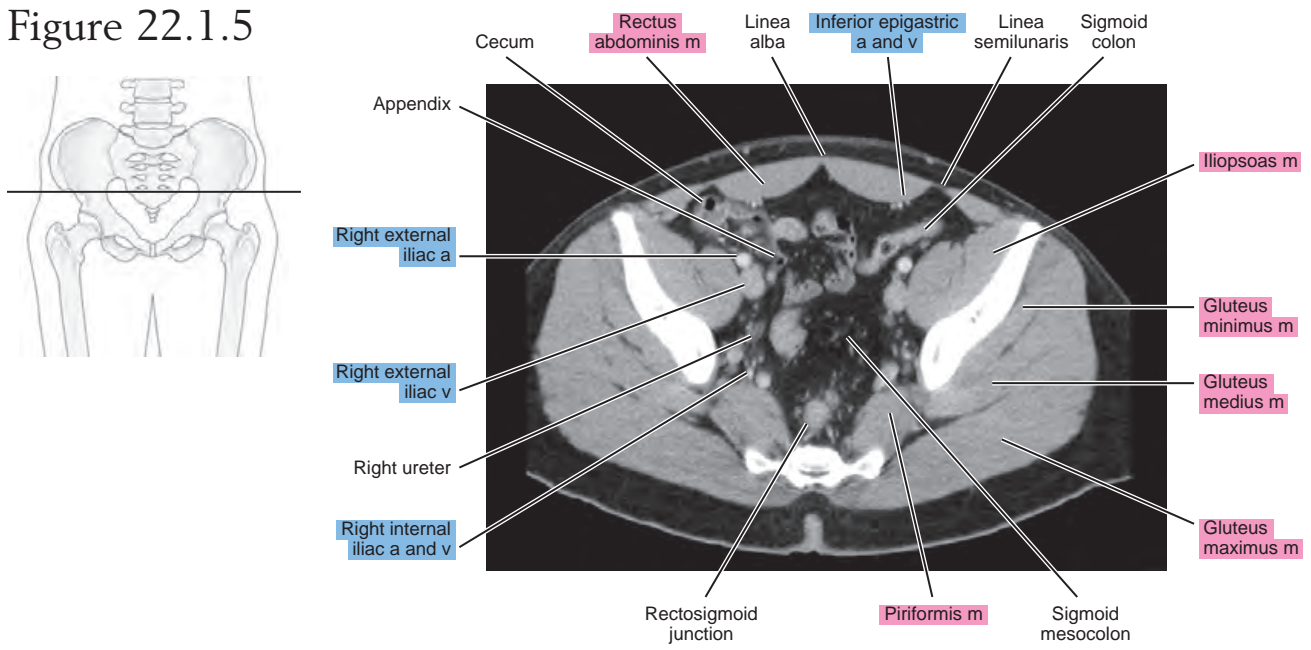


Figure 22.1.6

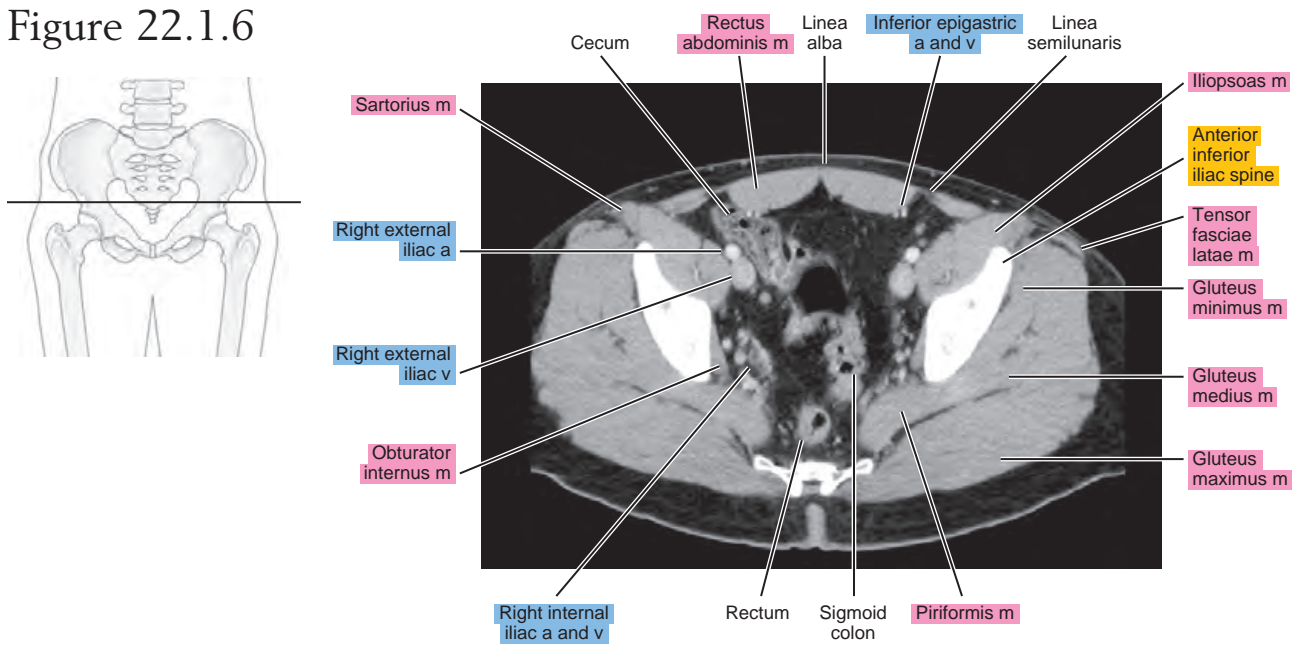


Figure 22.1.7

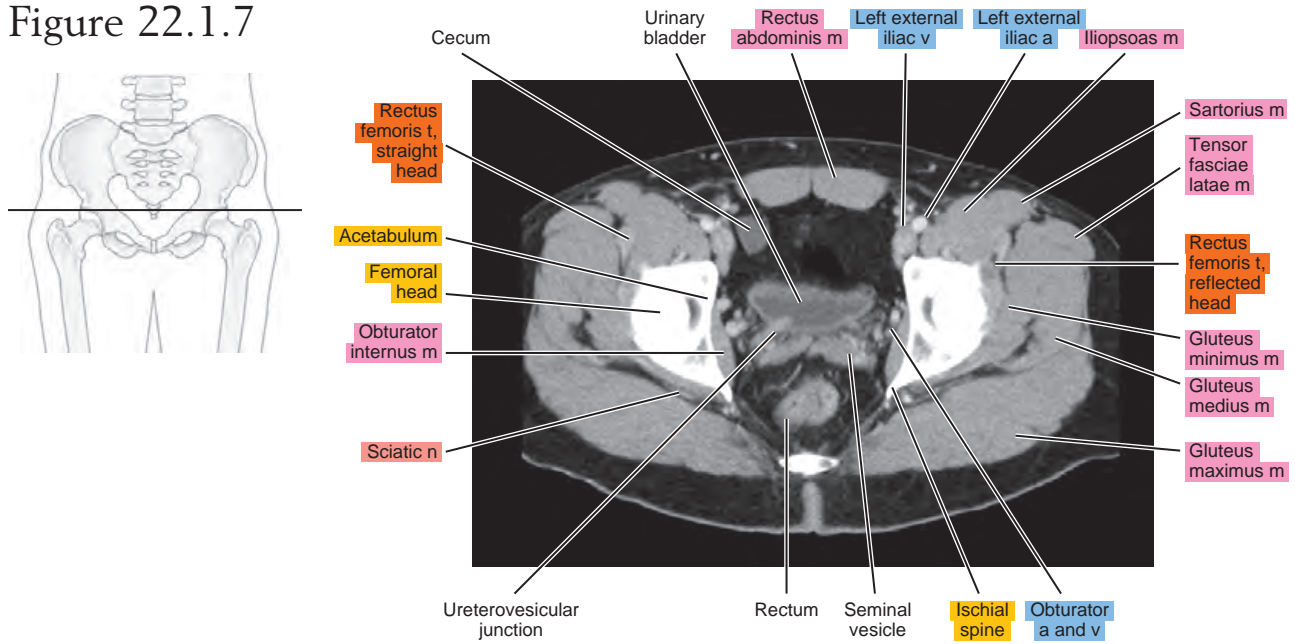


Figure 22.1.8

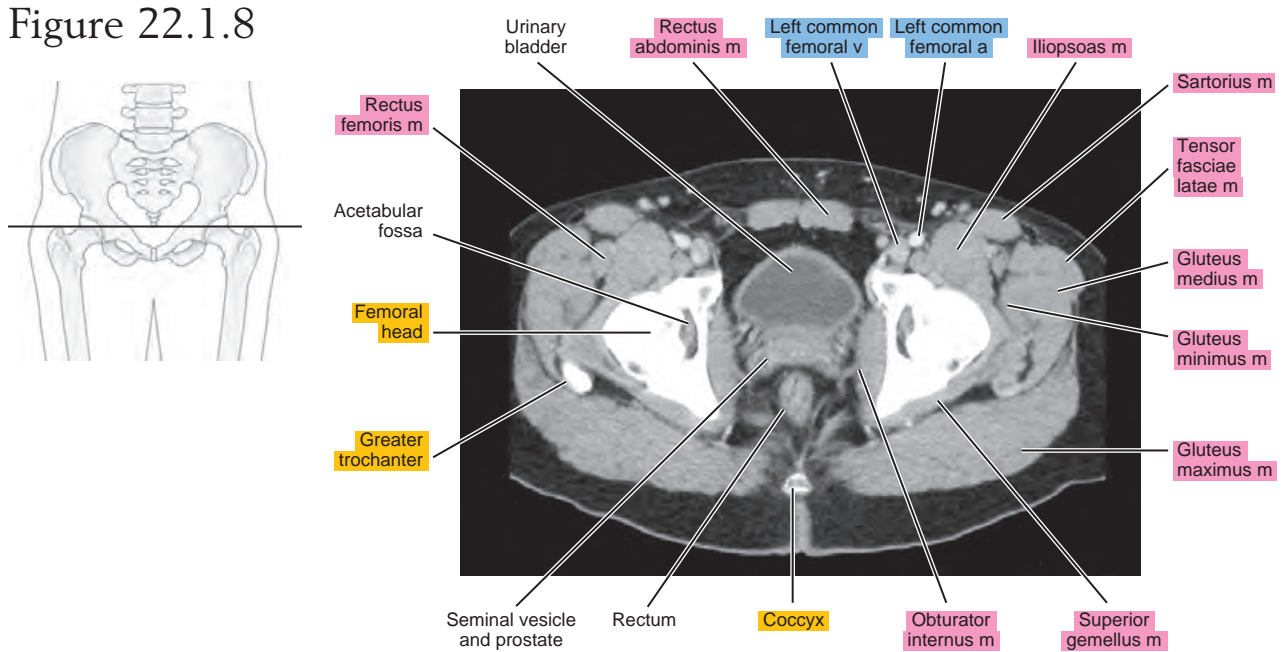


Figure 22.1.9

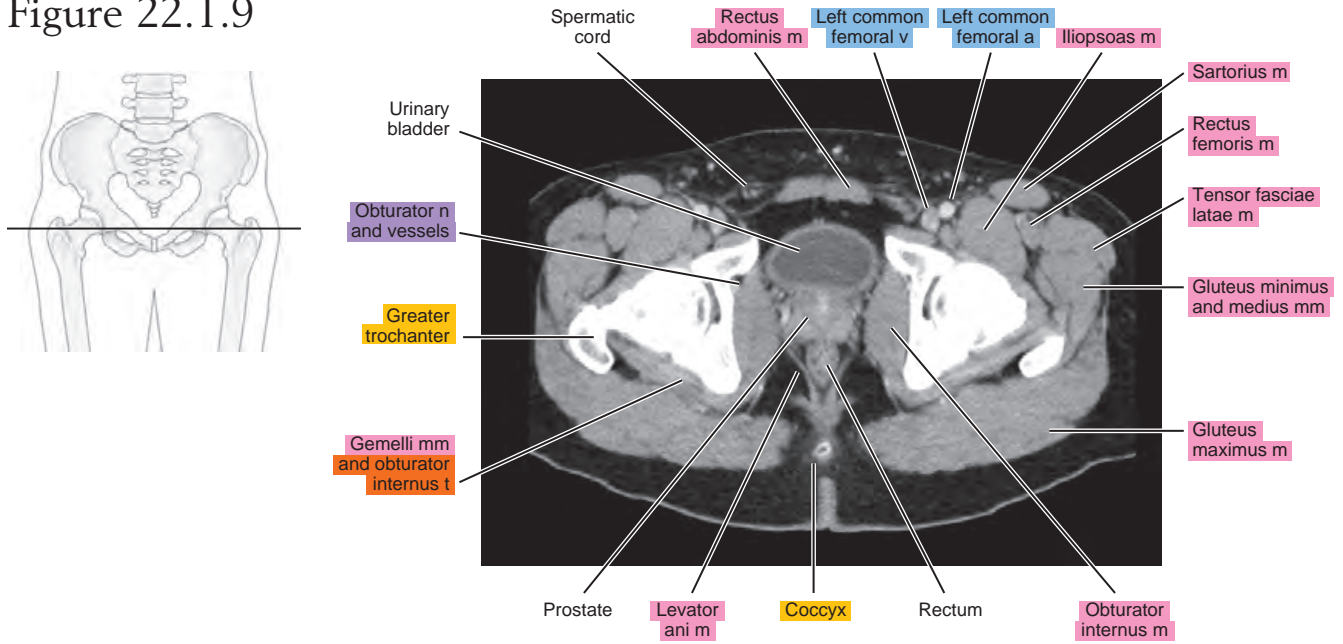


Figure 22.1.10

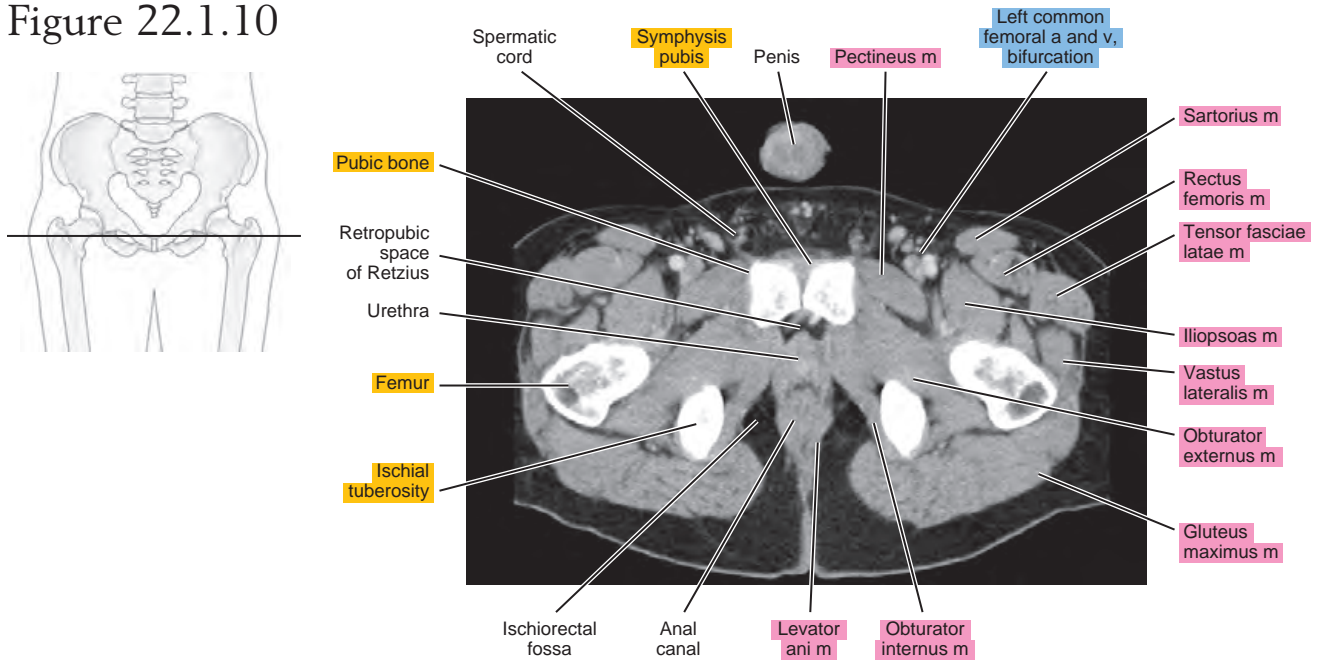


Figure 22.1.11

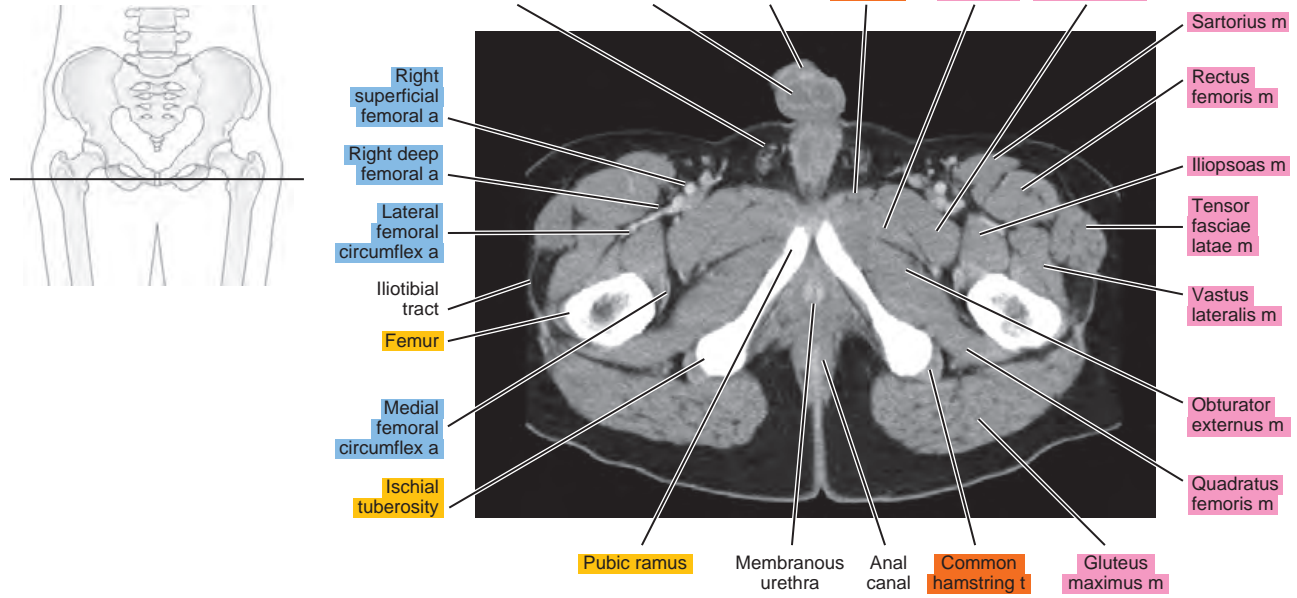
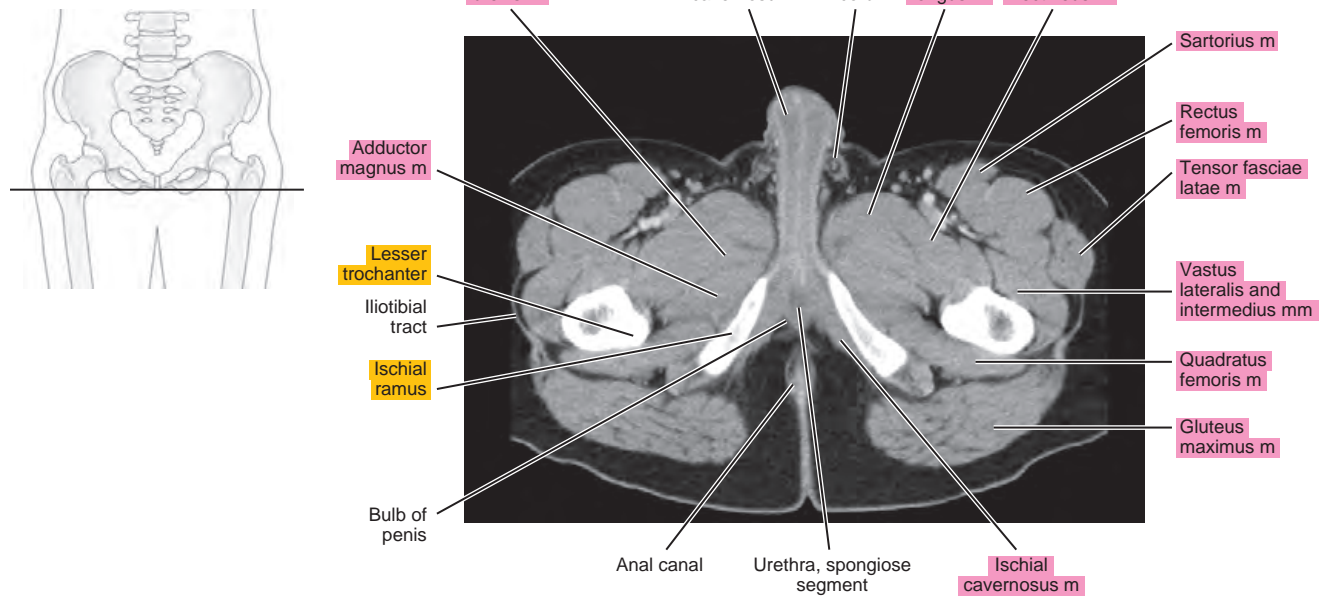


Figure 22.1.12



SAGITTAL

Figure 22.2.1

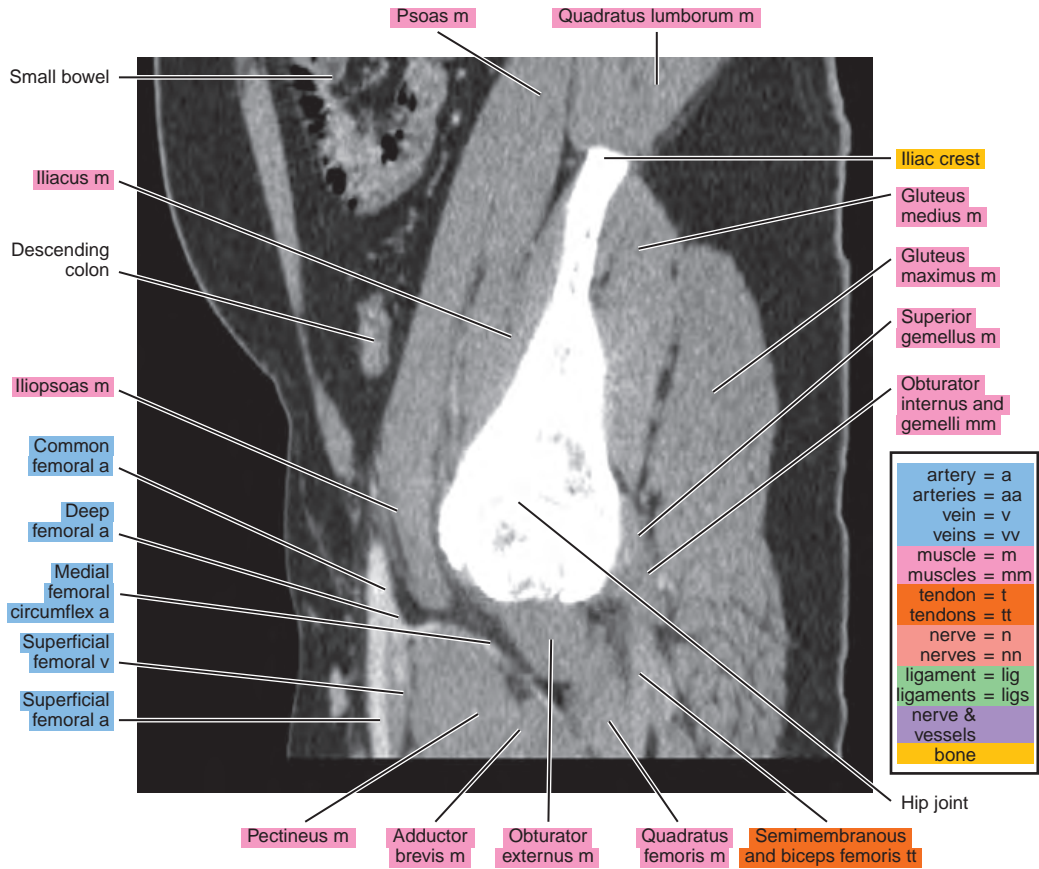
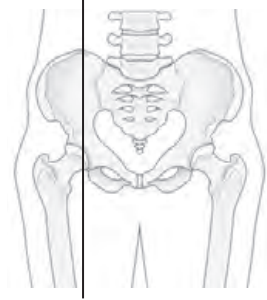


Figure 22.2.2

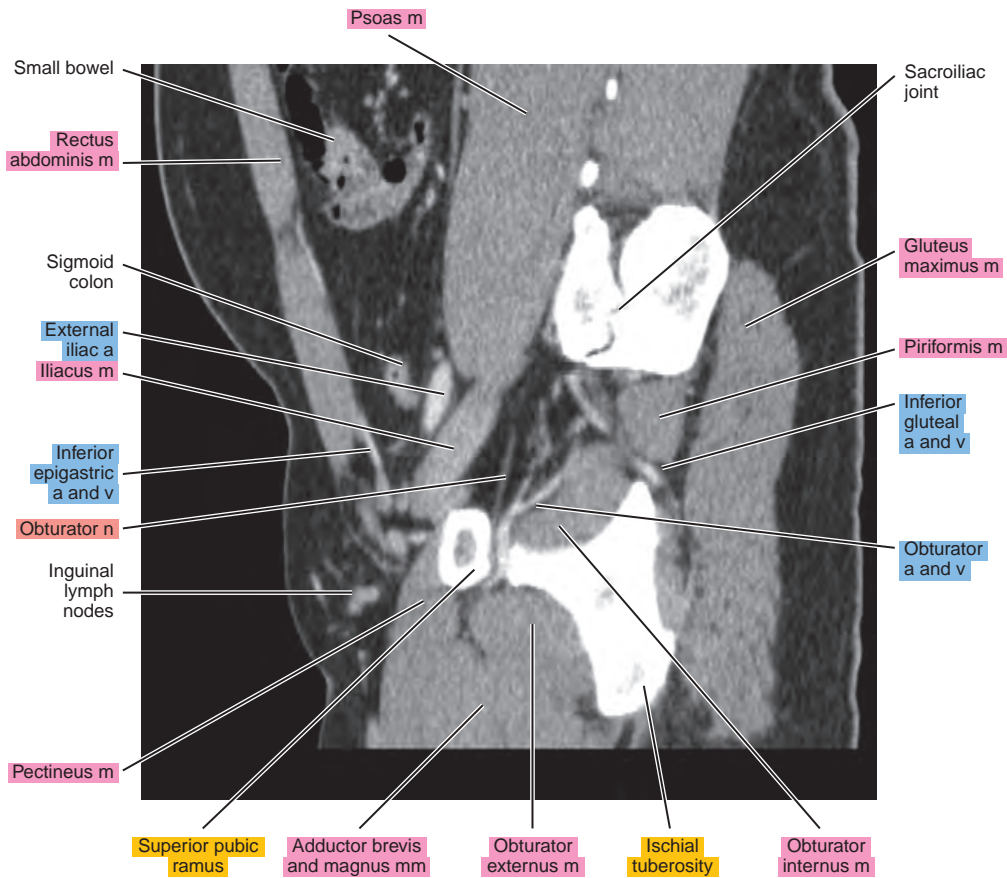
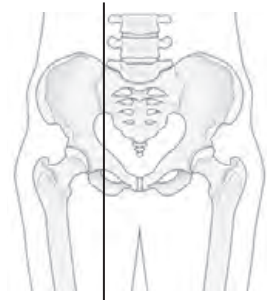


Figure 22.2.3

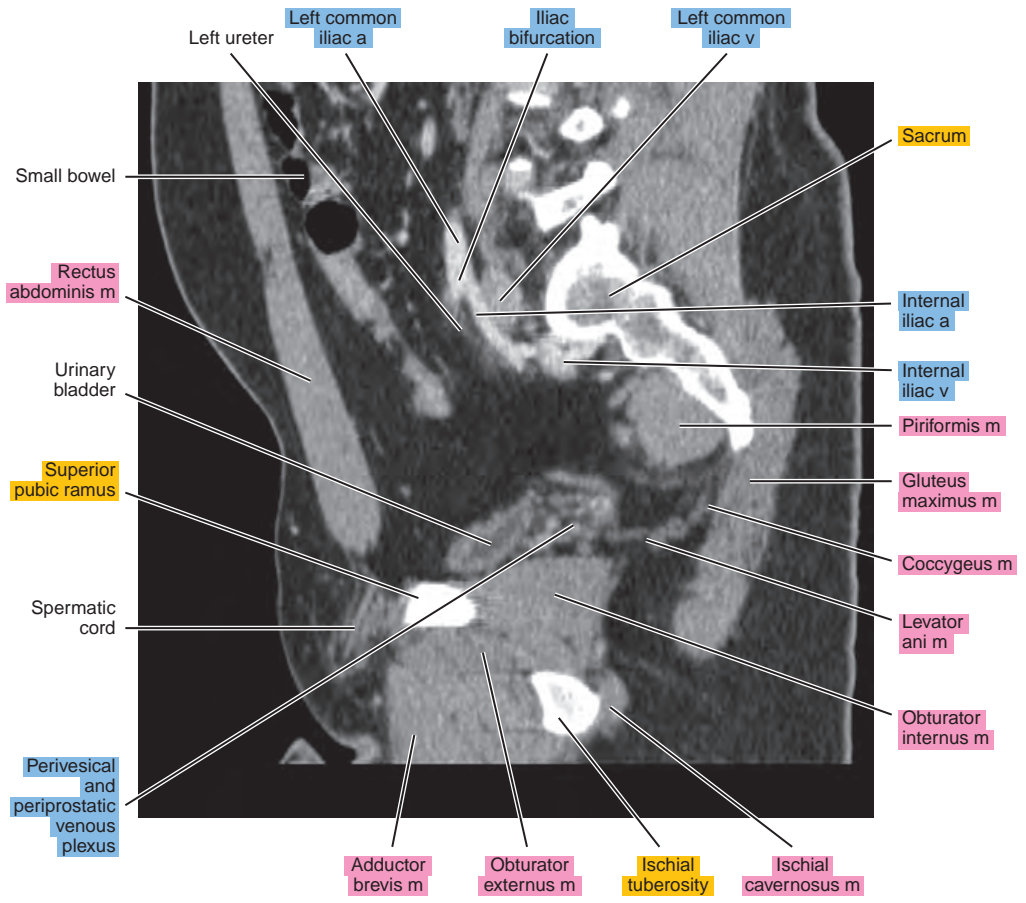
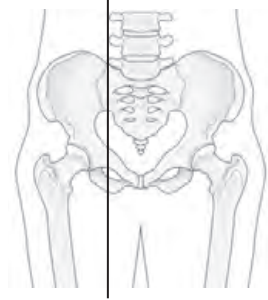


Figure 22.2.4

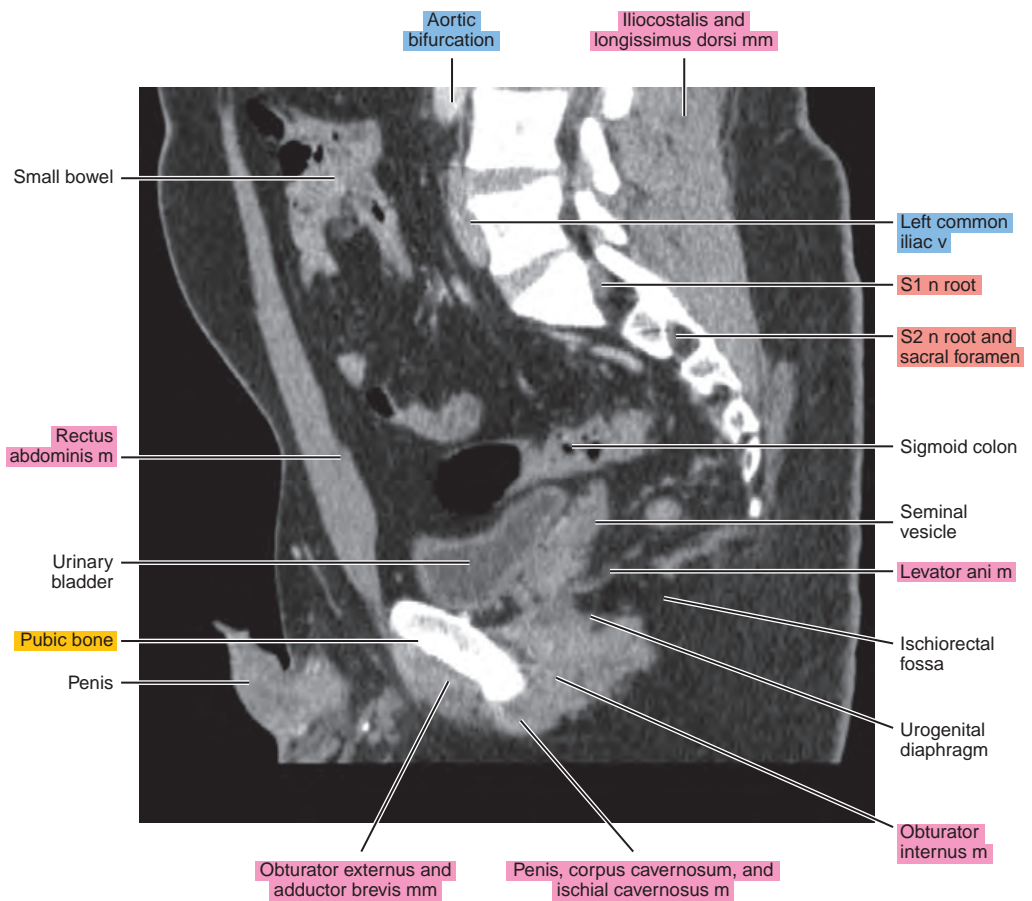
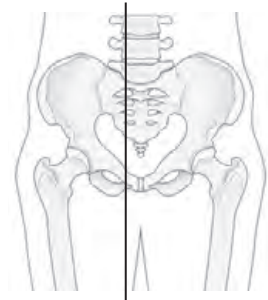
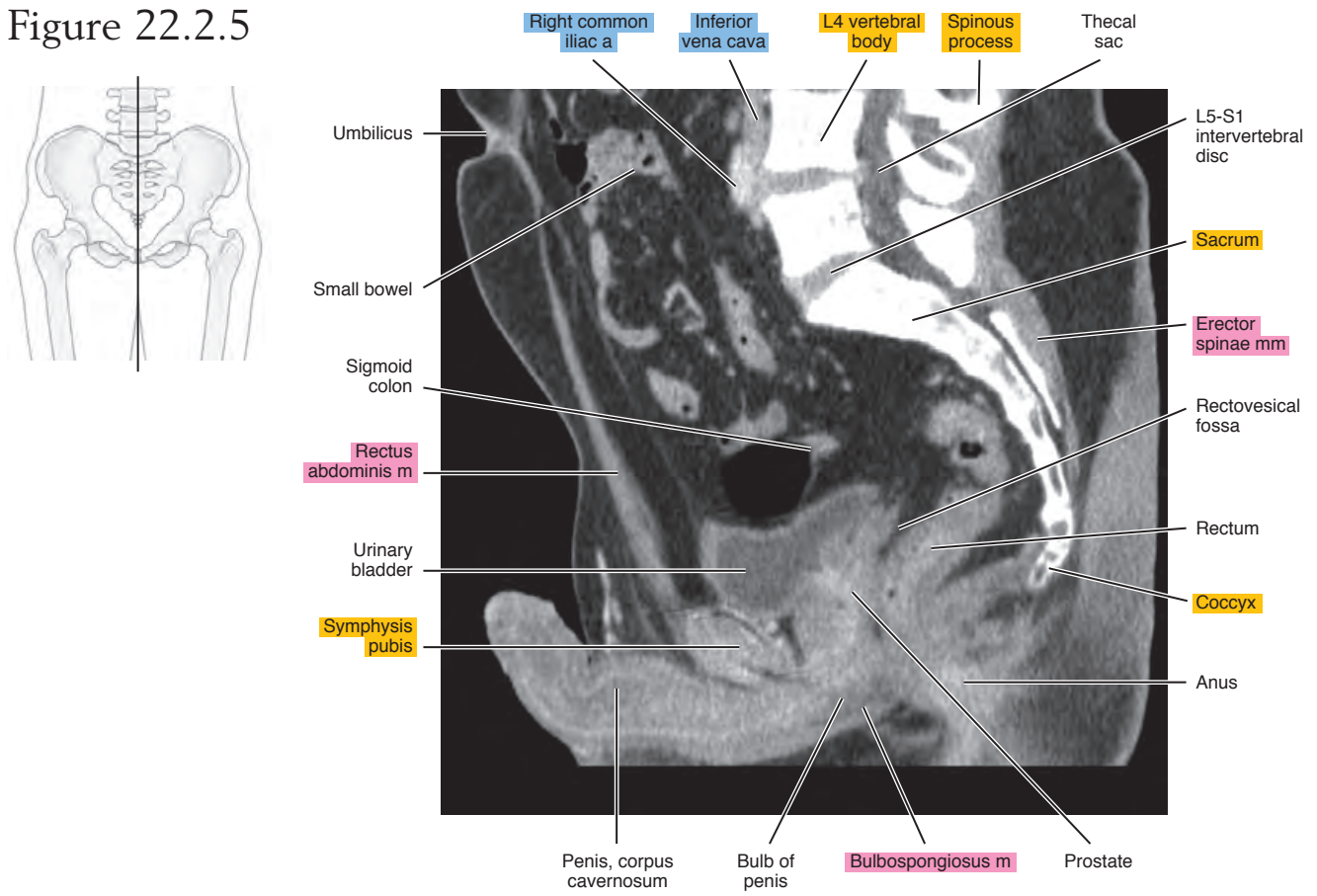


Figure 22.2.5



CORONAL

Figure 22.3.1

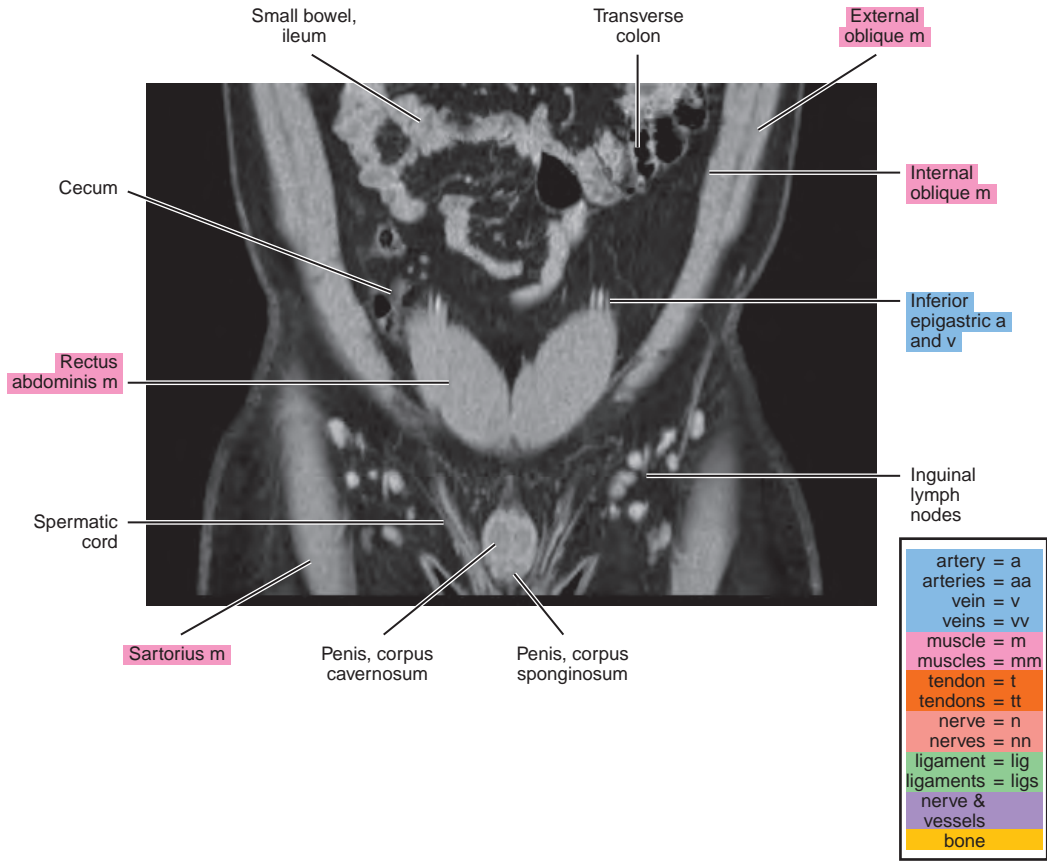
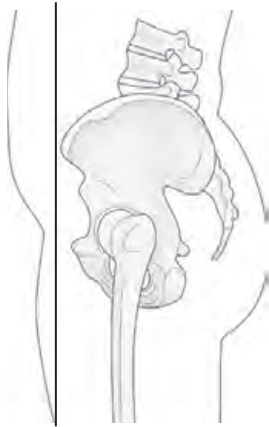

Figure 22.3.2

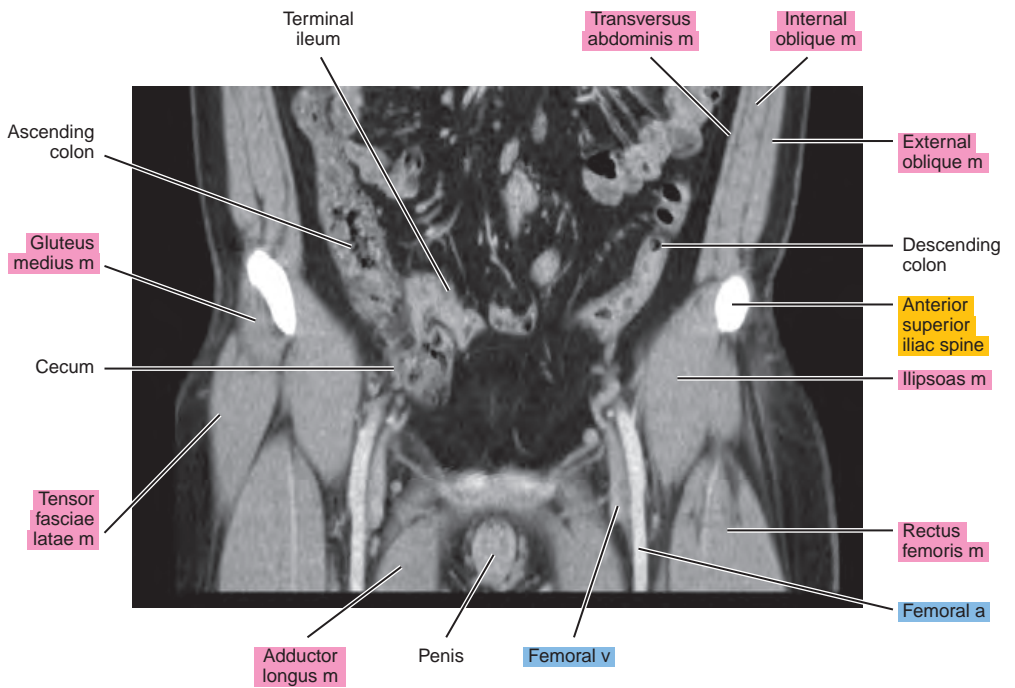
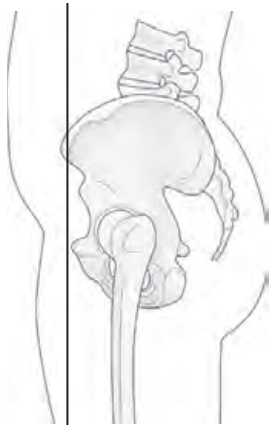


Figure 22.3.3

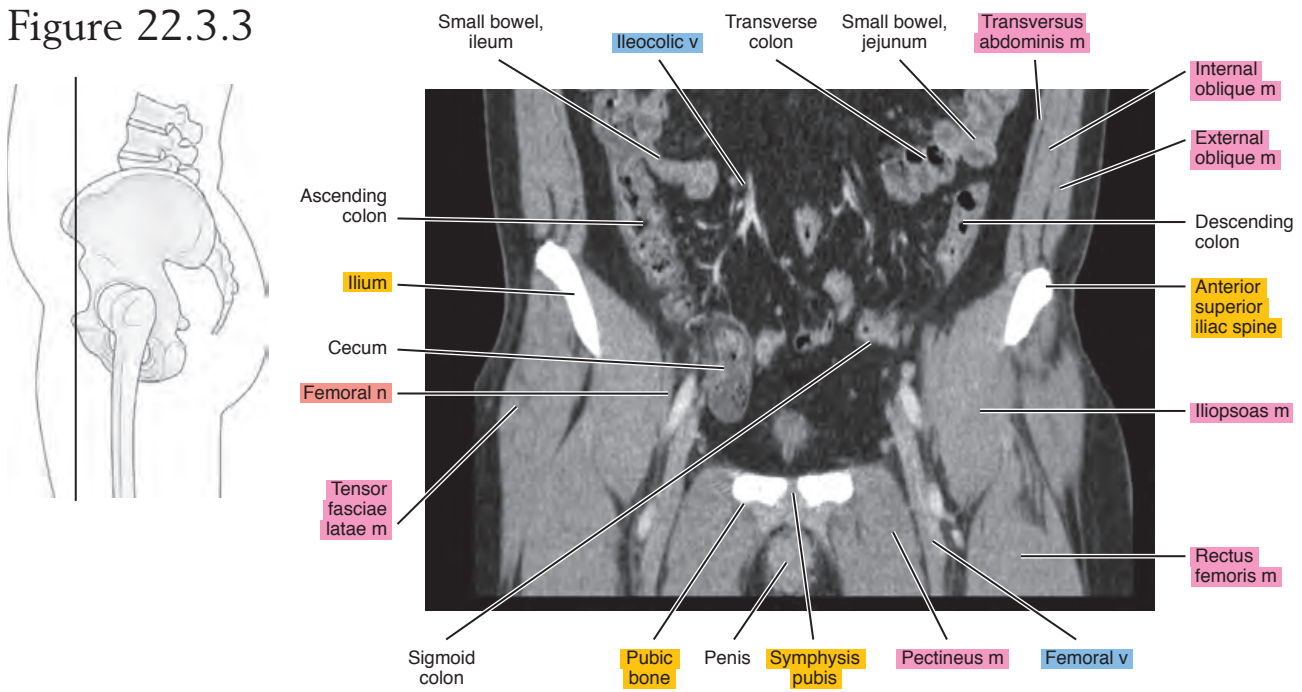


Figure 22.3.4

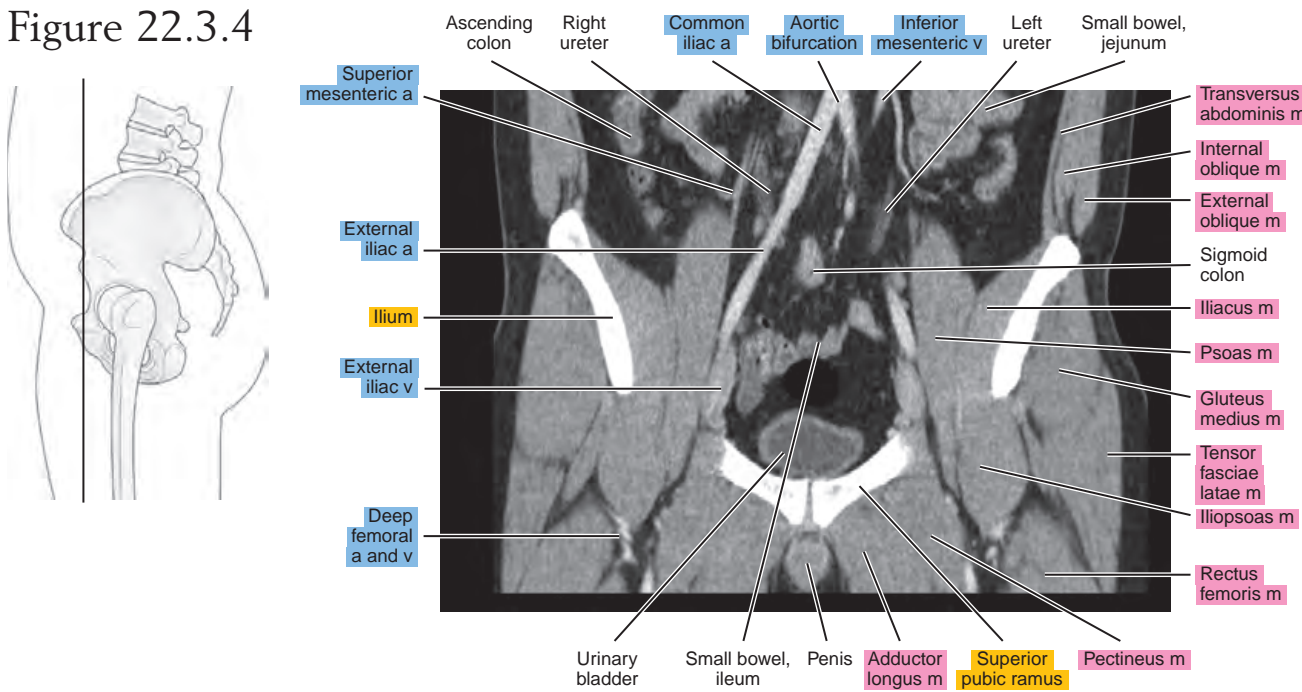


Figure 22.3.5

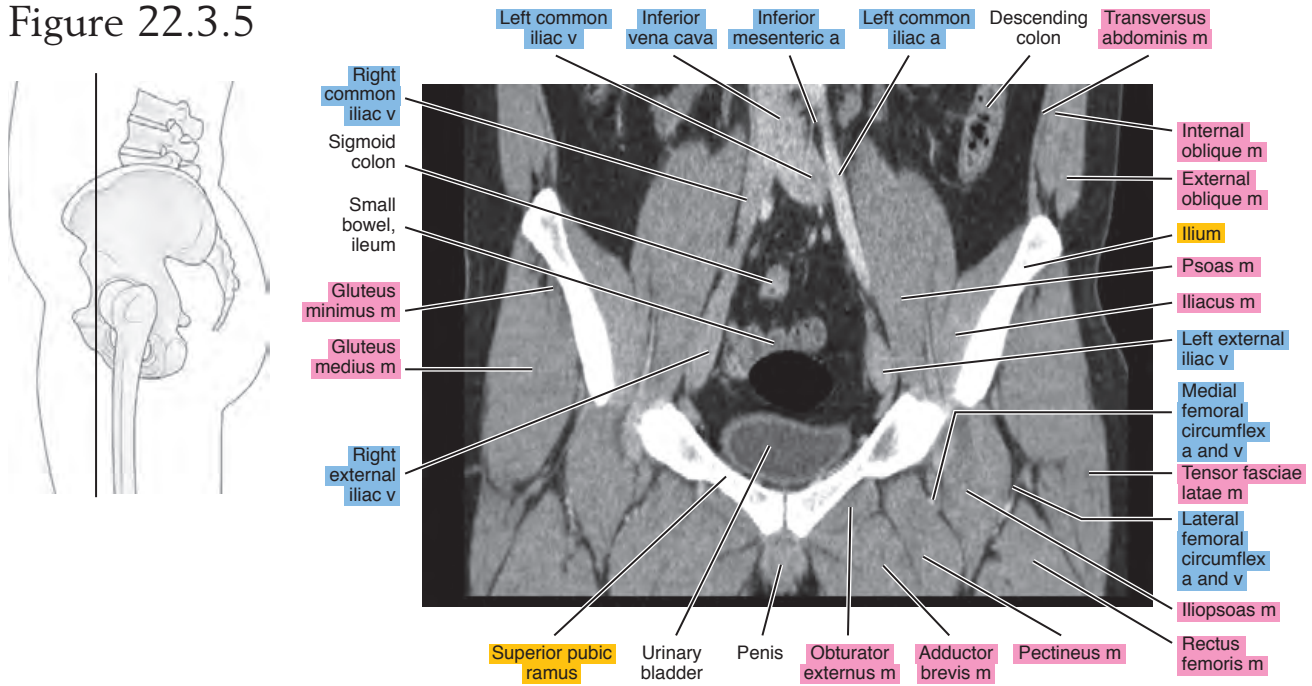


Figure 22.3.6

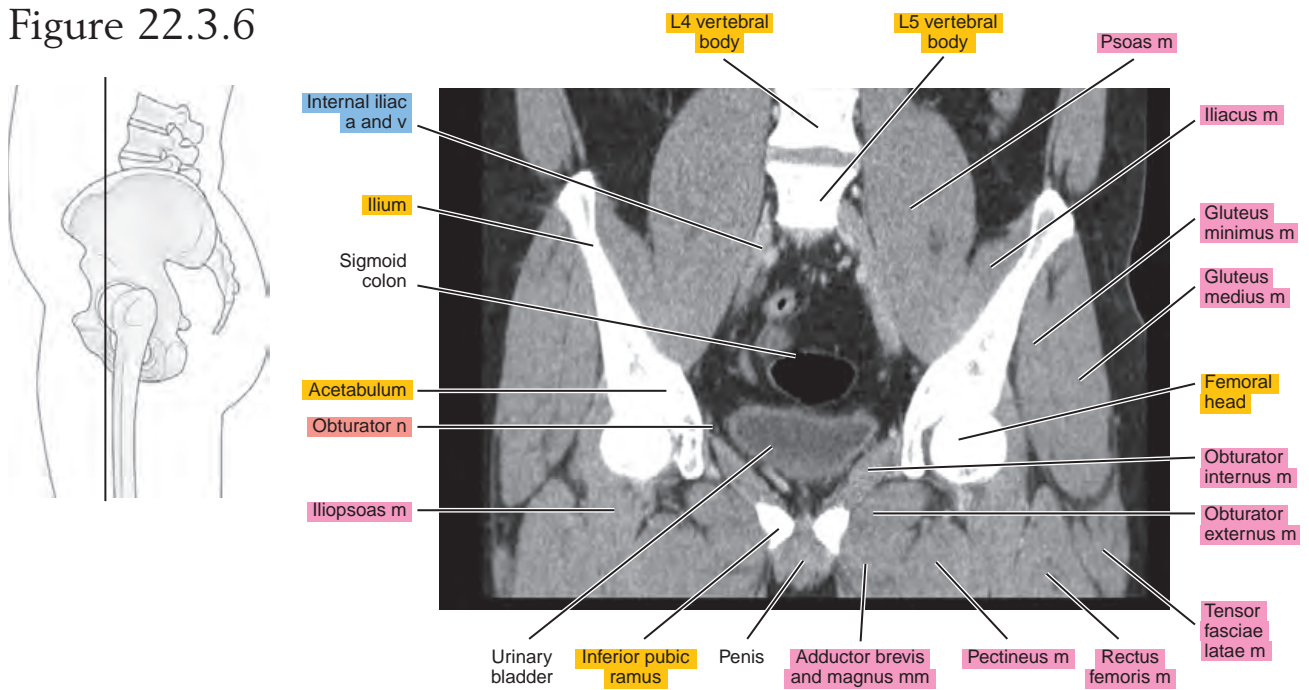


Figure 22.3.7

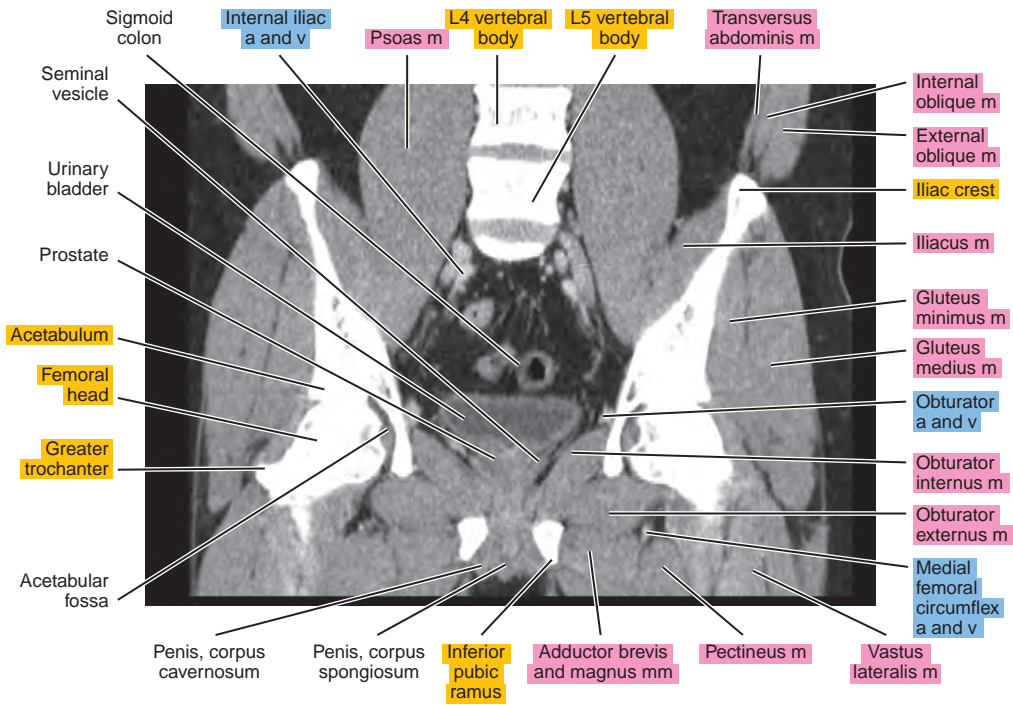
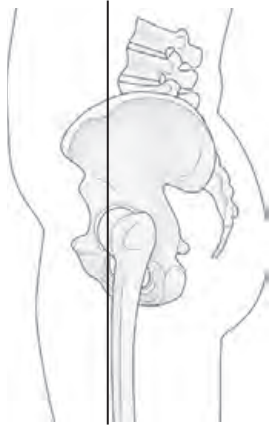

Figure 22.3.8

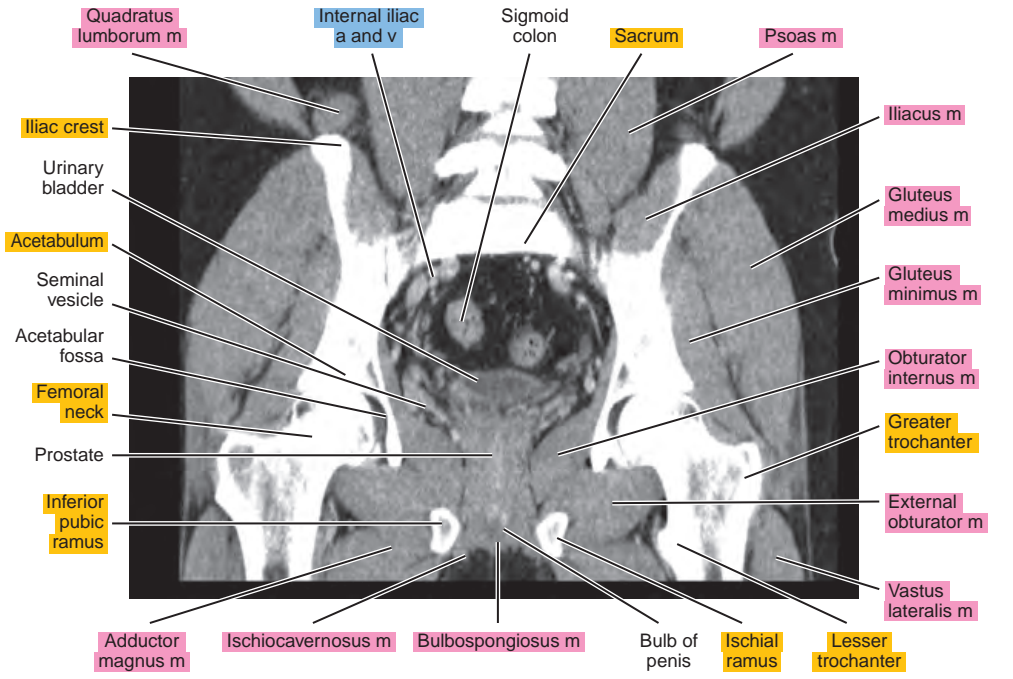
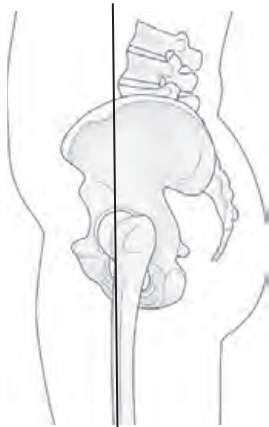

Figure 22.3.9

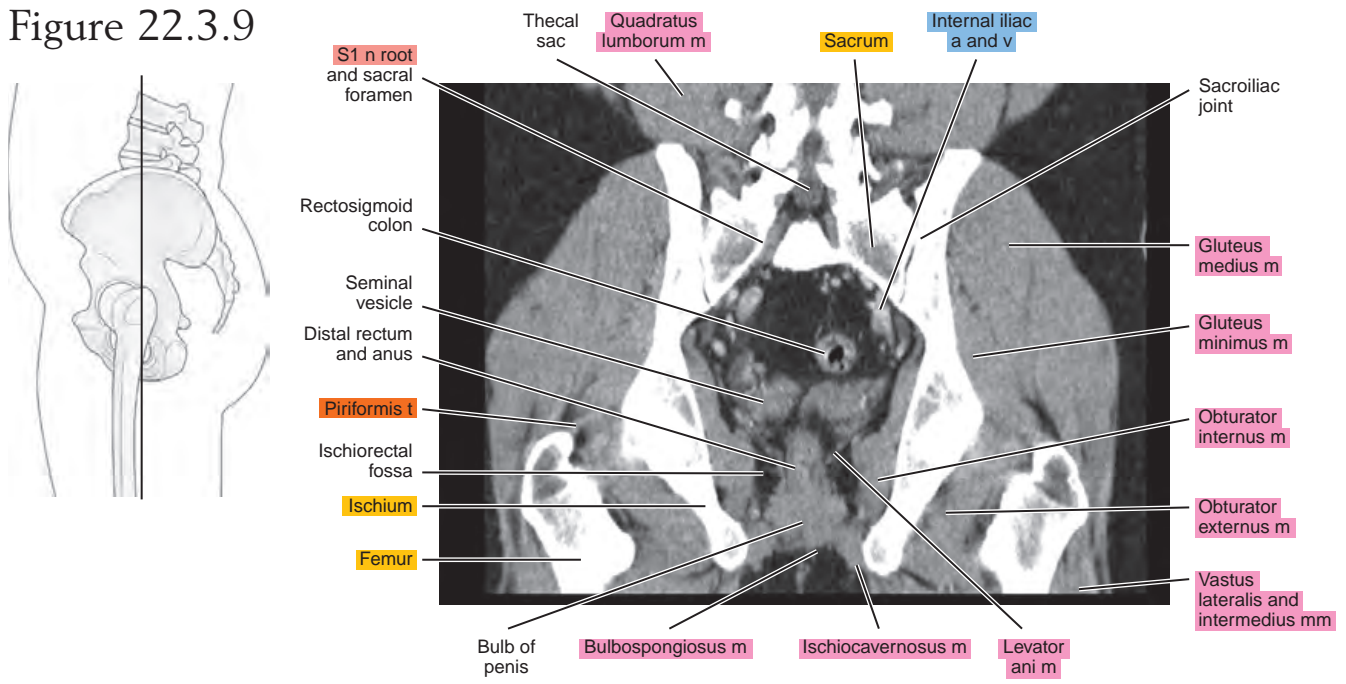


Figure 22.3.10

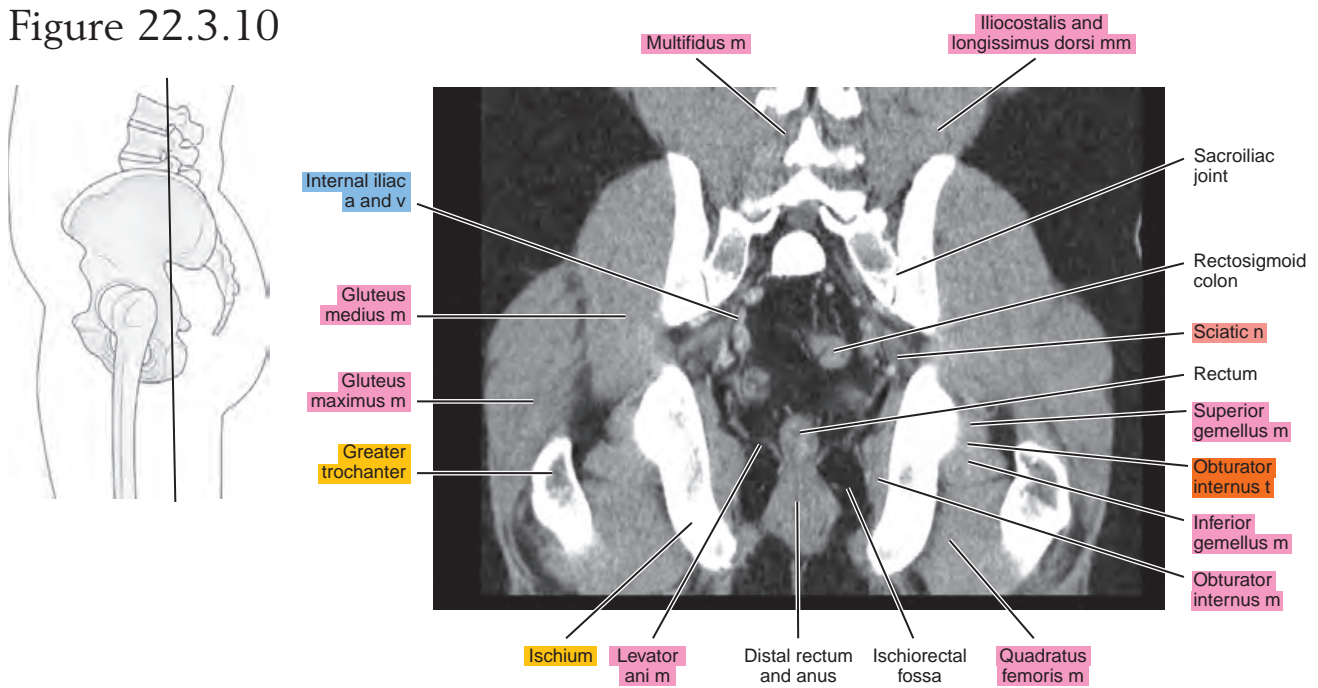
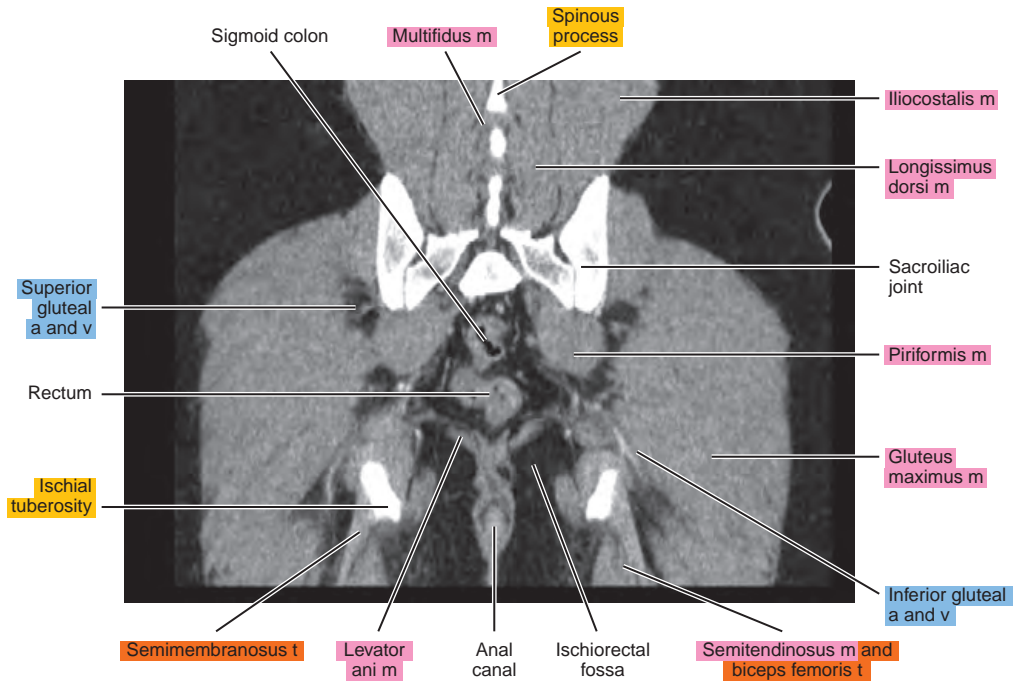
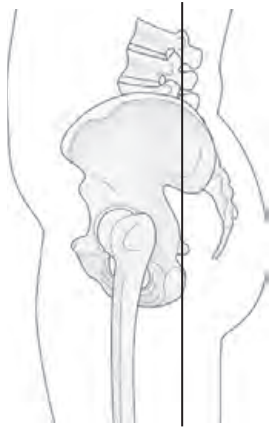


Figure 22.3.11



Chapter
23

CT of the Female Pelvis

AXIAL

Figure 23.1.1

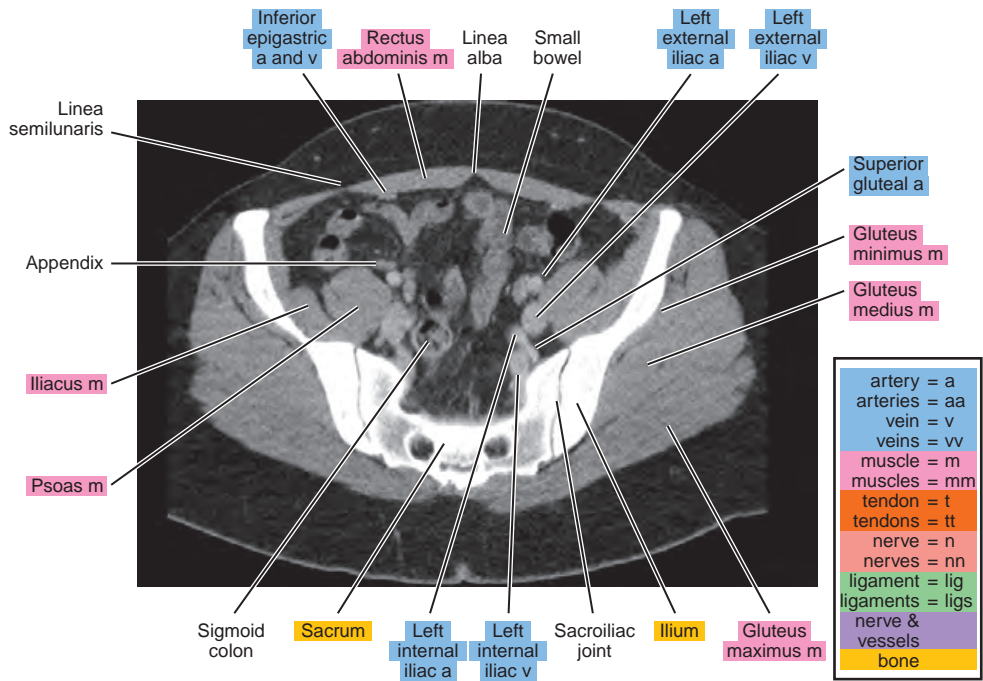
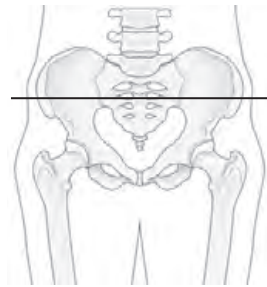


Figure 23.1.2

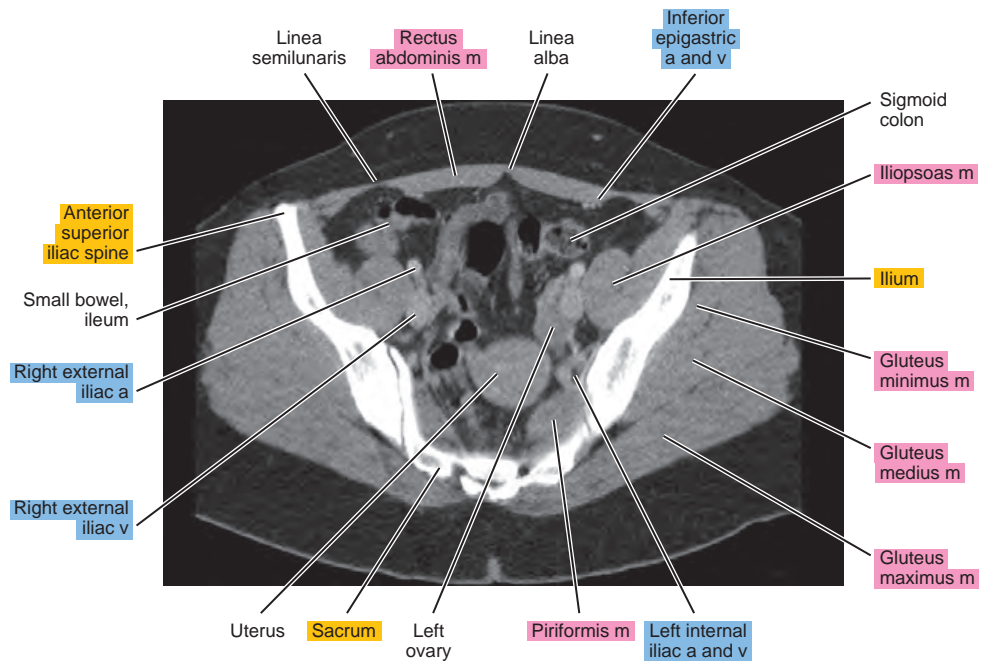
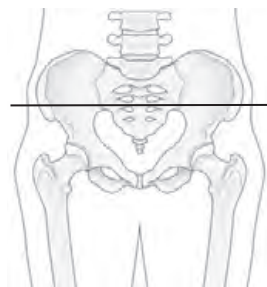


Figure 23.1.3

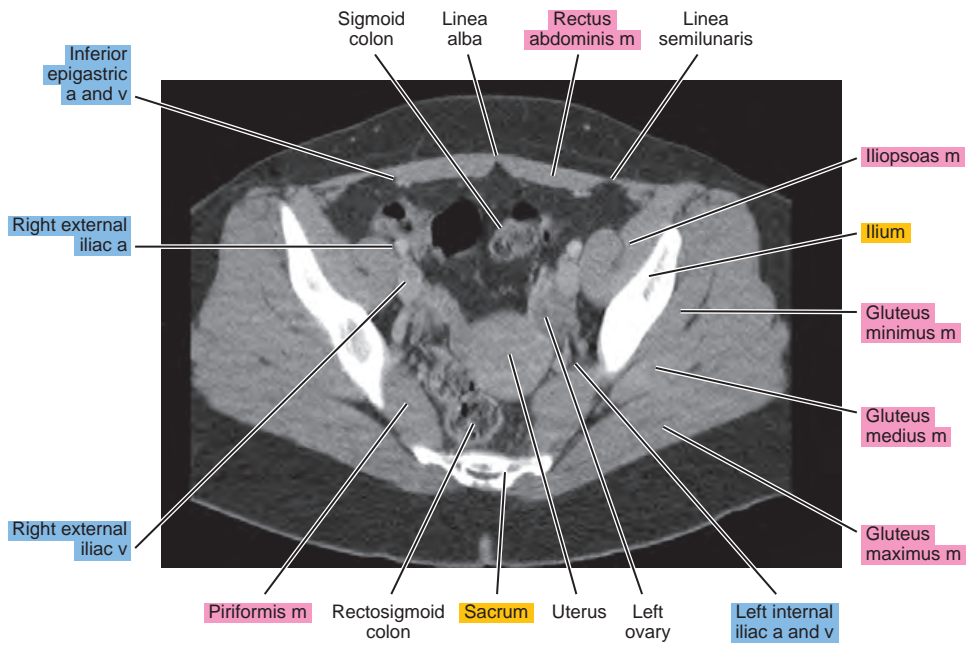
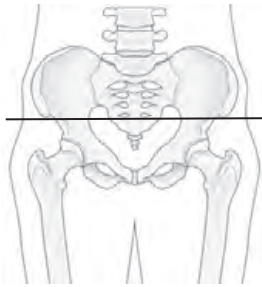


Figure 23.1.4

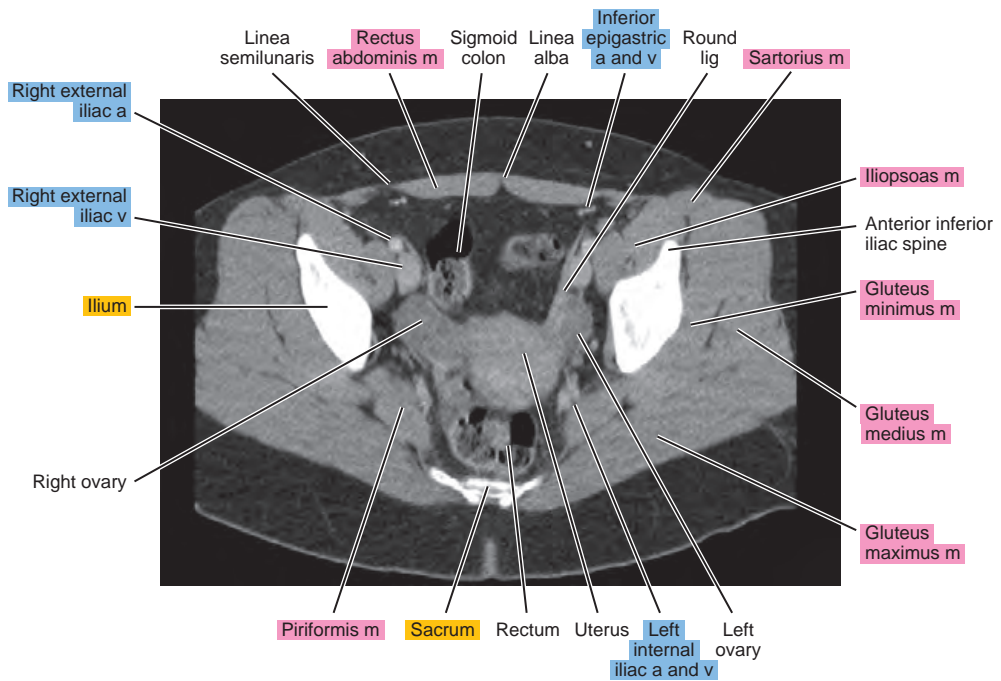
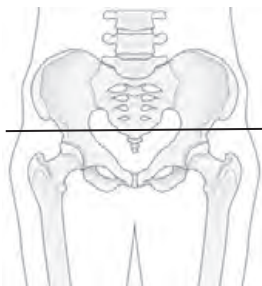


Figure 23.1.7

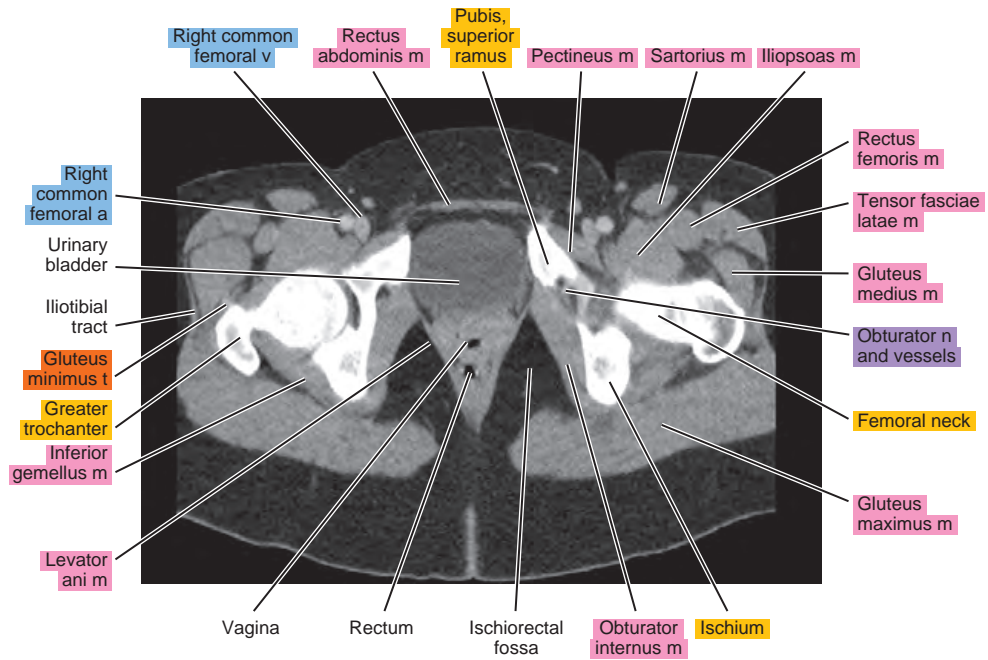
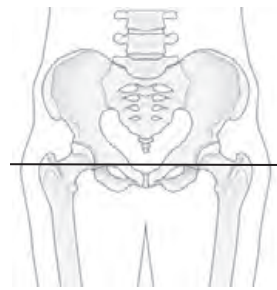


Figure 23.1.8

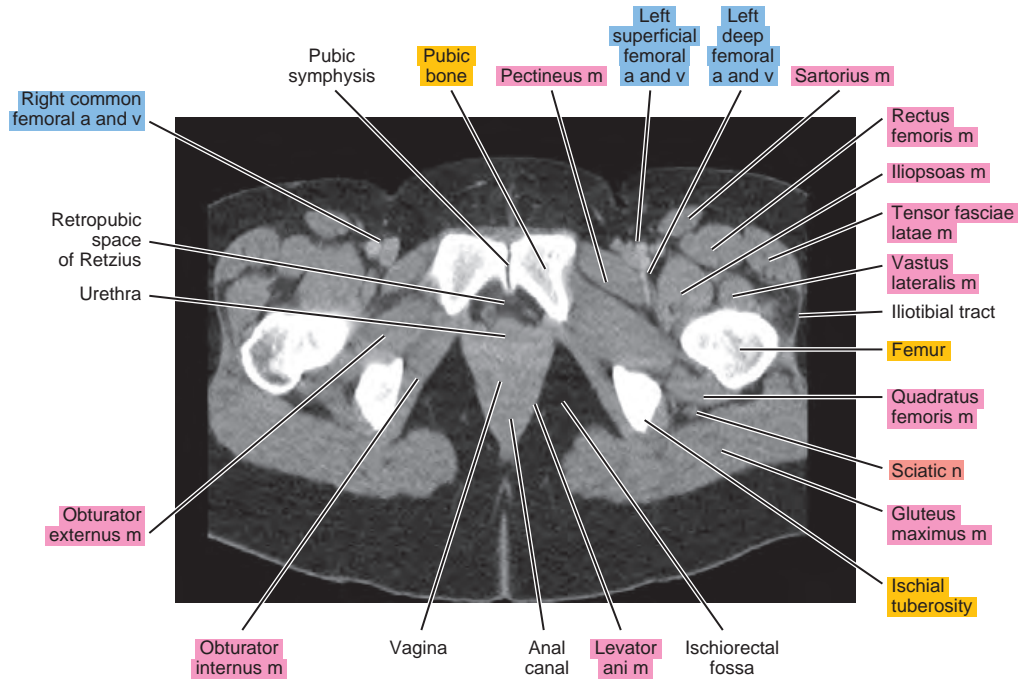
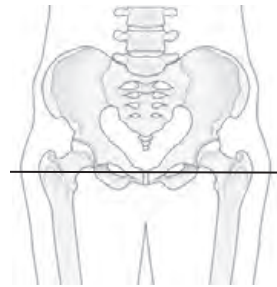
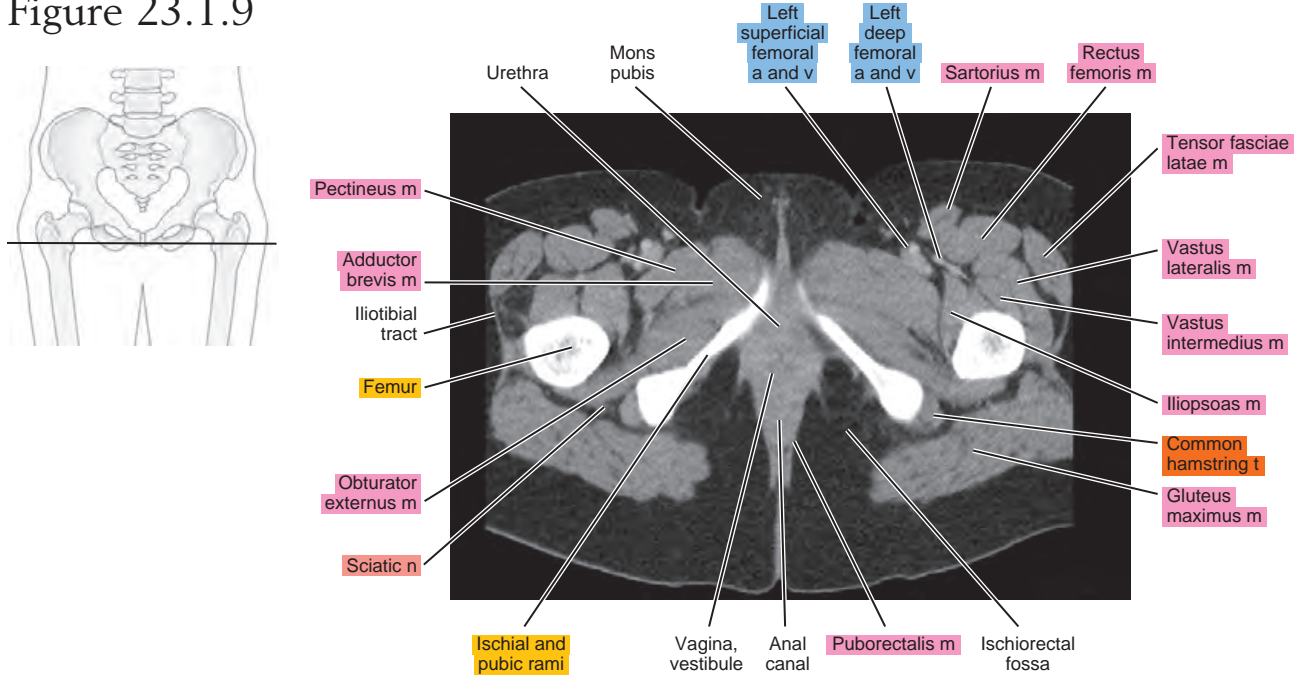


Figure 23.1.9



SAGITTAL

Figure 23.2.1

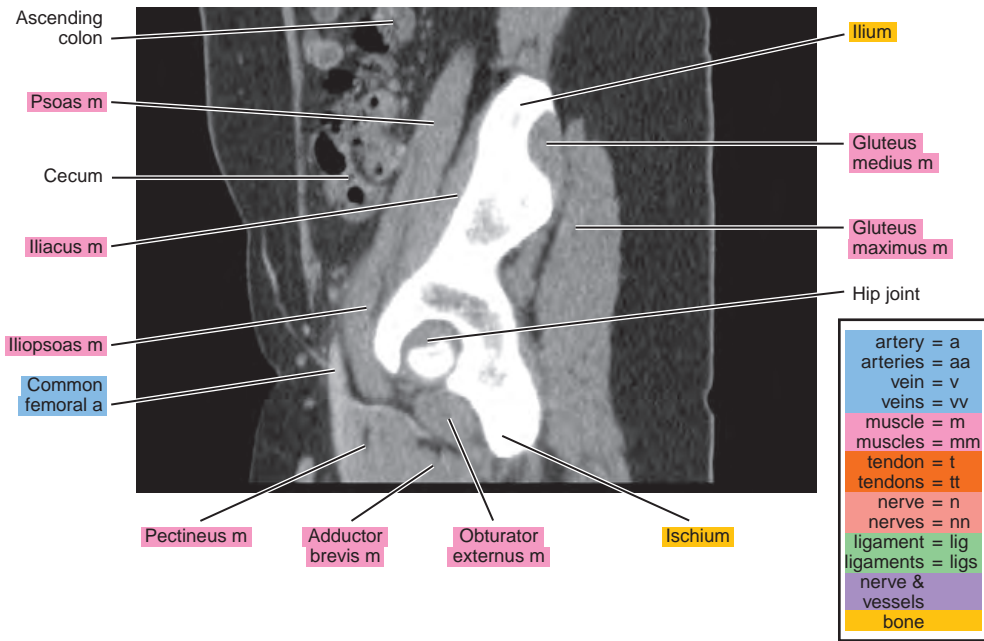
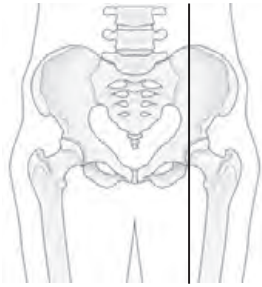


Figure 23.2.2

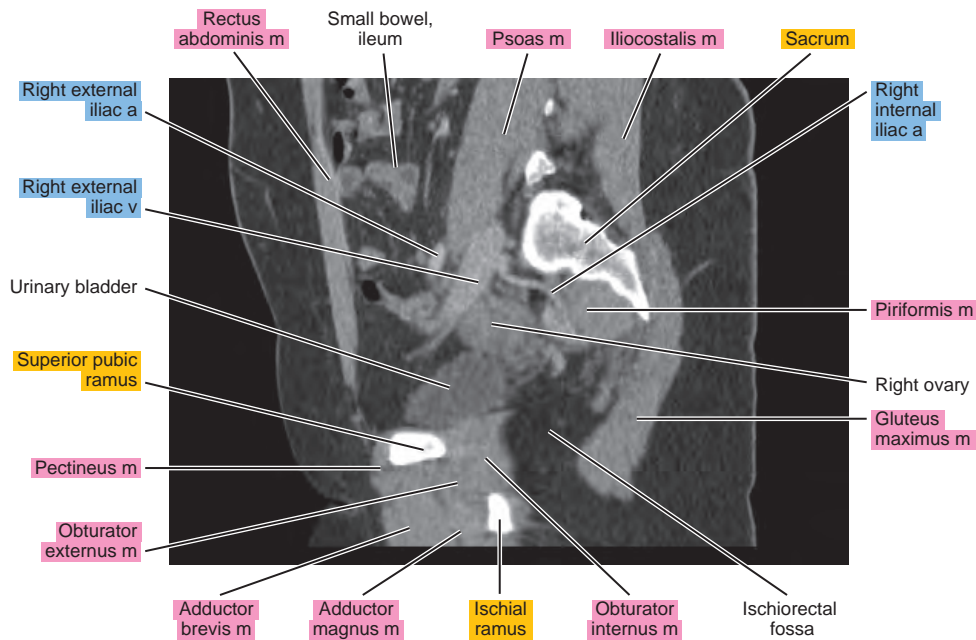
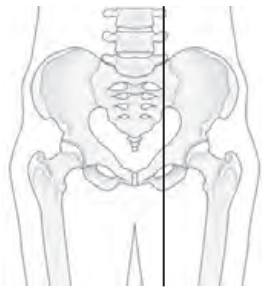


Figure 23.2.3

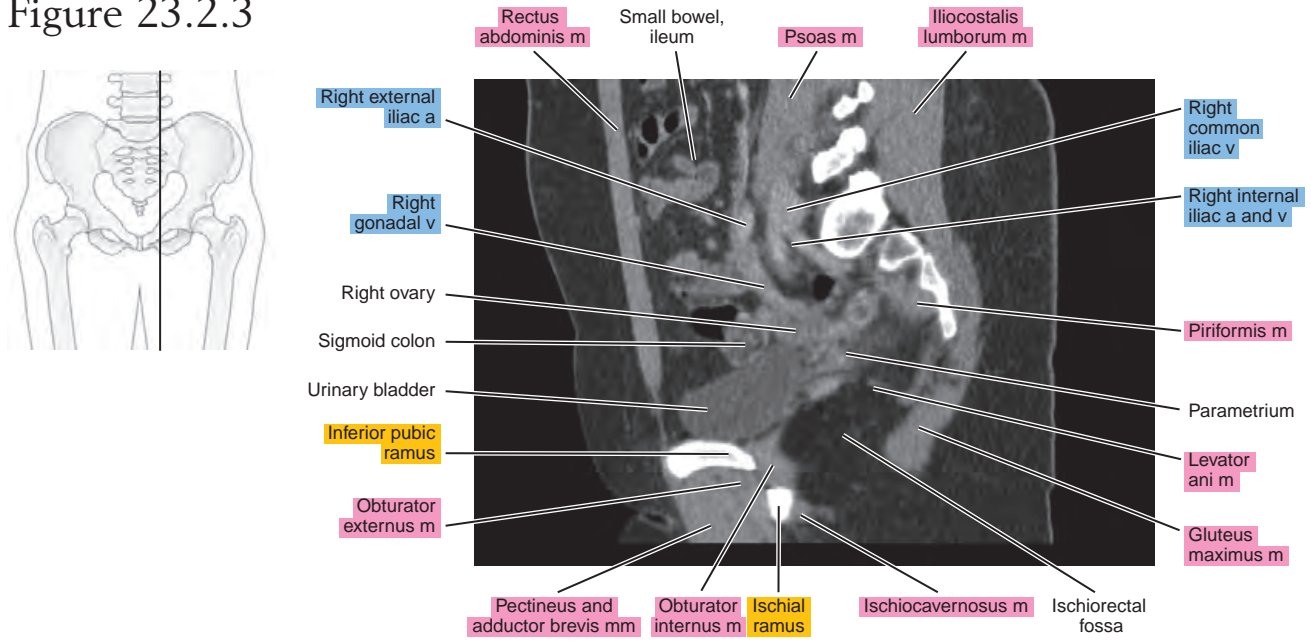


Figure 23.2.4

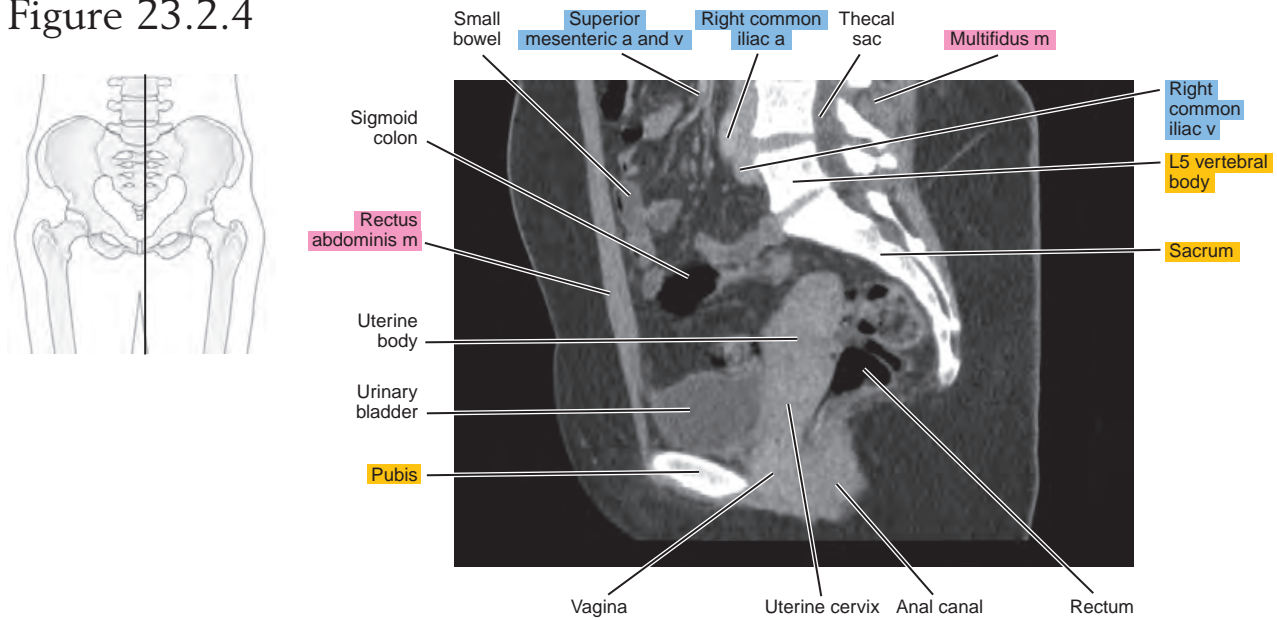
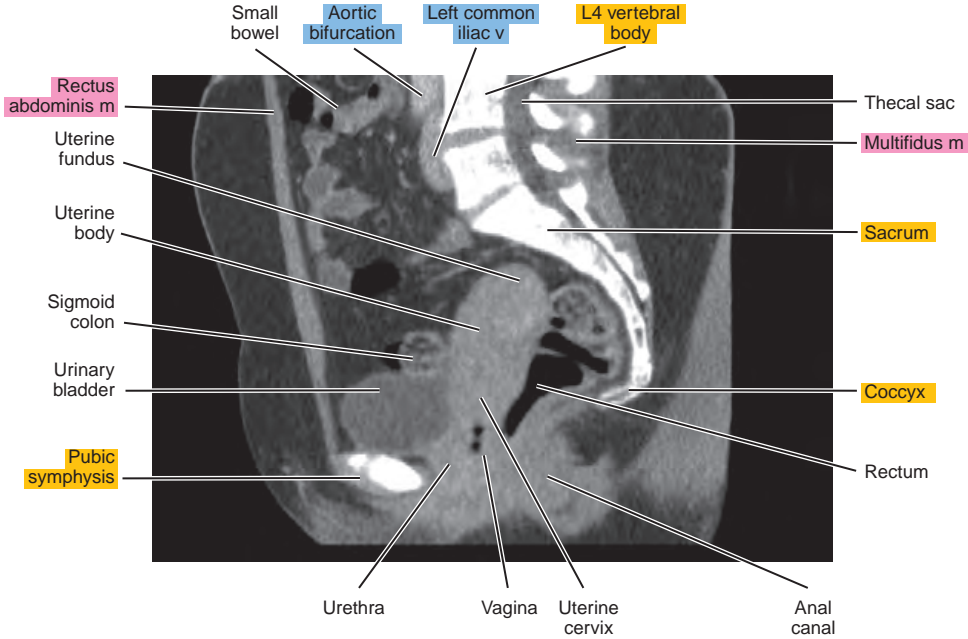
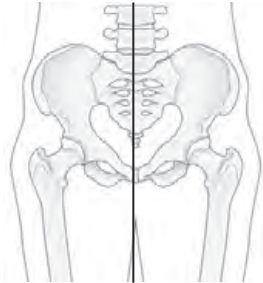


Figure 23.2.5



CORONAL

Figure 23.3.1

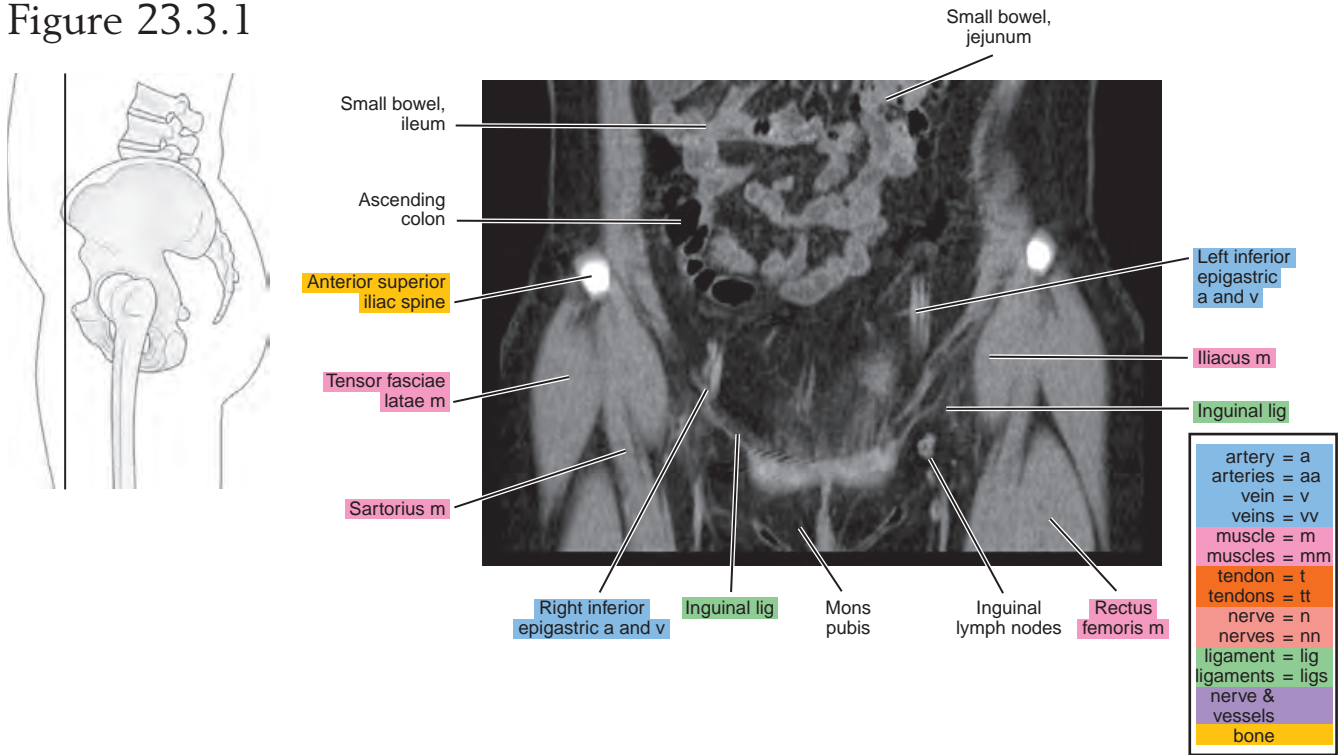


Figure 23.3.2

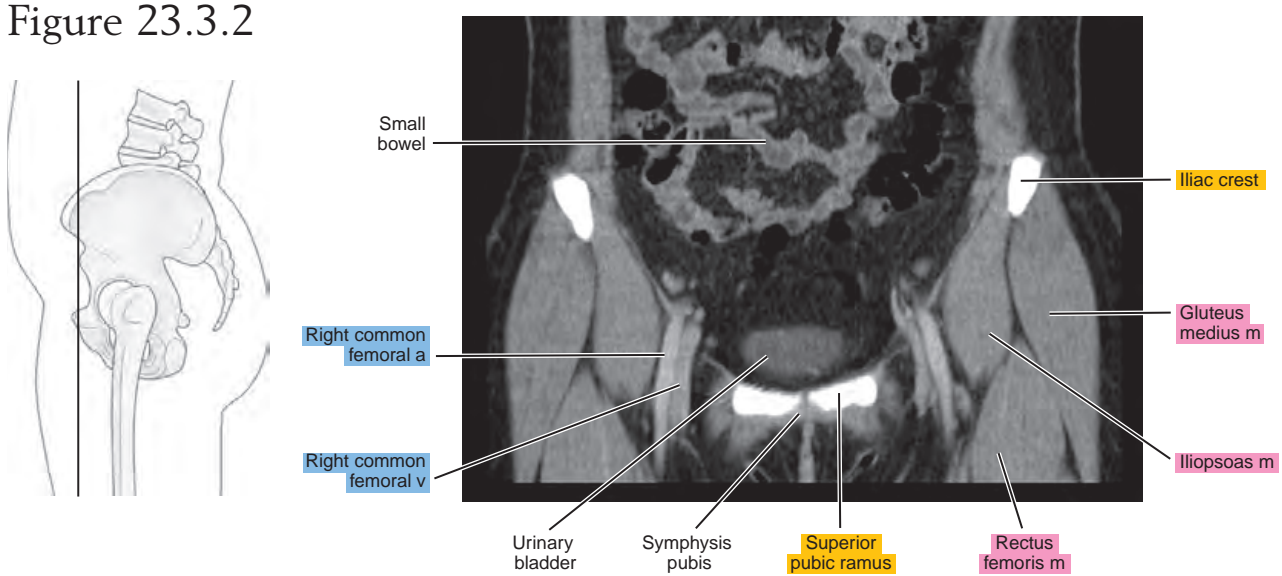


Figure 23.3.3

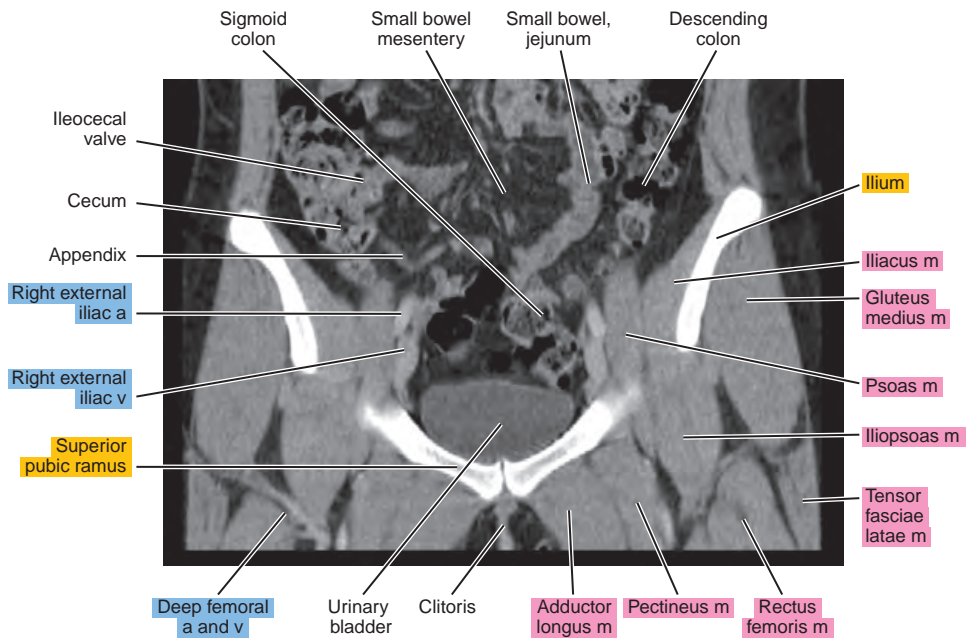
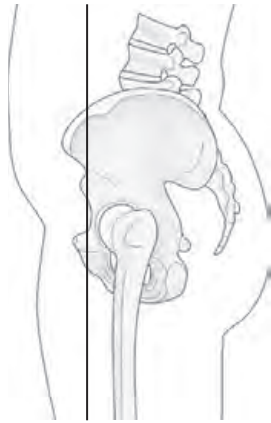

Figure 23.3.4

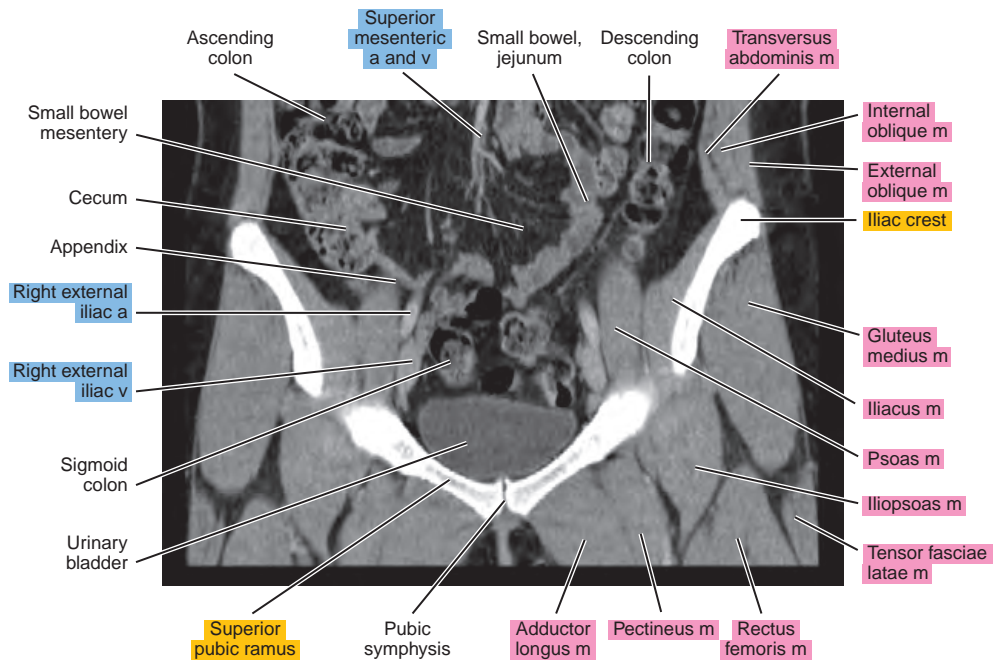
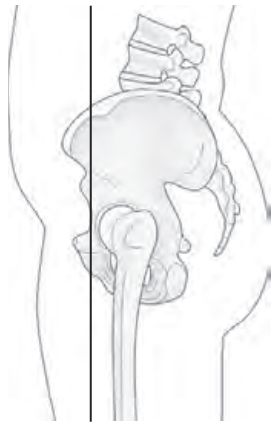

Figure 23.3.5

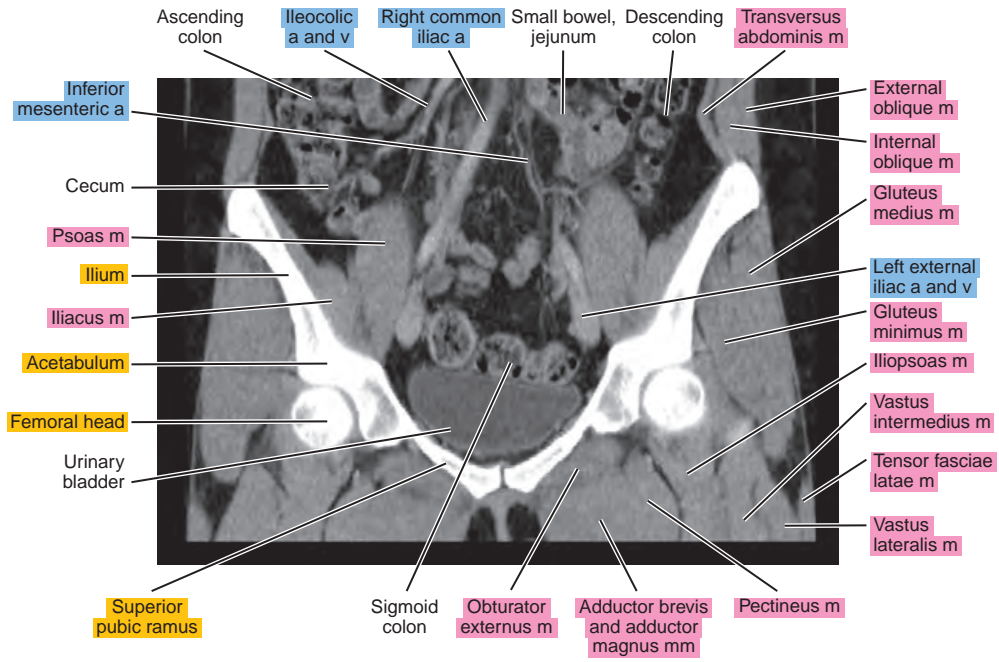
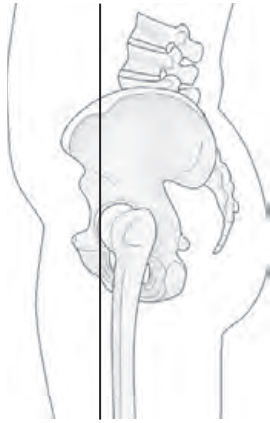

Figure 23.3.6

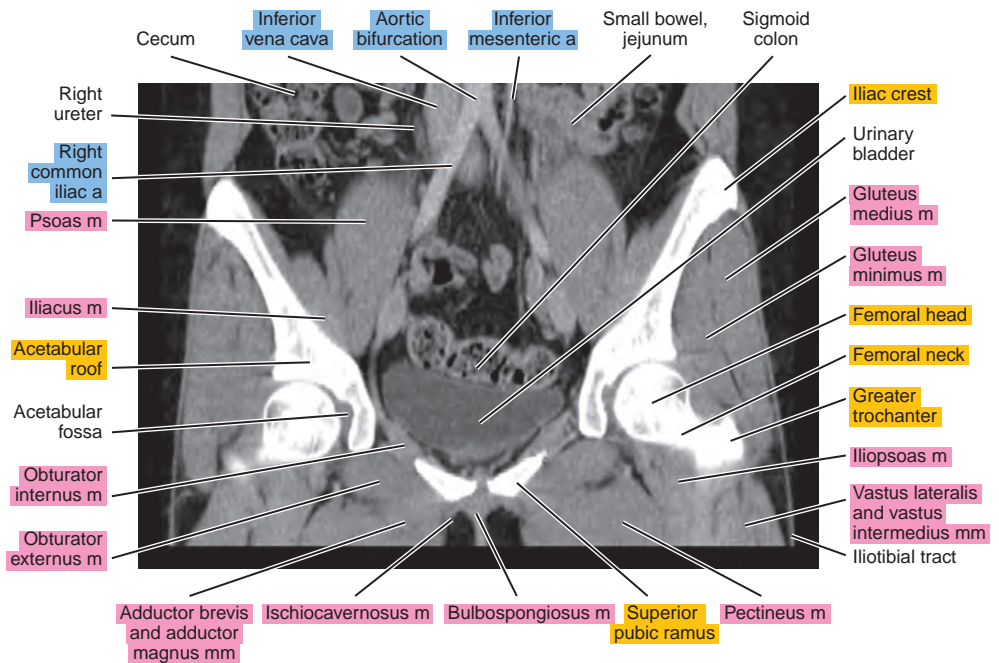
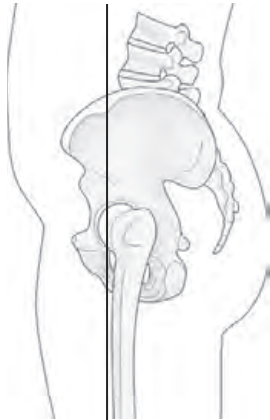

Figure 23.3.7

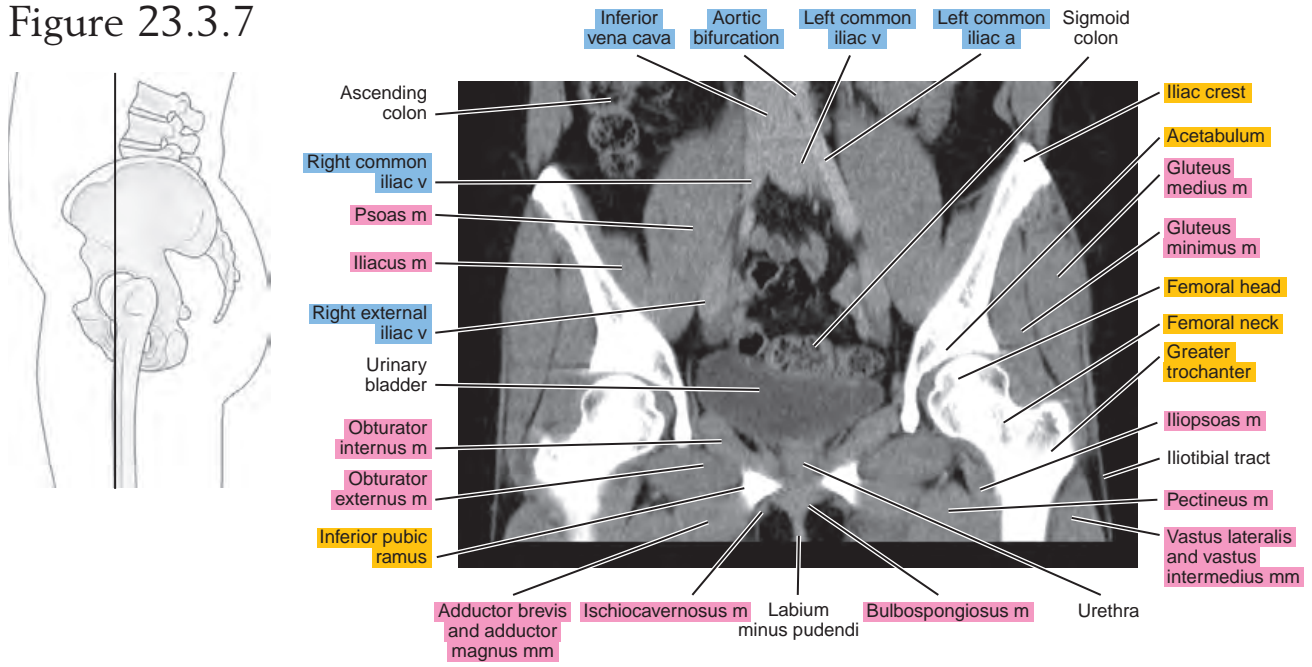


Figure 23.3.8

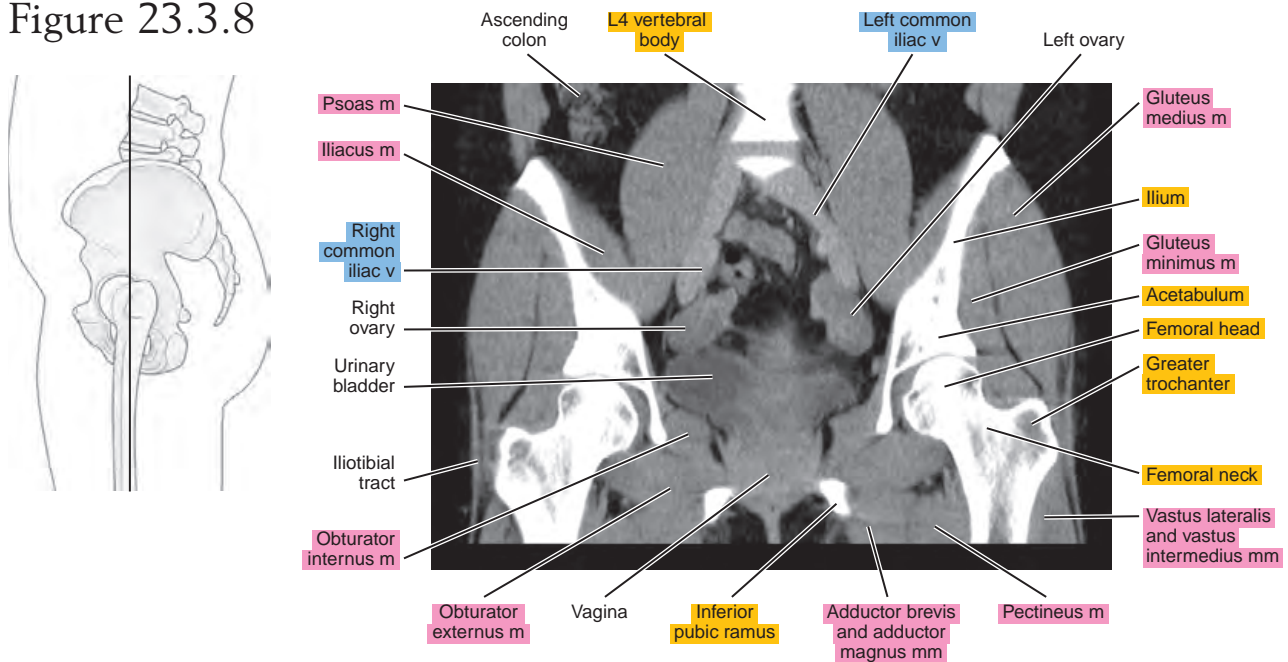


Figure 23.3.9

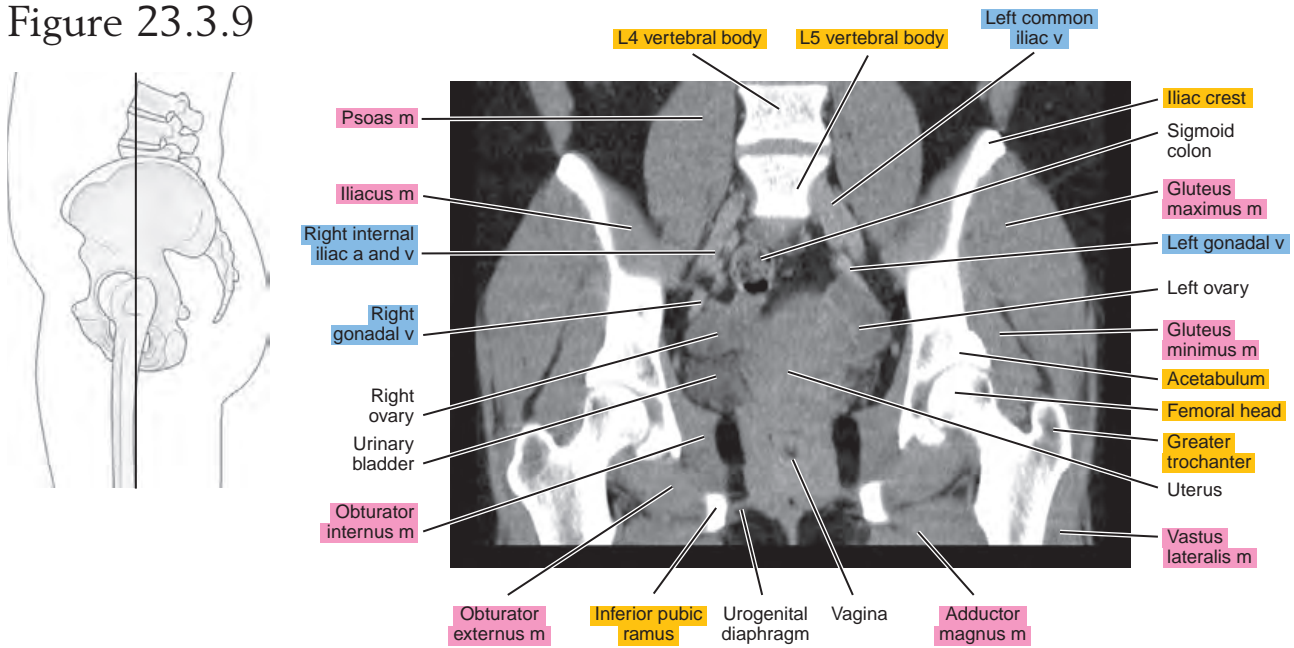


Figure 23.3.10

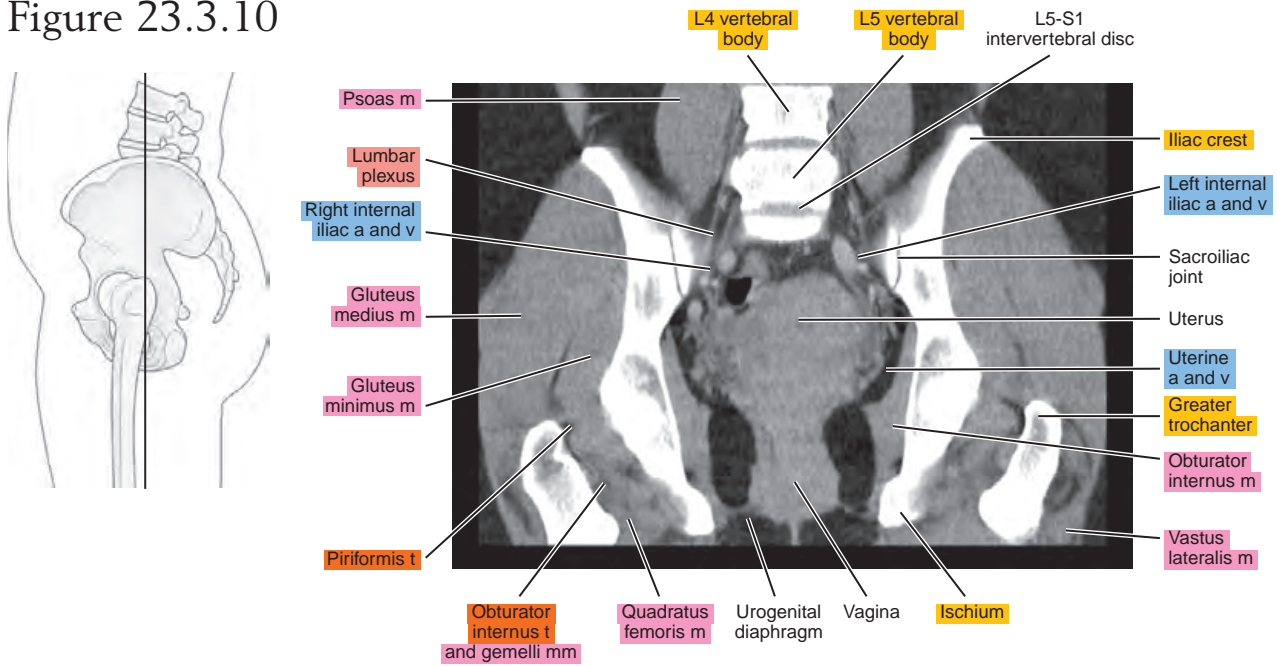


Figure 23.3.11

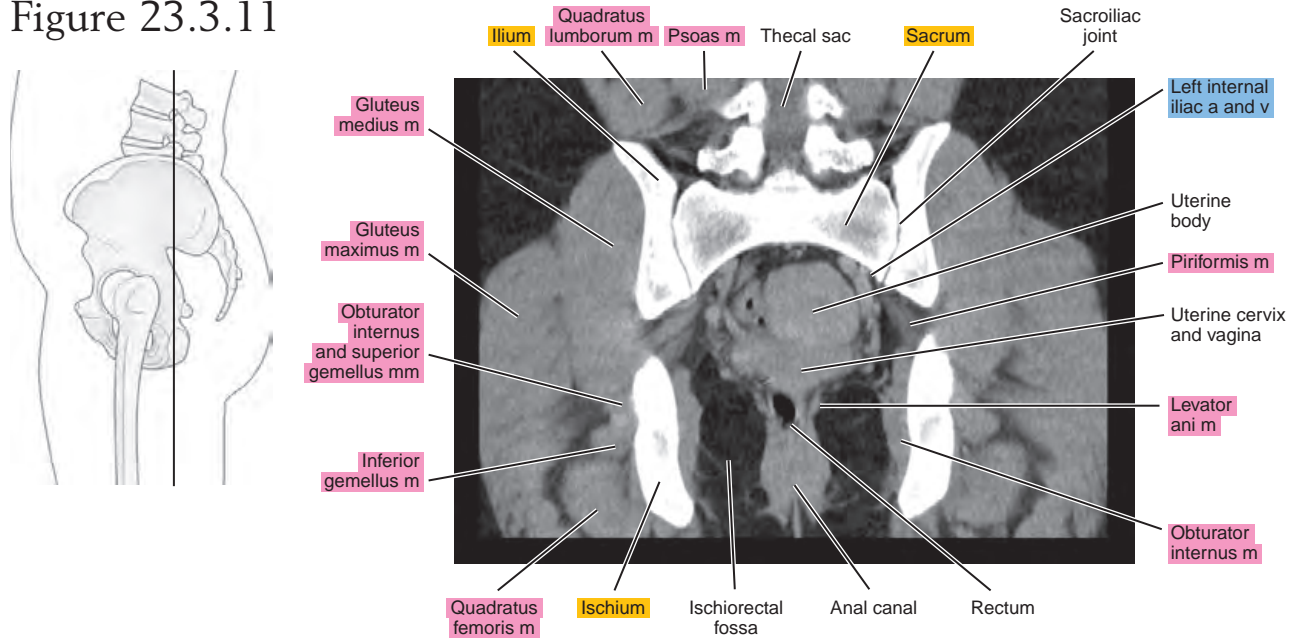
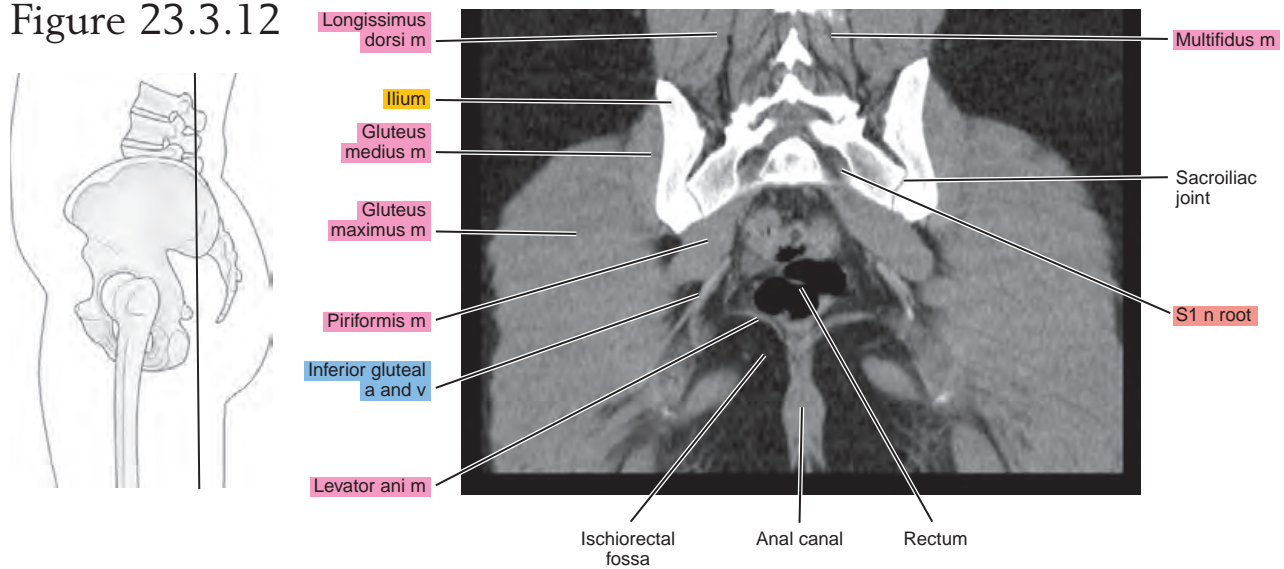


Figure 23.3.12



Chapter
24

MRI of the Male Pelvis

AXIAL

Figure 24.1.1

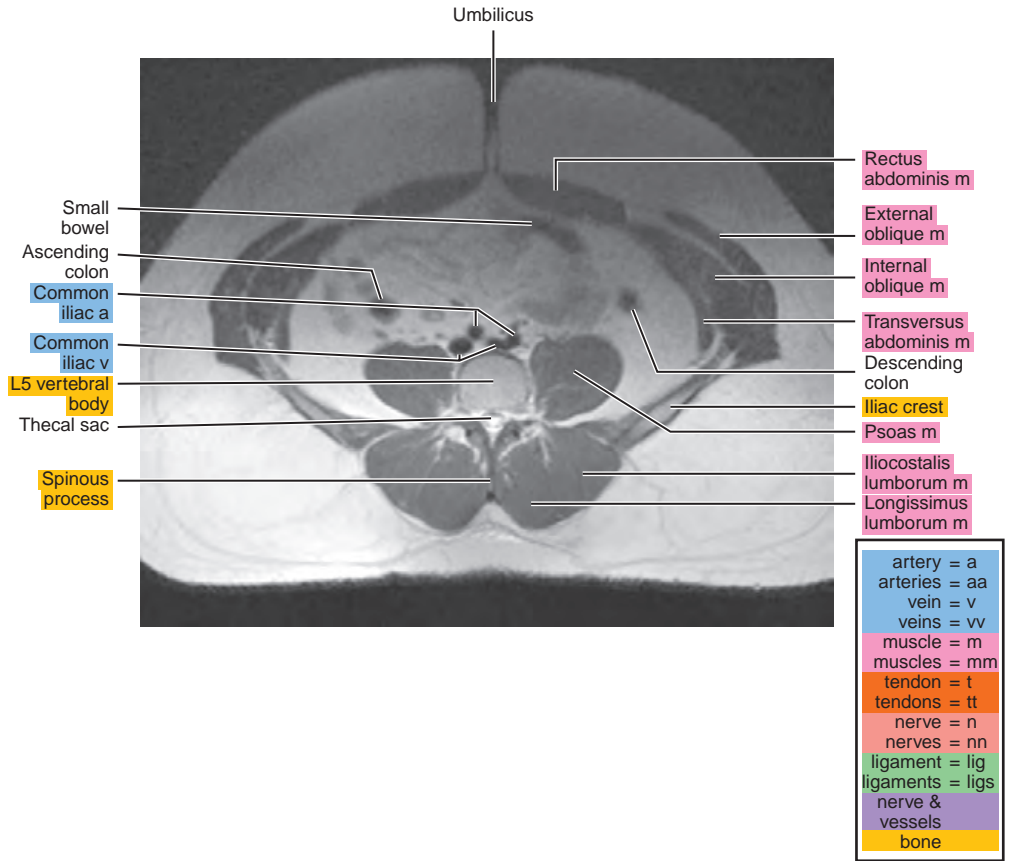
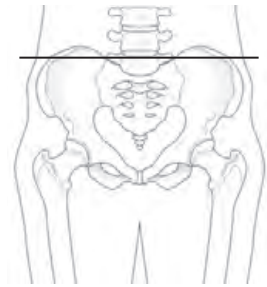


Figure 24.1.2

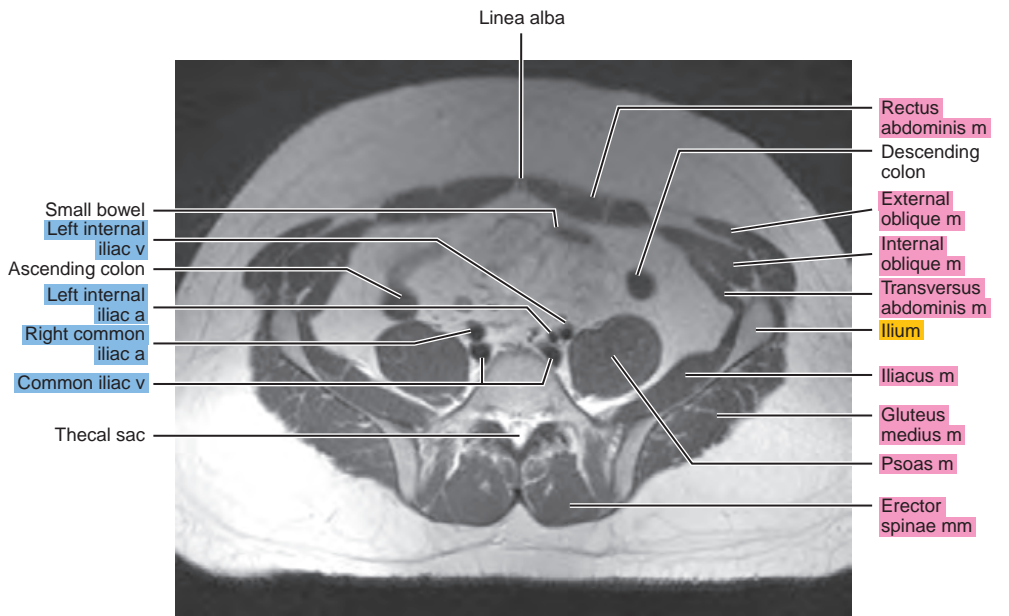
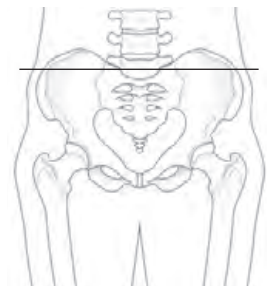


Figure 24.1.3

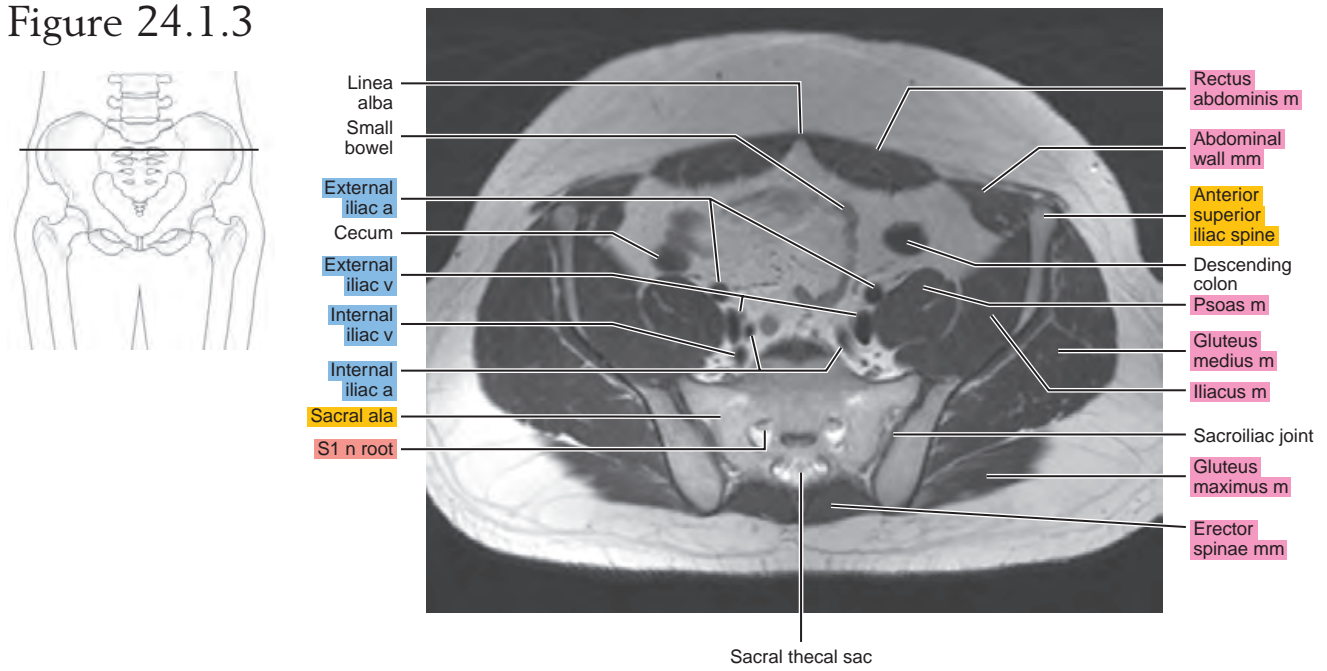


Figure 24.1.4

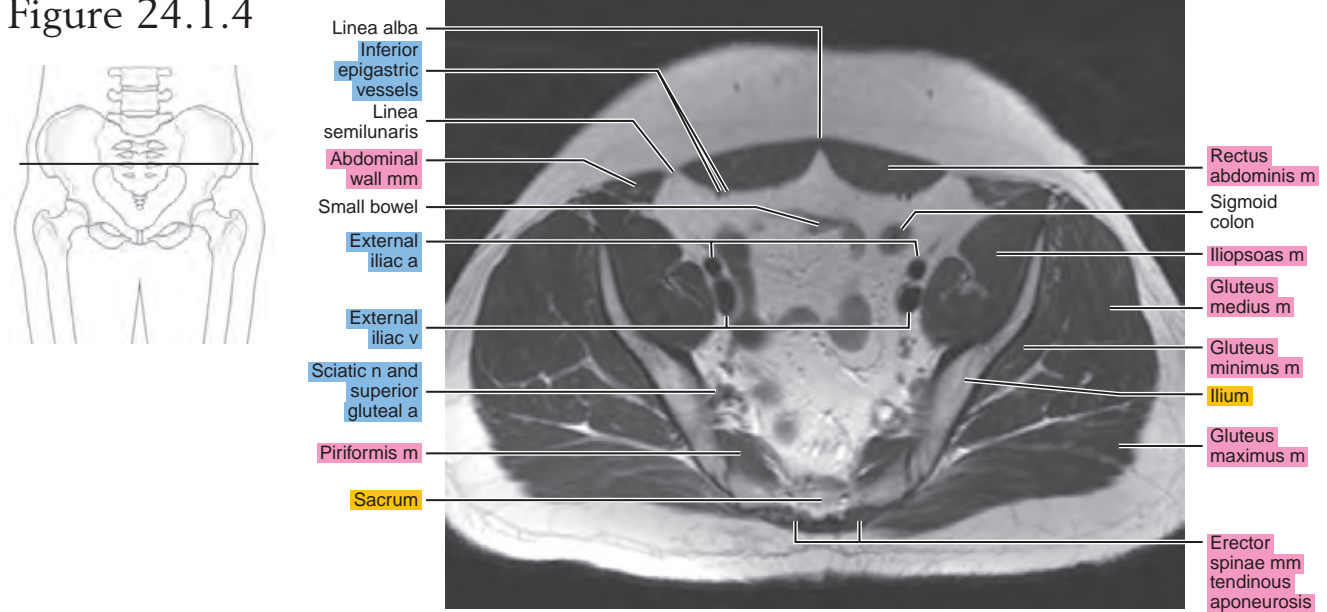


Figure 24.1.5

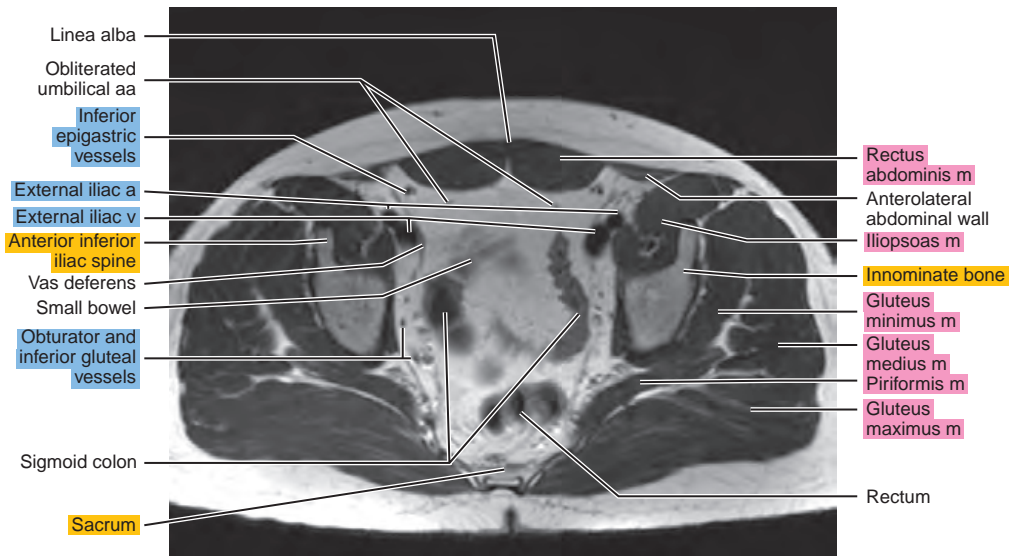
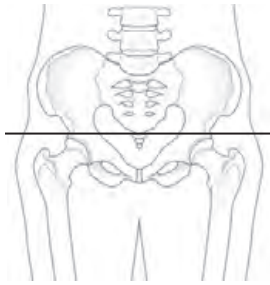


Figure 24.1.6

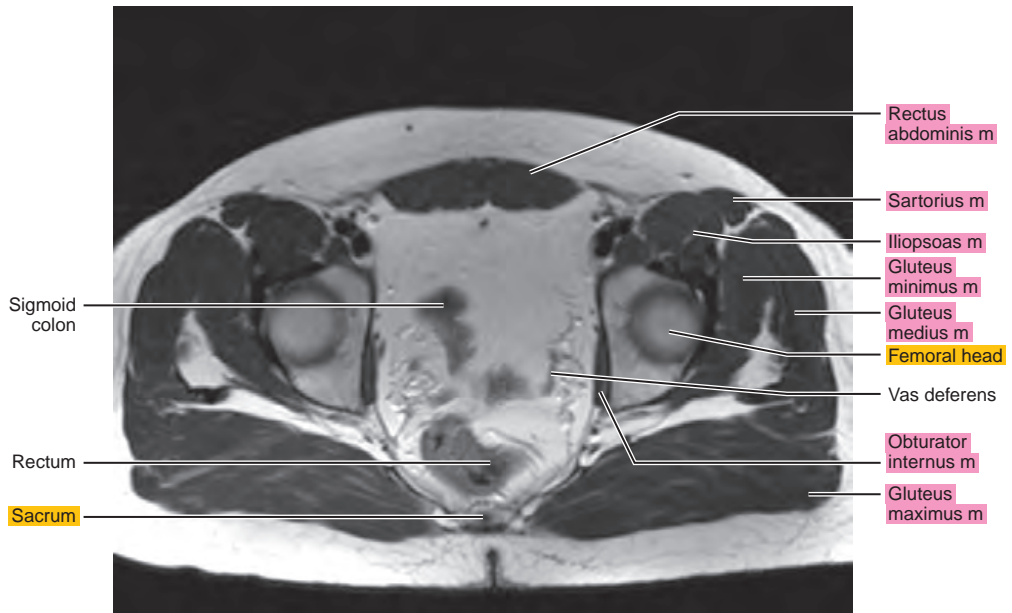
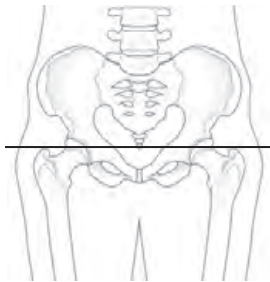


Figure 24.1.7

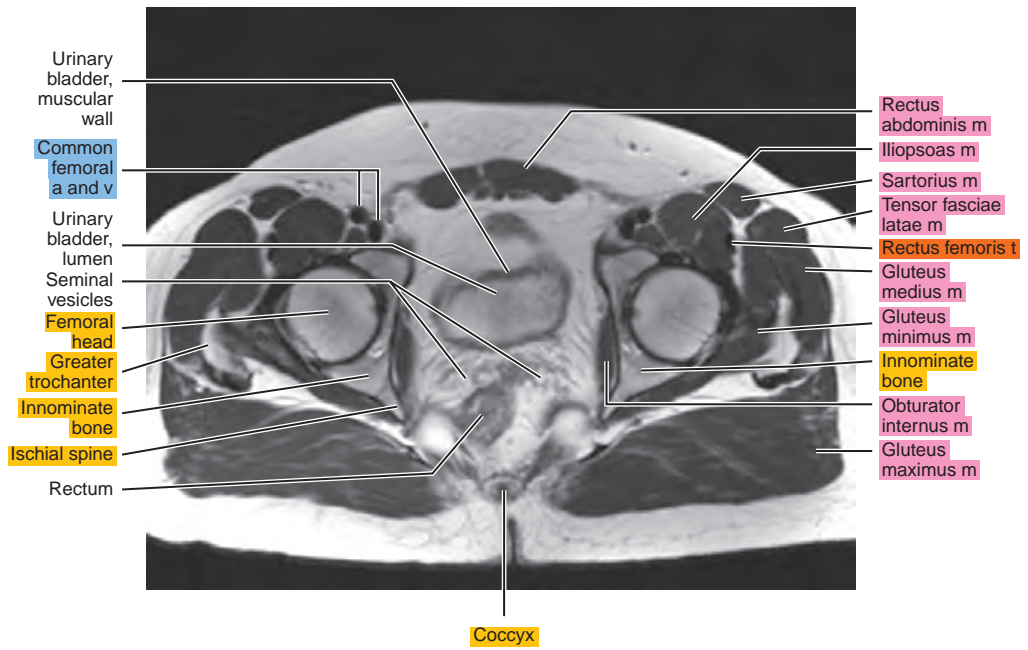
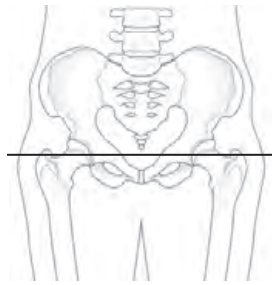


Figure 24.1.8

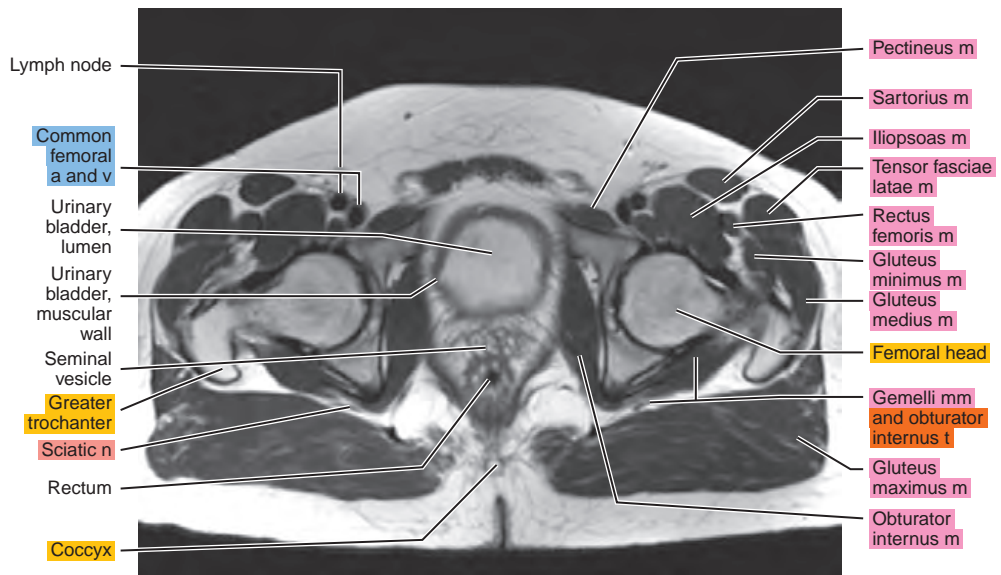
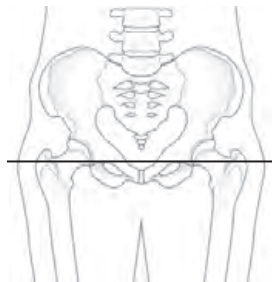


Figure 24.1.9

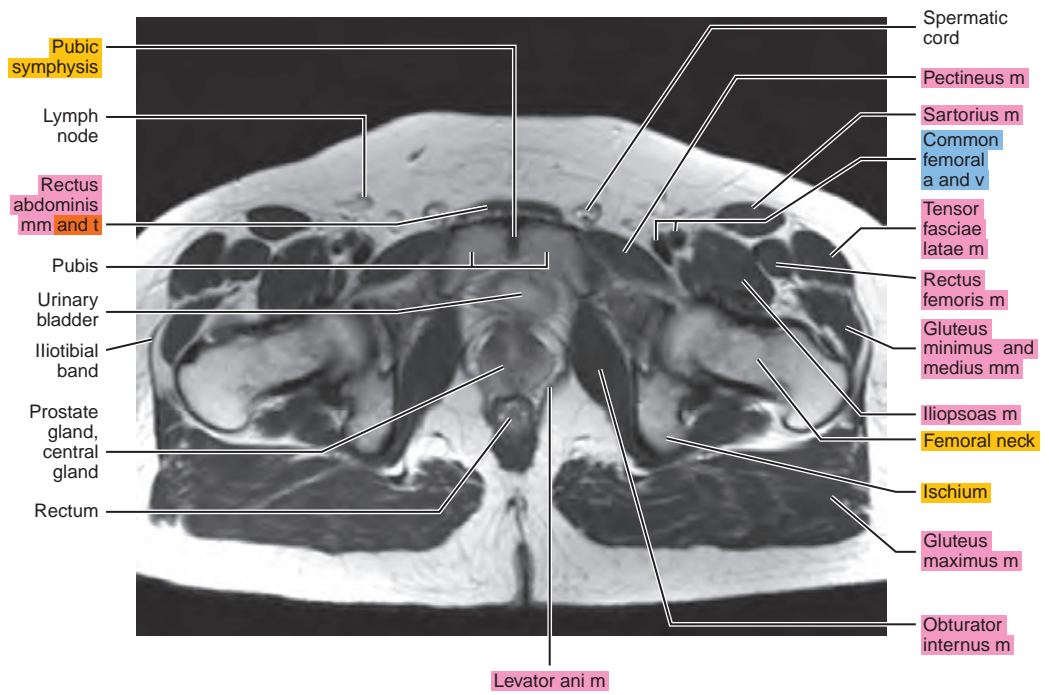
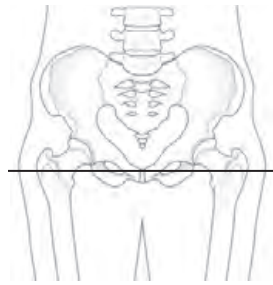


Figure 24.1.10

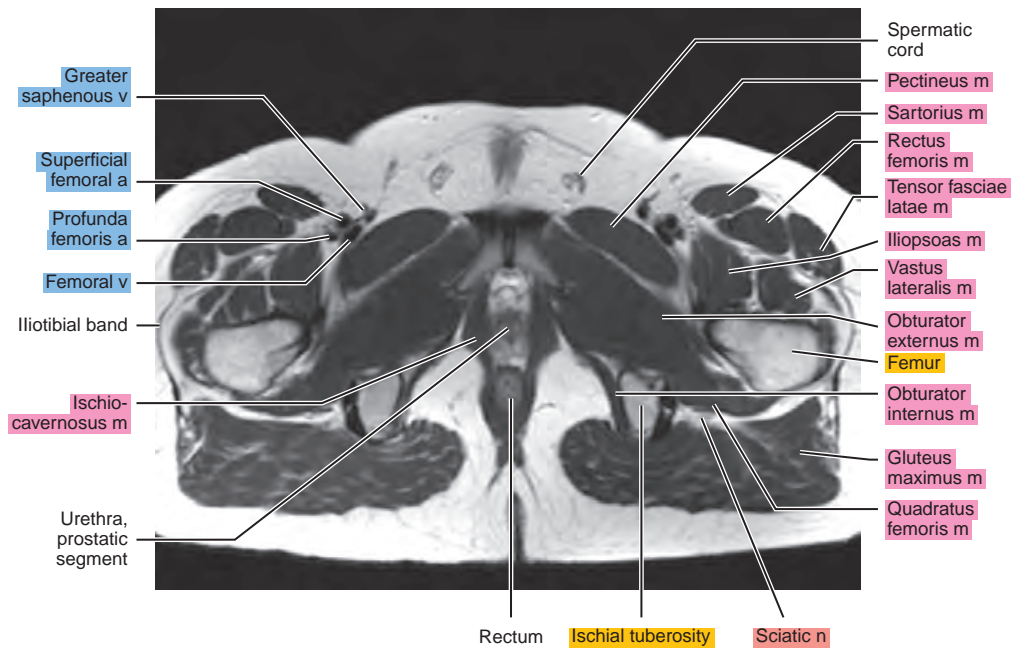
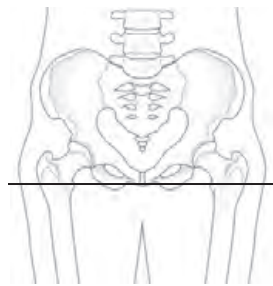


Figure 24.1.11

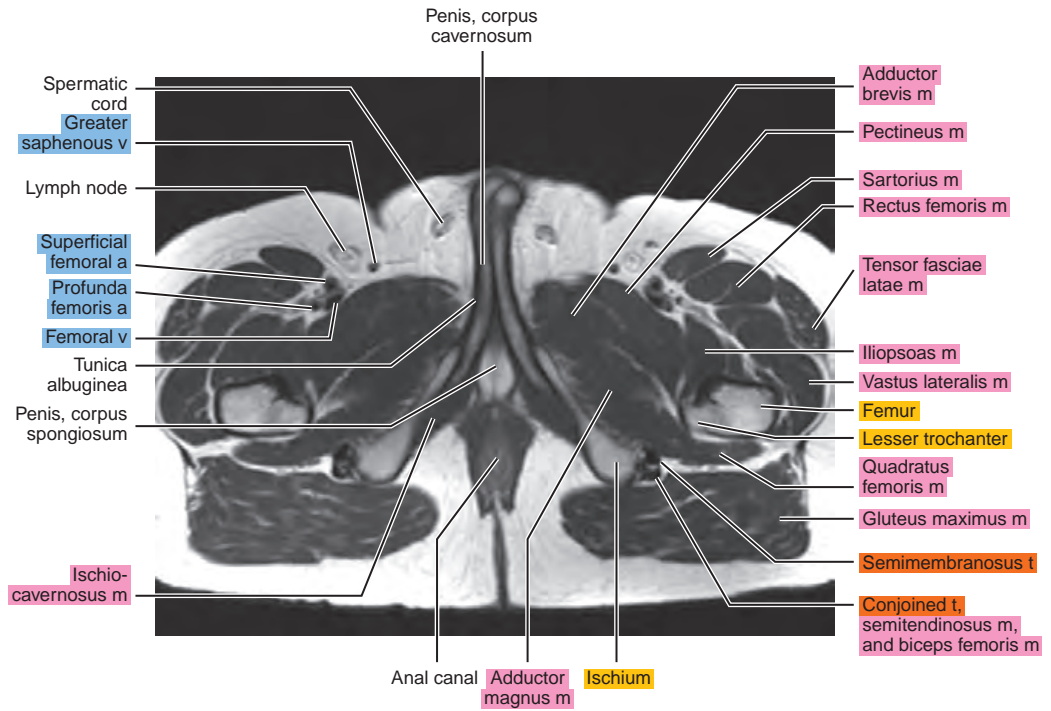
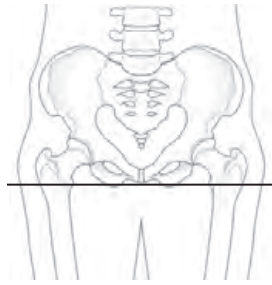
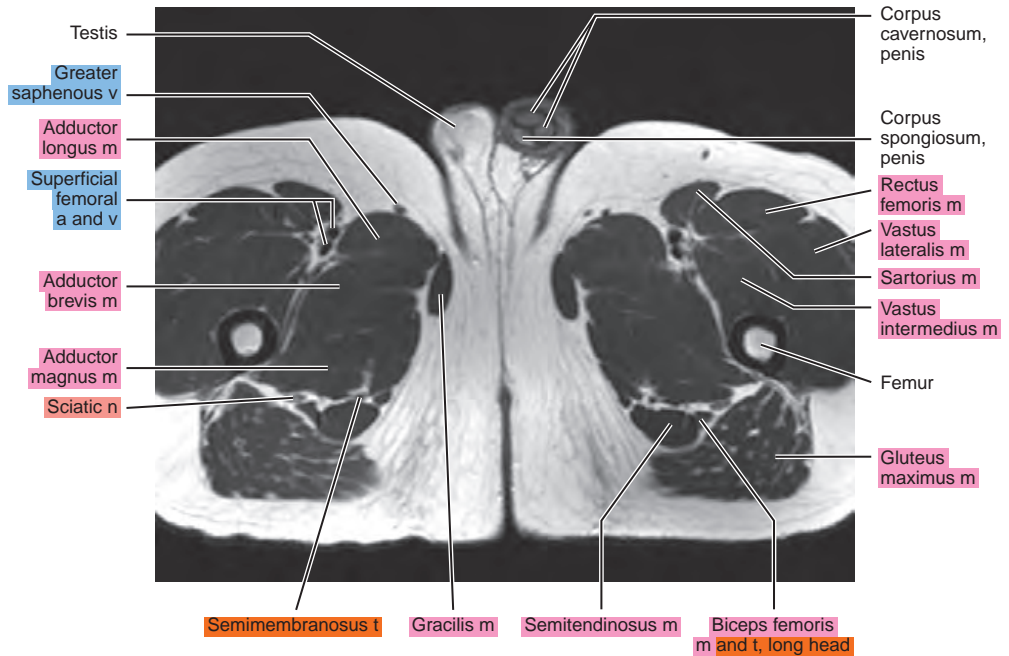
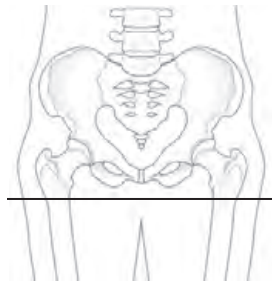


Figure 24.1.12



SAGITTAL

Figure 24.2.1

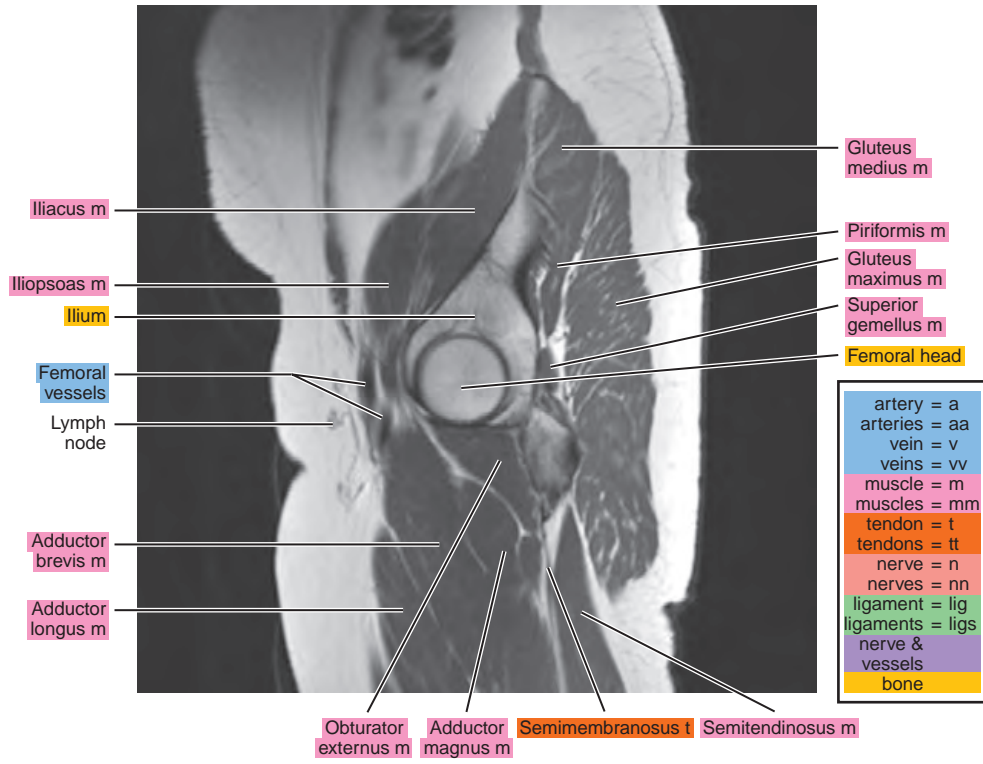
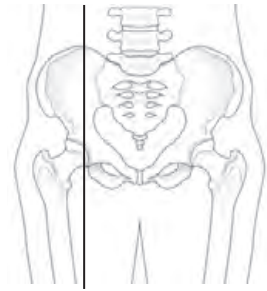


Figure 24.2.2

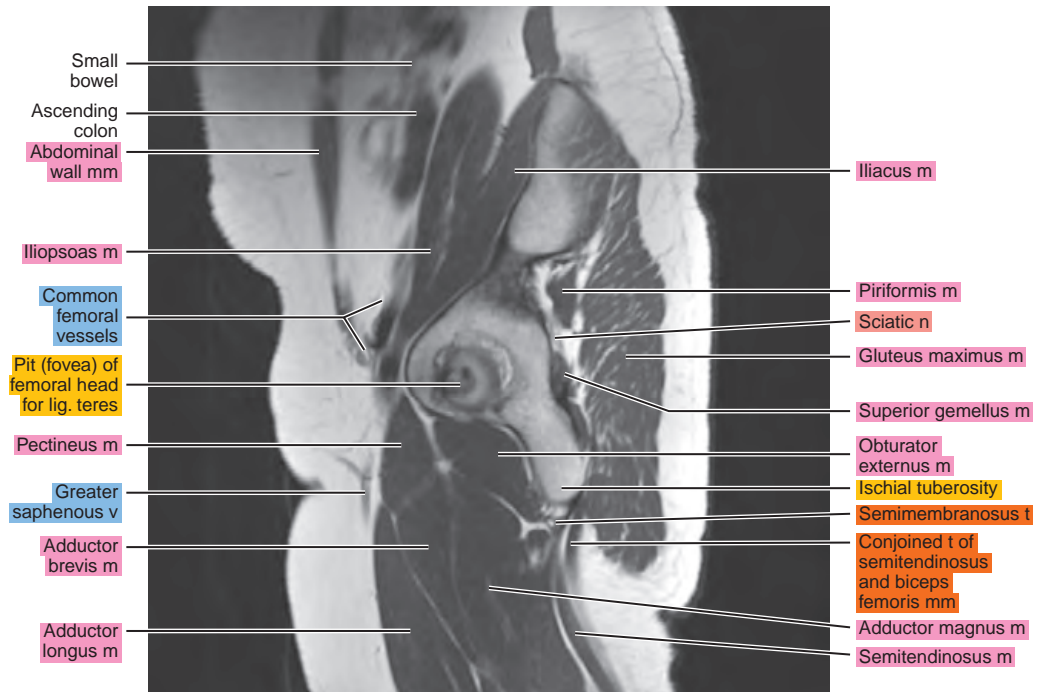
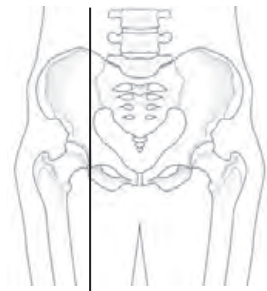


Figure 24.2.3

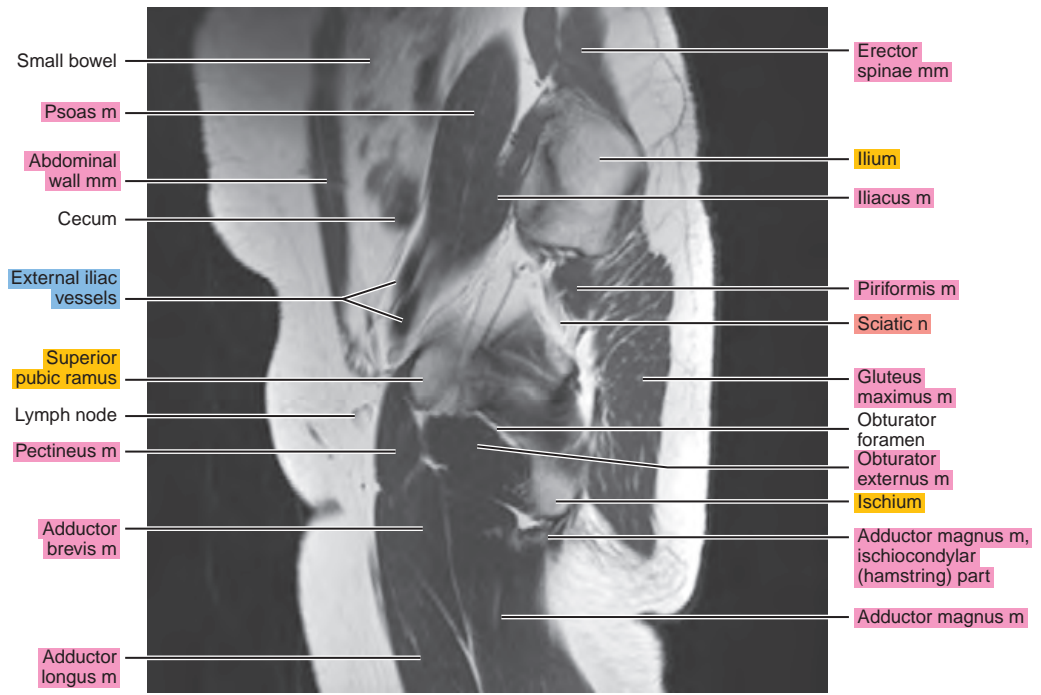
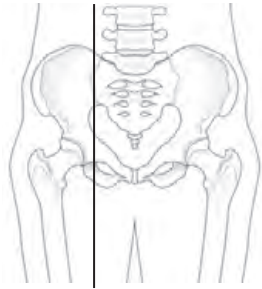


Figure 24.2.4

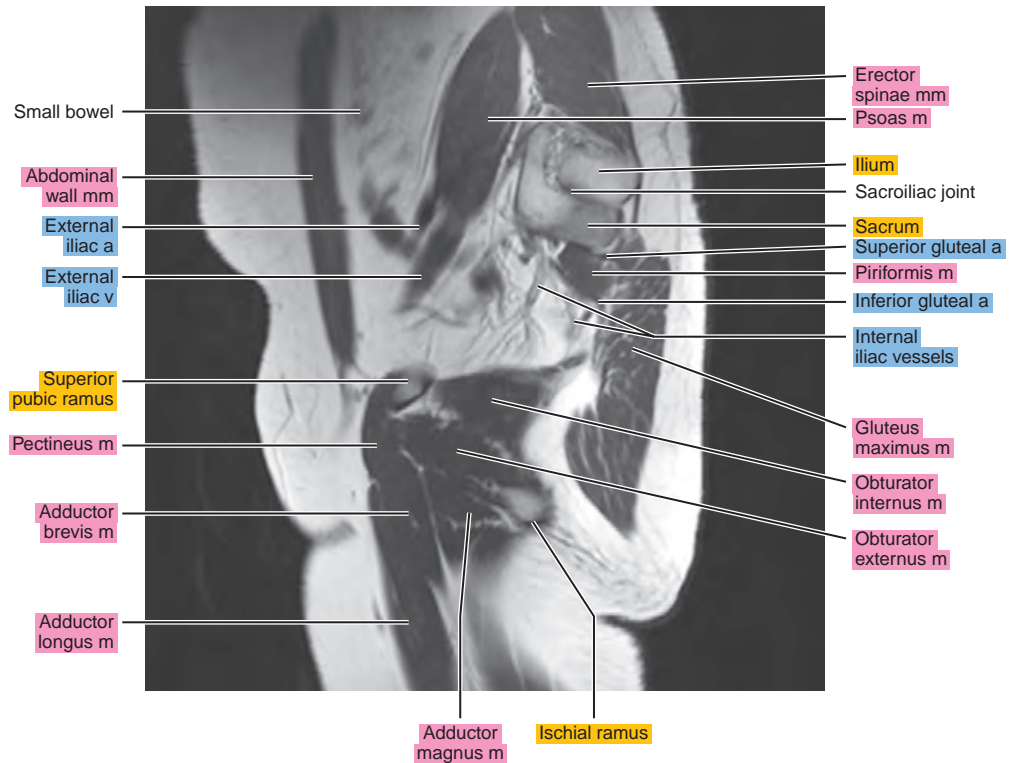
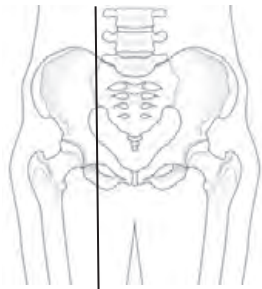


Figure 24.2.5

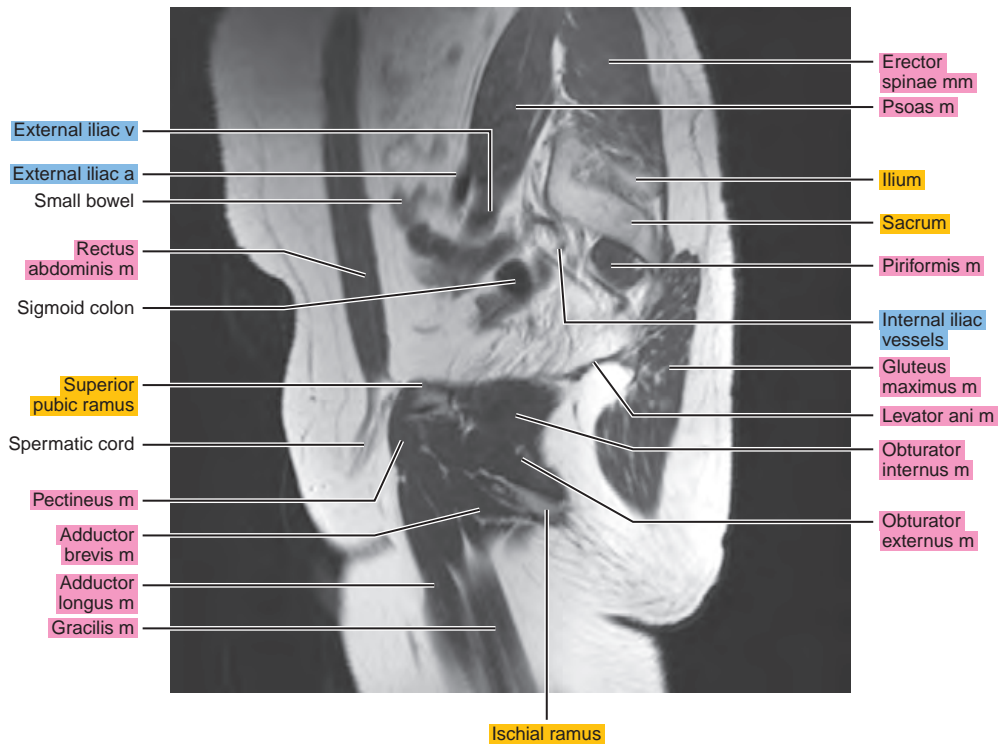
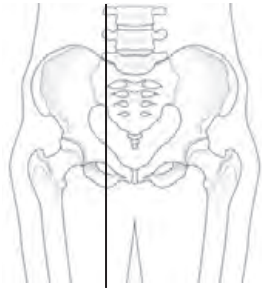


Figure 24.2.6

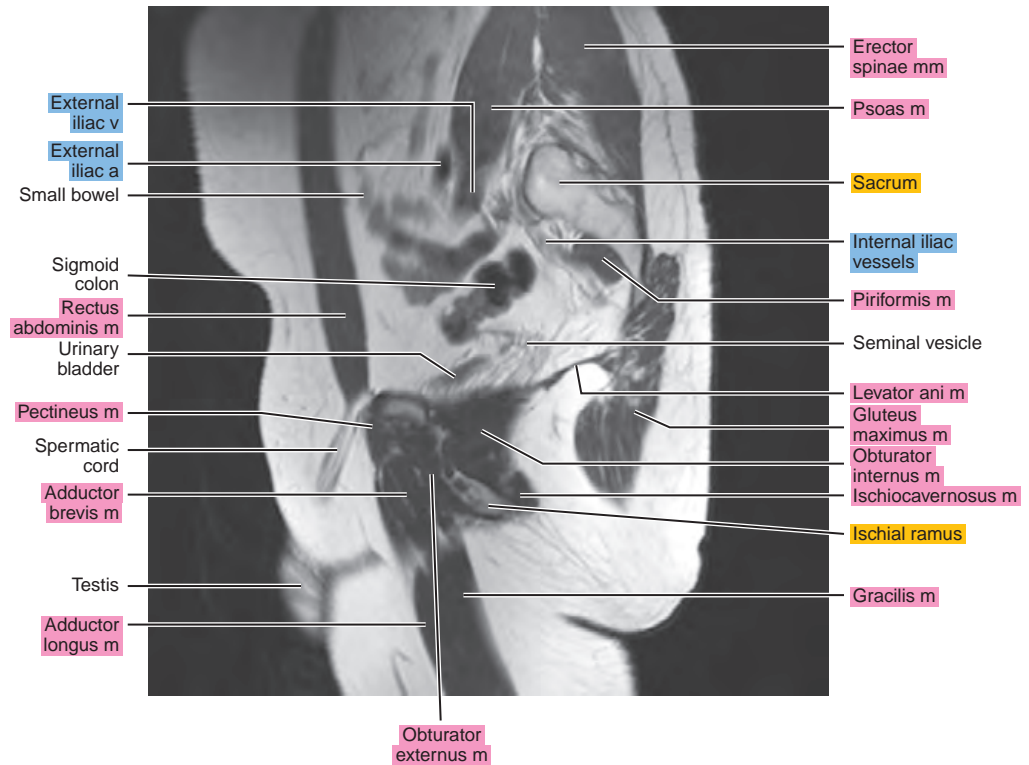
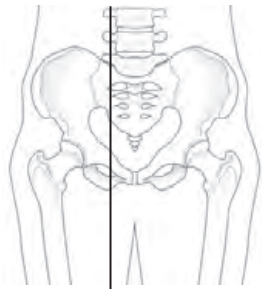


Figure 24.2.7

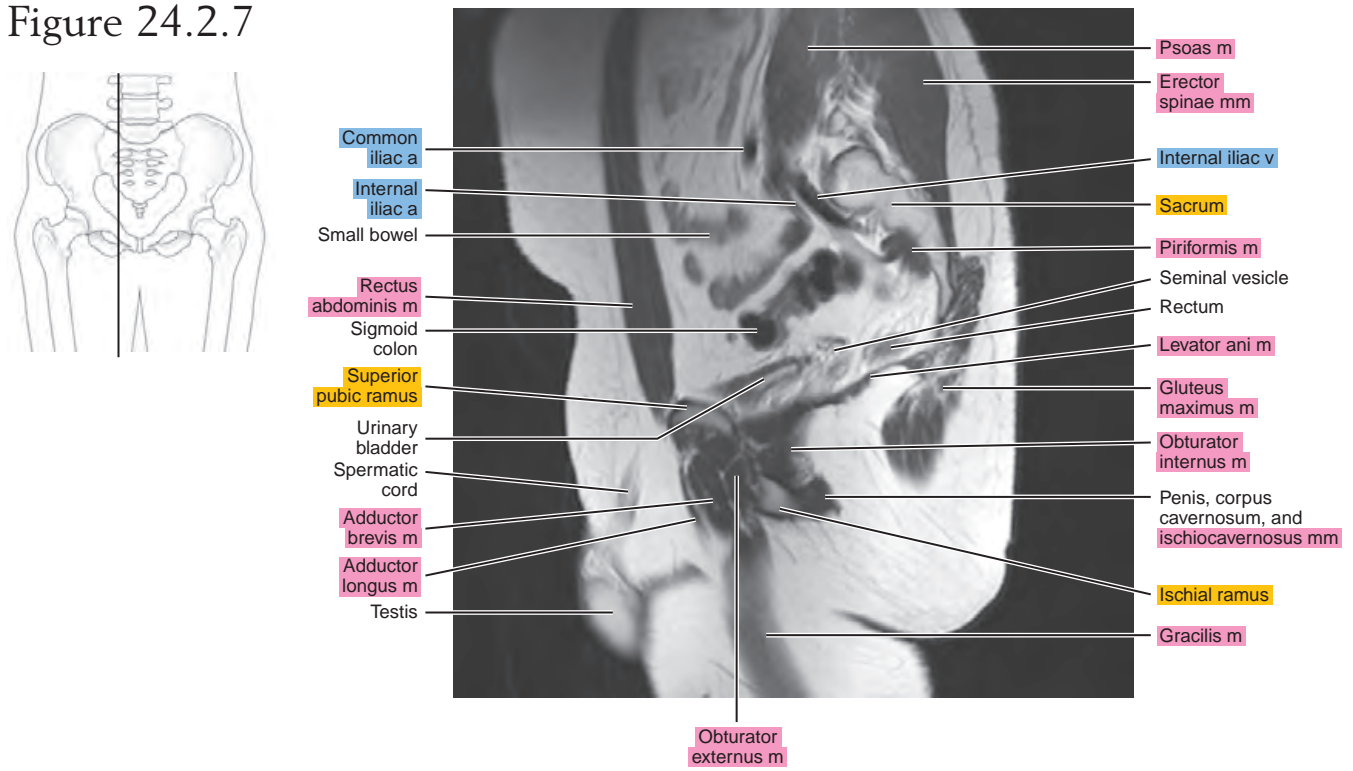


Figure 24.2.8

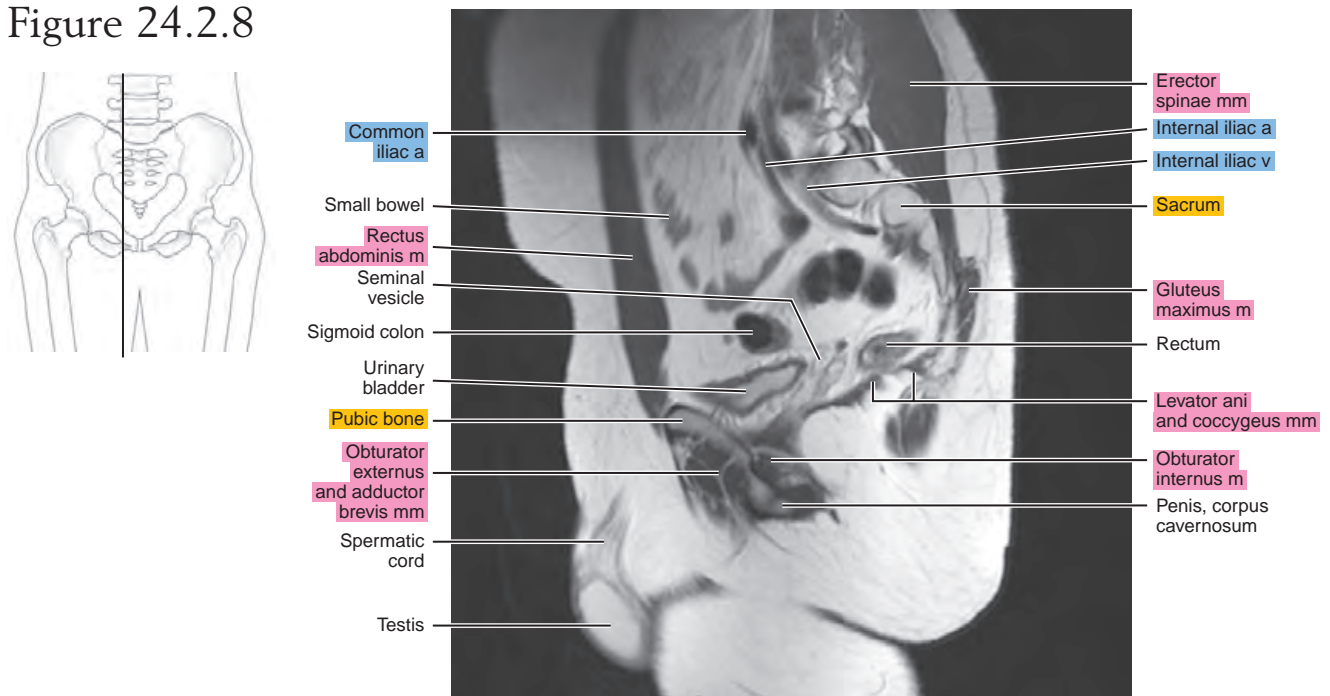


Figure 24.2.9

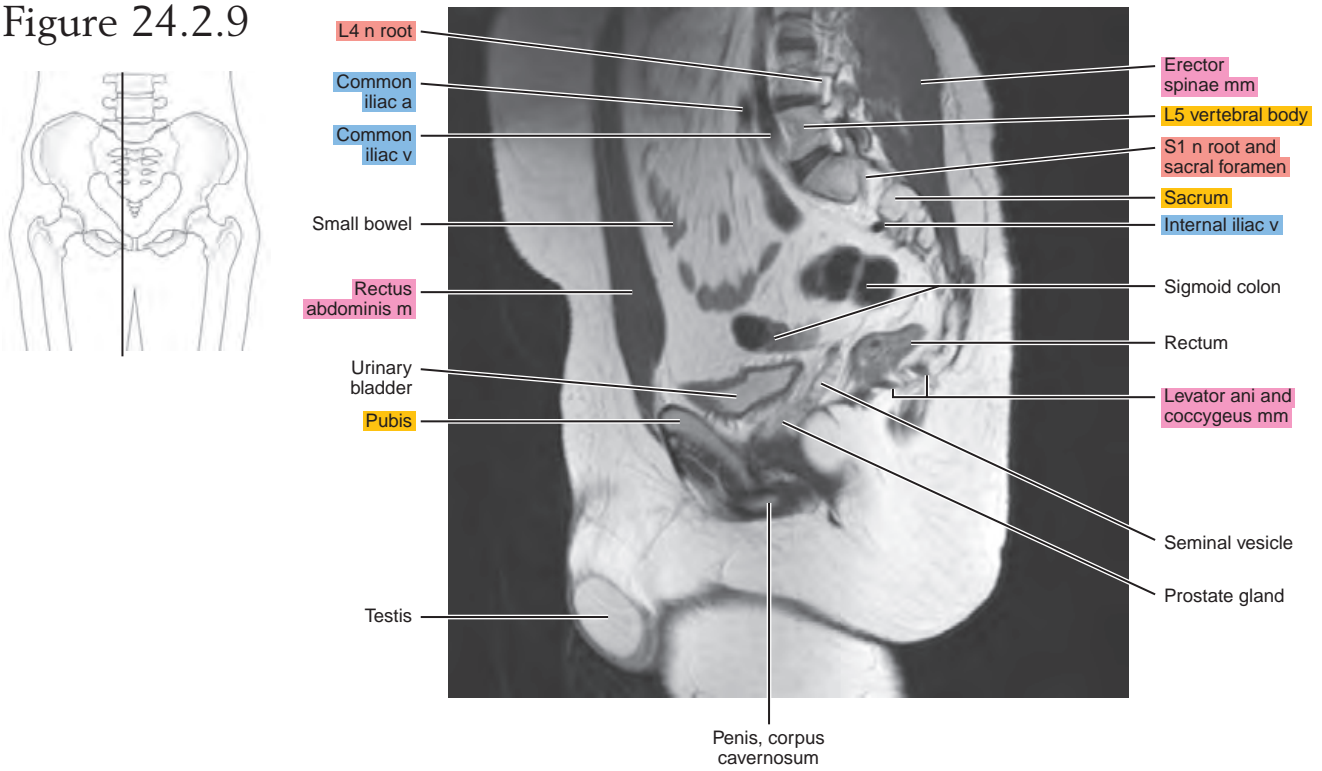


Figure 24.2.10

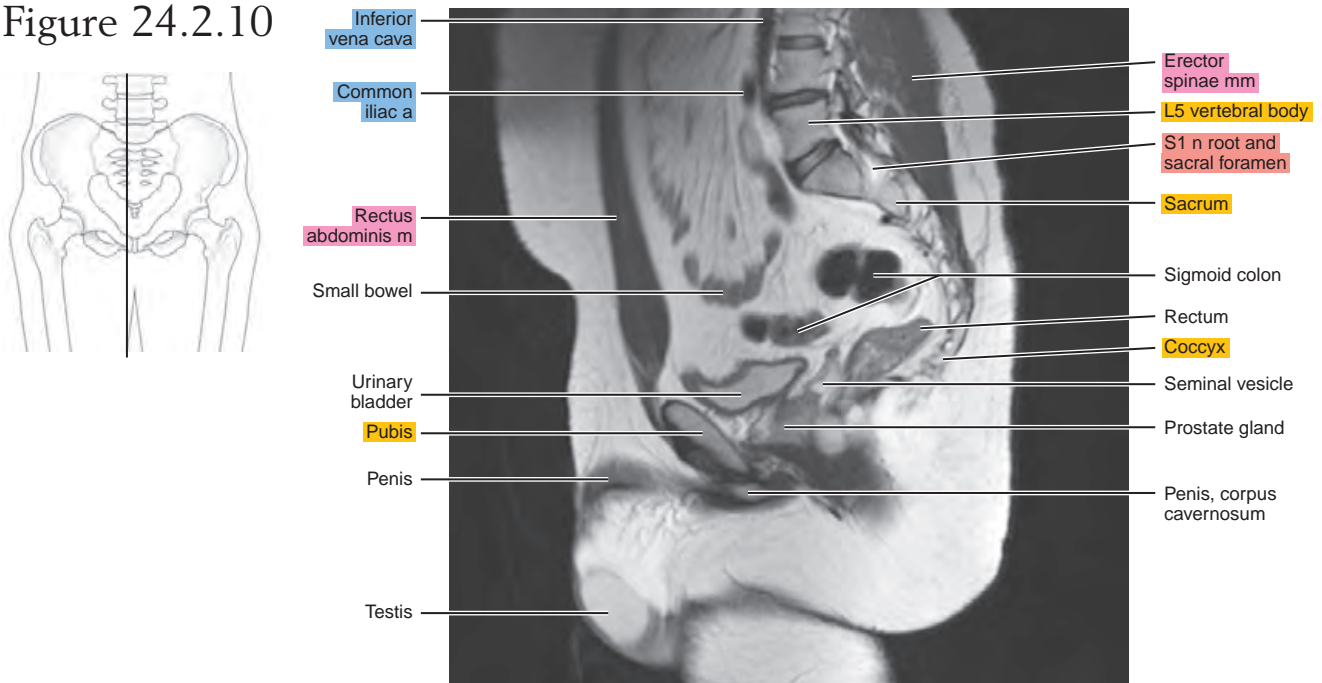


Figure 24.2.11

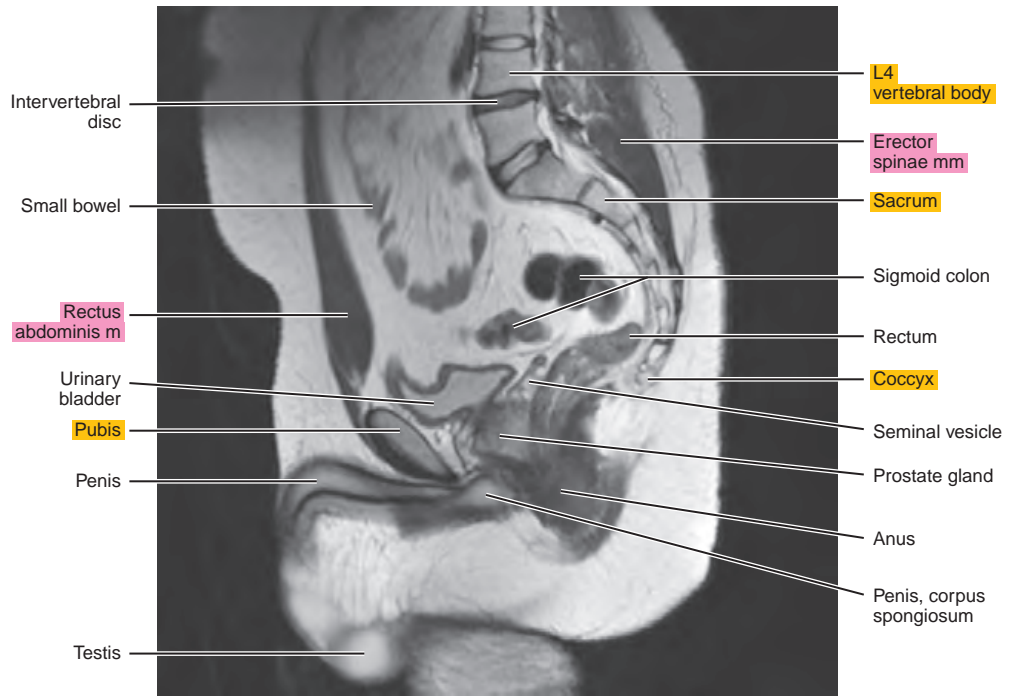
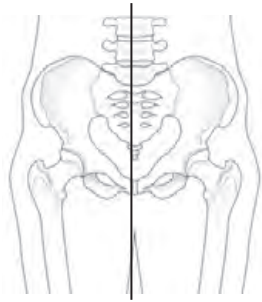
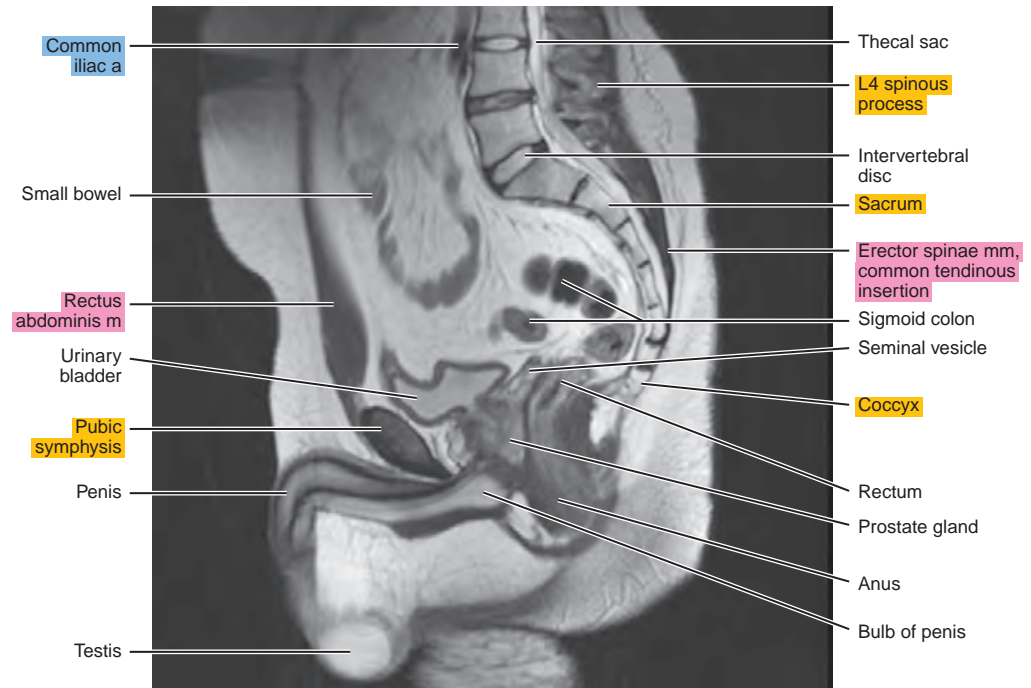
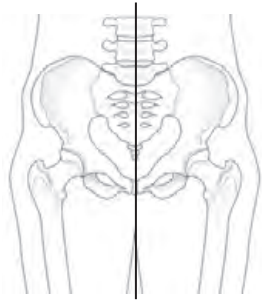


Figure 24.2.12



CORONAL

Figure 24.3.1

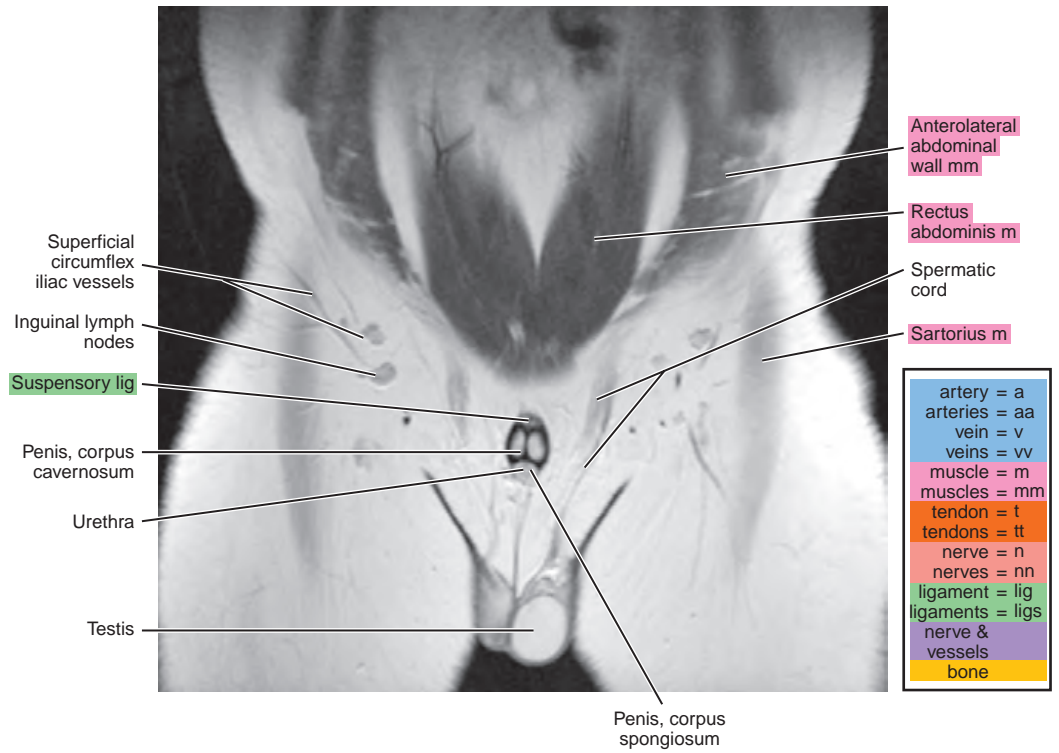
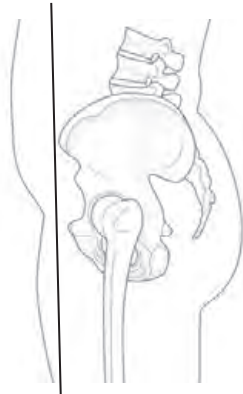


Figure 24.3.2

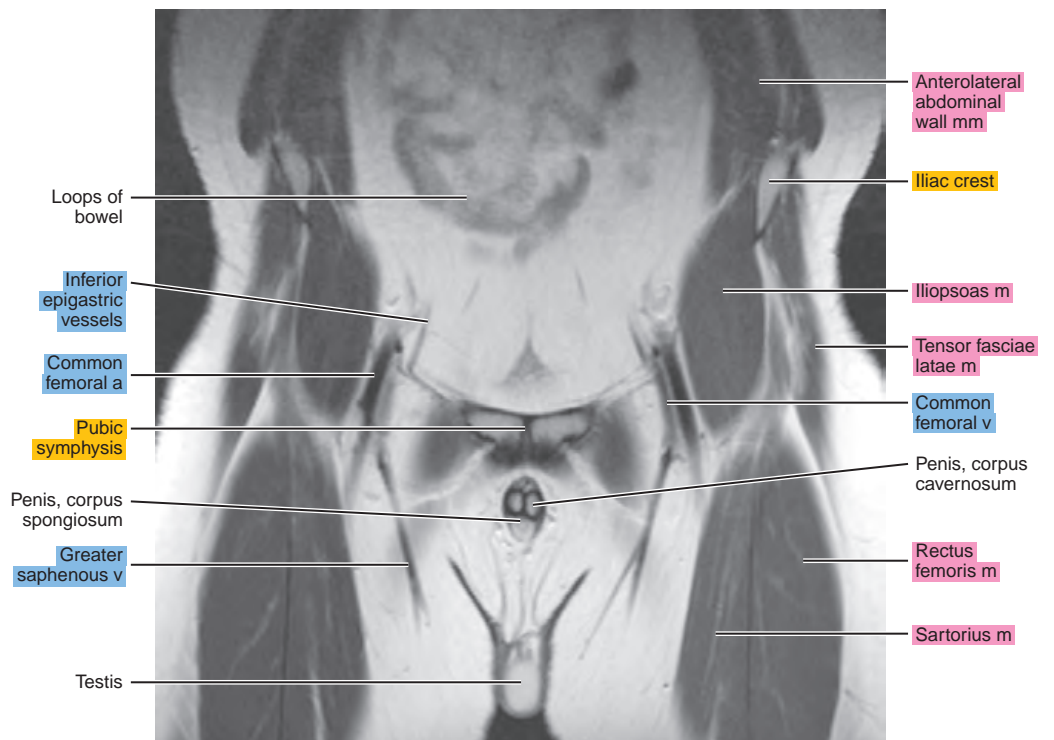
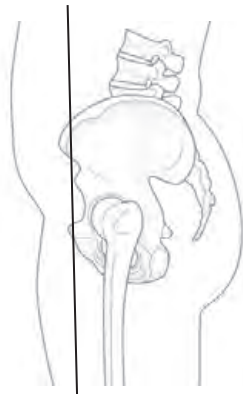


Figure 24.3.3

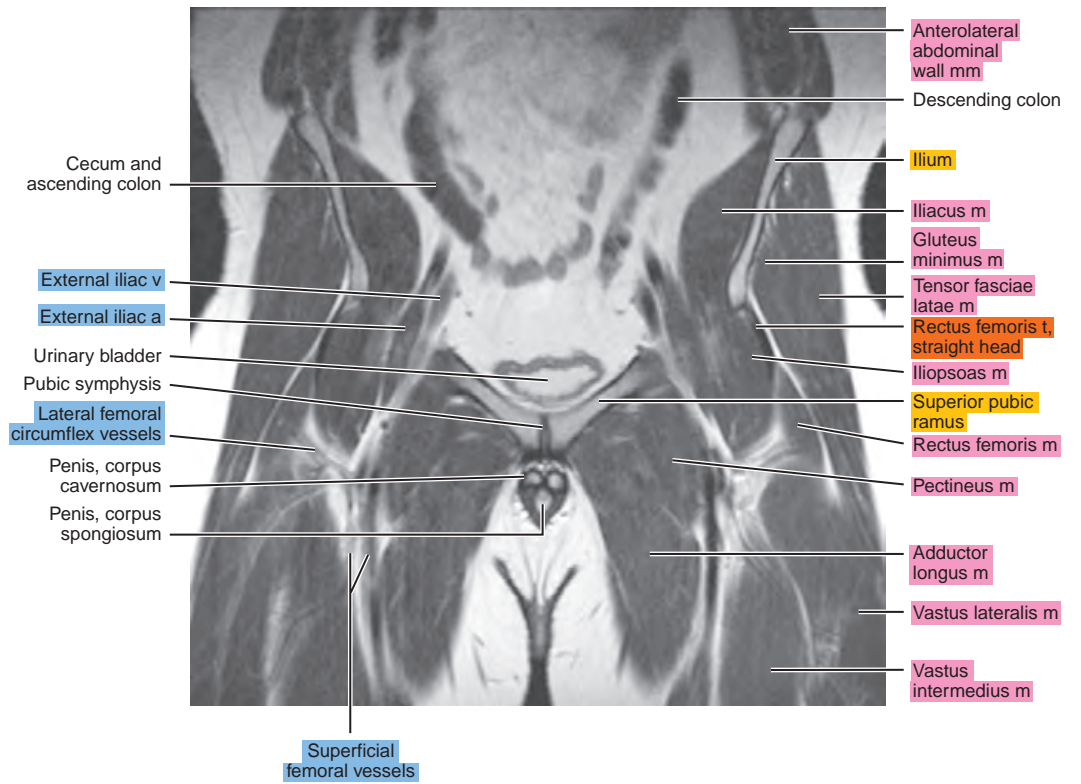
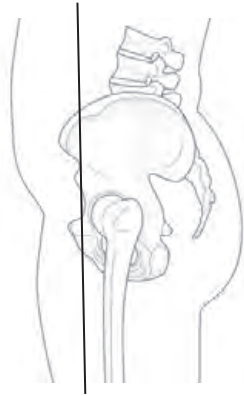


Figure 24.3.4

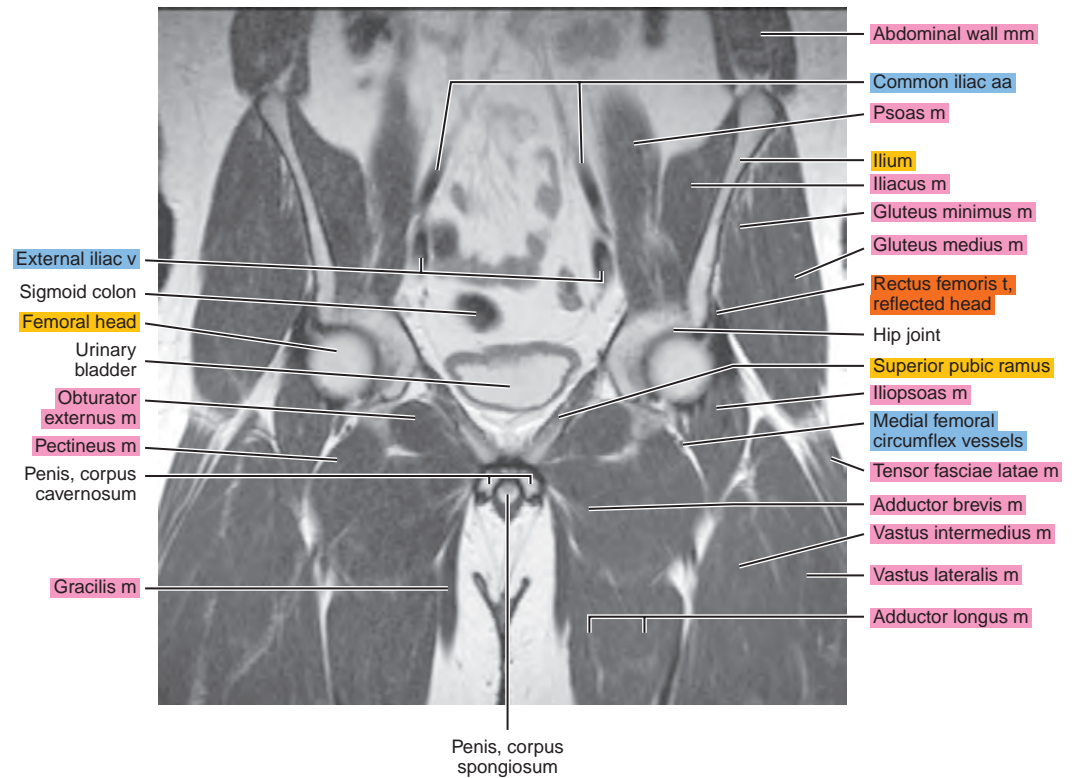
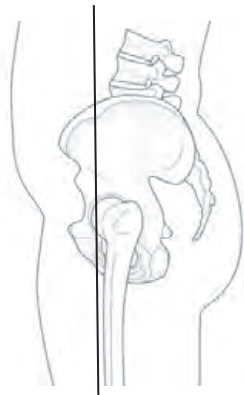


Figure 24.3.5

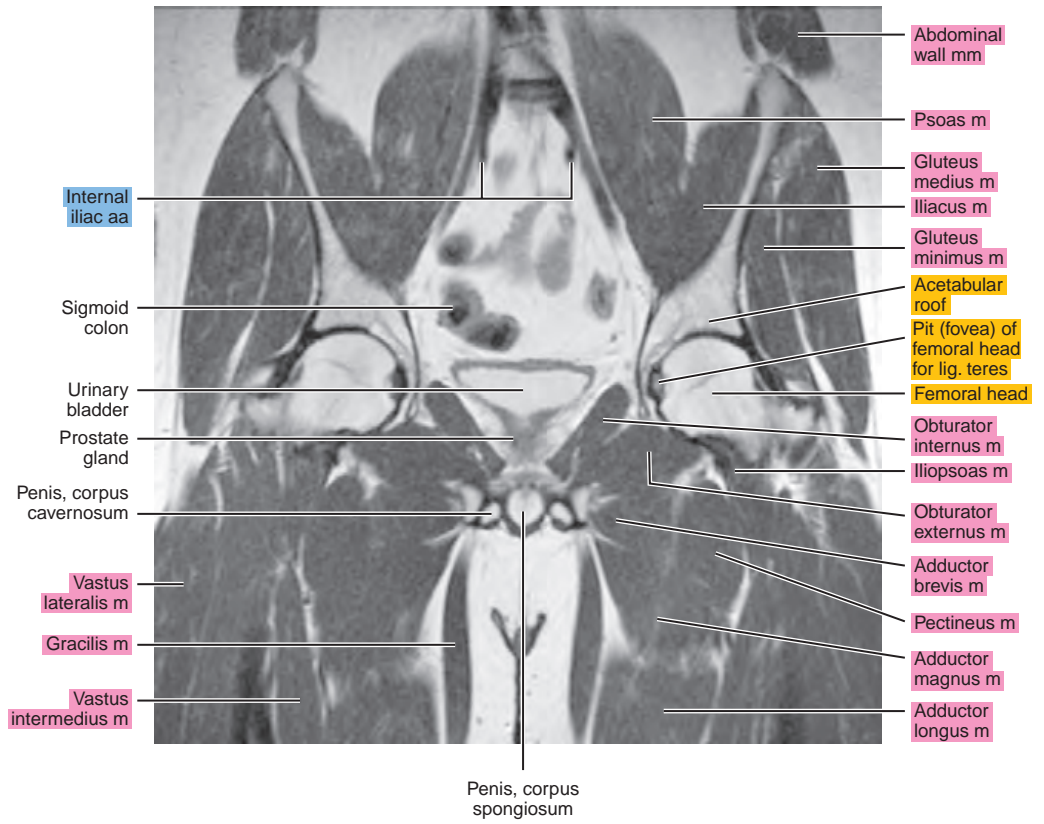
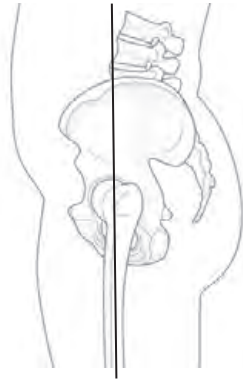


Figure 24.3.6

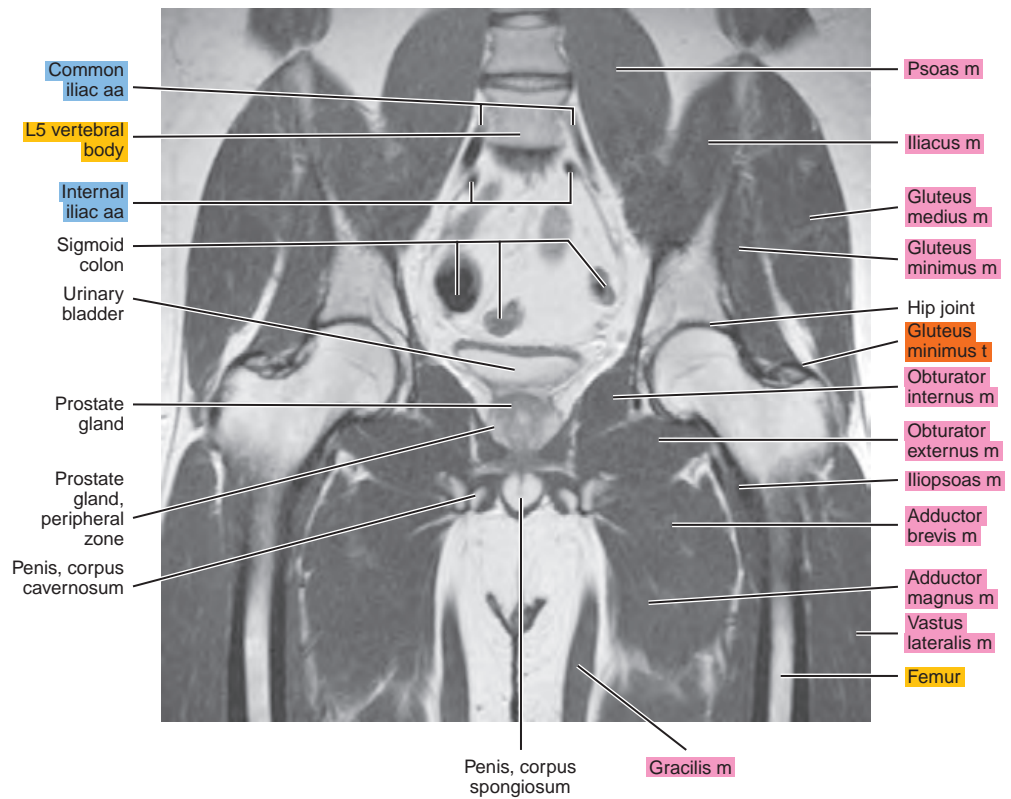
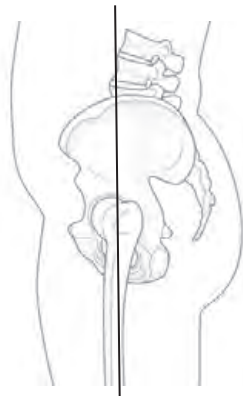


Figure 24.3.7

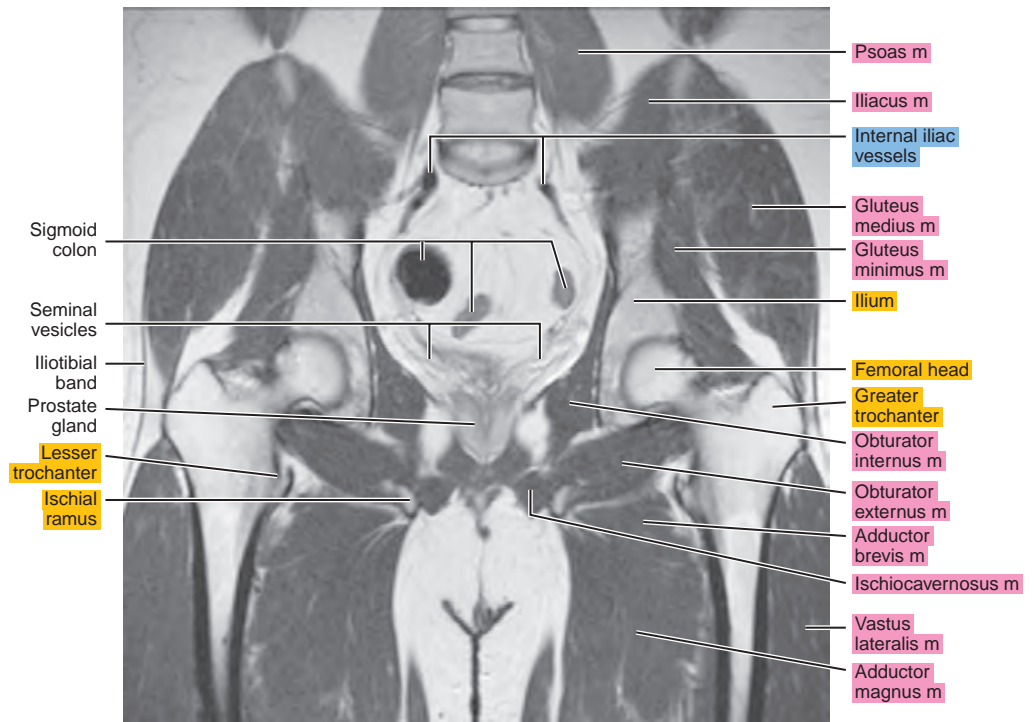
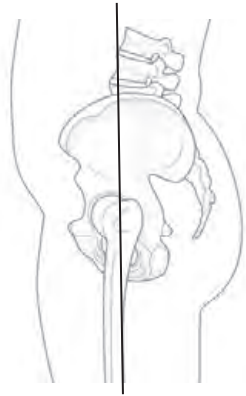


Figure 24.3.8

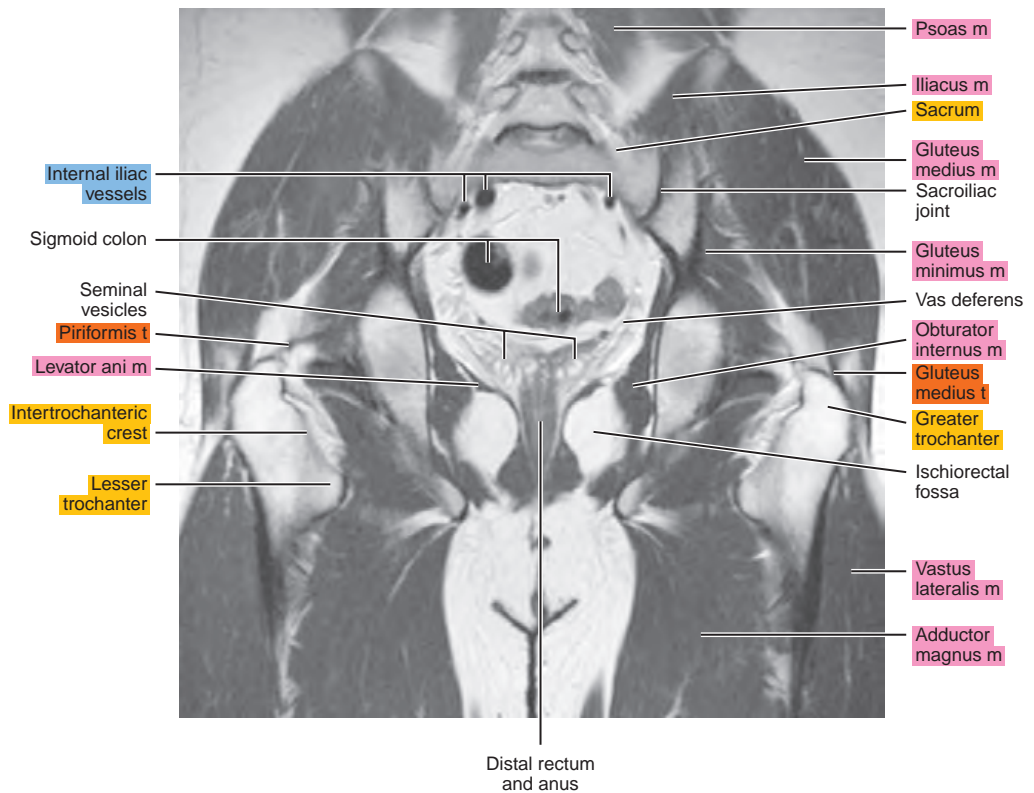
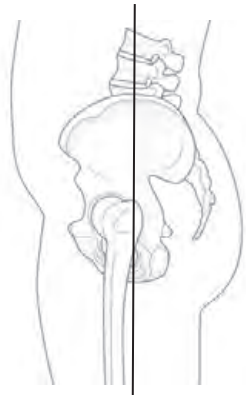


Figure 24.3.9

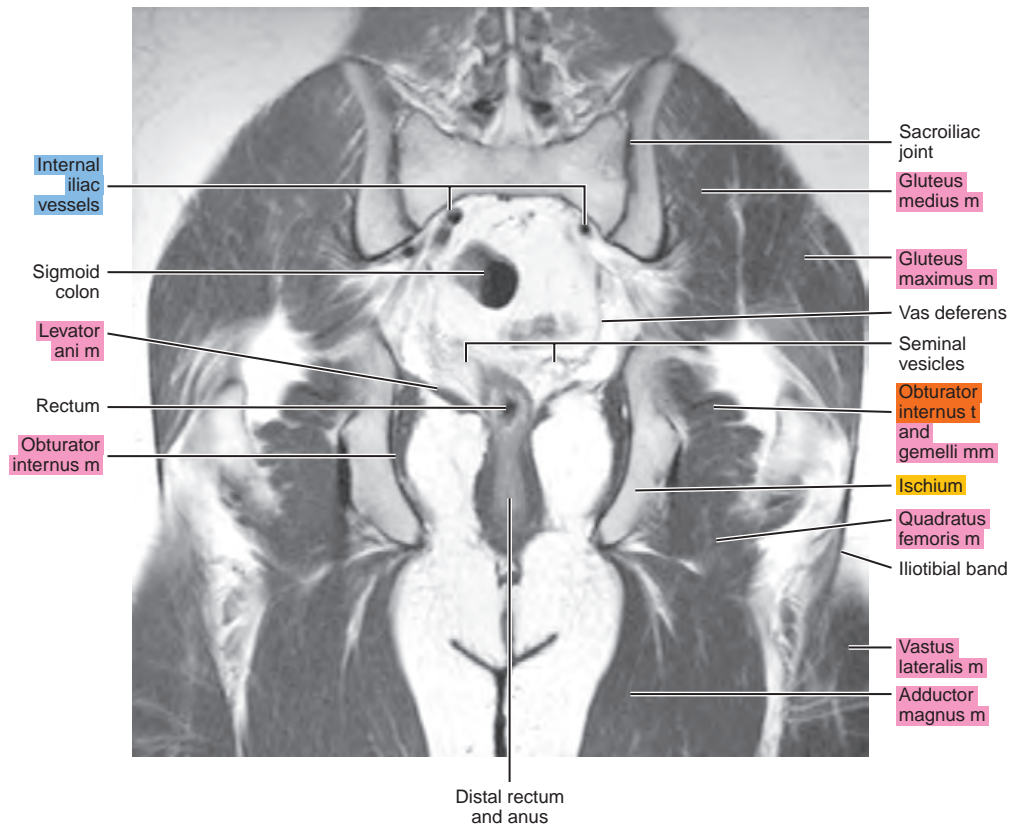
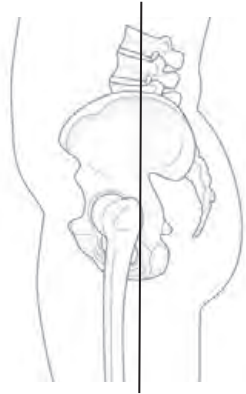


Figure 24.3.10

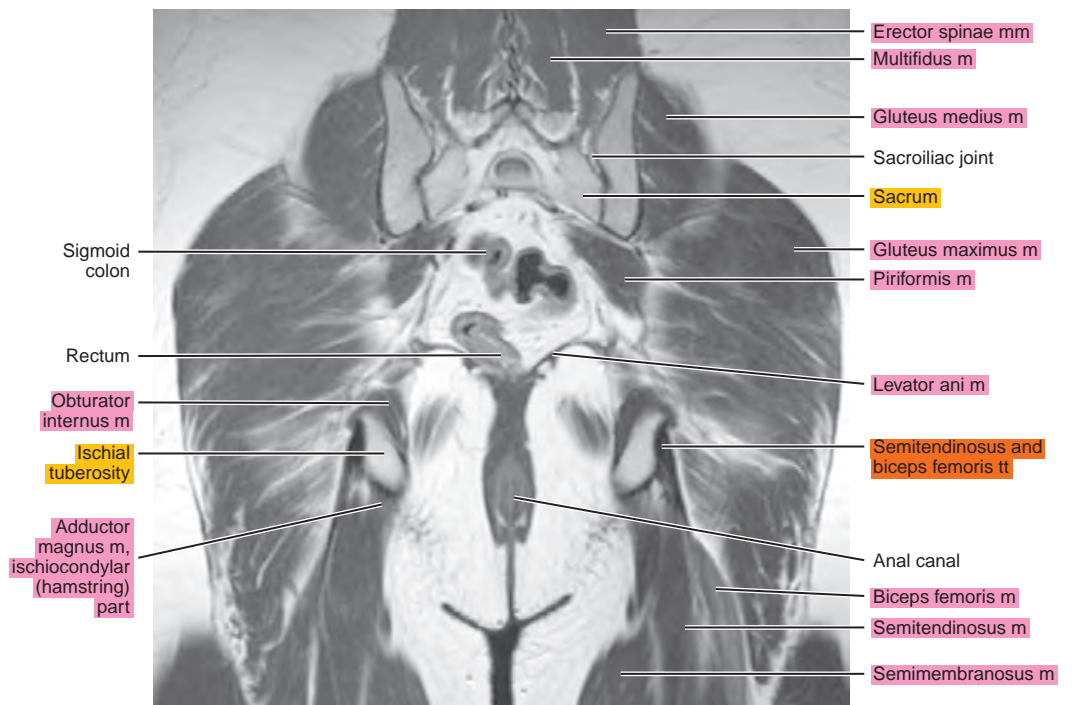
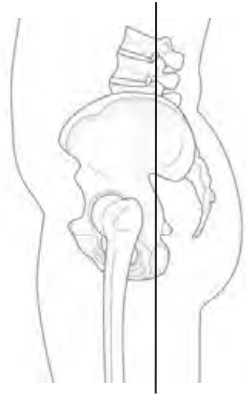


Figure 24.3.11

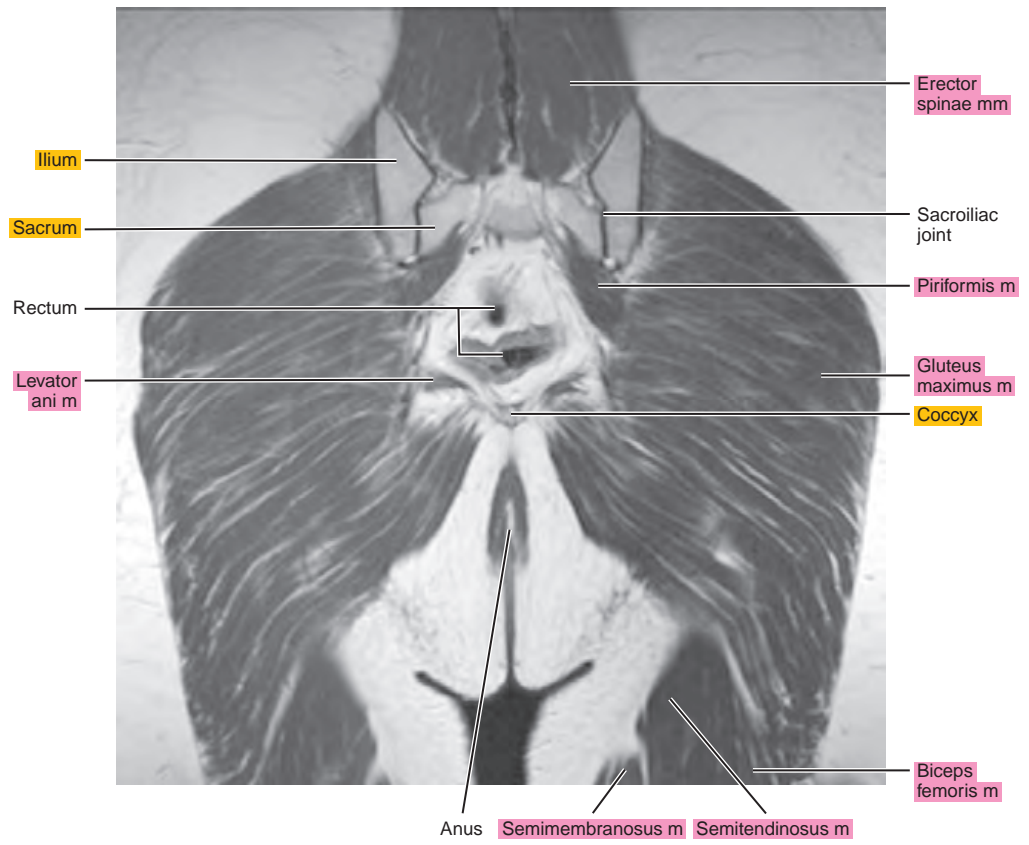
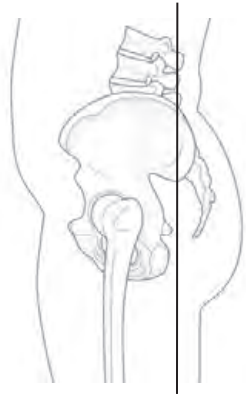
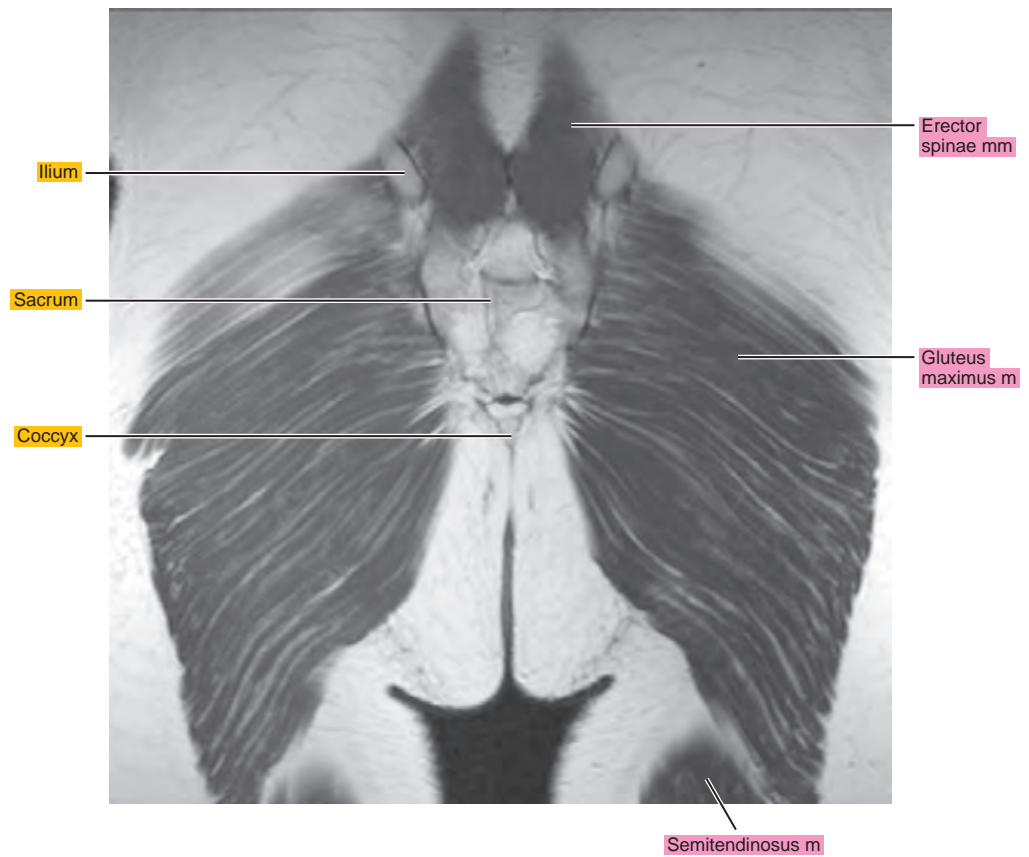
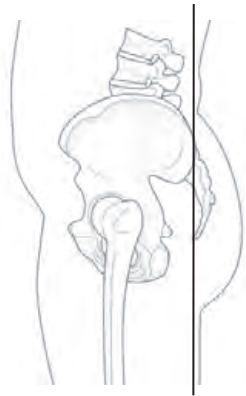

Figure 24.3.12



Chapter
25

MRI of the Female Pelvis

AXIAL

Figure 25.1.1

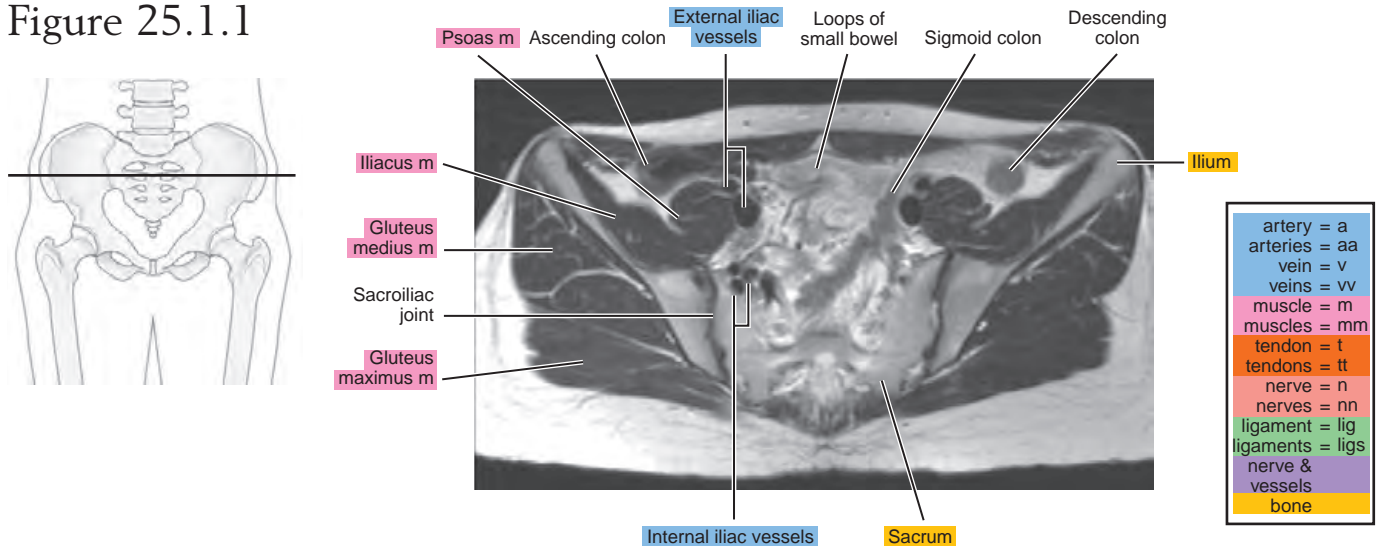


Figure 25.1.2

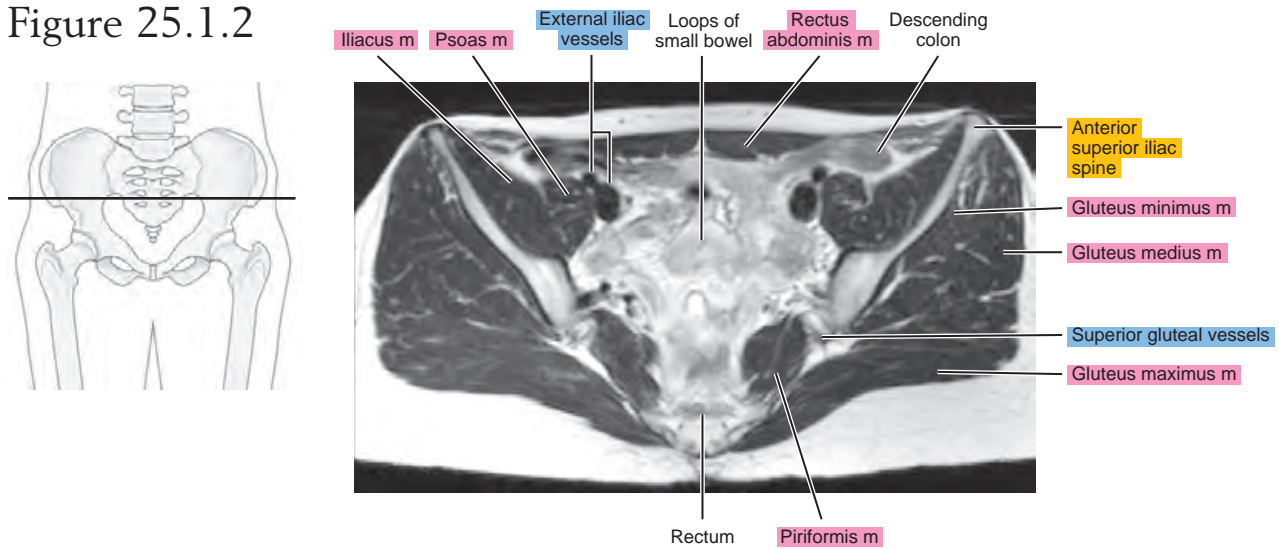


Figure 25.1.3

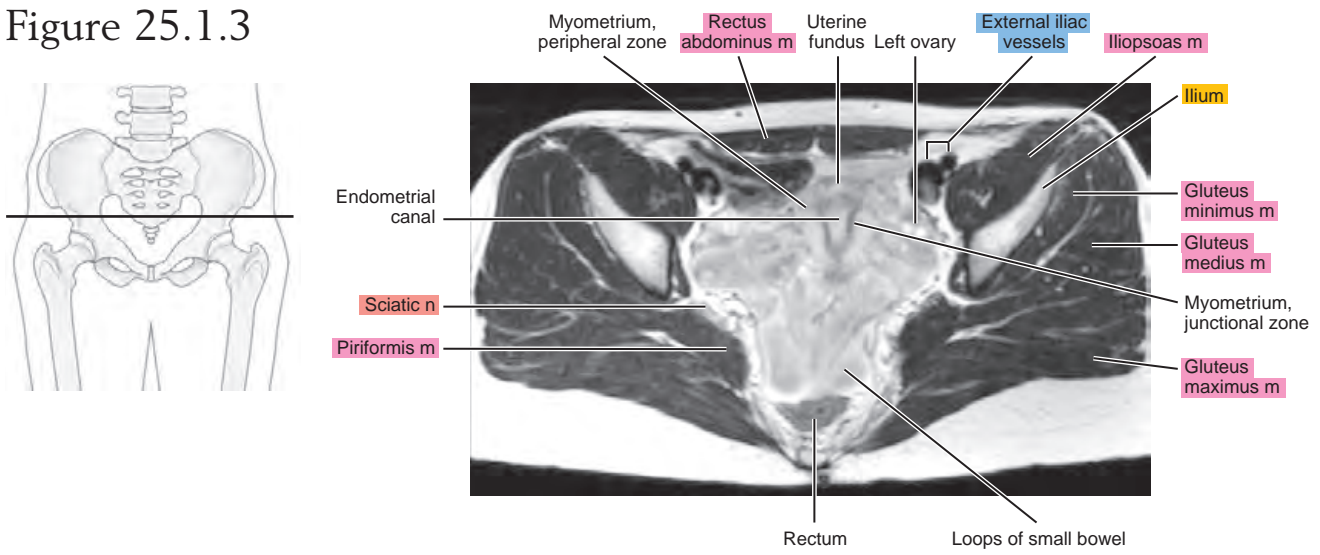


Figure 25.1.4

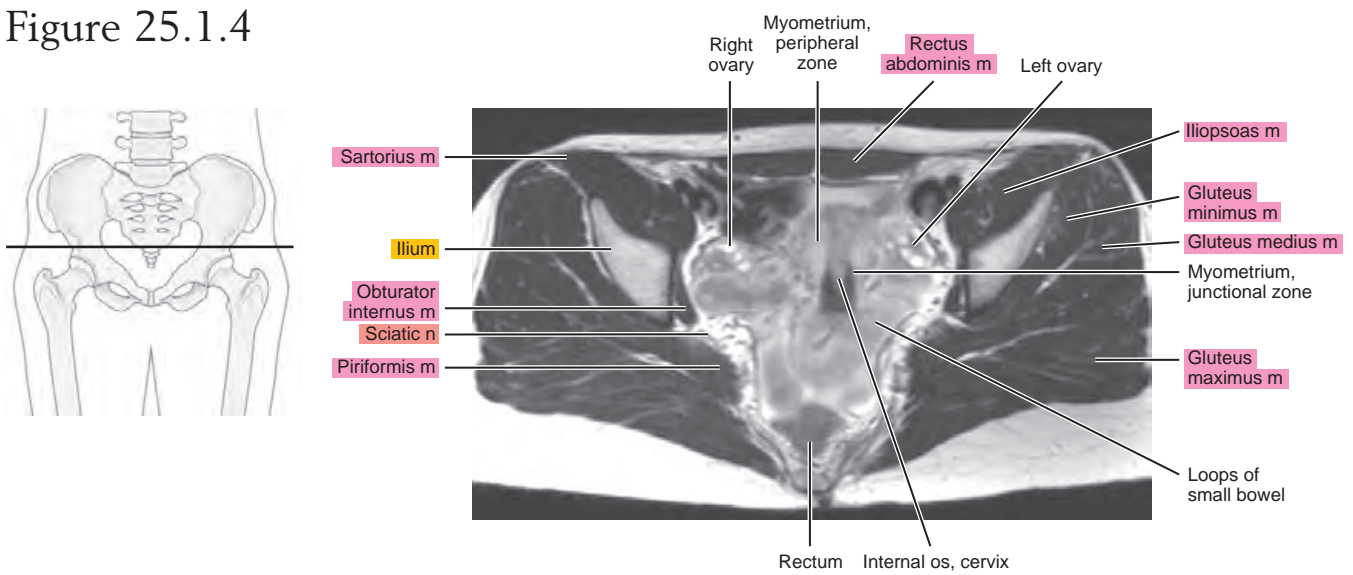


Figure 25.1.5

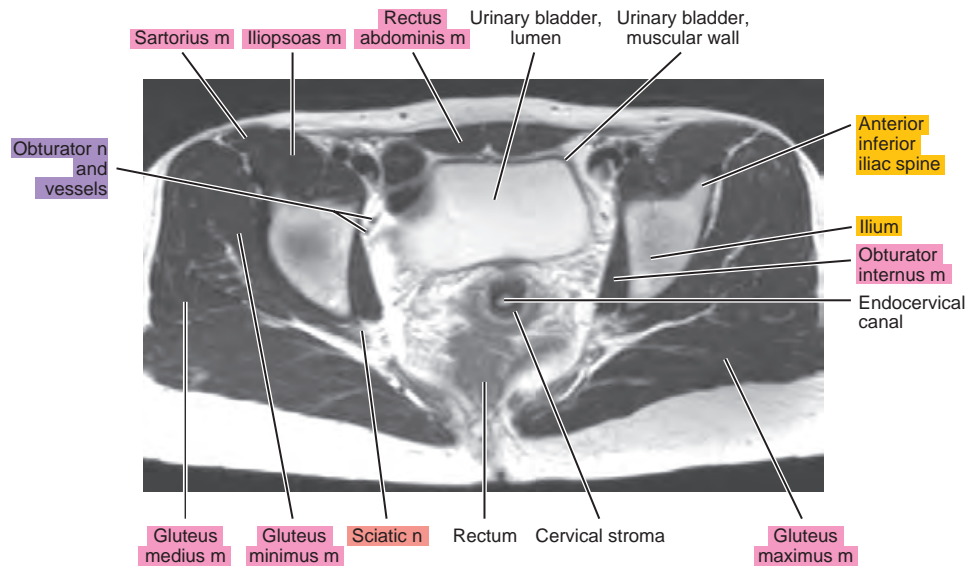
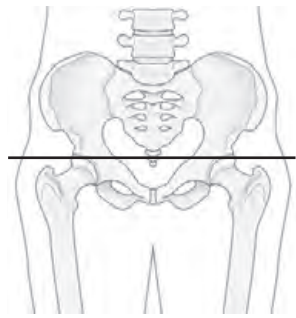


Figure 25.1.6

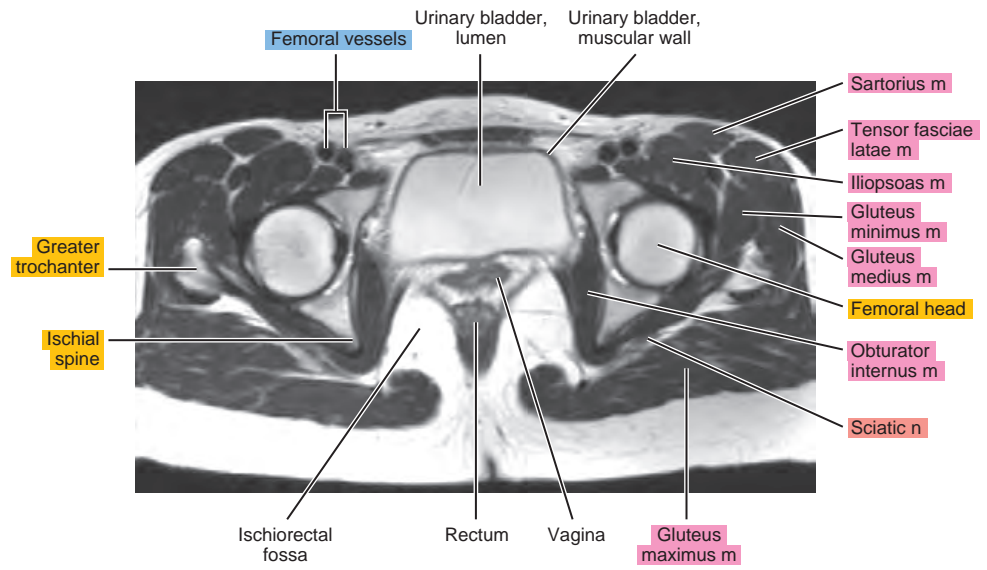
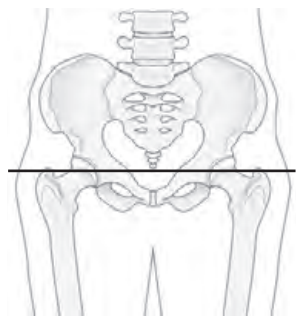


Figure 25.1.7

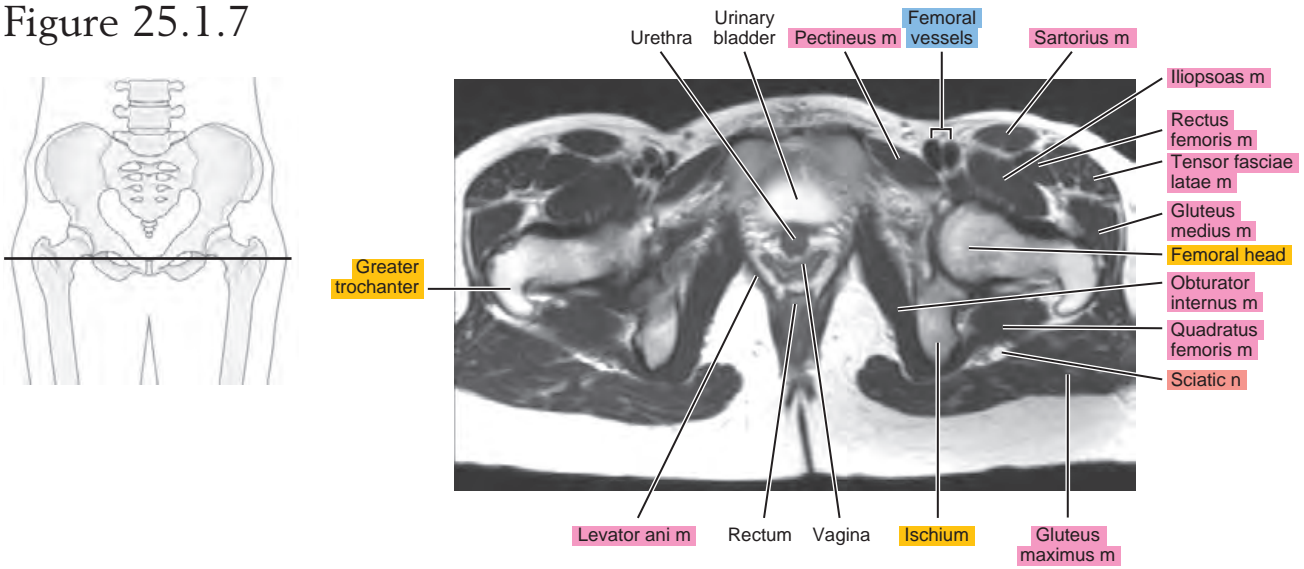
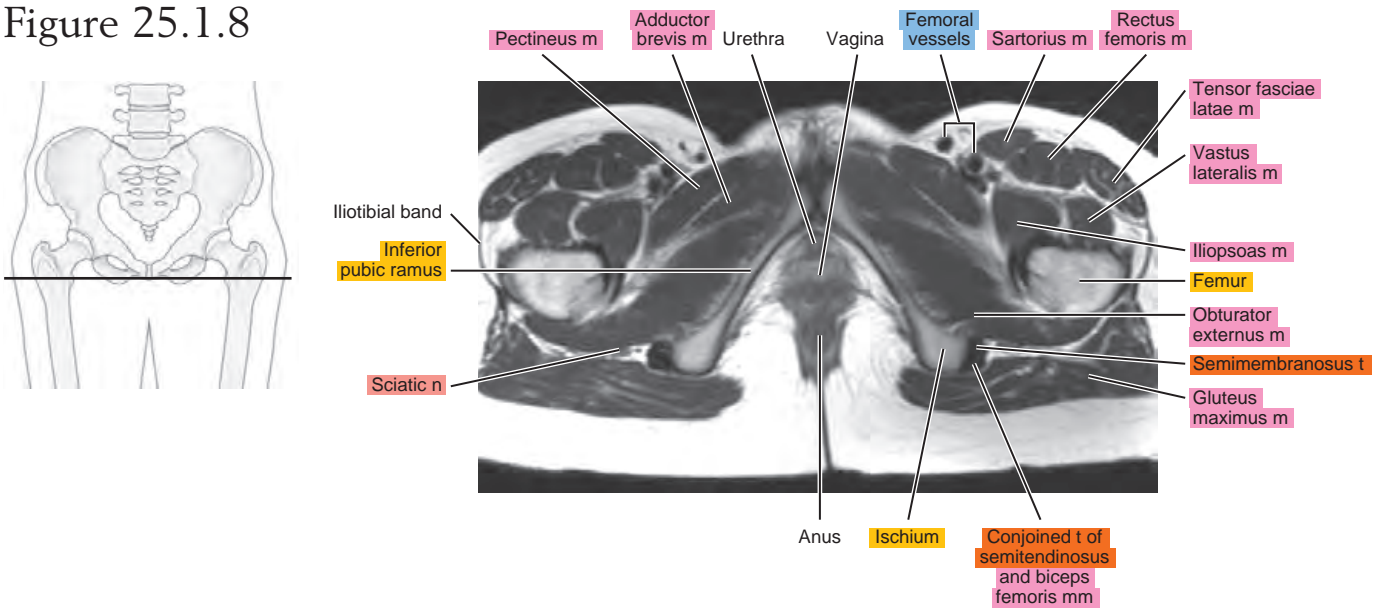


Figure 25.1.8



SAGITTAL

Figure 25.2.1

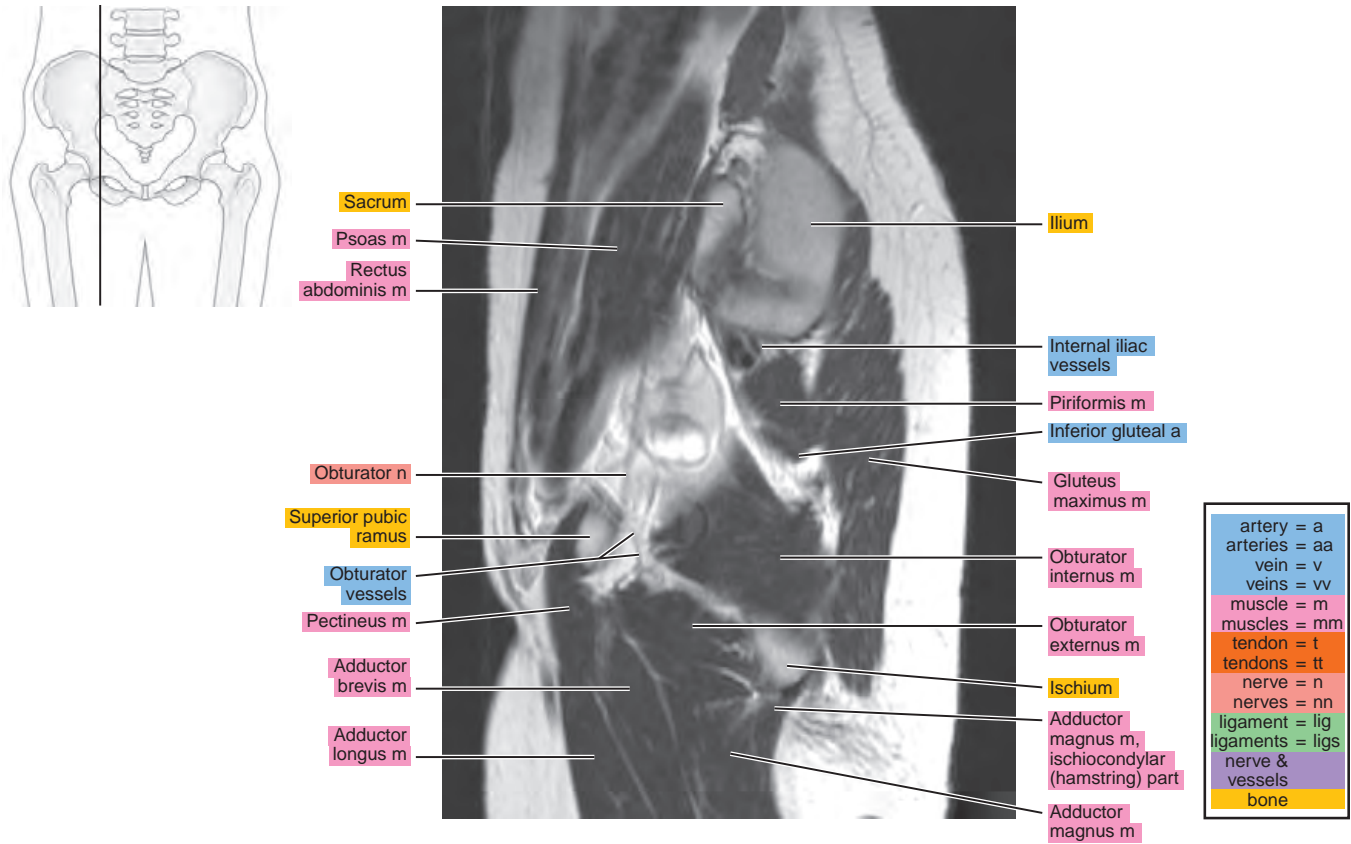


Figure 25.2.2

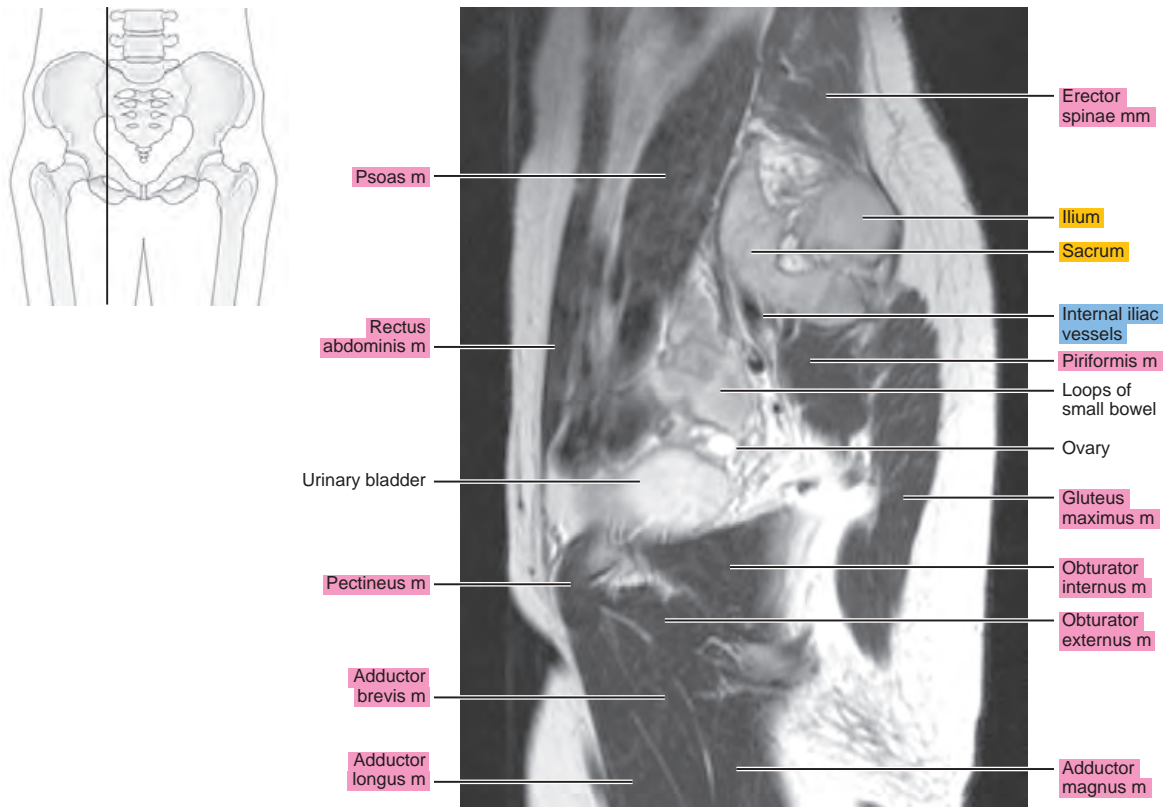


Figure 25.2.3

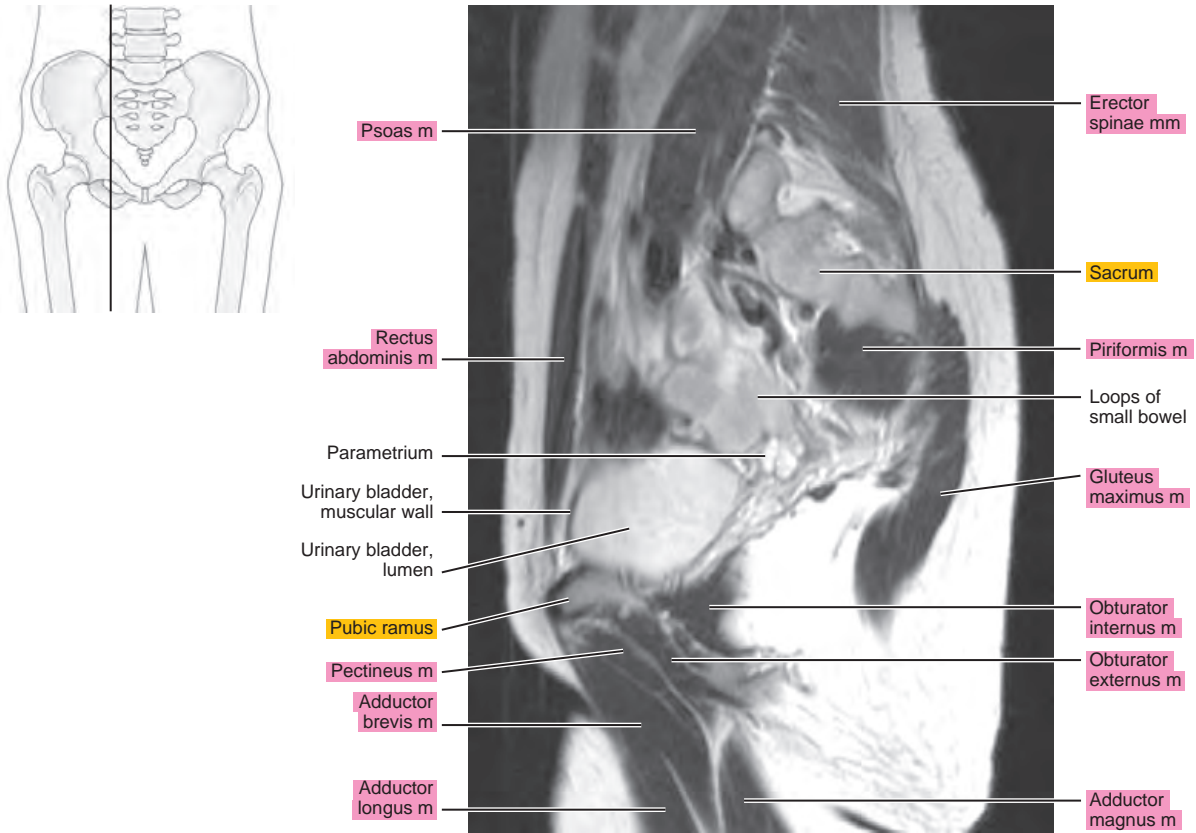


Figure 25.2.4

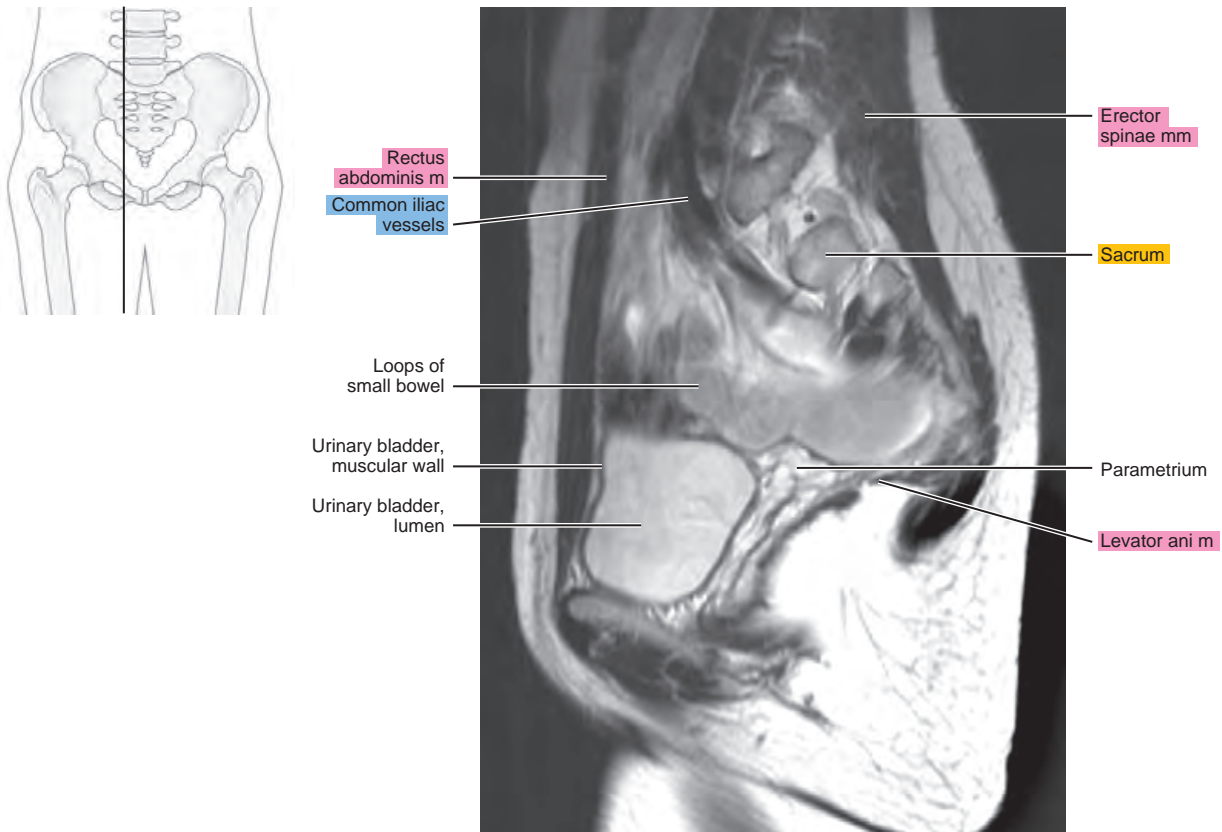


Figure 25.2.5

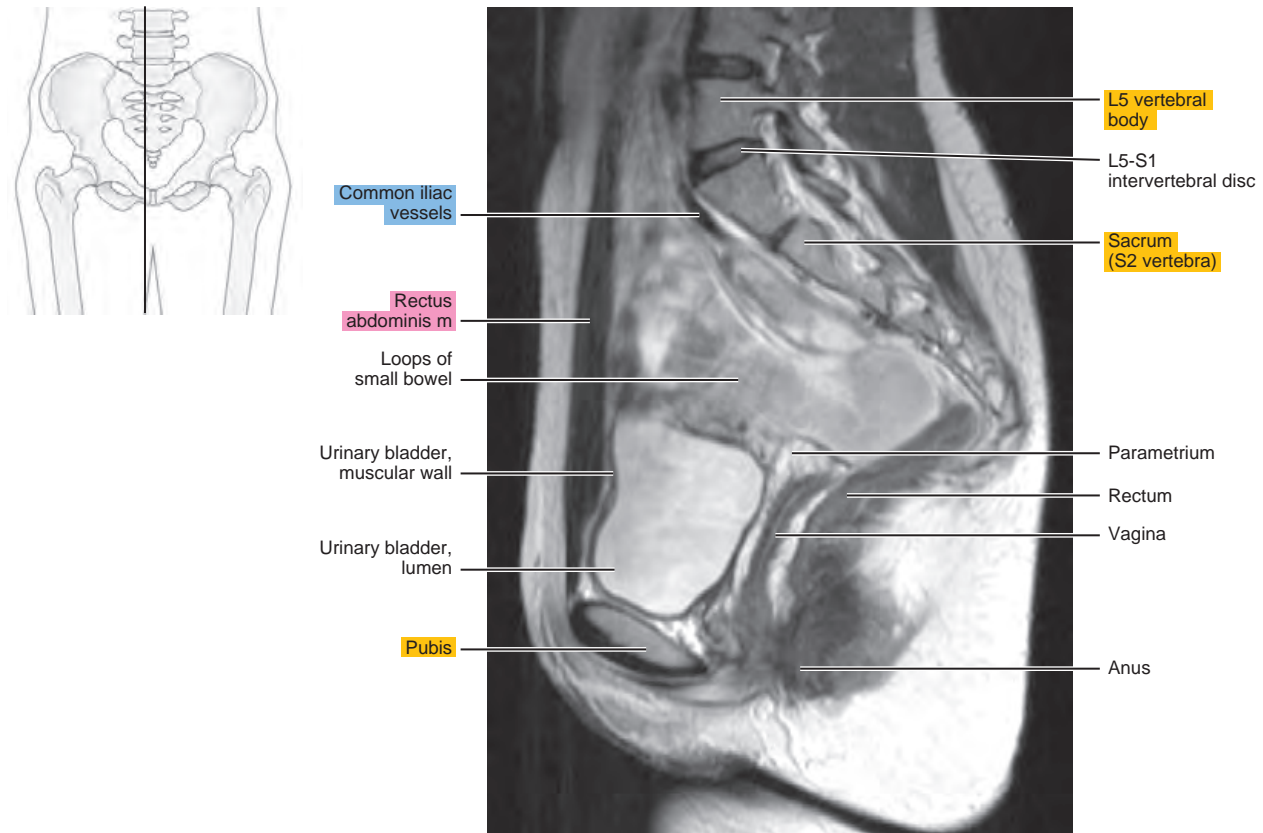


Figure 25.2.6

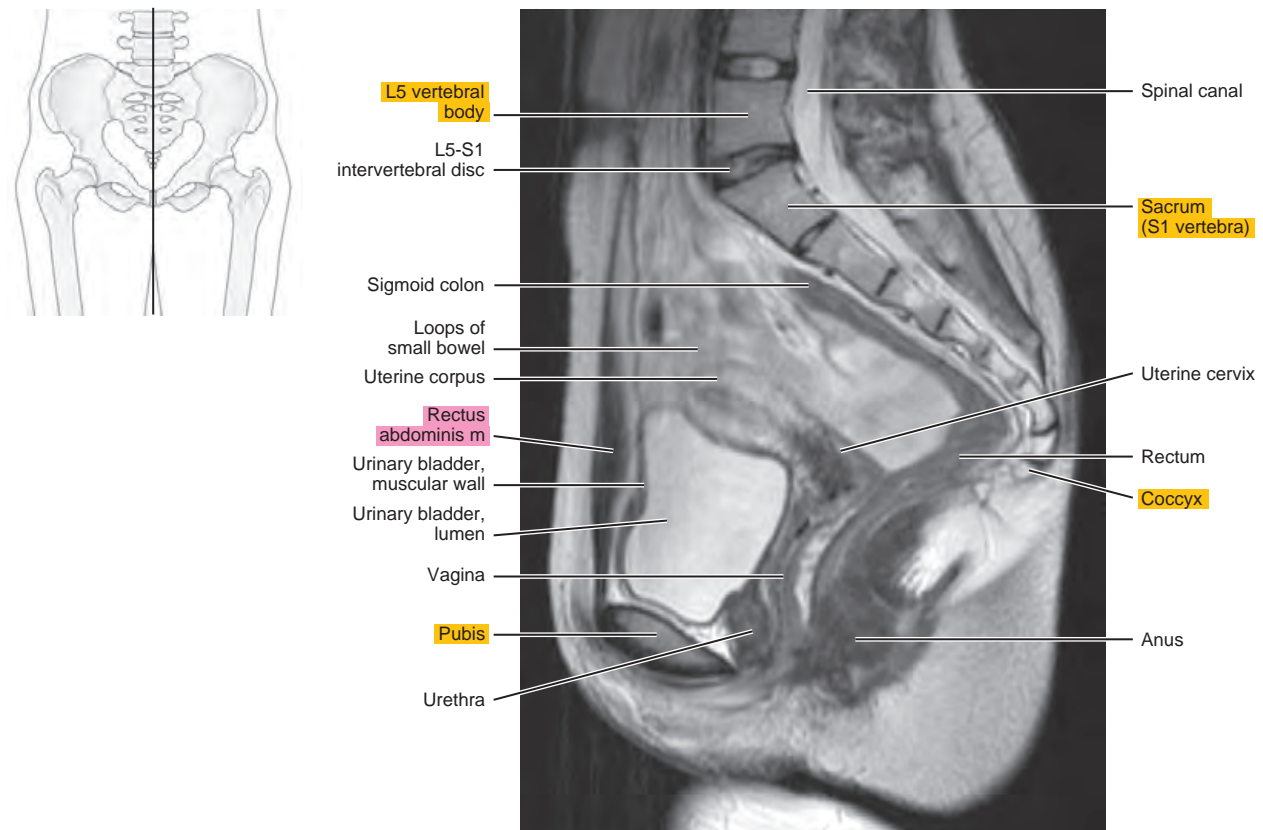
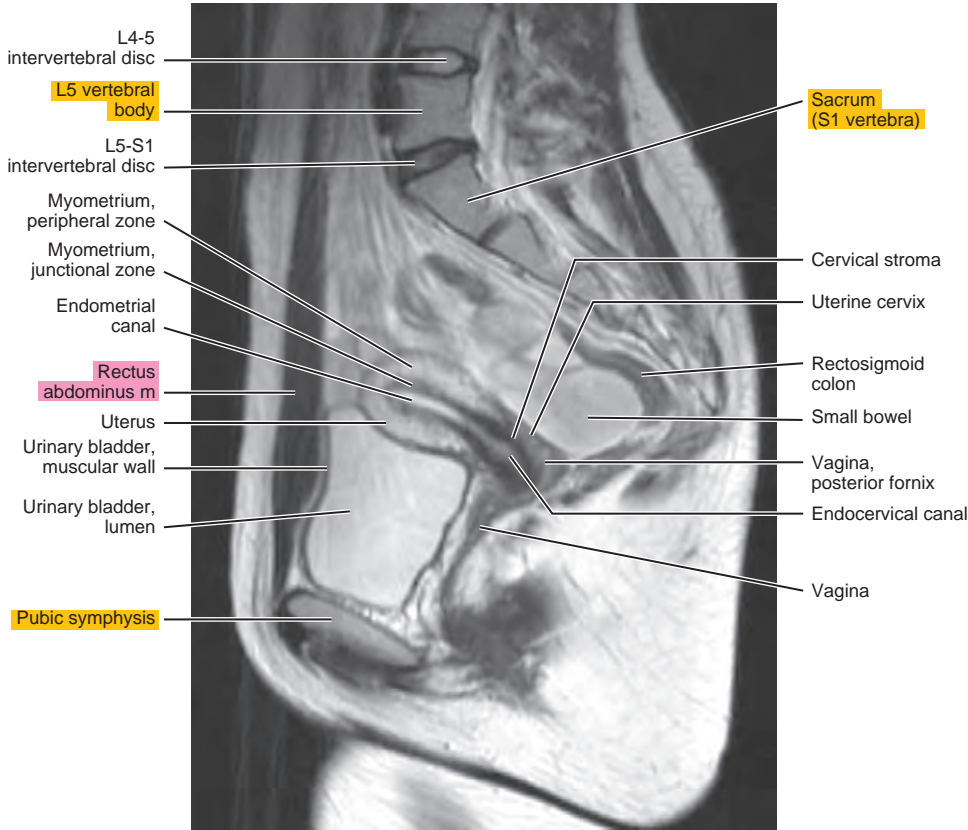
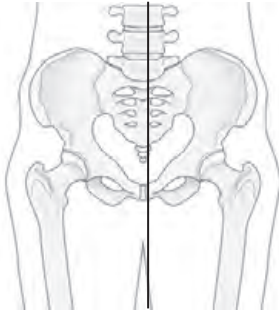


Figure 25.2.7



CORONAL

Figure 25.3.1

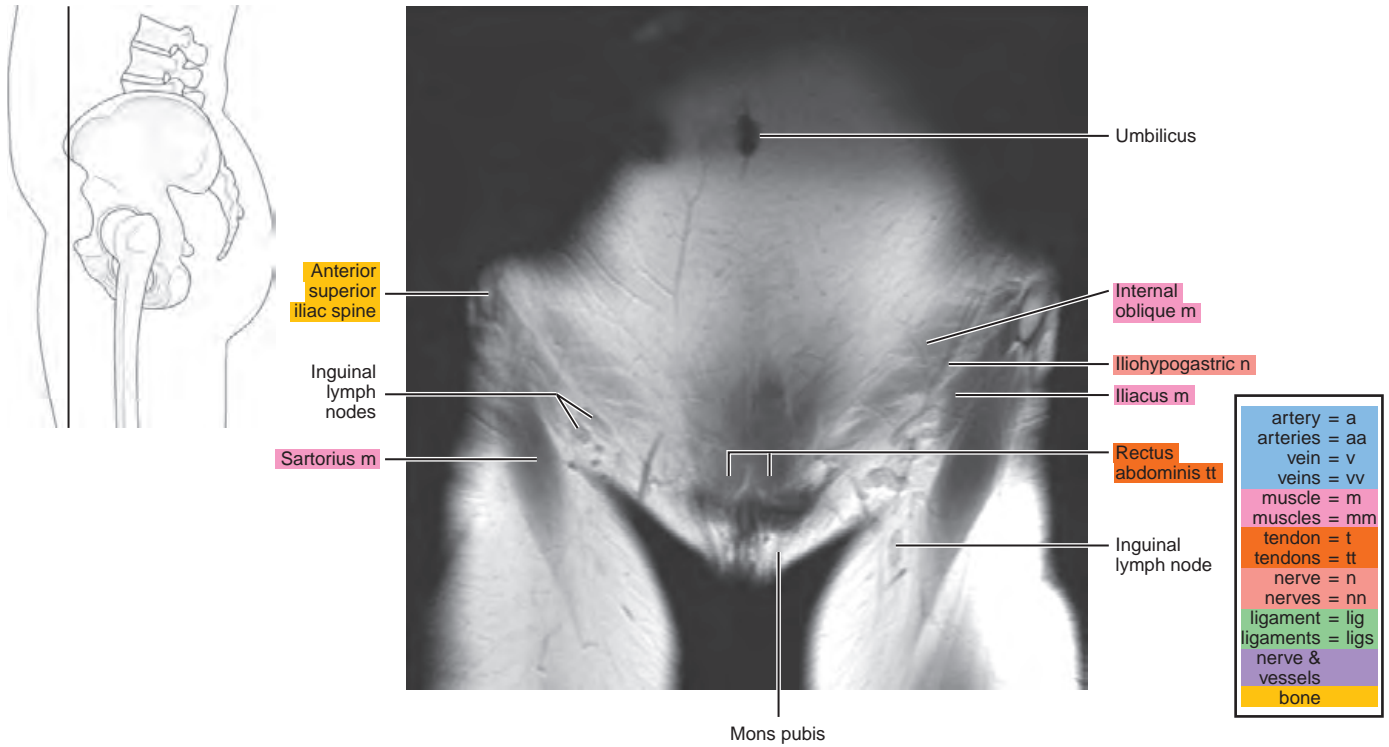


Figure 25.3.2

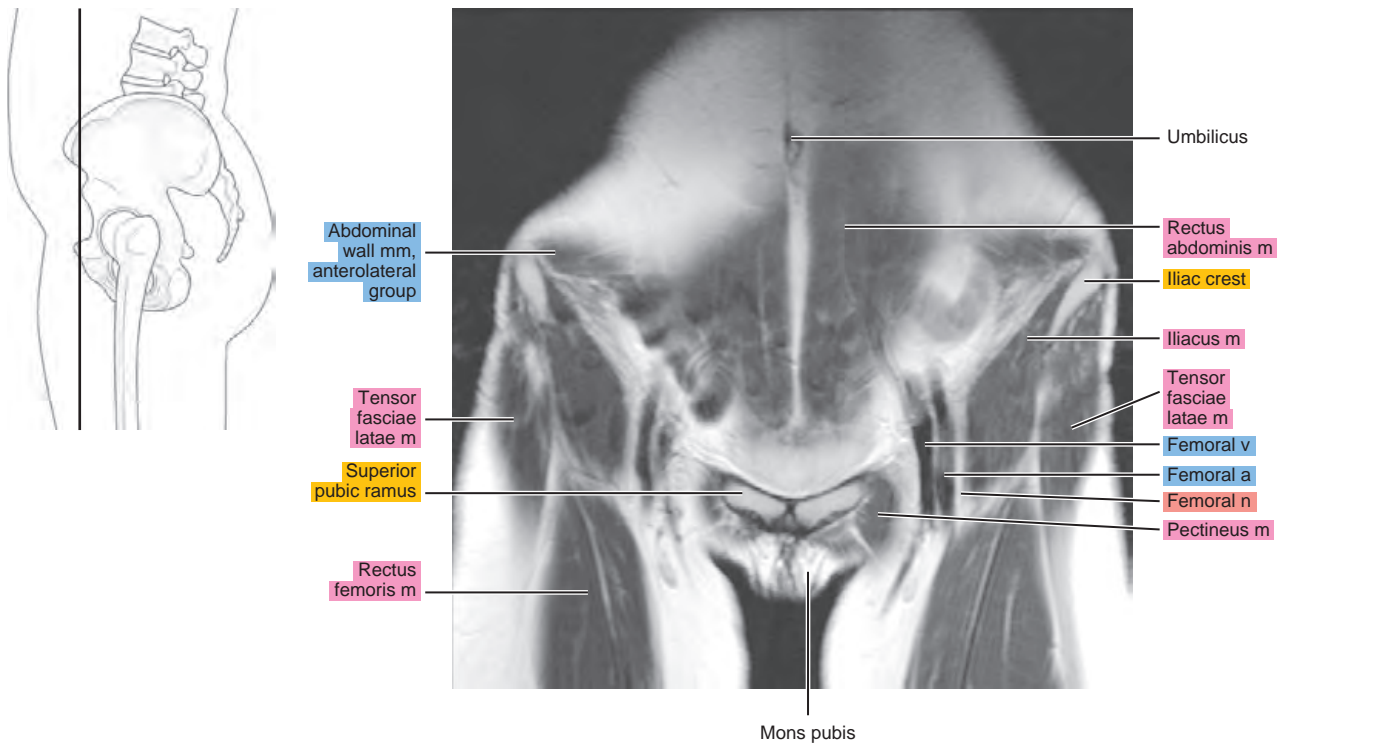


Figure 25.3.3

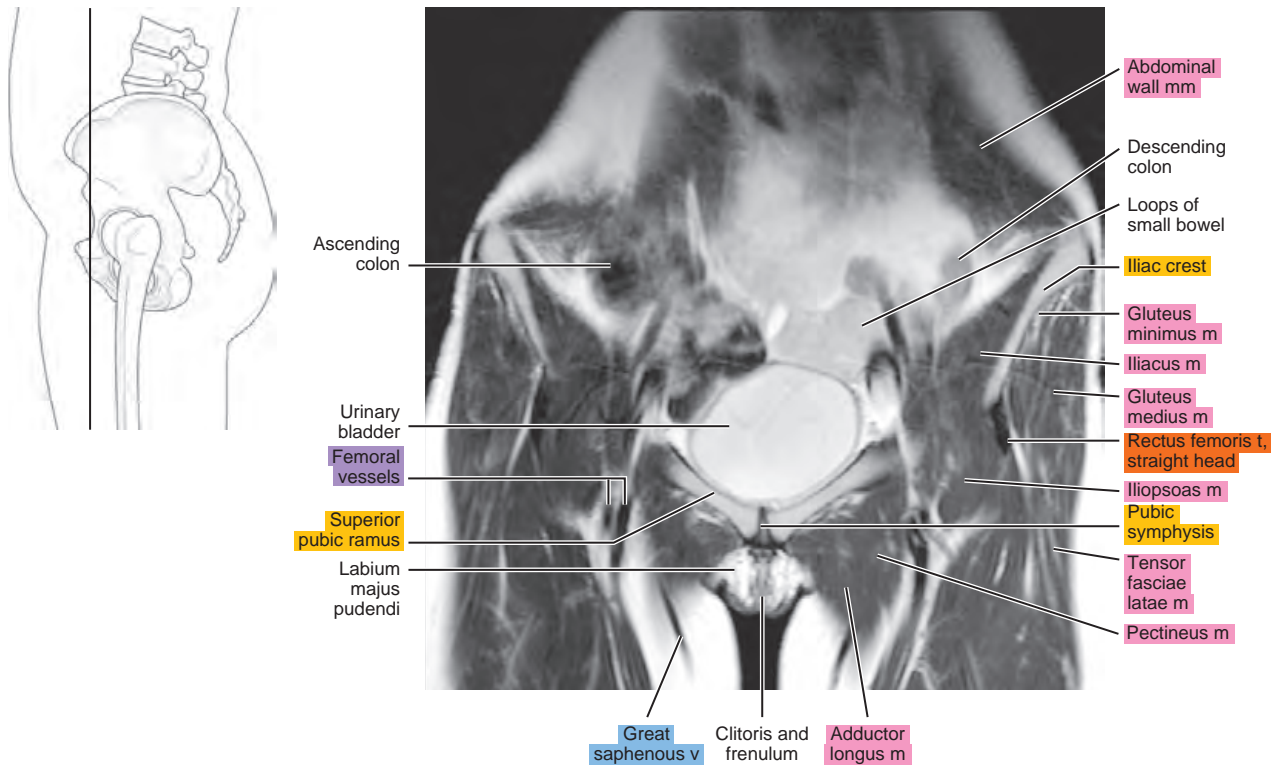


Figure 25.3.4

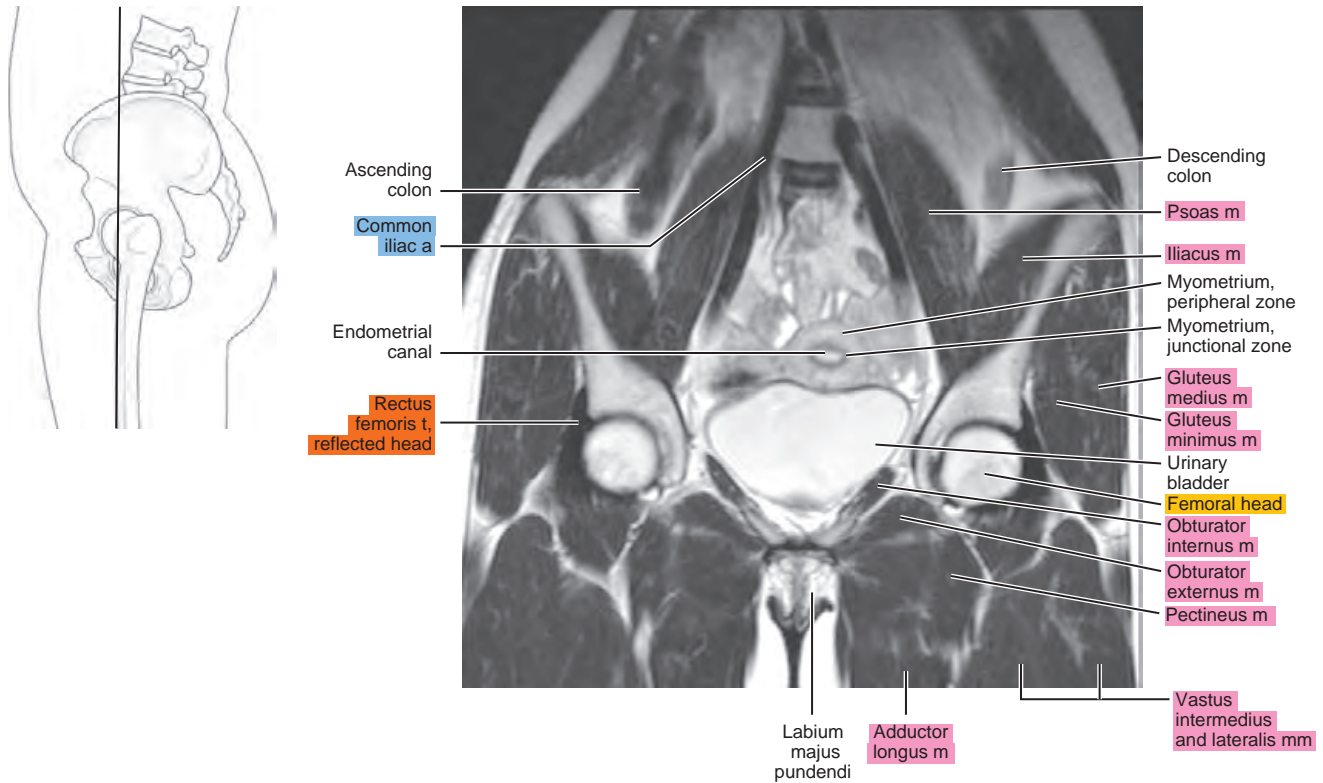


Figure 25.3.5

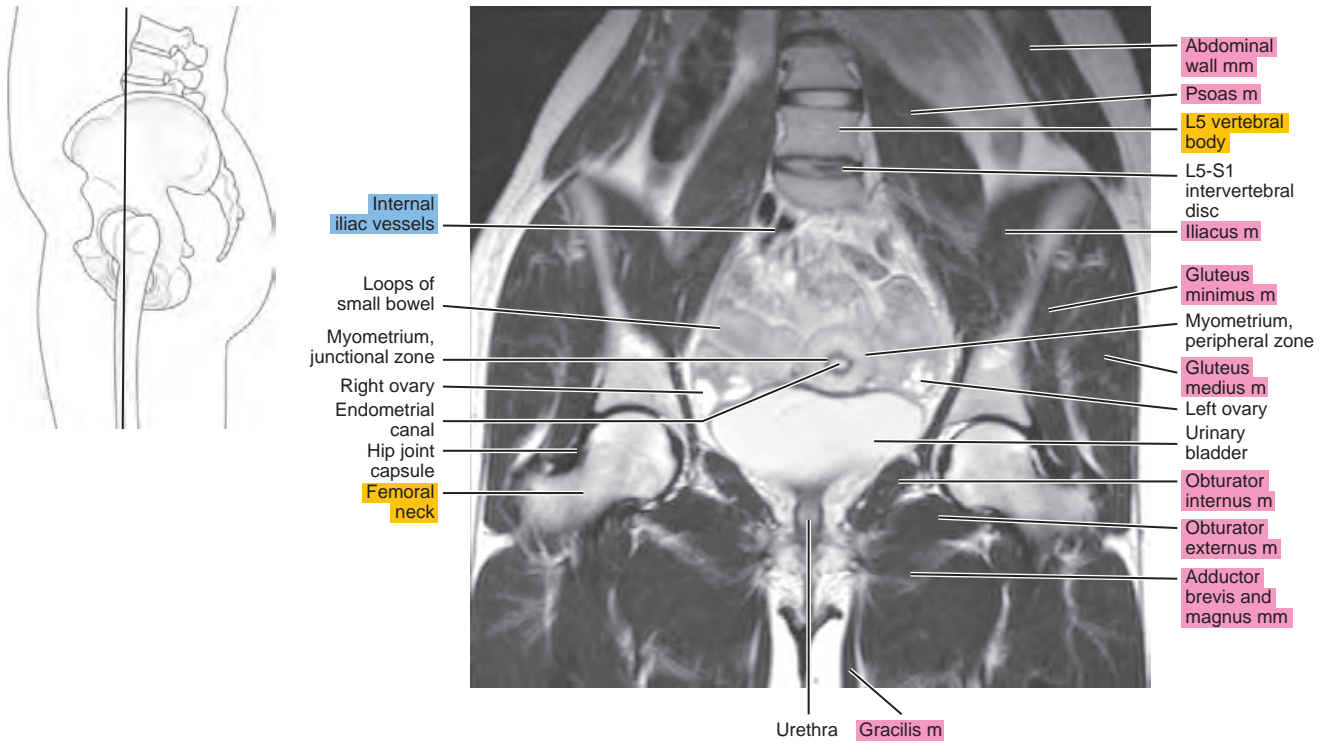


Figure 25.3.6

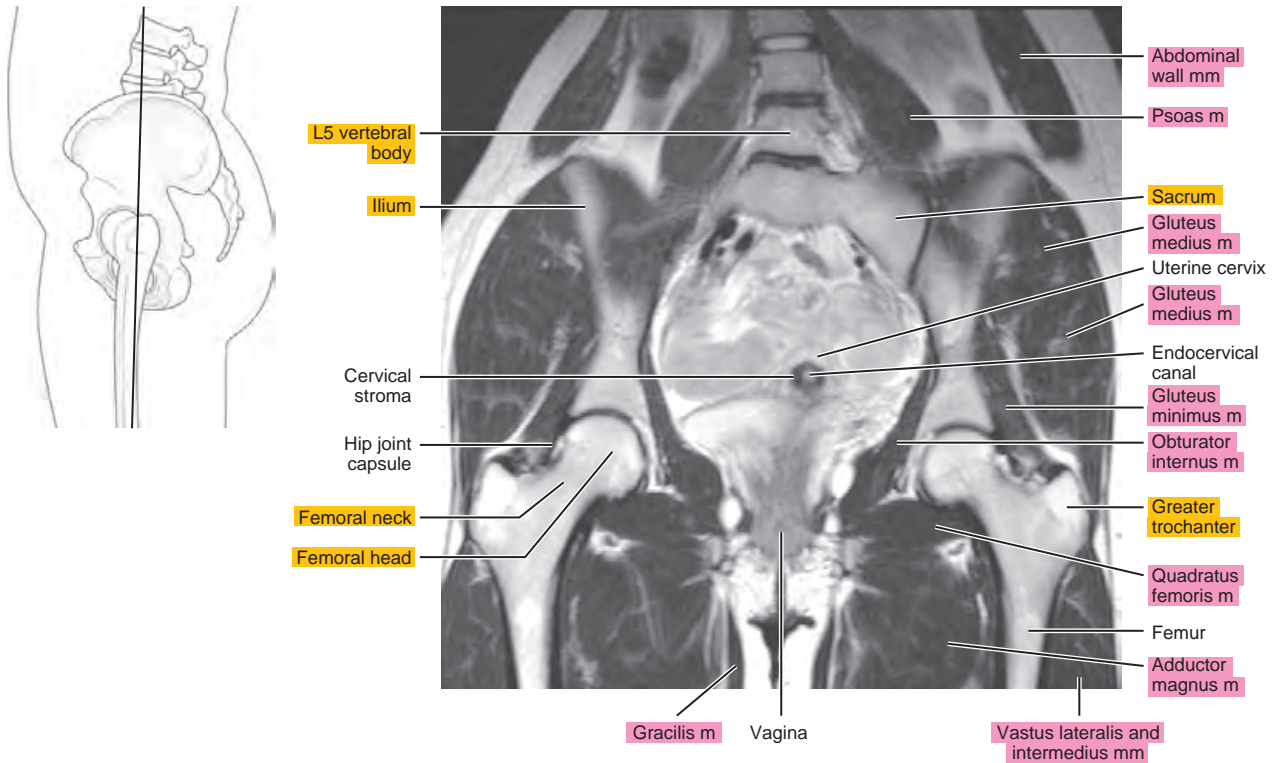


Figure 25.3.7

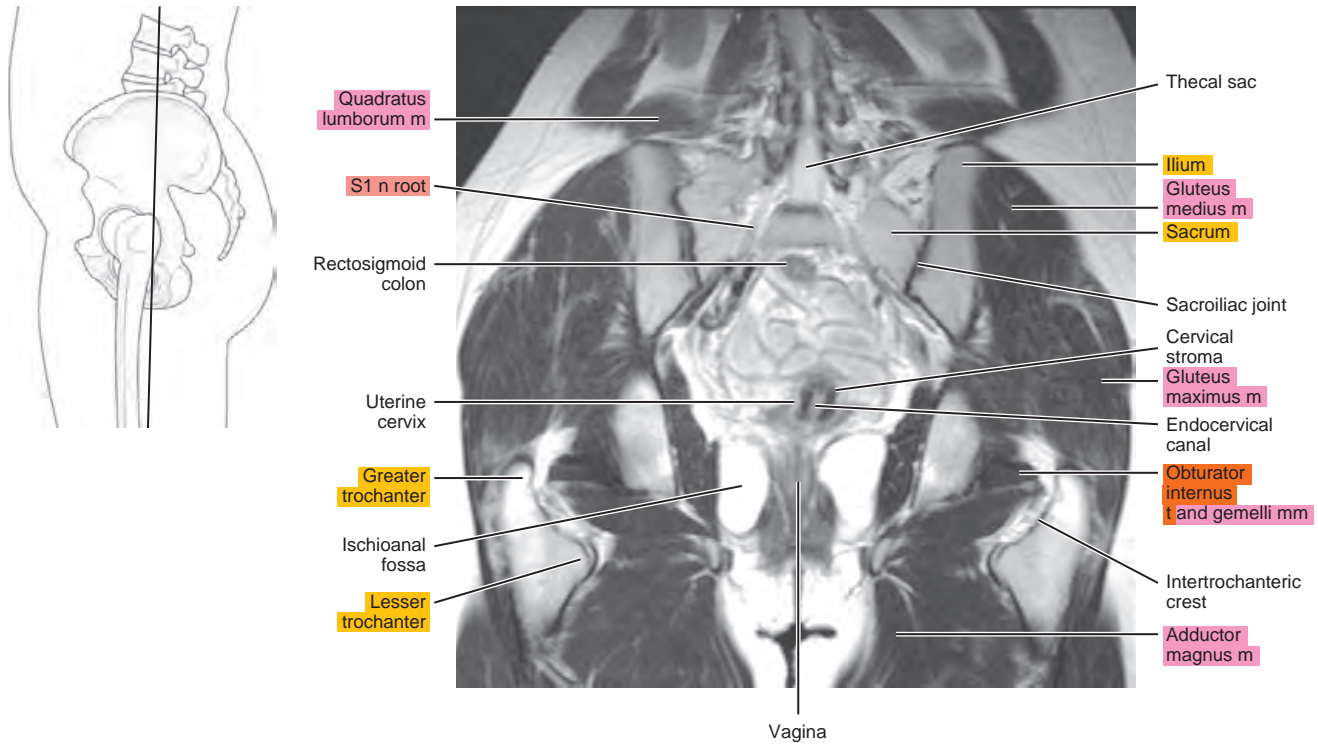


Figure 25.3.8

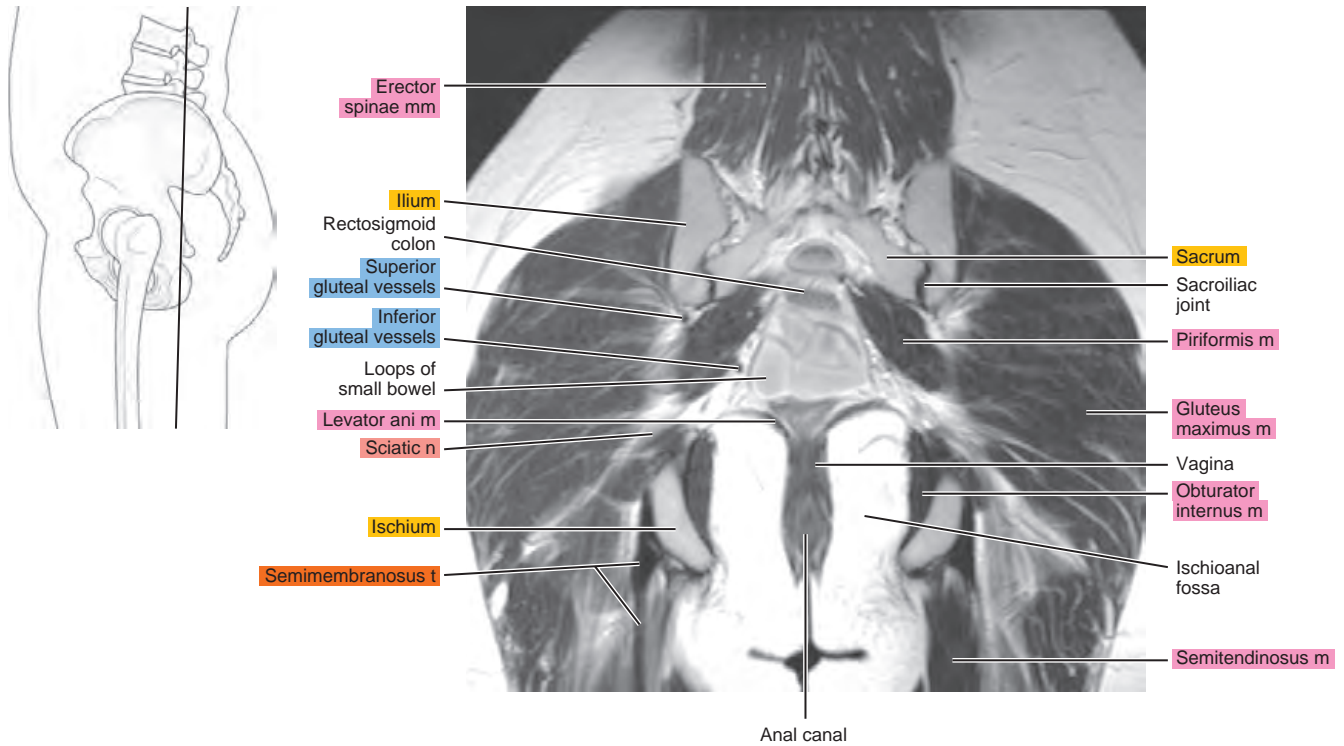
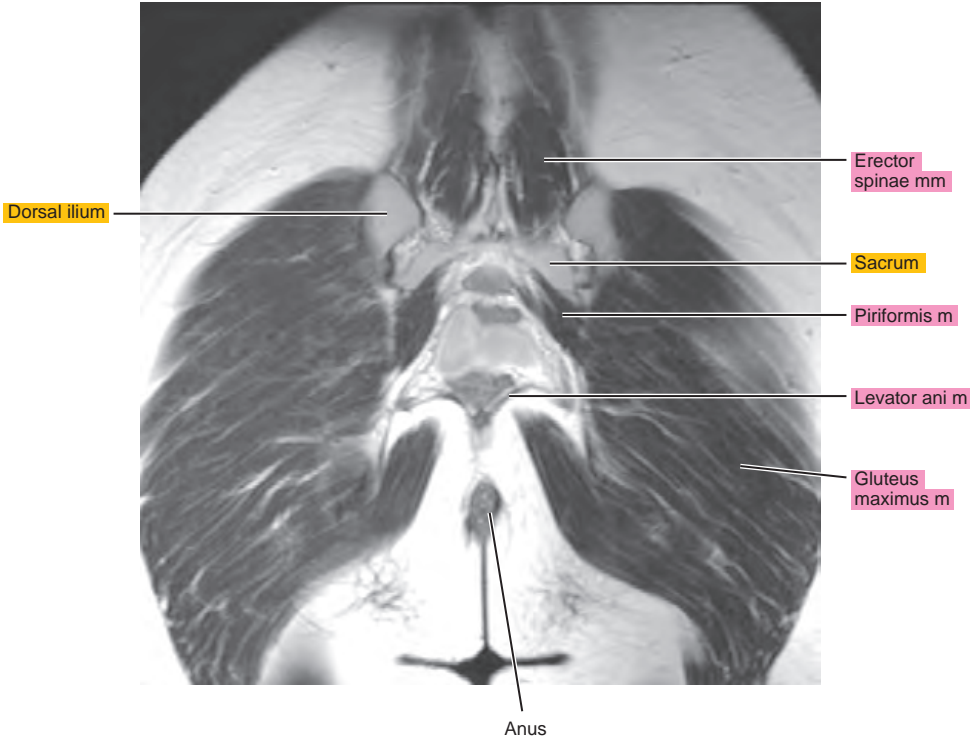
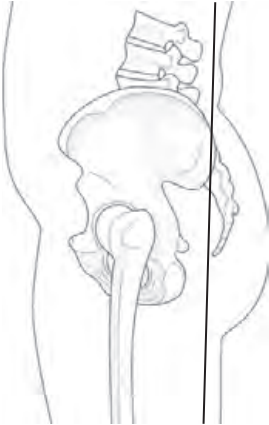


Figure 25.3.9



Index

- A**
- A1 pulley
 - axial view, of hand, 202, 204
 - sagittal view, of hand, 209
 - A2 pulley
 - axial view, of hand, 204
 - sagittal view, of hand, 209, 210
 - A3 pulley, sagittal view, of hand, 209, 210
 - A4 pulley, sagittal view, of hand, 209
 - A5 pulley, sagittal view, of hand, 209
 - Abdominal aorta
 - coronal view, of thorax CT, 454, 455
 - sagittal view
 - of heart MRI, 465
 - of thorax CT, 451
 - Abdominal wall m.
 - axial view, of male pelvis MRI, 554, 555
 - coronal view
 - of abdomen CT, 487
 - of female pelvis MRI, 580, 581, 582
 - of lumbar spine, 435, 436
 - of male pelvis MRI, 565, 566, 567
 - sagittal view, of male pelvis MRI, 559, 560
 - Abductor digiti minimi m.
 - axial view
 - of ankle, 357, 358
 - of foot, 389, 390
 - coronal view
 - of ankle, 372, 373, 374, 375, 376, 377, 378
 - of foot, 402, 403, 404, 405, 406, 407
 - of hand, 215, 216
 - oblique axial view, of ankle, 362, 363, 364
 - origin, insertion, and nerve supply of, 197t, 382–384t
 - sagittal view
 - of ankle, 366, 367, 368
 - of foot, 391, 392, 393
 - of hand, 211, 212, 213
 - Abductor digiti minimi t.
 - axial view
 - of foot, 390
 - of hand, 198, 199, 200, 202, 203
 - coronal view, of foot, 401, 402, 403, 404, 405, 406
 - oblique axial view, of ankle, 364
 - sagittal view, of foot, 391
 - Abductor hallucis m.
 - axial view
 - of ankle, 355, 356, 357
 - of foot, 386, 387, 388
 - coronal view
 - of ankle, 372, 373, 374, 375, 376, 377
 - of foot, 404, 405, 406, 407
 - oblique axial view, of ankle, 362, 363, 364
 - origin, insertion, and nerve supply of, 382–384t
 - sagittal view
 - of ankle, 370, 371
 - of foot, 395, 396, 397
 - Abductor hallucis t.
 - axial view, of foot, 388
 - coronal view, of foot, 400, 401, 402, 404, 405, 406, 407
 - oblique axial view, of ankle, 363, 364
 - sagittal view, of foot, 396, 397, 398
 - Abductor pollicis brevis m.
 - axial view, of hand, 198, 199, 200, 201
 - coronal view, of hand, 214
 - origin, insertion, and nerve supply of, 197t
 - sagittal view, of hand, 206, 207, 208
 - Abductor pollicis brevis t., sagittal view, of hand, 205, 206
 - Abductor pollicis longus m.
 - axial view, of forearm, 147, 148, 149, 150, 151, 152, 153, 154, 155
 - coronal view, of forearm, 167, 168
 - oblique sagittal view, of elbow, 128
 - origin, insertion, and nerve supply of, 144–145t
 - sagittal view, of forearm, 158, 159, 160
 - Abductor pollicis longus t.
 - axial view, of forearm, 151, 152, 153
 - coronal view, of hand, 214, 215
 - sagittal view, of forearm, 158
 - Accessory cephalic v.
 - axial view
 - of elbow, 115, 116, 117, 118, 119, 120, 121, 122, 123, 124
 - of forearm, 146
 - oblique coronal, of elbow, 134, 135
 - oblique sagittal view, of elbow, 125, 126
 - sagittal view, of forearm, 156
 - Accessory collateral lig.
 - axial view, of hand, 204
 - coronal view, of hand, 216
 - Accessory flexor digitorum longus m.
 - axial view, of ankle, 351, 352, 353, 354, 355
 - coronal view, of ankle, 378
 - sagittal view, of ankle, 369
 - Accessory hemiazygos v.
 - axial view, of thoracic spine, 415
 - sagittal view
 - of abdomen CT, 482
 - of thoracic spine, 418
 - Acetabular fossa
 - axial view
 - of female pelvis CT, 540
 - of hip, 227
 - of hip arthrogram, 255, 253, 254
 - of male pelvis CT, 525
 - coronal view
 - of female pelvis CT, 548
 - of hip, 245, 246
 - of hip arthrogram, 265
 - of male pelvis CT, 534
 - sagittal view
 - of hip, 240
 - of hip arthrogram, 261
 - Acetabular lig., transverse
 - axial view, of hip arthrogram, 254, 255
 - coronal view, of hip arthrogram, 262, 263, 264, 265
 - sagittal view, of hip arthrogram, 260, 261
 - Acetabular roof
 - coronal view
 - of female pelvis CT, 548
 - of hip, 245, 246
 - of male pelvis MRI, 567
 - sagittal view
 - of hip, 238, 239
 - of hip arthrogram, 257, 258, 259, 260
 - Acetabular wall, anterior
 - axial view
 - of female pelvis CT, 540
 - of hip, 226, 227
 - sagittal view
 - of hip, 239, 240
 - of hip arthrogram, 259, 260
 - Acetabular wall, posterior
 - axial view
 - of female pelvis CT, 540
 - of hip, 226, 227
 - sagittal view
 - of hip, 239
 - of hip arthrogram, 259
 - Acetabulum
 - axial view, of male pelvis CT, 525
 - coronal view
 - of female pelvis CT, 548, 549, 550
 - of hip, 245
 - of male pelvis CT, 533, 534
 - Achilles t.
 - axial view
 - of ankle, 349, 350, 351, 352, 353, 354, 355, 356, 357
 - of leg, 329, 330, 331, 332, 333
 - coronal view
 - of ankle, 380
 - of leg, 344, 345
 - gastrocnemius part, coronal view, of leg, 345
 - oblique axial view, of ankle, 359, 360
 - sagittal view
 - of ankle, 366, 367, 368
 - of leg, 338, 339
 - Acromioclavicular joint
 - axial view
 - of pectoral girdle and chest wall, 5
 - of shoulder, 36, 37
 - coronal view
 - of arm, 108, 109
 - of pectoral girdle and chest wall, 26, 27
 - oblique coronal view
 - of shoulder, 58, 59
 - of shoulder arthrogram, 79
 - oblique sagittal view
 - of shoulder, 51, 52
 - of shoulder arthrogram, 74

Note: Page numbers followed by *t* indicate tables. *a.* = artery; *ABER* = abduction external rotation; *lig.* = ligament; *ligs.* = ligaments; *m.* = muscle; *n.* = nerve; *t.* = tendon; *v.* = vein

- Acromioclavicular lig.
oblique sagittal view, of shoulder, 52
superior, oblique sagittal view, of shoulder arthrogram, 76, 77
- Acromion
ABER view, of shoulder arthrogram, 84, 85, 86, 87
angle of, oblique coronal view of shoulder, 62, 63
axial view
of pectoral girdle and chest wall, 5
of shoulder, 36, 37
coronal view
of arm, 108, 109, 110
of pectoral girdle and chest wall, 26, 27, 28, 29
oblique coronal view
of shoulder, 59, 60, 61, 62
of shoulder arthrogram, 78, 79, 80, 81, 82, 83
oblique sagittal view
of shoulder, 49, 50, 51, 52
of shoulder arthrogram, 72, 73, 74, 75, 76, 77
sagittal view
of arm, 102, 103, 104
of pectoral girdle and chest wall, 15, 16
- Adductor aponeurosis, sagittal view, of hand, 205, 205, 206
- Adductor brevis m.
axial view
of female pelvis CT, 542
of female pelvis MRI, 575
of hip, 229, 230, 231, 232
of male pelvis CT, 527
of male pelvis MRI, 558
of thigh, 269, 270, 270, 271
coronal view
of female pelvis CT, 548, 549
of female pelvis MRI, 582
of hip, 244, 245, 246
of male pelvis CT, 533, 534
of male pelvis MRI, 566, 567, 568
of thigh, 289, 290
origin, insertion, and nerve supply of, 268t
sagittal view
of female pelvis CT, 543, 544
of female pelvis MRI, 576, 577
of hip, 238, 239, 240, 241, 242
of male pelvis CT, 528, 529
of male pelvis MRI, 559, 560, 561, 562
of thigh, 283, 284, 285
- Adductor canal, axial view, of thigh, 275
- Adductor hallucis m., oblique head
axial view, of foot, 387, 388, 389
coronal view, of foot, 403, 404, 405
origin, insertion, and nerve supply of, 382–384t
sagittal view, of foot, 393, 394, 395, 396
- Adductor hallucis m., transverse head
axial view, of foot, 389
coronal view, of foot, 401, 402, 403
origin, insertion, and nerve supply of, 382–384t
sagittal view, of foot, 393, 394
- Adductor longus m.
axial view
of hip, 229, 230, 231, 232
of male pelvis CT, 527
of male pelvis MRI, 558
of thigh, 269, 270, 271, 272, 273, 274
coronal view
of female pelvis CT, 547
of female pelvis MRI, 581
of hip, 243, 244, 245
of male pelvis CT, 531, 532
of male pelvis MRI, 566, 567
of thigh, 288, 289, 290
origin, insertion, and nerve supply of, 268t
sagittal view
of female pelvis MRI, 576, 577
of hip, 239, 240, 241, 242
of male pelvis MRI, 559, 560, 561, 562
of thigh, 282, 283, 285
- Adductor longus t., axial view, of male pelvis CT, 527
- Adductor magnus m.
axial view
of hip, 230, 231, 232
of male pelvis CT, 527
of male pelvis MRI, 558
of thigh, 269, 270, 271, 272, 273, 274, 275
- Adductor magnus m. (*Continued*)
coronal view
of female pelvis CT, 548, 549, 550
of female pelvis MRI, 582, 583
of hip, 246, 247
of male pelvis CT, 533, 534
of male pelvis MRI, 567, 568, 569
of thigh, 290, 291
origin, insertion, and nerve supply of, 268t
sagittal view
of female pelvis CT, 543
of female pelvis MRI, 576, 577
of hip, 236, 237, 238, 239, 240, 241, 242
of male pelvis CT, 528
of male pelvis MRI, 559, 560
of thigh, 279, 280, 281, 282, 283, 284, 285
- Adductor magnus m., ischiocondylar (hamstring) part
coronal view, of male pelvis MRI, 569
sagittal view
of female pelvis MRI, 576
of male pelvis MRI, 560
- Adductor magnus t.
axial view, of knee, 295, 296, 297
coronal view
of knee, 316
of thigh, 292
sagittal view
of knee, 309
of thigh, 282
- Adductor pollicis brevis m., origin, insertion, and nerve supply of, 197t
- Adductor pollicis m.
axial view
of hand, 199, 200, 201, 202
sagittal view
of hand, 206, 207
- Adductor pollicis m., oblique head
coronal view, of hand, 215, 216
sagittal view
of hand, 208, 209
- Adductor pollicis m., transverse head
coronal view, of hand, 215, 216
sagittal view
of hand, 208, 209, 210
- Adductor pollicis t., axial view, of hand, 202
- Adductor tubercle, sagittal view, of knee, 309
- Adrenal gland
axial view
of abdomen CT, 476, 477
of abdomen MRI, 494, 495, 496, 497, 498
coronal view
of abdomen CT, 491, 492
of abdomen MRI, 515, 516
sagittal view
of abdomen CT, 482, 485
of abdomen MRI, 503, 504, 508
- Adrenal v., axial view, of abdomen CT, 476
- Anal canal
axial view
of female pelvis CT, 541, 542
of male pelvis CT, 526, 527
of male pelvis MRI, 558
coronal view
of female pelvis CT, 551
of female pelvis MRI, 583
of male pelvis CT, 536
of male pelvis MRI, 569
sagittal view, of female pelvis CT, 544, 545
- Anastomotic vv., sagittal view, of foot, 397, 398
- Anconeus m.
axial view
of elbow, 115, 116, 117, 118, 119, 120, 121, 122, 123, 124
of forearm, 146, 147
coronal view, of forearm, 168
oblique coronal view, of elbow, 140, 141, 142
oblique sagittal view, of elbow, 126, 127, 128
origin, insertion, and nerve supply of, 144–145t
sagittal view, of forearm, 160, 161
- Ankle joint
axial view, of ankle, 352
coronal view, of ankle, 374, 375, 376, 377
sagittal view, of ankle, 366, 367, 368
- Annular lig.
axial view, of elbow, 119, 120
oblique coronal, of elbow, 138, 139
oblique sagittal view, of elbow, 126, 128
- Anterior bands
ABER view, of shoulder arthrogram, 86, 87
axial view
of elbow, 118
of shoulder arthrogram, 71
coronal view, of arm, 107
oblique coronal view, of shoulder arthrogram, 80
oblique sagittal view
of elbow, 132
of shoulder arthrogram, 75
- Anus
axial view, of female pelvis MRI, 575
coronal view
of female pelvis MRI, 584
of male pelvis CT, 535
of male pelvis MRI, 568, 569, 570
sagittal view
of female pelvis MRI, 578
of male pelvis CT, 530
of male pelvis MRI, 564
- Aorta
axial view
of abdomen CT, 475, 476, 477, 478, 479
of abdomen MRI, 494, 495, 496, 497, 498, 499, 500, 501
of heart MRI, 462, 463
of lumbar spine, 425
of thoracic spine, 415, 416
of thorax CT, 445, 448
coronal view
of abdomen CT, 488, 489, 490, 491, 492
of abdomen MRI, 512, 513, 514, 515, 516
of lumbar spine, 432, 433
sagittal view
of abdomen CT, 483
of abdomen MRI, 504, 505
of thoracic spine, 418
- Aorta, abdominal
coronal view, of thorax CT, 454, 455
sagittal view
of heart MRI, 465
of thorax CT, 451
- Aorta, ascending
axial view
of heart MRI, 460, 461
of pectoral girdle and chest wall, 9, 10, 11
of thorax CT, 444, 445
coronal view
of heart MRI, 467, 468
of pectoral girdle and chest wall, 26
sagittal view
of heart MRI, 465
of thorax CT, 451
- Aorta, descending
axial view
of heart MRI, 460, 461
of thorax CT, 444, 445, 446, 447
coronal view, of heart MRI, 469
sagittal view
of abdomen CT, 482
of heart MRI, 464
of thorax CT, 450
- Aortic arch
axial view
of heart MRI, 460
of thorax CT, 443, 444
coronal view
of heart MRI, 468
of thorax CT, 453, 454, 455
- sagittal view
of heart MRI, 464, 465
of thorax CT, 450, 451
- Aortic bifurcation
axial view, of abdomen CT, 480
coronal view
of abdomen CT, 488
of female pelvis CT, 548, 549
of male pelvis CT, 532
sagittal view
of female pelvis CT, 545
of male pelvis CT, 529

- Aortic outflow tract, axial view, of heart MRI, 462
- Aortic root
axial view, of heart MRI, 462
coronal view, of thorax CT, 467
sagittal view
of heart MRI, 465
of thorax CT, 450, 451
- Aortic valve leaflets
axial view, of thorax CT, 446
coronal view, of thorax CT, 455
- Aortic valve plane, coronal view, of thorax CT, 454
- Aorticopulmonary window, sagittal view, of heart MRI, 465
- Appendix
axial view
of female pelvis CT, 538
of male pelvis CT, 524
coronal view, of female pelvis CT, 547
- Arcuate lig., median, sagittal view, of abdomen CT, 483
- Articular cartilage
axial view
of knee, 297
of shoulder, 40, 67, 68, 69
coronal view, of knee, 314, 315, 316
oblique coronal view, of shoulder, 60, 81
sagittal view, of knee, 303, 304, 305, 308, 309
- Articular recess, superior, coronal view, of hip arthrogram, 262, 263, 264, 265, 266
- Articulating process (facet)
inferior, sagittal view, of thoracic spine, 418, 419
superior, sagittal view, of thoracic spine, 418, 419
- Atrial appendage
axial view
of heart MRI, 462
of thorax CT, 445
coronal view, of thorax CT, 453
sagittal view
of heart MRI, 465
of thorax CT, 450
- Atrium
left
axial view
of heart MRI, 462
of thorax CT, 445, 446
coronal view
of abdomen MRI, 514
of heart MRI, 468
of thorax CT, 455, 456
sagittal view
of abdomen CT, 483
of heart MRI, 465
of thorax CT, 450, 451
right
axial view
of heart MRI, 462, 463
of thorax CT, 445, 446
coronal view
of abdomen CT, 490
of heart MRI, 467, 468
of thorax CT, 453, 454, 455
sagittal view
of abdomen CT, 484
of heart MRI, 465, 466
of thorax CT, 452
- Axillary a.
axial view
of pectoral girdle and chest wall, 7, 8, 9
of shoulder, 41, 42, 43, 44, 45
coronal view
of heart MRI, 468
of pectoral girdle and chest wall, 27, 28, 29
oblique coronal view, of shoulder, 56, 57, 58, 59
oblique sagittal view, of shoulder, 52, 53, 54, 55
sagittal view, of pectoral girdle and chest wall, 17, 18, 19, 20
- Axillary lymph node, oblique sagittal view, of shoulder, 53
- Axillary n.
axial view
of pectoral girdle and chest wall, 9, 10
of shoulder, 45
coronal view
of arm, 110
of pectoral girdle and chest wall, 29
- Axillary n. (*Continued*)
oblique coronal view
of shoulder, 59, 62, 63, 64
of shoulder arthrogram, 83
oblique sagittal view
of shoulder, 49, 50
of shoulder arthrogram, 75
sagittal view
of arm, 100, 101, 103, 104
of pectoral girdle and chest wall, 16
- Axillary neurovascular bundle
axial view, of pectoral girdle and chest wall, 10
coronal view, of arm, 108
sagittal view, of arm, 103, 104
- Axillary pouch
axial view, of shoulder arthrogram, 71
oblique sagittal view, of shoulder arthrogram, 75, 76
- Axillary recess, oblique coronal view, of shoulder arthrogram, 80, 81, 82, 83
- Axillary v.
axial view
of pectoral girdle and chest wall, 7, 8, 9
of shoulder, 41, 42, 43, 44, 45
coronal view
of heart MRI, 468
of pectoral girdle and chest wall, 27, 28
oblique coronal view, of shoulder, f, 56, 57, 58
oblique sagittal view, of shoulder, 53, 54, 55
sagittal view, of pectoral girdle and chest wall, 18, 19, 20
- Azygos v.
axial view
of abdomen MRI, 494, 495
of heart MRI, 461, 462, 463
of lumbar spine, 425
of thoracic spine, 415, 416
of thorax CT, 444, 445, 447, 448
coronal view
of abdomen MRI, 516
of lumbar spine, 432
sagittal view, of lumbar spine, 431
- Azygos v., arch
axial view, of thorax CT, 444
coronal view, of heart MRI, 468
sagittal view, of thorax CT, 451
- B**
- Basilic v.
axial view
of arm, 92, 93, 94, 95, 96, 97
of elbow, 115, 116, 117, 118, 119, 120, 122, 123, 124
coronal view
of arm, 106, 107, 108, 109
of elbow, 138, 139, 140
oblique coronal view
of elbow, 138, 139, 140
of shoulder, 60
oblique sagittal view, of elbow, 131, 132, 133
sagittal view
of arm, 102, 103
of forearm, 156
- Basilic v., median
axial view
of elbow, 118, 119, 120, 121, 122, 123, 124
of forearm, 146, 147, 148, 149, 150, 151, 152, 153
coronal view
of elbow, 134, 135
of forearm, 162
oblique coronal, of elbow, 134, 135
oblique sagittal view, of elbow, 131
- Basivertebral v.
axial view, of lumbar spine, 427
coronal view, of lumbar spine, 434
- Basivertebral venous plexus
axial view
of lumbar spine, 425
of thoracic spine, 416
coronal view, of thoracic spine, 420
sagittal view
of lumbar spine, 431
of thoracic spine, 419
- Biceps anchor
ABER view, of shoulder arthrogram, 84
axial view, of shoulder, 39
oblique coronal view, of shoulder, 59
oblique sagittal view, of shoulder, 52, 75, 76
- Biceps brachii m.
ABER view, of shoulder arthrogram, 85, 86
axial view
of arm, 94, 95, 96, 97
of elbow, 115, 116, 117
coronal view
of arm, 105, 107
of elbow, 134, 135, 136, 137
of pectoral girdle and chest wall, 27, 28, 29
oblique coronal view, of elbow, 134, 135, 136, 137
oblique sagittal view, of elbow, 125, 126, 127, 128, 129, 130
origin, insertion, and nerve supply of, 91t
sagittal view
of arm, 99, 100, 101, 102, 103, 104
of elbow, 125, 126, 127, 128, 129, 130
- Biceps brachii m., long head
axial view
of arm, 92, 93
of pectoral girdle and chest wall, 7, 8, 9, 10, 11, 12, 13
coronal view
of arm, 106, 107
of pectoral girdle and chest wall, 25, 26, 27, 28
of shoulder, 60
oblique coronal view, of shoulder, 60
sagittal view
of arm, 100, 101
of pectoral girdle and chest wall, 15
- Biceps brachii m., short head
axial view
of arm, 92, 93
of pectoral girdle and chest wall, 7, 8, 9, 10, 11, 12, 13
of shoulder, 41, 42, 43, 44, 45
coronal view
of arm, 106, 107
of pectoral girdle and chest wall, 25, 26, 27, 28
of shoulder, 57, 58, 59, 60, 61
oblique coronal view, of shoulder, 57, 58, 59, 60, 61
oblique sagittal view, of shoulder, 49, 50, 51
sagittal view
of arm, 102, 103
of pectoral girdle and chest wall, 15, 16, 17
of shoulder, 49, 50, 51
- Biceps brachii t.
ABER view, of shoulder arthrogram, 84
axial view
of arm, 96, 97
of elbow, 115, 116, 117, 118, 119, 120, 121, 122
of forearm, 146
coronal view
of arm, 105
of elbow, 136, 137, 138
of forearm, 164, 165
oblique coronal, of elbow, 136, 137, 138
oblique sagittal view, of elbow, 129
sagittal view
of arm, 101
of elbow, 129
of forearm, 157, 158
of pectoral girdle and chest wall, 15
- Biceps brachii t., long head
ABER view, of shoulder arthrogram, 84, 85
axial view
of pectoral girdle and chest wall, 7, 8, 9
of shoulder, 39, 40, 41, 42, 43, 44, 45
of shoulder arthrogram, 67, 68, 69, 70, 71
coronal view
of arm, 106
of pectoral girdle and chest wall, 26, 27
oblique coronal view
of shoulder, 59, 60, 61
of shoulder arthrogram, 78, 79, 80, 81
oblique sagittal view
of shoulder, 47, 48, 49, 50, 51
of shoulder arthrogram, 72, 73, 74, 75

- Biceps brachii t., short head
 ABER view, of shoulder arthrogram, 84
 axial view
 of pectoral girdle and chest wall, 7, 8, 9
 of shoulder, 42, 43, 44
 of shoulder arthrogram, 70, 71
 oblique coronal view
 of shoulder, 58, 59
 of shoulder arthrogram, 78, 79
 oblique sagittal view
 of shoulder, 50
 of shoulder arthrogram, 74
- Biceps femoris m.
 axial view, of thigh, 271, 272, 273, 274, 275, 276
 coronal view
 of knee, 317, 318, 319, 320
 of leg, 344
 of male pelvis MRI, 569, 570
 origin, insertion, and nerve supply of, 268t
 sagittal view, of knee, 302
- Biceps femoris m., long head
 axial view
 of hip, 230, 232
 of knee, 295
 of male pelvis MRI, 558
 of thigh, 272, 273, 274, 275, 276
 coronal view
 of hip, 244, 247
 of thigh, 291, 292, 293
 origin, insertion, and nerve supply of, 222–223t
 sagittal view
 of knee, 303
 of thigh, 277, 278, 279
- Biceps femoris m., short head
 axial view
 of knee, 295, 296, 297, 298
 of thigh, 273, 274, 275, 276
 coronal view
 of knee, 316, 319
 of thigh, 290
 sagittal view
 of knee, 302, 303
 of thigh, 277, 278
- Biceps femoris t.
 axial view
 of knee, 295, 296, 297, 298, 299, 300
 of thigh, 269, 270
 coronal view
 of knee, 317, 318, 319
 of leg, 344, 345
 of male pelvis CT, 536
 of male pelvis MRI, 569
 sagittal view
 of knee, 302
 of leg, 334
 of male pelvis CT, 528
- Biceps femoris t., long head, axial view
 of hip, 232
 of male pelvis MRI, 558
- Biceps m., short head, and coracobrachialis m.,
 conjoined tendon of, 7, 41
- Bicipital aponeurosis, axial view, of elbow, 118, 119, 120
- Bicipital (intertubercular) groove, axial view
 of shoulder, 41
 of shoulder arthrogram, 70, 71
- Bile duct, common
 axial view
 of abdomen CT, 477
 of abdomen MRI, 498, 499, 500
 coronal view
 of abdomen CT, 488
 of abdomen MRI, 513, 514
 sagittal view
 of abdomen CT, 484
 of abdomen MRI, 508
- Blumensaat's line, sagittal view, of knee, 306
- Brachial a.
 axial view
 of arm, 92, 93, 94, 95, 96, 97
 of elbow, 115, 117, 118, 119
 coronal view
 of arm, 105, 108
 of pectoral girdle and chest wall, 28
 oblique coronal view, of elbow, 136
 oblique sagittal view, of elbow, 125, 126, 127, 128, 129, 130, 131, 132
 origin, insertion, and nerve supply of, 144–145t
- Brachial a. (*Continued*)
 oblique sagittal view, of elbow, 130
 sagittal view
 of arm, 102
 of elbow, 130
- Brachial a., deep
 axial view, of pectoral girdle and chest wall, 11, 13
 coronal view, of pectoral girdle and chest wall, 29
 oblique coronal view, of shoulder, 60, 62
 sagittal view, of pectoral girdle and chest wall, 16
- Brachial neurovascular bundle
 axial view, of pectoral girdle and chest wall, 11, 12, 13
 coronal view
 of arm, 107, 108
 of pectoral girdle and chest wall, 29
 sagittal view, of pectoral girdle and chest wall, 16
- Brachial plexus
 coronal view, of pectoral girdle and chest wall, 27, 28
 oblique sagittal view, of shoulder, 53, 55
 sagittal view
 of pectoral girdle and chest wall, 19, 20, 21
 of thoracic spine, 417
- Brachial v.
 axial view
 of arm, 94, 95, 96, 97
 coronal view
 of arm, 105, 107, 108
 of pectoral girdle and chest wall, 28
 sagittal view, of arm, 102
- Brachialis m.
 axial view
 of arm, 92, 93, 94, 95, 96, 97
 of elbow, 115, 116, 117, 118, 119, 120, 121
 coronal view
 of arm, 105, 106, 107, 108
 of elbow, 136, 137, 138, 139
 oblique coronal, of elbow, 136, 137, 138, 139
 oblique sagittal view, of elbow, 125, 126, 127, 128, 129, 130, 131, 132
 origin, insertion, and nerve supply of, 91t
 sagittal view
 of arm, 98, 99, 100, 101, 102
 of elbow, 125, 126, 127, 128, 129, 130, 131, 132
 of forearm, 160
- Brachialis t.
 axial view
 of arm, 96, 97
 of elbow, 115, 116, 117, 118, 119, 120, 121
 oblique coronal, of elbow, 136
 sagittal view, of arm, 100, 101
- Brachiocephalic a.
 axial view
 of pectoral girdle and chest wall, 7, 8
 of thorax CT, 443
 coronal view, of thorax CT, 453, 454, 455
 sagittal view, of thorax CT, 452
- Brachiocephalic trunk
 coronal view, of pectoral girdle and chest wall, 26
 sagittal view, of heart MRI, 465
- Brachiocephalic v.
 axial view
 of pectoral girdle and chest wall, 7, 8, 9
 of thorax CT, 443
 coronal view
 of heart MRI, 468
 of pectoral girdle and chest wall, 26, 27
 of thorax CT, 453, 454, 455
 sagittal view
 of heart MRI, 465
 of pectoral girdle and chest wall, 23
 of thorax CT, 450, 451, 452
- Brachioradialis m.
 axial view
 of arm, 95, 96, 97
 of elbow, 115, 116, 117, 118, 119, 120, 121, 122, 123, 124
 of forearm, 146, 147, 148, 149, 150, 152
 coronal view
 of arm, 105, 106, 107, 108, 109
 of elbow, 134, 135, 136, 137, 138, 139, 140, 141
 of forearm, 164, 165, 166, 167
 oblique coronal, of elbow, 134, 135, 136, 137, 138, 139, 140, 141
 oblique sagittal view, of elbow, 125, 126, 127, 128
 origin, insertion, and nerve supply of, 144–145t
- Brachioradialis m. (*Continued*)
 sagittal view
 of arm, 98, 99
 of elbow, 125, 126, 127, 128
 of forearm, 156
- Brachioradialis t., axial view, of forearm, 150, 151, 153, 154, 155
- Breast
 coronal view, of abdomen MRI, 510, 511, 512
 sagittal view, of abdomen MRI, 502
- Bronchus
 axial view
 of heart MRI, 461
 of pectoral girdle and chest wall, 10
 of thorax CT, 444
 coronal view, of thorax CT, 456
 sagittal view
 of heart MRI, 464, 465
 of thorax CT, 449, 450
- Bulbospongiosus m.
 coronal view
 of female pelvis CT, 548, 549
 of male pelvis CT, 534, 535
 sagittal view, of male pelvis CT, 530
- C**
- C1 pulley, sagittal view, of hand, 209, 210
- C5-6 disc level, axial view, of pectoral girdle and chest wall, 4
- C7 vertebral body, axial view, of pectoral girdle and chest wall, 5
- Calcaneal tubercle
 axial view, of ankle, 355, 356
 lateral, coronal view, of ankle, 378, 379
- Calcaneal tuberosity
 axial view, of ankle, 355, 356, 357, 358
 sagittal view, of ankle, 366, 367, 368, 369
- Calcaneal vessels, medial, sagittal view, of ankle, 370
- Calcaneocuboid joint
 axial view, of ankle, 356, 363
 coronal view, of ankle, 373
 oblique axial view, of ankle, 363
 sagittal view, of foot, 393
- Calcaneocuboid lig., plantar
 axial view, of ankle, 355, 357
 coronal view, of ankle, 372, 373, 374, 375, 376
 sagittal view
 of ankle, 367, 368
 of foot, 393
- Calcaneofibular lig., axial view, of ankle, 354, 355
- Calcaneonavicular (spring) lig.
 inferoplantar
 axial view, of ankle, 355
 coronal view, of ankle, 372, 373
 oblique axial view, of ankle, 362
 sagittal view, of ankle, 370
 medioplantar, axial view, of ankle, 355
 plantar, oblique axial view, of ankle, 362
 superomedial, coronal view, of ankle, 373
- Calcaneus
 axial view
 of ankle, 355, 356, 357
 of foot, 386, 387, 388
 coronal view
 of ankle, 373, 374, 375, 376, 377, 378, 379, 380
 of leg, 342, 343, 344
 oblique axial view, of ankle, 360, 361, 362
 sagittal view
 of ankle, 366, 367, 368, 369, 370
 of foot, 392, 393, 394, 395, 396
- Calcar femorale
 axial view, of hip, 229, 230, 231
 coronal view, of hip, 246
- Capitate
 coronal view, of hand, 215, 216, 217
 sagittal view, of hand, 209
- Capitellum
 axial view, of elbow, 117, 118, 119
 oblique coronal, of elbow, 138, 139
 oblique sagittal view, of elbow, 126, 127, 128, 129
 sagittal view
 of arm, 99, 100
 of elbow, 126, 127, 128, 129

- Capsular insertion, axial view, of shoulder arthrogram, 69, 70
- Capsular lig.
lateral, coronal view, of knee, 317
oblique coronal view, of shoulder, 60, 61, 62
- Cardiac septum, coronal view, of heart MRI, 467
- Carina, axial view, of heart MRI, 460
- Carotid a., axial view
of pectoral girdle and chest wall, 4
of thorax CT, 442, 443
- Carotid a., common
axial view
of pectoral girdle and chest wall, 6, 7
of thorax CT, 442
coronal view
of pectoral girdle and chest wall, 26
of thorax CT, 454, 455
sagittal view, of thorax CT, 450, 451
- Carpal lig., palmar, axial view, of wrist, 173, 174, 175
- Carpometacarpal joint
2nd, sagittal view, of hand, 208
3rd, sagittal view, of hand, 209
- Cauda equina
coronal view
of lumbar spine, 435
of thoracic spine, 420
sagittal view, of thoracic spine, 419
- Caudate lobe of liver
axial view
of abdomen CT, 476
of abdomen MRI, 494, 495
coronal view
of abdomen CT, 490
of abdomen MRI, 514, 515
sagittal view
of abdomen CT, 483, 484, 485
of abdomen MRI, 507, 508
- Cecum
axial view
of male pelvis CT, 523, 524, 525
of male pelvis MRI, 554
coronal view
of abdomen CT, 488
of female pelvis CT, 547, 548
of male pelvis CT, 531, 532
of male pelvis MRI, 566
sagittal view
of abdomen MRI, 509
of female pelvis CT, 543
of male pelvis MRI, 560
- Celiac a.
axial view, of heart MRI, 465
coronal view
of abdomen MRI, 513, 514
of thorax CT, 455
sagittal view
of abdomen MRI, 505
of thorax CT, 450
- Celiac trunk
axial view
of abdomen CT, 476, 477
of abdomen MRI, 497
coronal view, of abdomen CT, 489, 490
sagittal view, of abdomen CT, 483
- Cephalic v.
axial view
of arm, 92, 93
of elbow, 115, 116, 117, 118, 119, 120, 121, 122, 123, 124
of forearm, 146, 147, 148, 149, 150, 151, 152, 153, 154, 155
of pectoral girdle and chest wall, 7, 10, 11, 12, 13
of shoulder, 40, 41, 42, 43, 44, 45
coronal view
of arm, 105
of elbow, 134, 135
of forearm, 164, 165, 166
of pectoral girdle and chest wall, 24, 25, 26, 27
oblique coronal view
of elbow, 134, 135
of shoulder, 56, 57, 58
oblique sagittal view
of elbow, 127, 128, 129
of shoulder, 48, 49, 50, 51, 52, 53, 54, 55
- Cephalic v. (*Continued*)
sagittal view
of forearm, 156, 157
of pectoral girdle and chest wall, 14, 15, 18, 19
- Cervical a. and v., superficial, coronal view, of thoracic spine, 422
- Cervical stroma
axial view, of female pelvis MRI, 574
coronal view, of female pelvis MRI, 582, 583
sagittal view, of female pelvis MRI, 579
- Cervical vessels, transverse
axial view, of pectoral girdle and chest wall, 5
coronal view, of pectoral girdle and chest wall, 28, 29
- Cervix, axial view, of female pelvis MRI, 573
- Circumflex a.
axial view
of heart MRI, 462
of thorax CT, 447
coronal view, of thorax CT, 454, 455
posterior, sagittal view, of pectoral girdle and chest wall, 16
- Circumflex femoral a.
lateral
axial view, of male pelvis CT, 527
coronal view, of male pelvis CT, 533
medial
axial view, of male pelvis CT, 527
coronal view, of male pelvis CT, 533, 534
sagittal view, of male pelvis CT, 528
- Circumflex femoral v.
lateral, coronal view, of male pelvis CT, 533, 534
medial, coronal view, of male pelvis CT, 533, 534
- Circumflex femoral vessels
lateral
axial view, of hip, 229
coronal view, of male pelvis MRI, 566
sagittal view, of hip, 234, 235, 236
medial
axial view, of hip, 229
coronal view, of male pelvis MRI, 566
sagittal view, of hip, 237, 239, 240
- Circumflex humeral a.
anterior
oblique coronal view, of shoulder, 59, 60
oblique sagittal view, of shoulder, 48, 49, 50, 52
sagittal view, of pectoral girdle and chest wall, 15
posterior
axial view
of pectoral girdle and chest wall, 8, 9
of shoulder, 44, 45
coronal view
of arm, 110
of pectoral girdle and chest wall, 29
oblique coronal view, of shoulder, 59, 60, 61, 62, 63, 64
oblique sagittal view, of shoulder, 49, 50, 51, 52
sagittal view
of arm, 100, 101, 103, 104
of pectoral girdle and chest wall, 15
- Circumflex humeral vessels
oblique coronal view, of shoulder arthrogram, 83
oblique sagittal view, of shoulder arthrogram, 75, 76
- Circumflex iliac v., superficial, coronal view, of hip, 243
- Circumflex iliac vessels, superficial, coronal view, of male pelvis MRI, 565
- Circumflex scapular a.
axial view, of pectoral girdle and chest wall, 9
coronal view
of arm, 109
of pectoral girdle and chest wall, 28, 29, 30
oblique coronal view, of shoulder, 59, 60, 61, 62, 63, 64
oblique sagittal view, of shoulder, 53, 54
sagittal view, of arm, 104
- Circumflex vessels, oblique coronal view, of shoulder, 62
- Clavicle
axial view
of pectoral girdle and chest wall, 6, 7, 8
of shoulder, 38, 39
of shoulder arthrogram, 67
of thorax CT, 442
coronal view
of arm, 108, 109
of pectoral girdle and chest wall, 24, 25, 26
- Clavicle (*Continued*)
distal
axial view
of pectoral girdle and chest wall, 5
of shoulder, 36, 37
coronal view, of pectoral girdle and chest wall, 27
sagittal view, of pectoral girdle and chest wall, 17
medial, sagittal view, of pectoral girdle and chest wall, 23
oblique coronal view
of shoulder, 56, 57, 58, 59
of shoulder arthrogram, 78, 79
oblique sagittal view
of shoulder, 52, 53, 54, 55
of shoulder arthrogram, 75, 76, 77
sagittal view
of heart MRI, 464, 466
of pectoral girdle and chest wall, 17, 18, 19, 20, 21, 22
of thorax CT, 449
- Clavicular head
coronal view
of heart MRI, 467
of thorax CT, 453
sagittal view, of thorax CT, 450, 452
- Clitoris, coronal view
of female pelvis CT, 547
of female pelvis MRI, 581
- Coccygeus m.
axial view
of female pelvis CT, 540
of hip, 227
sagittal view
of male pelvis CT, 529
of male pelvis MRI, 562, 563
- Coccyx
axial view
of female pelvis CT, 540
of male pelvis CT, 525, 526
of male pelvis MRI, 556
coronal view, of male pelvis MRI, 570
sagittal view
of female pelvis CT, 545
of female pelvis MRI, 578
of male pelvis CT, 530
of male pelvis MRI, 563, 564
- Collateral lig.
accessory
axial view, of hand, 204
coronal view, of hand, 216
sagittal view, of hand, 205
- Colon
axial view, of abdomen CT, 478, 479, 480
coronal view, of abdomen MRI, 510, 511, 512, 513, 514, 515
sagittal view
of abdomen CT, 481, 486
of abdomen MRI, 502, 503, 509
- Colon, ascending
axial view
of abdomen CT, 479, 480
of abdomen MRI, 501
of female pelvis MRI, 572
of male pelvis CT, 522, 523
of male pelvis MRI, 553
coronal view
of abdomen CT, 489, 490
of abdomen MRI, 511, 512, 513, 514, 515
of female pelvis CT, 546, 548, 549
of female pelvis MRI, 581
of male pelvis CT, 531, 532
of male pelvis MRI, 566
sagittal view
of abdomen CT, 486
of abdomen MRI, 509
of female pelvis CT, 543
of male pelvis MRI, 559
- Colon, descending
axial view
of abdomen CT, 479, 480
of abdomen MRI, 499, 500, 501
of female pelvis MRI, 572
of male pelvis CT, 522, 523
of male pelvis MRI, 553, 554

- Colon, descending (*Continued*)
 coronal view
 of abdomen CT, 489, 491, 492
 of abdomen MRI, 512, 513, 514, 515
 of female pelvis CT, 547, 548
 of female pelvis MRI, 581
 of male pelvis CT, 531, 532, 533
 of male pelvis MRI, 566
 sagittal view
 of abdomen CT, 481
 of abdomen MRI, 502, 503
 of male pelvis CT, 528
- Colon, hepatic flexure
 axial view
 of abdomen CT, 478, 479
 of abdomen MRI, 499, 500
 coronal view
 of abdomen CT, 488, 489, 490
 of abdomen MRI, 510, 511
 of thorax CT, 453
 sagittal view
 of abdomen CT, 486
 of abdomen MRI, 509
 of thorax CT, 452
- Colon, rectosigmoid
 axial view, of female pelvis CT, 539
 coronal view
 of female pelvis MRI, 583
 of male pelvis CT, 535
 sagittal view, of female pelvis MRI, 579
- Colon, sigmoid
 axial view
 of female pelvis CT, 538, 539, 540
 of female pelvis MRI, 572
 of male pelvis CT, 523, 524
 of male pelvis MRI, 554, 555
 coronal view
 of abdomen CT, 487
 of abdomen MRI, 512
 of female pelvis CT, 547, 548, 549, 550
 of male pelvis CT, 532, 533, 534, 536
 of male pelvis MRI, 566, 567, 568, 569
 sagittal view
 of abdomen CT, 482, 483
 of female pelvis CT, 544, 545
 of female pelvis MRI, 578
 of male pelvis CT, 528, 529, 530
 of male pelvis MRI, 561, 562, 563, 564
- Colon, splenic flexure
 axial view
 of abdomen CT, 478, 479
 of abdomen MRI, 496, 497, 498
 coronal view
 of abdomen CT, 488, 489, 490, 491
 of abdomen MRI, 511, 512
 sagittal view, of abdomen MRI, 502
- Colon, transverse
 axial view
 of abdomen CT, 479, 480
 of abdomen MRI, 498, 499, 500, 501
 coronal view
 of abdomen CT, 487, 488
 of abdomen MRI, 510, 511
 of male pelvis CT, 531, 532
 sagittal view
 of abdomen CT, 481, 482, 483, 484, 485
 of abdomen MRI, 503, 504, 505, 506, 507, 508, 509
- Conjoined t.
 of coracobrachialis m. and biceps m., short head, 7, 41
 of semitendinosus m. and biceps femoris m., long head
 axial view
 of female pelvis MRI, 575
 of hip, 230, 231, 232
 of male pelvis MRI, 558
 coronal view, of thigh, 291, 292
 sagittal view, of male pelvis MRI, 559
- Conus medullaris
 coronal view, of thoracic spine, 420
 sagittal view
 of lumbar spine, 431
 of thoracic spine, 419
- Coracoacromial lig.
 axial view
 of shoulder, 38, 39, 40
 of shoulder arthrogram, 68, 69
- Coracoacromial lig. (*Continued*)
 oblique sagittal view
 of shoulder, 50, 51
 of shoulder arthrogram, 73, 74, 75
 sagittal view, of pectoral girdle and chest wall, 16, 17
- Coracobrachialis m.
 and biceps m., short head, conjoined tendon of, 7, 41
 axial view
 of arm, 92
 of pectoral girdle and chest wall, 7, 8, 9, 10, 11, 12, 13
 of shoulder, 41, 42, 43, 44, 45
- coronal view
 of arm, 106, 107
 of pectoral girdle and chest wall, 25, 26, 27, 28, 29
 oblique coronal view, of shoulder, 57, 58, 59, 60, 61, 62
 oblique sagittal view
 of shoulder, 50, 51, 52
 of shoulder arthrogram, 75
 origin, insertion, and nerve supply of, 91t
- sagittal view
 of arm, 102, 103, 104
 of pectoral girdle and chest wall, 16, 17
- Coracobrachialis t.
 ABER view, of shoulder arthrogram, 84
- axial view
 of pectoral girdle and chest wall, 7
 of shoulder, 42, 43, 44
 of shoulder arthrogram, 70, 71
 oblique coronal view
 of shoulder, 57
 of shoulder arthrogram, 78, 79
 oblique sagittal view, of shoulder arthrogram, 74
- Coracoclavicular lig.
 axial view, of shoulder, 39
 conoid portion
 axial view, of shoulder, 38, 39
 oblique coronal view, of shoulder, 56, 57
 oblique sagittal view, of shoulder, 54, 55
 trapezoid portion
 axial view, of shoulder, 38, 39
 oblique coronal view, of shoulder, 57
 oblique sagittal view
 of shoulder, 53, 54
 of shoulder arthrogram, 76, 77
- Coracohumeral lig.
 axial view
 of shoulder, 39, 40
 of shoulder arthrogram, 68
 oblique coronal view
 of shoulder, 57, 58, 59
 of shoulder arthrogram, 78
 oblique sagittal view
 of shoulder, 48, 49, 50, 51, 52
 of shoulder arthrogram, 74
 sagittal view, of pectoral girdle and chest wall, 17
- Coracoid process
 ABER view, of shoulder arthrogram, 84
- axial view
 of pectoral girdle and chest wall, 6, 7
 of shoulder, 39, 40, 41
 of shoulder arthrogram, 67, 68, 69, 70
- base
 oblique coronal view, of shoulder arthrogram, 78
 oblique sagittal view, of shoulder, 53
 coronal view, of pectoral girdle and chest wall, 25, 26, 27
 oblique coronal view
 of shoulder, 57, 58
 of shoulder arthrogram, 78
 oblique sagittal view
 of shoulder, 50, 51, 52
 of shoulder arthrogram, 75, 76, 77
 sagittal view, of pectoral girdle and chest wall, 17
 tip, oblique sagittal view, of shoulder arthrogram, 74
- Coronary a., axial view
 of heart MRI, 462, 463
 of thorax CT, 445, 448
- Coronary sinus, axial view, of heart MRI, 463
- Coronoid fossa
 axial view, of elbow, 115, 116
 oblique coronal, of elbow, 139
 oblique sagittal view, of elbow, 129, 130
 sagittal view
 of arm, 101, 102
 of elbow, 129, 130
- Coronoid process
 axial view, of elbow, 119, 120
 oblique coronal, of elbow, 138, 139
 oblique sagittal view, of elbow, 129, 130
 sagittal view
 of arm, 100, 101
 of elbow, 129, 130
- Corpus cavernosum
 axial view
 of male pelvis CT, 527
 of male pelvis MRI, 558
 coronal view
 of male pelvis CT, 531, 534
 of male pelvis MRI, 565, 566
 sagittal view
 of male pelvis CT, 529, 530
 of male pelvis MRI, 562, 563
- Corpus spongiosum
 axial view
 of male pelvis CT, 527
 of male pelvis MRI, 558
 coronal view
 of male pelvis CT, 531, 534
 of male pelvis MRI, 565, 566, 567
 sagittal view, of male pelvis MRI, 564
- Costal cartilage
 axial view
 of abdomen CT, 475
 of abdomen MRI, 494
 coronal view
 of abdomen CT, 487
 of abdomen MRI, 510
 of pectoral girdle and chest wall, 24
 sagittal view
 of abdomen CT, 481
 of pectoral girdle and chest wall, 21, 22, 23
- Costochondral cartilage
 axial view, of pectoral girdle and chest wall, 9
 coronal view, of heart MRI, 467
- Costoclavicular lig., coronal view, of pectoral girdle and chest wall, 25
- Costotransverse foramen, axial view, of thoracic spine, 415, 416
- Costotransverse joint
 axial view
 of pectoral girdle and chest wall, 6
 of thoracic spine, 415, 416
 coronal view
 of pectoral girdle and chest wall, 31, 32
 of thoracic spine, 421
 sagittal view, of thoracic spine, 417, 418
- Costovertebral joint
 axial view
 of pectoral girdle and chest wall, 6, 8, 13
 of thoracic spine, 415
 coronal view
 of pectoral girdle and chest wall, 32
 of thoracic spine, 420
 sagittal view, of thoracic spine, 418
- Cotyloid notch, 261
- Crista, coronal view, of foot, 400, 401
- Cruciate lig., anterior
 axial view, of knee, 298
 coronal view
 of knee, 315, 316
 of leg, 343
 sagittal view, of knee, 305, 306
- Cruciate lig., posterior
 axial view, of knee, 298, 299
 coronal view
 of knee, 315, 316, 317
 of leg, 343, 344
 sagittal view
 of knee, 306, 307
 of leg, 338
- Crural fascia, axial view, of leg, 324, 325, 326, 327, 328, 329, 330, 332
- Crural septum
 anterior, axial view, of leg, 326, 327
 posterior, axial view, of leg, 329, 330, 331
- Cubital tunnel retinaculum, axial view, of elbow, 116, 117
- Cubital v., median
 axial view, of elbow, 115, 116, 117, 118
 oblique coronal, of elbow, 134, 135, 136, 137
 oblique sagittal view, of elbow, 129, 130

- Cubital v., median (*Continued*)
 sagittal view
 of elbow, 129, 130
 of forearm, 156
- Cuboid
 axial view
 of ankle, 355, 356, 357
 of foot, 386, 387, 388, 389
 coronal view
 of ankle, 372, 373
 of foot, 406, 407
 oblique axial view, of ankle, 363, 364
 sagittal view
 of ankle, 366, 367, 368, 369
 of foot, 391, 392, 393, 394
- Cuboid sulcus, sagittal view, of ankle, 367
- Cuneiform, lateral
 axial view
 of ankle, 354, 355
 of foot, 385, 386, 387
 coronal view, of foot, 405, 406, 407
 oblique axial view, of ankle, 363, 364
 sagittal view
 of ankle, 368, 369
 of foot, 392, 393, 394
- Cuneiform, medial
 axial view
 of ankle, 355
 of foot, 385, 386, 387
 coronal view, of foot, 405, 406
 oblique axial view, of ankle, 363, 364
 sagittal view
 of ankle, 370, 371
 of foot, 395, 396, 397
- Cuneiform, middle
 axial view
 of ankle, 354, 355
 of foot, 385, 386
 coronal view, of foot, 405, 406
 oblique axial view, of ankle, 363, 364
 sagittal view
 of ankle, 369, 370
 of foot, 394, 395
- Cuneiform joint, sagittal view, of ankle, 370
- Cuneocuboid lig.
 plantar, axial view, of ankle, 356
 sagittal view, of ankle, 368
- Cystic duct, axial view, of abdomen MRI, 497
- D**
- Deltoid lig.
 axial view, of ankle, 352, 353, 354
 coronal view, of ankle, 373, 374, 375, 376
 oblique axial view, of ankle, 361
 sagittal view, of ankle, 371
- Deltoid m.
 anterior
 axial view, of pectoral girdle and chest wall, 6, 7, 8
 coronal view, of pectoral girdle and chest wall, 24
 axial view
 of arm, 92
 of pectoral girdle and chest wall, 6, 7, 8, 9, 10, 11, 12, 13
 of shoulder, 37, 38, 39, 40, 41, 42, 43, 44, 45
 of shoulder arthrogram, 67, 68, 69, 70
 coronal view
 of arm, 105, 106, 108, 109, 110, 111, 112, 113
 of pectoral girdle and chest wall, 25, 26, 27, 28, 29, 30, 31, 32, 33
 of thoracic spine, 422
 middle, axial view, of pectoral girdle and chest wall, 6
 oblique coronal view
 of shoulder, 56, 57, 58, 59, 60, 61, 62, 63, 64, 65
 of shoulder arthrogram, 79, 80, 81, 82, 83
 oblique sagittal view
 of shoulder, 46, 47, 48, 49, 50, 51, 52, 53, 54, 55
 of shoulder arthrogram, 72, 73, 74, 75
 origin, insertion, and nerve supply, of, 35t, 412–414t
 posterior, axial view, of pectoral girdle and chest wall, 6, 7
 sagittal view
 of arm, 98, 99, 100, 101, 102, 103, 104
 of pectoral girdle and chest wall, 14, 15, 16, 17, 18
- Deltoid t.
 coronal view, of arm, 110, 111
 oblique coronal view, of shoulder, 62
- Deltoid tuberosity
 axial view, of arm, 92
 coronal view, of arm, 109
 sagittal view, of pectoral girdle and chest wall, 14, 15
- Deltopectoral triangle
 axial view, of shoulder, 42, 43, 44, 45
 oblique sagittal view, of shoulder, 50
- Diaphragm
 axial view
 of abdomen MRI, 494, 496, 497, 498, 499, 500
 of thorax CT, 448
 coronal view
 of abdomen CT, 487, 489
 of abdomen MRI, 513, 514, 515
 sagittal view
 of abdomen CT, 481, 483, 484, 485
 of thorax CT, 449, 452
 urogenital
 coronal view, of female pelvis CT, 550
 sagittal view, of male pelvis CT, 529
- Diaphragm, crus
 axial view
 of abdomen CT, 476, 477, 478
 of abdomen MRI, 494, 495
 coronal view
 of abdomen CT, 490, 491, 492
 of abdomen MRI, 516
 of lumbar spine, 433, 434, 435
 of thoracic spine, 420
 sagittal view, of abdomen CT, 483, 484, 485
- Digital a., palmar
 axial view, of hand, 201, 204
 coronal view, of hand, 215, 216
 sagittal view
 of hand, 210, 211
 of wrist, 181, 182
- Digital n., palmar, axial view, of hand, 204
- Digital neurovascular structures, axial view, of hand, 204
- Digital v.
 dorsal, axial view, of hand, 204
 palmar, axial view, of hand, 204
- Distal phalanx
 index finger, sagittal view, 206, 207, 208
 long finger, sagittal view, 209, 210
 ring finger, sagittal view, 211, 212
 small finger, sagittal view, 213
 thumb
 coronal view, 216
 sagittal view, 205
- Dorsal nerve root ganglion, sagittal view, of thoracic spine, 418, 419
- Dorsal ramus n. and vessels, coronal view, of lumbar spine, 434, 436
- Duodenal bulb
 axial view
 of abdomen CT, 478
 of abdomen MRI, 498
 coronal view
 of abdomen CT, 487
 of abdomen MRI, 512, 513
 sagittal view, of abdomen MRI, 508
- Duodenojejunal junction, axial view, of abdomen MRI, 501
- Duodenum
 axial view, of abdomen CT, 477
 sagittal view, of thorax CT, 451
- Duodenum, second portion
 axial view
 of abdomen CT, 478, 479
 of abdomen MRI, 498, 499, 500, 501
 coronal view
 of abdomen CT, 489, 490
 of abdomen MRI, 513, 514
 of thorax CT, 453
 sagittal view
 of abdomen CT, 485
 of abdomen MRI, 509
- Duodenum, third portion
 axial view
 of abdomen CT, 479
 of abdomen MRI, 500, 501
 coronal view, of abdomen CT, 489
- Duodenum, third portion (*Continued*)
 sagittal view
 of abdomen CT, 482, 483, 484
 of abdomen MRI, 505, 506, 507, 508
- Dura mater, coronal view, of thoracic spine, 420
- E**
- Endocervical canal
 axial view, of female pelvis MRI, 574
 coronal view, of female pelvis MRI, 582, 583
 sagittal view, of female pelvis MRI, 579
- Endometrial canal
 axial view, of female pelvis MRI, 573
 coronal view, of female pelvis MRI, 581, 582
 sagittal view, of female pelvis MRI, 579
- Epicondyle, lateral
 axial view, of elbow, 116, 117, 118
 coronal view
 of arm, 107, 108
 of elbow, 139, 140, 141
 oblique coronal, of elbow, 139, 140, 141
 oblique sagittal view, of elbow, 126
- Epicondyle, medial
 axial view, of elbow, 116, 117
 coronal view
 of arm, 106, 107
 of elbow, 139, 140
 oblique coronal, of elbow, 139, 140
 oblique sagittal view, of elbow, 131, 132
 sagittal view
 of arm, 103
 of elbow, 131, 132
- Epidural fat
 coronal view
 of lumbar spine, 435, 436
 of thoracic spine, 420
 sagittal view, of thoracic spine, 418, 419
- Epidural space, posterior, sagittal view, of thoracic spine, 419
- Epidural v., axial view, of lumbar spine, 425, 426
- Epidural vessels
 coronal view, of lumbar spine, 434
 sagittal view, of thoracic spine, 419
- Epigastric a., inferior
 axial view
 of female pelvis CT, 538, 539
 of male pelvis CT, 524
 coronal view
 of abdomen CT, 487
 of female pelvis CT, 546
 of male pelvis CT, 531
 sagittal view, of male pelvis CT, 528
- Epigastric v., inferior
 axial view
 of female pelvis CT, 538, 539
 of male pelvis CT, 524
 coronal view
 of abdomen CT, 487
 of female pelvis CT, 546
 of male pelvis CT, 531
 sagittal view, of male pelvis CT, 528
- Epigastric vessels, inferior
 axial view
 of female pelvis CT, 540
 of male pelvis MRI, 554, 555
 coronal view, of male pelvis MRI, 565
 sagittal view, of abdomen CT, 485
- Epitrochlear lymph node, oblique coronal, of elbow, 138
- Erector spinae m.
 axial view
 of abdomen MRI, 495, 497, 498, 499, 500, 501
 of male pelvis CT, 523
 of male pelvis MRI, 553, 554
 of pectoral girdle and chest wall, 8, 10, 11, 12, 13
 of thoracic spine, 415, 416
 coronal view
 of female pelvis MRI, 583, 584
 of male pelvis MRI, 569, 570
 of pectoral girdle and chest wall, 32, 33
 of thoracic spine, 421, 422
 sagittal view
 of abdomen MRI, 503, 505, 507, 508
 of female pelvis MRI, 576, 577
 of male pelvis CT, 530

- Erector spinae m. (*Continued*)
 of male pelvis MRI, 560, 561, 562, 563, 564
 of pectoral girdle and chest wall, 23
 of thoracic spine, 417, 418, 419
- Esophagus
 axial view
 of abdomen CT, 475
 of abdomen MRI, 494
 of heart MRI, 460, 461, 462, 463
 of pectoral girdle and chest wall, 5
 of thoracic spine, 416
 of thorax CT, 442, 443, 445, 446, 447, 448
- coronal view
 of abdomen MRI, 515
 of thorax CT, 455, 456
- sagittal view
 of abdomen CT, 483
 of abdomen MRI, 505
 of thoracic spine, 418, 419
 of thorax CT, 450, 451
- Extensor carpi radialis brevis m.
 axial view
 of elbow, 116, 117, 118, 119, 120, 121, 122, 123, 124
 of forearm, 146, 147, 148, 149, 150, 151
- coronal view
 of elbow, 136, 137, 138, 139
 of forearm, 166, 167, 168, 169
- oblique coronal, of elbow, 136, 137, 138, 139
- oblique sagittal view, of elbow, 125, 126, 127
- origin, insertion, and nerve supply of, 144–145t
- sagittal view
 of elbow, 125, 126, 127
 of forearm, 156, 157, 158
- Extensor carpi radialis brevis t.
 axial view
 of forearm, 151, 152, 153, 154
 of hand, 198
- coronal view
 of forearm, 167
- of hand, 217
- Extensor carpi radialis longus m.
 axial view
 of arm, 95, 96, 97
 of elbow, 115, 116, 117, 118, 119, 120, 121, 123, 124
 of forearm, 146, 147, 148, 149, 150
- coronal view
 of arm, 108
 of elbow, 134, 135, 136, 137, 138, 139, 140, 141
 of forearm, 167, 168, 169
- oblique coronal, of elbow, 134, 135, 136, 137, 138, 139, 140, 141
- oblique sagittal view, of elbow, 125, 126, 127
- origin, insertion, and nerve supply of, 144–145t
- sagittal view
 of arm, 98
 of elbow, 125, 126, 127
 of forearm, 156, 157
- Extensor carpi radialis longus t.
 axial view
 of forearm, 150, 151, 152, 153, 154
 of hand, 198
- coronal view
 of forearm, 167
 of hand, 217
- sagittal view, of forearm, 157
- Extensor carpi ulnaris m.
 axial view
 of elbow, 121, 122, 123, 124
 of forearm, 146, 147, 148, 149, 150, 151, 152, 153, 154, 155
- coronal view
 of elbow, 139, 140, 141
 of forearm, 166, 167, 168, 169
- oblique coronal view, of elbow, 139, 140, 141
- oblique sagittal view, of elbow, 126, 127, 128
- origin, insertion, and nerve supply of, 144–145t
- sagittal view
 of elbow, 126, 127, 128
 of forearm, 160, 161
- Extensor carpi ulnaris t.
 axial view
 of elbow, 118, 119, 120
 of forearm, 154, 155
- coronal view
 of elbow, 139
- Extensor carpi ulnaris t. (*Continued*)
 of forearm, 164, 165, 166
 of hand, 216, 217
- oblique coronal, of elbow, 139
- sagittal view, of hand, 211, 212
- Extensor digiti minimi m.
 axial view
 of elbow, 122, 123, 124
 of forearm, 146, 147, 148, 149, 150, 151
- coronal view, of forearm, 168
- oblique sagittal view, of elbow, 126, 127
- origin, insertion, and nerve supply of, 144–145t
- Extensor digiti minimi t.
 axial view
 of elbow, 118, 119, 120, 121, 122
 of forearm, 151, 152, 153, 154, 155
 of hand, 198, 199, 200, 201, 202, 203
- coronal view
 of elbow, 139
 of hand, 217
- oblique coronal, of elbow, 139
- oblique sagittal view, of elbow, 126
- sagittal view
 of elbow, 126
 of forearm, 159, 160
 of hand, 212
- Extensor digitorum, origin, insertion, and nerve supply of, 382–384t
- Extensor digitorum brevis m.
 axial view
 of ankle, 353, 354, 355, 356
 of foot, 386, 387
- coronal view
 of ankle, 372, 373, 374
 of foot, 405, 406
- oblique axial view, of ankle, 362, 363, 364
- sagittal view
 of ankle, 366, 367, 368
 of foot, 391, 392, 393
- Extensor digitorum longus m.
 axial view
 of ankle, 349, 350, 351
 of knee, 300, 301
 of leg, 324, 325, 326, 327, 328, 329, 330, 331, 332, 333
- coronal view
 of ankle, 373, 374, 375
 of foot, 407
 of knee, 315, 316, 317, 318
 of leg, 342, 343
- oblique axial view, of ankle, 359, 360
- origin, insertion, and nerve supply of, 322–323t
- sagittal view
 of ankle, 366, 367, 368
 of knee, 303
 of leg, 334, 335, 336
- Extensor digitorum longus t.
 axial view
 of ankle, 349, 350, 351, 352, 353
 of leg, 326, 327, 328, 329, 330, 331, 332, 333
- coronal view
 of ankle, 372
 of foot, 406, 407
 of leg, 342
- oblique axial view, of ankle, 359, 360, 361, 362, 363, 364
- sagittal view
 of ankle, 367, 368
 of foot, 393, 394, 395
 of leg, 334, 335, 336
- Extensor digitorum m.
 axial view
 of elbow, 120, 121, 122, 123, 124
 of forearm, 146, 147, 148, 149, 150, 151, 152, 153
- coronal view
 of elbow, 137, 138, 139
 of forearm, 167, 168, 169
- oblique coronal, of elbow, 137, 138, 139
- oblique sagittal view, of elbow, 125, 126, 127
- origin, insertion, and nerve supply of, 144–145t, 382–384t
- sagittal view
 of elbow, 125, 126, 127
 of forearm, 158, 159, 160, 161
- Extensor digitorum t.
 axial view
 of elbow, 118, 119
 of forearm, 151, 152, 153, 154, 155
 of hand, 198, 199, 200, 201, 202, 203, 204
- coronal view, of hand, 217, 218
- sagittal view
 of foot, 391, 395
 of hand, 207, 208, 209, 210, 211, 212
- Extensor expansion (hood)
 axial view, of hand, 203, 204
- coronal view, of hand, 216, 217, 218
- sagittal view, of hand, 205, 205, 206, 212, 213
- Extensor hallucis brevis m., oblique axial view, of ankle, 364
- Extensor hallucis longus m.
 axial view
 of ankle, 349, 350, 351
 of leg, 331, 332, 333
- coronal view
 of ankle, 372, 373
 of leg, 342, 343
- oblique axial view, of ankle, 359, 360, 361, 362
- origin, insertion, and nerve supply of, 322–323t
- sagittal view, of ankle, 367
- Extensor hallucis longus t.
 axial view
 of ankle, 349, 350, 351, 352
 of foot, 385, 386, 387
 of leg, 331, 332, 333
- coronal view
 of ankle, 372
 of foot, 399, 400, 401, 402, 403, 404, 405, 406, 407
 of leg, 342, 343
- oblique axial view, of ankle, 359, 360, 361, 362, 363, 364
- sagittal view
 of ankle, 368, 369
 of foot, 396, 397
- Extensor indicis m.
 axial view
 of forearm, 153, 154, 155
- coronal view, of forearm, 165, 166
- origin, insertion, and nerve supply of, 144–145t
- sagittal view, of forearm, 160
- Extensor indicis t.
 axial view
 of forearm, 155
 of hand, 198, 199, 200, 201, 202, 203, 204
- sagittal view, of forearm, 160
- Extensor pollicis brevis m.
 axial view
 of forearm, 151, 152, 153, 154, 155
- coronal view, of forearm, 166
- origin, insertion, and nerve supply of, 144–145t
- sagittal view, of forearm, 158, 159
- Extensor pollicis brevis t.
 axial view
 of forearm, 154, 155
 of hand, 198, 199, 200
- coronal view, of hand, 214, 215, 216
- sagittal view, of forearm, 158
- Extensor pollicis longus m.
 axial view, of forearm, 147, 148, 149, 150, 151, 152, 153, 154
- coronal view, of forearm, 166, 167
- origin, insertion, and nerve supply of, 144–145t
- sagittal view, of forearm, 159, 160
- Extensor pollicis longus t.
 axial view
 of forearm, 155
 of hand, 198, 199, 200, 201, 202
- coronal view
 of forearm, 166
 of hand, 216, 217
- Extensor retinaculum
 axial view, of ankle, 349, 350, 354
- oblique axial view, of ankle, 359, 362, 363
- Extensor t.
 common
 axial view, of elbow, 118
 oblique coronal, of elbow, 139, 140
- coronal view, of foot, 399, 401, 402, 403, 404, 405

- F**
- Facet joint
axial view, of lumbar spine, 425
sagittal view, of thoracic spine, 418, 419
- Falciform lig.
axial view, of abdomen CT, 477
coronal view, of abdomen CT, 487
sagittal view, of abdomen CT, 485
- Fat pad, anterior
axial view, of elbow, 115, 116
oblique sagittal view, of elbow, 129
sagittal view
of arm, 101, 102
of elbow, 129
- Fat pad, infrapatellar
axial view, of knee, 298, 299, 300
coronal view
of knee, 311, 312
of leg, 342
sagittal view
of knee, 304, 305, 306, 307
of leg, 336, 337, 338
- Fat pad, posterior
axial view, of elbow, 115
oblique sagittal view, of elbow, 128, 129
sagittal view
of arm, 101, 102
of elbow, 128, 129
- Femoral a.
axial view
of hip, 229, 230
of hip arthrogram, 251, 252, 254, 256
coronal view
of female pelvis MRI, 580
of male pelvis CT, 531
of thigh, 287, 290
sagittal view, of thigh, 283
- Femoral a., common
axial view
of female pelvis CT, 540, 541
of hip, 226, 227
of male pelvis CT, 525, 526
of male pelvis MRI, 556, 557
coronal view
of female pelvis CT, 546
of hip, 243, 244
of male pelvis MRI, 565
sagittal view
of female pelvis CT, 543
of hip, 240
of male pelvis CT, 528
- Femoral a., deep
axial view
of female pelvis CT, 541, 542
of hip, 228
of male pelvis CT, 527
of thigh, 269, 270, 271, 272
coronal view
of female pelvis CT, 547
of hip, 244
of male pelvis CT, 532
sagittal view
of hip, 235
of male pelvis CT, 528
of thigh, 279
- Femoral a., superficial
axial view
of female pelvis CT, 541, 542
of hip, 228
of male pelvis CT, 527
of male pelvis MRI, 557, 558
of thigh, 269, 270, 271, 272, 273, 274, 275
coronal view, of thigh, 288, 289
sagittal view, of male pelvis CT, 528
- Femoral circumflex a.
lateral
axial view, of male pelvis CT, 527
coronal view, of male pelvis CT, 533
medial
axial view, of male pelvis CT, 527
coronal view, of male pelvis CT, 533, 534
sagittal view, of male pelvis CT, 528
- Femoral circumflex v.
lateral, coronal view, of male pelvis CT, 533, 534
medial, coronal view, of male pelvis CT, 533, 534
- Femoral circumflex vessels
lateral
axial view, of hip, 228
coronal view, of male pelvis MRI, 566
sagittal view, of hip, 234, 235, 236
medial
axial view, of hip, 228, 230
coronal view, of male pelvis MRI, 566
sagittal view, of hip, 237, 239, 240
- Femoral condyle
lateral
axial view, of knee, 297, 298
coronal view
of knee, 311, 312, 313, 314, 315, 316, 317, 318
of leg, 343, 344
sagittal view, of knee, 302, 303, 304
medial
axial view, of knee, 297, 298
coronal view
of knee, 312, 313, 314, 315, 316, 317, 318
of leg, 343, 344
sagittal view
of knee, 308, 309, 310
of leg, 340
of thigh, 281
- Femoral cortex
anterior, coronal view, of thigh, 287
medial, sagittal view, of thigh, 280
posterior, coronal view, of thigh, 289
- Femoral diaphysis
axial view, of thigh, 269
coronal view, of hip, 245
sagittal view, of hip, 235, 236
- Femoral head
axial view
of female pelvis CT, 540
of female pelvis MRI, 574, 575
of hip, 226, 227, 228
of hip arthrogram, 251
of male pelvis CT, 525
of male pelvis MRI, 555, 556
coronal view
of female pelvis CT, 548, 549, 550
of female pelvis MRI, 581, 582
of hip, 245, 246
of hip arthrogram, 262, 265
of male pelvis CT, 533, 534
of male pelvis MRI, 566, 567, 568
sagittal view
of hip, 237, 239, 240
of hip arthrogram, 257, 258, 259, 260, 261
of male pelvis MRI, 559
- Femoral lig., head
coronal view, of male pelvis MRI, 567
sagittal view, of male pelvis MRI, 559
- Femoral n.
axial view, of hip, 227
coronal view
of female pelvis MRI, 580
of male pelvis CT, 532
- Femoral neck
axial view
of female pelvis CT, 541
of hip, 228, 229
of hip arthrogram, 254, 256
of male pelvis MRI, 557
coronal view
of female pelvis CT, 548, 549
of female pelvis MRI, 582
of hip, 246
of hip arthrogram, 263, 264, 265
of male pelvis CT, 534
sagittal view
of hip, 237
of hip arthrogram, 257
of thigh, 280
- Femoral shaft, axial view, of thigh, 270
- Femoral trochlea
axial view, of knee, 297, 298
coronal view, of knee, 311
- Femoral v.
axial view
of hip, 228, 229, 230
of hip arthrogram, 251, 252, 254, 256
of male pelvis MRI, 557, 558
- Femoral v. (Continued)
coronal view
of female pelvis MRI, 580
of male pelvis CT, 531, 532
of thigh, 287, 290
sagittal view, of thigh, 284
- Femoral v., common
axial view
of female pelvis CT, 540, 541
of hip, 226, 227, 228
of male pelvis CT, 525, 526
of male pelvis MRI, 556, 557
coronal view
of female pelvis CT, 546
of hip, 243, 244
of male pelvis MRI, 565
sagittal view, of hip, 239
- Femoral v., deep
axial view
of female pelvis CT, 541, 542
of thigh, 269, 270, 271, 272
coronal view
of female pelvis CT, 547
of male pelvis CT, 532
sagittal view, of hip, 235
- Femoral v., superficial
axial view
of female pelvis CT, 541, 542
of hip, 230
of male pelvis MRI, 558
of thigh, 270, 271, 272, 273, 274, 275
coronal view, of thigh, 288
sagittal view, of male pelvis CT, 528
- Femoral vessels
axial view, of female pelvis MRI, 574, 575
common, sagittal view, of male pelvis MRI, 559
coronal view
of female pelvis MRI, 581
of thigh, 287
sagittal view
of hip, 240
of hip arthrogram, 261
of male pelvis MRI, 559
- Femoral vessels, deep
axial view, of hip, 231, 232
coronal view
of hip, 244
of thigh, 288, 289
sagittal view
of hip, 238
of thigh, 281, 282
- Femoral vessels, superficial
axial view, of hip, 231, 232
coronal view
of male pelvis MRI, 566
of thigh, 288, 289
sagittal view
of hip, 238
of thigh, 281, 282, 283
- Femur
axial view
of female pelvis CT, 541, 542
of female pelvis MRI, 575
of hip, 229, 231, 232
of knee, 295, 296, 297
of male pelvis CT, 526, 527
of male pelvis MRI, 557, 558
of thigh, 269, 271, 272, 273, 274, 275, 276
coronal view
of female pelvis MRI, 582
of knee, 312, 313, 315
of leg, 342, 343
of male pelvis CT, 535
of male pelvis MRI, 567
of thigh, 288, 289
sagittal view
of knee, 303, 304, 305, 306, 307
of thigh, 278, 279, 280, 281
- Fibula
axial view
of ankle, 349, 350, 351
of knee, 301
of leg, 324, 325, 326, 327, 328, 329, 330, 331, 332, 333
coronal view
of ankle, 376, 377

- Fibula (Continued)**
 of leg, 342, 343, 344, 345
 oblique axial view, of ankle, 359, 360, 361
 sagittal view
 of ankle, 365, 366
 of knee, 304
 of leg, 336
- Fibular head**
 axial view, of knee, 300
 coronal view
 of knee, 318, 319, 320
 of leg, 344, 345
 sagittal view
 of knee, 302, 303
 of leg, 334, 335, 336
- Fibular (lateral) collateral lig.**
 axial view, of knee, 298, 299, 300
 coronal view
 of knee, 317, 318, 319
 of leg, 344
 sagittal view, of knee, 302
- Fibular notch, axial view, of ankle, 350, 351**
- Fibular shaft, sagittal view, of leg, 335**
- Finger, index**
 distal phalanx, sagittal view, 207, 208
 middle phalanx, sagittal view, 207
 proximal phalanx
 coronal view, 216, 217
 sagittal view, 206, 207, 208
 sagittal view, 206, 208
- Finger, long**
 distal phalanx, sagittal view, 209, 210
 middle phalanx
 coronal view, 215
 sagittal view, 209, 210
 proximal phalanx
 coronal view, 216, 217
 sagittal view, 209, 210
- Finger, ring**
 distal phalanx, sagittal view, 211, 212
 middle phalanx
 coronal view, 215
 sagittal view, 211, 212
 proximal phalanx
 coronal view, 216, 217
 sagittal view, 211, 212
- Finger, small**
 distal phalanx, sagittal view, 213
 middle phalanx
 coronal view, 215, 216
 sagittal view, 213
 proximal phalanx
 coronal view, 215, 216
 sagittal view, 212, 213
- Flexor carpi radialis m.**
 axial view
 of elbow, 119, 120, 121, 122, 123, 124
 of forearm, 146, 147, 148, 149, 150, 151
 coronal view
 of elbow, 134, 135, 136, 137
 of forearm, 162, 163, 164, 165
 oblique coronal, of elbow, 134, 135, 136, 137
 oblique sagittal view, of elbow, 129, 130, 131, 132
 origin, insertion, and nerve supply of, 144–145t
 sagittal view
 of arm, 103, 104
 of elbow, 129, 130, 131, 132
 of forearm, 156, 157, 158
- Flexor carpi radialis t.**
 axial view
 of forearm, 150, 151, 152, 153, 154, 155
 coronal view
 of forearm, 165
 of hand, 214
 sagittal view, of hand, 208
- Flexor carpi ulnaris m.**
 axial view
 of elbow, 118, 119, 120, 121, 122, 123, 124
 of forearm, 146, 147, 148, 149, 151, 152, 153, 154, 155
 coronal view
 of elbow, 138, 139, 140, 141
 of forearm, 162, 163, 164
 of hand, 214
 oblique coronal, of elbow, 138, 139, 140, 141
 oblique sagittal view, of elbow, 131, 132, 133
- Flexor carpi ulnaris m. (Continued)**
 origin, insertion, and nerve supply of, 144–145t
 sagittal view
 of elbow, 131, 132, 133
 of forearm, 160, 161
- Flexor carpi ulnaris t.**
 axial view, of forearm, 150, 153, 154, 155
 sagittal view
 of forearm, 158, 159
 of hand, 211
- Flexor digiti minimi brevis m.**
 axial view
 of hand, 198, 199, 200, 201, 202
 coronal view, of foot, 405
 origin, insertion, and nerve supply of, 197t, 382–384t
 sagittal view, of hand, 211
- Flexor digiti minimi m.**
 axial view, of foot, 389, 390
 coronal view
 of foot, 402, 404
 of hand, 215
 sagittal view
 of foot, 391, 392
 of hand, 211, 212
- Flexor digitorum brevis m.**
 axial view
 of ankle, 358
 of foot, 389, 390
 coronal view
 of ankle, 372, 373, 374, 375, 376, 377, 378
 of foot, 404, 405, 406, 407
 oblique axial view, of ankle, 362, 363, 364
 sagittal view
 of ankle, 368, 369, 370, 371
 of foot, 394, 395
- Flexor digitorum brevis t., coronal view, of foot, 399, 402, 403, 404, 405, 406, 407**
- Flexor digitorum longus m.**
 axial view
 of ankle, 349, 350
 of leg, 326, 327, 329, 330, 331, 332, 333
 coronal view, of leg, 343, 344
 origin, insertion, and nerve supply of, 322–323t
 sagittal view, of leg, 338
- Flexor digitorum longus t.**
 axial view
 of ankle, 349, 350, 351, 352, 353, 354, 355, 356
 of foot, 387, 388, 389
 of leg, 326, 327, 329, 330, 331, 332, 333
 coronal view
 of ankle, 372, 373, 374, 375, 376, 377
 of foot, 399, 402, 403, 404, 405, 406, 407
 of leg, 343
 oblique axial view, of ankle, 360, 361, 362, 363, 364
 sagittal view
 of ankle, 370, 371
 of foot, 395
 of leg, 338
- Flexor digitorum m., origin, insertion, and nerve supply of, 382–384t**
- Flexor digitorum profundus m.**
 axial view
 of elbow, 119, 120, 121, 122, 123, 124
 of forearm, 146, 147, 148, 149, 150, 151, 152, 153, 154, 155
 coronal view
 of elbow, 137, 138, 139, 140, 141, 142
 of forearm, 162, 163, 164, 165, 166
 oblique coronal, of elbow, 137, 138, 139, 140, 141, 142
 oblique sagittal view, of elbow, 129, 130, 131, 132
 origin, insertion, and nerve supply of, 144–145t
 sagittal view
 of elbow, 129, 130, 131, 132
 of forearm, 157, 158, 159, 160, 161
- Flexor digitorum profundus t.**
 axial view
 of forearm, 155
 of hand, 198, 199, 200, 201, 202, 203, 204, 208
 coronal view
 of forearm, 162, 163, 164, 165
 of hand, 215
 sagittal view
 of forearm, 157
 of hand, 207, 208, 209, 210, 211, 212, 213
- Flexor digitorum superficialis m.**
 axial view
 of elbow, 118, 119, 120, 121, 122, 123, 124
 of forearm, 146, 147, 148, 149, 150, 151, 152, 153, 154, 155
 coronal view
 of elbow, 135, 136, 137, 138, 139, 140
 of forearm, 162, 163, 164, 165, 166
 oblique coronal
 of elbow, 135, 136, 137, 138, 139, 140
 oblique sagittal view, of elbow, 130, 131, 133
 origin, insertion, and nerve supply of, 144–145t
 sagittal view
 of elbow, 130, 131, 133
 of forearm, 156, 157, 158, 159, 160
- Flexor digitorum superficialis t.**
 axial view
 of forearm, 148, 155
 of hand, 198, 199, 200, 201, 202, 203, 204
 coronal view
 of forearm, 163
 of hand, 214, 215
 sagittal view, of hand, 208, 209, 210, 211, 212, 213
- Flexor digitorum t., sagittal view**
 of fourth toe, 393
 of second toe, 395
 of third toe, 394
- Flexor hallucis brevis m.**
 coronal view, of foot, 405
 origin, insertion, and nerve supply of, 382–384t
 sagittal view, of foot, 396, 397, 398
- Flexor hallucis brevis m., lateral head**
 axial view, of foot, 388, 389
 coronal view, of foot, 402, 403, 404
- Flexor hallucis brevis m., medial head**
 axial view, of foot, 387, 388, 389
 coronal view, of foot, 402, 403, 404
- Flexor hallucis longus fascia**
 axial view, of ankle, 353
 oblique axial view, of ankle, 360
- Flexor hallucis longus m.**
 axial view
 of ankle, 349, 350, 351, 352, 353
 of leg, 325, 326, 327, 328, 329, 330, 331, 332, 333
 coronal view
 of ankle, 378, 379
 of leg, 344, 345
 oblique axial view, of ankle, 359
 origin, insertion, and nerve supply of, 322–323t
 sagittal view
 of ankle, 366, 367, 368
 of leg, 336, 337, 338
- Flexor hallucis longus t.**
 axial view
 of ankle, 349, 350, 351, 352, 353, 355, 356
 of foot, 387, 388, 389, 390
 of leg, 327, 331, 332, 333
 coronal view
 of ankle, 372, 373, 374, 376, 377, 378
 of foot, 399, 400, 401, 402, 404, 405, 406, 407
 of leg, 344
 oblique axial view, of ankle, 359, 360, 361, 363, 364
 sagittal view
 of ankle, 368, 369, 370
 of foot, 395, 396, 397, 398
 of leg, 338, 339
- Flexor hallucis t., oblique axial view, of ankle, 363**
- Flexor pollicis brevis m.**
 axial view
 of hand, 198, 199, 200, 201
 coronal view, of hand, 214, 215
 deep, sagittal view, of hand, 207, 208
 origin, insertion, and nerve supply of, 197t
 sagittal view, of hand, 206
 superficial, sagittal view, of hand, 207, 208
- Flexor pollicis longus m.**
 axial view, of forearm, 148, 149, 150, 151, 152, 153, 155
 coronal view, of forearm, 165, 166, 167
 origin, insertion, and nerve supply of, 144–145t
 sagittal view, of forearm, 157, 158
- Flexor pollicis longus t.**
 axial view
 of forearm, 155
 of hand, 198, 199, 200, 201, 202, 203

- Flexor pollicis longus t. (*Continued*)
 coronal view, of hand, 214, 215, 216
 sagittal view
 of forearm, 157
 of hand, 205, 206, 207, 208
- Flexor retinaculum
 axial view
 of ankle, 349, 350, 351, 352, 353, 354, 355
 coronal view
 of ankle, 375, 376
 of hand, 214
 oblique axial view, of ankle, 360, 361, 362
 sagittal view, of hand, 208, 209, 210
- Flexor t.
 common
 axial view, of elbow, 116, 117, 118
 coronal view, of arm, 107
 coronal view, of foot, 400, 401
- Forearm v.
 deep, oblique sagittal view, of elbow, 129
 superficial
 oblique sagittal view, of elbow, 125
 sagittal view, of forearm, 156
- Fovea
 axial view
 of hip, 227
 of hip arthrogram, 253
 coronal view, of hip arthrogram, 264
- Frenulum, coronal view, of female pelvis MRI, 581
- ## G
- Gallbladder
 axial view
 of abdomen CT, 477, 478
 of abdomen MRI, 498, 499
 body
 coronal view, of abdomen CT, 487, 488
 sagittal view, of abdomen CT, 486
 coronal view, of abdomen MRI, 511, 512, 513
 fundus
 axial view, of abdomen CT, 479
 coronal view, of abdomen CT, 487
 sagittal view, of abdomen CT, 486
 neck
 axial view, of abdomen MRI, 497
 coronal view
 of abdomen CT, 488, 489
 of thorax CT, 453
 sagittal view, of abdomen CT, 485
 sagittal view, of abdomen MRI, 509
- Gastric a.
 axial view, of abdomen MRI, 496, 497
 coronal view
 of abdomen CT, 488, 489, 490, 491
 of abdomen MRI, 513
 sagittal view
 of abdomen CT, 482, 483
 of abdomen MRI, 505
- Gastric v.
 axial view, of abdomen CT, 476
 coronal view, of abdomen CT, 489, 490, 491, 492
 sagittal view, of abdomen CT, 482
- Gastrocnemius aponeurosis
 axial view, of leg, 324, 326
 sagittal view, of leg, 337, 338, 339
- Gastrocnemius m., lateral head
 axial view
 of knee, 297, 298, 299, 300, 301
 of leg, 324, 325, 326, 327, 328
 coronal view
 of knee, 317, 318, 319, 320
 of leg, 345, 346, 347
 sagittal view
 of knee, 302, 303, 304, 305
 of leg, 334, 335, 336, 337
- Gastrocnemius m., medial head
 axial view
 of knee, 296, 297, 298, 299, 300, 301
 of leg, 324, 325, 326, 327, 328, 329
 coronal view
 of knee, 316, 317, 318, 319, 320
 of leg, 343, 344, 345, 346, 347
 sagittal view
 of knee, 307, 308, 309, 310
 of leg, 337, 338, 339, 340, 341
- Gastrocnemius m., origin, insertion, and nerve supply
 of, 322–323t
- Gastrocnemius t., medial head
 axial view, of knee, 298
 coronal view, of knee, 319
- Gastrocolic lig.
 coronal view, of abdomen CT, 487
 sagittal view, of abdomen CT, 483
- Gastrocolic trunk
 axial view, of abdomen CT, 479
 coronal view, of abdomen CT, 488
- Gastrooduodenal a.
 coronal view, of abdomen CT, 488
 sagittal view, of abdomen CT, 484
- Gastroepiploic a.
 coronal view, of abdomen CT, 487
 sagittal view, of abdomen CT, 483
- Gastroepiploic v.
 coronal view, of abdomen CT, 487
 sagittal view, of abdomen CT, 483
- Gastroesophageal junction
 axial view, of abdomen MRI, 494
 coronal view
 of abdomen CT, 490, 491
 of abdomen MRI, 514
 sagittal view
 of abdomen CT, 482
 of abdomen MRI, 504, 505
- Gastrohepatic lig.
 axial view, of abdomen CT, 476
 coronal view, of abdomen CT, 489
 sagittal view, of abdomen CT, 482
- Gemellus m.
 axial view
 of male pelvis CT, 526
 of male pelvis MRI, 556
 coronal view
 of female pelvis CT, 550
 of female pelvis MRI, 583
 of male pelvis MRI, 569
 sagittal view
 of hip, 236
 of male pelvis CT, 528
- Gemellus m., inferior
 axial view, of female pelvis CT, 541
 coronal view
 of female pelvis CT, 551
 of hip, 247
 of male pelvis CT, 535
 origin, insertion, and nerve supply of, 222–223t
- Gemellus m., superior
 axial view, of male pelvis CT, 525
 coronal view
 of female pelvis CT, 551
 of hip, 247
 of male pelvis CT, 535
 origin, insertion, and nerve supply of, 222–223t
 sagittal view
 of hip, 241
 of male pelvis CT, 528
 of male pelvis MRI, 559
- Gemellus t., sagittal view, of hip, 237
- Gerdy's tubercle
 axial view, of knee, 300
 coronal view
 of knee, 313
 of leg, 342, 343
 sagittal view, of knee, 303
- Gissane's angle, sagittal view, of ankle, 367
- Glenohumeral joint
 axial view, of pectoral girdle and chest wall, 7
 coronal view, of arm, 108, 109
- Glenohumeral lig., axial view, of shoulder, 44
- Glenohumeral lig., inferior
 ABER view, of shoulder arthrogram, 86, 87
 axial view
 of shoulder, 44
 of shoulder arthrogram, 71
 oblique coronal view, of shoulder arthrogram, 79, 80
 oblique sagittal view, of shoulder arthrogram, 75, 76
- Glenohumeral lig., middle
 ABER view, of shoulder arthrogram, 84, 85
 axial view
 of shoulder, 40
 of shoulder arthrogram, 68, 69, 70
- Glenohumeral lig., middle (*Continued*)
 oblique coronal view, of shoulder arthrogram, 78, 79
 oblique sagittal view, of shoulder arthrogram, 75, 76
- Glenohumeral lig., superior
 ABER view, of shoulder arthrogram, 84
 axial view
 of shoulder, 39, 40
 of shoulder arthrogram, 67, 68
 oblique coronal view, of shoulder, 59
 oblique sagittal view
 of shoulder, 49, 50, 51
 of shoulder arthrogram, 75, 76
- Glenoid
 ABER view, of shoulder arthrogram, 84, 85, 86, 87, 88, 89
 axial view
 of pectoral girdle and chest wall, 6, 7, 8
 of shoulder, 39, 40, 41, 42
 of shoulder arthrogram, 67, 68, 70
 of thorax CT, 442
 coronal view
 of arm, 109, 110
 of pectoral girdle and chest wall, 28
 oblique coronal view
 of shoulder, 59, 60, 61, 62
 of shoulder arthrogram, 79, 80, 81, 82
 oblique sagittal view
 of shoulder, 52
 of shoulder arthrogram, 76, 77
 sagittal view
 of arm, 103, 104
 of pectoral girdle and chest wall, 16
- Glenoid, inferior
 ABER view, of shoulder arthrogram, 87, 88
 axial view, of shoulder arthrogram, 71
- Glenoid, posterior
 coronal view, of pectoral girdle and chest wall, 29
 oblique coronal view, of shoulder arthrogram, 82
- Glenoid, superior
 axial view, of shoulder arthrogram, 67
 coronal view, of pectoral girdle and chest wall, 28
- Glenoid fossa, oblique sagittal view, of shoulder arthrogram, 76
- Glenoid labrum
 axial view
 of shoulder, 40, 41, 42, 43
 coronal view
 of arm, 108, 109
 of pectoral girdle and chest wall, 27
- Glenoid neck, axial view, of shoulder, 41, 42
- Gluteal a., inferior
 axial view, of hip, 226, 227
 coronal view
 of female pelvis CT, 551
 of hip, 247, 248
 of lumbar spine, 433
 of male pelvis CT, 536
 sagittal view
 of female pelvis MRI, 576
 of lumbar spine, 430
 of male pelvis CT, 528
 of male pelvis MRI, 560
- Gluteal a., superior
 axial view
 of female pelvis CT, 538
 of hip, 224
 of male pelvis MRI, 554
 coronal view
 of hip, 247, 248
 of lumbar spine, 433
 of male pelvis CT, 536
 sagittal view
 of hip, 242
 of lumbar spine, 430
 of male pelvis MRI, 560
- Gluteal a., trunk, coronal view, of lumbar spine, 433
- Gluteal tuberosity, axial view, of hip, 231
- Gluteal v., inferior
 axial view, of hip, 226
 coronal view
 of female pelvis CT, 551
 of lumbar spine, 433, 435
 of male pelvis CT, 536
 sagittal view, of male pelvis CT, 528

- Gluteal v., superior
axial view, of hip, 224
coronal view
of lumbar spine, 433, 435
of male pelvis CT, 536
sagittal view, of hip, 242
- Gluteal vessels, inferior
axial view, of male pelvis MRI, 555
coronal view
of female pelvis MRI, 583
of lumbar spine, 434, 435, 436
sagittal view, of hip, 241
- Gluteal vessels, superior
axial view, of female pelvis MRI, 572
coronal view
of female pelvis MRI, 583
of lumbar spine, 434, 435, 436
sagittal view, of hip, 240, 241
- Gluteus maximus m.
axial view
of female pelvis CT, 538, 539, 540, 541, 542
of female pelvis MRI, 572, 573, 574, 575
of hip, 224, 225, 226, 227, 228, 229, 230, 231, 232
of lumbar spine, 428
of male pelvis CT, 523, 524, 525, 526, 527
of male pelvis MRI, 554, 555, 557, 558
of thigh, 269, 270, 271
coronal view
of female pelvis CT, 550, 551
of female pelvis MRI, 583, 584
of hip, 247, 248, 249
of lumbar spine, 429, 435, 436
of male pelvis CT, 535, 536
of male pelvis MRI, 569, 570
of thigh, 290, 291, 292
origin, insertion, and nerve supply of, 222–223t
sagittal view
of abdomen MRI, 502, 509
of female pelvis CT, 543, 544
of female pelvis MRI, 576, 577
of hip, 233, 234, 235, 236, 237, 238, 239, 240, 241, 242
of lumbar spine, 430
of male pelvis CT, 528, 529
of male pelvis MRI, 559, 560, 561, 562
of thigh, 277, 278, 279, 280, 281, 282, 283, 284, 285
- Gluteus medius m.
axial view
of female pelvis CT, 538, 539, 540, 541
of female pelvis MRI, 572, 573, 574, 575
of hip, 224, 225, 226, 227, 228, 229
of lumbar spine, 426, 427, 429
of male pelvis CT, 522, 523, 524, 525, 526
of male pelvis MRI, 553, 554, 555, 556, 557
coronal view
of abdomen CT, 492
of abdomen MRI, 514, 515, 516
of female pelvis CT, 546, 547, 548, 549, 550, 551
of female pelvis MRI, 581, 582, 583
of hip, 244, 245, 246, 247
of lumbar spine, 434, 435, 436
of male pelvis CT, 531, 532, 533, 534, 535
of male pelvis MRI, 566, 567, 568, 569
origin, insertion, and nerve supply of, 222–223t
sagittal view
of abdomen CT, 481
of abdomen MRI, 502, 503, 509
of female pelvis CT, 543
of hip, 233, 234, 235, 236, 237, 238, 239
of lumbar spine, 429
of male pelvis CT, 528
of male pelvis MRI, 559
- Gluteus medius t.
axial view
of female pelvis CT, 540
of hip, 226, 227
of hip arthrogram, 251, 252, 253
coronal view, of male pelvis MRI, 568
sagittal view, of hip, 236
- Gluteus minimus m.
axial view
of female pelvis CT, 538, 539, 540
of female pelvis MRI, 572, 573, 574
of hip, 224, 225, 226
- Gluteus minimus m. (*Continued*)
of male pelvis CT, 523, 524, 525, 526
of male pelvis MRI, 555, 556, 557
coronal view
of female pelvis CT, 548, 549, 550
of female pelvis MRI, 581, 582
of hip, 244, 245, 246, 247
of lumbar spine, 433
of male pelvis CT, 533, 534, 535
of male pelvis MRI, 566, 567, 568
origin, insertion, and nerve supply of, 222–223t
sagittal view, of hip, 233, 234, 235, 236, 237, 238, 239
- Gluteus minimus t.
axial view
of hip, 227, 228
of hip arthrogram, 253
sagittal view, of hip, 234, 235
- Gonadal v.
axial view, of abdomen CT, 479, 480
coronal view
of abdomen CT, 490
of female pelvis CT, 550
sagittal view
of abdomen CT, 482, 485
of female pelvis CT, 544
- Gracilis m.
axial view
of hip, 231, 232
of knee, 295
of male pelvis MRI, 558
of thigh, 269, 270, 271, 272, 273, 274, 275, 276
coronal view
of female pelvis MRI, 582
of hip, 244, 245, 246
of knee, 320
of male pelvis MRI, 566, 567
of thigh, 290, 291, 292, 293
origin, insertion, and nerve supply of, 268t
sagittal view
of male pelvis MRI, 561, 562
of thigh, 282, 283, 284, 285
- Gracilis t.
axial view, of knee, 295, 296, 297, 298, 299, 300
coronal view
of knee, 317, 318, 319, 320
of leg, 345
sagittal view, of knee, 309, 310
- Greater saphenous v.
axial view
of ankle, 349, 350, 351, 352, 353
of hip, 229, 230, 231, 232
of knee, 295, 296, 297, 298, 299, 300, 301
of leg, 324, 325, 326, 327, 328, 329, 330, 331, 332, 333
of male pelvis MRI, 557, 558
of thigh, 269, 272, 275, 276
coronal view
of ankle, 372, 373, 374
of female pelvis MRI, 581
of foot, 407
of hip, 243
of knee, 316, 317
of leg, 343, 344
of male pelvis MRI, 565
of thigh, 286, 287, 288, 289, 290, 291
oblique axial view, of ankle, 359, 360, 361, 362
sagittal view
of ankle, 370
of hip, 239, 240
of leg, 340, 341
of male pelvis MRI, 559
of thigh, 284, 285
- Greater sciatic foramen, coronal view, of hip, 247
- Greater sciatic notch, sagittal view, of hip, 241
- Greater trochanter
axial view
of female pelvis CT, 541
of female pelvis MRI, 574, 575
of hip, 227, 228
of hip arthrogram, 254, 255
of male pelvis CT, 525
of male pelvis MRI, 556
coronal view
of female pelvis CT, 548, 549, 550
of female pelvis MRI, 582, 583
- Greater trochanter (*Continued*)
of hip, 246, 247
of hip arthrogram, 265, 266
of male pelvis CT, 534, 535
of male pelvis MRI, 568
of thigh, 288, 289
sagittal view
of hip, 234, 235, 236, 237
of thigh, 277, 278
- Greater tuberosity of humerus
ABER view, of shoulder arthrogram, 85, 86, 87, 88
axial view
of pectoral girdle and chest wall, 6, 8
of shoulder, 39, 40, 41
of shoulder arthrogram, 68, 69, 70, 71
coronal view
of arm, 107, 108, 109
of pectoral girdle and chest wall, 26, 27, 28
- oblique coronal view
of shoulder, 60, 61, 62
of shoulder arthrogram, 79, 80, 81, 82
- oblique sagittal view
of shoulder, 46, 47
of shoulder arthrogram, 72
- sagittal view
of arm, 100
of pectoral girdle and chest wall, 14
- ## H
- Hamate
coronal view, of hand, 216, 217
sagittal view, of hand, 210, 211
- Hamate, hook
coronal view, of hand, 214, 215
sagittal view, of hand, 210
- Hamstring fascia, axial view, of thigh, 272, 273
- Hamstring t., common, axial view
of female pelvis CT, 542
of hip, 229
of male pelvis CT, 527
- Heart
axial view
of abdomen CT, 475
of abdomen MRI, 494, 495
coronal view, of abdomen MRI, 511, 512, 513, 514, 515
sagittal view, of abdomen MRI, 502, 503, 504, 505, 506, 507
- Hemiazzygos v.
axial view
of abdomen MRI, 496
of thoracic spine, 416
of thorax CT, 447, 448
coronal view, of thoracic spine, 420
sagittal view, of thoracic spine, 418
- Hemidiaphragm
coronal view, of thorax CT, 457, 458
sagittal view, of abdomen MRI, 505
- Hepatic a.
axial view
of abdomen CT, 476, 477
of abdomen MRI, 496, 497
coronal view, of abdomen CT, 488
sagittal view
of abdomen CT, 484, 485
of abdomen MRI, 508
- Hepatic a., common
axial view
of abdomen CT, 477
of abdomen MRI, 497
coronal view
of abdomen CT, 489, 490
of abdomen MRI, 513
sagittal view
of abdomen CT, 484
of abdomen MRI, 506
- Hepatic a., proper
coronal view, of abdomen CT, 489
sagittal view
of abdomen CT, 484, 485
of abdomen MRI, 507
- Hepatic cyst, axial view, of abdomen MRI, 496
- Hepatic duct, common, sagittal view, of abdomen CT, 485

- Hepatic v.
axial view
of abdomen CT, 475, 476, 477
of abdomen MRI, 494
coronal view
of abdomen CT, 488, 491
of abdomen MRI, 513, 515
- Hepatic v., middle
axial view
of abdomen CT, 475, 476, 477
of abdomen MRI, 494
coronal view
of abdomen CT, 488, 490
of abdomen MRI, 513
- Hepatoduodenal lig., coronal view, of abdomen CT, 488
- Hilum, posterior, coronal view, of heart MRI, 469
- Hip
coronal view, of male pelvis MRI, 566, 567
sagittal view
of female pelvis CT, 543
of male pelvis CT, 528
- Hip capsule
axial view, 226
coronal view, 582
- Humeral circumflex a., anterior
oblique coronal view, of shoulder, 59, 60
oblique sagittal view, of shoulder, 48, 49, 50, 52
sagittal view, of pectoral girdle and chest wall, 15
- Humeral circumflex a., posterior
axial view
of pectoral girdle and chest wall, 8, 9
of shoulder, 44, 45
coronal view
of arm, 110
of pectoral girdle and chest wall, 15
oblique coronal view, of shoulder, 59, 60, 61, 62, 63, 64
oblique sagittal view, of shoulder, 49, 50, 51, 52
sagittal view
of arm, 102, 103
of pectoral girdle and chest wall, 29
- Humeral circumflex vessels
oblique sagittal view, of shoulder arthrogram, 75, 76
posterior
oblique coronal view, of shoulder arthrogram, 83
oblique sagittal view, of shoulder arthrogram, 78
- Humeral diaphysis
ABER view, of shoulder arthrogram, 86, 87
axial view
of pectoral girdle and chest wall, 10, 12
of shoulder, 45
coronal view
of arm, 107, 108
of pectoral girdle and chest wall, 28, 29, 30, 31
oblique coronal view
of shoulder, 62
of shoulder arthrogram, 83
oblique sagittal view
of shoulder, 50
of shoulder arthrogram, 75
sagittal view, of pectoral girdle and chest wall, 15
- Humeral epiphysis, oblique sagittal view, of shoulder, 46, 47, 49, 50, 51
- Humeral head
ABER view, of shoulder arthrogram, 85, 86, 87, 88
articular cartilage, 40
axial view
of elbow, 123
of pectoral girdle and chest wall, 6, 7
of shoulder, 39, 40, 41
of shoulder arthrogram, 67, 68, 69
of thorax CT, 442
coronal view
of arm, 107, 108, 109, 110
of pectoral girdle and chest wall, 26, 27, 28
medial, sagittal view, of pectoral girdle and chest wall, 16
oblique coronal view
of shoulder, 59, 60, 61, 62, 63
of shoulder arthrogram, 79, 80, 81
oblique sagittal view
of elbow, 132, 133
of shoulder, 48, 49, 50
of shoulder arthrogram, 72, 73, 74, 75
- Humeral head (*Continued*)
posterior
ABER view, of shoulder arthrogram, 88, 89
oblique coronal view, of shoulder arthrogram, 83
sagittal view
of arm, 100, 101, 102, 103
of pectoral girdle and chest wall, 14, 15, 16
- Humeral lig., transverse, axial view, of shoulder, 40
- Humeral metaphysis, oblique sagittal view, of shoulder, 47
- Humeral physis, oblique sagittal view, of shoulder, 46, 47, 48
- Humeral surgical neck
ABER view, of shoulder arthrogram, 85, 86, 87
axial view
of pectoral girdle and chest wall, 8
of shoulder arthrogram, 71
oblique coronal view
of shoulder, 61, 62
of shoulder arthrogram, 81, 82
oblique sagittal view, of shoulder arthrogram, 73, 74
- Humerus
axial view
of arm, 92, 93, 94, 95, 96, 97
of pectoral girdle and chest wall, 9
of shoulder, 42, 43, 44
coronal view
of arm, 109
of elbow, 139, 140
of shoulder, 63
of shoulder arthrogram, 83
oblique coronal view
of elbow, 139, 140
of shoulder, 63
of shoulder arthrogram, 83
oblique sagittal view
of elbow, 127, 128, 130
of shoulder, 48, 49
sagittal view
of arm, 100, 101
of elbow, 127, 128, 130
of shoulder, 48, 49
spiral groove, coronal view, of arm, 109
- Humphrey's lig.
axial view, of knee, 298
coronal view, of knee, 317
sagittal view, of knee, 307
- I**
- Ileocecal valve
axial view, of male pelvis CT, 523
coronal view
of abdomen CT, 488
of female pelvis CT, 547
- Ileocolic a.
axial view, of male pelvis CT, 522
coronal view, of female pelvis CT, 548
- Ileocolic v., coronal view
of female pelvis CT, 548
of male pelvis CT, 532
- Ileum
axial view
of abdomen CT, 479, 480
of female pelvis CT, 538
of male pelvis CT, 523
coronal view
of abdomen CT, 487, 488
of female pelvis CT, 546
of male pelvis CT, 531, 532, 533
sagittal view, of female pelvis CT, 543, 544
- Iliac a., common (*Continued*)
sagittal view
of abdomen CT, 482, 483, 484
of abdomen MRI, 507
of female pelvis CT, 544
of lumbar spine, 431
of male pelvis CT, 529, 530
of male pelvis MRI, 562, 563, 564
- Iliac a., external
axial view
of female pelvis CT, 538, 539, 540
of hip, 225
of lumbar spine, 427, 428
of male pelvis CT, 523, 524, 525
of male pelvis MRI, 554, 555
coronal view
of female pelvis CT, 547, 548
of hip, 245
of lumbar spine, 432
of male pelvis CT, 532
of male pelvis MRI, 566
sagittal view
of abdomen CT, 484
of female pelvis CT, 543, 544
of male pelvis CT, 528
of male pelvis MRI, 560, 561
- Iliac a., internal
axial view
of female pelvis CT, 538, 539
of lumbar spine, 427, 428
of male pelvis CT, 523, 524
of male pelvis MRI, 553, 554
coronal view
of female pelvis CT, 550, 551
of male pelvis CT, 533, 534, 535
of male pelvis MRI, 567
sagittal view
of female pelvis CT, 543, 544
of lumbar spine, 430
of male pelvis CT, 529
of male pelvis MRI, 562
- Iliac bifurcation, sagittal view, of male pelvis CT, 529
- Iliac circumflex v., superficial, coronal view, of hip, 243
- Iliac circumflex vessels, superficial, coronal view, of male pelvis MRI, 565
- Iliac crest
axial view
of abdomen CT, 480
of lumbar spine, 426
of male pelvis CT, 522
of male pelvis MRI, 553
coronal view
of female pelvis CT, 546, 547, 548, 549, 550
of female pelvis MRI, 580, 581
of lumbar spine, 435, 436
of male pelvis CT, 534
of male pelvis MRI, 565
sagittal view
of abdomen CT, 486
of hip, 236
of male pelvis CT, 528
- Iliac spine, anterior inferior
axial view
of female pelvis CT, 539
of female pelvis MRI, 574
of hip, 225
of male pelvis CT, 523, 524
of male pelvis MRI, 555
coronal view, of hip, 244
sagittal view, of hip, 235, 236, 237
- Iliac spine, anterior superior
axial view
of female pelvis CT, 538
of female pelvis MRI, 572
of male pelvis CT, 523
of male pelvis MRI, 554
coronal view
of female pelvis CT, 546
of female pelvis MRI, 580
of hip, 244
of male pelvis CT, 531, 532
sagittal view, of hip, 235, 236
- Iliac v., common
axial view
of abdomen CT, 480

- Iliac v., common (*Continued*)
 of lumbar spine, 426, 427
 of male pelvis CT, 522, 523
 of male pelvis MRI, 553
 coronal view
 of abdomen CT, 488
 of female pelvis CT, 549, 550
 of lumbar spine, 432
 of male pelvis CT, 533
 sagittal view
 of abdomen CT, 483, 484
 of female pelvis CT, 544, 545
 of lumbar spine, 431
 of male pelvis CT, 529
 of male pelvis MRI, 563
- Iliac v., external
 axial view
 of female pelvis CT, 538, 539, 540
 of hip, 225
 of lumbar spine, 428
 of male pelvis CT, 524, 525
 of male pelvis MRI, 554, 555
 coronal view
 of female pelvis CT, 547, 548, 549
 of hip, 245
 of male pelvis CT, 532, 533
 of male pelvis MRI, 566
 sagittal view
 of female pelvis CT, 543
 of male pelvis MRI, 560, 561
- Iliac v., internal
 axial view
 of female pelvis CT, 538, 539
 of lumbar spine, 427, 428
 of male pelvis CT, 524
 of male pelvis MRI, 553, 554
 coronal view
 of female pelvis CT, 550, 551
 of male pelvis CT, 533, 534, 535
 sagittal view
 of female pelvis CT, 544
 of male pelvis CT, 529
 of male pelvis MRI, 562, 563
- Iliac vessels, common, sagittal view
 of abdomen MRI, 504, 507
 of female pelvis MRI, 577, 578
- Iliac vessels, coronal view, of lumbar spine, 433
- Iliac vessels, external
 axial view
 of female pelvis MRI, 572, 573
 of hip, 224
 coronal view, of hip, 245, 246
 sagittal view
 of hip, 241
 of male pelvis MRI, 560
- Iliac vessels, internal
 axial view
 of female pelvis MRI, 572
 of hip, 224
 coronal view
 of female pelvis MRI, 582
 of male pelvis MRI, 568, 569
 sagittal view
 of female pelvis MRI, 576
 of male pelvis MRI, 560, 561
- Iliac wing, coronal view, of hip, 244
- Iliacus, axial view, of male pelvis CT, 523
- Iliacus m.
 axial view
 of female pelvis CT, 538
 of female pelvis MRI, 572
 of lumbar spine, 426, 428, 429
 of male pelvis MRI, 553, 554
 coronal view
 of abdomen CT, 490
 of abdomen MRI, 513
 of female pelvis CT, 546, 547, 548, 549, 550
 of female pelvis MRI, 580, 581, 582
 of hip, 245
 of lumbar spine, 432, 433, 434
 of male pelvis CT, 532, 533, 534
 of male pelvis MRI, 566, 567, 568
 origin, insertion, and nerve supply of, 222–223t
 sagittal view
 of abdomen CT, 481
- Iliacus m. (*Continued*)
 of abdomen MRI, 502, 503, 509
 of female pelvis CT, 543
 of lumbar spine, 429
 of male pelvis CT, 528
 of male pelvis MRI, 559, 560
- Iliocostalis cervicis m., origin, insertion, and nerve supply of, 412–414t
- Iliocostalis lumborum m.
 axial view
 of abdomen MRI, 495, 496, 498, 499, 500, 501
 of lumbar spine, 425, 426, 427, 428
 coronal view
 of abdomen MRI, 516, 517
 of lumbar spine, 429, 436, 437
 origin, insertion, and nerve supply of, 412–414t
 sagittal view
 of abdomen MRI, 503, 509
 of female pelvis CT, 544
 of lumbar spine, 429
- Iliocostalis m.
 axial view
 of abdomen CT, 475, 477, 479, 480
 of male pelvis CT, 522
 of male pelvis MRI, 553
 coronal view
 of abdomen CT, 492
 of male pelvis CT, 535, 536
 sagittal view
 of abdomen CT, 481, 482, 483, 486
 of female pelvis CT, 543
 of male pelvis CT, 529
- Iliocostalis thoracis m.
 axial view, of thoracic spine, 415, 416
 origin, insertion, and nerve supply of, 412–414t
 sagittal view, of thoracic spine, 417
- Iliofemoral lig.
 axial view, of hip arthrogram, 251, 252, 253, 254, 255, 256
 coronal view, of hip arthrogram, 262, 263, 264, 265, 266
 sagittal view, of hip arthrogram, 257, 258, 259
- Iliohypogastric n., coronal view, of female pelvis MRI, 580
- Iliolumbar a.
 axial view, of lumbar spine, 428
 coronal view, of lumbar spine, 433
 sagittal view, of lumbar spine, 430
- Iliolumbar lig.
 axial view, of lumbar spine, 426
 coronal view, of lumbar spine, 435
 transverse part, sagittal view, of lumbar spine, 429
- Iliolumbar v., axial view, of lumbar spine, 428
- Iliolumbar vessels
 axial view, of lumbar spine, 427
 iliac branches, coronal view, of lumbar spine, 434
- Iliopsoas m.
 axial view
 of female pelvis CT, 538, 539, 540, 541, 542
 of female pelvis MRI, 573, 574, 575
 of hip, 224, 225, 226, 227, 228, 229, 230
 of male pelvis CT, 523, 524, 525, 526, 527
 of male pelvis MRI, 554, 555, 556, 557, 558
 coronal view
 of female pelvis CT, 546, 547, 548, 549
 of female pelvis MRI, 581
 of hip, 244, 245, 246
 of lumbar spine, 432
 of male pelvis CT, 531, 532, 533
 of male pelvis MRI, 565, 566
 of thigh, 287, 288
 sagittal view
 of female pelvis CT, 543
 of hip, 236, 237, 240, 241
 of lumbar spine, 429
 of male pelvis CT, 528
 of male pelvis MRI, 559
 of thigh, 281, 282, 283
- Iliopsoas t.
 axial view
 of hip, 224, 225, 226, 227, 228, 229, 230
 of hip arthrogram, 251, 252, 253, 254, 255, 256
 coronal view, of hip, 245, 246
 sagittal view
 of hip, 238, 239, 240
 of hip arthrogram, 258, 259, 260
- Iliotibial band
 axial view
 of female pelvis MRI, 575
 of hip, 224, 225, 226, 227, 228, 229, 230, 231, 232
 of knee, 295, 296, 297, 298, 299, 300
 of male pelvis MRI, 557
 of thigh, 269, 270, 271, 272, 273, 274, 275, 276
 coronal view
 of hip, 245, 246, 247
 of knee, 312, 313, 314, 315, 316, 317
 of leg, 342, 343
 of male pelvis MRI, 568, 569
 of thigh, 290
 sagittal view
 of hip, 233, 234
 of thigh, 277
- Iliotibial tract
 axial view
 of female pelvis CT, 541, 542
 of hip, 229
 of male pelvis CT, 527
 coronal view
 of female pelvis CT, 548, 549
 of thigh, 289
- Ilium
 axial view
 of female pelvis CT, 538, 539
 of female pelvis MRI, 572, 573, 574
 of hip, 224, 225, 226
 of lumbar spine, 426, 427, 428, 429
 of male pelvis MRI, 553
 coronal view
 of abdomen CT, 492
 of abdomen MRI, 515, 516
 of female pelvis CT, 547, 548, 549, 551
 of female pelvis MRI, 582, 583
 of hip, 245, 247, 248
 of hip arthrogram, 262, 263, 264, 265, 266
 of lumbar spine, 432, 433, 434, 435, 437
 of male pelvis CT, 532, 533
 of male pelvis MRI, 566, 568, 570
 sagittal view
 of abdomen CT, 481
 of abdomen MRI, 502, 503, 509
 of female pelvis CT, 543
 of female pelvis MRI, 576
 of hip, 235, 236, 237, 240, 241, 242
 of hip arthrogram, 257, 258, 259, 260, 261
 of lumbar spine, 430
 of male pelvis MRI, 559, 560, 561
- Inferior articular recess, 256
- Inferior vena cava
 axial view
 of abdomen CT, 475, 476, 477, 478, 479, 480
 of abdomen MRI, 494, 495, 496, 497, 498, 499, 500, 501
 of heart MRI, 463
 of lumbar spine, 425
 of male pelvis CT, 522
 of thorax CT, 447
 coronal view
 of abdomen CT, 488, 489, 490, 491
 of abdomen MRI, 513, 514, 515
 of female pelvis CT, 548, 549
 of lumbar spine, 432, 433
 of male pelvis CT, 533
 of thorax CT, 455, 456
 sagittal view
 of abdomen CT, 484
 of abdomen MRI, 507, 508
 of heart MRI, 466
 of lumbar spine, 430, 431
 of male pelvis CT, 530
 of male pelvis MRI, 563
 of thorax CT, 451, 452
- Infraglenoid tubercle
 ABER view, of shoulder arthrogram, 89
 axial view, of shoulder arthrogram, 71
 oblique sagittal view
 of shoulder, 52
 of shoulder arthrogram, 77
- Infrahyoid m.
 axial view, of pectoral girdle and chest wall, 4
 coronal view, of pectoral girdle and chest wall, 25

- Infrapatellar fat pad
axial view, of knee, 298, 299, 300
coronal view
of knee, 311, 312
of leg, 342
sagittal view
of knee, 304, 305, 306, 307
of leg, 336, 337, 338
- Infraspinatus m.
ABER view, of shoulder arthrogram, 87, 88
axial view
of pectoral girdle and chest wall, 6, 7, 8, 9, 10
of shoulder, 38, 39, 40, 41, 42, 43
of shoulder arthrogram, 67, 68, 69
coronal view
of arm, 110, 111, 112, 113
of pectoral girdle and chest wall, 29, 30, 31, 32, 33
of thoracic spine, 420, 421, 422, 423
oblique coronal view
of shoulder, 61, 62, 63, 64
of shoulder arthrogram, 81, 82, 83
oblique sagittal view
of shoulder, 50, 51, 52, 53, 54, 55
of shoulder arthrogram, 75, 76, 77
origin, insertion, and nerve supply of, 35t, 412–414t
sagittal view
of arm, 100, 101, 102, 103, 104
of pectoral girdle and chest wall, 14, 15, 16, 17, 18, 19, 20
- Infraspinatus t.
ABER view, of shoulder arthrogram, 86, 87
axial view
of shoulder, 39, 40, 41
of shoulder arthrogram, 67, 68
oblique coronal view
of shoulder, 61, 62, 63, 64
of shoulder arthrogram, 81, 82, 83
oblique sagittal view
of shoulder, 47, 48, 49, 50
of shoulder arthrogram, 72, 73, 74, 75, 76, 77
sagittal view
of arm, 102
of pectoral girdle and chest wall, 16
- Inguinal lig., coronal view
of female pelvis CT, 546
of hip, 243
- Inguinal lymph nodes
coronal view
of female pelvis CT, 546
of female pelvis MRI, 580
of male pelvis CT, 531
of male pelvis MRI, 565
sagittal view, of male pelvis CT, 528
- Innominate bone, axial view, of male pelvis MRI, 555, 556
- Intercarpal lig., coronal view, of hand, 216
- Interclavicular lig., coronal view, of pectoral girdle and chest wall, 25
- Intercondylar eminence, coronal view, of knee, 315, 316
- Intercondylar fossa, axial view, of knee, 297, 298
- Intercondylar notch
coronal view
of knee, 315, 316
of leg, 343
- Intercostal a.
coronal view
of pectoral girdle and chest wall, 30, 31
of thoracic spine, 420, 421
sagittal view
of abdomen CT, 482
of thoracic spine, 417
- Intercostal m.
axial view
of abdomen CT, 477
of pectoral girdle and chest wall, 12
coronal view
of pectoral girdle and chest wall, 24, 31, 33
of thoracic spine, 420, 421
sagittal view
of abdomen CT, 481
of pectoral girdle and chest wall, 20, 21, 22
- Intercostal n.
coronal view, of thoracic spine, 420, 421
sagittal view, of thoracic spine, 417
- Intercostal neurovascular bundle, sagittal view
of pectoral girdle and chest wall, 21, 23
of thoracic spine, 418
- Intercostal v.
axial view, of thorax CT, 447
coronal view
of pectoral girdle and chest wall, 30, 31
of thoracic spine, 420
sagittal view
of abdomen CT, 482
of thoracic spine, 417
- Intercostal vessels
axial view
of abdomen CT, 475
of thoracic spine, 415
coronal view, of pectoral girdle and chest wall, 31, 32
sagittal view, of abdomen CT, 481
- Intercuneiform lig.
axial view, of foot, 386
coronal view, of foot, 405
- Interlobar a.
axial view, of thorax CT, 445
coronal view, of thorax CT, 454, 456, 457
- Interalleolar lig., posterior, coronal view, of ankle, 377
- Intermetatarsal lig.
axial view, of foot, 387
coronal view, of foot, 404
- Intermuscular septum, lateral
axial view
of elbow, 118, 119
of thigh, 270
oblique coronal, of elbow, 139
sagittal view, of thigh, 277, 278
- Interosseous a., anterior
axial view
of elbow, 118, 119, 122, 123, 124
of forearm, 146, 148, 149, 150, 151, 152, 153, 154
coronal view
of elbow, 138, 139
of forearm, 165, 166, 168
oblique coronal, of elbow, 138, 139
oblique sagittal view, of elbow, 129
sagittal view
of elbow, 129
of forearm, 158, 159
- Interosseous a., common
axial view
of elbow, 123, 124
of forearm, 146
oblique coronal, of elbow, 137, 138
sagittal view, of forearm, 159
- Interosseous a., oblique coronal, of elbow, 138
- Interosseous a., posterior
axial view
of elbow, 124
of forearm, 147, 148, 149, 150, 155
coronal view, of forearm, 168, 169
oblique sagittal view, of elbow, 127
sagittal view
of elbow, 127
of forearm, 158, 159, 160
- Interosseous m.
axial view, of hand, 204
origin, insertion, and nerve supply of, 197t
- Interosseous m. dorsal
1st
axial view, of hand, 199, 200, 202, 203
coronal view, of hand, 216, 217
sagittal view, of hand, 205, 206, 207
2nd
axial view, of hand, 199, 200, 201, 202, 203
coronal view, of hand, 216, 217, 218
sagittal view, of hand, 208, 209
3rd
axial view, of hand, 200, 201, 202, 203
coronal view, of hand, 216, 217
sagittal view, of hand, 210
4th
axial view, of hand, 199, 200, 201, 202, 203
coronal view, of hand, 216, 217
sagittal view, of hand, 211, 212
axial view, of foot, 385, 386, 387, 388
coronal view, of foot, 401, 402, 403, 404
origin, insertion, and nerve supply of, 382–384t
sagittal view, of foot, 391, 392, 393, 394, 395
- Interosseous m., palmar
1st
axial view, of hand, 200, 202, 203
coronal view, of hand, 216
2nd
axial view, of hand, 201, 202
coronal view, of hand, 216
sagittal view
of hand, 210
of wrist, 185
3rd
axial view, of hand, 199, 200, 201, 202
coronal view, of hand, 216
sagittal view
of hand, 211, 212
of wrist, 185
axial view, of hand, 200, 201
- Interosseous m., plantar
axial view, of foot, 388, 389
coronal view, of foot, 401, 402, 403, 404
origin, insertion, and nerve supply of, 382–384t
sagittal view, of foot, 392, 393, 395, 396
- Interosseous membrane
axial view
of ankle, 349
of forearm, 149, 150, 151, 152
of leg, 325, 326, 327, 330, 331, 332, 333
oblique sagittal view, of elbow, 128
- Interosseous n., anterior
axial view
of elbow, 119, 120, 121
of forearm, 147, 148, 149, 150, 151, 152, 153, 154
coronal view
of elbow, 138, 139
of forearm, 165, 166
oblique coronal, of elbow, 138, 139
oblique sagittal view, of elbow, 129
sagittal view
of elbow, 129
of forearm, 158
- Interosseous n., posterior
axial view, of forearm, 147, 148, 149, 150, 151, 152, 153, 154
coronal view
of elbow, 139
of forearm, 168, 169
oblique coronal, of elbow, 139
oblique sagittal view, of elbow, 127
sagittal view
of elbow, 127
of forearm, 159, 160
- Interosseous sacroiliac lig.
coronal view, of lumbar spine, 436, 437
sagittal view, of lumbar spine, 430
- Interosseous t., coronal view
of foot, 399
of hand, 216
- Interosseous v., posterior, sagittal view, of forearm, 159
- Interosseous vessels, posterior, oblique coronal, of elbow, 139
- Interphalangeal joint
distal, sagittal view, of hand, 207, 208, 209, 211
proximal, sagittal view, of hand, 207, 208, 209, 210, 211, 212, 213
sagittal view, of hand, 205
- Interspinales cervicis m., origin, insertion, and nerve supply of, 412–414t
- Interspinales lumborum m., origin, insertion, and nerve supply of, 412–414t
- Interspinales thoracis m.
axial view, of thoracic spine, 416
origin, insertion, and nerve supply of, 412–414t
sagittal view, of thoracic spine, 419
- Interspinous lig.
coronal view, of thoracic spine, 422
sagittal view
of lumbar spine, 431
of thoracic spine, 419
- Intertransversarii anteriores cervicis m., origin, insertion, and nerve supply of, 412–414t
- Intertransversarii laterales lumborum m., origin, insertion, and nerve supply of, 412–414t
- Intertransversarii thoracis m., origin, insertion, and nerve supply of, 412–414t

- Intertransversarius m.
coronal view, of lumbar spine, 435
sagittal view, of thoracic spine, 418
- Intertrochanteric crest, coronal view
of female pelvis MRI, 583
of male pelvis MRI, 568
- Interventricular septum
axial view, of thorax CT, 446, 447
sagittal view, of thorax CT, 449, 450
- Intervertebral disc
coronal view, of pectoral girdle and chest wall, 30
sagittal view
of abdomen MRI, 506, 507
of heart MRI, 465
of male pelvis MRI, 564
of thoracic spine, 419
- Intraventricular septum, axial view, of heart MRI, 462
- Ischial ramus
axial view
of female pelvis CT, 542
of male pelvis CT, 527
coronal view
of male pelvis CT, 534
of male pelvis MRI, 568
sagittal view
of female pelvis CT, 543, 544
of male pelvis MRI, 560, 561, 562
- Ischial spine, axial view
of female pelvis MRI, 574
of hip, 227
of hip arthrogram, 253
of male pelvis CT, 525
of male pelvis MRI, 556
- Ischial tuberosity
axial view
of female pelvis CT, 541
of hip, 228, 229, 230
of male pelvis CT, 526, 527
of male pelvis MRI, 557
coronal view
of male pelvis CT, 536
of male pelvis MRI, 569
sagittal view
of male pelvis CT, 528, 529
of male pelvis MRI, 559
- Ischioanal fossa, coronal view, of female pelvis MRI, 583
- Ischiocavernosus m.
axial view
of male pelvis CT, 527
of male pelvis MRI, 557, 558
coronal view
of female pelvis CT, 548, 549
of male pelvis CT, 534, 535
of male pelvis MRI, 568
sagittal view
of female pelvis CT, 544
of male pelvis CT, 529
of male pelvis MRI, 561, 562
- Ischiofemoral lig.
axial view, of hip arthrogram, 252, 253, 254, 255
coronal view, of hip arthrogram, 266
sagittal view, of hip arthrogram, 257, 258, 259
- Ischiorectal fossa
axial view
of female pelvis CT, 540, 541, 542
of female pelvis MRI, 574
of male pelvis CT, 526
coronal view
of female pelvis CT, 551
of male pelvis CT, 535, 536
of male pelvis MRI, 568
sagittal view
of female pelvis CT, 543, 544
of male pelvis CT, 529
- Ischium
axial view
of female pelvis CT, 541
of female pelvis MRI, 575
of hip, 228
of hip arthrogram, 255, 256
of male pelvis MRI, 557, 558
of thigh, 269
coronal view
of female pelvis CT, 550, 551
of female pelvis MRI, 583
- Ischium (*Continued*)
of hip, 246, 247
of hip arthrogram, 263, 264, 265
of male pelvis CT, 535
of male pelvis MRI, 569
of thigh, 291, 292
sagittal view
of female pelvis CT, 543
of female pelvis MRI, 576
of hip, 240, 241, 242
of hip arthrogram, 260, 261
of male pelvis MRI, 560
of thigh, 283, 284
- J**
- Jejunum
axial view
of abdomen CT, 478, 479, 480
of abdomen MRI, 497, 498, 499, 500, 501
coronal view
of abdomen CT, 487, 489, 490, 491
of abdomen MRI, 511, 512, 513, 514, 515
of female pelvis CT, 546, 547, 548
of male pelvis CT, 532
sagittal view, of abdomen CT, 481
- Joint capsule
axial view, of lumbar spine, 425
coronal view
of hand, 216
of hip, 582
oblique sagittal view, of shoulder arthrogram, 75
- Jugular v.
axial view, of thorax CT, 442
coronal view, of thorax CT, 453, 454
- Jugular v., anterior
axial view, of pectoral girdle and chest wall, 6, 7
coronal view, of pectoral girdle and chest wall, 25
sagittal view, of pectoral girdle and chest wall, 22, 23
- Jugular v., external
axial view, of pectoral girdle and chest wall, 6
coronal view, of pectoral girdle and chest wall, 26, 27
sagittal view, of pectoral girdle and chest wall, 20, 21
- Jugular v., internal
axial view, of pectoral girdle and chest wall, 6
coronal view, of pectoral girdle and chest wall, 26
sagittal view, of pectoral girdle and chest wall, 23
- K**
- Kager's triangle
axial view, of ankle, 352, 353, 354, 355
coronal view, of ankle, 379, 380
sagittal view, of ankle, 367, 368
- Kidney
left
axial view
of abdomen CT, 477, 478, 479
of abdomen MRI, 496, 497, 498, 499, 500, 501
of lumbar spine, 429
coronal view
of abdomen CT, 491, 492
of abdomen MRI, 515, 516, 517
of lumbar spine, 435
of thoracic spine, 420
of thorax CT, 457
sagittal view
of abdomen MRI, 502, 503, 504
of heart MRI, 464
of thoracic spine, 417
of thorax CT, 449
sagittal view, of abdomen CT, 481
left inferior pole
axial view, of abdomen CT, 479
coronal view, of abdomen CT, 491
left superior pole
axial view, of abdomen CT, 476, 477
sagittal view, of abdomen CT, 482
left upper pole, axial view, of abdomen MRI, 496
right
axial view
of abdomen CT, 477, 478, 479
of abdomen MRI, 497, 498, 499, 500, 501
of lumbar spine, 429
- Kidney (*Continued*)
coronal view
of abdomen CT, 491, 492
of abdomen MRI, 515, 516, 517
of lumbar spine, 436
of thoracic spine, 420
of thorax CT, 457
sagittal view
of abdomen CT, 485, 486
of abdomen MRI, 508, 509
right inferior pole
axial view, of abdomen CT, 479
coronal view
of abdomen CT, 490
of lumbar spine, 434
right superior pole
axial view, of abdomen CT, 476, 477
sagittal view, of abdomen CT, 485
right upper pole, axial view, of abdomen MRI, 496
sagittal view, of lumbar spine, 430
- L**
- L1
transverse process, 436
vertebra, 434
- L2
nerve, 435
pedicle, 435
spinal ganglion, 435
spinous process, 437
vertebra, 425
vertebral body, 490
- L3
nerve, 434
nerve root, 425
pedicle, 434
spinous process, 431
transverse process, 430
vertebral body, 491
- L3-4 disc, 425
- L4
dorsal ramus of spinal n., 434
inferior facet, 426, 427
nerve, 434
nerve root, sagittal view, 563
spinous process, 426, 427, 564
vertebral body
coronal view, 533, 534, 549, 550
sagittal view, 530, 545, 564
- L4-5
annulus fibrosus, 431
facet joint, 427
intervertebral disc, 579
nucleus pulposus, 431, 433
- L4-5 disc, 426
- L5
inferior facet, 431
lamina, 427
laminar arch, 435
lateral recess, 426, 427
nerve, 427, 434, 435
nerve root, 431
pars interarticularis, 431
pedicle, 426, 427, 431
spinal ganglion, 427
spinous process, 427, 428, 436, 437
superior facet, 426, 427, 431
transverse process, 435
vertebra, 426, 427, 433
vertebral body
axial view, 553
coronal view, 533, 534, 550, 567, 582
sagittal view, 544, 563, 578, 579
- L5-S1
articular facet, 427
facet joint, 428
intervertebral disc
axial view, 427
coronal view, 433, 550, 582
sagittal view, 431, 530, 578, 579
- Labium majus pudendi, coronal view, of female pelvis MRI, 581
- Labium minus pudendi, coronal view, of female pelvis CT, 549

- Labrum, anterior
 ABER view, of shoulder arthrogram, 85, 86, 87, 88
 axial view
 of hip arthrogram, 251, 252, 253, 254
 of shoulder, 41
 of shoulder arthrogram, 67, 68, 69, 70
 oblique sagittal view, of shoulder arthrogram, 75, 76
 sagittal view, of hip arthrogram, 257, 258, 260
- Labrum, anterior superior, coronal view, of hip arthrogram, 262, 263
- Labrum, inferior
 ABER view, of shoulder arthrogram, 87, 88
 axial view, of shoulder, 43
 coronal view, of hip arthrogram, 266
 oblique coronal view, of shoulder, 60
 sagittal view, of hip arthrogram, 260
- Labrum, oblique coronal view, of shoulder arthrogram, 79, 80, 81
- Labrum, posterior
 ABER view, of shoulder arthrogram, 86, 87, 88
 axial view
 of hip arthrogram, 251, 252, 253, 254
 of shoulder, 41, 42
 of shoulder arthrogram, 67, 68, 69, 70, 71
 coronal view, of hip arthrogram, 265, 266
 oblique coronal view, of shoulder arthrogram, 82
 oblique sagittal view
 of shoulder, 52
 of shoulder arthrogram, 76
 sagittal view, of hip arthrogram, 257, 258, 259, 260
- Labrum, superior
 ABER view, of shoulder arthrogram, 85
 axial view, of shoulder arthrogram, 67
 coronal view, of hip arthrogram, 263, 264, 265
 oblique coronal view, of shoulder, 59, 60, 61
 oblique sagittal view
 of shoulder, 52
 of shoulder arthrogram, 75
 sagittal view, of hip arthrogram, 257
- Lamina, axial view, of lumbar spine, 425
- Laryngeal n., recurrent, axial view, of thorax CT, 442
- Lateral meniscus
 anterior horn, sagittal view, of knee, 303, 304, 305
 body
 coronal view, of knee, 315, 317
 sagittal view, of knee, 302
 coronal view, of knee, 315
 posterior horn
 coronal view, of knee, 317
 sagittal view, of knee, 303, 304, 305
 sagittal view, of knee, 303
- Lateral recess, sagittal view, of thoracic spine, 419
- Latissimus dorsi m.
 axial view
 of abdomen CT, 475, 479, 480
 of abdomen MRI, 494, 495, 496, 497, 498, 501
 of pectoral girdle and chest wall, 9, 10, 11, 12, 13
 of shoulder, 45
 coronal view
 of abdomen MRI, 516, 517
 of arm, 108, 109, 110, 111, 112, 113
 of pectoral girdle and chest wall, 27, 28, 29, 30, 31, 32, 33
 of thoracic spine, 420, 421, 422
 oblique coronal view, of shoulder, 60, 61, 62, 63, 64, 65
 oblique sagittal view, of shoulder, 51, 52, 53, 54, 55
 origin, insertion, and nerve supply of, 35t, 412–414t
 sagittal view
 of abdomen CT, 481, 482, 486
 of arm, 102, 103, 104
 of pectoral girdle and chest wall, 16, 17, 18, 19, 20, 21, 22
- Latissimus dorsi t.
 axial view
 of pectoral girdle and chest wall, 10
 of shoulder, 44, 45
 coronal view, of arm, 108
 oblique sagittal view, of shoulder, 49, 50, 51
 sagittal view, of arm, 102, 103
- Lesser saphenous v.
 axial view
 of ankle, 349, 350, 351, 352, 353, 354
 of knee, 295, 296, 297, 298, 300, 301
 of leg, 324, 325, 326, 327, 328, 329
- Lesser saphenous v. (*Continued*)
 coronal view
 of ankle, 374, 375, 378, 379
 of leg, 345
 oblique axial view, of ankle, 359, 360, 362
 sagittal view
 of ankle, 365, 366
 of knee, 306
- Lesser trochanter
 axial view
 of hip, 231
 of male pelvis CT, 527
 of male pelvis MRI, 558
 of thigh, 269
 coronal view
 of female pelvis MRI, 583
 of hip, 246
 of hip arthrogram, 266
 of male pelvis CT, 534
 of male pelvis MRI, 568
 of thigh, 290
 sagittal view
 of hip, 237, 238
 of thigh, 280, 281
- Lesser tuberosity of humerus
 ABER view, of shoulder arthrogram, 84
 axial view
 of pectoral girdle and chest wall, 8
 of shoulder, 41, 42
 of shoulder arthrogram, 69, 70
 coronal view
 of arm, 106, 107
 of pectoral girdle and chest wall, 25, 26
 oblique coronal view
 of shoulder, 59
 of shoulder arthrogram, 78, 79
 oblique sagittal view
 of shoulder, 48
 of shoulder arthrogram, 73, 74
 sagittal view
 of arm, 101, 102
 of pectoral girdle and chest wall, 15
- Levator ani m.
 axial view
 of female pelvis CT, 540, 541
 of female pelvis MRI, 575
 of male pelvis CT, 526
 of male pelvis MRI, 557
 coronal view
 of female pelvis CT, 551
 of female pelvis MRI, 583, 584
 of hip, 248
 of male pelvis CT, 535, 536
 of male pelvis MRI, 568, 569, 570
 sagittal view
 of female pelvis CT, 544
 of female pelvis MRI, 577
 of male pelvis CT, 529
 of male pelvis MRI, 561, 562, 563
- Levator costae m., coronal view, of pectoral girdle and chest wall, 32
- Levator scapulae m.
 axial view, of pectoral girdle and chest wall, 6
 coronal view
 of pectoral girdle and chest wall, 28, 29, 30, 31
 of thoracic spine, 421
 origin, insertion, and nerve supply of, 412–414t
 sagittal view, of pectoral girdle and chest wall, 21, 22
- Ligamentum flavum
 axial view, of lumbar spine, 425, 428
 sagittal view
 of lumbar spine, 431
 of thoracic spine, 419
- Ligamentum teres
 coronal view, of abdomen CT, 487
 fissure
 axial view
 of abdomen CT, 476, 477
 of abdomen MRI, 497, 498
 coronal view, of abdomen MRI, 510, 511
 sagittal view, of abdomen MRI, 508
 sagittal view, of abdomen CT, 485
- Ligamentum teres femoris
 axial view, of hip arthrogram, 252, 253, 254
 coronal view, of hip arthrogram, 263, 264, 265
 sagittal view, of hip arthrogram, 260, 261
- Ligamentum venosum
 axial view, of abdomen MRI, 495
 coronal view, of abdomen CT, 490
 fissure
 axial view, of abdomen CT, 476
 sagittal view, of abdomen MRI, 507
 sagittal view, of abdomen CT, 483
- Linea alba
 axial view
 of abdomen CT, 477
 of abdomen MRI, 500, 501
 of female pelvis CT, 538, 539, 540
 of male pelvis CT, 522, 523, 524
 of male pelvis MRI, 553, 554, 555
 sagittal view, of abdomen MRI, 505, 506
- Linea aspera, axial view, of thigh, 272
- Linea semilunaris, axial view
 of female pelvis CT, 538, 539
 of male pelvis CT, 523, 524
 of male pelvis MRI, 554
- Lisfranc lig.
 axial view, of foot, 386
 coronal view, of foot, 405
- Liver
 axial view
 of abdomen CT, 476, 477, 478, 479
 of abdomen MRI, 494, 495, 496, 497, 498, 499, 500, 501
 of heart MRI, 463
 of thorax CT, 447, 448
 coronal view
 of abdomen CT, 487, 488, 489, 490, 491, 492
 of abdomen MRI, 510, 511, 512, 513, 514, 516, 517
 of heart MRI, 467, 468, 469
 of thoracic spine, 420
 of thorax CT, 453, 455, 457
 sagittal view
 of abdomen CT, 481, 482, 483, 484, 485, 486
 of abdomen MRI, 503, 504, 505, 506, 507, 508, 509
 of heart MRI, 464, 465, 466
 of thorax CT, 450, 451, 452
- Longissimus capitis m., origin, insertion, and nerve supply of, 412–414t
- Longissimus cervicis m., origin, insertion, and nerve supply of, 412–414t
- Longissimus dorsi m.
 axial view
 of abdomen CT, 475, 477, 479, 480
 of male pelvis CT, 522
 coronal view
 of abdomen CT, 492
 of female pelvis CT, 551
 of male pelvis CT, 535, 536
 sagittal view
 of abdomen CT, 481, 482, 483, 484, 485, 486
 of male pelvis CT, 529
- Longissimus lumborum m.
 axial view
 of lumbar spine, 425, 426, 427
 of male pelvis MRI, 553
 coronal view, of lumbar spine, 435, 436, 437
- Longissimus thoracis m.
 axial view
 of abdomen MRI, 494, 495, 496, 497, 498, 499, 500, 501
 of thoracic spine, 415, 416
 coronal view
 of abdomen MRI, 517
 of thoracic spine, 422
 origin, insertion, and nerve supply of, 412–414t
 sagittal view
 of abdomen MRI, 504
 of lumbar spine, 429, 430
- Longitudinal lig., anterior, sagittal view
 of lumbar spine, 431
 of thoracic spine, 419
- Longitudinal lig., posterior, sagittal view
 of lumbar spine, 431
 of thoracic spine, 419
- Longus colli m., axial view, of pectoral girdle and chest wall, 6
- Lumbar a.
 axial view, of lumbar spine, 425
 coronal view, of lumbar spine, 432
- Lumbar plexus, coronal view, of female pelvis CT, 550

- Lumbar spine, coronal view, of abdomen MRI, 513, 514, 515
- Lumbar triangle
 inferior, axial view, of abdomen CT, 480
 superior, axial view, of abdomen CT, 479
- Lumbar v.
 axial view
 of abdomen CT, 477, 478
 of lumbar spine, 425
 coronal view, of lumbar spine, 432
 sagittal view, of abdomen CT, 482
- Lumbar vertebral a., coronal view, of lumbar spine, 433
- Lumbar vertebral v., coronal view, of lumbar spine, 433
- Lumbar vertebral vessels, coronal view, of lumbar spine, 434
- Lumbar vessels, sagittal view, of abdomen CT, 484
- Lumbosacral fascia, dorsal, axial view, of lumbar spine, 428
- Lumbosacral trunk
 axial view, of lumbar spine, 426, 428
 coronal view, of lumbar spine, 434, 435
 sagittal view, of lumbar spine, 430
- Lumbrical m.
 1st
 axial view, of hand, 202, 203
 sagittal view, of hand, 207, 208
- 2nd
 axial view, of hand, 202, 203
 sagittal view, of hand, 209
- 3rd
 axial view, of hand, 202
 sagittal view, of hand, 209, 210
- 4th, sagittal view, of hand, 212
 axial view, of hand, 202, 204
 coronal view, of hand, 214, 215
 origin, insertion, and nerve supply of, 197t, 382–384t
 sagittal view, of foot, 392, 393
- Lumbrical t., axial view, of hand, 204
- Lunate, coronal view, of hand, 215, 216, 217
- Lung
 left
 axial view
 of abdomen CT, 475, 476
 of abdomen MRI, 494
 of heart MRI, 460, 462, 463
 coronal view
 of abdomen CT, 492
 of abdomen MRI, 512, 513, 514, 515, 516, 517
 of heart MRI, 467, 468, 469
 sagittal view
 of abdomen CT, 481, 482
 of abdomen MRI, 502, 503, 504
 of heart MRI, 464
 of thoracic spine, 417, 418
- right
 axial view
 of abdomen CT, 475, 476
 of abdomen MRI, 494
 of heart MRI, 460, 462, 463
 of pectoral girdle and chest wall, 7, 8, 9, 10
 coronal view
 of abdomen CT, 492
 of abdomen MRI, 512, 513, 514, 515, 516, 517
 of heart MRI, 467, 468, 469
 of pectoral girdle and chest wall, 25, 26, 27, 28, 29, 30
 sagittal view
 of abdomen CT, 484, 486
 of abdomen MRI, 508, 509
 of heart MRI, 466
 of pectoral girdle and chest wall, 19, 20, 21
- Lymph node (*Continued*)
 sagittal view
 of hip, 239, 240
 of knee, 306
 of male pelvis MRI, 559, 560
 of thigh, 282
- M**
- Malleolus, lateral
 axial view, of ankle, 352, 353, 354
 coronal view
 of ankle, 375, 376, 377, 378
 of leg, 342, 343
 oblique axial view, of ankle, 360, 361
 sagittal view
 of ankle, 365, 366
 of leg, 335, 336
- Malleolus, medial
 axial view, of ankle, 352
 coronal view
 of ankle, 374, 375
 of leg, 342
 oblique axial view, of ankle, 360, 361
 sagittal view
 of ankle, 370, 371
 of leg, 339
- Malleolus, posterior, axial view, of ankle, 352
- Mammary a., internal
 axial view, of heart MRI, 460, 461, 462
 sagittal view, of abdomen CT, 485
- Mammary v., internal, axial view, of heart MRI, 460, 461, 462
- Mammary vessels, internal, coronal view
 of heart MRI, 467
 of pectoral girdle and chest wall, 24
- Manubrium
 axial view
 of heart MRI, 465
 of thorax CT, 443
 coronal view
 of heart MRI, 467
 of pectoral girdle and chest wall, 24, 25
 sagittal view
 of pectoral girdle and chest wall, 23
 of thorax CT, 451, 452
- Medial cutaneous n., of forearm, axial view, of arm, 93, 94, 96
- Medial meniscus
 anterior horn
 coronal view, of knee, 314
 sagittal view, of knee, 308, 309
 body, coronal view, of knee, 315, 316, 317
 coronal view, of knee, 314
 posterior horn
 coronal view, of knee, 317
 sagittal view, of knee, 307, 308, 309
 sagittal view, of knee, 310
- Median basilic v.
 axial view
 of elbow, 118, 119, 120, 121, 122, 123, 124
 of forearm, 146, 147, 148, 149, 150, 151, 152, 153
 coronal view, of forearm, 162
 oblique coronal, of elbow, 134, 135
 oblique sagittal view, of elbow, 131
- Median cubital v.
 axial view, of elbow, 115, 116, 117, 118
 oblique coronal, of elbow, 134, 135, 136, 137
 oblique sagittal view, of elbow, 129, 130
 sagittal view, of forearm, 156
- Median n.
 axial view
 of arm, 92, 93, 94, 95, 96, 97
 of elbow, 117, 118, 119, 120, 121, 122, 123, 124
 of forearm, 146, 147, 148, 149, 150, 151, 152, 153, 154, 155
 of hand, 198, 199, 200, 201, 202
 coronal view
 of forearm, 164
 of hand, 214
 oblique coronal, of elbow, 136, 137
 oblique sagittal view, of elbow, 130, 131
 sagittal view
 of arm, 102
 of forearm, 157, 158
- Median raphe, coronal view, of leg, 346, 347
- Median v.
 axial view, of elbow, 115, 116, 117
 sagittal view, of forearm, 156
- Meniscal lig., transverse
 axial view, of knee, 299
 coronal view, of knee, 313
 sagittal view, of knee, 306
- Meniscofemoral (Humphrey's) lig.
 axial view, of knee, 298
 coronal view, of knee, 317
 sagittal view, of knee, 307
- Meniscus homologue, coronal view, of hand, 216
- Mesenteric a., inferior
 axial view
 of abdomen CT, 480
 of male pelvis CT, 522
 coronal view
 of abdomen CT, 488
 of female pelvis CT, 548
 of male pelvis CT, 532, 533
 sagittal view, of abdomen CT, 483
- Mesenteric a., superior
 axial view
 of abdomen CT, 477, 478, 479
 of abdomen MRI, 498, 499, 500, 501
 coronal view
 of abdomen CT, 488, 489, 490
 of abdomen MRI, 512, 513, 514
 of female pelvis CT, 547
 of male pelvis CT, 532
 of thorax CT, 453, 454, 455
 sagittal view
 of abdomen CT, 483
 of abdomen MRI, 505, 506
 of female pelvis CT, 544
 of heart MRI, 465
 of thorax CT, 450
- Mesenteric v., inferior
 coronal view
 of abdomen CT, 488, 489, 490
 of male pelvis CT, 532
 sagittal view, of abdomen CT, 482
- Mesenteric v., superior
 axial view
 of abdomen CT, 478, 479
 of abdomen MRI, 499, 500, 501
 coronal view
 of abdomen CT, 488
 of abdomen MRI, 512
 of female pelvis CT, 547
 sagittal view
 of abdomen CT, 483
 of female pelvis CT, 544
- Mesenteric vessels
 axial view
 of abdomen CT, 479, 480
 of male pelvis CT, 522
 sagittal view
 of abdomen CT, 481, 483
 of abdomen MRI, 503, 504, 505
- Mesentery
 axial view
 of abdomen CT, 479, 480
 of male pelvis CT, 522
 coronal view
 of abdomen CT, 487
 of female pelvis CT, 547
 sagittal view, of abdomen CT, 481, 483
- Mesocolon, sigmoid
 axial view, of male pelvis CT, 524
 sagittal view, of abdomen CT, 483
- Metacarpal
 1st
 axial view, of hand, 198, 199, 200, 201
 coronal view, of hand, 215
 sagittal view, of hand, 205, 205, 206
- 2nd
 axial view, of hand, 198, 199, 200, 201
 sagittal view, of hand, 207, 208, 209
- 3rd
 axial view, of hand, 198, 199
 sagittal view, of hand, 209, 210
- 4th
 axial view, of hand, 198, 199
 sagittal view, of hand, 210

- Metacarpal (*Continued*)
 5th
 axial view, of hand, 198, 199
 sagittal view, of hand, 211, 212
- Metacarpal a., palmar, axial view, of hand, 199, 200, 201
- Metacarpal base
 1st, coronal view, of hand, 214
 2nd, coronal view, of hand, 216, 217
 3rd, coronal view, of hand, 216, 217
 4th, coronal view, of hand, 216, 217
 5th, coronal view, of hand, 216
- Metacarpal head
 2nd, axial view, of hand, 204
 3rd
 axial view, of hand, 204
 sagittal view, of hand, 210
 4th, sagittal view, of hand, 211, 212
 5th
 coronal view, of hand, 216
 sagittal view, of hand, 212, 213
- Metacarpophalangeal joint
 axial view, of hand, 201
 sagittal view, of hand, 205, 206, 207, 208, 209, 210, 211, 212
- Metatarsal
 1st
 axial view, of foot, 386, 387
 coronal view, of foot, 401, 402, 403, 404
 sagittal view, of foot, 397
 2nd
 axial view, of foot, 386, 387
 coronal view, of foot, 401, 402, 403, 404, 405
 sagittal view, of foot, 394, 395
 3rd
 axial view, of foot, 387, 388
 coronal view, of foot, 401, 402, 403, 404, 405
 sagittal view, of foot, 393
 4th
 axial view, of foot, 388
 coronal view, of foot, 401, 402, 403, 404, 405
 sagittal view, of foot, 392
 5th
 axial view
 of ankle, 356, 357
 of foot, 389
 coronal view, of foot, 401, 402, 403, 404, 405
 sagittal view, of foot, 391
- Metatarsal base
 1st
 axial view, of foot, 385, 387
 sagittal view, of foot, 395, 396
 2nd
 axial view, of foot, 385
 sagittal view, of foot, 394
 3rd
 axial view, of foot, 386
 sagittal view
 of ankle, 369
 of foot, 392, 393, 394
 4th
 axial view, of foot, 387, 388
 sagittal view
 of ankle, 367, 368, 369
 of foot, 391, 392, 393
 5th
 axial view
 of ankle, 357, 358
 of foot, 388, 390
 coronal view, of foot, 406
 sagittal view
 of ankle, 367, 368
 of foot, 391
- Metatarsal head
 1st
 axial view, of foot, 388, 389
 coronal view, of foot, 400
 sagittal view, of foot, 397, 398
 2nd
 axial view, of foot, 388, 389
 coronal view, of foot, 400
 sagittal view, of foot, 395, 396
 3rd
 axial view, of foot, 388, 389
 coronal view, of foot, 400
 sagittal view, of foot, 394
- Metatarsal head (*Continued*)
 4th
 axial view, of foot, 388, 389
 coronal view, of foot, 400
 sagittal view, of foot, 393
 5th
 axial view, of foot, 390
 coronal view, of foot, 400, 401
 sagittal view, of foot, 391
- Metatarsophalangeal joint
 1st, coronal view, of foot, 399, 400
 2nd, coronal view, of foot, 399
 3rd, coronal view, of foot, 399
 4th, coronal view, of foot, 400
- Middle phalanx
 index finger, sagittal view, 207
 long finger
 coronal view, 215
 sagittal view, 209, 210
 ring finger
 coronal view, 215
 sagittal view, 211, 212
 small finger
 coronal view, 215, 216
 sagittal view, 213
- Mitral valve, axial view, of heart MRI, 462
- Mitral valve plane
 axial view, of thorax CT, 446
 coronal view, of thorax CT, 455
- Moderator band, axial view, of thorax CT, 446
- Mons pubis
 axial view, of female pelvis CT, 542
 coronal view
 of female pelvis CT, 546
 of female pelvis MRI, 580
- Multifidus m.
 axial view
 of abdomen CT, 475, 477, 480
 of abdomen MRI, 494, 495, 496, 497, 498, 499, 500, 501
 of lumbar spine, 425, 426, 427, 428
 of pectoral girdle and chest wall, 4, 5
 of thoracic spine, 415
 coronal view
 of abdomen CT, 492
 of abdomen MRI, 517
 of female pelvis CT, 551
 of lumbar spine, 436, 437
 of male pelvis CT, 535, 536
 of male pelvis MRI, 569
 of pectoral girdle and chest wall, 28, 30
 origin, insertion, and nerve supply of, 412–414t
 sagittal view
 of abdomen CT, 484
 of abdomen MRI, 505, 506
 of female pelvis CT, 544, 545
 of lumbar spine, 429, 430, 431
- Musculocutaneous n., axial view
 of arm, 93
 of elbow, 115, 116
- Myometrium
 junctional zone
 axial view, of female pelvis MRI, 573
 coronal view, of female pelvis MRI, 581, 582
 sagittal view, of female pelvis MRI, 579
 peripheral zone
 axial view, of female pelvis MRI, 573
 coronal view, of female pelvis MRI, 581, 582
 sagittal view, of female pelvis MRI, 579
- N**
- Nail, sagittal view, of hand, 211
- Navicular
 axial view
 of ankle, 353, 354
 of foot, 385, 386
 coronal view
 of ankle, 372
 of foot, 407
 oblique axial view, of ankle, 363
 sagittal view
 of ankle, 368, 369, 370, 371
 of foot, 394, 395, 396, 397
- Navicular tuberosity, sagittal view, of foot, 397
- Nerve root, coronal view, of thorax CT, 458
- Neural foramina
 coronal view, of thorax CT, 458
 sagittal view
 of abdomen MRI, 505
 of heart MRI, 465
- Neuroforamen, lateral, sagittal view, of thoracic spine, 418, 419
- Neurovascular bundle
 axial view, of pectoral girdle and chest wall, 12
 sagittal view, of pectoral girdle and chest wall, 17
- Nutrient a., axial view, of thigh, 272
- O**
- Oblique m., external
 axial view
 of abdomen CT, 477, 478, 480
 of abdomen MRI, 498, 499
 of male pelvis CT, 522, 523
 of male pelvis MRI, 553
 coronal view
 of abdomen CT, 487, 489, 490, 492
 of abdomen MRI, 511, 512, 513, 514
 of female pelvis CT, 547, 548
 of male pelvis CT, 531, 532, 533, 534
 origin, insertion, and nerve supply of, 474t
- Oblique m., internal
 axial view
 of abdomen CT, 478, 480
 of hip, 224
 of male pelvis CT, 522, 523
 of male pelvis MRI, 553
 coronal view
 of abdomen CT, 487, 489, 490
 of abdomen MRI, 511, 512, 513, 514, 515
 of female pelvis CT, 547, 548
 of female pelvis MRI, 580
 of hip, 243
 of male pelvis CT, 531, 532, 533, 534
 origin, insertion, and nerve supply of, 474t
 sagittal view, of abdomen CT, 481
- Obturator a.
 axial view, of male pelvis CT, 525
 coronal view, of male pelvis CT, 534
 sagittal view, of hip, 242
- Obturator externus m.
 axial view
 of female pelvis CT, 541, 542
 of female pelvis MRI, 575
 of hip, 228, 229
 of male pelvis CT, 526, 527
 of male pelvis MRI, 557
 coronal view
 of female pelvis CT, 548, 549, 550
 of female pelvis MRI, 581, 582
 of hip, 244, 245, 246, 247
 of male pelvis CT, 533, 534, 535
 of male pelvis MRI, 566, 567, 568
 origin, insertion, and nerve supply of, 222–223t
 sagittal view
 of female pelvis CT, 543, 544
 of female pelvis MRI, 576, 577
 of hip, 239, 240, 241, 242
 of male pelvis CT, 528, 529
 of male pelvis MRI, 559, 560, 561, 562
 of thigh, 282, 283, 284, 285
- Obturator externus t.
 axial view
 of hip, 228
 of hip arthrogram, 253
 coronal view
 of hip, 246, 247
 of hip arthrogram, 266
 sagittal view, of hip, 236, 237
- Obturator foramen, sagittal view
 of hip, 242
 of male pelvis MRI, 560
- Obturator internus m.
 axial view
 of female pelvis CT, 540, 541
 of female pelvis MRI, 573, 574, 575
 of hip, 225, 226, 227, 228, 229
 of male pelvis CT, 524, 525, 526
 of male pelvis MRI, 555, 556, 557
 coronal view
 of female pelvis CT, 548, 549, 550, 551

- Obturator internus m. (*Continued*)
 of female pelvis MRI, 581, 582, 583
 of hip, 245, 246, 247
 of male pelvis CT, 533, 534, 535
 of male pelvis MRI, 567, 568, 569
 origin, insertion, and nerve supply of, 222–223t
 sagittal view
 of female pelvis CT, 543, 544
 of female pelvis MRI, 576, 577
 of hip, 236, 237, 238, 239, 240, 241, 242
 of male pelvis CT, 528, 529
 of male pelvis MRI, 560, 561, 562
 of thigh, 285
- Obturator internus t.
 axial view
 of female pelvis CT, 540
 of hip, 227, 228
 of hip arthrogram, 254
 of male pelvis CT, 526
 of male pelvis MRI, 556
- coronal view
 of female pelvis CT, 550
 of female pelvis MRI, 583
 of hip arthrogram, 266
 of male pelvis CT, 535
 of male pelvis MRI, 569
- sagittal view
 of hip, 237
 of hip arthrogram, 257, 258, 259, 260, 261
- Obturator n.
 axial view
 of female pelvis CT, 541
 of female pelvis MRI, 574
 of hip, 227
 of lumbar spine, 428
 of male pelvis CT, 526
- coronal view
 of hip, 245
 of lumbar spine, 433
 of male pelvis CT, 533
- sagittal view
 of female pelvis MRI, 576
 of hip, 242
 of male pelvis CT, 528
- Obturator v.
 axial view, of male pelvis CT, 525
 coronal view, of male pelvis CT, 534
 sagittal view, of hip, 242
- Obturator vessels
 axial view
 of female pelvis CT, 541
 of female pelvis MRI, 574
 of hip, 227
 of male pelvis CT, 526
 sagittal view, of female pelvis MRI, 576
- Olecranon
 axial view, of elbow, 116, 117, 118, 119
 coronal view, of arm, 108, 109
 oblique coronal view, of elbow, 140, 141, 142
 oblique sagittal view, of elbow, 129, 131
 sagittal view, of arm, 101, 102
- Olecranon fossa
 axial view, of elbow, 115, 116, 118
 coronal view, of arm, 108
 oblique coronal, of elbow, 140
 oblique sagittal view, of elbow, 129, 130
 sagittal view, of arm, 101, 102
- Omental vessels
 coronal view, of abdomen CT, 487
 sagittal view, of abdomen CT, 483, 484
- Omentum
 coronal view, of abdomen CT, 487
 sagittal view, of abdomen CT, 483, 484
- Omohyoid m., inferior
 axial view, of shoulder, 38
 coronal view, of pectoral girdle and chest wall, 26, 27, 28
 oblique coronal view, of shoulder, 56, 57
 sagittal view, of pectoral girdle and chest wall, 19, 20
- Omohyoid t., inferior
 axial view, of shoulder, 38, 39
 coronal view, of pectoral girdle and chest wall, 27
 oblique coronal view, of shoulder, 57
 sagittal view, of pectoral girdle and chest wall, 19, 20
- Opponens digiti minimi m.
 axial view, of hand, 198, 199, 200, 201
 coronal view
 of foot, 402, 405
 of hand, 214, 215, 216
 origin, insertion, and nerve supply of, 197t, 382–384t
 sagittal view, of hand, 209, 210, 211, 212
- Opponens pollicis brevis m., axial view, of hand, 198, 199, 200
- Opponens pollicis m.
 coronal view, of hand, 214
 origin, insertion, and nerve supply of, 197t
 sagittal view, of hand, 206, 207, 208
- Os, internal, axial view, of female pelvis MRI, 573
- Ovary
 axial view
 of female pelvis CT, 538, 539
 of female pelvis MRI, 573
- coronal view
 of female pelvis CT, 549, 550
 of female pelvis MRI, 582
- sagittal view
 of female pelvis CT, 543, 544
 of female pelvis MRI, 576
- ## P
- Palmar aponeurosis
 axial view
 of hand, 198, 199, 200, 201
 of wrist, 179
 coronal view, of hand, 214
 sagittal view
 of hand, 209
 of wrist, 183, 184
- Palmar arch, deep
 axial view
 of hand, 198, 199
 of wrist, 179
 coronal view, of hand, 215, 216
 sagittal view, of wrist, 180, 181, 182, 183, 184, 185
- Palmar arch, sagittal view, of wrist, 181, 184, 185
- Palmar arch, superficial
 axial view, of hand, 198, 200
 coronal view, of hand, 214
 sagittal view, of wrist, 181, 184, 185
- Palmar digital a., common, sagittal view of, 181, 182
- Palmar v., sagittal view, of wrist, 183
- Palmaris brevis m.
 axial view, of hand, 198, 199
 coronal view
 of hand, 214
 of wrist, 189
 origin, insertion, and nerve supply of, 197t
 sagittal view, of wrist, 185, 186, 187
- Palmaris longus m.
 axial view
 of elbow, 118, 119, 120, 122, 123, 124
 of forearm, 146, 147, 148, 149, 150
 coronal view, of forearm, 162
 oblique coronal, of elbow, 135, 136, 137
 oblique sagittal view, of elbow, 132, 133
 origin, insertion, and nerve supply of, 144–145t
 sagittal view, of forearm, 159, 160
- Palmaris longus t.
 axial view
 of forearm, 151, 152, 153, 154, 155
 of wrist, 171, 172, 173, 174, 175, 176, 177, 178
- coronal view
 of forearm, 162, 163, 164
 of hand, 214
 of wrist, 189
- sagittal view, of wrist, 183, 184
- Pancreas
 axial view
 of abdomen CT, 477, 478
 of abdomen MRI, 496
- body
 axial view
 of abdomen CT, 478
 of abdomen MRI, 496, 497, 498
- coronal view
 of abdomen CT, 488, 489, 490
 of abdomen MRI, 512, 513, 514
- Pancreas (*Continued*)
 sagittal view
 of abdomen CT, 482, 483
 of abdomen MRI, 504, 505, 506
- head
 axial view
 of abdomen CT, 478
 of abdomen MRI, 498, 499, 500, 501
- coronal view
 of abdomen CT, 488, 489
 of abdomen MRI, 512, 513, 514
 of thorax CT, 453
- sagittal view
 of abdomen CT, 484, 485
 of abdomen MRI, 507, 508, 509
- neck
 axial view, of abdomen CT, 477
 coronal view, of abdomen CT, 488
 sagittal view, of abdomen CT, 483
- tail
 axial view
 of abdomen CT, 478
 of abdomen MRI, 497, 498
- coronal view
 of abdomen CT, 490, 491, 492
 of abdomen MRI, 514, 515, 516
- sagittal view
 of abdomen CT, 481
 of abdomen MRI, 502, 503
- Pancreatic duct
 axial view, of abdomen CT, 478
 coronal view
 of abdomen CT, 489
 of abdomen MRI, 512
- Pancreaticoduodenal v., superior, sagittal view, of abdomen CT, 484
- Papillary m., anterior
 axial view, of thorax CT, 446
 coronal view, of thorax CT, 453
- Papillary m., left ventricular, coronal view, of thorax CT, 454
- Papillary m., posterior
 axial view, of thorax CT, 447
 sagittal view, of thorax CT, 449
- Parametrium, sagittal view
 of female pelvis CT, 544
 of female pelvis MRI, 577, 578
- Patella
 axial view, of knee, 297, 298
 coronal view, of knee, 311
 sagittal view, of knee, 303, 304, 305, 306, 307
 upper pole, axial view, of knee, 296
- Patellar facet
 lateral, axial view, of knee, 297
 medial, axial view, of knee, 297
- Patellar lig.
 coronal view, of knee, 311, 312, 313
 sagittal view
 of knee, 304, 305, 306
 of leg, 336, 337, 338
- Patellar retinaculum
 coronal view, of knee, 311
 lateral
 axial view, of knee, 296, 297, 299
 coronal view, of knee, 311, 312, 313
- medial
 axial view, of knee, 296, 297, 298
 coronal view, of knee, 311, 312, 313, 314
 sagittal view, of knee, 308
- Patellar t., axial view, of knee, 298, 299, 300, 301
- Pectineus m.
 axial view
 of female pelvis CT, 541, 542
 of female pelvis MRI, 575
 of hip, 227, 228, 229, 230
 of male pelvis CT, 526, 527
 of male pelvis MRI, 556, 557, 558
 of thigh, 269
- coronal view
 of female pelvis CT, 547, 548, 549
 of female pelvis MRI, 580, 581
 of hip, 244, 245
 of male pelvis CT, 532, 533, 534
 of male pelvis MRI, 566, 567
- origin, insertion, and nerve supply of, 268t

- Pectineus m. (*Continued*)
 sagittal view
 of female pelvis CT, 543, 544
 of female pelvis MRI, 576
 of hip, 238, 239, 240, 241, 242
 of male pelvis CT, 528
 of male pelvis MRI, 559, 560, 561
 of thigh, 281, 282, 283, 284, 285
- Pectoralis major m.
 ABER view, of shoulder arthrogram, 84, 85, 86
 axial view
 of heart MRI, 460
 of shoulder, 40, 41, 42, 43, 44, 45
 coronal view
 of arm, 105
 of pectoral girdle and chest wall, 26
 oblique coronal view, of shoulder, 56, 57
 oblique sagittal view, of shoulder, 49, 50, 51, 52, 53, 54, 55
 origin, insertion, and nerve supply of, 35t
 sagittal view
 of arm, 104
 of pectoral girdle and chest wall, 15, 16, 18, 19, 20
- Pectoralis major m., clavicular head
 axial view, of pectoral girdle and chest wall, 7, 8, 9
 coronal view, of pectoral girdle and chest wall, 24, 25
 sagittal view, of pectoral girdle and chest wall, 17, 18, 20, 21, 22
- Pectoralis major m. costosternal head
 axial view, of pectoral girdle and chest wall, 10, 11, 12
 sagittal view, of pectoral girdle and chest wall, 23
- Pectoralis major m., sternoclavicular head, axial view, of pectoral girdle and chest wall, 9
- Pectoralis major m., sternocostal head
 axial view, of pectoral girdle and chest wall, 10, 13
 coronal view, of pectoral girdle and chest wall, 24, 25
 sagittal view, of pectoral girdle and chest wall, 17, 18, 20, 21, 22
- Pectoralis major t.
 axial view, of pectoral girdle and chest wall, 10, 11
 oblique coronal view, of shoulder, 57
 sagittal view
 of arm, 101, 103
 of pectoral girdle and chest wall, 15
- Pectoralis minor m.
 axial view
 of heart MRI, 460
 of pectoral girdle and chest wall, 7, 8, 9, 10, 11, 12, 13
 of shoulder, 41, 42, 43, 44, 45
 coronal view, of pectoral girdle and chest wall, 26
 oblique sagittal view, of shoulder, 53, 54, 55
 origin, insertion, and nerve supply of, 35t
 sagittal view, of pectoral girdle and chest wall, 18, 19, 20
- Pectoralis minor t.
 axial view
 of pectoral girdle and chest wall, 7
 of shoulder arthrogram, 69, 70
 long head, axial view, of shoulder, 41
 oblique coronal view, of shoulder, 56
 oblique sagittal view, of shoulder, 52, 53, 55
- Pedicle
 axial view, of lumbar spine, 425
 coronal view, of thorax CT, 458
 sagittal view, of abdomen MRI, 505, 507
- Penis
 axial view
 of male pelvis CT, 526, 527
 of male pelvis MRI, 558
 bulb
 axial view, of male pelvis CT, 527
 coronal view, of male pelvis CT, 534, 535
 sagittal view
 of male pelvis CT, 530
 of male pelvis MRI, 564
 coronal view
 of male pelvis CT, 531, 532, 533, 534
 of male pelvis MRI, 565, 566, 567
 sagittal view
 of male pelvis CT, 529, 530
 of male pelvis MRI, 562, 563, 564
- Pericardial fat, sagittal view, of abdomen CT, 481
- Pericardium
 axial view, of thorax CT, 445, 446, 447, 448
 sagittal view, of abdomen CT, 481
- Periprostatic venous plexus, sagittal view, of male pelvis CT, 529
- Perirenal fascia, coronal view, of abdomen CT, 491
- Perivesical venous plexus, sagittal view, of male pelvis CT, 529
- Peroneal a.
 axial view, of ankle, 349
 oblique axial view, of ankle, 360
- Peroneal n., common
 axial view
 of knee, 295, 296, 297, 298, 299, 300, 301
 of leg, 324
 of thigh, 275, 276
 coronal view, of knee, 318, 319, 320
 sagittal view
 of knee, 302, 303, 304
 of leg, 334
- Peroneal n., communicating, axial view, of knee, 296, 297, 298
- Peroneal n., deep
 axial view
 of ankle, 349, 350
 of leg, 325
 coronal view, of leg, 343
 oblique axial view, of ankle, 360, 361, 362
- Peroneal n., superficial
 axial view, of leg, 325, 326
 oblique axial view, of ankle, 360
- Peroneal retinaculum
 inferior
 axial view, of ankle, 354
 coronal view, of ankle, 376
 oblique axial view, of ankle, 361
 superior, axial view, of ankle, 351, 352, 353
- Peroneal sulcus, sagittal view, of foot, 391, 392
- Peroneal tubercle
 axial view, of ankle, 356
 coronal view, of ankle, 376
- Peroneal v.
 axial view, of ankle, 349
 oblique axial view, of ankle, 360
- Peroneal vessels, axial view, of leg, 325, 326, 327, 328, 329, 330, 331, 333
- Peroneus brevis m.
 axial view
 of ankle, 349, 350, 351, 352, 353
 of leg, 326, 327, 328, 329, 330, 331, 332, 333
 coronal view
 of ankle, 378, 379
 of leg, 344
 oblique axial view, of ankle, 359, 360
 origin, insertion, and nerve supply of, 322–323t
 sagittal view
 of ankle, 365, 366
 of leg, 334, 335
- Peroneus brevis t.
 axial view
 of ankle, 349, 350, 351, 352, 353, 354, 355, 356, 357
 of foot, 388, 389
 of leg, 327, 328, 329, 330, 331, 332, 333
 coronal view
 of ankle, 372, 373, 374, 375, 376, 377, 378
 of foot, 407
 oblique axial view, of ankle, 359, 360, 361, 362, 363, 364
 sagittal view
 of ankle, 365, 366
 of foot, 391
 of leg, 334, 335
- Peroneus longus m.
 axial view
 of knee, 301
 of leg, 324, 325, 326, 327, 328, 329, 330, 331, 332, 333
 coronal view
 of knee, 317, 319, 320
 of leg, 344, 345
 origin, insertion, and nerve supply of, 322–323t
 sagittal view
 of knee, 302, 303
 of leg, 334, 335, 336
- Peroneus longus t.
 axial view
 of ankle, 349, 350, 351, 352, 353, 354, 355, 356, 357
 of foot, 387, 388, 389
 of leg, 327, 328, 329, 330, 331, 332, 333
 coronal view
 of ankle, 372, 373, 374, 375, 376, 377, 378
 of foot, 405, 406, 407
 of leg, 344, 345
 oblique axial view, of ankle, 359, 360, 361, 362, 363, 364
 sagittal view
 of ankle, 365, 366, 367, 368
 of foot, 391, 392, 393
 of leg, 334, 336
- Peroneus quartus m.
 axial view, of ankle, 352, 353, 354
 coronal view, of ankle, 378
 sagittal view, of ankle, 366
- Peroneus quartus t.
 axial view, of ankle, 355
 coronal view, of ankle, 378
- Peroneus tertius m.
 oblique axial view, of ankle, 360, 361, 362
 origin, insertion, and nerve supply of, 322–323t
- Peroneus tertius t., oblique axial view, of ankle, 363, 364
- Pes anserinus
 axial view, of knee, 301
 coronal view
 of knee, 315
 of leg, 344
 sagittal view, of knee, 310
- Piriformis m.
 axial view
 of female pelvis CT, 538, 539
 of female pelvis MRI, 572, 573
 of hip, 224, 225, 226
 of male pelvis CT, 523, 524
 of male pelvis MRI, 554, 555
 coronal view
 of female pelvis CT, 550, 551
 of female pelvis MRI, 583, 584
 of hip, 248, 249
 of lumbar spine, 436
 of male pelvis CT, 535, 536
 of male pelvis MRI, 569, 570
 origin, insertion, and nerve supply of, 222–223t
 sagittal view
 of female pelvis CT, 543, 544
 of female pelvis MRI, 576, 577
 of hip, 237, 238, 239, 240, 241, 242
 of lumbar spine, 430
 of male pelvis CT, 528, 529
 of male pelvis MRI, 559, 560, 561, 562
- Piriformis t.
 axial view, of hip, 226, 227
 coronal view, of male pelvis MRI, 568
 sagittal view, of hip, 237
- Pisiform
 coronal view, of hand, 214, 215
 sagittal view, of hand, 211
- Pisohamate lig., coronal view, of hand, 215
- Plantar a., lateral, coronal view
 of ankle, 372, 375
 of foot, 404, 405
- Plantar a., medial
 coronal view
 of ankle, 372, 373
 of foot, 404, 406, 407
 sagittal view, of ankle, 369, 371
- Plantar aponeurosis
 coronal view, of ankle, 372, 377, 378
 oblique axial view, of ankle, 362
- Plantar aponeurosis, lateral
 axial view, of ankle, 358
 coronal view
 of ankle, 374, 375, 376
 of foot, 407
 oblique axial view, of ankle, 364
- Plantar aponeurosis, medial
 coronal view
 of ankle, 374, 375, 376
 of foot, 403, 404, 405, 407
 oblique axial view, of ankle, 364

- Plantar fascia, lateral, sagittal view, of ankle, 367, 368
- Plantar fascia, medial, sagittal view
of ankle, 368, 369, 370, 371
of foot, 394
- Plantar fascia, sagittal view, of foot, 394
- Plantar lig., long
coronal view, of ankle, 374, 375
sagittal view, of ankle, 368
- Plantar n., lateral
axial view, of ankle, 356, 357
coronal view
of ankle, 372, 375
of foot, 404, 405
- Plantar n., medial
axial view
of ankle, 356, 357
of foot, 388, 389
coronal view
of ankle, 372, 373
of foot, 404, 406, 407
sagittal view
of ankle, 370, 371
of foot, 396
- Plantar vessels, lateral
axial view, of ankle, 356, 357
oblique axial view, of ankle, 361, 362, 363, 364
sagittal view, of ankle, 370
- Plantar vessels, medial
axial view
of ankle, 356, 357
of foot, 388, 389
oblique axial view, of ankle, 361, 362, 363, 364
sagittal view
of ankle, 370, 371
of foot, 396
- Plantaris m.
axial view, of knee, 297, 298, 299, 300
coronal view, of knee, 317, 318
origin, insertion, and nerve supply of, 322–323t
sagittal view, of knee, 303, 304, 305, 306
- Plantaris t.
axial view
of ankle, 352, 353, 354, 355
of knee, 301
of leg, 324, 325, 331, 333
sagittal view, of knee, 307, 308
- Platysma m., axial view, of pectoral girdle and chest wall, 4
- Popliteal a.
axial view
of knee, 295, 296
of leg, 324
of thigh, 275, 276
coronal view
of leg, 344
of thigh, 290
sagittal view, of leg, 337
- Popliteal v.
axial view
of knee, 295, 296
of leg, 324
of thigh, 275, 276
coronal view, of thigh, 290
- Popliteal vessels
axial view, of knee, 296, 297, 298, 299, 300
coronal view
of knee, 317, 318, 319, 320
of leg, 345
of thigh, 289, 290
sagittal view
of knee, 305, 306
of leg, 338
of thigh, 278, 280
- Popliteus m.
axial view
of knee, 299, 300, 301
of leg, 324, 325, 326
coronal view
of knee, 318, 319
of leg, 344
origin, insertion, and nerve supply of, 322–323t
sagittal view
of knee, 304, 305, 306, 307, 308
of leg, 336, 337, 338
- Popliteus t.
axial view, of knee, 299
coronal view, of knee, 316, 317
sagittal view, of knee, 303, 304
- Portacaval space, axial view, of abdomen CT, 477
- Portal v.
axial view, of abdomen CT, 476, 477
coronal view, of thorax CT, 454
- left
axial view
of abdomen CT, 475
of abdomen MRI, 496
coronal view
of abdomen CT, 488, 489
of abdomen MRI, 511, 512
sagittal view
of abdomen CT, 484, 485
of abdomen MRI, 508
umbilical portion
axial view, of abdomen CT, 476
axial view, of abdomen MRI, 495
sagittal view, of abdomen CT, 484
- main
axial view
of abdomen CT, 476, 477
of abdomen MRI, 496, 497, 498
coronal view
of abdomen CT, 489
of abdomen MRI, 513
sagittal view
of abdomen CT, 484
of abdomen MRI, 507, 508
- right
anterior branch
axial view, of abdomen CT, 476, 477
coronal view, of abdomen CT, 489
sagittal view, of abdomen CT, 486
axial view
of abdomen CT, 476
of abdomen MRI, 495, 496
coronal view, of abdomen CT, 490, 491
posterior branch
axial view, of abdomen CT, 476, 477
coronal view, of abdomen CT, 491
sagittal view, of abdomen CT, 486
sagittal view
of abdomen CT, 485
of abdomen MRI, 508, 509
sagittal view, of thorax CT, 452
- Posterior bands
axial view, of elbow, 117
oblique sagittal view
of elbow, 132
of shoulder arthrogram, 75
- Profunda brachii a.
axial view, of arm, 92, 93, 94, 95
sagittal view, of arm, 101, 102
- Profunda femoris a., axial view, of male pelvis MRI, 557, 558
- Pronator quadratus m.
axial view, of forearm, 153, 154, 155
coronal view, of forearm, 163, 164, 165
origin, insertion, and nerve supply of, 144–145t
sagittal view, of forearm, 158, 159, 160
- Pronator teres m.
axial view
of elbow, 115, 116, 117, 118, 119, 120, 121, 122, 123, 124
of forearm, 146, 147, 148, 149
coronal view, of forearm, 163, 164, 165, 166, 167
oblique coronal, of elbow, 134, 135, 136, 137, 138, 139
oblique sagittal view, of elbow, 129, 130, 131, 132, 133
origin, insertion, and nerve supply of, 144–145t
sagittal view
of arm, 103, 104
of forearm, 158
- Pronator teres m., deep head
axial view
of elbow, 121, 122, 123
of forearm, 146
oblique coronal, of elbow, 138, 139
oblique sagittal view, of elbow, 130, 131
- Pronator teres t.
axial view
of elbow, 124
of forearm, 148, 149, 150
coronal view, of forearm, 166, 167
oblique sagittal view, of elbow, 132, 133
- Prostate gland
axial view
of male pelvis CT, 525, 526
of male pelvis MRI, 557
coronal view
of male pelvis CT, 534
of male pelvis MRI, 567, 568
sagittal view
of male pelvis CT, 530
of male pelvis MRI, 563, 564
- Proximal phalanx
2nd toe
coronal view, 399
sagittal view, 395, 396, 398
3rd toe
axial view, 389
coronal view, 399
sagittal view, 394
4th toe
axial view, 389
coronal view, 399
sagittal view, 392
5th toe
axial view, 388, 389
coronal view, 399
sagittal view, 391
axial view, of hand, 204
great toe
axial view, 388, 389
coronal view, 399
sagittal view, 397
index finger
coronal view, 216, 217
sagittal view, 206, 207, 208
little toe, coronal view, 400
long finger
coronal view, 216, 217
sagittal view, 209, 210
ring finger
coronal view, 216, 217
sagittal view, 211, 212
small finger
coronal view, 215, 216
sagittal view, 212, 213
thumb
axial view, 202, 203
coronal view, 216
sagittal view, 205, 205
- Psoas m.
axial view
of abdomen CT, 479, 480
of abdomen MRI, 501
of female pelvis CT, 538
of female pelvis MRI, 572
of lumbar spine, 425, 426, 427, 428, 429
of male pelvis CT, 522, 523
of male pelvis MRI, 553, 554
coronal view
of abdomen CT, 489, 490, 491
of abdomen MRI, 513, 514, 515, 516
of female pelvis CT, 547, 548, 550, 551
of female pelvis MRI, 581, 582
of hip, 245
of lumbar spine, 432, 433, 434, 435, 436
of male pelvis CT, 532, 533, 534
of male pelvis MRI, 566, 567, 568
sagittal view
of abdomen CT, 481, 482, 485, 486
of abdomen MRI, 503, 504, 508, 509
of female pelvis CT, 543, 544
of female pelvis MRI, 576, 577
of lumbar spine, 430
of male pelvis CT, 528
of male pelvis MRI, 560, 561, 562
- Psoas major m., origin, insertion, and nerve supply of, 222–223t
- Pubic bone
axial view
of female pelvis CT, 541
of male pelvis CT, 526

- Pubic bone (*Continued*)
 coronal view, of male pelvis CT, 532
 sagittal view
 of male pelvis CT, 529
 of male pelvis MRI, 562
- Pubic ramus
 axial view
 of female pelvis CT, 542
 of male pelvis CT, 527
 sagittal view, of female pelvis MRI, 577
- Pubic ramus, inferior
 axial view
 of female pelvis MRI, 575
 of hip, 229, 230
 coronal view
 of female pelvis CT, 549, 550
 of hip, 246
 of male pelvis CT, 533, 534
 sagittal view, of female pelvis CT, 544
- Pubic ramus, superior
 axial view
 of female pelvis CT, 541
 of hip, 227, 228
 coronal view
 of female pelvis CT, 546, 547, 548
 of female pelvis MRI, 580, 581
 of hip, 244, 245
 of hip arthrogram, 262
 of male pelvis CT, 532, 533
 of male pelvis MRI, 566
 of thigh, 288
 sagittal view
 of female pelvis CT, 543
 of female pelvis MRI, 576
 of hip, 242
 of male pelvis CT, 528, 529
 of male pelvis MRI, 560, 561, 562
- Pubic symphysis
 axial view
 of female pelvis CT, 541
 of male pelvis MRI, 557
 coronal view
 of female pelvis CT, 547
 of female pelvis MRI, 581
 of male pelvis MRI, 565, 566
 of thigh, 288
 sagittal view
 of female pelvis CT, 545
 of female pelvis MRI, 579
 of male pelvis MRI, 564
- Pubis
 axial view, of male pelvis MRI, 557
 coronal view, of hip, 245
 sagittal view
 of female pelvis CT, 544
 of female pelvis MRI, 578
 of male pelvis MRI, 563, 564
 of thigh, 284, 285
- Puborectalis m., axial view, of female pelvis CT, 542
- Pulmonary a.
 coronal view
 of heart MRI, 467
 of thorax CT, 453, 455
 left
 axial view
 of heart MRI, 461
 of thorax CT, 444
 coronal view, of thorax CT, 457
 sagittal view
 of heart MRI, 464
 of thorax CT, 449
- main
 axial view
 of heart MRI, 461
 of pectoral girdle and chest wall, 11
 of thorax CT, 444, 445
 coronal view
 of heart MRI, 468
 of thorax CT, 453, 454, 456
 sagittal view
 of heart MRI, 464
 of thorax CT, 450
- right
 axial view
 of heart MRI, 461
- Pulmonary a. (*Continued*)
 of pectoral girdle and chest wall, 11
 of thorax CT, 444
 coronal view
 of heart MRI, 468
 of thorax CT, 455
 sagittal view
 of heart MRI, 465
 of thorax CT, 451
 sagittal view, of thorax CT, 449, 450, 451
- Pulmonary outflow tract
 axial view
 of heart MRI, 462
 of thorax CT, 446
 coronal view
 of heart MRI, 467
 of thorax CT, 453
 sagittal view
 of heart MRI, 464, 465
 of thorax CT, 449, 450
- Pulmonary trunk, axial view, of thorax CT, 445
- Pulmonary v.
 left
 axial view
 of heart MRI, 461, 462
 of thorax CT, 445
 coronal view
 of heart MRI, 468
 of thorax CT, 454, 456
 sagittal view
 of heart MRI, 464
 of thorax CT, 449, 450
 middle, axial view, of heart MRI, 462
- right
 axial view, of heart MRI, 462
 coronal view, of thorax CT, 454, 457
 sagittal view
 of heart MRI, 466
 of thorax CT, 452
 sagittal view, of heart MRI, 466
 segmental, sagittal view, of thorax CT, 449
- Pulmonic valve, axial view, of heart MRI, 461
- Q**
- Quadrangular space
 axial view, of pectoral girdle and chest wall, 8, 9
 coronal view, of pectoral girdle and chest wall, 28, 29
 oblique coronal view, of shoulder, 62, 63
 sagittal view, of arm, 101
- Quadratus femoris m.
 axial view
 of female pelvis CT, 541
 of female pelvis MRI, 575
 of hip, 229, 230, 231
 of male pelvis CT, 522, 527
 of male pelvis MRI, 557, 558
 coronal view
 of female pelvis CT, 550, 551
 of female pelvis MRI, 582
 of hip, 246, 247
 of male pelvis CT, 535
 of male pelvis MRI, 569
 of thigh, 291
 origin, insertion, and nerve supply of, 222–223t
 sagittal view
 of hip, 237, 238, 239
 of male pelvis CT, 528
 of thigh, 279, 280, 281, 282
- Quadratus lumborum m.
 axial view
 of abdomen CT, 478, 479, 480
 of abdomen MRI, 501
 of lumbar spine, 425, 427
 of male pelvis CT, 522
 coronal view
 of abdomen CT, 491, 492
 of abdomen MRI, 515, 516
 of female pelvis CT, 551
 of female pelvis MRI, 583
 of lumbar spine, 429, 434, 435
 of male pelvis CT, 534, 535
 sagittal view
 of abdomen CT, 481, 486
 of abdomen MRI, 502, 503
- Quadratus lumborum m. (*Continued*)
 of lumbar spine, 429
 of male pelvis CT, 528
- Quadratus lumborum t., axial view, of lumbar spine, 426
- Quadratus plantae m.
 axial view
 of ankle, 355, 356, 357
 of foot, 388, 389
 coronal view
 of ankle, 372, 373, 374, 375, 376, 377, 378, 379
 of foot, 405, 406, 407
 oblique axial view, of ankle, 361, 362, 363, 364
 origin, insertion, and nerve supply of, 382–384t
 sagittal view
 of ankle, 368, 369
 of foot, 393, 394, 395
- Quadriceps t.
 axial view, of knee, 295, 296
 coronal view
 of knee, 311
 of thigh, 287
 sagittal view
 of knee, 304, 305, 306, 307
 of thigh, 281
- Quadrilateral plate
 axial view, of female pelvis CT, 540
 coronal view, of hip, 246
 sagittal view, of hip, 241
- R**
- Radial a.
 axial view
 of elbow, 119, 120, 121, 122, 123, 124
 of forearm, 147, 148, 149, 150, 151, 152, 153, 154
 of hand, 198
 coronal view
 of forearm, 164, 165, 166
 of hand, 215, 216
 oblique coronal, of elbow, 134, 135, 136
 oblique sagittal view, of elbow, 129
 sagittal view, of forearm, 156, 157
- Radial collateral lig.
 axial view
 of elbow, 118, 119, 120
 of hand, 204
 coronal view, of hand, 216, 217
 oblique coronal, of elbow, 138, 139
 oblique sagittal view, of elbow, 126
 sagittal view, of hand, 206
- Radial fossa
 oblique sagittal view, of elbow, 128
 sagittal view, of arm, 100
- Radial head
 axial view, of elbow, 119, 120
 coronal view, of arm, 106, 107
 oblique coronal, of elbow, 138, 139
 oblique sagittal view, of elbow, 126, 127, 128, 129
 sagittal view, of arm, 99, 100
- Radial n.
 axial view
 of arm, 92, 93, 94, 95, 96
 of elbow, 115
 of pectoral girdle and chest wall, 11, 12, 13
 coronal view
 of arm, 109
 of pectoral girdle and chest wall, 29, 30, 31
 oblique coronal view
 of elbow, 138, 139
 of shoulder, 60, 62
 oblique sagittal view
 of elbow, 126
 of shoulder, 52
 sagittal view
 of arm, 100, 101, 102
 of pectoral girdle and chest wall, 16
- Radial n., deep
 axial view
 of elbow, 115, 116, 117, 118, 119, 120, 121, 122, 123, 124
 of forearm, 146, 147
 oblique coronal, of elbow, 136, 137, 138, 139, 140
 oblique sagittal view, of elbow, 127
 sagittal view, of forearm, 157, 158

- Radial n., superficial
axial view
of elbow, 115, 116, 117, 118, 119, 120, 121, 122, 123, 124
of forearm, 146, 147, 148, 149, 150, 151, 152, 153, 154, 155
coronal view, of forearm, 165, 166, 167
oblique coronal, of elbow, 136
oblique sagittal view, of elbow, 127
- Radial neck
axial view, of elbow, 121
oblique coronal, of elbow, 139
sagittal view, of forearm, 158
- Radial notch of ulna, axial view, of elbow, 119
- Radial recurrent a.
axial view, of elbow, 119, 120, 121
oblique coronal view, of elbow, 140
- Radial sesamoid
axial view, of hand, 201
sagittal view, of hand, 206
- Radial styloid, coronal view, of hand, 216
- Radial tuberosity
axial view, of elbow, 122
coronal view, of forearm, 166
oblique coronal, of elbow, 138, 139
oblique sagittal view, of elbow, 128
sagittal view, of forearm, 158
- Radioscaphocapitate lig., coronal view, of hand, 215
- Radioulnar joint, proximal, axial view, of elbow, 119
- Radioulnar lig., palmar
coronal view, of wrist, 191
sagittal view, of wrist, 186
- Radius
axial view, of elbow, 123, 124
coronal view
of forearm, 165, 166, 167, 168
of hand, 215, 216, 217, 218
oblique coronal, of elbow, 136, 137, 138
oblique sagittal view, of elbow, 128
sagittal view, of forearm, 157, 158, 159
- Rectosigmoid junction, axial view, of male pelvis CT, 524
- Rectovesical fossa, sagittal view, of male pelvis CT, 530
- Rectum
axial view
of female pelvis CT, 539, 540, 541
of female pelvis MRI, 572, 573, 574, 575
of hip, 224, 225, 226, 227, 228
of male pelvis CT, 524, 525, 526
of male pelvis MRI, 555, 556, 557
coronal view
of female pelvis CT, 551
of hip, 248
of male pelvis CT, 535, 536
of male pelvis MRI, 568, 569, 570
sagittal view
of female pelvis CT, 544, 545
of female pelvis MRI, 578
of male pelvis CT, 530
of male pelvis MRI, 562, 563, 564
- Rectus abdominis m.
axial view
of abdomen CT, 475, 477, 478, 480
of abdomen MRI, 498, 499
of female pelvis CT, 538, 539, 540, 541
of female pelvis MRI, 573, 574
of hip, 224, 225, 226
of male pelvis CT, 522, 523, 524, 525, 526
of male pelvis MRI, 553, 554, 555, 556, 557
coronal view
of abdomen CT, 487
of abdomen MRI, 511
of female pelvis MRI, 580
of hip, 243
of male pelvis CT, 531
of male pelvis MRI, 565
origin, insertion, and nerve supply of, 474t
sagittal view
of abdomen CT, 481, 482, 484, 485, 486
of abdomen MRI, 502, 503, 504, 507, 508, 509
of female pelvis CT, 543, 544, 545
of female pelvis MRI, 576, 577, 578, 579
of hip, 241
of male pelvis CT, 528, 530
of male pelvis MRI, 561, 562, 563, 564
- Rectus abdominis m. (*Continued*)
tendinous intersection
coronal view, of abdomen MRI, 511
sagittal view, of abdomen MRI, 502, 503, 507, 508
- Rectus abdominis t., axial view, of male pelvis MRI, 557
- Rectus femoris m.
axial view
of female pelvis CT, 540, 541, 542
of female pelvis MRI, 575
of hip, 226, 227, 228, 229, 230, 231, 232
of male pelvis CT, 525, 526, 527
of male pelvis MRI, 556, 557, 558
of thigh, 269, 270, 271, 272, 273, 274, 275
coronal view
of female pelvis CT, 546, 547
of female pelvis MRI, 580
of hip, 243, 244
of male pelvis CT, 531, 532, 533
of male pelvis MRI, 565, 566
of thigh, 286, 287
origin, insertion, and nerve supply of, 268t
sagittal view
of hip, 233, 234, 235, 236, 237
of thigh, 279, 280, 281, 282, 283
- Rectus femoris t.
axial view
of hip, 226, 227, 228, 229
of hip arthrogram, 251, 252, 253, 254, 255, 256
of thigh, 271, 276
coronal view
of hip, 243
of thigh, 286, 287
sagittal view, of hip, 237
- Rectus femoris t., reflected head
axial view
of hip, 225
of male pelvis CT, 525
of male pelvis MRI, 556
coronal view
of female pelvis MRI, 580, 581
of hip, 245
of male pelvis MRI, 566
sagittal view, of hip, 237
- Rectus femoris t., straight head
axial view
of hip, 225
of male pelvis CT, 525
coronal view
of female pelvis MRI, 580, 581
of hip, 244
of male pelvis MRI, 566
- Renal a.
left
axial view
of abdomen CT, 478
of abdomen MRI, 500
coronal view
of abdomen CT, 490
of abdomen MRI, 514, 515
of lumbar spine, 432
sagittal view
of abdomen CT, 482, 483
of abdomen MRI, 503, 504
right
axial view, of abdomen MRI, 499
coronal view
of abdomen CT, 490
of abdomen MRI, 514, 515
of lumbar spine, 432
sagittal view
of abdomen CT, 484, 485
of abdomen MRI, 506, 507, 508
of lumbar spine, 431
sagittal view, of abdomen CT, 481
- Renal cortex
axial view, of abdomen CT, 478
coronal view, of abdomen CT, 492
sagittal view, of abdomen CT, 486
- Renal hilum, sagittal view, of abdomen CT, 481
- Renal medulla
axial view, of abdomen CT, 478
coronal view, of abdomen CT, 492
sagittal view, of abdomen CT, 486
- Renal pelvis
axial view
of abdomen CT, 478, 479
of abdomen MRI, 500
coronal view
of abdomen CT, 491
of abdomen MRI, 516
sagittal view
of abdomen CT, 485
of abdomen MRI, 503, 508
- Renal sinus
axial view, of abdomen MRI, 497, 498
sagittal view, of abdomen MRI, 509
- Renal v.
left
axial view
of abdomen CT, 478, 479
of abdomen MRI, 498, 499, 500
coronal view
of abdomen CT, 489, 490
of abdomen MRI, 513, 514, 515
of lumbar spine, 432
sagittal view
of abdomen CT, 482, 483
of abdomen MRI, 503, 504, 505, 506
right
axial view
of abdomen CT, 478
of abdomen MRI, 499, 500
coronal view
of abdomen CT, 490
of abdomen MRI, 515
of thorax CT, 455
sagittal view
of abdomen CT, 485
of abdomen MRI, 508
sagittal view, of abdomen CT, 481
- Retrobursal fat, coronal view, of knee, 311
- Retropubic space of Retzius, axial view
of female pelvis CT, 541
of male pelvis CT, 526
- Retrotrochlear eminence
axial view, of ankle, 355, 356
coronal view, of ankle, 378
- Rhomboid major m.
axial view
of pectoral girdle and chest wall, 7, 8, 9, 10, 11, 12
of thoracic spine, 415
coronal view
of pectoral girdle and chest wall, 32, 33
of thoracic spine, 422
origin, insertion, and nerve supply of, 412–414t
sagittal view
of pectoral girdle and chest wall, 20, 21, 22, 23
of thoracic spine, 417
- Rhomboid minor m.
axial view, of pectoral girdle and chest wall, 6
coronal view
of pectoral girdle and chest wall, 32
of thoracic spine, 421
origin, insertion, and nerve supply of, 412–414t
sagittal view
of pectoral girdle and chest wall, 21, 22
of thoracic spine, 417
- Rib
1st, sagittal view, of thorax CT, 449
3rd, sagittal view, of pectoral girdle and chest wall, 23
6th, axial view, of thoracic spine, 415
9th, axial view, of thoracic spine, 416
10th, axial view, of thoracic spine, 416
11th, sagittal view, of lumbar spine, 429, 430
12th
coronal view
of abdomen CT, 492
of lumbar spine, 436, 437
sagittal view, of lumbar spine, 429, 430
angle, sagittal view, of thoracic spine, 417
axial view
of abdomen CT, 475
of abdomen MRI, 494
of pectoral girdle and chest wall, 6, 8, 9, 10, 11, 13
coronal view
of pectoral girdle and chest wall, 27, 28, 30, 31, 33
of thoracic spine, 421, 422
of thorax CT, 457

- Semimembranosus m.
axial view
of knee, 295, 296
of male pelvis MRI, 558
of thigh, 269, 270, 271, 272, 273, 274, 275, 276
coronal view
of knee, 319, 320
of leg, 345
of male pelvis MRI, 569, 570
of thigh, 290, 291, 292, 293
origin, insertion, and nerve supply of, 222–223t
sagittal view
of knee, 306, 307, 308
of thigh, 279, 280, 281, 282
- Semimembranosus t.
axial view
of female pelvis MRI, 575
of hip, 230, 231, 232
of knee, 295, 296, 297, 298, 299
of male pelvis MRI, 558
of thigh, 269, 270, 271, 272, 273
coronal view
of female pelvis MRI, 583
of knee, 318, 319, 320
of leg, 345
of male pelvis CT, 536
of thigh, 291
sagittal view
of hip, 239
of hip arthrogram, 259
of knee, 308, 309
of leg, 339, 340
of male pelvis CT, 528
of male pelvis MRI, 559
of thigh, 280, 281, 282
- Seminal vesicle
axial view
of male pelvis CT, 525
of male pelvis MRI, 556
coronal view
of male pelvis CT, 534, 535
of male pelvis MRI, 568, 569
sagittal view
of male pelvis CT, 529
of male pelvis MRI, 561, 562, 563, 564
- Semispinalis, axial view, of thoracic spine, 415
- Semispinalis capitis m.
axial view, of pectoral girdle and chest wall, 6
coronal view, of pectoral girdle and chest wall, 28, 29, 30, 31
origin, insertion, and nerve supply of, 412–414t
sagittal view, of pectoral girdle and chest wall, 23
- Semispinalis cervicis m.
axial view, of pectoral girdle and chest wall, 4
coronal view, of pectoral girdle and chest wall, 29
origin, insertion, and nerve supply of, 412–414t
- Semispinalis thoracis m.
axial view, of pectoral girdle and chest wall, 7, 8, 10, 11, 12
coronal view, of pectoral girdle and chest wall, 31, 33
origin, insertion, and nerve supply of, 412–414t
- Semitendinosus m.
axial view
of hip, 230, 231, 232
of knee, 295
of male pelvis MRI, 558
of thigh, 269, 272, 273, 274, 275, 276
coronal view
of female pelvis MRI, 583
of hip, 247, 248
of male pelvis MRI, 569, 570
of thigh, 291, 292, 293
origin, insertion, and nerve supply of, 222–223t
sagittal view
of hip, 237, 238, 239, 240
of male pelvis MRI, 559
of thigh, 279, 280, 281, 282
- Semitendinosus t. (*Continued*)
sagittal view
of hip, 238, 239
of hip arthrogram, 259
of knee, 308, 309, 310
of leg, 340
of male pelvis MRI, 559
- Serratus anterior m.
axial view
of abdomen CT, 475
of abdomen MRI, 494, 495, 496, 497
of pectoral girdle and chest wall, 6, 7, 8, 9, 10, 11, 12, 13
of shoulder, 39
coronal view
of abdomen MRI, 516, 517
of pectoral girdle and chest wall, 27, 28, 29, 30, 31, 32, 33
of thoracic spine, 420, 421, 422
oblique coronal view, of shoulder, 56, 57
origin, insertion, and nerve supply of, 412–414t
sagittal view, of pectoral girdle and chest wall, 18, 19, 20, 21
- Serratus posterior m.
axial view
of pectoral girdle and chest wall, 5
of thoracic spine, 416
sagittal view, of pectoral girdle and chest wall, 21
- Serratus posterior m., inferior
coronal view, of thoracic spine, 422
origin, insertion, and nerve supply of, 412–414t
sagittal view, of pectoral girdle and chest wall, 21, 22
- Serratus posterior m., superior
coronal view
of pectoral girdle and chest wall, 31
of thoracic spine, 421, 422, 423
origin, insertion, and nerve supply of, 412–414t
sagittal view, of pectoral girdle and chest wall, 21, 22
- Sesamoid
lateral
axial view, of foot, 389
coronal view, of foot, 400, 401
sagittal view, of foot, 397
medial
axial view, of foot, 389
coronal view, of foot, 400, 401
sagittal view, of foot, 398
radial
axial view, of hand, 201
sagittal view, of hand, 206
ulnar
axial view, of hand, 201
sagittal view, of hand, 206
volar plate
axial view, of hand, 204
coronal view, of hand, 215
sagittal view, of hand, 207
- Sinuses of Valsalva, sagittal view, of heart MRI, 465
- Small bowel
axial view
of abdomen CT, 478, 479, 480
of female pelvis CT, 538
of male pelvis CT, 522, 523
of male pelvis MRI, 553, 554, 555
coronal view
of abdomen CT, 487, 488, 489, 490, 491
of female pelvis CT, 546, 547, 548
of male pelvis CT, 531, 532
loops
axial view
of female pelvis MRI, 572
of male pelvis CT, 522
coronal view
of abdomen CT, 487
of abdomen MRI, 511
of female pelvis MRI, 581, 582, 583
of male pelvis MRI, 565
sagittal view, of female pelvis MRI, 576, 577, 578
sagittal view
of abdomen CT, 481, 483, 484, 485, 486
of abdomen MRI, 502, 503, 504, 505, 506, 507, 508, 509
of female pelvis CT, 543, 544, 545
of female pelvis MRI, 576, 579
of male pelvis CT, 528, 529, 530
of male pelvis MRI, 559, 560, 561, 562, 563, 564
- Soleus m.
axial view
of ankle, 349, 350, 351, 352
of knee, 300, 301
of leg, 324, 325, 326, 327, 328, 329, 330, 331, 332, 333
coronal view
of ankle, 379, 380
of knee, 319, 320
of leg, 342, 343, 344, 345, 346
origin, insertion, and nerve supply of, 322–323t
sagittal view
of ankle, 367, 368
of knee, 302, 303, 305, 306, 307, 308
of leg, 334, 335, 336, 337, 338, 339, 340
Soleus t., axial view, of leg, 324, 330, 331, 332
- Spermatic cord
axial view
of hip, 228
of male pelvis CT, 526, 527
of male pelvis MRI, 557, 558
coronal view
of hip, 243
of male pelvis CT, 531
of male pelvis MRI, 565
sagittal view
of male pelvis CT, 529
of male pelvis MRI, 561, 562
- Spinal canal
axial view, of abdomen MRI, 494, 495
coronal view, of abdomen MRI, 515, 516, 517
sagittal view
of abdomen MRI, 505, 506
of female pelvis MRI, 578
- Spinal cord
axial view
of abdomen MRI, 494, 495
of heart MRI, 462
of thoracic spine, 416
coronal view
of abdomen MRI, 517
of pectoral girdle and chest wall, 31
of thoracic spine, 420
of thorax CT, 457, 458
sagittal view
of abdomen MRI, 505, 506
of heart MRI, 465
of thoracic spine, 419
of thorax CT, 451
- Spinal n., sagittal view, of thoracic spine, 418
- Spinalis capitis m., origin, insertion, and nerve supply of, 412–414t
- Spinalis cervicis m., origin, insertion, and nerve supply of, 412–414t
- Spinalis thoracis m.
axial view, of thoracic spine, 415
coronal view
of pectoral girdle and chest wall, 31
of thoracic spine, 422
origin, insertion, and nerve supply of, 412–414t
sagittal view, of thoracic spine, 419
- Spinoglenoid notch
axial view
of shoulder, 40
of shoulder arthrogram, 67, 68
coronal view, of pectoral girdle and chest wall, 29
oblique coronal view, of shoulder arthrogram, 80
oblique sagittal view, of shoulder, 53
- Spinolaminar junction, sagittal view, of lumbar spine, 431
- Spinous process
axial view
of lumbar spine, 425
of male pelvis MRI, 553
coronal view
of abdomen CT, 492
of abdomen MRI, 517
of male pelvis CT, 536
of pectoral girdle and chest wall, 33
of thoracic spine, 421, 422
sagittal view
of abdomen MRI, 506
of male pelvis CT, 530
of thoracic spine, 419

- Spleen
axial view
of abdomen CT, 475, 476, 477, 478, 479
of abdomen MRI, 494, 495, 496, 497, 498, 499, 500
coronal view
of abdomen CT, 491, 492
of abdomen MRI, 512, 513, 514, 515, 516, 517
of lumbar spine, 436
of thoracic spine, 420
of thorax CT, 457
sagittal view
of abdomen CT, 481, 482
of abdomen MRI, 502, 503
of thoracic spine, 417
of thorax CT, 449
- Splenic a.
axial view, of abdomen MRI, 497
coronal view
of abdomen CT, 488, 489, 490, 491
of abdomen MRI, 514, 515
of thorax CT, 454
sagittal view
of abdomen CT, 481, 482, 483
of abdomen MRI, 503, 504, 505
- Splenic hilum, sagittal view, of abdomen CT, 481
- Splenic v.
axial view
of abdomen CT, 476, 477, 478
of abdomen MRI, 498
coronal view
of abdomen CT, 489, 490, 491, 492
of thorax CT, 454
sagittal view
of abdomen CT, 481, 482, 483
of abdomen MRI, 503, 504, 505, 506
- Splenic vessels
axial view, of abdomen MRI, 495, 496
coronal view, of abdomen MRI, 515
sagittal view, of abdomen MRI, 502
- Splenius capitis m.
axial view, of pectoral girdle and chest wall, 6, 7, 8
coronal view, of pectoral girdle and chest wall, 29, 30, 31, 32
origin, insertion, and nerve supply of, 412–414t
sagittal view, of pectoral girdle and chest wall, 22, 23
- Splenius cervicis m.
axial view, of pectoral girdle and chest wall, 6, 7, 8
coronal view, of pectoral girdle and chest wall, 32
origin, insertion, and nerve supply of, 412–414t
sagittal view, of pectoral girdle and chest wall, 22, 23
- Splenoportal confluence
axial view, of abdomen CT, 478
coronal view, of abdomen CT, 488
sagittal view, of abdomen CT, 483
- Sternoclavicular joint
axial view, of pectoral girdle and chest wall, 8
coronal view, of pectoral girdle and chest wall, 24, 25
sagittal view, of pectoral girdle and chest wall, 23
- Sternocleidomastoid m.
axial view, of pectoral girdle and chest wall, 6
coronal view, of pectoral girdle and chest wall, 25, 26, 27
sagittal view, of pectoral girdle and chest wall, 23
- Sternocleidomastoid m., clavicular head
axial view, of pectoral girdle and chest wall, 6
sagittal view, of pectoral girdle and chest wall, 21, 22, 23
- Sternocleidomastoid m., sternal head
axial view, of pectoral girdle and chest wall, 6, 7, 8
coronal view, of pectoral girdle and chest wall, 25
- Sternohyoid m.
axial view, of pectoral girdle and chest wall, 6, 7, 8
sagittal view, of pectoral girdle and chest wall, 22, 23
- Sternothyroid m., axial view, of pectoral girdle and chest wall, 7, 8
- Sternum
axial view
of abdomen MRI, 494
of heart MRI, 460, 462, 463
of pectoral girdle and chest wall, 9, 10, 11, 12, 13
of thorax CT, 444, 446
coronal view
of abdomen CT, 487
of abdomen MRI, 510
of heart MRI, 467
of pectoral girdle and chest wall, 24
- Sternum (*Continued*)
sagittal view
of abdomen CT, 483
of abdomen MRI, 506
of heart MRI, 465
of thorax CT, 451
- Stomach
antrum
axial view
of abdomen CT, 478, 479
of abdomen MRI, 498, 499, 500
coronal view
of abdomen CT, 487
of abdomen MRI, 511
sagittal view
of abdomen CT, 482, 483
of abdomen MRI, 508
axial view, of abdomen CT, 475, 476, 477, 478, 479
- body
axial view
of abdomen CT, 477, 478, 479
of abdomen MRI, 496, 497, 498
coronal view
of abdomen CT, 487
of abdomen MRI, 510, 511
sagittal view
of abdomen CT, 481
of abdomen MRI, 504, 505, 506, 507
- coronal view
of abdomen CT, 488, 489
of thorax CT, 453
- fundus
axial view
of abdomen CT, 477
of abdomen MRI, 494, 495
coronal view
of abdomen CT, 491, 492
of abdomen MRI, 511, 512, 513, 514, 515
sagittal view
of abdomen CT, 481
of abdomen MRI, 503, 504
- pylorus ring, coronal view, of abdomen MRI, 512
- sagittal view
of abdomen CT, 481, 482, 483
of thorax CT, 449
- Subarachnoid space, sagittal view, of thoracic spine, 419
- Subclavian a.
axial view
of pectoral girdle and chest wall, 6
of thorax CT, 442, 443
coronal view
of heart MRI, 468
of pectoral girdle and chest wall, 27
of thorax CT, 454, 455
sagittal view
of pectoral girdle and chest wall, 21, 22
of thorax CT, 449, 450
- Subclavian v.
axial view
of pectoral girdle and chest wall, 7
of thorax CT, 442
coronal view
of pectoral girdle and chest wall, 25, 26, 27
of thorax CT, 453, 454, 455
sagittal view
of pectoral girdle and chest wall, 21, 22
of thorax CT, 449, 452
- Subclavian vessels, coronal view, of heart MRI, 468
- Subclavius m.
axial view
of pectoral girdle and chest wall, 7
of shoulder, 38, 39, 40
coronal view, of pectoral girdle and chest wall, 25, 26
oblique coronal view, of shoulder, 56
oblique sagittal view, of shoulder, 55
origin, insertion, and nerve supply of, 35t
sagittal view, of pectoral girdle and chest wall, 18, 19, 20, 21
- Subcutaneous fat, coronal view, of abdomen MRI, 510, 517
- Subcutaneous vessels, coronal view, of abdomen MRI, 510
- Sublabral sulcus, oblique coronal view, of shoulder, 59
- Sublime process
axial view, of elbow, 119, 120
oblique coronal, of elbow, 139
- Subscapular a.
axial view
of pectoral girdle and chest wall, 9
of shoulder, 44, 45
coronal view, of pectoral girdle and chest wall, 28
oblique coronal view, of shoulder, 58
oblique sagittal view, of shoulder, 53, 54
- Subscapular recess
oblique coronal view, of shoulder arthrogram, 78, 79
oblique sagittal view, of shoulder arthrogram, 77
- superior
axial view, of shoulder arthrogram, 69
oblique coronal view, of shoulder arthrogram, 78
oblique sagittal view, of shoulder arthrogram, 76, 77
- Subscapularis m.
ABER view, of shoulder arthrogram, 85, 86, 87, 88, 89
axial view
of heart MRI, 460
of pectoral girdle and chest wall, 6, 7, 8, 9, 10, 11
of shoulder, 39, 40, 41, 42, 43, 44, 45
of shoulder arthrogram, 67, 68, 69, 70
coronal view
of arm, 107, 108, 109, 110
of pectoral girdle and chest wall, 26, 27, 28, 29, 30, 31, 32
of thoracic spine, 420, 421, 422, 423
oblique coronal view
of shoulder, 56, 57, 58, 59, 60
of shoulder arthrogram, 78, 79, 80, 81
oblique sagittal view
of shoulder, 51, 52, 53, 54, 55
of shoulder arthrogram, 76, 77
origin, insertion, and nerve supply of, 35t
sagittal view
of arm, 103
of pectoral girdle and chest wall, 15, 17, 18, 19
- Subscapularis t.
ABER view, of shoulder arthrogram, 84, 85
axial view
of shoulder, 40, 41, 42
of shoulder arthrogram, 68, 69, 70
coronal view, of arm, 106
oblique coronal view
of shoulder, 58
of shoulder arthrogram, 78
oblique sagittal view
of shoulder, 48, 49, 50, 51
of shoulder arthrogram, 72, 73, 74, 75, 76, 77
sagittal view, of pectoral girdle and chest wall, 15
- Subtalar joint, anterior
coronal view, of ankle, 373
sagittal view, of ankle, 368, 369
- Subtalar joint, middle
coronal view, of ankle, 374, 375
oblique axial view, of ankle, 362
sagittal view
of ankle, 369, 370
of foot, 395
- Subtalar joint, posterior
coronal view, of ankle, 376, 377, 378
oblique axial view, of ankle, 361
sagittal view, of ankle, 366, 367, 368, 369
- Subtrapezial plexus, coronal view, of thoracic spine, 422
- Sulcus, posterior, axial view, of ankle, 354
- Superior vena cava
axial view
of heart MRI, 460, 461, 462
of pectoral girdle and chest wall, 9, 10, 11
of thorax CT, 444, 445
coronal view
of pectoral girdle and chest wall, 26, 27
of thorax CT, 454, 455
sagittal view, of thorax CT, 451
- Supinator m.
axial view
of elbow, 120, 121, 122, 123, 124
of forearm, 146, 147, 148
coronal view
of forearm, 164, 165, 166, 167, 168
oblique coronal
of elbow, 136, 137, 138, 139, 140
oblique sagittal view
of elbow, 126, 127, 128
origin, insertion, and nerve supply of, 144–145t
sagittal view, of forearm, 157, 158, 159

- Supinator ridge, axial view, of elbow, 121
- Supracondylar crest, lateral
axial view, of arm, 95, 96, 97
sagittal view, of arm, 99, 100
- Supraglenoid tubercle
axial view, of shoulder, 67
oblique sagittal view, of shoulder, 52, 76
- Suprascapular a.
axial view
of pectoral girdle and chest wall, 7
of shoulder, 38, 39, 40, 41
coronal view, of pectoral girdle and chest wall,
28, 29
oblique coronal view
of shoulder, 56, 57, 58, 59, 60, 61
of shoulder arthrogram, 79, 80
oblique sagittal view, of shoulder, 53
- Suprascapular n.
axial view
of pectoral girdle and chest wall, 7
of shoulder, 39, 40, 41
coronal view, of pectoral girdle and chest wall, 28, 29
oblique coronal view
of shoulder, 56, 57, 58, 59, 60, 61
of shoulder arthrogram, 79, 80
oblique sagittal view, of shoulder, 53
- Suprascapular neurovascular bundle
axial view, of pectoral girdle and chest wall, 7
sagittal view, of pectoral girdle and chest wall, 17
- Suprascapular notch
axial view, of pectoral girdle and chest wall, 7
oblique coronal view
of shoulder, 60, 61
of shoulder arthrogram, 79
- Suprascapular v., axial view, of shoulder, 39
- Supraspinatus lig.
axial view, of thoracic spine, 415, 416
coronal view, of thoracic spine, 423
- Supraspinatus m.
ABER view, of shoulder arthrogram, 84, 85
axial view
of heart MRI, 460
of pectoral girdle and chest wall, 6
of shoulder, 37, 38, 39
coronal view
of arm, 109, 110
of pectoral girdle and chest wall, 26, 27, 28, 29, 30
of thoracic spine, 420, 421, 422
oblique coronal view
of shoulder, 58, 59, 60, 61
of shoulder arthrogram, 78, 79, 80
oblique sagittal view
of shoulder, 49, 50, 51, 52, 53, 54, 55
of shoulder arthrogram, 75, 76, 77
origin, insertion, and nerve supply of, 35t,
412–414t
sagittal view
of arm, 100, 101, 103, 104
of pectoral girdle and chest wall, 15, 16, 17, 18,
19, 20
- Supraspinatus t.
ABER view, of shoulder arthrogram, 85
axial view
of pectoral girdle and chest wall, 6
of shoulder, 38, 39
of shoulder arthrogram, 67, 68
coronal view
of arm, 108, 109
of pectoral girdle and chest wall, 26, 27
oblique coronal view
of shoulder, 59, 60, 61
of shoulder arthrogram, 78, 79, 80
oblique sagittal view
of shoulder, 47, 48, 49, 50
of shoulder arthrogram, 72, 73, 74, 75, 76, 77
sagittal view
of arm, 103
of pectoral girdle and chest wall, 16
- Supraspinous lig., sagittal view
of lumbar spine, 431
of thoracic spine, 419
- Sural cutaneous n., medial, axial view, of leg, 327, 328
- Sural n.
axial view, of ankle, 349, 350
medial, axial view, of leg, 324, 325, 326, 329
- Suspensory lig., coronal view, of male pelvis MRI, 565
- Sustentaculum tali
axial view, of ankle, 355
coronal view, of ankle, 374, 375
oblique axial view, of ankle, 361, 362
sagittal view
of ankle, 369, 370
of foot, 395, 396
- Sympathetic trunk, axial view, of lumbar spine, 427
- Symphysis pubis
axial view, of male pelvis CT, 526
coronal view
of female pelvis CT, 546
of male pelvis CT, 532
sagittal view, of male pelvis CT, 530
- Synovial space
axial view, of knee, 297
sagittal view, of knee, 304, 305, 306, 307
- T**
- T5, spinous process, 415
- T6
lamina, 415
vertebra, 415
- T7
inferior facet, 415
superior facet, 415
- T9
pedicle, 416
vertebra, 416
- T10
pedicle, 416
vertebra, 416
- T12 vertebra, 435
- T12 vertebral a. and v., sagittal view, of lumbar spine, 431
- T12–L1
annulus fibrosus, 435
nucleus pulposus, 435
- Talar dome
coronal view, of ankle, 374, 375, 376
oblique axial view, of ankle, 352, 360
sagittal view, of ankle, 366, 367, 368, 369
- Talocalcaneal joint, posterior facet, axial view, of ankle, 354
- Talocalcaneal lig.
coronal view, of ankle, 374, 375
sagittal view, of ankle, 366, 367, 368
- Talofibular lig., anterior
axial view, of ankle, 353
coronal view, of ankle, 376
- Talofibular lig., posterior
axial view, of ankle, 354
coronal view, of ankle, 377
oblique axial view, of ankle, 360
sagittal view, of ankle, 365, 366, 367
- Talonavicular joint
axial view, of ankle, 353, 354
coronal view, of ankle, 372
sagittal view, of ankle, 369
- Talonavicular lig., oblique axial view, of ankle, 362
- Talus
axial view
of ankle, 354
of foot, 386
body
axial view, of ankle, 353
coronal view, of ankle, 374, 375, 376
sagittal view, of ankle, 367, 368, 369
coronal view
of ankle, 373, 374, 377, 378
of leg, 342
head
axial view
of ankle, 353, 354
of foot, 385
coronal view, of ankle, 372
sagittal view
of ankle, 368, 369
of foot, 394, 395
lateral process
coronal view, of ankle, 376
sagittal view, of ankle, 366, 367
neck
axial view, of ankle, 353
sagittal view, of foot, 394
- Talus (*Continued*)
oblique axial view, of ankle, 361, 362
posterior process
axial view, of ankle, 354
oblique axial view, of ankle, 360
sagittal view, of ankle, 368
sagittal view
of ankle, 370
of foot, 393, 396
- Tarsal sinus
axial view, of ankle, 354
coronal view, of ankle, 374
sagittal view, of ankle, 368
- Tarsometatarsal joint, 5th, axial view, of ankle, 356
- Tensor fasciae latae m.
axial view
of female pelvis CT, 540, 541, 542
of female pelvis MRI, 574, 575
of hip, 224, 225, 226, 227, 228, 229, 230, 231
of male pelvis CT, 524, 525, 526, 527
of male pelvis MRI, 556, 557, 558
of thigh, 269, 270
coronal view
of female pelvis CT, 546, 547, 548
of female pelvis MRI, 580, 581
of hip, 244, 245
of male pelvis CT, 531, 532, 533
of male pelvis MRI, 565, 566
of thigh, 286, 287, 288
origin, insertion, and nerve supply of, 222–223t
sagittal view
of hip, 233, 234, 235
of thigh, 277, 278, 279
- Teres major m.
axial view
of pectoral girdle and chest wall, 9, 10, 11, 12
of shoulder, 45
coronal view
of arm, 109, 110, 111, 113
of pectoral girdle and chest wall, 28, 29, 30, 31,
32, 33
of thoracic spine, 421, 422, 423
oblique coronal view, of shoulder, 61, 62, 63, 64
oblique sagittal view
of shoulder, 50, 51, 52, 53, 54, 55
of shoulder arthrogram, 77
origin, insertion, and nerve supply of, 35t,
412–414t
sagittal view
of arm, 101, 103, 104
of pectoral girdle and chest wall, 15, 16, 17, 18, 19
- Teres major t.
axial view
of pectoral girdle and chest wall, 10
of shoulder, 44, 45
coronal view
of arm, 108
of pectoral girdle and chest wall, 28
oblique sagittal view, of shoulder, 49, 50, 51
- Teres minor m.
axial view
of pectoral girdle and chest wall, 8, 9, 10
of shoulder, 42, 43, 44, 45
of shoulder arthrogram, 70, 71, 88
coronal view
of arm, 109, 110, 111, 112, 113
of pectoral girdle and chest wall, 29, 30, 31, 32
of thoracic spine, 420, 421, 422, 423
oblique coronal view
of shoulder, 62, 63, 64
of shoulder arthrogram, 83
oblique sagittal view
of shoulder, 49, 50, 51, 52, 53, 54, 55
of shoulder arthrogram, 75, 76, 77
origin, insertion, and nerve supply of, 35t,
412–414t
sagittal view
of arm, 100, 101, 102, 103, 104
of pectoral girdle and chest wall, 15, 16, 17
- Teres minor t.
ABER view, of shoulder arthrogram, 87, 88, 89
axial view, of shoulder arthrogram, 70
oblique coronal view
of shoulder, 64
of shoulder arthrogram, 83

- Teres minor t. (*Continued*)
 oblique sagittal view
 of shoulder, 48, 49, 50
 of shoulder arthrogram, 72, 73, 74, 75, 76
 sagittal view
 of arm, 102
 of pectoral girdle and chest wall, 15
- Testis
 axial view, of male pelvis MRI, 558
 coronal view, of male pelvis MRI, 565
 sagittal view, of male pelvis MRI, 561, 562, 563, 564
- Thecal sac
 axial view
 of lumbar spine, 425, 426, 427, 428
 of male pelvis CT, 523
 of male pelvis MRI, 553, 554
 coronal view
 of female pelvis CT, 551
 of female pelvis MRI, 583
 of lumbar spine, 435
 of male pelvis CT, 535
 of thoracic spine, 420
 sagittal view
 of female pelvis CT, 544, 545
 of lumbar spine, 431
 of male pelvis CT, 530
 of male pelvis MRI, 564
- Thoracic a.
 lateral, oblique sagittal view, of shoulder, 55
 segmental, coronal view, of thoracic spine, 420
- Thoracic a., internal
 axial view
 of pectoral girdle and chest wall, 10, 11, 12, 13
 of thorax CT, 443, 444
 coronal view, of pectoral girdle and chest wall, 24, 25
- Thoracic duct, axial view, of thoracic spine, 416
- Thoracic lamina, coronal view, of thoracic spine, 421
- Thoracic n., lateral, oblique sagittal view, of shoulder, 55
- Thoracic neurovascular bundle
 lateral, coronal view, of pectoral girdle and chest wall, 31
 long, coronal view, of pectoral girdle and chest wall, 31
- Thoracic pars interarticularis, sagittal view, of thoracic spine, 419
- Thoracic pedicle
 coronal view, of thoracic spine, 420
 sagittal view, of thoracic spine, 419
- Thoracic spinal n.
 coronal view, of thoracic spine, 420
 sagittal view, of thoracic spine, 419
- Thoracic v., internal
 axial view
 of pectoral girdle and chest wall, 10, 11, 12, 13
 of thorax CT, 444
 coronal view, of pectoral girdle and chest wall, 24, 25
- Thoracic v., segmental, coronal view, of thoracic spine, 420
- Thoracic vertebra
 coronal view, of pectoral girdle and chest wall, 28
 sagittal view, of thoracic spine, 419
- Thoracic vertebral body
 axial view
 of heart MRI, 460, 462
 of pectoral girdle and chest wall, 9
 coronal view, of pectoral girdle and chest wall, 29, 30
 sagittal view, of heart MRI, 465
- Thoracic vertebral vessels
 axial view, of thoracic spine, 415
 sagittal view, of thoracic spine, 418
- Thoracoacromial a.
 axial view, of pectoral girdle and chest wall, 7
 oblique coronal view, of shoulder, 56
- Thoracoacromial a., acromial branch
 axial view
 of pectoral girdle and chest wall, 6
 of shoulder, 36, 37, 38
 oblique coronal view, of shoulder, 57, 58
- Thoracoacromial a., clavicular branch
 axial view, of shoulder, 36
 oblique coronal view, of shoulder, 57, 58
- Thoracoacromial a., deltoid branch, axial view, of shoulder, 41
- Thoracoacromial v., acromial branch, axial view, of shoulder, 37, 38
- Thoracodorsal a., oblique coronal view, of shoulder, 58
- Thoracolumbar fascia
 axial view
 of lumbar spine, 427
 posterior part, 425, 426, 427, 428
 of thoracic spine, posterior part, 416
- sagittal view
 of lumbar spine, 430, 431
 posterior part, 429, 430
 of thoracic spine, 418
- Thumb
 distal phalanx
 coronal view, 216
 sagittal view, 205
 interphalangeal joint, coronal view, 217
- proximal phalanx
 axial view, 202
 coronal view, 216
 sagittal view, 205, 205, 206
- Thyrocervical trunk, coronal view, of pectoral girdle and chest wall, 27
- Thyroid
 axial view
 of pectoral girdle and chest wall, 5
 of thorax CT, 442
 coronal view, of thorax CT, 453
- Thyroid cartilage
 axial view, of pectoral girdle and chest wall, 4
 coronal view, of pectoral girdle and chest wall, 25
- Tibia
 axial view
 of ankle, 349, 350, 351, 352
 of knee, 300, 301
 of leg, 324, 325, 326, 328, 329, 331, 333
- coronal view
 of ankle, 374, 375, 376, 377
 of knee, 314, 315, 316, 317, 318
 of leg, 342, 343, 344
- distal, sagittal view, of leg, 336, 338
- oblique axial view, of ankle, 359, 360, 361
- sagittal view
 of ankle, 366, 367, 368, 369, 371
 of knee, 303, 304, 305, 307, 309, 310
 of leg, 337, 338, 339
- Tibial a., posterior, coronal view, of leg, 344
- Tibial condyle, medial, axial view, of knee, 300
- Tibial cortex, coronal view, of leg, 342, 343
- Tibial eminence, coronal view
 of knee, 316, 317
 of leg, 337
- Tibial (medial) collateral lig.
 axial view, of knee, 298, 299
- coronal view
 of knee, 315, 316
 of leg, 343
- Tibial n.
 axial view
 of ankle, 349, 350, 351, 352, 353, 354, 355, 356
 of knee, 295, 296, 297, 298, 299, 300, 301
 of leg, 324, 325, 326, 327, 328, 329, 330, 331, 332, 333
 of thigh, 275, 276
- coronal view
 of ankle, 377, 379
 of knee, 317, 318, 319, 320
 of leg, 344
 of thigh, 290
- oblique axial view, of ankle, 359, 361
- sagittal view
 of ankle, 369, 370
 of knee, 305
- Tibial plafond
 coronal view, of ankle, 374, 375, 376
- sagittal view
 of ankle, 366, 367, 368, 369
 of leg, 337
- Tibial plateau, lateral
 axial view, of knee, 299
- coronal view
 of knee, 314, 315, 318, 319
 of leg, 343, 344
- sagittal view
 of knee, 302, 303, 304
 of leg, 335, 336, 337
- Tibial plateau, medial
 axial view, of knee, 299
- coronal view
- Tibial plateau, medial (*Continued*)
 of knee, 313, 318
 of leg, 343, 344
- sagittal view
 of knee, 308, 309
 of leg, 339, 340
- Tibial tubercle
 axial view
 of ankle, 351
 of knee, 300, 301
 of leg, 324
- sagittal view, of leg, 336
- Tibial tuberosity
 coronal view, of knee, 313
- sagittal view, of knee, 306
- Tibialis anterior a.
 axial view
 of ankle, 349, 350, 351
 of leg, 325
- coronal view, of leg, 343, 344
- oblique axial view, of ankle, 360, 361, 362
- Tibialis anterior m.
 axial view
 of knee, 300, 301
 of leg, 324, 325, 326, 327, 328, 329, 330, 331, 332, 333
- coronal view
 of knee, 314, 315, 316
 of leg, 342, 343
- oblique axial view, of ankle, 359
- origin, insertion, and nerve supply of, 322–323t
- sagittal view
 of knee, 303, 304
 of leg, 334, 335, 336
- Tibialis anterior t.
 axial view
 of ankle, 349, 350, 351, 352, 353
 of foot, 385, 386
 of leg, 327, 328, 329, 330, 331, 332, 333
- coronal view
 of ankle, 372
 of foot, 405, 406, 407
 of leg, 342, 343
- oblique axial view, of ankle, 359, 360, 361, 362, 363, 364
- sagittal view
 of ankle, 369, 370
 of foot, 396, 397
 of leg, 336, 337
- Tibialis anterior v., axial view
 of ankle, 349, 350, 351
 of leg, 325
- Tibialis anterior vessels
 axial view, of leg, 324, 326, 327, 329, 330, 331, 333
- coronal view, of ankle, 373
- sagittal view
 of ankle, 367, 368
 of leg, 338
- Tibialis posterior a.
 axial view, of ankle, 349, 350, 351, 352, 353
- coronal view, of ankle, 379
- oblique axial view, of ankle, 361
- Tibialis posterior m.
 axial view
 of knee, 301
 of leg, 324, 325, 326, 327, 328, 329, 330, 331, 332, 333
- coronal view
 of knee, 316, 317, 318
 of leg, 343, 344
- origin, insertion, and nerve supply of, 322–323t
- sagittal view
 of knee, 304
 of leg, 336, 337, 338
- Tibialis posterior t.
 additional slip
 coronal view, of foot, 406, 407
 oblique axial view, of ankle, 362, 363, 364
- axial view
 of ankle, 349, 350, 351, 352, 353, 354, 355
 of foot, 386
 of leg, 325, 326, 327, 328, 329, 330, 331, 332, 333
- coronal view
 of ankle, 372, 373, 374, 375, 376

- Tibialis posterior t. (*Continued*)
 of foot, 407
 of leg, 343, 344
 cuneiform slip
 axial view
 of ankle, 355
 of foot, 386, 387
 sagittal view
 of ankle, 371
 of foot, 396
 oblique axial view, of ankle, 359, 360, 361, 363
 sagittal view
 of ankle, 370, 371
 of foot, 396, 397
 of leg, 337, 338, 339
- Tibialis posterior v., axial view, of ankle, 349, 350, 351, 352, 353
- Tibialis posterior vessels
 axial view
 of ankle, 354, 355, 356
 of leg, 324, 325, 326, 327, 328, 329, 330, 331, 332, 333
 coronal view
 of ankle, 376, 377
 of knee, 319
 oblique axial view, of ankle, 359, 360
- Tibioalcalcanal lig., sagittal view, of ankle, 370
- Tibiofibular joint, proximal
 sagittal view
 of knee, 303
 of leg, 335, 336
- Tibiofibular lig., anterior inferior
 axial view, of ankle, 352
 oblique axial view, of ankle, 360
 sagittal view, of ankle, 365, 366
- Tibiofibular lig., posterior inferior
 axial view, of ankle, 352
 coronal view, of ankle, 377, 378
 oblique axial view, of ankle, 360
- Tibiotalar joint, axial view, of ankle, 352, 353, 354
- Tibiotalar lig.
 anterior, sagittal view, of ankle, 370
 posterior, sagittal view, of ankle, 370
- Toe, 1st (great), proximal phalanx
 axial view, 388, 389
 coronal view, 399
 sagittal view, 397, 398
- Toe, 2nd
 extensor t., sagittal view, 395
 proximal phalanx
 coronal view, 399
 sagittal view, 395, 396
- Toe, 3rd, proximal phalanx
 axial view, 389
 coronal view, 399
 sagittal view, 394
- Toe, 4th
 flexor t., sagittal view, 393
 proximal phalanx
 axial view, 389
 coronal view, 399
 sagittal view, 392
- Trachea
 axial view
 of heart MRI, 460
 of pectoral girdle and chest wall, 7, 8, 9
 of thorax CT, 442, 443
 coronal view
 of heart MRI, 468
 of pectoral girdle and chest wall, 24, 26, 27
 of thorax CT, 454, 455, 456
 sagittal view
 of heart MRI, 465
 of thorax CT, 451
- Tracheal carina
 axial view, of thorax CT, 444
 coronal view, of thorax CT, 456
- Transverse acetabular lig.
 axial view, of hip arthrogram, 254, 355
 coronal view, of hip arthrogram, 262, 263, 264, 265
 sagittal view, of hip arthrogram, 260, 261
- Transverse cervical vessels
 axial view, of pectoral girdle and chest wall, 5
 coronal view, of pectoral girdle and chest wall, 28, 29
- Transverse humeral lig., axial view, of shoulder, 42, 43
- Transverse meniscal lig.
 coronal view, of knee, 313
 sagittal view, of knee, 306
- Transverse process
 axial view
 of lumbar spine, 425
 of thoracic spine, 415, 416
 coronal view, of thoracic spine, 421
- Transversospinalis m.
 axial view, of thoracic spine, 415, 416
 coronal view, of thoracic spine, 421
 sagittal view, of thoracic spine, 418
- Transversus abdominis m.
 axial view
 of abdomen CT, 478, 480
 of abdomen MRI, 498, 499
 of hip, 224
 of male pelvis CT, 522, 523
 of male pelvis MRI, 553
 coronal view
 of abdomen CT, 487, 489, 490
 of female pelvis CT, 547, 548
 of male pelvis CT, 531, 532, 533, 534
 origin, insertion, and nerve supply of, 474t
 sagittal view, of abdomen CT, 481, 486
- Trapezium
 coronal view, of hand, 214, 215, 216
 sagittal view, of hand, 207, 208
- Trapezius m.
 axial view, 36, 37
 of heart MRI, 460
 of pectoral girdle and chest wall, 6, 7, 8, 9, 10, 11, 12, 13
 of shoulder, 36, 37
 of thoracic spine, 415, 416
 coronal view
 of pectoral girdle and chest wall, 27, 28, 29, 30, 31, 32, 33
 of thoracic spine, 420, 421, 422, 423
 oblique coronal view, of shoulder, 56, 57, 58, 59, 60, 61
 oblique sagittal view
 of shoulder, 53, 54, 55
 of shoulder arthrogram, 76, 77
 origin, insertion, and nerve supply of, 412–414t
 sagittal view
 of pectoral girdle and chest wall, 17, 18, 19, 20, 21, 22, 23
 of thoracic spine, 417, 418, 419
- Trapezoid
 coronal view, of hand, 215, 216, 217
 sagittal view, of hand, 207, 208
- Trapezoid lig., coracoclavicular portion, coronal view,
 of pectoral girdle and chest wall, 26, 27
- Trapezotriquetral lig., dorsal, coronal view, of hand,
 216, 217
- Triangular fibrocartilage, coronal view, of hand, 215,
 216, 217
- Triangular space
 coronal view
 of arm, 110
 of pectoral girdle and chest wall, 29
 oblique coronal view, of shoulder, 62
- Triceps brachii m.
 axial view
 of arm, 95, 96, 97
 of elbow, 116
 coronal view
 of arm, 109, 110
 of pectoral girdle and chest wall, 30, 31, 32, 33
 oblique coronal, of elbow, 138, 139
 origin, insertion, and nerve supply of, 91t
 sagittal view
 of arm, 99, 100, 101
 of pectoral girdle and chest wall, 15
- Triceps brachii m., lateral head
 axial view
 of arm, 92, 93, 94
 of elbow, 115
 of pectoral girdle and chest wall, 9, 10, 11, 12
 of shoulder, 45
 coronal view
 of arm, 109, 110, 111, 112
 of pectoral girdle and chest wall, 30, 31
- Triceps brachii m., lateral head (*Continued*)
 oblique coronal view
 of elbow, 141, 142
 of shoulder, 63, 64
 oblique sagittal view
 of elbow, 125, 126, 132
 of shoulder, 49, 50
 sagittal view
 of arm, 98, 99, 100, 101
 of pectoral girdle and chest wall, 14, 15
- Triceps brachii m., long head
 axial view
 of arm, 92, 93, 94
 of elbow, 115
 of pectoral girdle and chest wall, 8, 9, 10, 11, 12, 13
 of shoulder, 43, 44, 45
 of shoulder arthrogram, 71
 coronal view
 of arm, 110, 111, 112, 113
 of pectoral girdle and chest wall, 29, 30, 31, 32, 33
 oblique coronal view
 of elbow, 139, 140, 141
 of shoulder, 62, 63, 64, 65
 oblique sagittal view
 of elbow, 129, 130, 131
 of shoulder, 49, 50, 51, 52, 53, 54
 sagittal view
 of arm, 99, 100, 101, 102, 103
 of pectoral girdle and chest wall, 14, 15
- Triceps brachii m., medial head
 axial view
 of arm, 92, 93, 94
 of elbow, 115
 of pectoral girdle and chest wall, 12, 13
 coronal view
 of arm, 108, 109
 of pectoral girdle and chest wall, 30, 31
 oblique coronal, of elbow, 139, 140, 141, 142
 oblique sagittal view, of elbow, 127, 128, 129
 sagittal view
 of arm, 101, 102, 103, 104
 of pectoral girdle and chest wall, 15
- Triceps brachii musculotendinous unit, coronal view,
 of arm, 109
- Triceps brachii t.
 axial view
 of arm, 95, 96, 97
 of elbow, 115, 116, 117
 coronal view, of arm, 109, 110
 oblique coronal, of elbow, 141, 142
 oblique sagittal view, of elbow, 126, 127, 129, 130, 131
 sagittal view, of arm, 101, 102
- Triceps brachii t., long head
 ABER view, of shoulder arthrogram, 89
 axial view, of shoulder, 44, 45
 coronal view
 of arm, 110
 of pectoral girdle and chest wall, 29
 oblique sagittal view
 of shoulder, 51
 of shoulder arthrogram, 76, 77
- Triceps m., lateral head, axial view, of pectoral girdle
 and chest wall, 9
- Tricipital aponeurosis, axial view, of elbow, 116
- Tricuspid plane, axial view, of heart MRI, 463
- Triquetrum
 coronal view, of hand, 215, 216, 217
 sagittal view
 of hand, 210, 211
 of wrist, 210, 211
- Trochlea
 axial view, of elbow, 117, 118
 femoral
 axial view, of knee, 297, 298
 coronal view, of knee, 311
 oblique coronal, of elbow, 138, 139
 oblique sagittal view, of elbow, 129, 130, 131
 sagittal view, of arm, 100, 101, 102, 103
- Trochlear notch
 oblique sagittal view, of elbow, 129, 130
 sagittal view, of arm, 101, 102
- Tunica albuginea, axial view, of male pelvis MRI,
 558

- U**
- Ulna**
axial view, of elbow, 120, 121, 122, 123, 124
coronal view
 of forearm, 163, 164, 165, 166, 167
 of hand, 216, 217, 218
oblique coronal, of elbow, 139, 140
oblique sagittal view, of elbow, 128, 129
radial notch, axial view, of elbow, 119
sagittal view
 of arm, 101
 of forearm, 159, 160, 161
- Ulnar a.**
axial view
 of elbow, 119, 120, 121, 122, 123, 124
 of forearm, 146, 147, 148, 149, 150, 151, 152, 153, 154, 155
coronal view
 of forearm, 162, 163, 164, 165
 of hand, 214, 215
oblique coronal, of elbow, 136, 137, 138
oblique sagittal view, of elbow, 129
sagittal view, of forearm, 158, 159
- Ulnar a., deep**
axial view, of hand, 198
coronal view, of hand, 215
- Ulnar a., superficial, axial view, of hand, 198, 199**
- Ulnar collateral a., inferior, axial view, of arm, 96, 97**
- Ulnar collateral a., superior, axial view**
of arm, 93, 94, 95, 96, 97
of elbow, 117, 118, 119, 120, 121, 122
- Ulnar collateral lig.**
accessory, coronal view, of hand, 216
axial view
 of elbow, 117, 118, 119
 of hand, 204
coronal view
 of arm, 107
 of hand, 216, 217
- lateral**
axial view, of elbow, 119, 120, 121, 122
oblique coronal, of elbow, 139, 140
oblique sagittal view, of elbow, 126, 127, 128
- oblique coronal, of elbow, 139
oblique sagittal view, of elbow, 132
sagittal view, of hand, 205, 206
- Ulnar head**
axial view, of elbow, 123
oblique sagittal view, of elbow, 131, 132
- Ulnar n.**
axial view
 of arm, 92, 94, 95, 96
 of elbow, 115, 116, 117, 118, 119, 120, 121, 122, 123, 124
 of forearm, 146, 147, 148, 149, 150, 151, 152, 153, 154, 155
coronal view
 of forearm, 162, 163
 of hand, 214, 215
oblique coronal, of elbow, 138, 139, 140, 141
oblique sagittal view, of elbow, 131, 132
sagittal view
 of forearm, 159, 160
 of hand, 210
- Ulnar recurrent a., oblique coronal, of elbow, 138**
- Ulnar sesamoid**
axial view, of hand, 201
sagittal view, of hand, 206
- Ulnar styloid, coronal view, of hand, 216, 217**
- Ulnar tuberosity, oblique sagittal view, of elbow, 130**
- Ulnotriquetral lig., palmar, sagittal view, of wrist, 187**
- Umbilical a., obliterated, axial view, of male pelvis MRI, 555**
- Umbilicus**
axial view
 of abdomen CT, 480
 of male pelvis MRI, 553
coronal view
 of abdomen MRI, 510
 of female pelvis MRI, 580
sagittal view
 of abdomen CT, 483
 of abdomen MRI, 506
 of male pelvis CT, 530
- Uncinate process**
axial view
 of abdomen CT, 479
 of abdomen MRI, 499, 500
coronal view, of abdomen CT, 488
sagittal view, of abdomen CT, 484
- Ureter**
axial view
 of abdomen MRI, 501
 of male pelvis CT, 522, 523, 524
coronal view
 of abdomen MRI, 515
 of female pelvis CT, 548
 of male pelvis CT, 532
sagittal view
 of abdomen MRI, 508
 of male pelvis CT, 529
- Ureterovesicular junction, axial view, of male pelvis CT, 525**
- Urethra**
axial view
 of female pelvis CT, 541, 542
 of female pelvis MRI, 575
 of male pelvis CT, 526
coronal view
 of female pelvis CT, 549
 of female pelvis MRI, 582
 of male pelvis MRI, 565
membranous, axial view, of male pelvis CT, 527
prostatic segment, axial view, of male pelvis MRI, 557
sagittal view
 of female pelvis CT, 545
 of female pelvis MRI, 578
spongiose segment, axial view, of male pelvis CT, 527
- Urinary bladder**
axial view
 of female pelvis CT, 540, 541
 of female pelvis MRI, 574, 575
 of hip, 228
 of male pelvis CT, 525, 526
 of male pelvis MRI, 556
coronal view
 of female pelvis CT, 546, 547, 548, 549, 550
 of female pelvis MRI, 581, 582
 of hip, 244, 245
 of male pelvis CT, 532, 533, 534
 of male pelvis MRI, 566, 567
sagittal view
 of female pelvis CT, 543, 544, 545
 of female pelvis MRI, 576, 577, 578, 579
 of male pelvis CT, 529, 530
 of male pelvis MRI, 561, 562, 563, 564
- Urogenital diaphragm**
coronal view, of female pelvis CT, 550
sagittal view, of male pelvis CT, 529
- Uterine a.**
axial view, of female pelvis CT, 540
coronal view, of female pelvis CT, 550
- Uterine body**
coronal view, of female pelvis CT, 551
sagittal view, of female pelvis CT, 544, 545
- Uterine cervix**
axial view, of female pelvis CT, 540
coronal view
 of female pelvis CT, 551
 of female pelvis MRI, 582, 583
sagittal view
 of female pelvis CT, 544, 545
 of female pelvis MRI, 578, 579
- Uterine corpus, sagittal view, of female pelvis MRI, 578**
- Uterine fundus**
axial view, of female pelvis MRI, 573
sagittal view, of female pelvis CT, 545
- Uterine v.**
axial view, of female pelvis CT, 540
coronal view, of female pelvis CT, 550
- Uterosacral lig., axial view, of female pelvis CT, 540**
- Uterus**
axial view, of female pelvis CT, 538, 539, 540
coronal view, of female pelvis CT, 550
sagittal view, of female pelvis MRI, 579
- V**
- Vagina**
axial view
 of female pelvis CT, 541, 542
 of female pelvis MRI, 574, 575
coronal view
 of female pelvis CT, 549, 550, 551
 of female pelvis MRI, 582, 583
posterior fornix, sagittal view, of female pelvis MRI, 579
sagittal view
 of female pelvis CT, 544, 545
 of female pelvis MRI, 579
- Vagus n., axial view, of thorax CT, 442**
- Valsalva, sinuses of, sagittal view, of heart MRI, 465**
- Vas deferens**
axial view, of male pelvis MRI, 555
coronal view, of male pelvis MRI, 568, 569
- Vastus intermedius m.**
axial view
 of female pelvis CT, 542
 of hip, 230, 231, 232
 of male pelvis CT, 527
 of male pelvis MRI, 558
 of thigh, 269, 272, 273, 274, 275, 276
coronal view
 of female pelvis CT, 548, 549
 of female pelvis MRI, 581, 582
 of hip, 244, 245
 of male pelvis CT, 535
 of male pelvis MRI, 566, 567
 of thigh, 288, 289
origin, insertion, and nerve supply of, 268t
sagittal view
 of hip, 234, 235, 236, 237
 of thigh, 277, 278, 279, 280, 281
- Vastus intermedius t., axial view, of thigh, 270, 271, 275, 276**
- Vastus lateralis m.**
axial view
 of female pelvis CT, 542
 of female pelvis MRI, 575
 of hip, 228, 229, 230, 231, 232
 of knee, 295, 296
 of male pelvis CT, 526, 527
 of male pelvis MRI, 557, 558
 of thigh, 269, 270, 271, 272, 273, 274, 275, 276
coronal view
 of female pelvis CT, 548, 549, 550
 of female pelvis MRI, 581, 582
 of hip, 244, 245, 246
 of knee, 313, 314, 315
 of male pelvis CT, 534, 535
 of male pelvis MRI, 566, 567, 568, 569
 of thigh, 286, 287, 289, 290, 291
origin, insertion, and nerve supply of, 268t
sagittal view
 of hip, 233, 234, 235
 of knee, 302
 of thigh, 277, 278, 279, 280
- Vastus medialis m.**
axial view
 of knee, 295, 296
 of thigh, 273, 274, 276
coronal view
 of knee, 311, 312, 313, 314, 315, 316
 of thigh, 288, 289, 290
origin, insertion, and nerve supply of, 268t
sagittal view
 of knee, 307, 308, 309, 310
 of thigh, 281, 282, 283
- Ventricle**
left
 axial view
 of heart MRI, 462, 463
 of thorax CT, 446, 447
 coronal view
 of abdomen CT, 488, 490
 of abdomen MRI, 512
 of heart MRI, 467, 468
 of thorax CT, 453, 455
 sagittal view
 of abdomen CT, 481, 482, 483
 of heart MRI, 464
 of thorax CT, 449, 450, 451

Ventricle (*Continued*)

- right
 - axial view
 - of heart MRI, 462, 463
 - of thorax CT, 446, 447, 448
 - coronal view
 - of abdomen CT, 487, 488, 490
 - of heart MRI, 467, 468
 - of thorax CT, 453
 - sagittal view
 - of abdomen CT, 481, 482
 - of heart MRI, 464, 466
 - of thorax CT, 449, 450, 451
- Ventricular cavity
 - left
 - coronal view, of heart MRI, 468
 - sagittal view, of heart MRI, 464
 - right, sagittal view, of heart MRI, 465
- Ventricular myocardium, left
 - coronal view, of heart MRI, 468
 - sagittal view, of heart MRI, 464
- Ventricular outflow tract, right, sagittal view, of heart MRI, 464
- Ventricular papillary m., left, coronal view, of thorax CT, 454
- Vertebra, thoracic
 - coronal view, of pectoral girdle and chest wall, 28
 - sagittal view, of thoracic spine, 419

- Vertebral a.
 - axial view
 - of pectoral girdle and chest wall, 4
 - of thorax CT, 442
 - sagittal view, of lumbar spine, 431
- Vertebral body
 - axial view
 - of heart MRI, 460, 462
 - of pectoral girdle and chest wall, 9, 10, 11, 13
 - coronal view
 - of abdomen MRI, 513, 514, 515
 - of heart MRI, 468, 469
 - of pectoral girdle and chest wall, 29, 30
 - of thorax CT, 457
 - sagittal view
 - of abdomen MRI, 505, 506, 507
- Vertebral v.
 - axial view, of thorax CT, 442
 - sagittal view, of lumbar spine, 431
- Vertebral vessels, thoracic
 - axial view, of thoracic spine, 415
 - sagittal view, of thoracic spine, 418
- Vestibule, axial view, of female pelvis CT, 542
- Volar plate
 - axial view, of hand, 202, 204
 - coronal view, of hand, 214, 215, 216
 - sagittal view, of hand, 205, 207, 208, 209, 210, 211, 212, 213

X

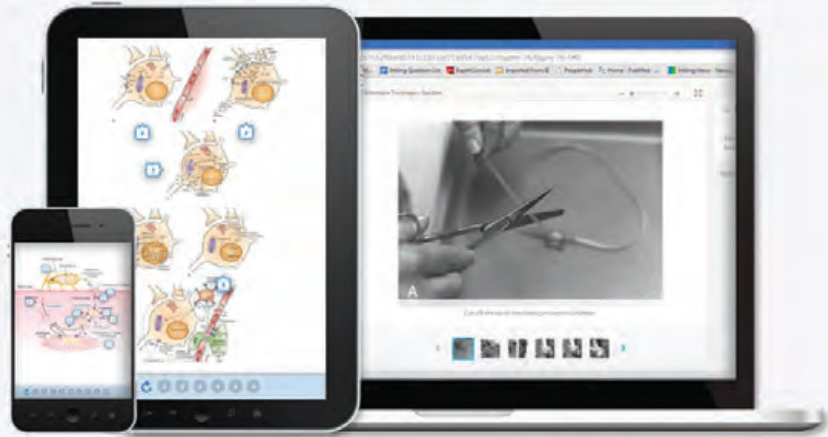- Xiphoid process
 - axial view
 - of abdomen MRI, 496
 - of thorax CT, 446, 447
 - coronal view
 - of abdomen CT, 487
 - of abdomen MRI, 510
 - of heart MRI, 467
 - sagittal view
 - of heart MRI, 465
 - of thorax CT, 451

Z

- Zona articularis, coronal view, of hip arthrogram, 266
- Zona orbicularis
 - axial view, of hip arthrogram, 253, 254, 255, 256
 - coronal view, of hip arthrogram, 263, 264, 265, 266
 - sagittal view, of hip arthrogram, 257, 258
- Zygapophyseal (facet) joint, sagittal view, of thoracic spine, 418, 419

Any screen. Any time. Anywhere.

Activate the eBook version
of this title at no additional charge.



Expert Consult eBooks give you the power to browse and find content, view enhanced images, share notes and highlights—both online and offline.

Unlock your eBook today.

- 1 Visit expertconsult.inkling.com/redeem
- 2 Scratch off your code
- 3 Type code into “Enter Code” box
- 4 Click “Redeem”
- 5 Log in or Sign up
- 6 Go to “My Library”

It's that easy!

Scan this QR code to redeem your eBook through your mobile device:



Place Peel Off
Sticker Here

For technical assistance:
email expertconsult.help@elsevier.com
call 1-800-401-9962 (inside the US)
call +1-314-447-8200 (outside the US)

ELSEVIER

Use of the current edition of the electronic version of this book (eBook) is subject to the terms of the nontransferable, limited license granted on expertconsult.inkling.com. Access to the eBook is limited to the first individual who redeems the PIN, located on the inside cover of this book, at expertconsult.inkling.com and may not be transferred to another party by resale, lending, or other means.